How to Prevent and Treat Exuberant Granulation Tissue

Richard P. Hackett, DVM, MS, Diplomate ACVS

Author's address: Department of Clinical Sciences, College of Veterinary Medicine, Cornell University, Ithaca, NY 14853; e-mail: rph2@cornell.edu.

1. Introduction

Wound overhealing through formation of exuberant granulation tissue may substantially complicate healing of limb wounds in horses.[1] Formation of granulation tissue through fibroplasia is an essential component of wound healing. Granulation tissue is important to fill wound defects, to cover exposed tendon, bone, and other vital structures, and to provide a substrate for epithelial migration and is essential for wound contraction. Ideally, granulation tissue proliferation stops when the wound defect has filled to the surface and epithelial migration and contraction commence as the main healing mechanisms. Unfortunately, in some horses, granulation tissue proliferation continues unabated, leading to exuberant granulation tissue (EGT). EGT characteristically is raised above the wound surface, irregular, chronically inflamed, contracts poorly due to fibrosis, and is a physical barrier to wound epithelialization.

Recent studies comparing healing of distal limb wounds to body wounds and the healing of wounds in horses compared with ponies have begun to improve our understanding of this problem.[2] In both comparisons, the initial inflammatory response to wounding in horse limb wounds is weak and persists much longer as a chronic inflammatory response. Alterations in cytokine profiles as a result of chronic inflammation lead to high levels of pro-fibrotic mediators and reduced levels of cytokines responsible for differentiation of fibroblasts into the myofibroblasts necessary for wound contraction. The outcome is inefficient wound contraction and ongoing fibroplasia.

Risk Factors for EGT

EGT is primarily a problem of the distal limb (carpus/tarsus and below) of horses. High movement areas such as the dorsum of the tarsus or fetlock, exposed flexor tendons, and heel bulbs are at higher risk.[1] Large-breed horses are at higher risk than ponies or smaller breeds.[1] EGT is more likely to develop in wounds with foreign material, chronic infection, or chronic inflammation.[1] Numerous experimental studies have shown that bandaging or casting limb wounds increases the risk of EGT.[3–6] This is thought to occur because of a change in wound oxygen tension to favor angiogenesis and fibroblast proliferation in bandaged wounds and through irritant effects of wound dressings.

This report describes methods for prevention and treatment of exuberant granulation tissue in equine limb wounds.

NOTES

Fig. 1. Large wound on dorsolateral metatarsus is at high risk for development of EGT because this is an area of increased tissue tension and motion, and the underlying exposed bone will delay healing.

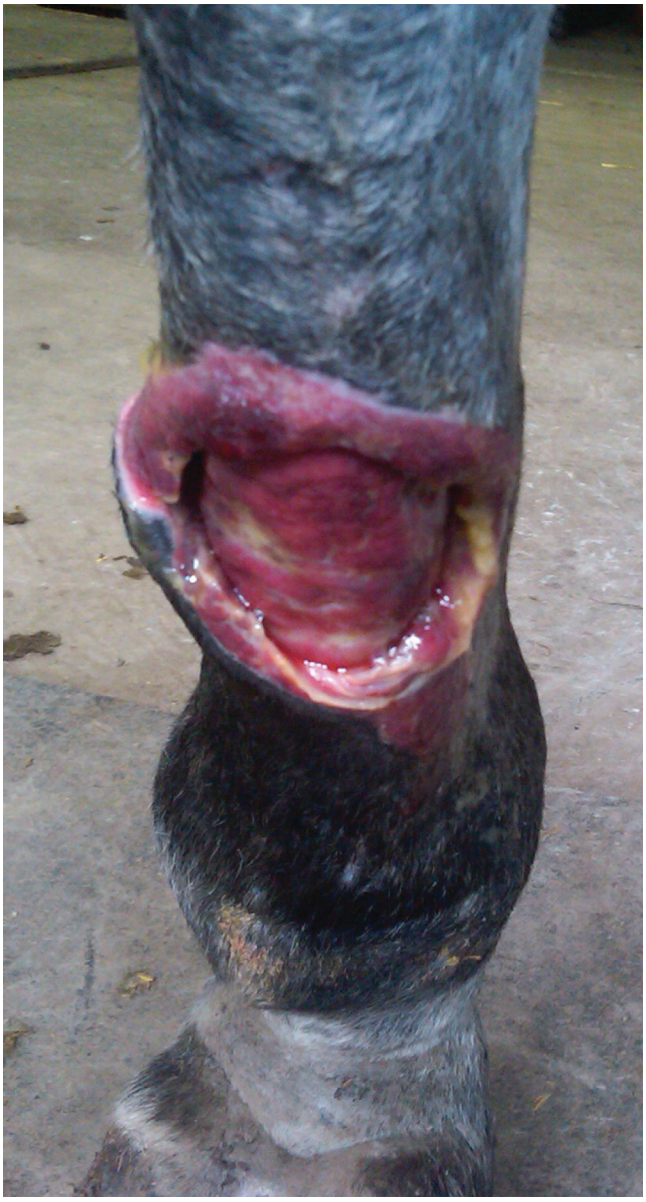

Fig. 2. This wound on the plantar aspect of the distal cannon region is at high risk of EGT due to movement related to the shear of flexor tendons relative to the cutaneous wound.

2. Materials and Methods

Prevention of EGT

EGT is a risk only in those injuries that are healing as open wounds, by contraction and epithelialization. Whenever possible, limb wounds should be closed by a suture technique such as primary closure, delayed primary closure, or secondary closure to avoid EGT and improve the cosmetic and functional outcomes. If a wound cannot be closed due to tissue loss, granulation tissue overgrowth must be carefully controlled during the healing process. Large, open wounds in large-breed horses, particularly those in high motion areas, should be considered at high risk for EGT (Figs. 1 and 2). Initial wound therapy should be similar to that of a wound to be sutured and should focus on controlling infection (regional limb perfusion, systemic antibiotics) and removal of foreign material and damaged tissue (complete wound excision, lavage). The wound should be maintained under pressure bandage and exercise restricted to stall confinement. Daily bandage changes allow wound cleansing and additional debridement if necessary. Granulation tissue will be grossly evident in the wound approximately 5 days after wounding. In large wounds, it may take several weeks to fill the wound bed. As the wound



Fig. 3. Silicone gel wound dressing.

bed fills in with healthy granulation tissue, the bandage can be changed less often (every 2 to 3 days). Once the granulation tissue has filled in the bed to level with surrounding skin, silicone gel dressings[a] are used long term to help reduce the likelihood that granulation tissue will become exuberant (Figs. 3 through 6).[7] These occlusive dressings are placed on the wound surface as the contact layer and are reusable after gentle cleansing in warm water with dishwashing soap at bandage changes. An alternative approach is to bandage the wound only until it has filled with granulation tissue and leave it open thereafter. In either case, wounds must be monitored closely for evidence of tissue exuberance. Any granulation tissue protruding above the surface of the plane of adjacent skin should be removed with a scalpel. This is critical, as neither contraction nor epithelialization are effective in wounds with exuberant tissue. Although contraction is much less effective in distal limb wounds than in wounds of the upper limbs or trunk, most limb wounds will contract to at least some degree (often to a surprising extent). Contraction begins about 10 days after wounding and may last several weeks. Once contraction has stopped, skin grafting is indicated in wounds with a large remaining defect. Epithelialization from the wound margins and tissue grafts, when needed, is then allowed to effect final coverage.

A cast is often placed over high-motion wounds, particularly large wounds of the heel bulbs or flexor tendons, at 2 to 3 days, once the acute risk of infection is over. The cast is maintained for 10 to 14 days, and the wound is then maintained under bandage as described above.

Almost all large, open wounds will develop some exuberance of granulation tissue during the healing process. In most cases, this is readily managed by methods described above. If the tendency toward exuberance is extreme, several issues must be considered. Ensure that excessive motion is not a problem. Evaluate granulation tissue for local infection (culture wound discharge if indicated), and treat appropriately with systemic and regional antimicrobials. Chronic inflammation may contribute to excessive granulation and can be addressed by occasional topical application of corticosteroids (1% hydrocortisone ointment,[b] q 7 days). Last, be aware that neoplastic transformation of open

Fig. 4. Silicone gel wound dressing on a metatarsal wound.

Fig. 5. Granulating wound of the pastern and heel bulb. This wound was initially placed in a cast to stabilize the heel bulb.

Fig. 6. Same horse as Fig. 5 after 6 weeks of silicone gel dressing and bandage. No trimming of granulation tissue was necessary.

wounds in horses, particularly to fibroplastic sarcoid, is well described, and biopsy may be indicated.[8]

Treatment of EGT

The first step in treatment of wounds with exuberant tissue is to determine why tissues developed this problem. Risk factors such as excessive movement, foreign material, bone sequestration, devitalized tendon or ligament, local infection, and chronic inflammation should be identified and addressed. In most cases, there is not a discrete reason for EGT formation. It occurred because of the innate risk factors for the wound to develop EGT coupled with poor wound management.

Wounds with exuberant masses of granulation tissue are addressed by surgical excision (Figs. 7 through 10). This is performed in the standing, sedated horse. Preoperative antibiotics should be given in horses with very large or infected masses. Antibiotics are not used after surgery because virtually all infected tissue is removed by this procedure. The exuberant tissue is surgically prepped, but local anesthesia is not necessary because exuberant granulation tissue is not innervated. Hemorrhage will be controlled by rapid application of a pressure wrap after resection. It is helpful to have

Fig. 7. EGT on lateral aspect of the metatarsus.

Fig. 8. Same wound as in Fig. 7 during excision of exuberant tissue. Bleeding from many small vessels is often profuse but is readily controlled by a pressure bandage. Resection is started distally to prevent blood from obscuring the field of view.

bandage materials open and readily available before starting the resection. Using a No. 22[c] scalpel blade, start at the bottom of the wound and excise exuberant tissues on a plane with surrounding skin. Hemorrhage from numerous small vessels is often substantial, but blood loss can be minimized by working quickly. The pressure bandage is changed the day after resection and additional tissue removed as needed.

After removal of exuberant tissue, the wound is managed as described above—pressure wrap, silicone dressing, wait for contraction, then graft if needed. Many of these wounds have never had an opportunity to go through the contraction phase of healing; it is often remarkable how rapidly they can heal when given the opportunity. Wait until wound contraction has ceased before pursuing tissue grafting.

3. Results

In our hospital, wounds that have previously developed EGT or are at high risk for EGT due to size or location are managed as described above. Silicone gel dressings were used to treat 13 cases in our hospital in the last year. We also recommended them to our referring veterinarians for management of wounds in the field. Our subjective impression is that silicone gel dressings are highly effective in reducing the tendency of large, open limb wounds to develop EGT.

4. Discussion

Silicone gel dressings have been shown to prevent exuberant granulation tissue in experimentally created horse limb wounds.[7] We have used them in our hospital for several years and consider them safe and highly effective in helping to prevent occurrence or recurrence of EGT in open limb wounds. Our initial client cost is ~$70, but the dressings are reusable and can be used for weeks, making them quite cost-effective. Silicone gel dressings are mar-

Fig. 9. Same wound as in Fig. 7, 1 day after excision of exuberant tissue (EGT was removed slightly below the plane of surrounding skin).

Fig. 10. Same wound as in Fig. 7, 28 days later (owner photograph). Wound is healing primarily by wound contraction. Pinch grafts were placed to assist epithelialization.

keted in the human field for treatment of wound overhealing (hypertrophic scar and keloid), with great success.[9–11] These dressings are fully occlusive and appear to occlude microvessels on the wound surface and gradually decrease oxygen tension in the tissues until a point of anoxia, when fibroblasts can no longer function and undergo apoptosis. The ratio of collagen synthesis to degradation is then altered in favor of the latter, thus minimizing fibrosis.

The role of bandaging in the management of distal limb wounds is somewhat controversial. It is generally agreed that bandaging is appropriate during the early phases of healing to keep the wound clean and protect vulnerable tissues from contamination with bacteria and foreign material, protect exposed tissues, absorb wound exudates, control edema of the limb, and provide some degree of immobilization. Once the wound bed has filled with granulation tissue, bandaging is often continued to protect the wound and keep it clean, to prevent desiccation of wound tissues, and to allow topical therapy. Prolonged bandaging has the potential to promote EGT, and several studies have shown that bandages increase the risk of EGT.[3–6] Many of these studies evaluated healing of an excised 2.5 × 2.5 cm experimental wound, a model perhaps not entirely representative of the massive injuries often seen clinically. Regardless, wounds under bandage probably will require more frequent trimming of exuberant tissue than those left open (a problem that might be somewhat alleviated by the use of silicone gel dressings). In practice, bandages are often necessary in management of large traumatic wounds to protect and keep the wound clean, to prevent limb edema, and to reduce motion. If EGT is controlled, the ultimate healing time is not prolonged by bandaging[5,6] and thus it is still commonly used.

References and Footnotes

1. Theoret CL, Wilmink JM. Treatment of exuberant granulation tissue. In: Stashak TS, Theoret C. *Equine Wound Management*. 2nd ed. Ames, IA: Wiley-Blackwell, 2008: 445–462.
2. Wilmink JM, Stolk PWT, van Weeren PR, et al. Differences in second-intention healing between horses and ponies: macroscopical aspects. *Equine Vet J* 1999;31–53.
3. Barber SM. Second intention wound healing in the horse: the effect of bandages and topical steroids. In *Proceedings* Am Assoc Equine Pract 1989;35:107–117.
4. Theoret CL, Barber SM, Moyana TN, et al. Preliminary observations on expression of transforming growth factors ß1 and ß3 in equine full-thickness skin wounds healing normally or with exuberant granulation tissue. *Vet Surg* 2002;31: 266–277.
5. Berry DB II, Sullins KE. Effects of topical application of antimicrobials and bandaging on healing and granulation tissue formation in wounds of the distal aspect of the limbs in horses. *Am J Vet Res* 2003;64:88–92.
6. Dart AJ, Perkins NR, Dart CM, et al. Effect of bandaging on second intention healing of wounds of the distal limb in horses. *Aust Vet J* 2009;215–218.
7. Ducharme-Desjarlais M, Celeste CJ, Leapult E, et al. Effect of silicone containing dressing on exuberant granulation tissue formation and wound repair in horses. *Am J Vet Res* 2005;1133–1139.
8. Knottenbelt DC. Sarcoid transformation at wound sites. In: Stashak TS, Theoret C. *Equine Wound Management.* 2nd ed. Ames, IA: Wiley-Blackwell, 2008:585–608.
9. Carney SA, Cason CG, Gower JP, et al. Cica-Care gel sheeting in the management of hypertrophic scarring. *Burns* 1994;20:163–167.
10. Gold MH, Foster TD, Adair MA, et al. Prevention of hypertrophic scars and keloids by the prophylactic use of topical silicone gel sheets following a surgical procedure in an office setting. *Dermatol Surg* 2001;27:641–644.
11. Kischer CW, Shetlar MR, Shetlar CL. Alteration of hypertrophic scars induced by mechanical pressure. *Arch Dermatol* 1975;111:60–64.

[a]Cica-Care gel sheet. Smith and Nephew. Hull, England.
[b]Hydrocortisone 1%, Qualitest, Huntsville, AL 35811.
[c]Miltex Carbon steel surgical blades, Miltex, Inc., York, PA 17402.