How to Use a Safety Hook Knife to Treat Epiglottal Entrapment in the Horse

Mathieu Lacourt, DVM; and Marcel Marcoux, DVM, MS

Treatment of epiglottal entrapment per nasum on a standing horse can be done with less risk when using a safety hook knife. Authors' address: Montreal University, Large Animal Hospital, 1525 rue des Vétérinaires, Saint Hyacinthe, Quebec J2S 7C6, Canada; e-mail: marcel.marcoux@umontreal.ca (Marcoux).

1. Introduction

Epiglottal entrapment was described as a dorsal displacement of the subepiglottal mucosa with the ary-epiglottic folds through the epiglottis >30 yr ago (Fig. 1).[1] It is a common cause of abnormal respiratory noise and exercise intolerance, especially with racehorses.[2] Some pathologies of the epiglottis, such as hypoplasia, inflammation, and swelling of the subepiglottic tissues, can induce entrapment.[3–5] Epiglottic entrapment may be intermittent or permanent. Short-term epiglottic entrapment may be cured by anti-inflammatory treatments, but most cases will need surgery to improve racing performances.[4]

The goal of the surgery is to free the epiglottis from the mucosa. Several surgical methods have been described in the literature.[4]

Some surgical methods, such as resection through laryngotomy or trans-oral axial[6] division are performed under general anesthesia, thus increasing the risk of complications.[6] Surgeries can also be performed on standing horses when transection can be done with a hook knife,[7,8] a laser,[4,9–11] or by electrocoagulation.[12] Techniques using a laser are relatively safe but require expensive and specialized equipment. Axial transection on standing sedated horses with a hook bistoury can be done per nasum or through the mouth,[13,14] but the risk of iatrogenic laceration is considered important because the blade of the hook knife is not protected. Indeed, if the horse were to move quickly during surgery, the soft palate or other surrounding tissues could easily be cut accidentally. In the case of long-term entrapment, the tissue can be thick and fibrotic, making the incision of tissues more difficult. Such accidental lesions could induce severe complications, especially if there is a laceration of the soft palate.[16] Axial division per nasum is less expensive, faster, and does not require sophisticated instrumentation.

2. Axial Division per Nasum

A retrospective study was performed at the Centre Hospitalier Universitaire Vétérinaire (CHUV) of the University of Montreal. From 1996 to 2007, 33 horses were treated for epiglottal entrapment with a classical hook knife (Figs. 2 and 3). In this study, 29 entrapments were cured with no complications. Overall, there were two superficial wounds of the soft palate, one of the epiglottis and one case of deep laceration of the soft palate, which were registered.

NOTES

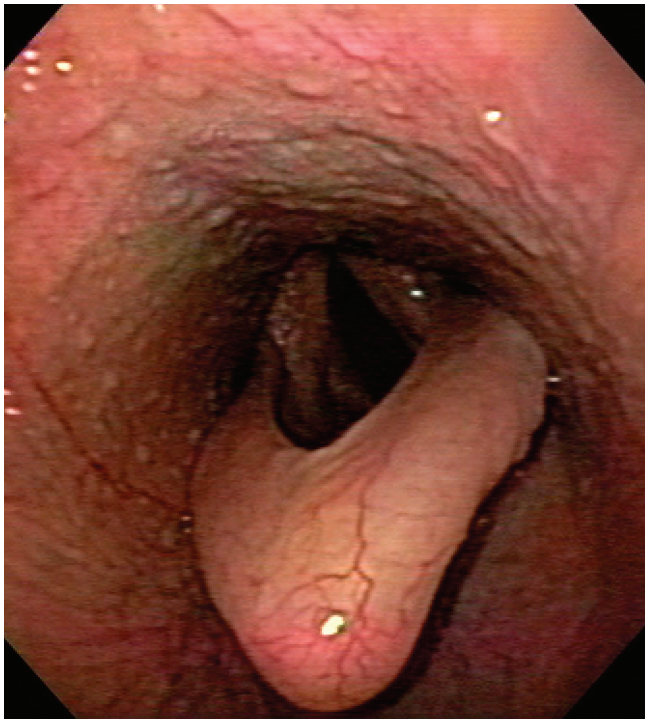

Fig. 1. View of epiglottal entrapment when using a transnasal approach.

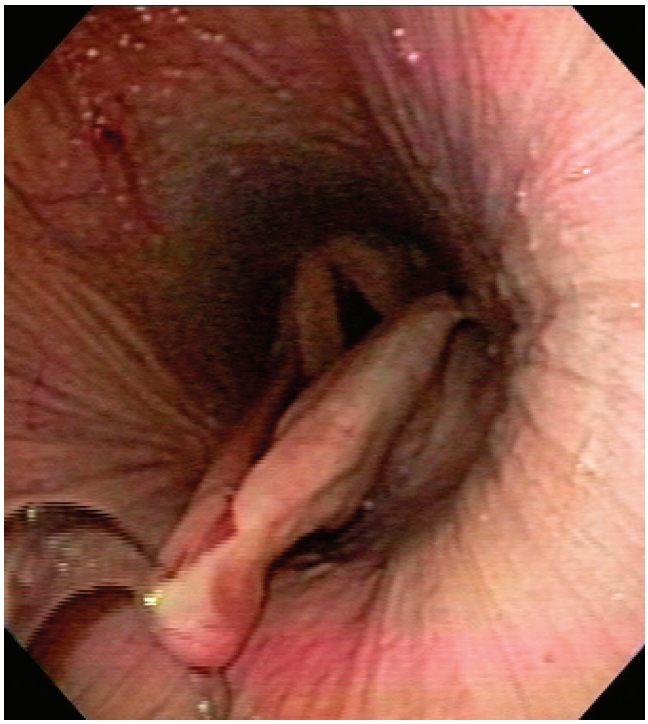

Fig. 3. View of the transnasal approach. When the bistoury is drawn rostrally, the sharp tip of the hook can easily cause injuries to the soft palate.

The limit of the axial division per nasum technique is in fact the dangerous nature of the instrument and the unpredictable reaction of the animal to the surgery. This project aimed to develop a safer hook knife. The idea was to protect the blade with a retractable shield that could protect surrounding tissues when entering, incising, and leaving the upper airways.

3. Materials and Methods

Instrument

A new instrument[a] (Figs. 4–6) had to be designed that would have the same general characteristics as the classical hook knife. The blade would need to have a sharp extremity to easily insert the bistoury through the mucosa before cutting, and the instrument would need to be flexible enough to adapt its curve to the anatomy of each horse. We also had to design a device that would protect the blade and could be opened and closed easily by the surgeon. The knife had to keep all characteristics pertaining to its length, malleability, and strength.

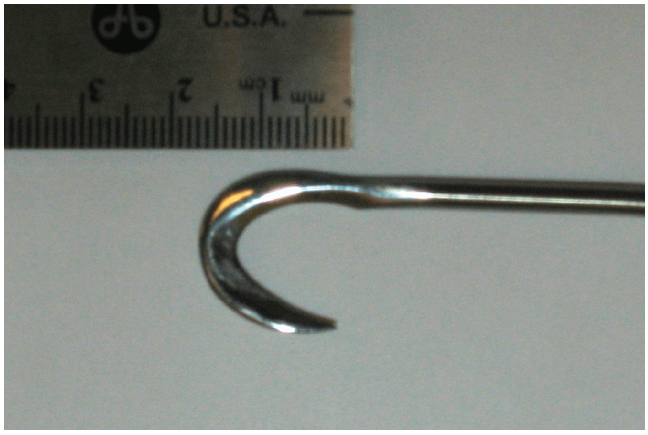

Fig. 2. Classical hook knife.

Horses

Four horses were treated with our new hook knife with shield in 2008. All horses were Standardbreds that were presented for poor performances at high speeds. Horses had been diagnosed with an epiglottic fold entrapment by endoscopic examination by the referring veterinarians. Data recorded included history, physical and endoscopic examination, surgical technique, and post-operative complications. Owners or referring veterinarians were questioned by phone to evaluate the long-term outcome of the surgery.

Surgical Technique

The horses were held in stocks and sedated with xylazine[b] (0.5 mg/kg, IV) and butorphanol tartrate[c] (0.02 mg/kg, IV). Sulfamide trimethoprime[d] (2.5 mg/kg, IV, q 12 h) and phenylbutazone[e] (2.2 mg/kg, IV, q 12 h) were administered. Sixty milliliters of lidocaine[f] was sprayed over the larynx and the nasal

Fig. 4. General view of the hook knife with shield.

cavities through a catheter in the endoscopic canal. A 5-min delay was allowed before introducing the endoscope in one nasum and the hook knife in the other nasum with the shield closed. Once the hook knife was positioned over the epiglottis, the shield was opened by exerting pressure on the handle (Fig. 6), and the hook was positioned under the entrapped tissues on the median axis of the epiglottis and retracted rostrally until the tip protruded from the mucosa. Special attention was paid to assure that the end of the hook pierced the mucosa as near as possible to the tip of the epiglottis to incise the mucosa in its entire length. The shield was closed by releasing the pressure on the handle, and the mucosa was cut with a rostral movement. After the procedure, the epiglottis and the aryepiglottic fold were examined, and the procedure was repeated if needed.

Post-Operative Treatment

Horses received no feed for 4 h after surgery. Sulfamide trimethoprime[g] (5 mg/kg, PO, q 12 h) and phenylbutazone[h] (2.2 mg/kg, PO, q 12 h) were administered for 3 days after surgery, and an anti-inflammatory solution[i] was administered into the pharynx through a catheter through the nose for 5 days. Owners were advised to keep the horses on stall rest for 2 wk before returning progressively to exercise.

4. Results

Horses

Four horses (four mares between 2 and 4 yr of age) underwent standing axial division per nasum with this shielded hook knife to correct epiglottic fold entrapments. Horses were referred for abnormal respiratory noises and poor racing performance. All horses had been endoscopically examined after a race and diagnosed with an epiglottic fold entrapment.

Surgical Procedure

The surgery was successful on all four cases. The ary-epiglottic fold was easily cut on each case, with a surgical time averaging 5 min between the preparation and the section of the epiglottic fold entrapment (Fig. 7). No iatrogenic lesions were observed in the larynx, pharynx, and nasal cavities. The rod of the instrument was easily adapted to the anatomy of each horse. Three entrapments were cut in a single effort, whereas one entrapment needed to be cut twice because of its atypical "V" shape. All horses were controlled endoscopically the day after surgery. Three cases showed no signs of swelling at all. Only one horse showed mild swelling of the epiglottic folds, which resolved within a few days. After 2 wk of rest, all horses were able to return progressively to exercise.

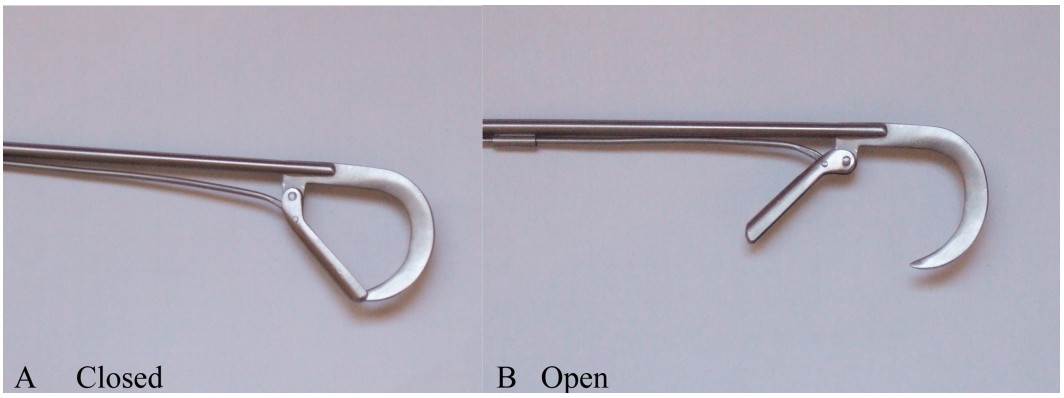

Fig. 5. Extremity of the hook.



Fig. 6. Handle of the hook (squeeze the handle to open the hook).

Follow-Up

The referring veterinarians performed an endoscopic examination on each horse 2 wk after surgery. No recurrence of the entrapment was seen. All horses were judged to have a complete resolution of the epiglottic fold entrapment. Since the surgery, all horses have performed at a similar or higher level.

5. Discussion

The surgical technique that we used with this shielded hook knife is the same as the one used in the past with the classical hook knife. In our clinical experience, axial division per nasum on standing horses has yielded good results despite the few cases of iatrogenic lacerations. A recurrence rate of 5% has already been reported with this technique. This is lower than with electrosurgery, and the same as with the laser.[4,8] Although laser surgery has become popular in recent years, it requires expensive material, and lesions to the epiglottis are possible.

With the classical hook knife, the most critical phase of standing axial division surgery is when the surgeon applies a strong, rostral traction on the instrument to incise the entrapped mucosa. These tissues are often fibrotic and offer strong resistance. When the mucosa is suddenly cut under these conditions, the extremity of the classical hook knife can penetrate and damage the soft palate or other tissues in the area.[16] This possibility is also favored by unexpected movements on the part of the horse.

Based on our experience with this new instrument, we consider the shielded hook knife to be a valuable means of limiting iatrogenic lesions. The two main characteristics of this instrument are its reactivity and the position of the shield. The instrument is based on a spring mechanism so that the hook is maintained closed except when the surgeon applies a deliberate pressure on the handle. The operator has to squeeze the handle to open the extremity of the hook and as soon as there is no pressure on the handle, the shield returns to its protective position. The protection of the shield enables the instrument to slide over the soft palate, therefore avoiding all unwanted contact between the blade and the surrounding tissues. We have observed, through slow motion visualization of endoscopic videos taken during surgery, that the shield of the hook knife stayed in contact with the soft palate during the traction phase of the surgery, therefore protecting the soft palate from the blade of the hook. The hook can be introduced and removed from the upper airways with few risks of trauma because it remains in the closed position during these steps. This shielded hook knife allows for the trans-nasal axial division of subepiglottic tissues entrapping the epiglottis to be done standing with less risk of injury to the horse.

We noted the absence of post-surgical swelling in our limited number of cases. This is probably because of the clean section that we obtained with the bistoury. It has been our clinical experience that a clean section is easier to obtain with a blade than with a laser because the section can be done more quickly with less movement from the horse. The absence of swelling encourages tissues to heal properly, thus reducing the risks of recurrence.

Some authors consider that the oral approach could possibly allow the surgeon to position the bistoury more ventrally in the subepiglottic tissues.[15] It seems logical to think that a longer incision may prevent early healing and recurrence of the condition. The shape of the blade on this shielded hook knife has been designed to have a larger diameter than the classical hook knife, thus making it possi-

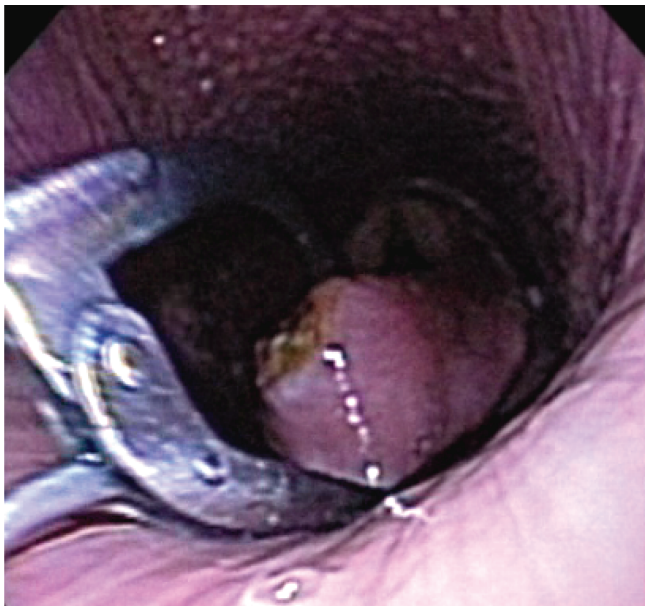

Fig. 7. After loading the mucosa and closing the shield of the knife, incision of the ary-epiglottic fold can be completed safely.

ble to insert it more easily under the mucosa, even with the horse in the standing position.

Procedures done on standing horses avoid the costs and the 0.08% risk associated with general anesthesia.[16] The horses we treated responded well to the sedation and local anesthesia so that we were able to practice the surgery with no difficulty. It has been our experience that a large topical anesthesia of the pharynx, larynx, and nasal cavities is essential for this standing procedure. Another advantage of this technique is that it could be used at the stable.

This shielded hook knife enables the surgeon to benefit from the low cost and recurrence rates associated with the classical axial division per nasum technique and allows the procedure to be accomplished on a standing horse with decreased risk of iatrogenic trauma or injury.

References and Footnotes

1. Boles CL, Raker CE, Weat JD. Epiglottic entrapment by arytenoepiglottic folds in the horse. *J Am Vet Med Assoc* 1978;172:338–342.
2. Brown JA, Hinchcliff KW, Jackson MA, et al. Prevalence of pharyngeal and laryngeal abnormalities in Thoroughbreds racing in Australia, and their association with performance. *Equine Vet J* 2005;37:397–401.
3. Ordidge RM. Epiglottic entrapment in the horse. *Vet Rec* 1977;100:365–366.
4. Stick JA. Larynx. In: Auer JA, Stick JA, eds. *Equine surgery,* 3rd ed. St. Louis: Saunders Elsevier, 2006;566–590.
5. Davenport-Gooddall CLM, Parente EJ. Disorders of the larynx. *Vet Clin North Am [Equine Pract]* 2003;19:169–187.
6. Lumsden JM, Stick JA, Caron JP, et al. Surgical treatment for epiglottic entrapment in horses: 51 cases (1981–1992). *J Am Vet Med Assoc* 1994;205:729–735.
7. Greet TRC. Experiences in treatment of epiglottal entrapment using a hook knife per nasum. *Equine Vet J* 1995;27: 122–126.
8. Honnas CM, Wheat JD. Epiglottic entrapment: A transnasal surgical approach to divide the aryepiglottic fold axially in standing horse. *Vet Surg* 1988;17:246–251.
9. Tate LP, Sweeney CL, Bowman KF, et al. Transendoscopic Nd:YAG laser surgery for treatment of epiglottal entrapment and dorsal displacement of the soft palate in the horse. *Vet Surg* 1990;19:356–363.
10. Tulleners EP. Transendoscopic contact neodymium:yttrium aluminum garnet laser correction of epiglottic entrapment in standing horses. *J Am Vet Med Assoc* 1990;196:1971–1980.
11. Blikslager AT, Tate LP. History, instrumentation and techniques of flexible endoscopic laser surgery in horses. *Vet Clin North Am [Equine Pract]* 2000;16:251–267.
12. Jann HW, Cook WR. Transendoscopic electrosurgery for epiglottal entrapment in the horse. *J Am Vet Med Assoc* 1985;187:484–492.
13. Ross MW, Gentile DG, Evans LE. Transoral axial division, under endoscopic guidance, for correction of epiglottic entrapment in horses. *J Am Vet Med Assoc* 1996;203:416–420.
14. Perkins JD, Hughes TK, Brain B. Endoscope-guided, transoral axial division of entrapping epiglottic fold in fifteen standing horses. *Vet Surg* 2007;36:800–803.
15. Holcombe SJ, Robertson JT, Richardson L. Surgical repair of iatrogenic palate defects in two horses. *J Am Vet Med Assoc* 1994;205:1315–1317.
16. Mee AM, Cripps PJ, Jones RS. A retrospective study of mortality associated with general anesthesia in horses: elective procedures. *Vet Rec* 1998;142:275–276.

[a]Custom instrument, Montreal University (CHUV), St. Hyacinthe, Quebec J2S 7C6, Canada.

[b]Anased, Novopharm, Toronto MIB 2K9, Canada.

[c]Torbugesic, Fort Dodge Animal Health, Fort Dodge, IA 50501.

[d]Trivetrin, Schering Plough, Quebec H9R 1B4, Canada.

[e]Phenylbutazone tablets, Dominion Veterinary Laboratories, Winnipeg, Manitoba R3E 3A1, Canada.

[f]Lurocaine, Vétoquinol N-A Inc., Lavaltrie, Québec J5T 3S5, Canada.

[g]Novotrimel, Novopharm, Toronto MIB 2K9, Canada.

[h]Phenylbutazone tablets, Dominion Veterinary Laboratories, Winnipeg, Manitoba R3E 3A1, Canada.

[i]Pharyngal solution: nitrofurazone 333 mg, prednisolone 333 mg, sulfamethrazine sodique 25% 66.7 ml, DMSO 90% 50 ml, glycérine qsp 500 ml, Gentes and Bolduc, Beaudry St-Hyacinthe, Quebec J2S 8W2, Canada.