The Thoroughbred Racehorse Foot: Evaluation and Management of Common Problems

Scott E. Morrison, DVM

Author's address: Rood & Riddle Equine Hospital, PO Box 12070, Lexington, KY 40580; e-mail: smorrison@roodandriddle.com.

1. Introduction

The importance of foot shape and balance in high-performance racehorses is paramount to maintaining soundness and optimal performance. Functionally adapted for speed and efficient use of energy, the Thoroughbred foot is light and lacks the mass for protection commonly seen in other heavier-boned breeds. The relatively thin walls and soles of the Thoroughbred foot make it more susceptible to injury and hoof capsule distortion. Hoof capsule distortion refers to hoof abnormalities such as flares, cracks, under-run, collapsed, and sheared heels—all of which result from long-term abnormal weight distribution on the foot. Distortions affect function and have been correlated to musculoskeletal injuries and lameness.[1–3]

The racehorse practitioner is often presented with an acute or chronic foot problem to manage. Having knowledge of the etiology of the more common foot problem will help formulate a successful treatment plan to heal the acute condition, return the horse back to soundness, and prevent reoccurrence. Without the proper knowledge of the entire problem, most foot problems are quickly fixed and patched up, and the underlying hoof capsule distortion is never effectively addressed. Therefore, it is likely to reoccur.

Balance is the term used when describing the shape, angle, and spatial arrangement of anatomical structures of the foot. Learning how to evaluate a foot and detect imbalance or overloaded regions of a foot are important for formulating a treatment plan. Although some properties of balance will vary with limb conformation and are subjective, it is generally accepted[4,5] that balanced Thoroughbred feet possess the following characteristics:

- Even distal interphalangeal (DIP) joint space on anterior-posterior standing radiograph
- Straight hoof pastern axis
- Center of the DIP joint or widest part of foot should be located in the center of the weight-bearing surface of the shoe in the sagittal plane
- Palmar angle of pedal bone should be between 2° to 5°
- Heel position should be located at the widest part of the frog
- Heel angle should be within 5° of toe angle
- Solar surface of foot perpendicular to long axis of pastern bone in the sagittal plane
- Even hoof wall growth from all regions of the coronary band

NOTES

Fig. 1. Common racehorse foot with negative palmar angle and thin sole depth at heel.

Fig. 2. Properly glued shoe; note that there is very little glue on the sole, and the frog sulci are not obstructed.

The typical Thoroughbred conformation of a longer, more sloping pastern places more force on the heel region.[6] Repetitive speed training in racehorses decreases hoof angle over time,[7] and, as hoof angle decreases, more stress is placed on the heel region.[6] Therefore, low hoof angles and increased stress on the heel region can become a self-perpetuating cycle if proper intervention is not implemented to reverse the downward trend of the foot (Fig. 1).

The heel region is usually the first part of the foot to display a distortion because it is generally made up of softer, more compliant structures than is the toe. Hoof capsule distortions occur slowly over time and are the result of long-term abnormal weight-bearing.

The horse's foot is capable of handling huge impact forces without structurally collapsing. This is because when a horse is traveling, the moving foot fills with blood during the swing phase, probably from centrifugal force and creating turgor pressure. This fluid in closed spaces may help support the architecture of the foot during ground impact, thus allowing the foot to withstand high impact forces.[8] Most hoof capsule deformities (under-run, collapsed heels) slowly develop over time. The author believes that most of these distortions occur while the foot is semi-static (while the horse is just standing around). Racehorses spend 22+ hours a day standing in a straw-bedded stall. It is during this period that the foot is mostly dependent on the architecture of the foot tissues for support. Long-term, low-magnitude loading creates distortion rather than short-term, high-magnitude force. Horses standing in a stall with little arch/sole support slowly fatigue the integrity of the capsule and propagate distortions. The arch of the sole slowly flattens, the heels become under-run, and perhaps a heel bulb becomes sheared or shunted proximally. The insidious nature of a hoof capsule distortion slowly compromises the foot, rendering it more susceptible to an acute injury.

2. Heel Pain in the Front Limb

In the author's experience, the most common site of heel pain in the racehorse is pain in the medial heel region of the front feet. Pain in this region can originate from a variety of sources: bruising of the sensitive sole, osteitis of the wing of the coffin bone (pedal osteitis), submural pain from sensitive laminae/wall separations, sheared or shunted heels, and quarter/heel cracks. Pain in the medial heel is so prevalent that rarely does the author fail to find sensitivity over the medial heel/bar region on a routine hoof tester exam of a racehorse. The etiology of heel pain in the racehorse is multifactorial; conformation, farriery, track conditions, and management all play major roles. Even though common causes of heel pain can be seen simultaneously as a syndrome, this paper will discuss them separately.

3. Heel Bruise/Stone Bruise

A common reason for a racehorse to be scratched from a race or given time off is for a stone bruise or bruised foot. The author finds this cause of lameness has always been surprising. Racehorses generally are housed, hot-walked, trained, and raced on fairly good footing, with little chance for a stone or hard terrain to directly bruise the foot. Therefore, the term "stone bruise," in most cases, is a misnomer. Bruising of the foot can be caused in three different ways: (1) sole pressure from the shoe or glue. This can be from a shoe that was fitted too small or too tight, creating sole pressure, or from a shoe that has been left on too long, allowing the heels to overgrow or expand over the shoe creating sole pressure. (2) Gluing shoes with acrylic has become common practice in racehorses with brittle, poor-quality walls. Care must be taken in using very little glue and not allowing the glue to set up on the pliable solar surface. The acrylic, once set up, can become very firm, creating sole pressure or pressure on the soft solar heel bulbs. If the glue is allowed too high up the wall near the heel bulb, then, during speed training when the heel bulb compresses, the top edge of the glue can pinch the heel bulbs, creating soreness (Fig. 2).

The third cause of a heel bruise is an excessive heel check on the shoe. That is, the branches of the

Fig. 3. A, Properly fitted race plate, with heel checks and unobstructed frog sulci. B, Race plate fitted too tightly in the heels, with no heel checks. The frog sulci are obstructed and likely to trap dirt, causing bruising.

shoe wrap around too tightly, covering up the medial and lateral sulci of the frog and don't allow clearance of the footing through the sulci. The branch of the shoe will allow footing to ball up and become tightly compacted as it is forced into the sulci at high speeds during the sliding phase of impact. Rapid deceleration of the foot will drive the track substrate into the sulci like a wedge, creating bruising. This is



Fig. 4. A, Shoe with a stabilizer pad welded in for support and protection. B, Heartbar welded into a steel training plate. C, Onion heel shoes, used to protect the bars. D, Unilateral onion heel, used to protect the wing of the pedal bone and bar.

probably the most common cause of medial heel bruising (Fig. 3). Repetitive bruising of the sole or an acute severe bruise can cause inflammation of the bone (pedal osteitis). Pedal osteitis is most successfully diagnosed by nuclear scintigraphy or magnetic resonance imaging, which can show active inflammation and edema. Less accurate diagnostics are radiographs that may show the chronic change of demineralization and loss of the normal, smooth contour of the solar border of the pedal bone (Fig. 4). This, along with positive response to hoof testers and diagnostic analgesia, is probably sufficient to make a diagnosis in a young horse; however, it is questionable how accurate the radiographic changes are without the aid of diagnostics that show the physiology of acute inflammation.[9]

Pedal osteitis can be seen more commonly in the heel region of a low-heeled foot, but it can also be seen in the toe region, particularly in upright or club-footed horses. Severe trauma to the margins of the pedal bone can cause marginal rim fractures. These cases are typically severely acutely lame and then improve over a few days with stall rest. These horses require at least 60 to 90 days of rest to heal before being gradually reintroduced back into training. Shoeing is for protection, shock absorption, and ease of the breakover, and to decrease tension on anterior laminae against the bone fragments in the toe region. A wide web shoe, or a shoe and pad, with a rolled/rockered toe are indicated. For pedal osteitis of the palmar/plantar process, a shoe with protection of the heel quarters is indicated. Shoe with pad, stabilizer plate, onion heel shoe, or bar shoe are indicated. Once the inflammation has resolved, most cases will require special shoeing when they go back into training because reoccurrence is very common. Training in an onion heel shoe, bar shoe, or spider plate is usually effective.

Fig. 6. Outward rotation of the front limbs. Note the white hairs on the inside of the right front fetlock from interference.

4. Shunted Heel/Sheared Heel

By far the most frustrating hoof problem in the racehorse is the reoccurring quarter crack. Often the author hears about a quarter crack hampering the ability of a Triple Crown or other high-profile race contender. Quarter cracks are almost always preceded by a shunted or sheared heel hoof capsule distortion (Fig. 5). The quarter or heel crack is an acute episode that results from the more insidious, slowly developing condition of the sheared/shunted heel. A shunted or sheared heel is when one heel bulb is displaced proximally. This condition is most commonly the result of long-term overloading of the medial heel quarter. This condition has been described in horses with a base narrow, outward rotational limb deformity; creating the ground reaction force to shift medially during the landing/support phase. These cases typically strike on the lateral aspect of the foot and then load medially, However, in the author's experience, sheared heels are seen more commonly in racehorses without outward rotation of the limb. Horses with severe outward rotation usually interfere, which commonly affects performance. Sheared heels in upper-level racehorses are more commonly seen in horses that are slightly carpal valgus and have an inward rota-

Fig. 5. Sheared medial heel.

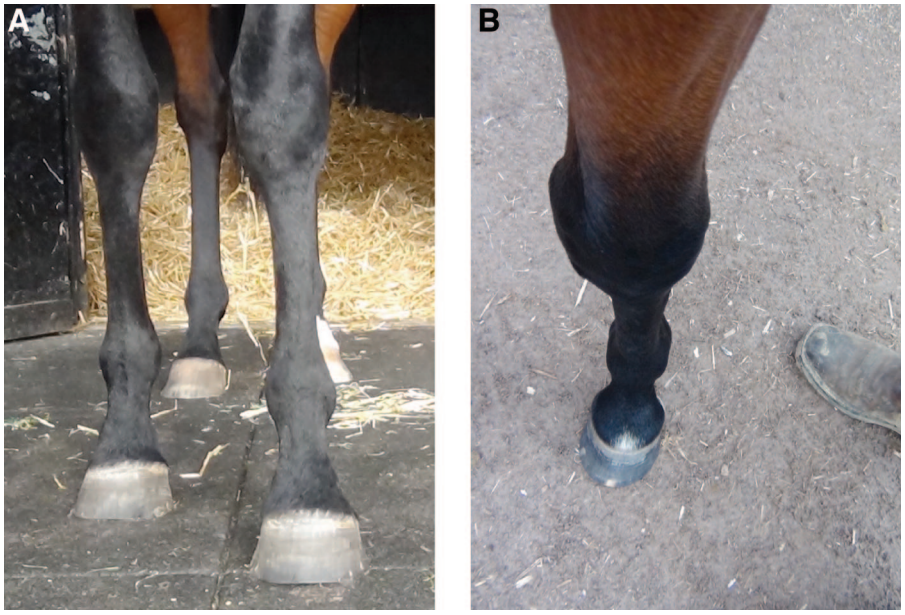

Fig. 7. A, Front view of the left front limb with slight carpal valgus and inward rotation of the pastern. B, Left front limb with slight carpal valgus and inward rotation of the distal cannon bone and pastern.

tion of the distal limb (emanating from the distal metacarpus or pastern). Carpal valgus conformation has been shown to shift the center of pressure medially,[10] and the inward rotation of the distal limb turns the hoof like a dial, putting the medial heel more in line with the center of force, or directly beneath the cannon bone (Fig. 6). This combination of conformation faults is very common in high-level, successful racehorses. However, it puts increased compressive forces on the medial heel, shunting or displacing it proximally. The increased compression on this region of the foot slows wall and sole growth medially, causing the foot to easily grow out of balance between shoeing cycles. It is very common for these feet to be high on the lateral side and low medially when viewed from the solar surface (Fig. 7). Radiographs taken before trimming and shoeing typically show the coffin bone low medially, especially when evaluated several weeks after shoeing and trimming.

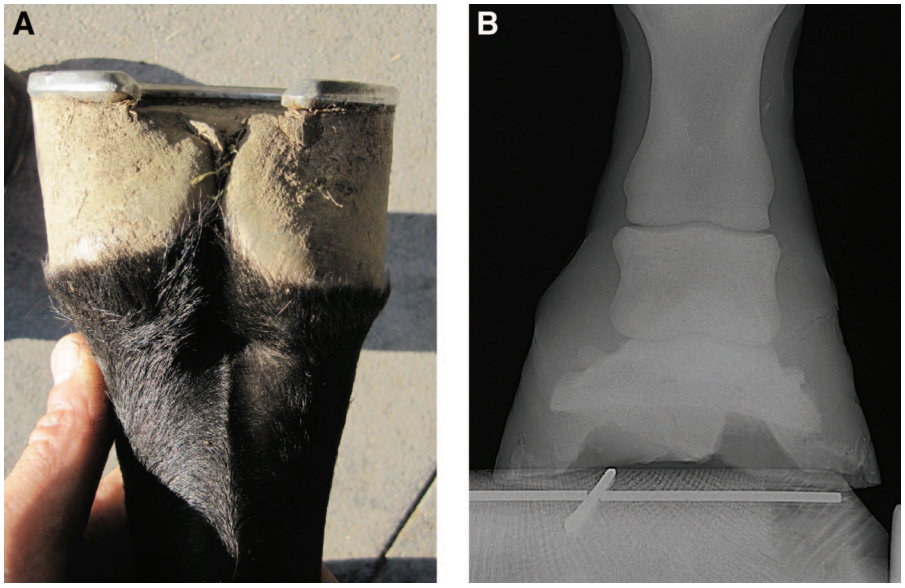

Fig. 8. A, Medial sheared heel that is also out of balance and high laterally. B, Radiograph of a medial sheared heel case that is high laterally.

Fig. 9. A, Case with slight carpal varus and significant inward rotation of the pastern on the right front. B, Same case, viewed from the front; note the offset appearance of the hoof and pastern. C, Radiograph of the same right front foot.

Since 2010, the author has examined 72 sheared heels on Thoroughbred racehorses and recorded the conformation of the limb, with photographs taken directly dorsal to the carpus of each leg affected. Of the 72 sheared heels on the front feet, 70 sheared heels were medial and two were lateral. Both cases with laterally sheared heels were fetlock varus. Of the 70 medially sheared heels, 60 had a combination of carpal valgus and inward rotation of the distal limb, eight had outward rotation of the limb, one had fetlock valgus, and one had normal conformation (no major conformation fault). Therefore, conformation is very likely to be involved in the development of a sheared heel.

In the hind end, it is more common to see sheared heels and subsequent quarter crack in the lateral heel. This is more common in horses that are base narrow behind and/or fetlock varus in the hind end. It appears that sheared heels and quarter cracks are most common in the better horses, as higher speed increases ground reaction forces on the foot (the better horses strike the ground harder).[11]

Management of the sheared heel is key in maintaining soundness and preventing the occurrence of quarter cracks. Patching the quarter crack has been described in detail elsewhere and is not covered in this report. Keeping the foot trimmed and balanced is fundamental. Trimming and shoeing on a shorter 3-week schedule may be necessary to prevent severe imbalances. The sole surface of the foot is typically divided into quadrants or quarters (medial/lateral toe quarters, medial/lateral heel quarters). If the toe (quarters) are left long, more force is placed on the heel quarters. If the lateral toe and heel quarters are left high, the medial half of the foot is loaded. Although studies show that artificially elevating the lateral aspect of the hoof shifted the center of pressure laterally, it is unknown if this holds true in cases that naturally grow faster laterally and grow out of balance. In practice, the author sees more signs of compression and damage on the medial side as the lateral wall grows higher and the foot becomes more imbalanced. Therefore, to unload the medial quarter, the author trims the toes as short as possible and lowers the lateral heel so that the solar surface of the foot is perpendicular to the long axis of the pastern. It is important to fit with a shoe that is centered on the coffin joint, so that the widest part of the foot is in the center of the shoe and the heel of the shoe is at least at the widest part of the frog. Too much length of the toe combined with a medial-lateral imbalance can overload the medial quarter. Because the sheared heel results from overloading and displacement of the hoof

Fig. 10. Foot trimmed and shod perpendicular to the long axis of the pastern.

Fig. 11. A, The two-part elastomer is mixed and applied to the sole surface of the foot. B, It is then wrapped onto the foot, and the horse stands on a flat surface until elastomer sets up. C and D, The orthotic is removed and trimmed up so that it can easily be inserted and removed daily.

wall/heel bulb, methods to unload and allow the wall to drop back down are necessary for successful management. This can be performed most effectively with the use of a heartbar, bar shoe, or stabilizer plate, which transfers weight onto the base of the frog (Fig. 8). The wall beneath the sheared heel can then be floated off the shoe so that the displaced wall can drop down. Many trainers do not like the added weight and decreased traction created with a bar shoe; therefore this shoeing prescription sometimes can have poor compliance. One option is to train in the bar shoe and switch to a normal race plate on race day or shortly before. Another option used in the author's practice with significant success is the use of temporary orthotics. This is when a two-part elastomer dental impression putty[a] is used to make a custom orthotic or arch support for each foot. The removable orthotics are placed into the feet and wrapped in place with Vetwrap[b] (Fig. 9). The orthotics can be removed for training and placed back in the foot when the horse is in the stall. The orthotics provide arch support and help unload the perimeter wall to strengthen the arch and allow the shunted wall to drop. Bar shoes or temporary orthotics, combined with shortened balanced trimming intervals, have significantly decreased the occurrence of quarter cracks and improved the sheared heels in the author's practice. Although not always feasible, letting these cases go barefoot when possible is very effective in improving the sheared heel. Often the medial heel sole depth is so thin that these cases need shoes to resume training.

5. Pedal Bone Fractures

Secondary to weak heel structures and high loads placed on the heels is trauma to the coffin bone, including fracture of the wing. Wing fractures are the most common pedal bone fracture the author sees in the Thoroughbred racehorse. It has been reported that wing fractures are more common laterally in the left front and medially in the right front.[2,6] However, in the author's experience, lateral wing fractures are more commonly seen in the right and left front feet. This could be because most horses land lateral heel first at higher speeds, and fractures of the wing may occur during initial impact. Clinical signs are acute severe lameness. Radiographs taken usually show the fracture line immediately. Occasionally, the fracture line is not evident until there is demineralization and lysis at

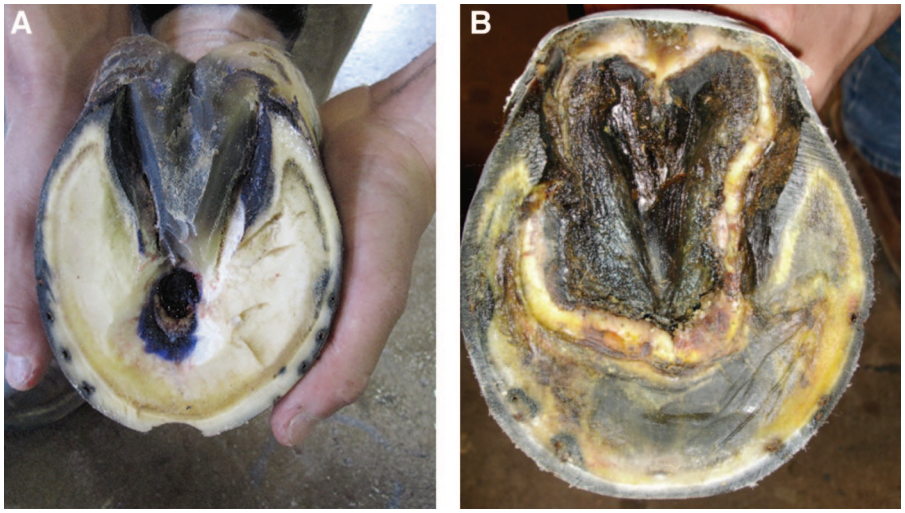

Fig. 12. A, Chemical burn to the sole region. This burn extended down to the solar surface of the pedal bone and required surgical debridement to heal. B, Chemical burn to the frog, which involved the digital cushion, deep digital flexor tendon, and navicular bone. This horse was euthanized.

the margins of the fracture. If a diagnosis is not evident on initial radiographs and a fracture is suspected, then follow-up radiographs are usually repeated in 3 to 5 days. Most wing fractures require 6 to 8 months to heal. Treatment consists of bar shoe with sole support or a wall cast. Most cases are stall rested for 2 to 3 months and hand-walked until the fracture has healed. Some cases will not heal completely and may only heal with a fibrous union, in which a radiolucent line persists. Adequate stabilization with shoeing and stall rest will probably result in radiographic healing.

6. Subchondral Bone Trauma/Contusions to the Pedal Bone

Cases with contusion to the pedal bone or subchondral bone present similar to a fractured pedal bone. However, follow-up radiographs fail to reveal a diagnosis. Cases are usually diagnosed on magnetic resonance imaging or nuclear scintigraphy. Treatment is shoeing to absorb concussion and protect the solar surface and stall rest, combined with aspirin and isoxsuprine until digital pulses have returned to normal and the horse walks soundly. Some cases may resolve in days and some severe cases can take months.

7. Chemical Burns

Treating infections or exposed sensitive tissue in the foot is not in the scope of this lecture, but mismanagement and topical medication on the sensitive tissue of the foot is so prevalent on the racetrack that it should be mentioned here.

It is very common to see cases that have had sensitive tissue exposed by a subsolar abscess/infection or a quarter crack that has been treated at the racetrack with caustic materials in an effort to "harden" and heal over the defect. Most of the compounds are formulated for treating thrush and contain iodine and formalin and usually contain purple dyes to indicate the presence of medication. These compounds are made to treat superficial infections of the frog and have no place in treatment of exposed sensitive tissue or coria. Many quarter cracks are first treated with these substances to "dry them out" before patching. The iodines and formalin damage the sensitive submural tissues or corium/lamellar, creating scar tissue. This weakened, damaged tissue in the bed of the crack is probably part of the reason for the high prevalence of crack reoccurrence. Similarly, the author has seen numerous cases of exposed corium of the sole chemically burned (Fig. 10). Severe cases can involve the solar surface of the coffin bone and the deep digital flexor tendon, creating career-ending or life-threatening damage (Figs. 11 and 12). Client education in proper use and misuse of topical agents is imperative to prevent misuse of these compounds.[12–26]

References and Footnotes

1. Colahan D, Muir G. Center of pressure location of the hoof with and without hoof wedges. *Equine Exerc Physiol* 1991; 113–119.
2. Dyhre-Poulsen P, Smedegaard H, Roed J, et al. Equine hoof function investigated by pressure transducers inside the hoof and accelerometers mounted on the first phalanx. *Equine Vet J* 1994;26:362–366.
3. Eliashar E, McGuigan M, Wilson A. Relationship of foot conformation and force applied to the navicular bone of sound horses at the trot. *Equine Vet J* 2004;36:431–435.
4. Curtis S. Preparing yearlings for sales. In: *Farriery: Foal to Racehorse.* 1999:67–75.
5. Curtis S. The racehorse in training: problems associated with imbalance. In: *Farriery: Foal to Racehorse.* 1999:91–103.
6. Balch O, Clayton H, Lanovaz J. Weight- and length-induced changes in limb kinematics in trotting horses, in *Proceedings.* Am Assoc Equine Pract 1996;42:218–219.

7. Castelijns H. Pathogenesis and treatment of spontaneous quarter cracks quantifying vertical mobility of the hoof capsule at the heels. *Pferdeheilkunde* 2006;5:569–576.
8. Balch O, Ratlaff M, Hyde M, et al. Locomotor effects of hoof angle and mediolateral balance of horses exercising on a high speed treadmill: preliminary results, in *Proceedings*. Am Assoc Equine Pract 1991;37:687–708.
9. Moyer W, O'Brien T, Walker M. Nonseptic pedal osteitis: a cause of lameness and a diagnosis? in *Proceedings*. Am Assoc Equine Pract 1999;45:178–179.
10. O'Grady S. How to Manage a quarter crack, in *Proceedings*. Am Assoc Equine Pract 2010;56:141–147.
11. Peel J, Peel M, Davies H. The effect of gallop training on hoof angle in the Thoroughbred racehorses. *Equine Vet Suppl* 2006;36:43.
12. Anderson TM, McIlwraith CW, Douay P. The role of conformation in musculoskeletal problems in the racing Thoroughbred. *Equine Vet J* 2004;36:571–575.
13. Back W, Clayton H. *The Role of the Hoof and Shoeing: Equine Locomotion*. Toronto: WB Saunders; 2001:135–163.
14. Barrey E. Investigation of the vertical hoof force distribution in the equine forelimb with an instrumented hoofboot. *Equine Vet J* 1990;9:35–38.
15. Balch O, White K, Butler D. How lameness is associated with selected aspects of hoof imbalance, in *Proceedings*. Am Assoc Equine Pract 1993;39.
16. Floyd A. Deformities of the limb and their relevance to the foot. *Equine Podiatry* 2007;263.
17. Hood D. Center of digital load during quasi-static loading. 12th Annual Bluegrass Laminitis Symposium. 1998:47–62.
18. Kane A, Stover S, Gardner I, et al. Hoof size, shape, and balance as possible risk factors for catastrophic musculoskeletal injury of Thoroughbred racehorses. *Am J Vet Res* 1998; 59:1545–1552.
19. Mansmann R, James S, Blikslager A, et al. Long toes in the hind feet and pain in the gluteal region: an observational study of 77 horses. *Equine Vet J* 2010;30:720–726.
20. McKinlay I. Repairing quarter cracks and wall separations. 3rd Annual Promoting Excellence Equine Foot Symposium. 2011:19–22.
21. Moyer W, Anderson J. Sheared heels: diagnosis and treatment. *J Am Vet Med Assoc* 1975;166:53–55.
22. O'Grady S. How to manage sheared heels, in *Proceedings*. Am Assoc Equine Pract 2005;51:451–456.
23. Parks A. The Foot and shoeing. In: Ross M, Dyson S, editors. *Diagnosis and Management of Lameness in the Horse.* Philadelphia, Pennsylvania: Saunders; 2003:250–261.
24. Ratzlaff M, Wilson P, Hyde M, et al. Relationships between locomotor forces, hoof position and joint motion during the support phase of the stride of galloping horses. *Acta Anat* 1993;146:200–204.
25. Thompson K, Cheung T, Silverman M. The effect of toe angle on tendon, ligament and hoof wall strains in vitro. *J Equine Vet Sci* 1993;13:651–653.
26. Van Heel M, Moleman M, Barneveld A, et al. Changes in location of centre of pressure and hoof-unrollment pattern in relation to an 8-week shoeing interval in the horse. *Equine Vet J* 2005;37:536.

[a]Elastomer dental impression putty, NANRIC, Lawrenceburg, KY 40342.
[b]Vetwrap, 3M Animal Care Products, St Paul, MN 55144-1000.