How to Perform a Standing Enucleation

Wendy M. Townsend, DVM, MS, Diplomate ACVO

Author's address: Department of Veterinary Clinical Sciences, Purdue University College of Veterinary Medicine, 625 Harrison Street, West Lafayette, IN 47907; e-mail: townsenw@purdue.edu.

1. Introduction

Enucleation is one of the most frequently performed orbital surgeries.[1] Indications for enucleation include a blind, painful eye; ocular neoplasia; severe corneal or intra-ocular infection; and ocular trauma not amenable to surgical repair. Several publications recommend that equine enucleation only be performed under general anesthesia.[2,3] However, per several recent reports, enucleation can be performed safely on standing horses with appropriate sedation and local anesthesia.[4,5]

The option to perform a standing enucleation allows the surgeon to avoid the risks of general anesthesia including fractures, myositis, and neuropathies. Ocular surgery has been associated with an increased incidence of movement and hypotension during anesthesia followed by difficult or prolonged recovery.[6] These complications probably occur as the result of the deeper plane of anesthesia required to diminish ocular sensation and mobility. Geriatric patients, horses with orthopedic disease, or heavy draft horses therefore might be better candidates for a standing enucleation than an enucleation performed under general anesthesia.

2. Materials and Methods

Case Selection

Not every horse is an appropriate candidate for standing surgery. The horse's temperament or an extremely painful eye might not allow a standing procedure. During the initial assessment of the horse, if the horse will not tolerate an ocular examination after sedation, local nerve blocks, and application of a topical anesthetic, it probably will be difficult to perform enucleation as a standing procedure. Also, an enucleation for neoplasia that requires extensive resection and advanced reconstructive procedures is better performed under general anesthesia.

Positioning

The horse should be placed in stocks. Care must be taken to pad the cheek pieces of the halter with towels or foam to prevent pressure and damage to the facial nerve during surgery. An effective head support can be constructed by inverting the lid of a 50-gallon trash can and setting a foam pad on its top (Fig. 1). The padding prevents trauma to nerves within the muzzle. In the field, a headrest can also

NOTES

Fig. 1. The "table" was created with the use of foam pads and a trash can, on which the horse's head is placed during surgery.

be created with hay bales covered with towels. Cross-ties can be used to position the head. However, the cross-ties often hinder the surgeon's movement, and the halter cheek piece could be pulled into the surgical site. Portable dental rests can be helpful, but some may tip or fall over if the horse lifts its head.

Preoperative Medications and Sedation

An intravenous (IV) catheter is placed in the jugular vein. Flunixin meglumine (1.1 mg/kg IV), gentamicin (6.6 mg/kg IV), and potassium penicillin (22,000 units/kg IV) are administered before surgery. A bolus of detomidine (0.01–0.02 mg/kg IV) and butorphanol (0.01–0.02 mg/kg IV) are administered. Although systemic opioids have been associated with sudden head movements,[3] their addition can reduce responses to touch and provide better antinociception.[7] Muzzle tremors are often not noted unless high doses of opioids are used.[7] Detomidine is then diluted (10 mg detomidine/250 mL lactated Ringer's solution or 0.9% sodium chloride) for use as a constant-rate infusion. Depending on the horse's level of sedation after the initial bolus, the detomidine infusion is initiated at a rate of 0.2–0.4 μg/kg per minute for the first 15 minutes and then decreased to 0.1–0.2 μg/kg per minute for the next 15 minutes. The rate is then typically maintained at 0.1 μg/kg per minute for the duration of the procedure. With the use of a 0.04-mg/mL dilution of detomidine, an infusion rate of 100 mL/h (25 drops per minute for a 15–drops/mL IV set) would be equal to an approximately 0.1–μg/kg per minute dose for a 500-kg horse. If additional sedation is required, the rate can be increased, but typically not more than 0.6 μg/kg per minute is required.[8] The detomidine infusion allows for a more consistent level of sedation without increased levels of ataxia or other side effects.[7] Clipping or injecting local anesthetics should not be performed until the appropriate level of sedation has been reached.[7] If tolerated, cotton balls can be placed in the ears to decrease stimuli from sounds in the environment.

Local Anesthesia

Before local anesthetics are administered, the periocular area should be clipped and prepared for surgery with a 1:50 betadine solution. Before preparing the ocular surface, local nerve blocks should be performed.[9] A retrobulbar nerve block is performed with the use of a 22-gauge, 3.5-inch spinal needle. The orbital fossa is palpated just caudal to the posterior aspect of dorsal orbital rim. The needle is introduced perpendicular to the skin surface and advanced to the extraocular muscle cone (Fig. 2). As the needle is advanced through the extraocular muscles, the eye will deviate slightly dorsally, and a "popping" sensation can be palpated. The plunger is then pulled back to ensure that the needle is not positioned within a vessel; 10 mL of a 50:50 lidocaine and bupivacaine mixture is then injected. This combination is used for its rapid onset and good tissue penetration (lidocaine) and the prolonged duration of action, up to 8 hours, of bupivacaine.[10] The block should take effect within 5–10 minutes. Frontal and palpebral nerve blocks are performed with the same 50:50 lidocaine and bupivacaine mixture. A ring block along the orbital rim is performed to ensure adequate analgesia of the peri-orbital skin. A topical anesthetic (0.5% tetracaine viscous ophthalmic solution) is then applied to the corneal surface to further improve corneal and conjunctival anesthesia. Tetracaine ophthalmic solution is preferred over proparacaine ophthalmic solution because tetracaine better anesthetizes the equine cornea.[11] A 2.5% phenylephrine ophthalmic solution is applied to the ocular surface to constrict conjunctival vessels and thereby decrease bleeding and increase the duration of action of the topical anesthetic. Routine preparation of the globe for surgery is then completed.

Surgery

A transpalpebral or transconjunctival enucleation can be performed. The presence of infection or neoplasia warrants the transpalpebral approach. Oth-

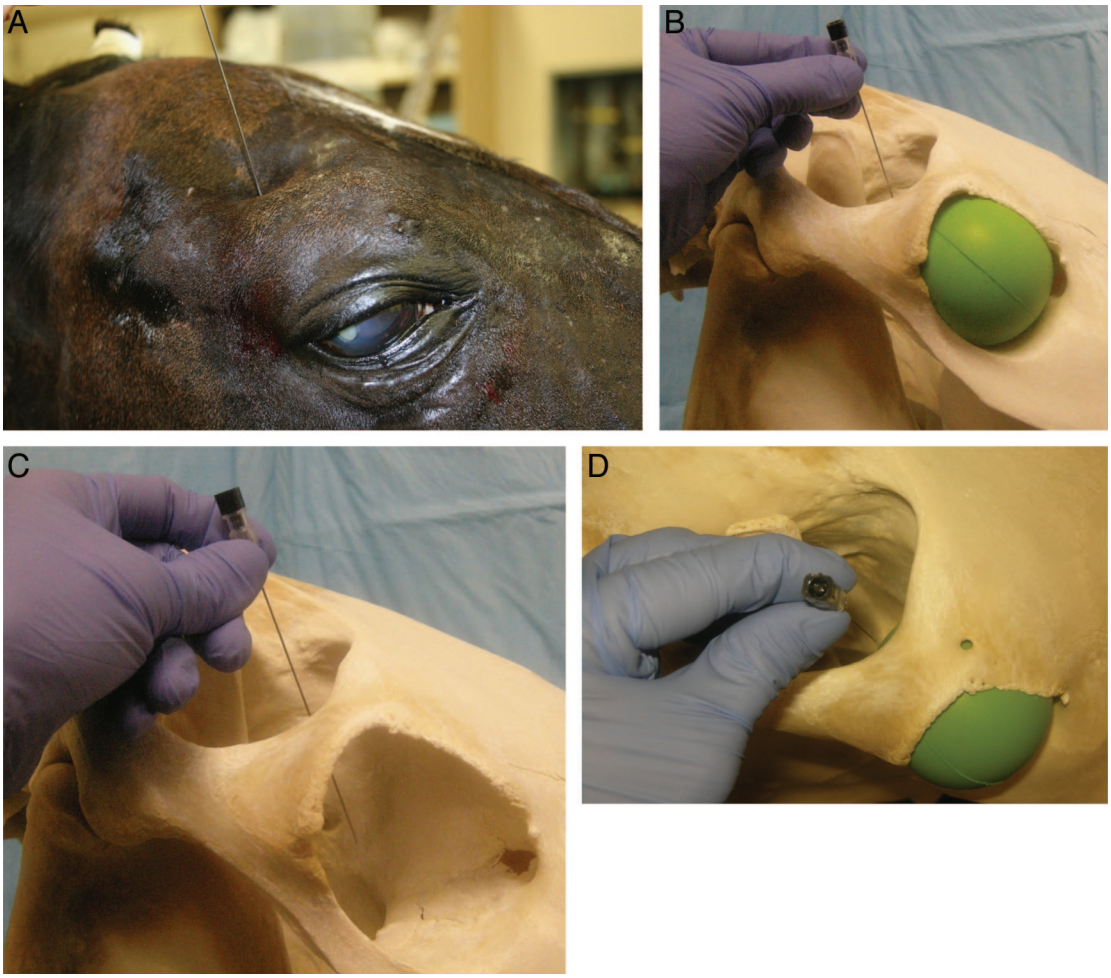

Fig. 2. A–D, Proper needle placement for the retrobulbar nerve block.

erwise, the transconjunctival approach is simpler and allows better visualization with less bleeding throughout the procedure. A drape should be placed over the surgical site. However, some horses, despite sedation, do not tolerate having the ears or contralateral eye covered with the drape. The towel clamps to secure the drape should be placed either within areas that were blocked or hooked to the halter because other facial skin has not been anesthetized. For the transconjunctival approach, an eyelid speculum is used to improve visualization. To better secure the speculum, it can either be supported by an assistant or the hinge can be hooked to the halter with a towel clamp. If the horse becomes reactive during the procedure, the rate of the detomidine infusion can be increased, a bolus of butorphanol or detomidine can be administered, or additional local anesthetic can be infiltrated into the sensitive area. The enucleation is performed the same as under general anesthesia.

Postoperative Care

The detomidine infusion is discontinued. Gauze pads (4 × 4) are placed over the incision site and covered with a stockinette (6-inch) with holes cut out for the ears and remaining eye. The stockinette is secured with an elastic adhesive bandage in a figure-of-8 pattern around the ears and contralateral eye. Usually within 10–20 minutes of discontinuing the detomidine infusion, the horse is able to return to the stall. Flunixin meglumine (1.1 mg/kg IV or PO q 12–24 hours) is continued for 3–5 days after surgery. Antibiotics are used as needed on a case-by-case basis. The bandage is typically removed 1 day after surgery. The horse is usually discharged the day after surgery. Sutures are removed in 10–14 days.

3. Results

Enucleation can be safely and effectively performed in the standing horse with adequate sedation, sufficient local anesthesia, and appropriate restraint. Whereas complications such as orbital abscess formation, retrobulbar hemorrhage, and stimulation of the oculocardiac reflex have previously been reported with the retrobulbar nerve block,[12] complications are rare, and the author has not seen any complications. In the author's experience, place-

ment of surgical drapes and maintenance of a sterile surgical field are slightly more challenging than in the recumbent patient. However, the author has performed more than 30 standing enucleations, with no increase in complication rate compared with enucleations performed under general anesthesia. Most horses stand quietly for the procedure, but if the horse becomes restless or reactive, an increase in the rate of the detomidine infusion, a bolus of butorphanol, or the infusion of additional local anesthetic has been sufficient to allow completion of the surgery.

The author compared the surgical times for 4 enucleations performed standing and 4 performed under general anesthesia. The average surgical times were identical. For the surgeries performed with standing sedation, the total average time from walking the horse into the stocks to the horse returning to its stall was 99 minutes. For the surgeries performed under general anesthesia, the total average time from induction to standing was 158 minutes. The anesthesia and surgery charges for an enucleation performed standing were 66% of the cost of the procedure performed under general anesthesia. However, when the anesthesia and surgery charges were divided by the total time that the staff were with the horse (returned to the stall or standing in the recovery stall), the charges per minute were 105% more for the procedures performed standing.

4. Discussion

In most horses, an enucleation can be performed with standing sedation. However, appropriate case selection is important. Horses requiring extensive surgical resection or with exceptionally painful globes are better candidates for enucleation under general anesthesia. The use of a detomidine constant-rate infusion allows for excellent control of the level of sedation and avoids the marked ataxia that can occur when administration of repeated boluses of sedation are required. Performing an enucleation in the standing horse is straightforward and allows the surgeon to avoid the potential complications associated with general anesthesia. As such, the author prefers to perform enucleation as a standing procedure in the horse unless there are mitigating factors.

References

1. Pierce K, Townsend W. Surgery of the globe and orbit. In: Auer J, Stick J, editors. *Equine Surgery. 4th edition.* St Louis, MO: Elsevier Saunders; 2012:728–743.
2. Gilger B. Diseases and surgery of the globe and orbit. In: Gilger B, editor. *Equine Ophthalmology. 2nd edition.* Maryland Heights, MO: Elsevier Saunders; 2011:93–132.
3. Robertson SA. Standing sedation and pain management for ophthalmic patients. *Vet Clin North Am Equine Pract* 2004; 20:485–497.
4. Hewes CA, Keoughan GC, Gutierrez-Nibeyro S. Standing enucleation in the horse: a report of 5 cases. *Can Vet J* 2007;48:512–514.
5. Pollock PJ, Russell T, Hughes TK, et al. Transpalpebral eye enucleation in 40 standing horses. *Vet Surg* 2008;37:306–309.
6. Parviainen AK, Trim CM. Complications associated with anaesthesia for ocular surgery: a retrospective study 1989–1996. *Equine Vet J* 2000;32:555–559.
7. Ringer S. Chemical restraint for standing surgery. In: Auer J, Stick J, editors. *Equine Surgery. 4th edition.* St Louis, MO: Elsevier Saunders; 2012:253–262.
8. Wilson DV, Bohart GV, Evans AT, et al. Retrospective analysis of detomidine infusion for standing chemical restraint in 51 horses. *Vet Anaesth Analg* 2002;29:54–57.
9. Labelle AL, Clark-Price SC. Local anesthesia for ophthalmic procedures in the standing horse. *Vet Clin North Am Equine Pract* 21 Jan 2013 [Epub ahead of print].
10. Dugdale A. Local anesthetics. In: Dugdale A, editor. *Veterinary Anaesthesia: Principles to Practice.* Malaysia: Blackwell Publishing Ltd; 2010:116–117.
11. Sharrow-Reabe KL, Townsend WM. Effects of action of proparacaine and tetracaine topical ophthalmic formulations on corneal sensitivity in horses. *J Am Vet Med Assoc* 2012;241: 1645–1649.
12. Short CE, Rebhun WC. Complications caused by the oculocardiac reflex during anesthesia in a foal. *J Am Vet Med Assoc* 1980;176:630–631.