Life After Deep Digital Flexor Tenotomies

Raul J. Bras, DVM, CJF, APF

Author's address: Rood and Riddle Equine Hospital, PO Box 12070, Lexington, KY 40580-2070; e-mail: rbras@roodandriddle.com.

1. Introduction

Despite significant research and recent findings over the past decade, a complete understanding of laminitis and its complex pathophysiological processes remain uncertain. Preventative measurements and strategies of this devastating disease remain largely empirical and anecdotal with little information from evidence-based medicine. Recent technological advances offer some promises towards the effective treatment or the rehabilitation process of the laminitic horse. Laminitis can be one of the most frustrating, but rewarding diseases to treat. Anyone interested in working with foot problems in the horse must have an effective strategy for treating the laminitic horse. It is these cases in particular which are in the most need of veterinary expertise. There are a few instances when there is the opportunity to dramatically improve the quality of an animal's life. With the appropriate treatment approach, a large proportion of laminitic horses can be rehabilitated to pasture soundness, light use, and even some degree of athletic performance.[1] However, some advanced cases cannot be rehabilitated to an acceptable level of comfort and therefore euthanasia is advised to prevent needless suffering.

If the distal phalanx continues to displace and/or if the foot fails to show continuous improvement defined as hoof growth with shoeing mechanics alone, oftentimes a deep digital flexor (DDF) tenotomy is warranted. A DDF tenotomy is the fastest way to counteract the forces at play and restore perfusion and tissue mass to the dorsal regions of the foot (Fig. 1). These feet generally respond with significant distal dorsal sole growth at the tip of the coffin bone over 4–6 weeks (Fig. 2).

One of the most significant developments not only in the evaluation and treatment of laminitis but also understanding the mechanics of the foot in general has been the venogram: a simple but technique sensitive procedure that allows visualization of the vascular tree of the foot.[2–4] The venogram has become an invaluable tool that also allows visualization of the effects of pathology and various treatment concepts, making it one of the most valuable tools for diagnosis and treatment strategy.[5] The venogram provides the first detectable evidence that confirms laminitis, clearly distinguishing it from other syndromes with similar clinical signs, and reveals the damaging effects of laminitis earlier in the syndrome than radiographs. Having this information at the time of first clinical signs or shortly thereafter allows a treatment window with the largest response, enhancing the ability to make more timely decisions concerning reversal therapy and also providing a baseline that facilitates monitoring the efficiency of the chosen treatment regimen. This can offer a much more favorable prognosis than wait-

NOTES

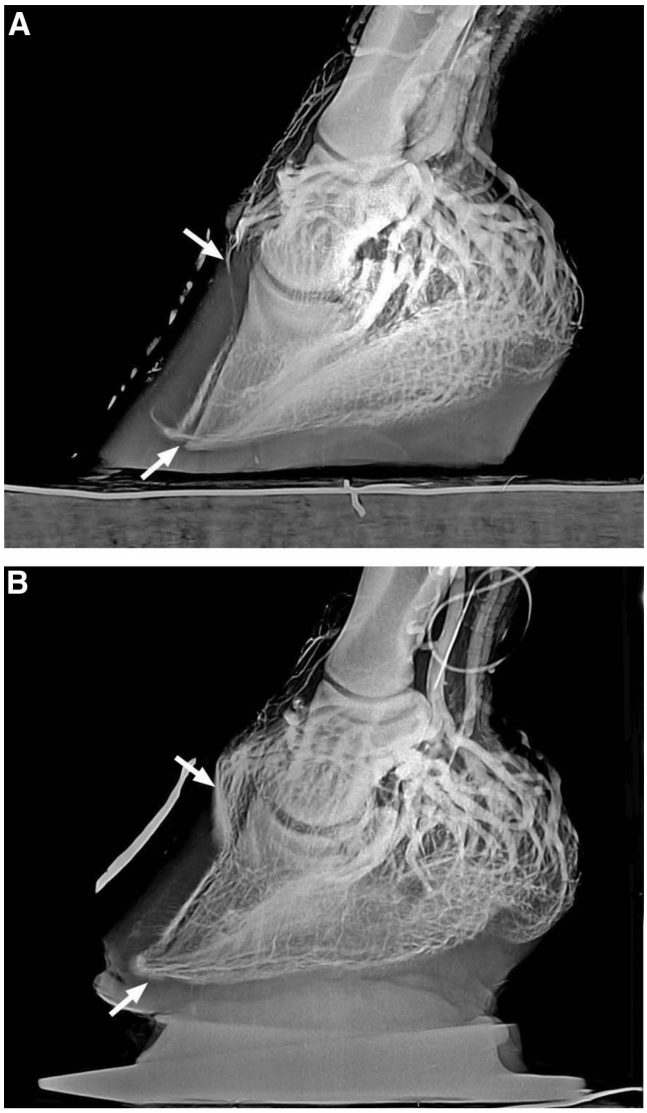

Fig. 1. A, Venogram study before DDF tenotomy with evidence of severe compromised blood supply. The distal phalanx apex has descended distal to the circumflex vessel (arrow) and contrast is absent distal to the apex identifying poor perfusion of the solar plexus and absent terminal papillae. The coronary plexus (arrow) is also compromised with poor perfusion and absent papillae. B, Venogram study 6 weeks post DDF tenotomy shows that contrast has returned to the coronary plexus, and papillae are evident (arrow). The distal phalanx apex and the lamellar-circumflex junction has returned to a normal orientation (arrow). Contrast is slightly reduced distal to the distal phalanx palmar processes. (Images courtesy of Dr. Amy Rucker.)

Fig. 2. A, Horse with derotation/re-alignment shoe and DDF tenotomy. B, Evidence of a positive response to DDF tenotomy 6 weeks later with significant sole growth. C, The ultimate goal has been achieved when health of the coffin bone and re-establishing normal coffin bone alignment with adequate sole depth has been maintained.

ing until radiographic evidence confirms that significant displacement has occurred.

By re-establishing vascular perfusion, the ultimate goal is to maintain health of the coffin bone and eventually re-establish normal coffin bone alignment and adequate sole depth. Transection of the DDF tendon allows immediate re-alignment of the coffin bone in relation to the ground surface. Timing of the DDF tenotomy and re-alignment shoeing procedure is critical. The procedure should be performed before the patient experiences advanced structural failure. The most important

aspect of the procedure is management of the foot. Combination of surgery with the appropriate trim and therapeutic shoeing is imperative for long-term success. Performing the DDF tenotomy without realignment shoeing of the hoof capsule will have a short-term clinical improvement and most likely won't affect the survival rate.[1]

Transection of the DDF tendon is a controversial treatment for chronic laminitis largely because of the variation in personal experience with the procedure and the varying success rates reported in previously published data.[1] Differences in reported success rates are more likely because of the dissimilarities in foot pathology and the foot management associated with the procedure. Outcomes are determined based on the degree of bone disease, solar penetration, degrees of rotation, sinking (distal displacement of the coffin bone but no rotation), number of limbs involved, and front or hind feet affected. There are several issues to consider when making the decision to perform a DDF tenotomy: initial damage assessment, short- and long-term goals of the client, aftercare capabilities and responsibilities of the caretakers, mechanical knowledge, and skill level of the farrier and veterinarian relative to the patient, and financial impact. The DDF tenotomy has often been viewed merely as a salvage procedure. It is only considered late in case management and is often performed without considering the benefits of repositioning the palmar/plantar (herein referred to as palmar) and the articular surface of the coffin bone with healthy load zones. However, if performed early in case management, at the first indication that the vascular supply is not responding to optimum mechanics before permanent damage occurs, the DDF tenotomy can greatly enhance the prognosis by increasing the potential for rapid vascular reperfusion to severely compressed areas. This can preserve the integrity of the palmar rim and optimize solar and tubular papillae function, which accelerates sole and horn growth.

Transection of the DDF tendon as a treatment for chronic laminitis has been reported with variable success rates in the previously published data. Eastman et al[6] reported the results of 35 cases between 1988 and 1997. A total of 77% of the cases survived a minimum of 6 months, and 59% survived >2 years. Allen et al[7] reported on 13 cases. Five of these (39%) returned to limited athletic activity, six (46%) were pasture sound, and the remaining two cases (15%) improved initially but were eventually euthanized (one due to further deterioration after 9 months, and the other due to economic reasons). Hunt et al[8] reported the experience with 20 cases. In these cases, 55% survived less than 1 month, 30% survived longer than 6 months, 15% of these remained lame. None of the cases in that study returned to athletic performance. These studies had a large variation in case specifics and included the degree of coffin bone injury at presentation, chronicity, shoeing and/or trimming protocols at the time the DDF tenotomy was performed, and follow-up care. In Hunt's study, there were several cases which all received the same shoeing protocol and postsurgical foot management.

To better evaluate the efficacy of the tenotomy procedure, Morrison[9] subclassified 245 cases that received a DDF tenotomy into the following categories: degree of displacement of the coffin bone, coffin bone disease, medial, lateral, or vertical sinking of the coffin, and coffin bone that penetrated the sole.[5] Of the 245 cases, 51% were considered a success. Success was defined as survival for >1 year after surgery, maintaining good body condition, and an Obel lameness Grade of 2 or less (moving freely at the walk but possibly having a stiff gait, sore on turning, and able to pick up each foot when asked). Cases with no coffin bone disease and no signs of sinking or solar penetration had an 83% success rate. Cases with moderate coffin bone disease, and no sinking or solar penetration had a 93% success rate. Cases with severe coffin bone disease and no sinking or penetration had a 44% success rate. Cases with signs of sinking (medial, lateral, or vertical) had an overall success rate of 18%, while non-sinkers had a success rate of 71%. Cases with penetration and no sinking had an 88% success rate while cases with penetration and sinking had a 25% success rate. The number of limbs involved and their location was also associated with outcome: success rate for one limb was 52%; two limbs, 50%; four limbs, 50%; front limb, 51%; and hind limbs, 50%.

During laminitis and the rehabilitation process, it is important to minimize further damage to the foot. As a team, the veterinarian and farrier should have an understanding of the normal supporting structures of the digit, biomechanical forces on the foot, and the structural failure that results when these forces act on a diseased and damaged foot. In a healthy foot, the antagonistic forces between the laminae that support the coffin bone dorsally and the deep DDF tendon that pull palmarly are in balance. In the laminitic foot, these forces are out of balance due to the loss of dorsal laminar support. This allows the unopposed palmar force of the DDF tendon to pull the coffin bone away from the hoof capsule and creates instability. Venograms clearly outline the blood circulation in the foot, and perfusion deficits that are a consequence of laminitis. This is an invaluable diagnostic that could help with prognosis. The clinical information gained from a physical examination of the foot, venograms, and radiographs will dictate which treatment modalities need to be implemented. The multitude of prognostic factors that affect outcome in the horse with laminitis make treating these cases a challenge. Treating the horse with laminitis requires experience, expertise, realistic expectations, and a unified effort by the farrier, veterinarian, and owner.

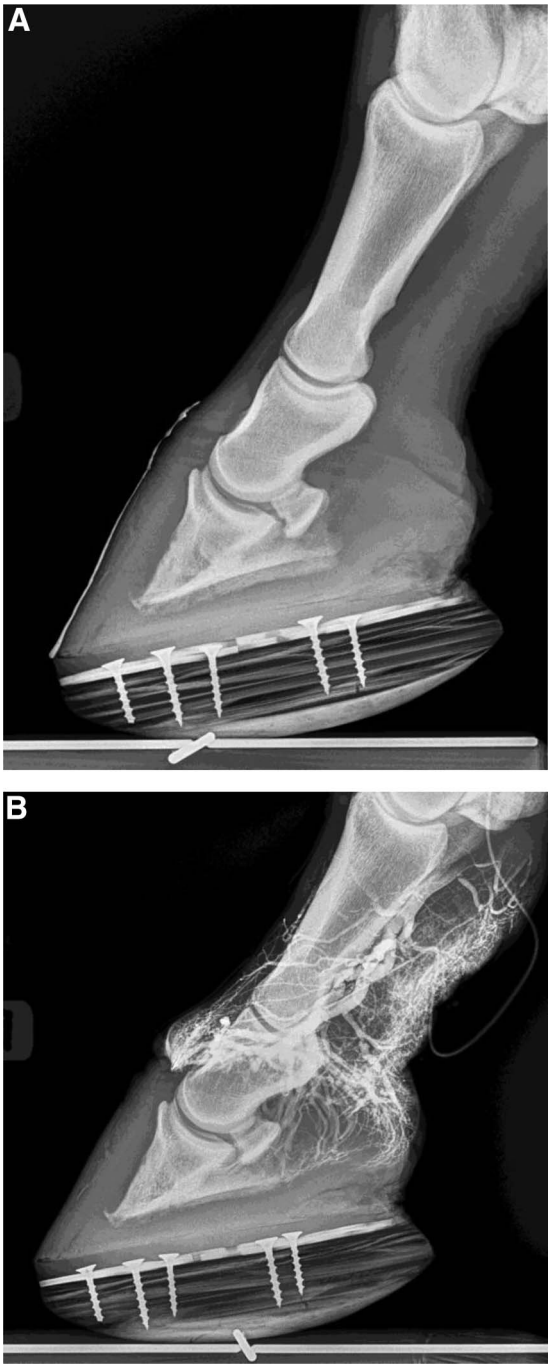

Fig. 3. A, Radiograph of a horse with acute laminitis with no improvement that was fitted with an optimum mechanical approach with no evidence of displacement of the coffin bone. B, Venogram that revealed clear evidence that the vascular damage (complete occlusion) exceeded the benefits of optimum mechanical treatment, which played a major role in the decision to perform a DDF tenotomy.

Serial venograms play a major role in the decision to perform a DDF tenotomy as it can reveal clear evidence that the vascular damage has progressed beyond the benefits of optimum mechanical treatment (Fig. 3). The information obtained will clearly distinguish the case that was fitted with an efficient mechanical aid at the onset of the syndrome from the case that was not. The value of frequent venograms to monitor the integrity of the blood supply, especially in the absence of remarkable growth, is the best way to detect the reason for horn growth deficit. Most cases with moderate to severe vascular damage will not have noticeable horn growth for the first 30 to 45 days even with mechanical aid, and will not have detectable rotation of the coffin bone. Without the diagnostic benefit of a venogram, essential information about perfusion will delay surgery by several weeks, causing the optimum treatment period to be missed. Waiting for the horse to develop complications such as seromas/abscesses due to the vascular damage, which occurs approximately 6 to 8 weeks from onset of clinical signs, to make surgical decisions can save lives for a while but significant irreversible damage sets the stage for ongoing complications and often euthanasia. When there is little if any growth 30 days post onset it is most probable that there is declining vascular supply in spite of the soundless level.[5] Do not rely on the pain scale to assess progress as it can be very deceptive.[5]

The role of the venogram is pivotal to proper case management and outcomes. Assessing internal damage with the venogram allows a better understanding of the correlation between the vascular pattern and healing response and how the mechanical component greatly influences both. Using sheer mechanics and shifting the load from the dorsal half of the foot palmarly to the heel proves to be the most reliable means of treating the laminitic horse. Doing so expeditiously, ideally before the destructive cycle to the blood supply has caused irreversible damage to soft tissue growth centers and the palmar rim including the respective terminal papillae, can produce favorable results in a large majority of cases.[10] Prognosis is related principally to vascular integrity and damage at the time of insult. Vascular compromise creates soft tissue damage, followed by mechanical disruption of the equilibrium between the supportive forces of the laminae and tensile force of the DDF tendon. Timing of treatment and a DDF tenectomy is essential for an optimal outcome by quickly re-establishing healthy vascular supply, which can prevent the mechanical phase from destroying the suspension network.

Realignment shoeing is also known as derotation shoeing[6] (Fig. 4). Transection of the DDF tendon allowed immediate realignment of the coffin bone relative to the ground surface. The goal for the realignment shoeing was to apply a tenotomy rail bar shoe[a] onto the foot to re-establish parallel alignment of the ground surface and the coffin bone. Additionally, the shoe should have a heel extension to prevent the distal interphalangeal joint from dorsi-flexing after transection of the tendon. The palmar extension of the shoe should be continued to a

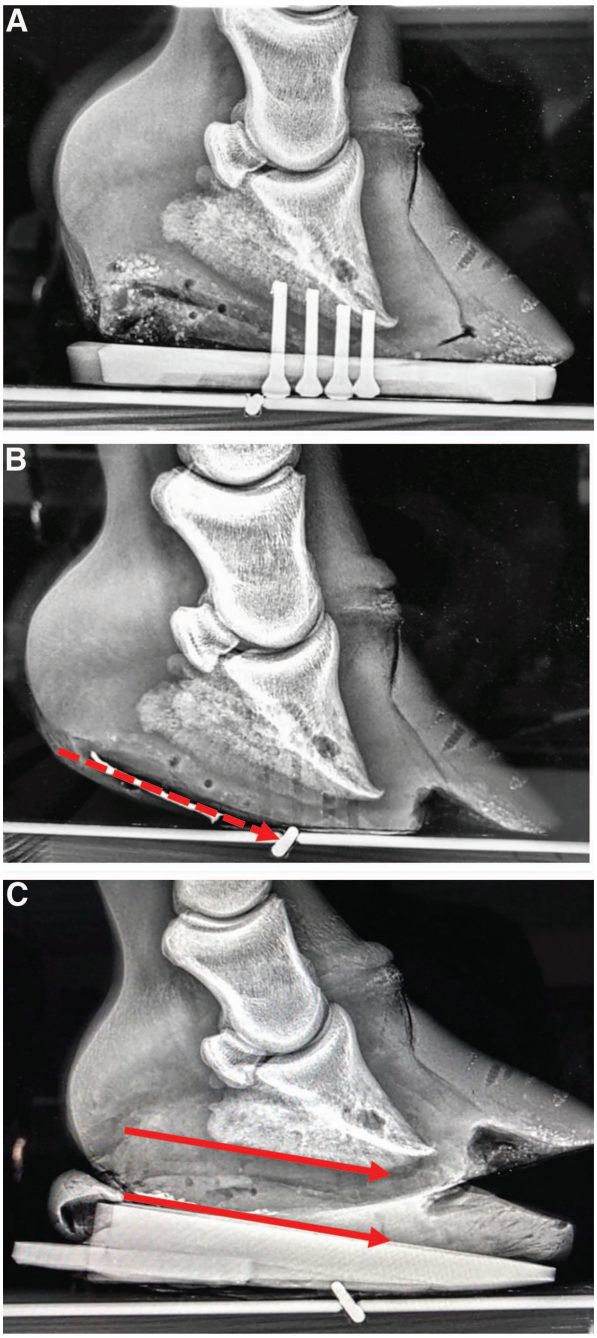

Fig. 4. Example of derotation/re-alignment shoeing. A, Radiograph with evidence of severe displacement of the coffin bone. B, Dotted red line-trimming only as needed to match the palmar angle of the coffin bone. C, Evidence of achieving a parallel level of the coffin bone with the derotation rail shoe after DDF tenotomy.

line dropped at a 90° angle from the proximal palmar aspect of the first phalanx to the ground with the horse standing squarely. The heel extension serves to improve sole mechanics by providing additional support to the palmar aspect of the foot. The sole support material[b] is then mixed and applied to the sole. The shoe is then firmly placed onto the foot at the same angle as the solar surface of P3 as viewed on the radiographs. At this point, the sole support material was often molded into a toe wedge to achieve proper shoe alignment. Once the proper angle is achieved, the shoe is glued in place using fiberglass cloth impregnated with the adhesive[c] leaving the toe open to minimize the chances for abscess formation which can be caused when the toe is covered with the adhesive material.

Successful management of the laminitic horse begins with the understanding of the normal supporting structures of the digit, the disease process, vascular compromise, and the structural failure that results in the laminitic foot. An early accurate diagnosis, and appropriate treatment are imperative for a successful outcome. Rehabilitation of the laminitic horse requires a dedicated team and cooperative efforts between the farrier, veterinarian, and owner. As with any surgical and therapeutic procedure, timing and proper case selection are essential for the best long-term outcome. The information presented here provides useful information that can assist the equine professionals in formulating a prognosis for laminitis cases requiring the DDF tenotomy and the realignment shoeing procedure. To be qualified as a competent equine podiatrist is one of the most rewarding and treasured credential that a pathological focused farrier or veterinarian could possess. Saving the career or life of a horse that is suffering from developmental complications can be one of the most gratifying experiences one could ever have.

Acknowledgments

Declaration of Ethics

The Author has adhered to the Principles of Veterinary Medical Ethics of the AVMA.

Conflict of Interest

The Author has no conflicts of interest.

References and Footnotes

1. Morrison SE. Deep digital flexor tenotomy and realignment shoeing for chronic laminitis. 5th International Equine Conference on Laminitis and Diseases of the Foot, West Palm Beach, FL, November 5–8, 2009, pp. 50–1.
2. Redden RF. Clinical and radiographic examination of the equine foot, in *Proceedings*. Am Assoc Equine Pract 2003; 49:320–327.
3. Rucker A, Redden RF, Arthur EG, et al. How to perform the digital venogram, in *Proceedings*. Am Assoc Equine Pract 2006;52:526–530.
4. D'Arpe L, Bernardini D, Coppola L. How to do a digital venography in the standing horse, in *Proceedings*. 10th International Congress of World Equine Veterinary Association 2008;529–530.
5. Redden RF. The use of venograms as a diagnostic tool, in *Proceedings*. Bluegrass Laminitis Symposium 1993;1–6.
6. Eastman TG, Honnas CM, Hague BA, et al. Deep digital flexor tenotomy as a treatment for chronic laminitis in horses: 35 cases (1988–1997). *J Am Vet Med Assoc* 1999;214:517–9.

7. Allen D Jr, White NA 2nd, Foerner JF, et al. Surgical management of chronic laminitis in horses: 13 cases (1983–1985). *J Am Vet Med Assoc* 1986;189:1604–6.
8. Hunt RJ, Allen D, Baxter GM, et al. Mid-metacarpal deep digital flexor tenotomy in the management of refractory laminitis in horses. *Vet Surg* 1991;20:15–20.
9. Morrison S. Long-term prognosis using deep digital flexor tenotomy and realignment shoeing for treatment of chronic laminitis. *J Equine Vet Sci* 2011;31:89–96.
10. Redden RF. Shoeing the laminitic horse, in *Proceedings*. Am Assoc Equine Pract 1997;43:356–359.

[a]Tenotomy rail bar shoe, Nanric, Inc., Versailles, KY 40383.
[b]Elastomer, Advanced Cushion Support, Nanric, Inc., Versailles, KY 40383.
[c]Equilox Adhesive System, Equilox International, Pine Island, MN 55963.