

How to Surgically Remove the Third Eyelid in the Standing Horse

Justin S. Harper, DVM, MS, Diplomate ACVS

Author's address: Texas Specialty Veterinary Services, PLLC - 111 Shadywood, Boerne, Texas 78006; e-mail: jsharperdvm@yahoo.com. © 2009 AAEP.

1. Introduction

Diseases that can affect the nictating membrane or third eyelid of the horse include neoplasia, traumatic lacerations, and inflammatory/infectious processes.^{1,2} Squamous cell carcinoma is, by far, the most reported neoplastic condition associated with the third eyelid in the horse.¹ Diagnosis often requires surgical biopsy for definitive diagnosis. Most often, an excisional biopsy is taken, which combines diagnostics and treatment in the same procedure. Strontium probe brachytherapy, cryotherapy, or hyperthermia, when available, is occasionally used after excision of the third eyelid to prevent reoccurrence of neoplasia.³

Horses with neoplasia of the nictating membrane are often referred to veterinary surgical centers to have removal of the membrane performed under general anesthesia. The anesthetic risks and financial costs associated with general anesthesia can be prohibitive to some horse owners. Biopsy or removal of the third eyelid can be performed in a safe, routine fashion in the standing horse using appropriate sedation and local anesthesia. In addition to avoiding anesthetic and post-operative anesthetic complications, standing surgery for removal of the third eyelid is very economical.⁴⁻⁶ Standing sur-

gery for removal of the third eyelid can also be safely performed in the field.⁷

The purpose of this paper is to describe the equipment required and anesthetic techniques necessary for surgical removal of the third eyelid in the standing horse.

2. Materials and Methods

Supplies and Equipment

Most surgical supplies and instrumentation required for standing surgical removal of the nictating membrane in equine patients are part of the routine instruments used by equine practitioners in hospital and field settings. Specific instruments required for the procedure include Metzenbaum or Mayo scissors, Brown Adson or Graefe fixation forceps, and mosquito or Crile hemostatic tissue forceps. Although performing surgical removal of the nictating membrane in the standing horse is safe for the surgeon and patient when performed in stocks, this procedure can also be performed under appropriate restraint, sedation, and local anesthesia in the field.

Tranquilization

Detomidine HCl^a (0.01–0.02 mg/kg, IV) is the sedative most often recommended for performing ophthalmic procedures, because it provides more

NOTES

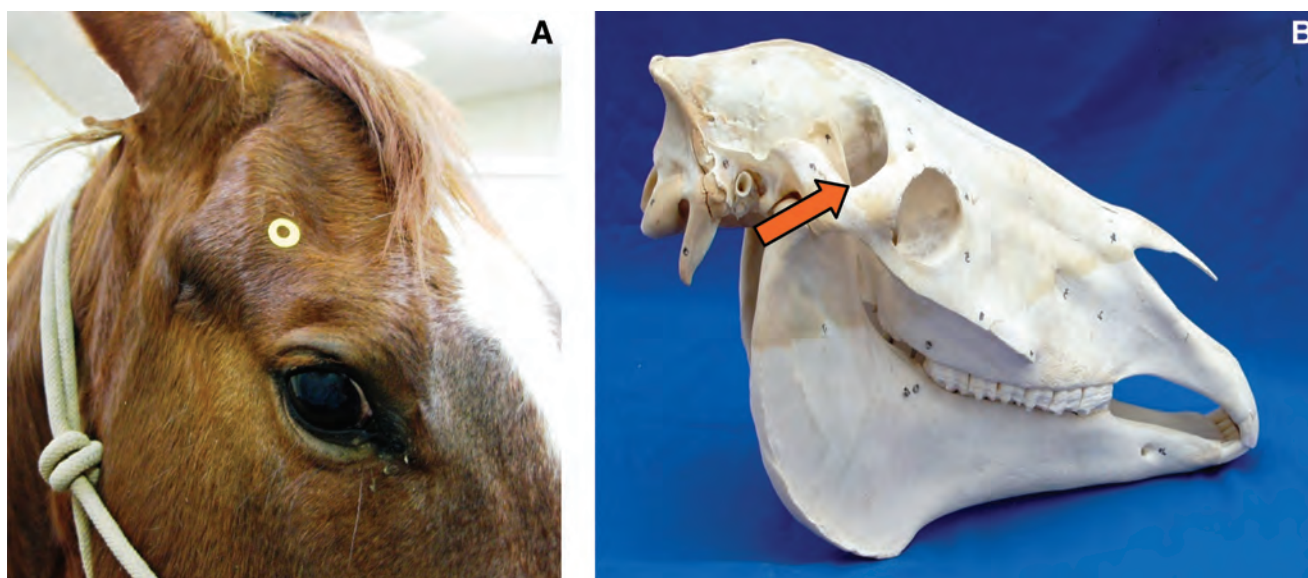


Fig. 1. Palpebral nerve block. (A) Location of the most common site for palpebral nerve block in the horse is identified by the yellow marker. (B) Two milliliters of 2% lidocaine HCl can be injected dorsolaterally to the highest point of the zygomatic arch.

profound sedation than alternatives such as xylazine^b or romifidine hydrochloride.^c The author, however, has also performed standing removal of the nictating membrane using these agents. Potential advantages of romifidine hydrochloride (40–120 $\mu\text{g/kg}$, IV) include less ataxia than that which occurs with other sedative agents.⁸ Only one dose of sedation is required for the surgical procedure. The combined use of butorphanol tartrate and these sedatives can, in some cases, cause unwanted head movement or exaggerated responses to stimuli.⁷

Nerve Blocks, Topical Anesthesia, and Direct Infiltrative Techniques

The third eyelid is innervated by the infratrochlear nerve, a branch of the trigeminal nerve. This membrane passively extends dorsolaterally across the orbit when the eye is retracted. Anesthesia of the third eyelid can be provided using 2% lidocaine hydrochloride^d or 2% mepivacaine hydrochloride.^e To provide adequate paralysis of the eyelids and analgesia, the author recommends performing the following nerve blocks:

1. The palpebral nerve, a branch of the auriculopalpebral nerve, provides motor innervation to the upper eyelid and surrounding adnexal structures. The nerve can be blocked locally where it crosses dorsolaterally to the highest point of the zygomatic arch (Fig. 1, A and B). Anesthesia of this nerve provides paralysis of the upper eyelid and provides no sensory innervation to the region. Thus, one could perform surgical excision of the third eyelid without this local block; however, the author routinely blocks

the palpebral nerve for ophthalmic examination to avoid additional movement of the surrounding structures.

2. The frontal nerve, a branch of the supraorbital nerve, provides sensory innervation of the upper medial two-thirds portion of eyelid. The frontal nerve exits the skull from the supraorbital foramen and can be palpated proximally to medially over the supraorbital process identified as a depression (Fig. 2, A and B).
3. The infratrochlear nerve, a branch of the trigeminal nerve, provides sensory innervation to the medial canthus of the eye. The nerve can be blocked as it courses through the trochlear notch located at the medial canthus of the eye (Fig. 3).
4. Some texts describe a retrobulbar nerve block to adequately immobilize the muscular structures of the globe and aid in surgical removal of the nictating membrane. It is of the author's opinion and experience that this block is seldom warranted for successful surgical resection.
5. Direct infiltration of the origin or ventromedial margin of the nictating membrane with anesthetic agent can be performed in addition to the palpebral, frontal, and infratrochlear nerve blocks. After previously described nerve blocks and appropriate sedation, the nictating membrane is extended dorsolaterally. Using a 25-gauge, 0.625-in hypodermic needle, local anesthetic agent is directly infiltrated into the ventromedial margin of the nictating membrane (Fig.

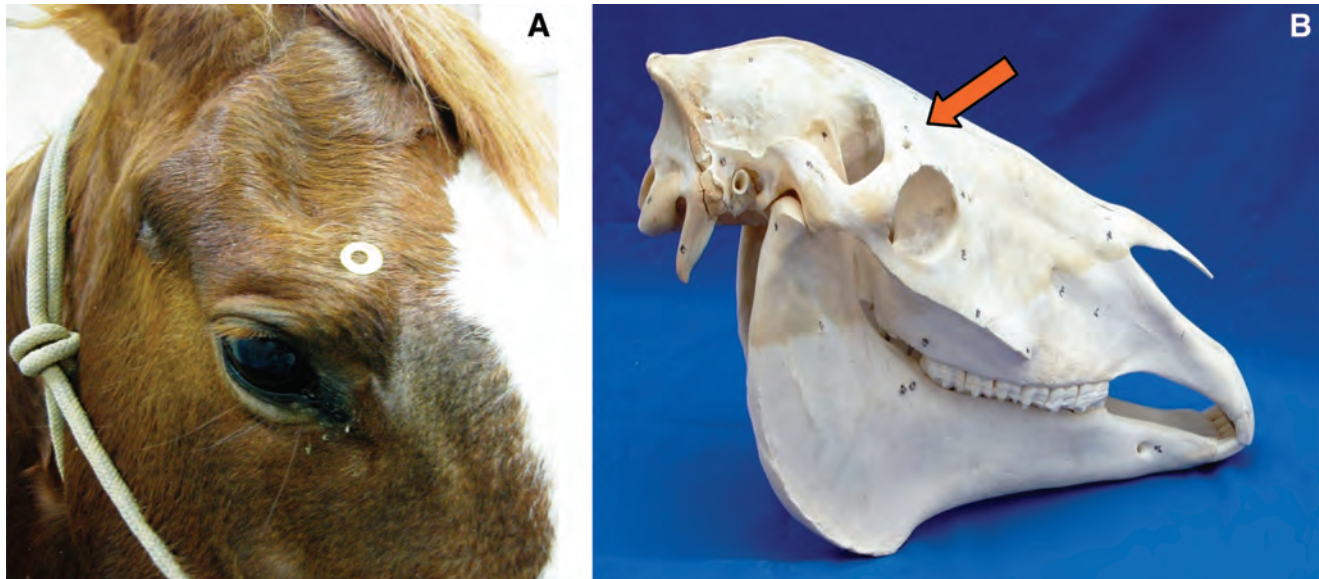


Fig. 2. Frontal nerve block. (A) A yellow marker identifies the location of the frontal nerve block. (B) One milliliter of 2% lidocaine HCl is injected subcutaneously near the depression of the supraorbital foramen.

- 4). This technique could be substituted for the infratrochlear nerve block.
6. Topical anesthesia of the corneal surface is warranted and provides desensitization of the cornea during the surgical procedure. Topical anesthesia of the cornea can be provided by the application of several drops of

ophthalmic 0.5% proparacaine hydrochloride^f solution.

All previously described nerves can be anesthetized using ~1–3 ml of anesthetic solution injected adjacent to the nerve using a 25-gauge, 0.625-in needle. Local anesthetic agents typically have onset of action in 2–6 min and last from 30 to 120 min.⁹

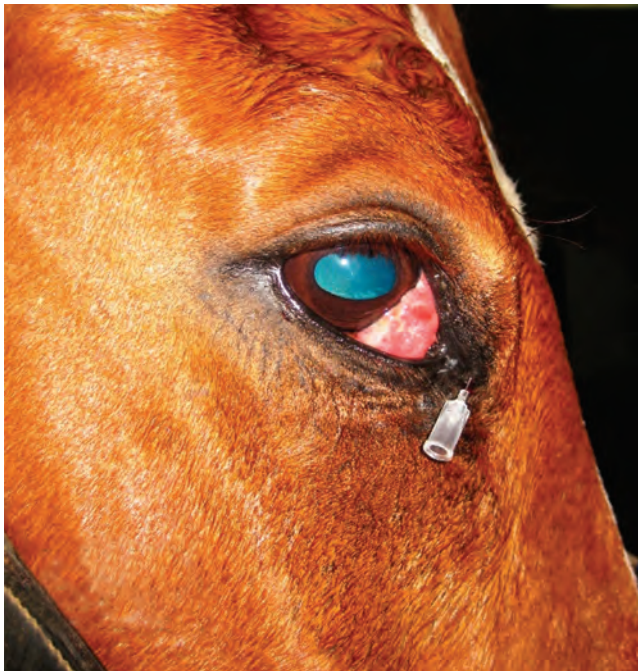

Fig. 3. The infratrochlear nerve block is located near the medial canthus of the eye. Two milliliters of 2% lidocaine HCl is injected subcutaneously.

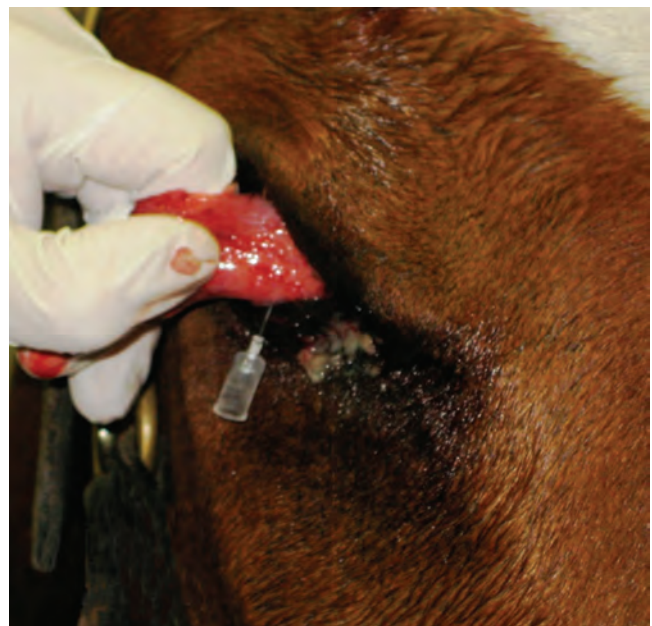

Fig. 4. Direct infiltration of 2% lidocaine HCl into ventromedial margin of the nictating membrane.

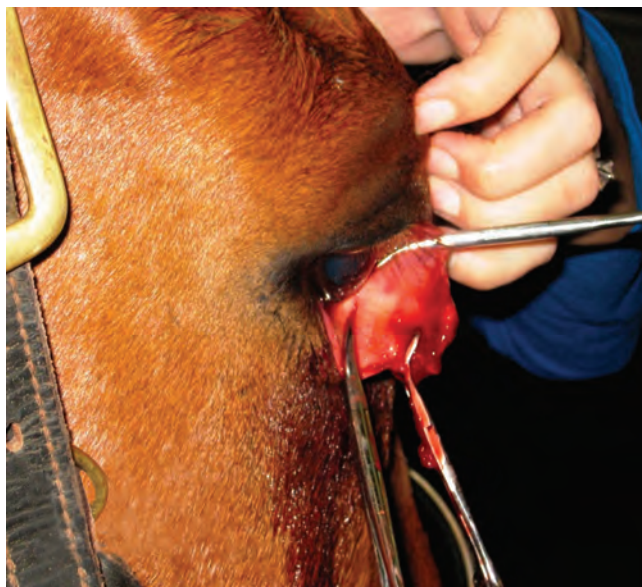

Fig. 5. Hemostatic tissue forceps are placed across the base of the third eyelid, proximally to the T-shaped piece of cartilage, to serve as surgical boundaries.

Surgical Procedure

After all previously mentioned steps have been performed, the patient is ready for surgical excision of the third eyelid. A twitch may be required; however, appropriate anesthetic blocks should provide adequate anesthesia and analgesia for the procedure.

The nictating membrane is composed of conjunctival mucosa, a lacrimal gland that produces por-

tions of the aqueous component of the tear film, and a T-shaped piece of cartilage embedded within the tissue. When excising the third eyelid, it is recommended to remove as much of the nictating membrane as possible to avoid recurrence of the original disease process.

The third eyelid is grasped using surgical tissue forceps, Graefe fixation forceps, or surgical gloved fingers to extend the full portion of the lid. After extension dorsolaterally across the globe, two curved Mosquito or Crile hemostatic tissue forceps are used to delineate the most ventromedial margins of the nictating membrane. Each hemostatic tissue forcep is placed across the base of the nictating membrane beyond or proximal to the T-shaped piece of cartilage (Fig. 5). The hemostatic forceps serve as surgical excision boundaries and also serve to crush conjunctiva to decrease hemorrhage from the surgical site. Subsequently, scissors (preferably curved Mayo scissors) are used to excise along the border of both hemostatic forceps, removing the entire third eyelid (Fig. 6, A and B). After removal of the hemostatic forceps, retrobulbar adipose tissue may occasionally prolapse from the medial canthus region. This tissue may also be excised using scissors without any untoward effects. Suture repair of the excised margins of the third eyelid can be performed; however, conjunctiva heals adequately by second intention, and the potential of iatrogenic irritation to the cornea from placement of suture near the globe is a good reason for not suturing the wound. The author allows the surgical site to heal by second intention.

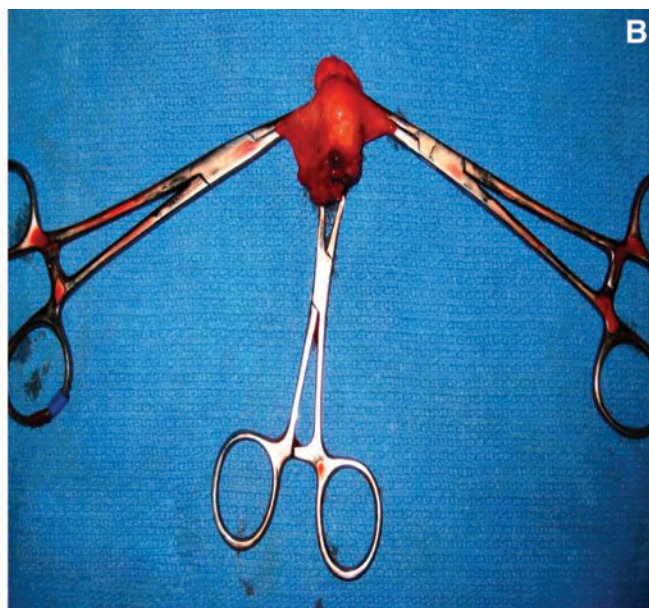
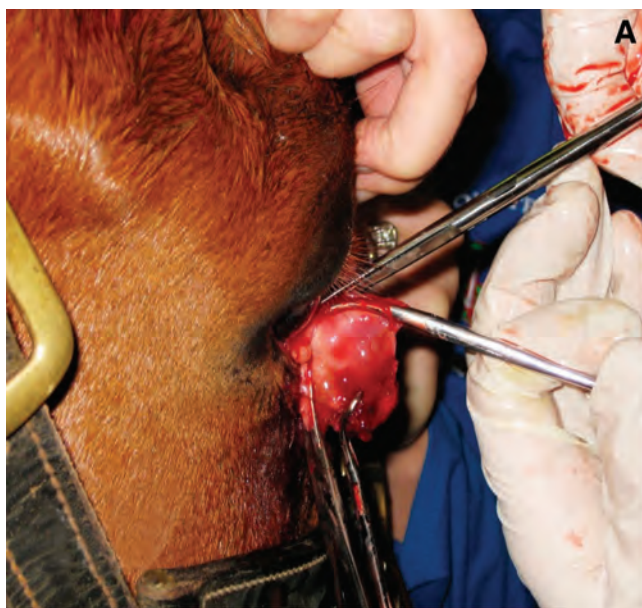

Fig. 6. Surgical removal of third eyelid. (A) Surgical excision of nictating membrane along borders created by hemostats. (B) Surgically excised nictating membrane.

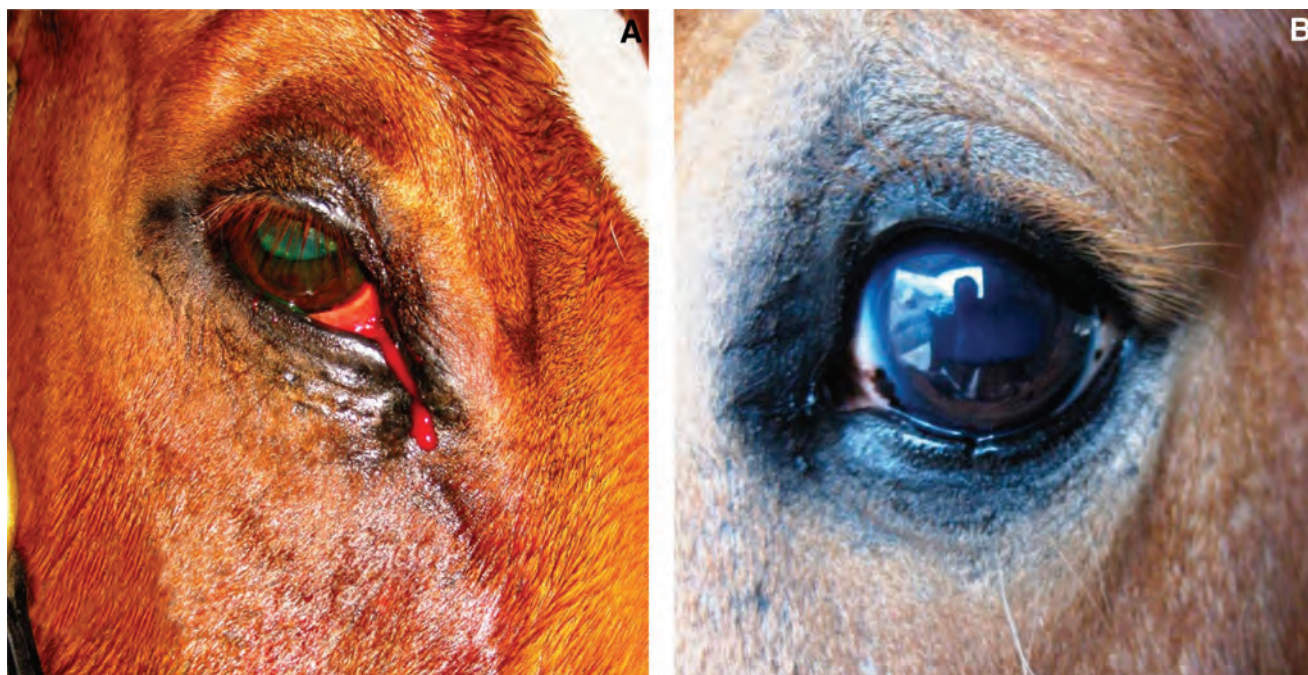

Fig. 7. Completed surgical removal of nictating membrane. (A) The eye immediately after removal. (B) The eye 3 mo post-surgical removal.

3. Results

Following the above recommended sedative and anesthetic techniques, surgical removal or excision of the third eyelid can be easily accomplished in the standing horse. This technique has successfully been performed by the author in 20 cases without any complications (Fig. 7, A and B). The most likely complication to be incurred while performing this procedure in the standing horse is iatrogenic induction of ulcerative keratitis. For this reason, the author routinely performs post-surgical fluorescein ophthalmic staining of the affected eye and prescribes twice daily topical ophthalmic triple antibiotic ointment application for 5 days after surgery. Other post-operative complications include retrobulbar adipose tissue prolapse or accumulation of mucopurulent debris in the medial canthus because of the large dead space present.¹⁰

4. Discussion

The benefits of performing standing surgical excision of the third eyelid far outweigh the risks and additional financial burden associated with general anesthesia. Although most minor ophthalmic surgical procedures involving adnexal structures including eyelids, conjunctiva, third eyelid, and the globe can be performed safely in the standing horse, most corneal or intraocular ophthalmic procedures require general anesthesia. Standing ophthalmic surgery of the orbital region requires appropriate sedation and the local anesthetic techniques previously discussed.

The third eyelid provides a source of seromucinous secretion to the precorneal tear film and redistributes the tear film across the surface of the cornea. Post-operatively, the removal of the third eyelid can lead to dry eye or keratoconjunctivitis sicca in the canine patient; however, this is rare in the equine patient.¹¹ Often caused by pathology or trauma, the third eyelid is completely removed in the equine patient. Squamous cell carcinoma is the most common neoplasm to affect the third eyelid in the horse that requires surgical excision. Routine standing surgical excision of the third eyelid does not seem to present any deleterious effects to the remaining functional eye structures.

In conclusion, standing surgical excision of the third eyelid in the equine patient is a valuable option for equine practitioners in the field or hospital setting. It requires routine instruments and knowledge of general sedative and anesthesia techniques available to all equine practitioners.

References and Footnotes

1. Lavach JD. *Large animal ophthalmology*. St. Louis, MO: Mosby, 1990.
2. Pusterla N, et al. Cutaneous and ocular habronemiasis in horses: 63 cases (1988–2002). *J Am Vet Med Assoc* 2003; 222:978–982.
3. Gilger BC. *Equine ophthalmology*. St. Louis: Elsevier, 2005.
4. Klein L. Anesthetic complications in the horse. *Vet Clin North Am [Equine Pract]* 1990;6:665–692.
5. Parvianinen AK, Trim CM. Complications associated with anesthesia for ocular surgery: a retrospective study 1989–1996. *Equine Vet J* 2000;32:555–559.

6. Little D, Redding WR, Blikslager AT. Risk factors for reduced postoperative fecal output in horses: 37 cases (1997–1998). *J Am Vet Med Assoc* 2001;218:414–420.
 7. Gilger BC. How to prepare for ocular surgery in the standing horse, in *Proceedings*. 48th Annual American Association of Equine Practitioners Convention 2002; 266–271.
 8. Clarke KW, England GCW, Goossens L. Sedative and cardiovascular effects of romifidine, alone and in combination with butorphanol, in the horse. *J Vet Anaesth* 1991; 18:25–29.
 9. Mama KR, Steffey EP. Local anesthetics. In: Adams HR, ed. *Veterinary pharmacology and therapeutics*, 8th ed. Ames, IA: Iowa State University Press, 2001;353.
 10. Whitaker CJG, Wilkie DA. Ophthalmology. In: Rose RJ, Hodgson DR, eds. *Manual of equine practice*, 2nd ed. W. B. Saunders Co., 2000;427–450.
 11. Carastro SM. Equine ocular anatomy and ophthalmic examination. *Vet Clin North Am [Equine Pract]* 2004;20: 285–299.
- ^aDormosedan, Pfizer Animal Health, Exton, PA 10017.
^bTranquived, Vedco, St. Joseph, MO 64504.
^cSedivet, Boehringer Ingelheim Vetmedica, St. Joseph, 64506.
^dLidocaine 2% injectable, The Butler Co., Columbus, OH 43228.
^eCARBOCAINE-V, Pharmacia & Upjohn Company, New York, NY 10017.
^fAlcaine, Alcon Laboratories, Fort Worth, TX 76134.