

# Epizootic lymphangitis in horses: a review of the literature

F.K. Al-Ani

Department of Veterinary Clinical Science, Faculty of Veterinary Medicine, Jordan University of Science and Technology, Irbid, P.O. Box 3030, Jordan

Submitted for publication: 4 May 1998

Accepted for publication: 9 June 1999

## Summary

Epizootic lymphangitis is a relatively common infectious disease of horses and other equids in certain parts of the world. The infection rate varies according to the geographic area and the age of the animal. The disease is most commonly characterised by a cord-like appearance of the subcutaneous lymphatic and cutaneous pyogranulomas, the discharge from which contains spherical or pear-shaped bodies of the causal agent, *Histoplasma farciminosum*. Diagnosis can be made by the demonstration of typical organisms in stained smears, culture and tissue sections. Serological tests and a skin hypersensitivity test have been described. Amphotericin B is the drug of choice for the treatment of clinical cases. An attenuated vaccine and a killed formalised vaccine are available and can be used in endemic areas to control the disease.

## Keywords

Epizootic lymphangitis – Fungal diseases – *Histoplasma farciminosum* – Horses – Jordan – Reviews.

## Introduction

Both *Histoplasma capsulatum* and *H. farciminosum* cause clinical disease in horses (15, 29, 48, 65). Histoplasmosis caused by *H. capsulatum* has been recognised in horses in certain areas of the world (40, 42, 50). The infection rate varies according to the geographic area and the age of the animal. In the United States of America (USA), histoplasmin reactors were found in 73% of forty-four horses tested (16, 36). Another study reported three cases of *H. capsulatum* infection out of thirty horses examined (40). Other reports indicate that epizootic lymphangitis is a disease which is distributed world-wide, with endemic foci in North Africa and Asia (1, 5, 49). The disease is characterised by a cord-like appearance of the subcutaneous lymphatic vessels, especially of the limbs, neck and chest, and the development of a series of pyogranulomas, the discharge from which contains yeast-like cells of the pathogen. Rarely, infection may lead to pneumonia and conjunctivitis (10, 17). The purpose of this paper is to review the existing literature on epizootic lymphangitis. Several studies have been conducted into the epidemiology of the disease (1, 2, 5, 6, 24, 41, 47, 49, 54).

## Aetiology

*Histoplasma farciminosum* (synonyms: *Cryptococcus farciminosum*, *Zymonema farciminosum*, *Histoplasma capsulatum* var. *farciminosum*) is the cause of epizootic lymphangitis (12, 14, 67). *Histoplasma farciminosum* will be used to name the agent, although according to Ajello the organism does not belong to the genus *Histoplasma* (3). The organism was first demonstrated in pus by Rivolta in 1873 (51) but was not successfully cultivated until 1896 when the first pure cultures were obtained by Tokishiga in Japan (66). The yeast form of the organism appears in pus as a double-contoured oval or ovoid body, measuring 2.5–3.5 µm by 3–4 µm. The saprophytic stage is mycelial and both forms can be cultivated if suitable media, temperature of incubation and carbon dioxide tension are provided (64). The organism grows slowly when the yeast phase is grown on media rich in protein and in an atmosphere enriched with CO<sub>2</sub> (10). Several culture media have been used, but the most satisfactory were Sabouraud's dextrose agar enriched with 2.5% glycerol; brain heart infusion agar enriched with 10% horse blood; nutrient agar supplemented with 2% dextrose;

mycobiologic agar and mycoplasma-like organism medium (6, 53). Growth on all media is very slow and appears after four to eight weeks of incubation at 25°C (31, 53). Colonies of the mycelial form are a yellowish/light brown to deep brown, convoluted, waxy and cauliflower-like. In body tissues, the ability of *H. farciminosum* to convert from the mycelial form to the yeast form appears to be dependent on temperature and nutrition as well as the strain (28). However, *in vitro*, conversion of the mycelial form to the yeast form of *H. farciminosum* can be achieved by incubating at 35°C to 37°C. Complete conversion to the yeast form is achieved only after four to five repeated serial transfers onto fresh media every eight days (53).

The biochemical characteristics of the mycelial form include positive reactions to catalase and urease tests as well as the assimilation of ammonium sulphate as the sole source of nitrogen. No fermentation of carbohydrate sugars, liquefaction of gelatine or reduction of nitrate occurs (62). The organism is highly resistant to the effects of physical and chemical agents (25, 62) and can survive for at least a month in the dust of stables or kraals (25). Bardelli and Ademollo found the pathogen to be viable and virulent after desiccation in the laboratory for 25 months (11). *H. farciminosum* may survive for up to ten weeks in non-sterile water at 26°C (25).

## Epidemiology

Epizootic lymphangitis is a contagious disease which can infect humans (45). The disease mainly affects horses, mules and donkeys, although infection may occur in camels and cattle (63). Mice and rabbits may be infected experimentally (39, 59). Horses under six years of age are most susceptible (45). The disease is endemic in countries bordering the Mediterranean, particularly in Italy and North Africa and is also found in Central and Southern Africa, and in regions of Asia and Russia (2, 4, 32, 33, 37, 44, 49, 56). Some doubt exists concerning the validity of the reported cases of epizootic lymphangitis in the USA. Gillespie and Timoney believe that all of these could have been cases of sporotrichosis, which resembles epizootic lymphangitis clinically (30).

The three major outbreaks of epizootic lymphangitis during the 20th Century have been associated with the massing together of large numbers of horses due to military operations (30).

The mode of transmission of the disease is not well established (35). Direct contact with infective materials through injured skin or through cutaneous abrasions is the most common mode of infection (50, 55). Spread of infection can also occur indirectly through contaminated objects such as grooming tools, feeding and watering utensils, and harnesses and wound dressings (35). Flies that feed on open wounds were incriminated as possible vectors by Saunders as early as 1944 (52), and later Plunkett confirmed this conclusion (43). The

organism has been isolated from the alimentary tract of biting flies that had alighted on open lesions, and the disease has developed in horses 4.8 km from the nearest case (57). Experimentally, flies (*Musca* spp. and *Stomoxys* spp.) have been shown to be capable of transmitting the infection. Records also exist of transmission of the disease from stallions to mares by copulation (30). In endemic areas in certain regions of the world, the seasonal dusty winds expose horses to the inhalation of dust and spores, leading to pneumonia (12, 20).

## Pathogenesis

The incubation period ranges from several weeks to six months (59). Following the initial invasion of the skin, the organism spreads through the lymphatic vessels to the regional lymph nodes, and in more advanced cases involves the internal organs (3, 38). Nodular and chronic suppurating lesions are evident in the skin overlying lymph vessels and nodes (54, 58).

When mucosal lesions occur, most are confined to the upper respiratory tract and eyes (5, 57). The nasal infection is usually accompanied by mucopurulent discharge containing large numbers of the fungus. In the Sudan, *H. farciminosum* has been isolated from granulomatous lung lesions of two horses suffering from pneumonia (18, 20). A fatal pneumonia due to *H. farciminosum* has been reported in an immunosuppressed foal (46).

## Clinical signs

The clinical signs of epizootic lymphangitis have been described in detail (1, 13, 14). Cases of epizootic lymphangitis can be grouped into four different forms, namely: cutaneous, respiratory, ocular and asymptomatic carriers (5). The clinical findings of each form will be discussed.

The cutaneous form of the disease, after which the disease was named, is the most common (10, 31, 38, 54, 56). The initial lesion is an open granulomatous wound along the course of a lymphatic vessel, which has a tendency to ulcerate, or to undergo alternating periods of discharge and closure for some weeks before healing with residual scar formation. Lesions are most common in the forelimbs, the chest wall, and the neck. In severe cases, skin over the entire body may be affected. The lesions begin as indolent, chancre-like papules, becoming larger over the course of weeks, and eventually form irregular pyogranulomatous nodules, which frequently ulcerate (1, 5). Mortality does not usually exceed 10% to 15%, and the main loss results from the inability of animals to work for several weeks because of extremely painful lesions.



The ophthalmic form of the disease is less frequent. Infection may occur as conjunctivitis or a naso-lachrymal infection (Fig. 1). Several authors have reported lachrymal and conjunctival lesions as the sole symptoms among equines in Egypt (17, 21, 22). The infection rarely becomes generalised (3, 20, 38). Initial infection is characterised by a watery discharge from one or both eyes and some swelling of the eyelids, followed by the development of papules and ulcerating button-like growths on the conjunctiva and/or on the nictitating membrane (5, 54, 58).



**Fig. 1**  
**A button-like growth on the eyelid of the right eye in a seven-year-old Arabian horse**

The respiratory form of the disease is characterised by lesions which are mostly confined to the upper respiratory tract. This form usually occurs as a late development in the cutaneous form of the disease (20). On the nasal mucosa, the lesions begin as yellowish papules or nodules and these soon form crater-like granulating ulcers that bleed easily. The lesions are usually found near the external nares. These lesions may also occur in the lungs (12, 18, 20).

Asymptomatic carriers can be identified clinically by the identification of fibrocalcific skin lesions at previous sites of infection (5). Such horses will give a positive result to an intradermal sensitivity test and positive reactions to serological tests (4, 61).

## Pathology

Gross lesions are manifested by pyogranulomas, purulent discharge of thickened superficial lymphatic vessels and enlargement of regional lymph nodes. Histopathologically, a

typical granulomatous tissue reaction occurs with a predominance of the large macrophages, many of which contain oval organisms in the cytoplasm (8). Affected tissues stained by Gram stain revealed the presence of ovoid, double-contoured yeast-like cells. Periodic-acid Schiff or Gomori's methenamine silver stains are very useful to demonstrate the presence of the organisms (34). Typical nodules of liquefied foci have also been recorded in the pleura, spleen, liver and bone marrow (12, 20, 38). Bennett described an interstitial pneumonia and granulomas of various sizes in which macrophage and giant cells predominated (13).

## Diagnosis

Laboratory tests used in the diagnosis of epizootic lymphangitis include isolation of the causative agent by culture and tests for the presence of antibodies in the blood (4, 9, 19, 26). Haematological picture showed leucocytosis, neutrophilia, and an increase in the erythrocyte sedimentation rates (5). The tests described below are used in the diagnosis of epizootic lymphangitis.

### Direct smear examination and culture technique

Diagnosis is usually based upon demonstration of the typical yeast-like, double-contoured cells in pus collected aseptically from the lesion and confirmed by culturing the pathogen (5, 44, 53, 59). *H. farciminosum* is a Gram-positive organism and is successfully cultivated on a variety of media. Growth is relatively slow; most isolates require from four to eight weeks for development of characteristic colonies (Figs 2 and 3). As the culturing technique is not totally reliable, a negative direct smear and/or culture should not be used as the basis of excluding the possibility of infection. The culture of several samples on different occasions may be required before the results can be considered either positive or negative (5).

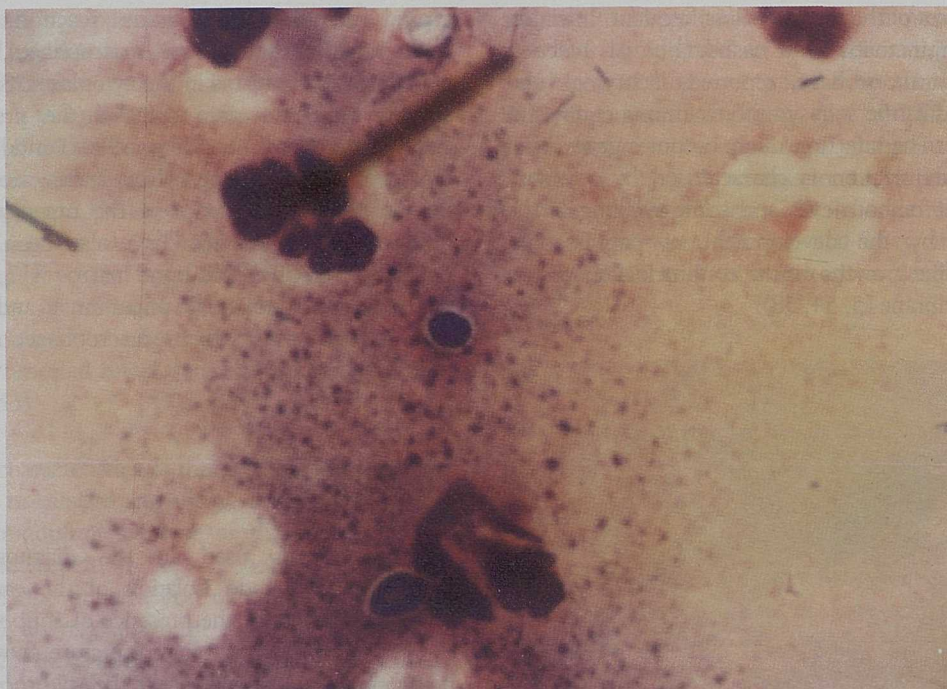
### Serological tests

In the absence of positive culture of *H. farciminosum*, a presumptive diagnosis is usually made, based on the presence of antibodies in the serum. Although several serological tests have been used for the diagnosis of epizootic lymphangitis, none of the tests are sufficiently sensitive or specific to confirm diagnosis. The four serological tests described below are relevant.

### Fluorescent antibody technique

The usefulness of the fluorescent antibody (FA) technique as a diagnostic tool for many infectious diseases has been firmly established. A number of investigators have explored the possibility of using the FA procedure for diagnosis of *H. farciminosum* infection (9, 19, 24). The test is rapid and reliable, especially in cases where detection and isolation of the organism is unsuccessful.



**Fig. 2****Gram-stain of *Histoplasma farciminosum***

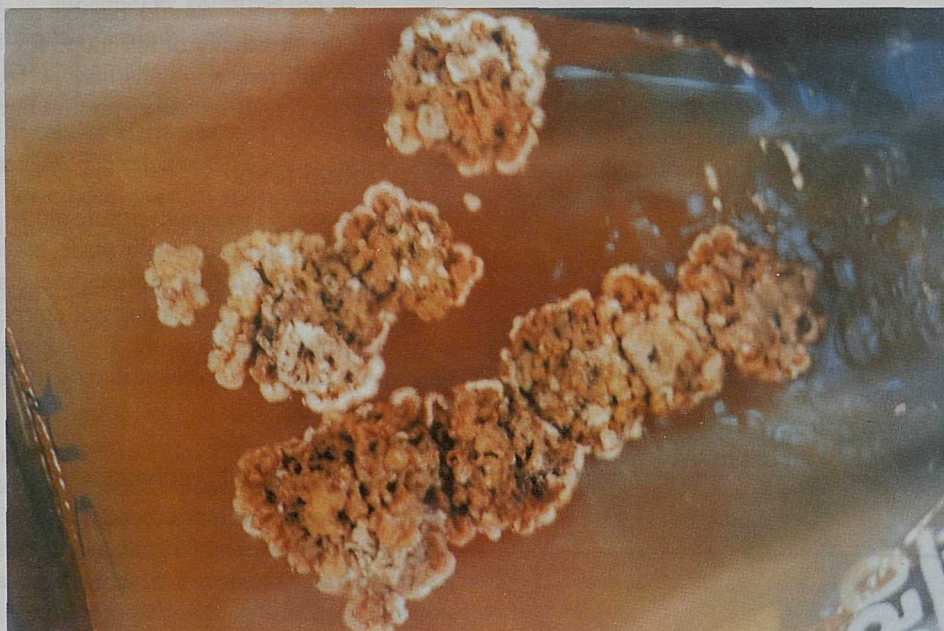
Note oval bodies with unstained capsule

**Agar gel immunodiffusion test**

An agar gel immunodiffusion test has been developed (60). The antigen used has been prepared from the mycelial (61) and the yeast (4) forms of the organism. This method is based on the fact that all *Histoplasma* spp. produce H and M histoplasmin antigens (64).

**Enzyme-linked immunosorbent assay**

An enzyme-linked immunosorbent assay (ELISA) for the detection of antibodies in horses infected with epizootic lymphangitis was evaluated (27). Mincing preparation of four weeks growth of the fungus in a phosphate buffer saline can be used as antigen. A peroxidase labelled goat anti-equine IgG

**Fig. 3**

Colony morphology of *Histoplasma farciminosum* on mycobiologic agar after 42 days incubation at 26°C

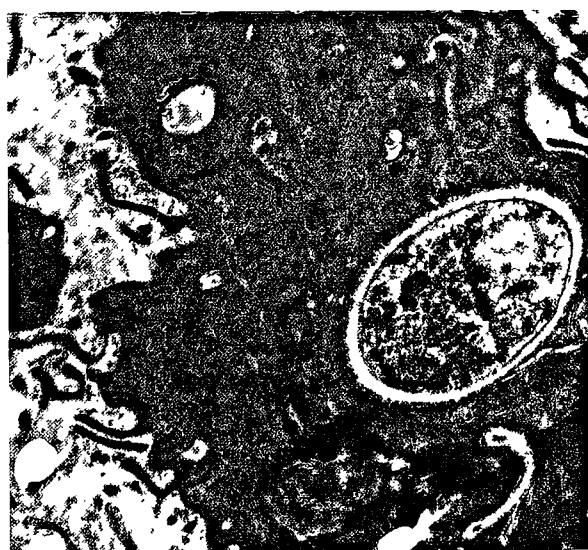(immunoglobulin G) was used as a conjugate (27). The ELISA is simple and reliable for the diagnosis of the disease.

### Haemagglutination test

The serum agglutination test is one of the traditional standard tests which is used widely. It is highly suitable for the large-scale screening of sera. A titre of 1:80 or more can be considered positive (7).

### Electron microscopic examination

Tissues taken from cutaneous lesions revealed the presence of oval bodies (8, 28). Most of the details of the fine internal structures could be observed (Fig. 4).



**Fig. 4**  
Electron microscopy of *Histoplasma farciminosum*  
( $\times 10,000$ )

### Animal inoculation

Experimental transmission of *H. farciminosum* has been attempted in mice, guinea-pigs and rabbits (6, 59). Immunosuppressed mice were highly susceptible to experimental infection and can be used for diagnostic purposes (6).

### Cell-mediated immunity

An accurate and reliable method of skin testing is the intradermal test (61, 62). This consists of intradermal injection of 0.1 ml of soluble antigen prepared from *H. farciminosum*. An increase in the thickness of the skin of 8 mm to 20 mm, 24 h after injection of the antigen can be regarded as a positive result (62).

## Differential diagnosis

Rigorous control measures are sometimes required by law to control or eradicate epizootic lymphangitis. Consequently, diagnosis must be performed with great care. A number of

diseases may be confused with epizootic lymphangitis (e.g. glanders, strangles, ulcerative lymphangitis and sporotrichosis), especially when these diseases occur under the same environmental conditions (44). As some of the diseases are a potential human health hazard, early diagnosis is important.

## Treatment

Epizootic lymphangitis is a chronic disease, although some cases may heal spontaneously a few weeks after the development of clinical signs (45). Intravenous dosing of iodide may be used (4); this type of treatment is a satisfactory procedure, particularly in endemic areas. The intravenous injection of 100 ml of sodium iodide of a 10% solution, repeated weekly for four weeks, gives good results (4). Different antifungal drugs have also been used (49) and successful treatment with amphotericin B has been reported (4). The infected horses were treated with an intravenous injection of amphotericin B at a dose of 0.2 mg/kg body weight three times on alternate days. The scabs were removed and the areas cleaned daily with an iodine solution for seven days. The lesions should heal fully within four weeks (4). *In vitro* testing, at a concentration of 50 mol/ml to 100 mol/ml of amphotericin B inhibited strongly the growth of the yeast phase of *H. farciminosum* (23). Administration of griseofulvin, repeated if necessary, has given good results when combined with iodides and local surgical treatment. The surgical treatment usually consists of opening the nodules and packing with gauze soaked in 7% tincture of iodine (22).

## Control and eradication

Outbreaks in non-endemic areas are probably best controlled by the slaughter of affected animals. The long incubation period of the disease, the high resistance of the causative agent and the presence of clinically healthy carriers make control of the disease difficult in endemic areas. The method used to control epizootic lymphangitis in large endemic areas will depend on the incidence of the disease, methods of husbandry, attitude and economic capacity of the farming community and the acceptance of the latter of a test and culling programme. Control of the disease depends upon elimination of the infection by culling infected horses, and preventing spread by hygiene precautions. Cleaning and disinfection will help to prevent the disease from spreading. This method of control is the most satisfactory and proven to be mandatory for large breeding companies in endemic areas (4). In many countries where epizootic lymphangitis has been introduced, the disease has subsequently been eradicated and thereby has been prevented from becoming endemic. The disease was eradicated from Great Britain in 1906 and no case has occurred since then. In recent years, immunisation against epizootic lymphangitis has become an option. A killed formalised vaccine prepared from the yeast form of the



fungus, administered subcutaneously in a dose of 5 ml once a year, has given good results (4). Reports indicate that a live vaccine has been successful in the People's Republic of China (68). An attenuated vaccine was developed by exposure of the causative agent to high temperature (68). Horses inoculated subcutaneously with 3 ml in a single dose had a protection rate of 75.5% and the duration of immunity exceeded

31 months following vaccination (68). Vaccinated animals may be serologically positive which may interfere with control and eradication programmes (4).

## Lymphangite épizootique des équidés : analyse de la littérature

F.K. Al-Ani

### Résumé

La lymphangite épizootique est une maladie infectieuse relativement répandue chez les chevaux et autres équidés dans certaines régions du monde. Le taux de morbidité varie selon la zone géographique et l'âge de l'animal. La maladie se caractérise le plus souvent par des cordons de pyogranulomes cutanés et lymphatiques superficiels, dont les écoulements contiennent les corps globulaires ou ovales de l'agent causal, *Histoplasma farciminosum*. Le diagnostic peut s'effectuer par la mise en évidence d'organismes caractéristiques sur frottis coloré, cultures et coupes histopathologiques. Des épreuves sérologiques et un test d'hypersensibilité de la peau existent également. L'amphotéricine B est le médicament le plus indiqué pour le traitement des cas cliniques. Un vaccin à germe atténué et un vaccin à germe inactivé par le formol sont disponibles et peuvent être utilisés dans les zones endémiques pour lutter contre la maladie.

### Mots-clés

Équidés – Études – *Histoplasma farciminosum* – Jordanie – Lymphangite épizootique – Mycoses.

## Linfangitis epizoótica en el caballo: síntesis bibliográfica

F.K. Al-Ani

### Resumen

La linfangitis epizoótica es una enfermedad infecciosa del caballo y otros équidos relativamente común en ciertas zonas del mundo. Su tasa de infección varía según el área geográfica y la edad del animal. La enfermedad suele caracterizarse por el aspecto tubular de los piogranulomas cutáneos y linfáticos superficiales, cuya secreción contiene cuerpos esféricos o piriformes del agente causal, *Histoplasma farciminosum*. Puede diagnosticarse observando la presencia de ese microorganismo de aspecto característico en frotis teñidos, cultivos o cortes histológicos. También se han descrito pruebas serológicas y una prueba de hipersensibilidad cutánea. La amfotericina B es el fármaco más

adecuado para el tratamiento de los casos clínicos. Existen asimismo una vacuna atenuada y una vacuna de organismos inactivados en el formol, que pueden utilizarse para luchar contra la enfermedad en zonas endémicas.

### Palabras clave

Caballo – *Histoplasma farciminosum* – Jordania – Linfangitis epizoótica – Micosis – Síntesis bibliográfica.

■

## References

1. Abou-Gabal M., Hassan F.K., Al-Siad A.A. & Al-Karim K.A. (1983). – Study on equine histoplasmosis epizootic lymphangitis. *Mykosen*, **26**, 145-151.
2. Addo P.B. (1980). – A review of epizootic lymphangitis and ulcerative lymphangitis in Nigeria: misnomer or misdiagnosis. *Bull. anim. Hlth Prod. Afr.*, **28**, 103-107.
3. Ajello L. (1968). – Comparative morphology and immunology of members of genus *Histoplasma*. A review. *Mykosen*, **11**, 507-514.
4. Al-Ani F.K. (1989). – Epizootic lymphangitis in horses: a goal for diagnosis, treatment and control? In Proc. 6th Technical Conference of animal diseases in the Arab world, 18-21 March, Baghdad. General Federation of Arab Veterinarians, Iraqi Veterinary Medical Syndicate, Baghdad, 11-22.
5. Al-Ani F.K. & Al-Delaimi A.K. (1986). – Epizootic lymphangitis in horses: clinical, epidemiological and hematological studies. *Pakistan vet. J.*, **6**, 96-100.
6. Al-Ani F.K., Khalifa K.A., Ali A.H., Hassan F.K., Al-Abbassy S.N., Redha Y.P. & Al-Zubaidi I.A. (1988). – Epizootic lymphangitis in horses: mice inoculation studies. *Pakistan vet. J.*, **8**, 5-8.
7. Al-Ani F.K., Hassan F.K. & Al-Juborri K.O. (1989). – Serodiagnosis of epizootic lymphangitis in horses by passive hemagglutination test. *J. Iraqi Vet.*, **7**, 1-16.
8. Al-Ani F.K., Ali H.A. & Banna H.B. (1998). – *Histoplasma farciminosum* infection of horses in Iraq. *Vet. Arhiv.*, **68**, 101-107.
9. Al-Delaimi A.K. & Khairallah A.M. (1984). – Application of fluorescent antibody test in the diagnosis of the epizootic lymphangitis. *Haryana Vet.*, **23**, 123-125.
10. Awad F.I. (1960). – Studies on epizootic lymphangitis in the Sudan. *J. comp. Pathol.*, **70**, 457-463.
11. Bardelli P. & Ademollo A. (1927). – Sulla resistenza delle Conture di *Cryptococcus farciminosus*. Rivolta agli agenti fisici e chimici. *Annual Igiene*, **37**, 81-85.
12. Bennett S.C. (1931). – *Cryptococcus pneumonia* in equidae. *J. comp. Pathol. Ther.*, **44**, 85-108.
13. Bennett S.C. (1932). – Epizootic lymphangitis: mycelial forms of the parasite in a natural case. *J. comp. Pathol.*, **45**, 158-160.
14. Bullen J.J. (1949). – The yeast-like form of *Cryptococcus farciminosus* (Rivolta): (*Histoplasma farciminosum*). *J. Pathol. Bacteriol.*, **95**, 658-671.
15. Cornick J.L. (1990). – Diagnosis and treatment of pulmonary histoplasmosis in a horse. *Cornell Vet.*, **80**, 97-103.
16. Edwards L.B., Acquoviva F.A. & Liveasay V.T. (1973). – Further observations on histoplasmin sensitivity in the United States. *Am. J. Epidemiol.*, **98**, 315-325.
17. El-Gundy M.H., Shokeir A.A., Wasfey I.A., Ahmed K.K., Elbedeiwy A., Abou-Gabal M. & El-Rehewy M.S. (1975). – Histoplasmosis of the eyes of donkeys. 11: An electron microscopic study. *Assiut Vet. med. J.*, **2**, 235-239.
18. Faccincani F. (1952). – Multiple pulmonary nodules in epizootic lymphangitis. *Arch. vet. ital.*, **3**, 27-32.
19. Fawi M.T. (1961). – Fluorescent antibody tests for the serodiagnosis of *Histoplasma farciminosum* infection in equidae. *Br. vet. J.*, **125**, 231-234.
20. Fawi M.T. (1971). – *Histoplasma farciminosum*, the etiological agent of equine cryptococcal pneumonia. *Sabouraudia*, **9**, 123-125.
21. Fouad K.M., Saleh S., Sokkar S. & Shouman M.T. (1973). – Studies of a surgical problem due to lachrymal histoplasmosis. *Tijdschr. Diergeneesk.*, **98**, 1032-1034.

22. Fouad K.M., Saleh S., Sokkar S. & Shouman M.T. (1973). – Studies on lachrymal histoplasmosis in donkeys in Egypt. *Zentralbl. Veterinärmed.*, B, 20, 584-593.
23. Gabal M.A. (1984). – The effect of Amphotericin B, 5-Fluorocytosine and nystatin on *Histoplasma farciminosum* in vitro. *Zentralbl. Veterinärmed.*, B, 31, 46-50.
24. Gabal M.A., Bana A.A. & Gendi M.E. (1983). – The fluorescent antibody technique for diagnosis of equine histoplasmosis (epizootic lymphangitis). *Zentralbl. Veterinärmed.*, B, 30, 283-287.
25. Gabal M.A. & Hennager S. (1983). – Study on the survival of *Histoplasma farciminosum* in the environment. *Mykosen*, 26, 481-484; 487.
26. Gabal M.A. & Khalifa K. (1983). – Study on the immune response and serological diagnosis of equine histoplasmosis (epizootic lymphangitis). *Zentralbl. Veterinärmed.*, B, 30, 317-321.
27. Gabal M.A. & Mohammed K.A. (1985). – Use of enzyme-linked immunosorbent assay for the diagnosis of equine histoplasmosis farciminosi (epizootic lymphangitis). *Mycopathologia*, 91, 35-37.
28. Garrison R.G. & Body K.S. (1975). – Aspects of the dimorphism of *Histoplasma farciminosum*: a light and electron microscopic study. *Sabouraudia*, 13, 174-184.
29. Giles R.C., Donahue J.M., Hong C.B., Tuttle P.A., Petrites-Murphy M.B., Poonacha K.B., Roberts A.W., Tramontin R.R., Smith B. & Swerczek T.W. (1993). – Causes of abortion, stillbirth and perinatal death in horses: 3527 cases (1986-1991). *J. Am. vet. med. Assoc.*, 203, 1170-1175.
30. Gillespie J.H. & Timoney J.F. (1981). – Hagan and Bruner's infectious diseases of domestic animals, 7th Ed. Cornell University Press, London, 390-391.
31. Guerin C., Abebe S. & Touati F. (1992). – Epizootic lymphangitis in horses in Ethiopia. *J. Mycol. méd.*, 2, 1-5.
32. Herve V., Gall-Campodonico P., Blance F., Improvisi L., Dupont B., Mathiot C. & Gall F. (1994). – Histoplasmosis due to *Histoplasma farciminosum* in an African horse. *J. Mycol. méd.*, 4, 54.
33. Jerabek J. (1994). – Less known animal diseases XII. Epizootic lymphangitis. *Veterinärství*, 44, 348-350.
34. Jones T.C. & Hunt R.D. (1983). – Veterinary pathology, 5th Ed. Lea & Febiger, Philadelphia, 683-689.
35. Jubb K.V., Kennedy P.C. & Palmer N. (1985). – Epizootic lymphangitis. In *Pathology of domestic animals*, Vol. 3, 4th Ed. Academic Press, New York, 82-84.
36. Kaplan W. (1973). – Epidemiology of the principal systemic mycosis of man and animals and the ecology of their etiologic agents. *J. Am. vet. med. Assoc.*, 163, 1043-1047.
37. Kapur D. (1952). – Epizootic lymphangitis. *Indian vet. J.*, 37, 342-343.
38. Khater A.R., Iskander M. & Mostafa A. (1968). – A histomorphological study of cutaneous lesions in equine histoplasmosis (epizootic lymphangitis). *J. Egypt. vet. med. Assoc.*, 28, 165-174.
39. Knowles R.C. & Moulton W.M. (1982). – Exotic diseases. In *Equine medicine and surgery*, 3rd Ed. (R.A. Mansmann & E.S. McAllister, eds). American Veterinary Publication, Santa Barbara, California, 357, 813.
40. Menges R.W., Harbermann R.T. & Selby L.A. (1963). – A review and recent findings of histoplasmosis in animals. *Vet. Med.*, 58, 331-338.
41. Office International des Epizooties (OIE) (1996). – Epizootic lymphangitis. In *Manual of standards for diagnostic tests and vaccines*, 3rd Ed. OIE, Paris, 457-460.
42. Panciera R.J. (1969). – Histoplasmosis (*Histoplasma capsulatum*) infection in a horse. *Cornell Vet.*, 59, 306-312.
43. Plunkett J.J. (1949). – Epizootic lymphangitis. *J. Army vet. Corps*, 20, 94-99.
44. Quinn P.J., Carter M.E., Markey B. & Carter G.R. (1994). – *Veterinary clinical microbiology*, 1st Ed. Wolfe Publishing Company, London, 407.
45. Radostits O.M., Blood D.C. & Gay C.C. (1994). – *Veterinary medicine*, 8th Ed. Baillière Tindall, London, 1167.
46. Ramachandran S. (1995). – Equine respiratory disease. 2. Mycotic and helminthic causes. *Centaur*, 11, 69-79.
47. Refai M. & Loot A. (1970). – Incidence of epizootic lymphangitis in Egypt with references to its geographical distribution. *Mykosen*, 13, 247-252.
48. Rezabek G.B., Donahue J.M., Giles R.C., Petrites-Murphy M.B., Poonacha K.B., Rooney J.R., Smith B.J., Swerczek T.W. & Tramontin R.R. (1993). – Histoplasmosis in horses. *J. comp. Pathol.*, 109, 47-55.
49. Richer F.J. (1977). – La lymphangite épizootique. Revue générale de la maladie et observations cliniques en République du Sénégal. [Epizootic lymphangitis. Review of the disease and clinical observations in Senegal.] PhD thesis, École nationale vétérinaire, Maisons-Alfort, 89 pp.
50. Richmond H. (1948). – Studies on epizootic lymphangitis. *N. Am. Vet.*, 29, 710.
51. Rivolta S. & Micellone I. (1883). – Del farcino criptococchio. *Giorn. Anat. Patol. Anim. dom.*, 15, 143-162.
52. Saunders L.Z. (1948). – Systemic fungus infection in animals: a review. *Cornell Vet.*, 38, 213-238.
53. Selim S.A., Soliman R., Osman K., Padhye A.A. & Ajello L. (1985). – Studies on histoplasmosis farciminosii (epizootic lymphangitis) in Egypt. Isolation of *Histoplasma farciminosum* from cases of histoplasmosis farciminosii in horses and its morphological characteristics. *Eur. J. Epidemiol.*, 1, 84-89.
54. Singh M.S. (1956). – Equine cryptococcoses (epizootic lymphangitis). *Indian vet. J.*, 32, 260-267.



55. Singh T. (1965). – Studies on epizootic lymphangitis. 1: Modes of infection and transmission of equine histoplasmosis (epizootic lymphangitis). *Indian J. vet. Sci.*, **35**, 102-110.
56. Singh T. (1966). – Studies on epizootic lymphangitis: clinical cases and experimental transmission. *Indian J. vet. Sci.*, **36**, 45-59.
57. Singh T., Varmani B.M. & Bhalla N.P. (1965). – Studies on epizootic lymphangitis. II. Pathogenesis and histopathology of equine histoplasmosis. *Indian J. vet. Sci.*, **35**, 111-120.
58. Singh T. & Varmani B.M. (1966). – Studies on epizootic lymphangitis. A note on pathogenicity of *Histoplasma farciminosum* (Rivolta) for laboratory animals. *Indian J. vet. Sci.*, **36**, 164-167.
59. Singh T. & Varmani B.M. (1967). – Some observations on experimental infection with *Histoplasma farciminosum* (Rivolta) and the morphology of the organism. *Indian J. vet. Sci.*, **37**, 47-57.
60. Soliman R., Ismail M., Hatem E., Kamillia O. & Selim S.A. (1984). – Studies on histoplasmosis farciminosii (epizootic lymphangitis) in Egypt. II. Serodiagnosis of epizootic lymphangitis using agar gel immunodiffusion test. *Vet. Med. J. (Giza)*, **34**, 109-116.
61. Soliman R., Saad M.A. & Refai M. (1985). – Studies of histoplasmosis farciminosii (epizootic lymphangitis) in Egypt. III. Application for a skin test (Histofarcin) in the diagnosis of epizootic lymphangitis in horses. *Mykosen*, **28**, 457-461.
62. Soliman R., El Seedy F.R., El-Agrab H., El-Bauomy A.M. & Shouman M.T. (1986). – Studies on histoplasmosis farciminosii (epizootic lymphangitis) in Egypt. IV. The biochemical characters of local isolates of *Histoplasma farciminosum* and their sensitivity to antimycotic and disinfectants *in vitro*. *Assuit Vet. med. J.*, **17**, 109-116.
63. Spesivtseva N.A. & Noskov A.I. (1959). – Epizootic lymphangitis in camels. *Trudy Vses Institute Vet. Sanit. Ectopar.*, **14**, 86.
64. Standard P.G. & Kaufman I. (1976). – Specific immunological test for the rapid identification of members of the genus *Histoplasma*. *J. clin. Microbiol.*, **3**, 191-199.
65. Swerczek T.W. (1992). – Identifying the mycotic causes of abortion in mares. *Vet. Med.*, **87**, 62-65.
66. Tokishiga M. (1896). – Über pathogene Blastomkosen. *Zentralbl. Bakteriol.*, **19**, 105-116.
67. Weeks R.J., Padhye A.A. & Ajello L. (1985). – *Histoplasma capsulatum* var. *farciminosum*: a new combination for *Histoplasma farciminosum*. *Mycologia*, **77**, 964-970.
68. Zhang W.T., Wang Z.R., Liu Y.P., Zhang D.L., Liang P.Q., Fang Y.Z., Huang Y.J. & Gao S.D. (1986). – Attenuated vaccine against epizootic lymphangitis of horses. *Chin. J. vet. Sci. Technol.*, **7**, 3-5.