AAEP®

EQUINE VETERINARY EDUCATION

American Edition | July 2016

The official journal of the American Association of Equine Practitioners, produced in partnership with BEVA.

IN THIS ISSUE:

EQUINE VETERINARY EDUCATION

AMERICAN EDITION **July 2016 · Volume 28 · Number 7**

CONTENTS

Cover photo by Dr. Eleanor Green.

American Association of Equine Practitioners
4033 Iron Works Parkway
Lexington, KY 40511
TEL (800) 443-0177 • (859) 233-0147
FAX (859) 233-1968
E-MAIL aaepoffice@aaep.org
www.aaep.org

To access our website, go to www.aaep.org, click on Members, select LOGIN, then enter your e-mail and password or, for first-time visitors, enter your e-mail as your Username and your member number with the letter 'a' in front as your Password.
Published monthly. Deadlines are the seventh of the preceding month.

All advertising inquiries should be addressed to:
Dana Kirkland (859) 233-0147
dkirkland@aaep.org

AAEP Mission Statement: To improve the health and welfare of the horse, to further the professional development of its members, and to provide resources and leadership for the benefit of the equine industry.

EQUINE VETERINARY EDUCATION
AMERICAN EDITION
July 2016 • Volume 28 • Number 7

Equine Veterinary Education is a refereed educational journal designed to keep the practicing veterinarian up to date with developments in equine medicine and surgery. Submitted case reports are accompanied by invited reviews of the subject (satellite articles) and clinical quizzes. Tutorial articles, both invited and submitted, provide in-depth coverage of issues in equine practice.

Equine Veterinary Education (American Edition ISSN 1525-8769) is published monthly by the American Association of Equine Practitioners, an international membership organization of equine veterinarians. Office of publication is 4033 Iron Works Parkway, Lexington, KY 40511. Periodicals Postage paid at Lexington, KY and additional mailing office. POSTMASTER: Send address changes to: Equine Veterinary Education, 4033 Iron Works Parkway, Lexington, KY 40511.

Communications regarding editorial matters should be addressed to: The Editor, Equine Veterinary Education, Mulberry House, 31 Market Street, Fordham, Ely, Cambridgeshire CB7 5LQ, UK. Telephone: 44 (0) 1638 720250, Fax: 44 (0) 1638 721868, E-mail: sue@evj.co.uk.

All manuscript submissions for the journal should be submitted online at http://mc.manuscriptcentral.com/eve. Full instructions and support are available on the site and a user ID and password can be obtained on the first visit. If you require assistance, click the Get Help Now link that appears at the top right of every ScholarOne Manuscripts page.

All subscription inquiries should be addressed to: Subscriptions Department, AAEP, 4033 Iron Works Parkway, Lexington, KY 40511, Telephone: (859) 233-0147, E-mail: jcooney@aaep.org. Subscription rates: AAEP annual membership dues include $40 for a subscription to *Equine Veterinary Education*. Other subscriptions at $151.80. Single copies $37.50.

Canadian Subscriptions: Canada Post Corporation Number 40965005. Send change address information and blocks of undeliverable copies to IBC, 7485 Bath Road, Mississauga, ON L4T 4C1, Canada.

Printed by: Cadmus Professional Communications, Lancaster Division, Lancaster, PA.

AAEPNEWS

Ethics: Is the bottom line really the bottom line?

By David Ramey, DVM

It is certainly true that a practice needs to be profitable to survive. Indeed, in 1970, Milton Friedman, the late Nobel Prize-winning economist, asserted that the sole purpose of a business is to make money for its shareholders.[1] For veterinary practitioners, one measure of success is assuredly the business' profit margin. But from an ethical perspective, is the bottom line really the bottom line?

Many people in other businesses would say, "No." While Friedman was probably correct, at least at some level, the single-minded goal of maximizing shareholder value ignores important aspects of the veterinarian-client-patient relationship (VCPR). Klaus Schwab, the German engineer and economist best known as the founder and executive chairman of the World Economic Forum, asserts that a different measure of business success should be used. His "stakeholder theory" of business asserts that businesses are not just accountable to shareholders; instead, businesses must focus on serving the interests of everyone who has a stake in the business. In the case of an equine veterinary business, everyone with a stake includes customers, employees, partners, suppliers, any other entity impacted by the business' operations, and especially horses.

Focusing too much on the bottom line of a practice comes with a cost. In economics, these costs are known as "externalities," or the side effects of business behavior. For example, a practice could theoretically increase its profits by selling each and every client an inexpensive but useless service or product at a high price. The practice might make a large profit on each sale, but such action would also show that the practice has little concern for the horse or horse owner. Acting without concern for horses or their owners is clearly unethical; if owners discover such practices, the side effect can be a loss of business.

If the bottom line is the main consideration for a practice, the business of equine veterinary medicine may also have a reduced value to horse owners. If the cost of veterinary care becomes too high—and cost of care is the No. 1 concern in AVMA-conducted surveys—it becomes a factor in making horse ownership unaffordable. High costs of horse ownership ultimately mean that fewer people own horses. Alternatively, horse owners may choose to avoid veterinary care in order to control costs. According to a 2013 AVMA survey, as many as 50% of horses in the United States do not see a veterinarian in any particular year.[2]

Acting ethically and with concern for everyone involved in the VCPR offers a competitive advantage. As Marc Benioff, chairman and CEO of Saleforce, wrote in his 2004 book, *Compassionate Capitalism*, "The competitive advantage you gain from being a caring and sharing company is significant; it instills in your people a higher integrity level. In turn, stakeholders want to be associated with a company that has heart. Community service: You do it because it's the right thing to do, but it's also the profitable thing to do."

While focusing on selling products and services may help increase profit, at least in the short term, in the long term, they hurt the horse industry. Every penny that a horse owner can save becomes money that the owner can use to maintain a horse—even use more veterinary services. Ethical business practices balance the profit needs of the veterinarian with the needs of the owner and the horse. Value needs to be created for all participants in the VCPR. Ethical businesses earn a reasonable profit, not necessarily a maximized one. Ultimately, it's in an equine practice's best interest to look out for its clients and their horses. This not only increases client loyalty, it also gains better clients.

Practicing ethically helps the veterinarian, too. There is growing evidence that responsible business conduct pays off for business,[3] and ethical business practices can help increase business satisfaction among business owners and employees. Satisfaction with veterinary practice appears to be a significant concern in the veterinary profession. In 2015, a survey of over 900 veterinarians conducted by *DVM360* magazine concluded that a veterinary career was producing less satisfaction and happiness than it did 10 years previously.[4] A 2016 survey by *US News and World Report* ranked the job of being a veterinarian at No. 88 out of the 100 best jobs, due in part to concerns about stress, work-life balance and future growth.[5]

The bottom line is not necessarily the bottom line. Good business ethics considers much more than profit. Good ethics can help increase job satisfaction and client confidence, and it can increase a practice's bottom line, too.

Dr. Ramey is the owner of Ramey Equine in Encino, Calif., and a member of the AAEP's Professional Conduct and Ethics Committee.

REFERENCES
[1] Friedman, M. The Social Responsibility of Business is to Increase its Profits. The New York Times Magazine, September 13, 1970. http://www.colorado.edu/studentgroups/libertarians/issues/friedman-soc-resp-business.html
[2] Burns, K. Vital Statistics. January 16, 2013. https://www.avma.org/news/javmanews/pages/130201a.aspx
[3] Nieuwenkamp, R. Can Companies Really Do Well By Doing Good? The Business Case for Corporate Responsibility. OECDInsights.org, November 2, 2015. http://oecdinsights.org/2015/11/02/can-companies-really-do-well-by-doing-good-the-business-case-for-corporate-responsibility/
[4] The Current State of Veterinary Job Satisfaction. DVM360 magazine. April 24, 2015. http://veterinarynews.dvm360.com/current-state-veterinary-job-satisfaction
[5] US News and World Report Best Jobs Ranking. January 10, 2016. http://money.usnews.com/careers/best-jobs/veterinarian

AAEPNEWS

Invest in practice success at the AAEP's 62nd Annual Convention

Meeting moves to Orlando's Orange County Convention Center

Connect with old friends and new ideas in core areas of equine healthcare when the AAEP's 62nd Annual Convention returns to Orlando, Fla., Dec. 3-7, 2016.

Unlike 2007, when the convention was last held in Orlando at the Gaylord Palms, this year's event has a new home: Orlando's Orange County Convention Center. The convention center is located on International Drive, the city's entertainment, dining and shopping thoroughfare, and a stone's throw from Orlando's major theme parks. A trolley service conveniently links the convention district with International Drive offerings.

The educational program will feature practical take-home knowledge that will help you deliver positive outcomes to your patients in the areas of dentistry, emergency and critical care, imaging, infectious disease, internal medicine, lameness, rehabilitation and reproduction. In addition, the in-demand topic of ethics will be the subject of a featured session, the keynote presentation (see article on page V) and a table topic. Meanwhile, daily Business of Practice sessions will help you manage the non-medical aspects of successful practice, including succession planning and navigating many of the other transitions encountered in equine practice.

Convention attendees can purchase afternoon and discounted multi-day tickets to Walt Disney World® Resort at https://www.mydisneymeetings.com/aaep16.

A daily slate of networking and social events will enable you to engage and form more meaningful relationships with colleagues, while a 300-exhibitor strong trade show will showcase the newest products and services for practice.

If you're ready to make a splash this December, visit www.aaep.org/info/annual-convention to register for the convention, book your hotel room and browse the educational program. Register online by Sept. 1 and save $115!

2015 convention session videos available for download

Perhaps you weren't able to attend the AAEP's 61st Annual Convention in Las Vegas. Or maybe a schedule conflict at the meeting prevented you from sitting in on a particular session. Whatever the reason, you can purchase and download videos of any or all of the 132 convention presentations, excluding Table Topics, through AAEP's arrangement with Digitell Inc.

To access session videos, visit www.prolibraries.com/aaep. First-time visitors to the site will need to register by creating a unique user id and password. Once created, you can download videos of the complete educational program, entire sessions or individual presentations within a session.

Additional information about this service is available by contacting the AAEP at (859) 233-0147. Tech support questions should be directed to Digitell at (800) 679-3646 or support@prolibraries.com.

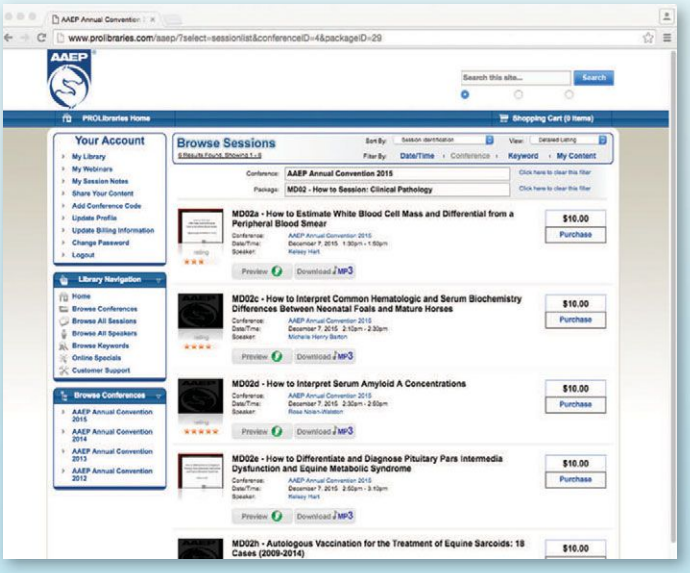

Convention keynote to offer fresh perspective on ethical consequences and success

Chuck Gallagher

In equine practice as in life, the choices you make every day define who you are and the outcomes you will live. While your employees may be aware of this on some level, do they truly realize the power behind the daily choices they make? More importantly, what's the risk to your practice if they don't?

With ethics consistently ranked as a topic of high importance among AAEP members, acclaimed ethics speaker Chuck Gallagher will reveal the life-changing consequences of the unethical decisions he made in his own attempt to build the great American dream when he delivers a compelling and thought-provoking keynote address at the AAEP's 62nd Annual Convention in Orlando, Fla., Dec. 3-7, 2016.

In his motivational presentation, "Every Choice Has a Consequence: Ethics, Integrity and the Power of Choices in Life and Business," Gallagher will draw upon personal stories and poignant life lessons to help you and your practice increase ethics awareness to achieve professional and personal success.

Gallagher's presentation will cover:

- How easy it is for ethical people to make unethical choices—and what to do about it
- The impact of life's choices and how they affect your performance, both personally and professionally
- Real-world practical examples of how to use ethics and integrity to create success in business and life

This powerful presentation by an executive whose poor choices cost him everything before rebuilding a successful life and career is filled with unforgettable messages of success and failure, illusions and reality, and choices and consequences.

MERCK Animal Health

The AAEP thanks Merck Animal Health for its sponsorship of the keynote presentation.

New regulation requires overtime pay for more employees

An AVMA@Work blog post on May 26 examined the effect on veterinary practices of a new Labor Department rule that will extend overtime pay to more salaried workers beginning Dec. 1, 2016. A portion of the blog is quoted here:

A new rule finalized last week by the U.S. Department of Labor requires time-and-a-half overtime pay for far more salaried workers than previously have been covered. This rule applies to employees in the private sector as well as those in federal, state, and local governments. It also applies to nonprofit charities that provide veterinary services for a fee (see the nonprofit fact sheet for more information on nonprofits that may be affected by this rule).

The Fair Labor Standards Act (FLSA) Overtime Final Rule, announced on May 18, requires employers to pay overtime to employees who earn $913 per week or less—up to $47,476 on an annual basis—and work more than 40 hours per week, even if they are salaried workers who are classified as managers or professionals. Previously, the overtime requirement applied only to hourly employees and salaried workers earning $455 a week or less—up to $23,660 per year.

There are some exemptions to the rule, but most of these exemptions won't apply to veterinary practices. Employees that are not exempt from the Fair Labor Standards Act must be paid the federal minimum wage (currently $7.25 per hour) and at least one and one-half times their regular rate of pay for any hours they work beyond 40 in a workweek.

To read the entire blog post, please access it at http://tinyurl.com/avmaot.

AAEPNEWS

From membership survey to strategic plan: Connecting the dots

By David Foley, AAEP Executive Director

David Foley

The AAEP conducts a general membership survey every three years in conjunction with the board of directors revising the organization's strategic plan. The chief goal of the survey is to understand the issues most important to you as well as your satisfaction with our work in these areas.

In the most recent membership survey from fall 2014, you told us:

- Overall satisfaction with your membership remains strong.
- Many of the issues rated as most important in previous surveys remain important; however, most of these issues experienced increases in member satisfaction levels.
- The top three issues on which AAEP should focus are quality of life, laypeople providing veterinary services, and ethics in the profession.
- Three key public policy issues that merit AAEP's attention are laypeople providing veterinary services, horse slaughter, and regulation of veterinary medicine.
- The *Proceedings* book and *Equine Veterinary Education* are your two most popular member publications, with an increasing number of you accessing the digital versions of these publications through the AAEP Publications App.

Overall, we were pleased that the majority felt AAEP was working for you and remained a valuable resource for your professional growth. Not everything was rosy, however. A couple of areas were identified as needing improvement—and we are listening.

We experienced a drop in satisfaction with the responsiveness and timeliness of our communications with you. Additionally, many expressed frustration with the AAEP website, specifically navigation. We heard you loud and clear and have factored these two areas, in particular, into the AAEP's new strategic plan.

The strategic plan consists of five key goals for the coming few years. Each goal has a board oversight team and a specific work plan for 2016, with regular updates occurring at each board meeting. The five goals are:

HIGHLIGHTS:

Members say AAEP should focus on quality of life, laypeople providing veterinary services, and ethics in the profession

Dissatisfaction with member communication and website is being addressed

New wellness resources will be rolled out during the second half of 2016

1. Enhance Member Value
The AAEP will work to provide more enhanced member benefits for all member segments and practice types. Further, AAEP will seek to increase member engagement in the Touch initiative. This means exploring additional member-exclusive benefits; strengthening awareness of existing member benefits through an improved communications plan; developing new and improved client relation tools through the Touch program; and expanding these programs to our student members and equine veterinary technician partners within the practice.

2. Improve Member Communications
AAEP is committed to providing timely communication to its members on issues affecting practice, the profession, and the equine industry. This will be accomplished using current technologies and an improved website to enhance convenience and accessibility to information. The results of a communications assessment conducted earlier this year are currently being analyzed but will soon result in a revised plan to ensure we are keeping you informed. We are also in the process of building a new website with an anticipated launch in early 2017.

3. Address Wellness/Quality of Life
AAEP will identify resource materials and develop select educational programming to address the many challenges that veterinary students and equine practitioners face in their personal and professional lives so they can better serve themselves, their families, clients, and patients. We recently branded this initiative as ***"AAEP Healthy Practice: Wellness for work, well-being for life."*** We are in the process of developing resource materials and programs ranging from physical to financial aspects that constitute good wellness. Resources and programming will debut at the summer Focus meeting and at the annual convention this December.

Educating industry stakeholders, owners and government officials of the value of the equine veterinarian will be integral to protecting the welfare of the horse from lay providers of equine dentistry and other services.

4. Promote the Profession

AAEP will expand its outreach to other industry stakeholders on the value of the equine veterinarian. This particular goal seeks to influence the lay encroachment on the practice of veterinary medicine. It involves a more aggressive outreach with industry stakeholders and horse owners on the value of an equine veterinarian as well as stronger advocacy for the equine veterinarian through a more advanced governmental relations program. The identification of specific stakeholder segments and message development will be the starting point for this long-term effort.

5. Offer the Finest Continuing Education

CE is AAEP's core mission and a permanent component of our strategic plan. AAEP will continue its culture of innovation and excellence by offering world-class, member-driven CE focused on timely topics and an enhanced member experience. On last year's CE Needs Analysis survey, you shared with us valuable insights on the medical topics most important to you so that our Educational Programs Committee can enhance our already popular CE options by delivering relevant and desired content. Additionally, we will take advantage of newer technologies for our CE delivery and will continue to identify innovative means to improve medical learning and member experience/networking opportunities at the annual convention.

Our strategic plan is ambitious, and we can't get it done in a year, so the board has prioritized the work plan so that we can make reasonable progress and measure our steps along the way. AAEP's strategic plan can be found at www.aaep.org/info/about-aaep.

These days, every product or service you buy, hotel you stay in, flight you take, and meal you have ends with you receiving a survey. We are all suffering from "survey fatigue," and we know we send you a lot—general surveys, economic surveys, continuing education surveys to name but a few. Your input is critical to us, and your views absolutely guide the board's decision-making in determining the overall direction of your association. We truly appreciate your interest and investment in making your association better. We'll keep asking.

Updated 'Immunization' PowerPoint presentation available

As an AAEP member, you can access ready-made client education PowerPoint presentations on core topics in equine health, including a newly updated presentation on immunizations. A new slide has been added to the presentation that details additional disease threats for which vaccines are available, including Leptospirosis, E. coli, Salmonella, anthrax and rattlesnake venom toxoid.

The Immunization PowerPoint presentation may be downloaded from www.aaep.org/info/client-education. If you host or are considering hosting client education seminars, we encourage you to visit the page to review all of the available PowerPoint topics. Contact Dana Kirkland, sponsorship and advertising coordinator, for additional information at dkirkland@aaep.org.



AAEPNEWS

142 members join AAEP's 'Honor Roll'

The AAEP has recognized long-standing commitments to the profession and association by conferring the Honor Roll distinction upon 142 veteran members who have reached the age of 70 and have maintained an AAEP membership for 40 years.

Congratulations to the following members who attained this milestone between July 1, 2015, and June 30, 2016:

Gordon J. Baker, BVSc PhD MRCVS, Essex, United Kingdom
William A. Baker, DVM, Versailles, KY
Jimmie U. Baldwin, DVM, Chelsea, OK
Charles R. Becker, DVM, Oxford, MI
Thomas J. Beckman, DVM, Hebron, KY
Ernest R. Benner, DVM, Charles Town, WV
Roy V. Bergman, VMD, Cochranville, PA
Jerry Bilinski, DVM, North Chatham, NY
Leonard P. Blach, DVM, Roswell, NM
R. Jerry Black, DVM, San Antonio, TX
Charles L. Boles, DVM, Buellton, CA
Randall H. Borri, DVM, Salem, WI
Malcolm J. Borthwick, Jr., VMD, New Hope, PA
R. Thomas Bowman, Jr., DVM, Chestertown, MD
Robert M. Bradley, DVM, Sun Valley, CA
Randall G. Brandon, DVM, Camden, SC
Larry A. Britt, DVM, Plant City, FL
William F. Brown, DVM, Spencer, TN
Charles F. Bryner, DVM, Saratoga Springs, NY
Wayne A. Burwash, DVM, Calgary, AB, Canada
Joseph F. Buxton, DVM, Snyder, OK
Paul F. Carney, DVM, Yuma, AZ
Mark W. Cheney, DVM, Lexington, KY
J. Clark Cleveland, Jr., DVM, Georgetown, KY
H. Steve Conboy, DVM, Lexington, KY
Peter S. Conserva, VMD, West Suffield, CT
Gary L. Cook, DVM, Bozeman, MT
William T.M. Cook, DVM Norwich, ON, Canada
Roger D. Cooper, DVM BA, Aberdeen, SD
Terry R. Corkran, VMD, Centreville, MD
Lanny H. Cornell, DVM, Rancho Santa Fe, CA
Albert Corte, Jr., DVM, Daphne, AL
R. Reynolds Cowles, Jr., DVM, Free Union, VA
Gary C. Cranney, DVM, San Marcos, CA
Sam M. Crosby, III, DVM, Edmond, OK
James R. Crum, DVM, Pike Road, AL
Andrew K. Currie, VMD, Llano, TX
Andrew P. Dalla Pozza, DVM, Kingston, WA
Tom V. David, DVM, Metairie, LA
Kenneth F. Delius, DVM, Orlando, FL
Wayne O. Evans, DVM, Mooers, NY
Keith R. Evringham, DVM, Aiken, SC
Bud Fackelman, DVM, Saratoga, WY
Ronald L. Fessler, DVM, Forest, VA
Mylon E. Filkins, DVM, Bakersfield, CA
Dave E. Fly, DVM, Edgewood, NM
Joseph J. Foerner, DVM, Plano, IL
Roger Footman, DVM, Erin, ON, Canada
Richard A. Frank, DVM, Stillwater, NY
Denys Frappier, DVM, Chateauguay, QC, Canada
Richard W. Fredericks, DVM, Northport, NY
Martin R. Frey, DVM MS, Corpus Christi, TX
Dale L. Gaide, DVM, Jackson, MI
Kenneth E. Gertsen, DVM, Highland, MI
Guy Giguere, DMV, Quebec, QC, Canada
Edward S. Gilbert, DVM, Odessa, FL
Ferris G. Gorra, DVM, New Milford, CT
Charles W. Graham, DVM, Elgin, TX
Barrie D. Grant, DVM MS DACVS, Bonsall, CA
Kenneth L. Greiner, DVM, Elbow Lake, MN
Alfred L. Hallowell, DVM, Auburn, WA
John Brian Hancey, DVM, Cambridge, ON, Canada
Roger A. Hanes, DVM, Windsor, CA
David V. Hanselka, DVM DACVS, Victoria, TX
C. Richard Harden, DVM, Richmond, VA
John M. Harris, Jr., DVM, Grand Junction, CO
Kent D. Haury, DVM, Halstead, KS
Gary E. Hefner, DVM, Allen, TX
Ronald L. Higginbotham, DVM, The Villages, FL
Dean F. Hill, DVM, Merrill, OR
Gene A. Hintz, DVM, Monument, CO
Donald L. Howard, DVM, Salem, OR
Donald C. Hunt, DVM, Middlebury, VT
David A. Jefferson, DVM, New Gloucester, ME
David H.R. Johnson, DVM BVSc, Middleboro, MA
Grant K. Johnson, DVM, North Lewisburg, OH
James N. Kantzer, DVM, Marion, OH
Larry H. Kelly, DVM, Lomita, CA
Richard M. Kester, DVM, Coral Springs, FL
Edward L. Larson, DVM BVSc, Watertown, SD
Ronald L. Laub, DVM, Lockeford, CA
Fred T. Lewis, DVM, Clarksville, MD
William F. Lieurance, DVM, Payson, AZ
Maury B. Linkous, III, DVM, Odessa, FL
Thomas G. Loafmann, DVM, Glencoe, MO
Joseph T. Lowry, DVM, Davis Junction, IL
John R. Lyon, DVM, Ojai, CA
Lawrence T. Maddren, DVM, Apalachicola, FL
Ronald J. Martens, DVM, Somerville, TX
Michael T. Martin, DVM, Bryan, TX
Donald J. McCrosky, DVM, Waterloo, IL
Don R. McDonald, DVM, Granbury, TX
John R. Mehaffey, DVM, Pataskala, OH
Jay G. Merriam, DVM MS, Glenwood Springs, CO
Thomas N. Monfort, DVM, Farmer City, IL
Robert L. Monroe, DVM, Kimberly, ID
James T. Morgan, DVM, Pilot Point, TX
Paul C. Mountan, DVM, Rhinebeck, NY
Harry A. Morrison, DVM, Bowmanville, ON, Canada
Jorge A. Murga, DVM, Chula Vista, CA
Rainer K. Muser, DVM, Rocky Hill, NJ
Gene O. Naugle, DVM, Penrose, CO
Dean P. Neely, VMD PhD, Ringoes, NJ
Frank A. Nickels, DVM, Lansing, MI
Paul M. Nolan, DVM, Ocean Ridge, FL
Robert M. Orcutt, DVM, Ipswich, MA
Frank C. Palka, DVM, Chester, CT
D. Kent Patton, DVM, Beatty, OR
William G. Paull, DVM, Delaware, OH
Frederick B. Peterson, VMD, Lexington, KY
Albert F. Polk, Jr., DVM, Burt Lake, MI
Kenneth S. Quirk, DVM, Salado, TX
J. Brent Rollins, DVM, Cave Creek, AZ
Marvin E. Rydberg, DVM, Lake Geneva, WI
Paul Ryding, DVM, Wichita, KS
James H. Schafer, DVM, Fort Collins, CO
Robert P. Schmitt, DVM, South Deerfield, MA
Roger I. Scullin, VMD, Damascus, MD
David B. Sequist, DVM, Stowe, VT
William J. Solomon, VMD, New Freedom, PA
Roger D. Spiess, DVM, Delta, OH
Max L. Sponseller, VMD, Georgetown, DE
Bronson K. Springstead, DVM BA, Jarales, NM
Gary M. Stangeland, DVM, Auburn, CA
Ted S. Stashak, DVM MS, Santa Rosa, CA
John R. Steele, DVM, Vernon, NY
James V. Stewart, VMD, Woodbine, MD
Ronald N. Stuber, VMD, Bigfork, MT
James A. Summers, DVM, Cave Creek, AZ
Terry Norman Teeple, DVM, Gig Harbor, WA
John M. Terry, DVM, Gilman, IA
Donald A. Trunk, DVM, San Diego, CA
Henry M. Vaupel, DVM, Fowlerville, MI
Helmuth Von Bluecher, DVM, Landrum, SC
Charles E. Wallace, DVM MS DACVS, Basseterre, Saint Kitts and Nevis
Harley L. Waxer, DVM, Willowdale, ON, Canada
William H. Whitney, DVM, Cedar Key, FL
Edward J. Wiebe, DVM, Langley, BC, Canada
James B. Wilkes, DVM, Martinez, GA
A. Barry Wood, DVM, Collinsville, TX
William C. Wood, DVM, Paulden, AZ
David G. Zipf, DVM, Dayton, MD

Touch Point: 'Difficult Conversations' video series helps you discuss tough topics with clients

The AAEP Touch Program's Difficult Conversations video series—new in 2016—delivers advice from veteran practitioners about topics that often can create challenging communication situations in daily practice.

The titles in the series are "Ending a Client Relationship"; "Euthanasia"; "Discussing Service Fees"; "Referring a Client"; and "Introducing a New Veterinarian to Clients."

According to market research with horse owners and trainers, the No. 1 reason why a client fires a veterinarian is because the client did not like the veterinarian's communication style or demeanor. In addition, when asked to rank the attributes most valued in a veterinarian, owners and trainers placed high importance on a veterinarian showing compassion towards the horse and listening to the client's opinion.

The Difficult Conversations series will help you navigate the sensitive topics that so strongly affect your relationships with your clients.

To access the videos and all other Touch resources, visit touch.aaep.org. You will log in using the same username and password as you use for the AAEP's main website, aaep.org. Look for the "Difficult Conversations" icon at the bottom of the website's home page.

Go behind the science: *EVE* and *EVJ* podcasts

Whether you want to make the best use of your time on the road or simply enjoy learning, download the latest editions of the *Equine Veterinary Education* and *Equine Veterinary Journal* podcasts from iTunes®.

In the current *EVE* episode, Drs. Undine Christmann and Courtney Pink discuss their paper "Lessons learned from a strangles outbreak on a large Standardbred farm"; and Dr. Craig Reinemeyer discusses the paper "Control of helminth parasites in juvenile horses." These papers are accessible at http://tinyurl.com/eve5161 and http://tinyurl.com/eve5162, respectively.

In the current *EVJ* episode, Dr. Jonathon Cheetham discusses the paper "Transoesophageal ultrasound and computer tomographic assessment of the equine *cricoarytenoid dorsalis* muscle: Relationship between muscle geometry and exercising laryngeal function"; and Dr. Michela Bullone discusses the paper "Environmental heat and airborne pollen concentration are associated with increased asthma severity in horses." These papers are available at http://tinyurl.com/evj6161 and http://tinyurl.com/evj6162.

Search "Equine Veterinary Education" and "EVJ" on iTunes to download the current episodes or subscribe to future episodes.

Broadway takes reins of American Horse Council

Julie Broadway

Julie Broadway, who served as executive director of the American Morgan Horse Association (AMHA) and Educational-Charitable Trust since 2007, has succeeded Jay Hickey as president of the American Horse Council (AHC). Hickey retired June 30 after 23 years in the position.

In addition to her duties at the AMHA, Broadway is the current board president for the Professional Association of Therapeutic Horsemanship and has played an active role with the AHC and the U.S. Equestrian Federation in recent years.

The AHC represents all segments of the horse industry before Congress and federal regulatory agencies.

AAEP Educational Partner Profile: Dechra Veterinary Products

Dechra Veterinary Products has emerged as a leader in equine medicine via a specialized range of approved products. In May 2014, Dechra achieved FDA-approval of OSPHOS® (clodronate injection), the only intramuscular bisphosphonate for control of the clinical signs associated with navicular syndrome in horses. We have taken a forward-thinking approach in regenerative medicine with our well-known brands, Orthokine® vet irap and Osteokine® (PRP). In addition to this line, Dechra also achieved FDA-approval in 2010 of Equidone® Gel (domperidone), a novel product for the prevention of fescue toxicosis in periparturient mares.

Dechra US recently acquired the manufacturing facility and assets to PSPC, Inc., including the PHYCOX® branded products. Auburn University has recently completed a study designed to observe improvements in lameness of the equine members of the Auburn University equestrian team after using Phycox EQ. The study has been submitted for review prior to publication.

To increase knowledge of Dechra products to all key customers, technical continuing education meetings are one of the primary ways Dechra interacts with veterinarians. Dechra has always believed in the concept of education as a platform upon which to build our company, while enhancing the veterinarian's and their staff's knowledge of the complex diseases that our products address. Dechra's educational offering serves to increase the knowledge of its customers primarily about disease states, case management and client communication; and secondarily about Dechra's product portfolio and how it can help improve the lives of the veterinarian's patients.

Dechra is committed to continually developing and investing in new products and services that support the work of the equine veterinarian and improve the health and welfare of the horse. As our equine team grows, we will strive to be a leading educator of veterinarians, technicians, students and horse owners, and give back to an industry that has helped us reach this level.

The AAEP welcomes new members and congratulates recent graduates

New Members:
Jessie Bridges, DVM, Penn Yan, NY
Carolyn Cooper, DVM, Ottawa, ON, Canada
Brittany Denker, DVM, Lexington, NE
Cancho Garcia, DVM, Madrid, Spain
Ahmed Ibrahim Mohmed Gawish, DVM, Abu Dhabi, United Arab Emirates
Catherine Sadtler Jacobs, DVM, Penryn, CA
Shannon McBride, DVM, San Marcos, CA
Michael Peters, DVM, Ava, MO
Phil Robinson, DVM, London, United Kingdom
Andrea Sanchez, DVM, Santa Ana, Costa Rica
Jennifer Sonis, DVM, Auckland, New Zealand
Richard A. Sylvester, DVM, Touchet, WA
David Warren, DVM, Weesatche, TX

Recent Graduates:
Marisa Adams, DVM, Issaquah, WA
Margaret Bojko, DVM, Oak Lawn, IL
Julia Elizabeth Coyle, DVM, Bloomfield Hills, MI
Megan Cullen, DVM, Chapel Hill, NC
Iris Rochelle Foote, DVM, Fowlerville, MI
Daniel S. Fordham, DVM, Camden, SC
Catherine Foreman, DVM, Aiken, SC
Emily Fournier, DVM, Ogden, KS
Chad Foust, DVM, Sheridan, WY
Amelia Hubbard, DVM, Stokesdale, NC
Crystal Martinez, DVM, Warrenton, NC
Caroline Ann McKinney, DVM, Grafton, MA
Elena McSherry, DVM, Lafayette, IN
Kathleen Morriss, DVM, Junction, TX
Shanna R. Nelson, DVM, Harrisonville, MO
Alexandra Radtke, DVM, Madison, WI
Jeremy Redmond, MSc, Vergennes, VT
Hannah Blair Richard, DVM MS, Vinton, LA
Lea Riddell, DVM, Saskatoon, SK, Canada
Heather E. Roney, DVM, Lansing, MI
Elizabeth Routh, DVM, Muncie, IN
Melissa Jen Lin Sim, DVM, Ravena, NY
Kathleen Stevens, DVM, Raleigh, NC
William Tyler Stevenson, DVM, Lamesa, TX
Stephanie White, DVM, Powell, WY

Members in the News

Five AAEP members appointed to AVMA committee posts


Dr. D. Craig Barnett


Dr. Matthew Edson


Dr. Clara Mason


Dr. Roger Saltman


Dr. Cara Wright

Five members of the AAEP were among recent committee appointments made by the AVMA board of directors.

Dr. D. Craig Barnett, director of equine veterinary technical services for Merck Animal Health in Paola, Ks., was reappointed the AAEP's primary representative to the Clinical Practitioners Advisory Committee. He is a 1985 graduate of the University of Missouri and has served on the AAEP's Biologic and Therapeutic Agents, Infectious Disease and Pediatrics committees.

Dr. Matthew Edson, owner of Rancocas Veterinary Associates in Mount Holly, N.J., was appointed to the Committee on Disaster and Emergency Issues representing food animal practice. He received his veterinary degree in 2011 from Kansas State University.

Dr. Clara Mason, owner of Clara A. Mason DVM Mobile Veterinary Services in Winfield, W.Va., and a member of the AAEP's Welfare and Public Policy Advisory Council, was reappointed the AAEP's alternate representative to the Animal Welfare Committee. Dr. Mason earned her DVM from Mississippi State University in 1992 and previously served on the AAEP's Educational Programs and Leadership Development committees.

Dr. Roger Saltman, group director of U.S. Cattle Veterinary Operations for Zoetis, was appointed at-large representative to the Veterinary Economics Strategy Committee. He is a 1981 graduate of Cornell University and resides in Cazenovia, N.Y.

Dr. Cara Wright, an equine relief veterinarian in Sarasota, Fla., was reappointed the AAEP's alternate representative to the Clinical Practitioners Advisory Committee. She received her DVM from Virginia-Maryland College of Veterinary Medicine in 2009.

Dr. James McDonald to Arizona Veterinary Hall of Fame


Dr. James McDonald

Dr. James McDonald, owner of EIEIO Professional Services in Camp Verde, Ariz., was inaugurated into the Arizona Veterinary Medical Association's (AzVMA) Veterinary Hall of Fame on May 20 for significant contributions to organized veterinary medicine and the veterinary profession.

Dr. McDonald has held every officer position within the AzVMA, including president in 2002. He currently chairs the Finance Committee and is retiring as the association's delegate to the AVMA.

In addition to his contributions within the AzVMA, Dr. McDonald has served on the AAEP's Educational Programs, Leadership Development and Public Policy committees.

Dr. Rebecca Stinson honored by University of Georgia CVM

Dr. Rebecca Stinson, a founding member of the Carolina Equine Hospital in Browns Summit, N.C., recently received a Distinguished Alumna Award from the University of Georgia College of Veterinary Medicine.


Dr. Rebecca Stinson

Dr. Stinson, who received her veterinary degree in 2002, is vice president of the AVMA. She previously served as a member of the AAEP's Student Relations Committee and as chair of the North Carolina VMA's Large Animal Committee.

AAEPNEWS

AAEP Meetings and Continuing Education

July 25-27, 2016	July 25-27, 2016	December 3-7, 2016	January 30-February 1, 2017
Focus on the Breeding Shed	Focus on Soft Tissue Lameness in the Performance Horse	62nd Annual Convention	19th Annual Resort Symposium
New Orleans, Louisiana	New Orleans, Louisiana	Orlando, Florida	The Westin, Grand Cayman

For more information, contact the AAEP office at (859) 233-0147 or (800) 443-0177 or online at ***www.aaep.org.***

Membership Benefits

Knowledge and networking opportunities merge at AAEP Annual Convention

Dr. Emma Read

"One of the best parts of my AAEP membership is attending the annual convention. The quality and variety of presentations is always excellent, and there are so many opportunities to make friends and catch up with old ones—some of whom I only see once a year at the meeting but can fall back into step with almost immediately and catch up on old times. Without a doubt, the trade show is the best in the business and not to be missed. If you can't find it there, then it doesn't exist!" —Emma Read, DVM, MVSc, DACVS, Calgary, Alberta, Canada

The AAEP's Annual Convention is the world's largest continuing education event dedicated to equine veterinary practice, and AAEP members receive a substantial discount on their registration compared to non-members.

With a choice from approximately 100 hours of continuing education credit, practitioners can acquire the most current clinical knowledge in diverse and important areas of equine medicine along with best business practices that are essential to a healthy bottom line.

The vast educational program is supplemented by daily networking and social events, which connect colleagues and expand professional footprints; and an expansive trade show that offers innovative solutions to practice challenges from more than 300 exhibitors.

The AAEP's 62nd Annual Convention will be held Dec. 3-7, 2016, at the Orange County Convention Center in Orlando, Fla. Prospective attendees are encouraged to register by Sept. 1 to save $115 off the standard registration rate. Visit www.aaep.org/info/annual-convention to register for the convention, book a hotel room or view the educational program.

AAEP group purchasing program qualifies your practice for substantial savings

As an AAEP member, you are eligible for substantial savings on supplies and services to operate your veterinary practice. The AAEP and The Veterinary Club have partnered to provide all AAEP members with access to the industry's most robust catalog of contracts offering substantial, quantifiable savings. Discounts are available at such companies as Verizon, Sprint, UPS, FedEx, Staples, Office Depot and Sherwin-Williams.

The Veterinary Club

Participation in the group purchasing program is free with your AAEP membership. Depending on usage, savings could exceed the annual cost of your AAEP membership.

To participate, AAEP members must register at www.theveterinaryclub.com. For more information about this membership benefit, contact Nick Altwies, membership services coordinator, at naltwies@aaep.org.

VETERINARY FORMULA
Wiser Concepts®

Dietary fat plays a role in managing patients with muscle myopathies and metabolic challenges

Horses diagnosed with muscle myopathies and metabolic challenges must be maintained on a diet low in starch and sugar. Energy derived from fat serves as an appropriate and healthy alternative.

Benefits of fat as an energy source

- Allows for a decrease in the amount of starch and sugar consumed while providing 2.25 times more energy
- Decreases lactic acid accumulation in muscle fibers during work
- Diminishes the incidence of hormone spikes that stress metabolic pathways
- Minimizes the risk of GI tract imbalances
- Provides plasma-free fatty acids for use during aerobic exercise
- Supports the proper absorption of the essential fat-soluble vitamins A, D, E and K

Support your patients with

WeightGainWise™

WeightGainWise is a high-fat supplement that helps patients achieve optimal performance levels, maintain condition, and remain healthy.

Available through all major veterinary suppliers.
Sold to veterinarians only.

For more information, call KPP:

800-772-1988

Developed by:

Kentucky Performance Products, LLC

KPPvet.com

EVE 2016-07

The Original - The Proven

Autologous treatment of joints, tendons and the back

Now two options to choose from!

Orthokine® vet irap 60

Orthokine irap 60:

- A completely closed system to reduce contamination
- Higher Serum yield and less hemolysis than other ACS kits on the market
- Sold through distribution

Orthokine® vet irap 10

Orthokine irap 10:

- Collect blood, process and deliver to the patient in the same day!
- No specialized centrifuge or rotor required (smaller syringe fits in a standard 12mL rotor)
- Kit includes everything needed for processing

For Technical Support or information, contact:
Dechra Veterinary Products at 866-933-2472 or www.dechra-us.com

Dechra
Veterinary Products

Highlights of recent clinically relevant papers

Third tarsal bone slab fracture repair

In this report Will Barker and Ian Wright, from the Newmarket Equine Hospital in the UK, describe minimally invasive repair of third tarsal bone slab fractures using a single 3.5 mm cortex screw placed in lag fashion in Thoroughbred racehorses.

Slab fractures of the third tarsal bone were repaired surgically in 17 Thoroughbred racehorses. The aim of surgical repair was to effectively compress the fracture, reduce secondary osteoarthritic changes and potentially reduce the time to return to training compared with conservative management.

Preoperatively, several radiographic views were taken until an optimal projection showing a single fracture line was obtained. This was used for surgical planning and intraoperative guidance. The fracture was displaced in 12 cases. A 'wedge-shaped' third tarsal bone has been thought to contribute to stress fractures; however, this conformation was present in only three cases. Periarticular new bone formation, loss of trabecular pattern, loss of bone density and loss of subchondral bone plate definition at the fracture site were present in several cases.

Surgical repair was performed under general anaesthesia with the affected limb held in extension. The proximal and distal margins of the fracture were defined by percutaneous needle markers. The area between these markers and the long and lateral digital extensor tendons was used to access the third tarsal bone. An 18 gauge spinal needle was placed in the centre of this area in line with the required trajectory of the implant screw. A vertical stab incision was made at the spinal needle. Under radiographic guidance, a glide hole was created along the spinal needle to the fracture site. A 2.5 mm thread hole was drilled before insertion of a 3.5 mm cortical screw. Fracture compression was confirmed radiographically and the skin incision closed.

Post operatively, horses were confined to a stable for 1–5 (median 4) weeks, before starting twice daily walking exercise for a minimum of 4 weeks. Trotting exercise then followed, increasing over 4 weeks before horses re-entered training.

Eleven horses (64%) raced post operatively (of which five had raced prior to surgery), three horses remained in rehabilitation, two were in training but had not yet raced and one had retired to stud. The mean time from surgery to first race was 7 months. Radiographic follow-up was performed in 15 horses. All fractures were healed at 4–6 months post operatively. In cases where loss of trabecular pattern, bone density or subchondral bone plate definition had been a feature, these progressively improved with fracture healing. New bone formation progressed in all five cases and occurred post operatively in one case.

This study shows that lag screw fixation of slab fractures of the third tarsal bone in racehorses is effective for stabilisation resulting in good rates of return to training and racing.

Neonatal encephalopathy survival

This retrospective cross-sectional study by Jocelyn Lyle-Dugas and colleagues in the USA aimed to determine the factors associated with outcome of foals hospitalised for neonatal encephalopathy (also known as neonatal maladjustment syndrome and dummy foals).

The clinical records of 94 foals (less than 14 days old at admission) were included in the study. Clinical information was subjected to statistical analysis, including signalment, vital signs at admission, clinical signs throughout hospitalisation including signs of neurological dysfunction, laboratory variables and the duration of clinical events. The diagnosis of neonatal encephalopathy was made on a clinical basis.

Of the 94 foals, 75 (79.8%) survived to discharge from the hospital. The most commonly recorded clinical signs were abnormal udder seeking, abnormal suckling, inability to stand, abnormal gastrointestinal motility, abnormal consciousness and seizures. In 14 foals, neonatal encephalopathy was the sole diagnosis. In the others, concurrent conditions reported were sepsis, pneumonia, prematurity/dysmaturity, patent urachus, limb deformity, colic and uroperitoneum.

Of the 19 nonsurvivors, four died and 15 were euthanased. Post mortem reports were available for 17 of which 11 had severe pneumonia, disseminated sepsis or sepsis-related complications. Microscopic examinations of brain sections were available in 11 cases and 10 showed neuronal necrosis or degeneration consistent with ischaemia. Factors which were significantly associated with nonsurvival in the multivariable logistic regression model were high total calcium concentration, low alkaline phosphatase activity, an increased number of co-morbidities, recumbency and the requirement for vasopressor therapy. Nonsurvivors were more likely to have received treatment with vasopressors, or received mechanical ventilation or respiratory stimulants than survivors. A wide range of medical treatments were used by different clinicians and no other therapeutic intervention was significantly associated with nonsurvival supporting the clinical impression that the quality of nursing care is most crucial to survival.

The prognosis for foals with neonatal encephalopathy in this study was good. No single therapy was shown to improve survival. High calcium and low alkaline phosphatase concentrations were found in nonsurvivors. Recumbency, multiple co-morbidities and use of vasopressors to treat hypotension are significantly associated with nonsurvival.

Heart rates in endurance riding

The aim of this study by Mette Flethøj and colleagues in Denmark was to evaluate heart rate, heart rate variability, and arrhythmia frequency as well as changes in cardiac biomarker values and their association with heart rate in horses before and after an endurance ride.

ECG recordings were obtained from 28 Arabian horses competing in a 120- or 160-km endurance ride before and after the ride to evaluate changes in heart rate and the SD of normal R-R intervals (SDNN) during the initial 12 hours of recovery. Frequencies of supraventricular and ventricular premature complexes before and after the ride were evaluated. Haematological analyses of blood samples obtained before the ride and twice during recovery included measurement of serum cardiac troponin I concentration and creatine kinase isoenzyme MB activity.

Heart rate was significantly increased and SDNN was decreased in the recovery compared with the prerace

period. Frequency of ventricular premature complexes increased slightly during recovery, whereas frequency of supraventricular premature complexes was not significantly different between preride and recovery periods. Serum cardiac troponin I concentration and creatine kinase isoenzyme MB activity were significantly increased in the recovery compared with the preride period. No associations were identified between cardiac biomarkers and velocity, distance, or mean heart rate.

Heart rate increased and SDNN decreased in horses after completion of an endurance ride. These and other cardiac changes suggested that prolonged exercise such as endurance riding might have cardiac effects in horses. Additional studies are needed to clarify the clinical relevance of the findings.

Joint lavage

The objective of this study by Andres Sanchez-Teran and colleagues in Canada and the UK was to evaluate the effect of through-and-through joint lavage on serum amyloid A (SAA) in the synovial fluid of six healthy horses.

One healthy tarsocrural joint of each horse was randomly assigned to receive repeated through-and-through joint lavage at 0, 48 and 96 h. Synovial fluid and blood samples were collected at 0 h (baseline) and at 24 h intervals for five days. Systemic and synovial SAA, total protein, nucleated cell count and percentage of neutrophils were measured and compared to baseline. Concentrations of systemic and synovial SAA percentage of neutrophils were not increased from baseline in contrast to total protein and nucleated cell counts (except for nucleated cell count at 96 h).

In conclusion, repeated through-and-through joint lavage did not affect synovial SAA concentrations in horses; however, synovial total protein and nucleated cell count values increased. Some of the total protein and nucleated cell count values observed in this study were within the range reported for septic arthritis 24 h after joint lavage. Therefore, synovial SAA may be a valuable marker to evaluate the clinical progression of septic joints after through-and-through joint lavage. Further clinical studies to evaluate synovial fluid SAA concentrations while treating synovial sepsis with through-and-through joint lavage are warranted.

Perineural injection of the ethmoidal nerve

In this study Michael Caruso and colleagues in the USA set out to describe the anatomical location of the ethmoidal nerve in the equine periorbital region and to determine the accuracy of a technique used to deposit local anaesthetic solution adjacent to the nerve.

Following preliminary dissections on 6 adult equine cadaver heads, 30 landmarks for injection of local anaesthetic adjacent to the ethmoidal nerve were identified. Evaluation of the injection technique was performed on 15 further cadaver heads by inserting a 20 gauge 6 cm spinal needle into the rostromedial aspect of the supraorbital fossa, where the caudal aspect of the zygomatic process emerges from the frontal bone caudal and medial to the globe. The needle was inserted to its hub at an angle of 110° to the long axis of the head using a protractor, in both sagittal and transverse planes, and 0.5 ml of new methylene blue dye was injected as a marker. The ethmoidal nerve was identified by dissection immediately after each injection and inspected for proximity of the dye. Dye was observed surrounding the nerve in 27 of 30 sites (90%) or lying within 5 mm of the nerve at the other 3 sites.

The technique described in this study proved reliable and simple. Anaesthetising the ethmoidal nerve may be helpful in desensitising portions of the ipsilateral paranasal sinuses and nasal cavity innervated by the nerve when sinonasal surgery is performed in the standing horse.

Airway angiogenesis in horses with heaves

In this study Nicolas Herteman and colleagues in Canada used narrow band imaging (NBI) endoscopy to determine whether the central airways of horses with heaves undergo angiogenesis.

Heaves, also known as recurrent airway obstruction, is a disease of horses characterised by lower airway inflammation and permanent structural changes of the bronchial wall. Chronic inflammation promotes the formation of new vessels, a process known as angiogenesis. Narrow band imaging endoscopy is a noninvasive technique that enhances the visualisation of submucosal vessels and commonly is used to study angiogenesis in human patients.

Eleven horses were studied (five with heaves and six healthy controls of similar age and weight). A library of NBI images was established from both the heaves and control horses. The images were taken from three sites: 130 from the trachea, 58 from the carina and 167 from the intermediate bronchi. Using dedicated stereology software, the volume density of superficial and deep vessels was calculated blindly by point counting at each site for all horses.

In the trachea, the volume density of superficial vessels was increased in horses with heaves compared with controls. No difference was found between groups for the volume density of both superficial and deep vessels at the carina or intermediate bronchi. Imaging of the airways using NBI was easily performed in standing sedated horses.

S. WRIGHT
EVE Editorial Office

References

Barker, W.H.J. and Wright, I.M. (2016) Slab fractures of the third tarsal bone: minimally invasive repair using a single 3.5 mm cortex screw placed in lag fashion in 17 Thoroughbred racehorses. *Equine Vet. J.* Epub ahead of print; DOI: 10.1111/evj.12570.

Caruso, M. 3rd, Schumacher, J. and Henry, R. (2016) Perineural injection of the ethmoidal nerve of horses. *Vet. Surg.* **45**, 494-498.

Flethøj, M., Kanters, J.K., Haugaard, M.M., Pedersen, P.J., Carstensen, H., Balling, J.D., Olsen, L.H. and Buhl, R. (2016) Changes in heart rate, arrhythmia frequency, and cardiac biomarker values in horses during recovery after a long-distance endurance ride. *J. Am. Vet. Med. Assoc.* **248**, 1034-1042.

Herteman, N., Bullone, M. and Lavoie, J.P. (2016) Endoscopic evaluation of angiogenesis in the large airways of horses with heaves using narrow band imaging. *J. Vet. Intern. Med.* **30**, 671-674.

Lyle-Dugas, J., Giguère, S., Mallicote, M.F., Mackay, R.J. and Sanchez, L.C. (2016) Factors associated with outcome in 94 hospitalised foals diagnosed with neonatal encephalopathy. *Equine Vet. J.* Epub ahead of print; DOI: 10.1111/evj.12553.

Sanchez-Teran, A.F., Bracamonte, J.L., Hendrick, S., Riddell, L., Musil, K., Hoff, B. and Rubio-Martínez, L.M. (2016) Effect of repeated through-and-through joint lavage on serum amyloid A in synovial fluid from healthy horses. *Vet. J.* **210**, 30-33.

ISELP has grown to over 800 Members World-Wide

Join Us in celebrating our 10th Year Anniversary in providing worldwide educational opportunities. Featured below is our second half of 2016 Three Day World-Wide Modules:

ONLINE REGISTRATION NOW OPEN

Registration Now Open for Italy & Kentucky



Pelvis
at Cascina Gufa
Merlino, Italy
July 1-3

Stifle & Thigh
at Hagyard Equine
Lexington, KY
August 25- 27



Shoulder & Elbow at Sporthorse
Medical Diagnostic Centre
Heesch, The Netherlands
September 16-18

Hock & Crus
At Kleider Veterinary Services
Langley, British Columbia
Sept. 29 – Oct. 1

2 Day Advanced
Pre-Purchase Exam
Clinique de Grosbois
Boissy St. Leger, France
October 26 - 27

Prox. Susp. To Distal Hind Limb
At Clinique de Grosbois
Boissy Saint Leger, France
October 28-30

CELEBRATING 10 YEARS
2006–2016

For More Information Please Visit www.iselp.org

www.iselp.org 540-687-4663 info@iselp.org

Case Report

Haemoperitoneum in a pregnant mare with an ovarian haematoma

T. M. Beachler, C. S. Bailey*, K. A. McKelvey, J. L. Davis, A. Edwards, M. Diaw, J. M. Vasgaard and M. D. Whitacre

College of Veterinary Medicine, North Carolina State University, Raleigh, USA.
**Corresponding author email: scot_bailey@ncsu.edu*
M. Diaw's present address: Universite de Montreal, Faculte de Medecine Veterinaire, 3200, rue Sicotte, Saint-Hyacinthe, Québec, Canada J2S 2M2.

Keywords: horse; haemoperitoneum; pregnancy; ovary; haematoma

Summary

Haemoperitoneum is a rarely reported but life-threatening complication of a multitude of disease processes that can affect horses. This report describes an unusual case of haemoperitoneum in a pregnant mare attributed to a unilateral ovarian haematoma during early gestation. The mare was treated with supportive care and discharged 8 days after initial presentation. Following discharge, the mare maintained her pregnancy to term and delivered a live colt at 321 days of gestation.

Introduction

Haemoperitoneum, or haemoabdomen, is characterised by the accumulation of blood within the peritoneal space due to intra-abdominal haemorrhage. Incidence within the equine population is rare, compared to that diagnosed in small animals and man, but it is often a life-threatening condition (Dechant *et al*. 2006). Affected horses present with a variety of clinical signs dependent upon the cause and severity of intra-abdominal haemorrhage. Common clinical findings include signs of anaemia, characterised by pale mucous membranes, lethargy, inappetence, tachycardia, tachypnoea, colic and evidence of shock or acute death, depending on the degree of blood loss (Dechant *et al*. 2006; Conwell *et al*. 2010). The aetiology of the haemorrhage may be investigated by rectal palpation, transrectal ultrasonography or transabdominal ultrasonography. However, the condition is often diagnosed upon surgical exploration or *post mortem* examination in horses. In small animals and man, additional imaging modalities including computed tomography and magnetic resonance imaging can be utilised to further investigate and identify underlying pathology; however, these imaging modalities are not currently able to image the abdomen in adult equine patients and this makes obtaining a final diagnosis challenging. This case describes the diagnosis and management of a pregnant mare with haemoperitoneum attributed to a large ovarian haematoma.

Case history

A 7-year-old Friesian mare used for competitive driving and as a broodmare was referred to the equine medicine department at the North Carolina State University College of Veterinary Medicine for evaluation of signs of severe anaemia. The mare delivered one foal without complication in 2009, in addition to achieving a successful pregnancy through embryo transfer in 2012. She had otherwise been healthy with no previous episodes of systemic illness. At presentation (denoted as Day 0), she was pregnant at 61 days of gestation. According to her owner, that morning she had been found acutely inappetent and depressed. On examination by her referring veterinarian, she was found to be tachycardic, tachypnoeic and severely anaemic (packed cell volume [PCV] 0.20 l/l) and was treated with intravenous (i.v.) flunixin meglumine (Banamine 1.1 mg/kg bwt i.v. s.i.d)[1] prior to referral.

Clinical findings

Upon presentation, the mare was mildly depressed and in moderate body condition. Tachycardia (60 beats/min), tachypnoea (60 breaths/min) and pale, tacky mucous membranes were detected on physical examination.

Ancillary diagnostic tests

Clinical pathology

Blood was drawn for a complete blood count (CBC), serum biochemistry and venous blood gas analysis. The results of the CBC revealed a severe normocytic, normochromic anaemia attributed to an episode of acute blood loss (PCV 0.19 l/l; rr: 0.28–0.40 l/l and total protein 46 g/l; rr: 59–80 g/l), mild leucocytosis (10.8×10^9/l; rr: 4.7–10.40 $\times 10^9$/l) characterised by a mature neutrophilia (8.9×10^9/l; rr: 2.5–6.8 $\times 10^9$/l) and monocytosis (0.54×10^9/l; rr: 0.017–0.52 $\times 10^9$/l), likely attributed to stress. Serum biochemistry revealed moderate hypoproteinaemia (40 g/l; rr: 55–75 g/l) characterised by a mild hypoalbuminaemia (21 g/l; rr: 28–35 g/l) and hypoglobulinaemia (19 g/l; rr: 24–4.4 g/l), hypocalcaemia (92 mg/l; rr: 113–134 mg/l) and hypochloraemia (96 mmol/l; rr: 98–103 mmol/l). Venous blood gas analysis revealed a moderate alkalosis (pH 7.52; rr: 7.16–7.45) and hyperlactataemia (5.5 g/l). All other values remained within normal limits.

Transabdominal ultrasound

On transabdominal ultrasonography a significant, highly cellular peritoneal effusion was seen diffusely throughout the abdomen (**Fig 1**) whereby visualisation of other abdominal organs was difficult.

Transrectal palpation and ultrasound

On transrectal palpation of the reproductive tract the pregnancy was consistent with approximately 60 days of

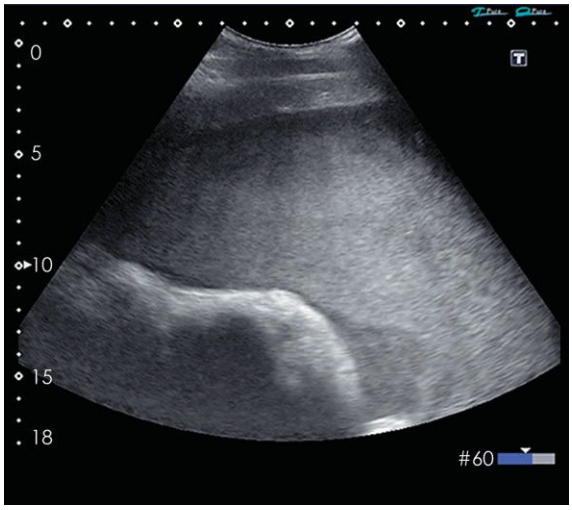

Fig 1: Greyscale transabdominal ultrasound image on initial presentation revealing a significant highly cellular peritoneal effusion evident throughout abdomen.

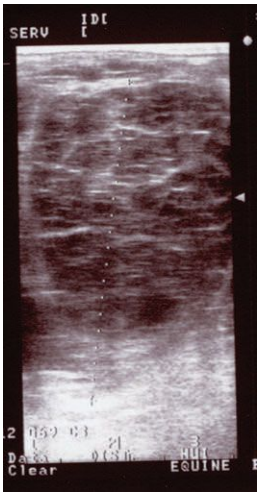

Fig 2: Greyscale transrectal image of right ovary with organised fibrin filled ovarian haematoma. Right ovary: 10.2 cm length × 10 cm width. Diameter of ovarian haematoma within right ovary: 9.2 cm.

gestation. On palpation of the ovaries, mild enlargement of the left ovary, estimated to be roughly the size of a softball (approximately 12 × 12 cm in diameter), was noted, along with significant enlargement of the right ovary, estimated to be roughly the size of a large cantaloupe (approximately 15 × 25 cm in diameter). Exact ovarian measurements were difficult to obtain as both the length and width of each ovary extended beyond that measurable by a 7.5 Hz transrectal probe. Transrectal ultrasonography revealed multiple *corpora lutea* and a large (50 mm) anovulatory follicle on the left ovary. A large organising ovarian haematoma was present on the right ovary measuring approximately 9.2 cm in diameter (**Fig 2**). No other ovarian structures could be visualised at that time on the right ovary. The uterus and broad ligament appeared within normal limits, with an active fetus and fetal heartbeat present, consistent with a 60 day pregnancy.

Abdominocentesis

Abdominocentesis was performed to characterise the peritoneal effusion. The sample was consistent with a haemorrhagic effusion with a PCV of 0.46 l/l, total protein 40 g/l and specific gravity 1.030. On cytological examination, marked haemodilution was present with occasional large mononuclear cells. Frequent erythrophagia with haemosiderin was noted with no evidence of any aetiological agents or neoplasia, indicative of a relatively chronic rather than acute haemorrhage.

Coagulation panel

Prothrombin time (PT) and partial thromboplastin time (PTT) were within normal limits.

Cross-match

Due to the mare's severity of anaemia as well as a continued decrease in PCV, a cross-match was performed with 5 available blood donors at the teaching hospital. Major cross-match abnormalities were detected with all 5 potential donors.

Definitive diagnosis

Haemoperitoneum associated with unilateral ovarian haematoma.

Treatment and outcome

On admission, an i.v. catheter was placed in the left jugular vein and the mare treated with i.v. fluids consisting of Ringer's Lactate (Veterinary Lactated Ringer's injection USP 0.5 l h)[2] and a constant rate infusion of the antifibrinolytic agent aminocaproic acid (Aminocaproic Acid injection USP 0.25 mg/kg bwt/min following a loading dose of 3.5 mg/kg bwt i.v. s.i.d)[3]. Ceftiofur sodium (Naxcel 5 mg/kg bwt i.v. b.i.d.)[4] was started as a broad spectrum antibiotic therapy to prevent secondary bacterial peritonitis. To prevent abortion resulting from development of potential peritonitis, endotoxaemia and inflammation, flunixin meglumine (Banamine 1.1 mg/kg bwt i.v. b.i.d.)[1] was continued as an anti-inflammatory and analgesic drug and a double dose of the synthetic progestin altrenogest (Regumate 0.088 mg/kg bwt *per os* s.i.d.)[1] was also started (Kindahl *et al*. 1991; Daels *et al*. 1996). Serial PCVs were performed overnight which illustrated an increasing anaemia until stabilisation at 0.16 l/l. A blood transfusion was considered upon initial presentation; however, conservative management was elected due to major cross-match abnormalities with all available blood donors as well as stabilisation of the PCV.

By the next morning, aminocaproic acid was discontinued following PCV stabilisation and the mare appeared brighter with an increased appetite for offered feed. All physical examination parameters had returned to normal limits. Repeat transabdominal ultrasonography revealed marked improvement with significant decrease in both volume and cellularity of the visualised peritoneal effusion (**Fig 3**). A coupled abdominocentesis and systemic PCV was performed at that time, revealing 0.35 and 0.18 l/l, respectively. Over the next few days, the mare continued to remain bright and alert with a normal appetite. A repeat CBC was performed 2 days following initial presentation, demonstrating a continued normocytic, normochromic, anaemia (PCV 0.18 l/l) and mild hypoproteinaemia (59 g/l; rr: 55–75 g/l) characterised by a

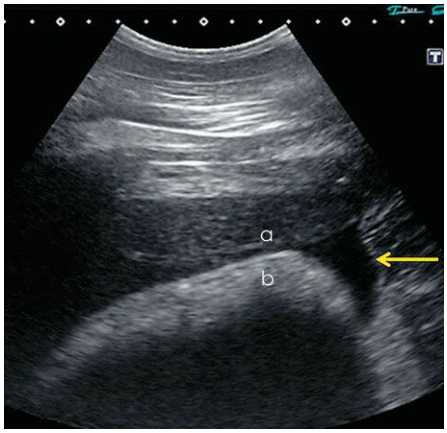

Fig 3: Greyscale transabdominal image taken 24 h following presentation. Significant decreased cellularity and volume of peritoneal effusion (yellow arrow) is evident in this image between liver (a) and colon (b).

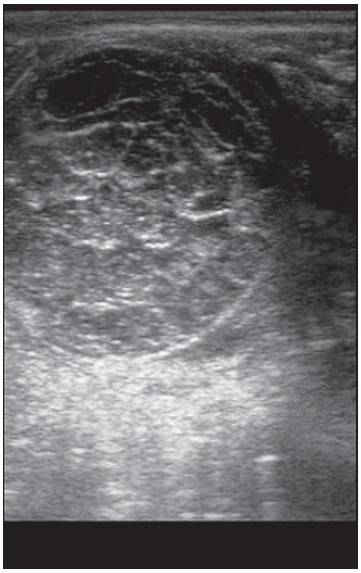

Fig 4: Greyscale transrectal ultrasound image revealing decreased diameter of the ovarian haematoma and increased organisation on Day 3 following initial presentation.

mild hypoalbuminaemia (25 g/l; rr: 28–35 g/l). All other parameters were within normal limits, and i.v. fluid therapy was discontinued at that time.

Repeat transrectal ultrasonography performed on Day 3 continued to reveal a normal active fetus. Examination of the ovaries revealed a similarly appearing left ovary with multiple *corpora lutea* and a large anovulatory follicle. A significant decrease in the size of the right ovary was noted and estimated approximately to that of a softball (approximately 12 × 12 cm in diameter) with an increased organisation and decreased diameter of the ovarian haematoma (**Fig 4**). Multiple *corpora lutea* could also be seen within the right ovary. By Day 5, all CBC values had returned to normal levels (PCV 0.31 l/l) and small amounts of hand walking and grazing were allowed. On Day 6, both ovaries appeared similar in size on repeat transrectal palpation and ultrasonography, 8.7 × 11.2 cm and 8.2 × 9.8 cm for the left and right ovaries

Fig 5: Greyscale transrectal ultrasound image revealing decreased diameter of the ovarian haematoma on Day 6 following initial presentation.

respectively, with continued reduction in ovarian haematoma diameter and reorganisation (**Fig 5**). The mare was transitioned to oral trimethoprim sulfa (Sulfamethoxazole and trimethoprim tablets USP[5] 30 mg/kg bwt *per os* b.i.d.) on Day 7 and was discharged from the hospital on Day 8 with instructions to continue oral trimethoprim sulfa and altrenogest until recheck in approximately 7 days.

Upon recheck examination at 75 days of gestation, the mare's pregnancy was within normal limits, with an active fetus present and fetal heartbeat of approximately 120 beats/min. At that time, only multiple *corpora lutea* could be detected on each ovary following reorganisation of the ovarian haematoma. All physical examination parameters remained within normal limits, with no signs of repeat haemorrhage. Altrenogest was decreased to a single dose (0.044 mg/kg bwt *per os* s.i.d.). The mare was rechecked again at 99 days of gestation with no abnormalities noted. At that time, serum progesterone concentration was 44 ng/ml and altrenogest was tapered and discontinued. The mare continued to be closely monitored at home and delivered a live colt at 321 days of gestation.

Discussion

This report describes an unusual case of haemoperitoneum in a pregnant mare. Utilising available imaging modalities, the only potential source of haemorrhage identified in this case was a large unilateral, right ovarian haematoma. While the presumptive diagnosis could not be confirmed, no other abnormalities were visualised on transabdominal ultrasound examination, nor was there an indication of organ dysfunction, systemic disease or coagulopathies on any biochemical profile or coagulation panel. The therapeutic protocol was selected based on treatment of other more common causes of haemoperitoneum and based on published interventions for gestational support in high risk equine pregnancies. Flunixin meglumine is an NSAID used widely in the horse which is very effective at inhibiting prostaglandin production systemically and in placental tissue (Bailey 2013). Both flunixin meglumine

and altrenogest have further previously been shown to clinically prevent LPS-induced abortion in mares (Daels *et al*. 1996). Although flunixin meglumine may have some effect on platelet aggregation *in vitro* (Johnstone 1983), in the authors' experience, this does not cause a clinical issue with thrombus formation and the benefits of flunixin administration were considered to outweigh the risk in this case. Aminocaproic acid is an antifibrinolytic drug shown to inhibit fibrinolysis (Fletcher *et al*. 2013), decrease fibrinogen and shorten partial thromboplastin times (Heidmann *et al*. 2005) and improve platelet function (Ross *et al*. 2007) in horses. The drug was selected in this case to help stabilise the ovarian haematoma in an attempt to prevent further bleeding, as well as offset any potential effects of flunixin on platelet function.

In the equine ovary, antral or mature tertiary follicles are composed of 3 distinct layers, the *theca externa*, *theca interna* and granulosa cell layer. The *theca externa* supports the follicular structure and is composed of loose connective tissue as well as a rich blood supply. The *theca interna* produces androgens in response to stimulation by luteinising hormone (LH). During normal ovulation, a *corpora haemorrhagicum* (CH) is formed as the oocyte and cumulus complex, granulosa cells and follicular fluid are evacuated from the follicle through the ovarian fossa. During ovulation, small vessels present in the highly vascular thecal layer rupture and small to substantial amounts of haemorrhagic or serosanguinous fluid can accumulate within the previous follicular cavity forming a CH (Bergfelt and Adams 2007). Low concentrations of antifibrinogen as well as the anticoagulants antithrombin III and antiplasmin found within the follicular fluid are believed to prevent the evacuating ovum from fusing to the forming clot during CH formation (Yamada and Gentry 1995). *Corpora haemorrhagicum* formation is not a pathological condition with 50–70% of mares forming these structures following a normal ovulation on ultrasonographic examination (Bergfelt and Adams 2007). The fluid-filled cavity within the CH will decrease in size over time due to initial clotting of haemorrhaging vessels and subsequent clot reorganisation over the days following ovulation. Luteinisation and formation of the *corpus luteum* (CL) occurs with the *theca interna* and granulosa cells forming small and large luteal cells, respectively.

Ovarian haematomas may be formed when excessive haemorrhage occurs during ovulation. While ovarian haematomas have been described as a common cause of unilateral ovarian enlargement, their true incidence has not been fully defined within the equine population (Bosu *et al*. 1982). Haematomas are differentiated from haemorrhagic anovulatory follicles as the haematoma may greatly exceed the diameter of the original follicle and a haemorrhagic anovulatory follicle typically begins approximately the same size as its preceding follicle. Regression of the ovarian haematoma is often completed over the next 1–2 oestrous cycles; however, they may persist for several months (McCue 2008). Mares that develop ovarian haematomas typically retain cyclicity and can become and remain pregnant. Endocrine patterns within cycling and pregnant mares remain normal with no obvious behavioural abnormalities noted (McCue 2008). In contrast, haemorrhagic anovulatory follicles do not result in pregnancy due to the lack of a true ovulation and can be associated with a delay in normal return to oestrus.

The mare discussed in this report likely developed an ovarian haematoma as a result of stimulation by equine chorionic gonadotropin (eCG), a hormone secreted by endometrial cups during normal equine pregnancy. Around Day 25 of gestation, the chorionic girdle cells develop from an infolding of the trophoblast layer of the conceptus. These binucleate girdle cells grow and multiply until approximately 35 days when a distinct band or chorionic girdle can be seen. At this time, girdle cells separate from the underlying trophoblast layer and begin to invade the maternal endometrium, reaching the endometrial stroma around Day 40 (Allen and Wilsher 2009). Once within the stroma, migration stops and the cells continue to grow and divide, forming a series of endometrial cups. Secretion of eCG is maximal at approximately 60–80 days of gestation. In the mare, eCG has both LH and follicular stimulating hormone (FSH) activity and acts in concert with FSH produced by the anterior pituitary to cause follicular recruitment, development and subsequent ovulation and/or luteinisation. This process results in the formation of secondary and accessory CLs, respectively. Progesterone produced by secondary and accessory CLs under the effect of eCG are vital for maintenance of equine pregnancy between gestational Day 35 and the onset of fetoplacental steroidogenic competence at approximately 120 days and concurrent wane of eCG production (Holtan *et al*. 1979, 1991). However, the degree of ovarian activity under the influence of eCG also results in dramatic enlargement of the ovaries, including the development of ovarian haematomas and anovulatory follicles (Squires and Ginther 1975). The mare described in this report was at approximately 60 days of gestation during the peak of eCG production and its responding follicular activity. At approximately 99 days of gestation, serum progesterone concentration was measured at 44 ng/ml, consistent with the formation of multiple secondary and accessory CLs earlier in gestation. Therefore the formation of an ovarian haematoma in this case was likely a response to the increase in follicular activity seen during normal equine pregnancy under eCG stimulation.

In horses, dogs, cats and man, aetiologies of haemoperitoneum have been classified into traumatic and nontraumatic categories (Lucey *et al*. 2005; Dechant *et al*. 2006; Herold *et al*. 2008). Traumatic causes can involve either a direct penetrating or blunt force injury to intra-abdominal organs, vessels or other structures. Atraumatic aetiologies frequently include rupture of intra-abdominal neoplasms particularly those involving the spleen or liver, idiopathic cases where an underlying diagnosis is not obtained, coagulopathies, mesenteric injuries, vascular abnormalities or abnormalities involving the internal reproductive tract. Splenic abnormalities involving both traumatic and atraumatic disease are the most commonly reported cause of canine haemoperitoneum (Pintar *et al*. 2003; Lux *et al*. 2013). Splenic haemangiosarcoma was diagnosed as the most frequent cause, accounting for 70–88% of cases (Culp *et al*. 2010; Lux *et al*. 2013).

Reproductive aetiologies of haemoperitoneum are frequently diagnosed in women, with ectopic pregnancies or rupture of ovarian cysts detected as the most common causes of haemoperitoneum in women of childbearing years (Furlan *et al*. 2009). Likewise, in horses, reproductive abnormalities have been reported to be the most commonly diagnosed causes of haemoperitoneum, with 22% involving rupture of the

uterine artery or uterine lacerations (Conwell *et al*. 2010). Another retrospective study found 13.4% of all reported cases resulted from haemorrhage from uterine artery rupture (Dechant *et al*. 2006). Uterine artery rupture is one of the most well known, as well as the most frequently diagnosed, reproductive cause of haemoperitoneum in horses. Affected horses include both peri- and *post partum* mares. Common presenting signs are those of colic and acute blood loss. The uterine artery is most frequently affected; however, the utero-ovarian arteries, external iliac arteries and vaginal arteries have reportedly also been affected (Arnold *et al*. 2008). Other reproductive abnormalities associated with equine haemoperitoneum include rupture of ovarian neoplasms, with the most common neoplasm being granulosa theca cell tumour (GCT); however, cases of ovarian adenocarcinoma have also been previously reported (Pauwels *et al*. 2012). Equine ovarian haematomas have rarely been reported as a cause of haemoperitoneum in the literature (Pusterla *et al*. 2005; Dechant *et al*. 2006; Conwell *et al*. 2010). Of 2 previous case reports identifying ovarian haematomas as a source of intra-abdominal haemorrhage, only one reported a successful outcome. In one case, haemorrhage was detected from bilateral ovarian haematomas in an early pregnant mare at 45 days of gestation (Serdish and Johnson 1997). In a second case, a unilateral ovarian haematoma was identified as the source of cyclic acute haemorrhage over successive oestrous cycles in an open miniature mare (Maxson *et al*. 1993). The mare was stabilised using a bovine haemoglobin preparation and the ovary surgically removed. Unlike the other 2 previously reported cases, the mare in this report responded well to supportive therapy and did not show additional episodes of haemorrhage throughout gestation, delivering a healthy colt at 321 days of gestation.

Authors' declaration of interest

No conflicts of interest have been declared.

Manufacturers' addresses

[1]Intervet Inc., Merck Animal Health, Summit, New Jersey, USA.

[2]Abbott Laboratories, North Chicago, Illinois, USA.

[3]Hospira Inc., Lake Forest, Illinois, USA.

[4]Zoetis Inc., Kalamazoo, Michigan, USA.

[5]Aurobindo Pharma Inc., Dayton, New Jersey, USA.

References

Allen, W.R. and Wilsher, S. (2009) A review of implantation and early placentation in the mare. *Placenta* **30**, 1005-1015.

Arnold, C.E., Payne, M., Thompson, J.A., Slovis, N.M. and Bain, F.T. (2008) Periparturient hemorrhage in mares: 73 cases (1998-2005). *J. Am. Vet. Med. Ass.* **232**, 1345-1351.

Bailey, C.S. (2013) Update on placentitis-what has been accomplished in the last 3 years? *Clin. Therio.* **5**, 326-333.

Bergfelt, D.R. and Adams, G.P. (2007) Ovulation and corpus luteum development. In: *Current Therapy in Equine Reproduction*, Eds: J.C. Samper, J.F. Pycock and A.O. Mckinnon, Elsevier, St Louis. pp 1-13.

Bosu, W.T.K., Van Camp, S.C., Miller, R.B. and Owen, R. (1982) Ovarian disorders: clinical and morphological observations in 30 mares. *Can. Vet. J.* **23**, 6-14.

Conwell, R.C., Hillyer, M.H., Mair, T.S., Pirie, R.S. and Clegg, P.D. (2010) Hemoperitoneum in horses: a retrospective review of 54 cases. *Vet. Rec.* **167**, 514-518.

Culp, W.T.N., Weisse, C., Kellogg, M.E., Gordon, I.K., Clark, D.L., May, L.R. and Drobatz, K.J. (2010) Spontaneous hemoperitoneum in cats: 65 cases (1994-2006). *J. Am. Vet. Med. Ass.* **236**, 978-992.

Daels, P.F., Besognet, B., Mohammed, H. and Odensvik, K. (1996) Effect of progesterone on prostaglandin F2 alpha secretion and outcome of pregnancy during cloprostenol-induced abortion in mares. *Am. J. Vet. Res.* **57**, 1331-1337.

Dechant, J.E., Nieto, J.E. and Jejune, S.S. (2006) Hemoperitoneum in horses: 67 cases (1987-2004). *J. Am. Vet. Med. Ass.* **229**, 253-258.

Fletcher, D.J., Brainard, B.M., Epstein, K., Radcliffe, R. and Divers, T. (2013) Therapeutic plasma concentrations of epsilon aminocaproic acid and tranexamic acid in horses. *J. Vet. Intern. Med.* **27**, 1589-1595.

Furlan, A., Fakhran, S. and Federle, M.P. (2009) Spontaneous abdominal hemorrhage: causes, CT findings, and clinical implications. *Am. J. Roentgenol.* **193**, 1077-1087.

Heidmann, P., Tornquist, S.J. and Qu, A. (2005) Laboratory measures of hemostasis and fibrinolysis after intravenous administration of ε-aminocaproic acid in clinically normal horses and ponies. *Am. J. Vet. Res.* **66**, 313-318.

Herold, L.V., Devey, J.J., Kirby, R. and Rudloff, E. (2008) Clinical evaluation and management of hemoperitoneum in dogs. *J. Vet. Emerg. Crit. Care* **18**, 40-53.

Holtan, D.W., Houghton, E., Silver, M., Fowden, A.L., Ousey, J. and Rossdale, P.D. (1991) Plasma progestagens in the mare, fetus, and newborn foal. *J. Reprod. Fertil., Suppl.* **44**, 517-528.

Holtan, D.W., Squires, E.L., Lapin, D.R. and Ginther, O.J. (1979) Effect of ovariectomy on pregnancy in mares. *J. Reprod. Fertil., Suppl.* **27**, 457-463.

Johnstone, I.B. (1983) Comparative effects of phenylbutazone, naproxen, and flunixin meglumine on equine platelet aggregation and platelet factor 3 availability in vitro. *Can. J. Comp. Med.* **47**, 172-179.

Kindahl, H., Daels, P., Odensvik, K., Daunt, D., Fredricksson, G., Stabenfeldt, G. and Hughes, J.P. (1991) Experimental models of endotoxemia related to abortion in the mare. *J. Reprod. Fertil., Suppl.* **44**, 509-516.

Lucey, B.C., Varghese, J.C. and Soto, J.A. (2005) Spontaneous hemoperitoneum causes and significance. *Current Probl. Diagn. Radiol.* **Sept/Oct**, 182-195.

Lux, C.N., Culp, W.T.N., Mayhew, P.D., Tong, K., Rebhun, R.B. and Kass, P.H. (2013) Perioperative outcome in dogs with hemoperitoneum: 83 cases (2005-2010). *J. Am. Vet. Med. Ass.* **242**, 1385-1391.

Maxson, A.D., Giger, U., Sweeney, C.R., Tomasic, M., Saik, J.E., Donawick, W.J. and Cothran, E.G. (1993) Use of a bovine hemoglobin preparation in the treatment of cyclic ovarian hemorrhage in a miniature horse. *J. Am. Vet. Med. Ass.* **203**, 1308-1311.

McCue, P.M. (2008) Review of ovarian abnormalities in the mare. *Proc. Am. Ass. Equine Practnrs.* **44**, 125-133.

Pauwels, F.E.T., Wigley, S.J., Munday, J.S. and Roe, W.D. (2012) Bilateral ovarian adenocarcinoma in a mare causing haemoperitoneum and colic. *N. Zeal. Vet. J.* **60**, 198-202.

Pintar, J., Breitschwerdt, E.B. and Hardie, E.M. (2003) Acute nontraumatic hemoabdomen in the dog: a retrospective of 39 cases. *J. Am. Anim. Hosp. Ass.* **39**, 518-522.

Pusterla, N., Fecteau, M.E., Madigan, J.E., Wilson, W.D. and Magdesian, K.G. (2005) Acute hemoperitoneum in horses: a review of 19 cases (1992-2003). *J. Vet. Intern. Med.* **19**, 344-347.

Ross, J., Dallap, B.L., Dolente, B.A. and Sweeney, R.W. (2007) Pharmacokinetics and pharmacodynamics of ε-aminocaproic acid in horses. *Am. J. Vet. Res.* **68**, 1016-1021.

Serdish, S.A. and Johnson, P.J. (1997) Theriogenology question of the month. *J. Am. Vet. Med. Ass.* **210**, 179-180.

Squires, E.L. and Ginther, O.J. (1975) Follicular and luteal development in pregnant mares. *J. Reprod. Fertil., Suppl.* **23**, 429-433.

Yamada, M. and Gentry, J.A. (1995) The hemostatic profile of equine ovarian follicular fluid. *Thromb. Res.* **77**, 45-54.

Clinical Commentary

Diagnosis, management and prognosis for haemoperitoneum in the horse

J. F. Hawkins

Department of Veterinary Clinical Sciences, College of Veterinary Medicine, Purdue University, West Lafayette, Indiana, USA.
Corresponding author email: hawkinsj@purdue.edu

Keywords: horse; abdomen; haemoperitoneum; blood transfusion

Introduction

Haemoperitoneum is a relatively uncommon cause of blood loss anaemia in the horse (Pusterla *et al.* 2005; Dechant *et al.* 2006; Conwell *et al.* 2010; Mudge 2014; Gray *et al.* 2015; Luethy *et al.* 2016). The most common causes of haemoperitoneum include abdominal trauma, reproductive abnormalities, post surgical haemorrhage, abdominal neoplasia and idiopathic. Affected horses are straightforward to diagnose because of abnormal physical examination findings and clinical pathology data. This commentary will focus on the historical findings, diagnostics and treatment of haemoperitoneum.

Historical findings

Historical findings associated with haemoperitoneum include recent abdominal wall trauma (e.g. kicks from another horse, collisions with immobile objects, etc.), pregnancy (as in the case report by Beachler *et al.* [2016] in this issue), previously performed surgical procedures (including castration, ovariectomy and gastrointestinal procedures), weight loss and chronic signs of abdominal pain. Horses can be subdivided into 3 categories: reproductive (male and female), post operative and post traumatic.

Reproductive

Female horses suspected of haemoperitoneum are usually cycling, pregnant or post partum (Green *et al.* 1988; Gatewood *et al.* 1990; Maxson *et al.* 1993; Sedrish and Johnson 1997; Alexander *et al.* 2004; Pauwels *et al.* 2012). Cycling and pregnant mares may be predisposed to ovarian haematomas or uterine neoplasia. Post partum mares are most commonly affected with haemoperitoneum secondary to rupture of the uterine arteries or uterus.

Post operative

Male horses following castration are at risk of haemoperitoneum secondary to bleeding from the spermatic cord or testicular artery. Similarly female horses following ovariectomy are at risk of haemoperitoneum. Haemoperitoneum following gastrointestinal surgery is most common following intestinal resection and anastomosis (Gray *et al.* 2015).

Post traumatic

Horses with a recent history of abdominal wall trauma (e.g. kicks and collisions with immobile objects) can be predisposed to traumatic disruption of the splenic or liver parenchyma and disruption of the body wall musculature, all of which can result in haemoperitoneum.

Abdominal neoplasia

Abdominal neoplasia is rare can be associated with haemoperitoneum (Luethy *et al.* 2016). Most horses with abdominal neoplasia involving the intestinal tract, urogenital tract, liver, kidneys, or spleen have a history of weight loss, anorexia, chronic signs of abdominal pain and/or diarrhoea.

Diagnostics

Examination of a horse with haemoperitoneum should begin with a complete physical examination and abdominal palpation *per rectum*. Physical examination confirms the clinical signs of blood loss anaemia, including tachycardia, tachypnoea, pale mucous membranes, delayed capillary refill time, depression, cool extremities, sweating and signs of abdominal pain. Abnormal clinical pathology abnormalities include anaemia (PCV 20%) and hypoproteinaemia (<6.0 g/dl) and elevations in blood lactate (>4 mm/l). Horses suspected of coagulation abnormalities, such as DIC, should have a coagulation profile performed (Epstein 2014). Abdominal palpation *per rectum* is useful in examination of the reproductive tract, urinary bladder, left kidney, caudal aspect of the spleen and caudal intestinal tract. In some instances haematomas or neoplastic masses are palpable.

Diagnostic ultrasonography is absolutely indicated in all horses with a suspicion of haemoperitoneum. A complete ultrasound examination should include transabdominal and *per rectum* approaches. Transabdominal ultrasonography includes imaging of the peritoneal fluid (e.g. visible fibrin or blood clots, swirling of peritoneal fluid), diaphragm, spleen, liver, intestinal tract and kidneys. Transrectal ultrasonography of the complete female urogenital tract should be performed to identify ovarian abnormalities, the uterus and broad ligaments. Horses with ovarian haematoma will have enlargement of the ovary and contain a haematoma in the centre of the ovary. Horses with uterine artery rupture typically have enlargement or haematoma formation in the broad ligament. Male horses which have been recently castrated and are affected by haemorrhage from the spermatic cord or testicular artery may have haematomas visible on the affected side. Splenic or hepatic masses or capsular disruption post trauma of these organs can also result in haemoperitoneum. This can sometimes be observed with abdominal ultrasonography.

Once the index of suspension has been raised about blood loss anaemia secondary to haemoperitoneum every effort should be made to localise the source of bleeding. This generally cannot be determined without invasive and minimally invasive diagnostic techniques. The most common

invasive technique is abdominocentesis. Abnormal findings associated with abdominocentesis include sanguineous abdominal fluid, elevated RBC (>20,000 RBC/μl) and WBC counts (>2500 cells/μl) and hyperproteinaemia (>2.5 g/dl). Typically, a PCV measurement will reveal a similar percentage to the systemic circulation. Likewise the total protein concentration will approximate the serum total protein concentration. Cytology of the abdominal fluid reveals erythrophagocytosis and evidence of nondegenerate neutrophilic inflammation. The only confounding factor could be iatrogenic penetration of the spleen during abdominocentesis. Frequently abdominocentesis repeated in an additional area of the abdomen away from the spleen will reveal sanguineous peritoneal fluid in the horse affected by haemoperitoneum.

Diagnostic laparoscopy can also be utilised to identify the source of haemorrhage (Klohnen 2012). This is most frequently done in the standing horse. Both the left and right side of the abdomen can be examined with the standing laparoscopy. Laparoscopy can be extremely useful in obtaining direct visualisation of the abdominal viscera. Laparoscopy can be combined with a small abdominal flank incision to facilitate palpation of the viscera (hand assisted laparoscopy) and/or manual positioning of an ultrasonography probe on the area of interest. Laparoscopy can be used to visualise the kidneys, reproductive tract, spleen, liver and abdominal viscera. In some cases, once the source of haemorrhage has been identified, it can be treated with laparoscopic techniques. For example, the author has treated a case of post operative haemorrhage following castration with extracorporeal ligation of the spermatic cord.

Treatment

All horses with blood loss anaemia secondary to haemoperitoneum require immediate stabilisation (Mudge 2014). Treatment of cardiovascular shock is paramount to a successful outcome whether or not surgical or medical management is required to treat the cause of the haemorrhage. The hallmarks of patient stabilisation include intravenous fluid therapy with colloids and crystalloid solutions and whole blood transfusion. All horses with blood loss anaemia should be supported with intravenous (i.v.) fluid therapy. The most difficult decision facing the clinician is the decision whether or not blood transfusion is necessary. Guidelines for blood transfusion for horses have been reported (Mudge 2014). The author uses a combination of clinical signs and haematological data to determine the decision for blood transfusion. Horses with clinical signs of acute blood loss including tachycardia, tachypnoea, depression and anorexia are candidates for blood transfusion. Some clinicians use a PCV 'cut off' to determine whether or not a transfusion is necessary. In general, a PCV of 15% in combination with clinical signs of blood loss anaemia should be treated with a blood transfusion. Once the decision for a blood transfusion has been made, the next consideration is selecting a suitable donor. If at all possible a cross match should be obtained to confirm that the donor and recipient are compatible (Hurcombe *et al.* 2007; Mudge 2014; Tomlinson *et al.* 2015). However, the author has had problems with identifying suitable donors via blood cross matching on multiple occasions in horses. It sometimes takes 8 or more different horses before a cross match has been obtained. Therefore, the author currently performs blood transfusions without cross matching. Preferably a Quarter Horse gelding should be used as a 'universal' blood donor. It has been previously demonstrated that transfused red blood cells from an appropriate cross-matched donor will remain viable longer than an inappropriate cross-matched donor (Tomlinson *et al.* 2015). Clinically, the author has not observed any differences between transfused blood between a cross-matched or noncross-matched donor. To decrease the likelihood for a transfusion reaction the author recommends that dexamethasone (20–40 mg i.v.) be administered prior to the blood transfusion. For the average 450 kg horse 6–8 l of whole blood should be transfused. Typically, only one transfusion is required unless ongoing haemorrhage is occurring.

The use of fibrin stabilising drugs such as Aminocaproic acid have been used by many veterinarians instead of using whole blood transfusions (Heidmann *et al.* 2005; Ross *et al.* 2007; Fletcher *et al.* 2013). Certainly if a whole blood transfusion is not an option, these drugs can be considered, but in the author's experience should not be used instead of whole blood. Whole blood is preferred because it provides red blood cells and fresh coagulation factors which most certainly aminocaproic acid does not provide. There is little scientific evidence that suggest that horses have a problem with fibrin clot stabilisation in association with acute blood loss and therefore the author has not found its use to be necessary.

Following medical stabilisation of the horse with haemoperitoneum, the decision for treatment revolves around identification of the primary cause of haemorrhage. If the source of haemoperitoneum cannot be identified with minimally invasive techniques such as ultrasonography and abdominal palpation *per rectum* the only reasonable alternative to obtain a diagnosis would be abdominal surgical exploration. Surgical correction if possible can result in prompt resolution of haemorrhage and provides the best option for stabilisation of the case. Once a decision for surgery has been made, the surgeon must decide whether or not the procedure can be completed using laparoscopic techniques or requires general anaesthesia and a ventral midline incision. The author makes his decision on laparoscopy vs. traditional surgical techniques solely on whether or not surgical access to the lesion can be achieved. For example, post castration haemorrhage and ovarian abnormalities are easier to access using standing laparoscopy. In contrast intestinal abnormalities associated with haemoperitoneum are best managed with a ventral midline approach under general anaesthesia. Horses which have a problem not amenable to surgical management, are unstable for surgical procedures, or are diagnosed with idiopathic haemoperitoneum will require supportive medical management.

Prognosis

The prognosis for successful treatment of haemoperitoneum is solely dependent on resolution of haemorrhage and treatment of the primary cause (Dechant *et al.* 2006). In 4 studies retrospectively reviewing haemoperitoneum from a variety of causes survival to hospital discharge ranged from 42 to 74% (Pusterla *et al.* 2005; Dechant *et al.* 2006; Conwell *et al.* 2010; Gray *et al.* 2015). Prognosis can be improved with appropriate medical management and judicious use of

Continued on page 410

Case Report

Guttural pouch empyema secondary to a periocular foreign body

D. P. M. Dias*, D. G. Macoris and A. C. Alessi†

Departamento de Clínica e Cirurgia Veterinária, and †Departamento de Patologia Veterinária, Faculdade de Ciências Agrárias e Veterinárias, Jaboticabal, Brazil.
**Corresponding author email: deborah_dias@hotmail.com*

Keywords: horse; empyema; eye orbit; guttural pouch; *Streptococcus*

Summary

This report describes a 3-year-old gelding presenting with signs of injury to its left eye following an accident in which the horse crashed into a hedge. The first treatment attempted to treat infections in the eye and respiratory tract due to secretions identified in the trachea. The horse did not improve and further clinical and radiographic evaluations detected a guttural pouch empyema. Surgical drainage was performed and antimicrobial treatment continued. However, the horse presented with severe epistaxis and euthanasia was elected due to suspected arterial rupture. At necropsy, a round and stiff branch plant was found creating a fistula from the left orbit to the left guttural pouch. Another branch was found inside the pouch, confirming the origin of the persistent infection and severity of the tissue lesion.

Introduction

The guttural pouch (GP) is an air-filled diverticulum of the auditory tube found in some members of the order Perissodactyla, such as horses, tapirs and rhinoceroses (Dyce *et al*. 2010). In horses, the pouches are paired and draped over the stylohyoid bone, forming medial and lateral compartments that occupy a wide area in the caudal portion of the head (Budras *et al*. 2010) extending from the roof of the pharynx to the commencement of the oesophagus ventrally and from the base of the skull and atlanto-occipital joint dorsally (Lepage 1994; Baptiste *et al*. 1996). The intimate contact with several osseous, muscular, vascular, neural and lymphoid structures makes anatomical knowledge essential in understanding the clinical signs associated with GP disease (Hardy and Léveillé 2003; Perkins *et al*. 2003; Lepage *et al*. 2004).

In horses, empyema is the most common disease of the GP (Hardy and Léveillé 2003; Gerard *et al*. 2006), and can be secondary to an upper airway infection or drainage of retropharyngeal abscesses into the ipsilateral pouch (Hardy and Léveillé 2003). The *Streptococcus equi* subspecies *equi* accounts for most primary bacterial infections of the GP (Freeman 1980; Judy *et al*. 1999; Perkins *et al*. 2003; Pusterla *et al*. 2006; Taylor and Wilson 2006), although the *Streptococcus equi* subspecies *zooepidemicus* can also be a contributor (Perkins *et al*. 2003). Clinical signs include anorexia, cough, fever, respiratory noise, retropharyngeal swelling painful on palpation, unilateral or bilateral nasal discharge (it can be bilateral with a unilateral empyema) and occasionally dysphagia due to cranial nerve dysfunction (Hardy and Léveillé 2003; Perkins *et al*. 2003; Gerard *et al*. 2006). Endoscopy usually shows discharge from one of the pharyngeal ostia of the auditory tube and radiographic projections of the skull can differentiate empyema from chondroids and retropharyngeal abscesses (Hardy and Léveillé 2003).

Treatment of GP empyema includes local flushing with antibiotics and acetylcysteine using a blinded or endoscopic-assisted procedure and establishment of drainage. The efficacy of systemically-administered antimicrobials may be decreased by poor drug penetration into the pouch and exudate (Verheyen *et al*. 2000; Perkins *et al*. 2003). However, systemic antibiotics are recommended to treat retropharyngeal lymph node abscesses because pouch discharge can infect the lower airway, especially if the horse is dysphagic (Hardy and Léveillé 2003).

Due to their behaviour as prey, horses are always ready to flee and frequently react nervously. They are more prone to accidents than other domestic animals (Goodwin 1999). It is common for foreign bodies to be introduced into soft tissues as a consequence of crashing. Retained foreign bodies are often difficult to visualise on imaging studies (Pattamapaspong *et al*. 2013) and can cause serious complications, such as life-threatening infections. When the eye is involved, metallic or organic material can penetrate the orbit and settle in the retrobulbar region (Gilger 2011) located close to the dorsal-rostral aspect of the GP (Baptiste 1998; Gilger 2011).

This report describes a case of a young horse diagnosed with GP empyema secondary to invasion of the diverticulum by a plant foreign body through the eye orbit.

Case history

A 3-year-old (465 kg) Brazilian saddle gelding was admitted to the Veterinary Teaching Hospital with the complaint of a left eye injury from 3 days prior. The owners reported that the lesion occurred when the animal fled, galloping and crashing into a dense hedge of *Mimosa caesalpiniaefolia*. An ocular oedema was evident the next day and 3 days after the accident the horse presented with depression, anorexia and respiratory distress. The horse was housed in a stable and had begun training for showjumping, but no travel or environmental changes were reported. Its deworming and vaccination statuses were up-to-date.

Initial examination and treatment

Upon arrival at the hospital, the horse was apathetic, tachycardic (72 beats/min), mildly pyrexic at 38.6°C and tachypnoeic (45 breaths/min). It showed nostril flaring during inspiration and tracheal mucus accumulation was identified by auscultation. Abnormal thoracic sounds were not identified. Mucous membranes were mildly congested and of a light red colour. A toxaemic red line was observed around the teeth and capillary refill time was prolonged (3 s). The left

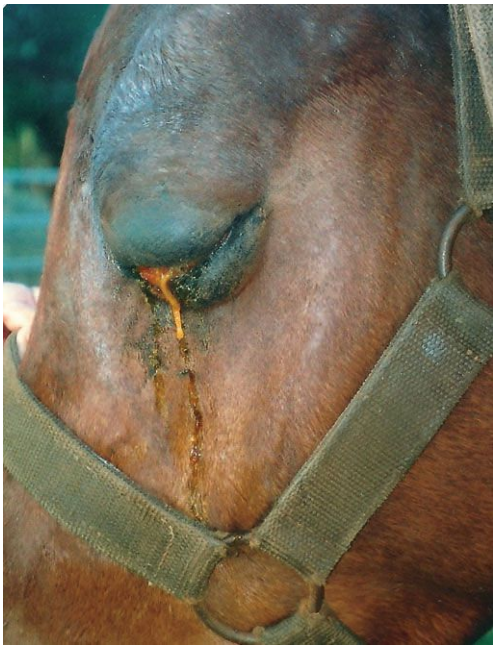

Fig 1: Horse showing ocular oedema and purulent discharge 3 days after a head trauma.

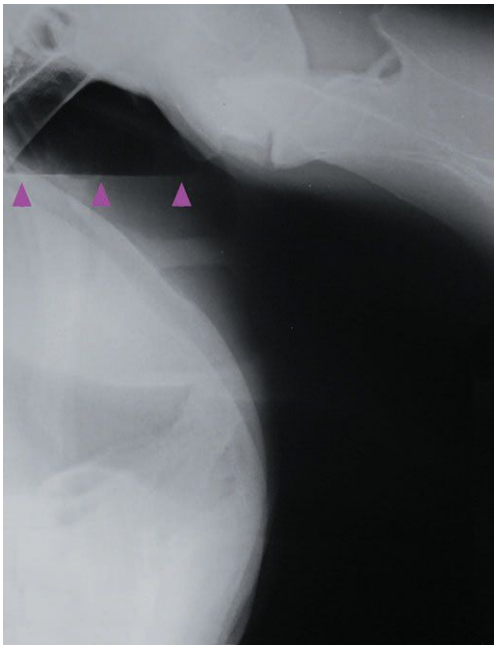

Fig 2: Lateral radiographic projection of the head of a horse with guttural pouch empyema showing a fluid line (arrowheads) within the left pouch.

eye showed purulent discharge with severe oedema closing the eyelids (**Fig 1**), which precluded thorough examination of the eye. A slight distension was observed caudally to the mandibular angle and ultrasonographic evaluation of this region and the ipsilateral jugular vein did not reveal abnormalities. Ultrasonography at the orbital region was also performed and revealed preservation of globe structures, with no evidence of perforation. Radiographic examination of the head showed subcutaneous emphysema around the left orbit and an absence of fractures. Upper airway endoscopy was not performed because the equipment was not available.

The horse received fluid therapy according to the dehydration status determined by means of clinical presentation, packed cell volume and total protein level. Flunixin meglumine (Banamine)[1] (1.1 mg/kg bwt i.m. s.i.d.), enrofloxacin (Flotril 10%)[1] (5 mg/kg bwt i.v. s.i.d.) and a combination of potassium, procaine and benzathine penicillin (30,000 u/kg bwt i.m. q. 48 h) (Pentabiótico Veterinário Reforçado)[2] were administered for 7 days. The eye was cleaned using sterile gauze moistened with a 0.9% sodium chloride solution, followed by the instillation of a 0.3% tobramycin eyewash (Tobrex)[3]. This procedure was repeated every 4 h for 7 days.

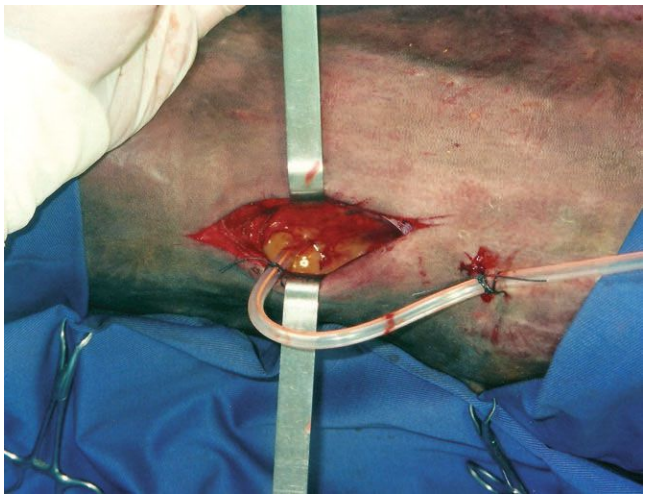

Fig 3: Modified Whitehouse surgical approach to the left guttural pouch of a horse presenting with empyema. A Foley catheter was implanted into the pouch to perform irrigation.

Further examination and case progression

Ten days after initiation of treatment, clinical signs began to deteriorate, the horse started coughing and another radiographic evaluation of the head was recommended. The lateral view revealed a sharply defined fluid line in the left GP (**Fig 2**), suggesting empyema. The GP was surgically assessed under general anaesthesia through a modified Whitehouse approach and 300 ml of mucopurulent material were drained from the pouch. A Foley catheter was introduced into the left GP through the incision and sutured to the skin using nylon (**Fig 3**). Post operatively, the left GP was flushed every 12 h using a 0.05% povidone-iodine solution. Flunixin meglumine and penicillin administration was resumed and treatment with omeprazole (4 mg/kg bwt *per os* s.i.d.) (Gastrozol Pasta)[4] and gentamicin (Gentocin)[1] (6.6 mg/kg bwt i.v. s.i.d.) were initiated. This therapy was performed for 7 days. A bacteriological study of purulent material from the GP identified *Streptococcus equi* strains.

Eight days after surgery the horse presented with severe dysphagia and left facial paralysis, with a loss of facial symmetry and deviation of the nose and superior lip. Its clinical presentation did not improve and 12 days after the surgical procedure the horse presented with severe bilateral epistaxis.

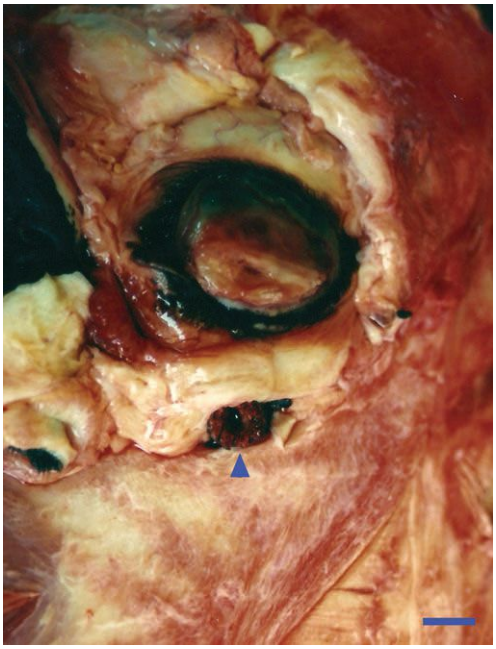

Fig 4: Left lateral view of a horse's head after skin removal showing a plant branch (arrowhead) retained between the globe and the ventral aspect of the orbit. Bar = 1 cm.

Internal carotid rupture was suspected and euthanasia was elected due to the poor prognosis.

Post mortem findings

Gross pathology revealed severe purulent conjunctivitis, severe corneal ulceration and opacity of the left eye. Removal of the skin and palpebral conjunctiva revealed the end of a plant branch retained in the periorbital tissues between the globe and ventral aspect of the orbit (**Fig 4**). The round and stiff branch was 7.5 cm in length and 1–1.3 cm in diameter and created a fistula communicating with the left GP. Another similar foreign body was found in the cranial-dorsal wall of the left GP accompanied by haemorrhagic fibrinopurulent exudate (**Fig 5**). This second plant branch was also round and stiff and was 4 cm long and 0.8 cm in diameter. The foreign bodies were removed from the tissues to be measured (**Fig 6**). Clots were observed around the left internal carotid artery. After removing the clots it was noted that the wall of the artery was injured.

Discussion

Considering the case history and clinical and pathological findings, it is suspected that when the horse crashed into the hedge, one plant branch penetrated the orbit, perforated the GP and broke into 2 fragments. Ocular structures were affected when the branch passed between the globe and zygomatic bone at the orbit contour, before perforating the periorbital tissue and cranial-dorsal wall of the left GP. Despite this severe trauma, the globe was preserved and no orbital fractures were identified. Oedema and ocular purulent discharge levels in the left eyelid were in accordance with the intensity of the trauma and infection. During the clinical examination the plant branch had not been detected, probably because it was below the surface of the conjunctiva.

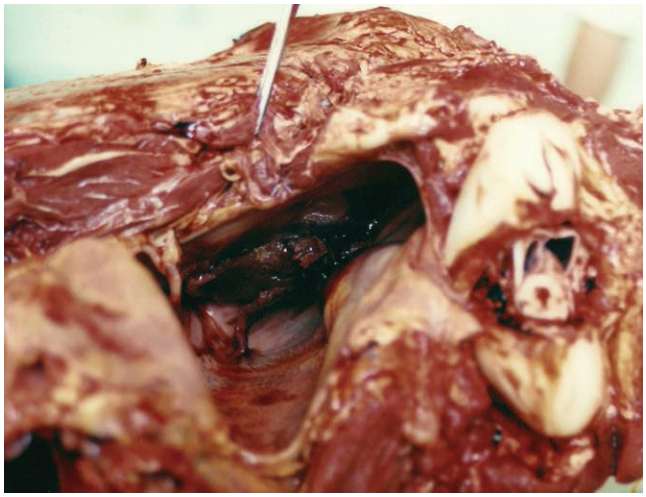

Fig 5: Ventral view of the left guttural pouch of a horse showing plant material, exudate and blood clots located in the dorsal aspect of the diverticulum.

Fig 6: Plant foreign bodies removed from the left ventral periorbital tissue (1) and from the cranial-dorsal wall of the left guttural pouch (2) of a horse presenting with guttural pouch empyema. Bar = 1 cm.

The retropharyngeal swelling observed on admission (3 days after crashing), although slight, is in accordance with GP empyema (Perkins *et al*. 2003), indicating that the horse developed the disease very quickly. However, this disease was disregarded on first examination because radiographic and ultrasonographic evaluations did not show any change and the horse had not presented with mucopurulent nasal discharge even though this is the most common clinical sign of the disease (Perkins *et al*. 2003; Freeman and Hardy 2012). Hawkins *et al*. (2001) reported that nasal discharge may be absent in cases of abnormalities related to the openings of the

pharyngeal orifice secondary to severe GP infections, which may have occurred in this case.

The other findings, such as depression, anorexia, tachycardia, tachypnoea, congested oral mucous membranes, prolonged capillary refill time and pyrexia are commonly associated with respiratory tract infections. The horse also presented with tracheal rattle upon first examination, a common result of excessive mucus accumulation caused by diseases of the lower airways (Pusterla *et al*. 2006). This tracheal abnormality could be associated with aspiration pneumonia, matching the development of the cough and dysphagia observed later. Thus, the first treatment was directed to the eye lesion, respiratory infection and dehydration. In the absence of improvement, the second radiographic evaluation of the head was performed to investigate the orbit. At that time, the left GP empyema was identified, suggesting that the infection developed progressively.

The dysphagia was observed clearly only 21 days after the accident, accompanied by facial nerve paralysis. The glossopharyngeal, vagus and hypoglossal nerves, which innervate muscles used in the swallowing process, are contained in a fold of the mucous membrane along the caudal wall of the GP medial compartment and the facial nerve passes closely to the dorsal aspect of the GP lateral compartment (Carmalt 2002; Borges and Watanabe 2011; Freeman and Hardy 2012). This close anatomic relationship between the guttural pouches and cranial nerves can lead to neurological abnormalities in the presence of GP disease and mycosis is the most common injury associated with disturbances of cranial nerves (Borges and Watanabe 2011). In the present case, although uncommon in cases of empyema (Modransky *et al*. 1982; Hardy and Léveillé 2003), cranial nerves may have been affected by the trauma and infection in the pouch, matching the progressive evolution of dysphagia and facial paralysis. However, dysphagia was evident after the surgical procedure; in addition to the severe trauma that occurred, the possibility of an iatrogenic neurological damage cannot be disregarded, as it is known that GP surgery risks damage to the glossopharyngeal nerve and pharyngeal branch of the vagus nerve (Freeman 2008).

For an accurate diagnosis of any infectious process affecting a horse's GP, the use of radiography in association with endoscopy is strongly recommended (Perkins *et al*. 2003; Gerard *et al*. 2006). In the present case, the foreign bodies were not detected because plant materials cannot usually be viewed using radiography (Pattamapaspong *et al*. 2013) and unfortunately an endoscope was not available. However, even if the foreign bodies had been identified during an endoscopic examination or surgical exploration, due to the severity and extent of the lesions and the deep location of the wood fragments discovered at necropsy, it would hardly be possible to remove them and recover the affected tissues.

A modified Whitehouse approach under general anaesthesia was performed aiming to achieve drainage and to apply a lavage system. For this purpose, it is known that the modified Garm's technique is less invasive and could be performed in standing horses (Muñoz *et al*. 2008). However, this technique requires endoscopic examination during surgery and as previously reported the equipment was not available.

Although instillation of antiseptics can irritate the GP mucosa and should be avoided (Hardy and Léveillé 2003), in the present case the left GP was flushed with a 0.05% povidone-iodine solution due to the severity and persistence of the infection. Regarding the aetiological agent, it is known that commensal normal flora of the upper airway and oral cavity have the potential to become pathogenic and cause disease when the host–organism relationship is disrupted (Long 2004). In the present case, *Streptococcus equi* subspecies was not differentiated but the infection was possibly associated to *Streptococcus equi zooepidemicus*, since this GP empyema was not secondary to strangles. However, we could not exclude the participation of *Streptococcus equi equi* because its predominant location in persistent and asymptomatic carriers is the GP (Newton *et al*. 1997; Fintl *et al*. 2000; Verheyen *et al*. 2000) and this empyema aetiology is particularly unusual. Thus, it is possible that the trauma caused by the foreign bodies broke the normal balance of bacterial flora within the GP, allowing the multiplication of *Streptococcus equi* that became pathogenic and produced an empyema. Wooden foreign bodies are an excellent medium for bacterial growth due to their porous nature and organic characteristics (Lammers 1988).

Another unique aspect of this case is that arterial haemorrhage and epistaxis are not common in cases of GP empyema, considering that the infection may remain chronically. The internal carotid artery runs along the middle portion of the medial compartment of the GP (Borges and Watanabe 2011), from ventral to dorsal and erosion of the thin guttural pouch membrane and underlying internal carotid arterial wall, leading to haemorrhage, is a cause of rapid fatality described in cases of GP mycosis (Baptiste *et al*. 1996; Lepage *et al*. 2004; Gerard *et al*. 2006). In the present case, epistaxis was copious and occurred only 26 days after trauma (14 days after surgery) and the site of internal carotid rupture was distant from the foreign body, as observed during necropsy. Therefore, possibly the infection and severe inflammation and not trauma or surgical procedure caused haemorrhage, highlighting the importance of preventative methods such as balloon-tipped catheterisation (Freeman and Donawick 1980a,b) and internal carotid artery embolisation (Matsuda *et al*. 1999; Léveillé *et al*. 2000; Benredouane and Lepage 2012) in cases of GP foreign bodies leading to empyema.

The original aetiology of this case was only identified after pathological examination, showing that foreign bodies should be considered in cases of persistent and severe GP infection. Furthermore, the periorbital location is a possible route for foreign bodies to penetrate the GP. There is no other report of such a case to the knowledge of the authors.

Authors' declaration of interests

No conflicts of interest have been declared.

Manufacturers' addresses

[1]Schering-Plough Veterinária, Rio de Janeiro, Brazil.

[2]Fort Dodge, Campinas, Brazil.

[3]Alcon, São Paulo, Brazil.

[4]Marcolab, Duque de Caxias, Brazil.

References

Baptiste, K.E. (1998) A preliminary study on the role of the equine guttural pouches in selective brain cooling. *Vet. J.* **155**, 139-148.

Baptiste, K.E., Holladay, S.D. and Freeman, L.E. (1996) Alterations in equine guttural pouch morphology with head position: observations using a new technique for producing accurate casts. *Anat. Rec.* **246**, 579-584.


PREMIUM PERFORMANCE DEMANDS PREMIUM FORAGE
World-Renowned Horseman
Clinton Anderson
NUTRITION THAT GIVES YOU THE WINNING EDGE
Standlee
PREMIUM WESTERN FORAGE
www.standleeforage.com
TIMOTHY GRASS
PELLETS
ALFALFA
CUBES
BEET PULP
SHREDS
ALFALFA TIMOTHY
CHOPPED
LARGE FLAKE
SHAVINGS
Proud sponsor of:
USEA
USDF
USHJA
DOWN UNDER HORSEMANSHIP
BETTER BARREL RACER

He's more than just a horse. To your clients, he's Family.

#1 Veterinarian Recommended Brand

Give him the best

COSEQUIN®

Joint Health Supplements

COSEQUIN® ASU PLUS

THE MOST ADVANCED COSEQUIN FORMULA!

Contains proprietary, trademarked ingredients NOT available in other brands.

Active Ingredients:

- FCHG49® Glucosamine (GLU)
- TRH122® Chondroitin Sulfate (CS)
- NMX1000® Avocado/Soybean Unsaponifiables (ASU)
- Green Tea Extract (EGCG)
- Hyaluronic Acid (HA)
- Methylsulfonylmethane (MSM)

HOW COSEQUIN WORKS

HA/ASU/GLU/CS[1] and ASU/EGCG[2]

- Reduce COX-2 activity
- Reduce PGE_2 production
- Inhibit NF-κB nuclear translocation

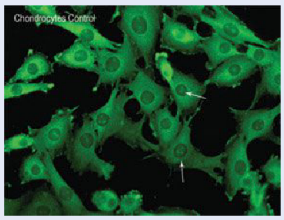

Unactivated equine chondrocytes with immunofluorescent staining for NF-κB, which is shown to be predominantly in the cytoplasm of cells.

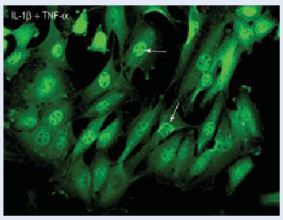

IL-1β and TNF-α activated equine chondrocytes with immunofluorescent staining showing the nuclear translocation of NF-κB.

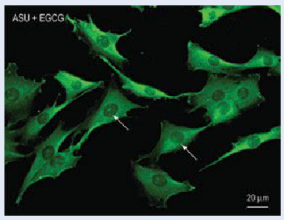

IL-1β and TNF-α activated equine chondrocytes pre-treated with NMX1000® ASU+EGCG with immunofluorescent staining showing the inhibition of NF-κB nuclear translocation.[2]

010.1258.00

nutramax® LABORATORIES VETERINARY SCIENCES, INC.
946 Quality Drive • Lancaster, SC 29720
nutramaxlabs.com • 1-888-886-6442

▼Source: Survey conducted in February 2016 of equine veterinarians who recommended oral joint health supplements.

1. Heinecke LF, Grzanna MW, Au AY, et al. Inhibition of prostaglandin E2 production by the combination of hyaluronan, avocado/soybean unsaponifiables, glucosamine, and chondroitin sulfate involves a NF-κB dependent mechanism. *ORS* 2011.

2. Heinecke LF, Grzanna MW, Au AY, et al. Inhibition of cyclooxygenase-2 expression and prostaglandin E2 production in chondrocytes by avocado soybean unsaponifiables and epigallocatechin gallate. *Osteoarthritis and Cartilage* 2010;18:220–227.

Benredouane, K. and Lepage, O. (2012) Trans-arterial coil embolization of the internal carotid artery in standing horses. *Vet. Surg.* **41**, 404-409.

Borges, A.S. and Watanabe, M.J. (2011) Guttural pouch diseases causing neurologic dysfunction in the horse. *Vet. Clin. N. Am.: Equine Pract.***27**, 545-572.

Budras, K.D., Sack, W.O. and Röck, S. (2010) Head. In: *Anatomy of the Horse*, 5th edn., Eds: K.D. Budras, W.O. Sack and S. Röck, Schluetersche, Hannover. pp 32-51.

Carmalt, J. (2002) Guttural pouch diseases in the horse. *Large Anim. Vet. Rounds* **2**, 1-6.

Dyce, K.M., Sack, W.O. and Wensing, C.J.G. (2010) The head and ventral neck of the horse. In: *Textbook of Veterinary Anatomy*, 4th edn., Eds: K.M. Dyce, W.O. Sack and C.J.G. Wensing, Elsevier, St Louis. pp 501-532.

Fintl, C., Dixon, P.M., Brazil, T.J., Pirie, R.S. and McGorum, B.C. (2000) Endoscopic and bacteriological findings in a chronic outbreak of strangles. *Vet. Rec.* **147**, 480-484.

Freeman, D.E. (1980) Diagnosis and treatment of diseases of the guttural pouch (Part 1). *Comp. Cont. Educ. Pract. Vet., Suppl.* **2**, S3-S11.

Freeman, D.E. (2008) Complications of surgery for diseases of the guttural pouch. *Vet. Clin. N. Am.: Equine Pract.* **24**, 485-497.

Freeman, D.E. and Donawick, W.J. (1980a) Occlusion of internal carotid artery in the horse by means of a balloon-tipped catheter: evaluation of a method designed to prevent epistaxis caused by guttural pouch mycosis. *J. Am. Vet. Med. Ass.* **176**, 232-235.

Freeman, D.E. and Donawick, W.J. (1980b) Occlusion of internal carotid artery in the horse by means of a balloon-tipped catheter: clinical use of a method to prevent epistaxis caused by guttural pouch mycosis. *J. Am. Vet. Med. Ass.* **176**, 236-240.

Freeman, D.E. and Hardy, J. (2012) Guttural pouch. In: *Equine Surgery*, 4th edn., Eds: J.A. Auer and J.A. Stick, Elsevier, St Louis. pp 623-642.

Gerard, M.P., Wotman, K.L. and Komáromy, A.M. (2006) Infections of the head and ocular structures in the horse. *Vet. Clin. N. Am.: Equine Pract.* **22**, 591-631.

Gilger, B.C. (2011) Diseases and surgery of the globe and orbit. In: *Equine Ophthalmology*, 2nd edn., Ed: B.C. Gilger, Elsevier, Maryland Heights. pp 93-132.

Goodwin, D. (1999) The importance of ethology in understanding the behaviour of the horse. *Equine Vet. J.* **31**, *Suppl.* **28**, 15-19.

Hardy, J. and Léveillé, R. (2003) Diseases of the guttural pouches. *Vet. Clin. N. Am.: Equine Pract.* **19**, 123-158.

Hawkins, J.F., Frank, N., Sojka, J.E. and Levy, M. (2001) Fistulation of the auditory tube diverticulum (guttural pouch) with a neodymium:yttrium-aluminum-garnet laser for treatment of chronic empyema in two horses. *J. Am. Vet. Med. Ass.* **218**, 405-407.

Judy, C.E., Chaffin, M.K. and Cohen, N.D. (1999) Empyema of the guttural pouch (auditory tube diverticulum) in horses: 91 cases (1977-1997). *J. Am. Vet. Med. Ass.* **215**, 1666-1670.

Lammers, R.L. (1988) Soft tissue foreign bodies. *Ann. Emerg. Med.* **17**, 1336-1347.

Lepage, O.M. (1994) Hemorragie dans les poches gutturales. Anatomie, diagnostic et étiologie. *Prat. Vet. Equine* **26**, 255-261.

Lepage, O.M., Perron, M.F. and Cadoré, J.L. (2004) The mystery of fungal infection in the guttural pouches. *Vet. J.* **168**, 60-64.

Léveillé, R., Hardy, J., Robertson, J.T., Willis, A.M., Beard, W.L., Weisbrode, S.E. and Lepage, O.M. (2000) Transarterial coil embolization of the internal and external carotid and maxillary arteries for prevention of hemorrhage from guttural pouch mycosis in horses. *Vet. Surg.* **29**, 389-397.

Long, M.T. (2004) Mechanisms of establishment and spread of bacterial and fungal infections. In: *Equine Internal Medicine*, 2nd edn., Eds: S.M. Reed, W.M. Bayly and D.C. Sellon, WB Saunders, Philadelphia. pp 59-74.

Matsuda, Y., Nakanishi, Y. and Mizuno, Y. (1999) Occlusion of the internal carotid artery by means of microcoils for preventing epistaxis caused by guttural pouch mycosis in horses. *J. Vet. Med. Sci.* **61**, 221-225.

Modransky, P.D., Reed, S.M. and Barbee, D.D. (1982) Dysphagia associated with guttural pouch empyema and dorsal displacement of the soft palate. *Equine Pract.* **4**, 34-38.

Muñoz, J.A., Stephen, J., Baptiste, K.E. and Lepage, O.M. (2008) A surgical approach to the lateral compartment of the equine guttural pouch in the standing horse: modification of the forgotten 'Garm technique'. *Vet. J.* **177**, 260-265.

Newton, J.R., Wood, J.L.N., Dunn, K.A., DeBrauwere, M.N. and Chanter, N. (1997) Naturally occurring persistent and asymptomatic infection of the guttural pouches of horses with *Streptococcus equi*. *Vet. Rec.* **140**, 84-90.

Pattamapaspong, N., Srisuwan, T., Sivasomboon, C., Nasuto, M., Suwannahoy, P., Settakorn, J., Kraisarin, J. and Guglielmi, G. (2013) Accuracy of radiography, computed tomography and magnetic resonance imaging in diagnosing foreign bodies in the foot. *Radiol. Med.* **118**, 303-310.

Perkins, G.A., Pease, A., Crotty, E. and Fubini, S.L. (2003) Diagnosing guttural pouch disorders and managing guttural pouch empyema in adult horses. *Comp. Cont. Educ. Pract. Vet.* **25**, 966-973.

Pusterla, N., Watson, J.L. and Wilson, W.D. (2006) Diagnostic approach to infectious respiratory disorders. *Equine Pract.* **5**, 174-186.

Taylor, S.D. and Wilson, W.D. (2006) *Streptococcus equi* subsp. *equi* (strangles) infection. *Equine Pract.* **5**, 211-217.

Verheyen, K., Newton, J.R., Talbot, N.C., Brauwere, M.N. and Chanter, N. (2000) Elimination of guttural pouch infection and inflammation in asymptomatic carriers of *Streptococcus equi*. *Equine Vet. J.* **32**, 527-532.

Clinical Commentary

Challenges associated with the diagnosis and management of guttural pouch epistaxis in equids

O. M. Lepage

Veterinary Campus of Lyon, Equine Department, VetAgro Sup, Université de Lyon, Marcy l'Etoile, France. Corresponding author email: olivier.lepage@vetagro-sup.fr

Keywords: horse; foreign body; guttural pouch; epistaxis

Guttural pouch diseases are considered to be relatively rare, but they are recognised in most regions of the world (Archer *et al.* 2012) and it is not unusual for large equine practices to see at least a dozen cases a year. In addition, with the generalised availability of endoscopes, examination of the guttural pouches is becoming a routine clinical procedure that helps to increase the recognition of various diseases (Baptiste 2004; Deluzurieux *et al.* 2013).

In horses, the guttural pouches have the same bacterial flora as the pharynx, and function as brain-cooling devices for blood destined to the brain (Baptiste *et al.* 2000). Due to the complicated anatomy of the guttural pouch, it is associated with numerous diseases (empyema, mycosis, tympany, *longus capitus* muscle rupture, stylohyoid bone fracture, foreign bodies, otitis, neoplasia, aneurysm, pharyngeal paralysis, dorsal displacement of the soft palate etc.) and a broad spectrum of clinical signs, in combination or alone (Muñoz Moran and Lepage 2014), from epistaxis to cranial nerve disorders. Each pouch is in close proximity to the pharynx, oesophagus, retropharyngeal lymph nodes, atlanto-occipital joint, middle ear, tympanic bulla and auditory meatus to list the most important structures, in addition to multiple nerves, veins and arteries. It is essential for the practitioner, before trying to understand the pathogenesis of the various diseases and to start treating them, to appreciate the global anatomy and be able to recognise the structures when accessing the pouches endoscopically. During endoscopic examination of the lateral compartment, in addition to the well described arteries (external carotid, maxillary, superficial temporal, caudal auricular arteries), maxillary vein, nerves (VII, carotid plexus) and the internal muscles, the parotid gland and auricular cartilage are also readily identified and sometimes the mandibular and chorda tympani nerves (Piat *et al.* 2014). In the medial compartment, endoscopy allows easy visualisation of arteries (external [ECA] and internal [ICA] carotid, and linguofacial arteries), nerves (IX, pharyngeal branch of the X, XII), atlanto-occipital and temporohyoid joints, the median septum, the jugular process of the occipital bone, retropharyngeal lymph nodes; other nerves can also be occasionally observed (X, laryngeal branch of the X, XI) (Piat *et al.* 2014).

Dias and co-authors describe the case of a 3-year-old gelding presenting with signs of eye injury following an accident (Dias *et al.* 2016). Twenty-six days after the trauma, and 22 days after various medical and surgical treatments for eye infection and empyema of the guttural pouch, the horse developed severe bilateral epistaxis and was finally subjected to euthanasia. Necropsy revealed the presence of a foreign body (stiff plant branch) and an empyema probably at the origin of wall erosion of the left ICA. If the authors had an endoscope, they would have certainly seen the foreign body in the guttural pouch and detected a breach of the ICA before it was too late.

Foreign bodies in the guttural pouch occur much less frequently than primary empyema or mycosis, but they are not uncommon and they need to be kept in mind when establishing a list of causes for empyema, neurological disorders and/or epistaxis from that region. These foreign bodies can penetrate into the retropharyngeal tissues and the guttural pouch damaging numerous neurovascular structures, inducing secondary clinical signs such as dyspnoea, dysphagia and pain in the upper neck (Rush 2004). Deep penetration of a segment of fence wire that migrated from the guttural pouch to the cervical spine, damaging the neurovascular structures and inducing an empyema and neurological deficits has also been described (Lepage 2007). In the 2 cases described of metallic foreign bodies (Bayly and Robertson 1982; Lepage 2007) endoscopy of the guttural pouch could only detect a small circular area of submucosal haemorrhage on the wall of the medial compartment and not the foreign body, which was only diagnosed by radiographic examination.

What is of interest in the case report of Dias *et al.* (2016) is the need for euthanasia subsequent to severe epistaxis after nearly a month of treatment. A similar profuse epistaxis after a 3-week period of depression and anorexia was recorded in a 14-month-old Thoroughbred (Bayly and Robertson 1982). A linear metal foreign body, diagnosed by radiography, was the origin of the bloody discharge originating from the left guttural pouch. Because the risks of a fatal outcome as a result of epistaxis originating from the guttural pouches are common, when considering the total number of horses presented with a disease of these structures, this knowledge should dominate all decisions about management.

Diagnosis of guttural pouch epistaxis

Diagnosis of epistaxis is mainly determined by clinical and endoscopic examination. Sometimes other diagnostic imaging techniques are required, such as echography, to help assess the caudal part of the major arteries located in the guttural pouches, and radiography, to help identification of radiopaque foreign bodies (Bayly and Robertson 1982); projections in 2 planes are ideally required for an accurate location of the object (Rush 2004).

Moderate to severe haemorrhage unassociated with exercise is by far the most common clinical presentation of epistaxis from the guttural pouch. The origin is usually a mycotic and/or bacterial agent, and the history often shows

that horses have several episodes of light to moderate haemorrhage prior to a potential fatal bleed. It is therefore very important to ask the owner, or the guardian of the animal, which nostril was originally stained with fresh or dry blood when the problem was first recognised. It helps later in the organisation of the endoscopy procedure and deciding which guttural pouch is at higher risk of being the problem. Indeed, very often at presentation, 2 clinical situations can be observed: either major active bleeding coming out from one or both nostrils or no blood at all neither on the nostrils or in the pharynx. These are 2 situations that prevent the clinician from obtaining information on the affected side. In the present case report (Dias *et al.* 2016), the foreign body in the guttural pouch was not detected because plant material usually cannot be identified by radiography (Pattamapaspong *et al.* 2013) and no endoscope was available. Endoscopy is a prerequisite instrument when dealing with guttural pouch disease and epistaxis.

The aetiology of epistaxis originating from the guttural pouch should include bacterial and/or mycotic infection, aneurysm, foreign bodies (Dias *et al.* 2016), fracture of the stylohyoid bone and rupture of the *longus capitus* muscle (Nation 1978). This last clinical presentation is usually associated with a history of acute trauma, and on endoscopic examination, a haematoma is observed at the muscle insertion site at the base of the skull.

Diagnosis of guttural pouch bacterial and/or mycotic infection is based on history, clinical signs and endoscopy of the pharynx and the guttural pouches. It affects horses of all ages (Nation 1978; Lepage *et al.* 2004; Ludwig *et al.* 2005), ponies (Lepage and Piccot-Crezollet 2005; Delfs *et al.* 2009) and donkeys (**Fig 1**). The 3 most common signs of the disease, in combination or alone, are uni- or bilateral mucopurulent nasal discharge, neurological disorders (e.g. dysphagia, Horner's syndrome, laryngeal hemiplegia and atrophy of the tongue) and epistaxis not induced by exercise (Cook 1968). A retrospective study, performed as part of an equine internship seminar (Marine Truffet 2015, VetAgro Sup, University of Lyon), and based on 46 equids affected by guttural pouch mycosis followed for a minimum of 6 months at the author's referral centre and treated only surgically with the transarterial coil embolisation (TACE) without specific antifungal treatment was undertaken in an attempt to elucidate the aetiopathogeny of guttural pouch mycosis and to find preventive methods in its development. The results were based on clinical records and on owner telephone interview. No common parameters could be identified for age, sex, breed, time of onset (the season), presence of concomitant disease or medical history. Affected horses were kept either stabled, or grazing on pasture or both, and they had different feeding regimens. The type of stabling and feeding in the months before the onset of clinical signs were not predisposing factors as has been suggested previously (Edwards and Greet 2007). Results of this study are in agreement with others (Lepage and Piccot-Crezollet 2005; Archer *et al.* 2012).

The original hypothesis of epistaxis from a guttural pouch affected by mycosis was the presence of an underlying aneurysm (Colles and Cook 1983). An aneurysm is indeed observed in some cases, but it is not common (Lepage and Piccot-Crezollet 2005). However, such an aneurysm is a unique source of haemorrhage and should be included in the differential diagnosis of guttural pouch epistaxis. In these cases, the bleeding site can be diagnosed by endoscopy only if the animal is not actively bleeding, if the ICA or ECA wall is abnormal and the rupture site is above the clot or the accumulation of blood located on the guttural pouch floor (**Fig 2**). Intraoperative diagnosis under fluoroscopic guidance is straight forward if endoscopic evaluation of the aneurysm is not possible (**Fig 3**).

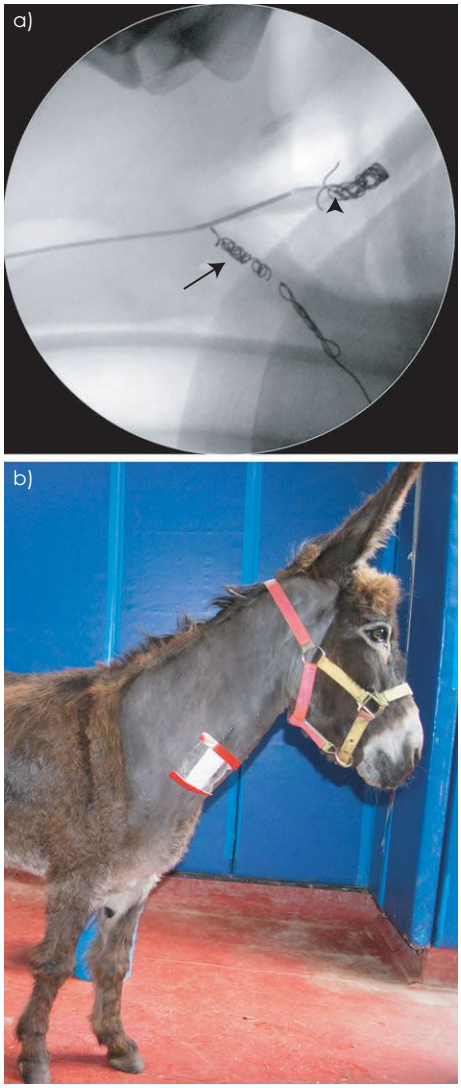

Fig 1: a) A 10-year-old female donkey with guttural pouch mycosis presented with epistaxis 7 days after a first standing transarterial coil embolisation technique procedure of the external carotid artery was performed to treat a unilateral right sided epistaxis. A second transarterial coil embolisation technique procedure under general anaesthesia showed misrecognition of local vascular anatomy during the first surgery. The linguofacial trunk was occluded (arrow) instead of the rostral external carotid artery (arrowhead) and the caudal maxillary artery. Complete resolution of epistaxis and mycosis occurred after the second surgery; b) note that the common carotid artery approach for the second attempt was performed distal to the first surgery to reduce the risk of iatrogenic trauma to the vagosympathic trunk.

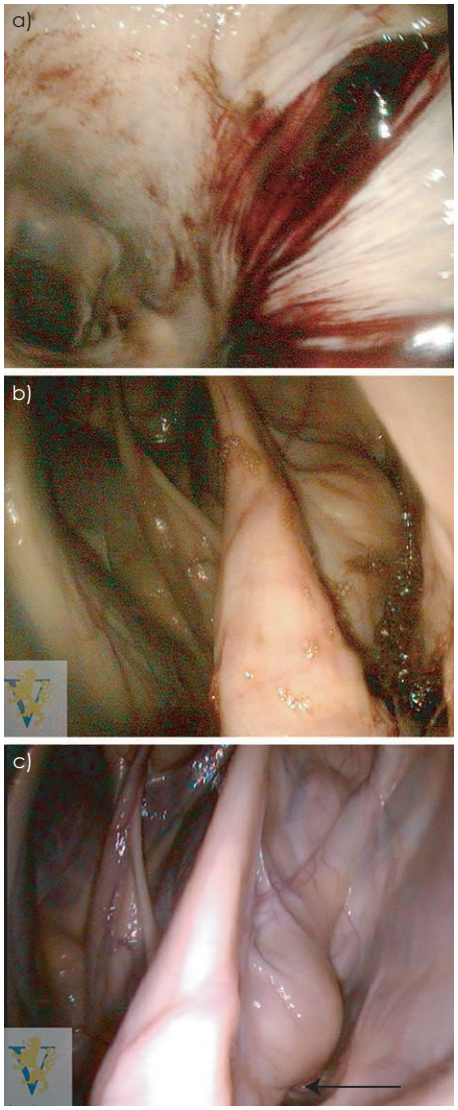

Fig 2: Endoscopic assessment of a 17-year-old gelding. a) At admission, old blood originating from the left guttural pouch pharyngeal ostium precluded further endoscopic investigation; b) Two days after left external carotid artery transarterial coil embolisation technique and packing of a bleeding aneurysm, no signs of bacterial or fungal infection can be observed. c) Four days after the surgical procedure, no more blood is present in the pouch and it allows assessment of the aneurysm rupture site (arrow).

Therapeutic options to control guttural pouch epistaxis

Once a diagnosis of epistaxis originating from a guttural pouch is confirmed, and differential diagnosis has excluded fracture of the stylohyoid bone and rupture of the *longus capitus* muscle, surgical treatment should be initiated immediately because, if left untreated, the risk of fatal haemorrhage is always high. Surgical vascular occlusion for prevention of haemorrhage is the recommended procedure (Freeman and Donawick 1980), latex balloon occlusion (Cheramie *et al.* 2000) and mainly TACE technique becoming, since the beginning of the century

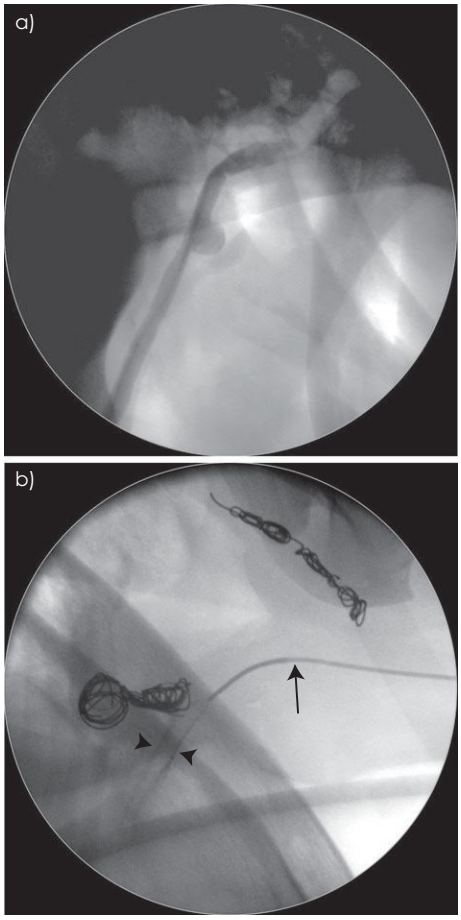

Fig 3: a) Arteriogram of an aneurysm of the internal carotid artery of a horse presenting with epistaxis and mycosis. The bleeding site in this case was located further rostral on the sigmoid flexure and the aneurysm was not involved in the bleeding process. b) Packing and occlusion of the 2 cm diameter aneurysm, from Figure 2b,c, on the external carotid artery located between the linguofacial trunk caudally and the caudal auricular artery rostrally. Contrast injection through a 5Fr-angiographic catheter (arrow) shows occlusion of the ECA and permeability of the lingofacial artery (arrowheads).

(Léveillé *et al.* 1999), the best treatment option. Ideally, the occlusion should be performed on the cardiac (caudal; **Fig 4b**) and cerebral (rostral; **Fig 4a**) sides of the lesion to prevent back bleeding. Coils are mechanical permanent blocking agents and their size should be carefully selected before advancing them through the angiographic catheter. A coil packing technique is performed to fill the lumen of any aneurysm (**Fig 3b**). Attempts to modify or adapt the technique are constantly proposed, especially if a fluoroscope is not available (Muñoz *et al.* 2015). The recent work of Truffet confirms previous studies (Lepage and Piccot-Crezollet 2005) of the high success rate with the TACE procedure, to prevent or treat active guttural pouch epistaxis in horses, without any additional treatment. Only one individual in that study needed a second TACE procedure, in the contralateral side, because a new episode of epistaxis was observed after the first TACE attempt. Secondary regression of fungal lesions were observed in all cases after a variable period of time.

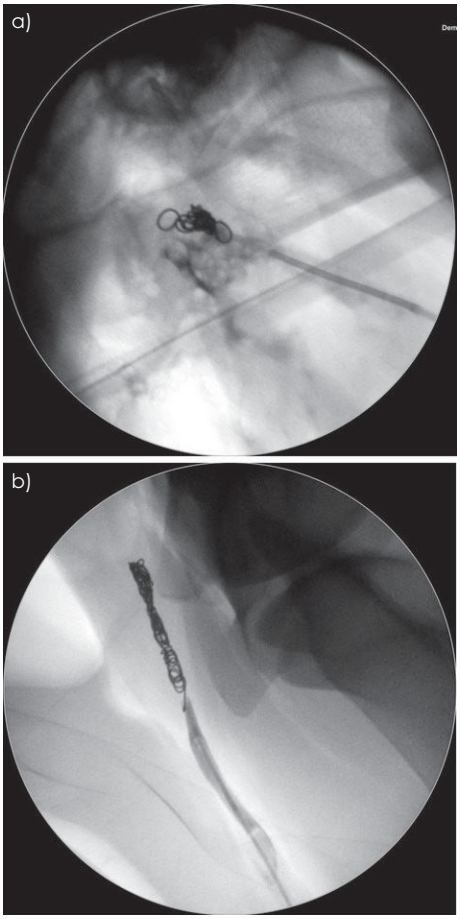

Fig 4: a) Angiogram showing complete occlusion rostral to an active bleeding lesion on the internal carotid artery; b) occlusion caudal to the lesion. Note that the contrast liquid is refluxing into the common and external carotid arteries. To avoid placing a coil in a necrotic segment of the guttural pouch wall, the coil is placed as caudally as possible in the internal carotid artery.

The TACE technique needs a minimum of one skilled surgeon who knows the technique and 2 assistants. The team divide the work so that one person manipulates the angiographic catheter, one manipulates the Newton coil delivery guide and the third one stays nonsterile to control the fluoroscope and all the specific materials needed during surgery. The surgeon needs to be familiar with the angiographic anatomy of the region. For the ICA, variations are categorised into 4 groups (Khairuddin *et al.* 2015): ICA and occipital artery arising as a common trunk; an aberrant branch of the extracranial ICA connected to the basilar artery; ICA aberrant branch ramifying into the surrounding tissue; and ICA aberrant branch giving rise to several smaller branches including connections to the ipsilateral occipital artery.

Occlusion of the affected arteries with detachable, self-sealing latex balloons has also been described (Cheramie *et al.* 2000) and another recent alternative to transarterial coils are transarterial nitinol intravascular plugs (Delfs *et al.* 2009). For a similar cost, this technique has the advantage in requiring only one plug on each site of the lesion, instead of multiple embolisation coils needed to occlude the arterial lumen effectively. A disadvantage is a reduced size availability of the plugs compared to the coils, which might be a limitation when the referral centre can potentially work with a variety of patients from a foal or a donkey to a large draught horse. Coil technology is also continuously under development and the Retracta[1] detachable embolisation coil now provides a safer delivery system for correct positioning, reducing at the same time the number of coils needed to complete occlusion. They can be used in combination with standard coils to reduce the price of surgery.

The TACE procedure is also feasible in the standing horse (Benredouane and Lepage 2012) and a more minimally invasive approach, with ultrasound guidance, to percutaneously access, via a skin stab incision, the common carotid artery for coil placement in the ICA has also been described in anaesthetised or standing horses (Maninchedda *et al.* 2015). At the end of the procedure, the angiographic catheter and the introducer sheath are removed together and manual pressure is applied to the insertion site. After stapling the stab incision, a neck bandage with a wad of compresses is applied for 24 h to exert local pressure. This technique avoids suture of the common carotid arteriotomy site and any surgical incision closure at the exception of the stab incision.

Increase success rate and reducing complications

Diagnostic tools and therapeutic approaches in regard to epistaxis from the guttural pouch need to be continuously adjusted with new technology and clinical information, in order to increase the success rate and minimise complications. Although the TACE procedure is effective in equids for the occlusion of arterial lesions in the guttural pouch and immediately controls the haemorrhage, accurate diagnosis and good preparation for surgery are still needed to increase the success rate.

It is recommended, before performing the endoscopy, to prepare the surgical facilities and alert the full clinical team, as a clot may become dislodged during endoscopic inspection of the guttural pouch, precipitating a potentially fatal haemorrhage. Endoscopy starts with pharyngeal, soft palate and arytenoid functional assessment (Lepage *et al.* 2004). If active bleeding or a clot originating from the pharyngeal ostium is not observed, both pouches should be assessed, with the one suspected to be normal examined first, in order to avoid a potential contamination through the endoscope. Attention to any abnormal communication between both pouches or with the pharynx should be noted. In cases that present with epistaxis, or unilateral clotted blood at the pharyngeal ostium of the pouch, the surgeon should commence surgery by assessing the rupture site, the presence of aneurysm, or any other abnormalities using multiple bolus injection of 2–5 ml contrast liquid under fluoroscopic examination.

Therapeutic complications from TACE are divided into minor and major categories. Minor complications have no long-term (more than 2 weeks) clinical sequelae. Haematoma at the carotid puncture site, reported in one study of percutaneous ultrasound-guided TACE (Maninchedda *et al.* 2015), belongs to this group. The rate for this complication is much higher than a similar approach in

man (Taha *et al.* 2007; Sulzbach-Hoke *et al.* 2010) and is probably explained by the thicker arterial wall and depth of the common carotid artery in horses. The chronicity, type and shape of the lesion may induce some scar tissue and/or neovascularisation, which, combined with a clot or alone, preclude the advancement of the angiographic catheter rostral to the lesion (Léveillé *et al.* 2000; Lepage and Piccot-Crezollet 2005) (**Fig 5a**). These anatomical variations should not be confused with an arterial spasm sometimes induced by the passage of the angiographic catheter and/or injection of contrast material (**Fig 5b**). In rare cases where it is not possible to occlude rostral to the location of the lesion, good occlusion at the site of the lesion and caudally are usually enough to reduce the blood flow and induce correct thrombosis.

Major complications during guttural pouch vascular surgery can be fatal or be responsible for permanent disorders. These complications are mainly related to the absence of appropriate materials and poor technique, including the case selection process and the site to be operated on. Before using TACE on cases, the surgeon needs to have a good understanding and appreciation of the vascular anatomy, variations and malformations. Fluoroscopic equipment is essential at this stage because a selective angiogram, to study the vascular lesion, is mandatory before embolisation. The angiogram excludes anatomical anomalies and estimates the size of the embolisation material. The angiographic catheter must then be placed as selectively as possible and secured during embolisation to prevent migration. Recurrence of epistaxis due to vascular anatomical misunderstanding has been observed in equids (**Fig 1a**), as well as improper size selection of the coils (**Fig 6**). The correct coil size is obtained by measuring the intraluminal arterial diameter, expressed in mm (data measured by the fluoroscope), and adding 20% of that measurement. The selected coil should roll up within the artery and wedge against the wall. If a deployed coil is too small compared with the intraluminal artery size it will migrate and embolise distally from the intended release position. Conversely, if the coil is too big, it will be prevented from assuming its configuration and the ends of the coil can protrude into undesired positions. Abnormal positioning of coils can potentially have disastrous neurological or vascular effects.

The standing TACE procedure (Benredouane and Lepage 2012) is a minimally invasive and effective method for maxillary, ICA and ECA occlusion that should be reserved for surgeons experienced with the technique performed under general anaesthesia and to clinical cases with major neurological symptoms such as ataxia or patients with very high risk parameters for general anaesthesia. We report here the complication of 2 horses that collapsed suddenly in our clinic during intracarotidian manipulation of the angiographic catheter, one in combination with the injection of meglumine ioxitalmate contrast medium. In both cases, and immediately afterwards, the fallen horses stood up safely after their loss of balance. The TACE procedure was continued directly under general anaesthesia without any further problems. If these temporary collapses do not seem to be related to the contrast product then they might be linked to transitory cerebral reduced blood flow or ischaemia induced by a spasm of the arteries (**Fig 5b**). In man, such transient ischaemic attacks (TIAs) (Ferro *et al.* 1996) and drop attack (Bisdorff *et al.* 2009) are well documented. Often called mini-

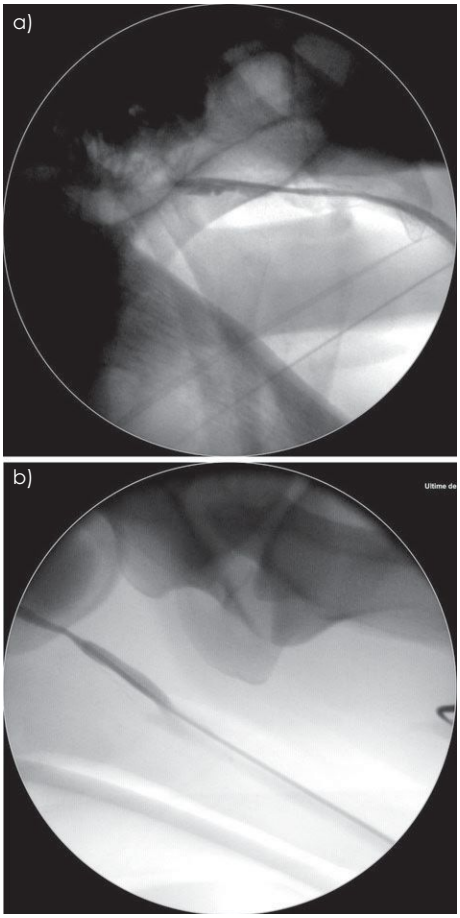

Fig 5: a) Angiogram showing a few cm of abnormal internal carotid artery relative to the basihyoid bone which precludes the rostral advancement of the angiographic catheter to place coils; b) vasospasm of the internal carotid artery. In this case it is recommended to place a coil fitting to the largest diameter observed, keeping a standard 20% increase size.

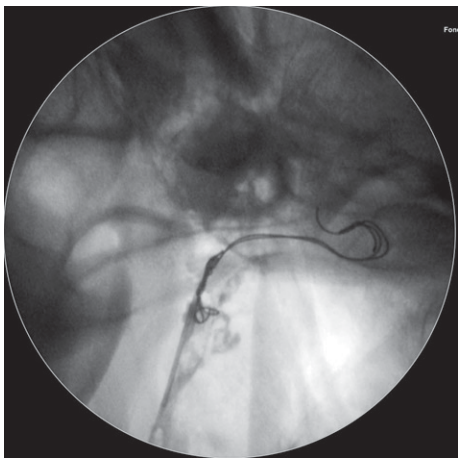

Fig 6: Wrong selected coil size. A coil too large for the luminal size of the target internal carotid artery rostral to an active bleeding site was chosen. This prevents the coil from assuming its configuration and leaves the coil unravelled, which protrudes the end into an undesired position in the sigmoid flexure.

strokes, these TIAs cause no permanent damage. Unlike a stroke, the symptoms of a TIA can resolve within a few minutes to 24 h. In horses, it is also not rare to be confronted by clinical cases presenting anatomic variations (Khairuddin *et al.* 2015), either congenital or induced by the disease process (luminal narrowing of the artery, major rupture, scar tissue). These changes make the surgical approach more complex and require a perfectly still horse, which is not always possible when performing a standing TACE procedure. General anaesthesia under such circumstances is the best option for the comfort of both the surgeon and the horse.

Can epistaxis prevention evolve further?

The imagination and intelligence of man will always be a source of development. Each change needs to be scrutinised by scientific study, and can only improve with experience and increased incidence. To avoid a fatal haemorrhage we must further improve the accuracy of early diagnosis, establish or continue the development of surgical instruments and target, in some cases, effective treatments to treat the cause.

Where diagnostic developments involve, among others, the expertise and growing technology in medical imaging, improvements in surgical technique are continuously being developed by neurosurgeons. A new method using a surgical support system for coil delivery has, for instance, been developed, and the surgery can be performed by only one surgeon (Nagano *et al.* 2010). This surgical support system still needs to be evaluated in equine surgery, but is of interest if we consider that having one skilled equine surgeon for this procedure in a referral centre is already difficult to achieve. More information is also needed to help the first line veterinarian confronted by a horse with epistaxis. Should they refer this case with any supportive treatment after uni- or bilateral common carotid artery ligation? All sorts of questions remain that are still controversial.

If additional treatment options to TACE can benefit in reducing the convalescence time in some cases of guttural pouch infection, more understanding of the pathogenesis is needed. Do we need to win a fight against *Aspergillus*, against bacteria or against the patient's physiological status?

In a recent study performed at VetAgro Sup, University of Lyon, intrapouch inoculation of *Aspergillus fumigatus* culture was performed in 8 normal guttural pouches of horses preconditioned with administration of systemic and local corticosteroids (M.C. Greppi, J.L. Cadoré, personal communication 2015). Mycotic lesions were described in all cases, but no development of clinical signs was identified and spontaneous regression within a 15–28 day period was observed. This observation is important because nobody can objectively assess the importance of spontaneous resolution of fungal lesions in a guttural pouch. At most, this evidence is noted when animals are presented and no treatment is undertaken, usually for financial reasons. Resolution of mycotic lesions is also observed from one to several weeks after TACE (Lepage and Piccot-Crezollet 2005), but we know that it is not always the case and that the presence of mycotic lesions seems to be independent of arterial occlusion (Ernst *et al.* 2006). How many individuals in the world equine population have not been diagnosed with GPM, by lack of clinical symptoms, absence of proper diagnostic means and have healed unnoticed? Meanwhile we should stop treating horses with multiple antifungal treatments as has been recently proposed (Cousty *et al.* 2015) especially if no proper occlusion technique has been performed. These multiple treatments, administered numerous times, have not proved successful while increasing the overall cost and do not prevent a fatal haemorrhage. But what are our options if, in some selected cases, *Aspergillus* is indeed involved not only with the epistaxis but the neurological signs that badly affect the prognosis? These cases may then benefit from adjunctive treatment such as hyperbaric oxygenation during the TACE procedure. Oxygen levels are indeed often decreased in the infected tissue of patients with aspergillosis, a hypoxic environment that impairs the oxidative killing capacity and phagocytosis of white cells and macrophage (García-Covarrubias *et al.* 2002).

Conclusion

Early diagnosis of guttural pouch epistaxis is essential in preventing a potential fatal haemorrhage. Endoscopy and radiology are obligatory complementary techniques to the clinical examination. Differential diagnosis should include mycotic and or bacterial infection, fracture of the stylohyoid bone, rupture of the *longus capitus* muscle, aneurysm and migration of foreign bodies (Dias *et al.* 2016). Any type of neurological disorder associated should be recognised and explained to the owner, because it gives a poorer prognosis in affected horses (Lepage and Piccot-Crezollet 2005) even after successfully preventing or stopping the epistaxis.

Independently of epistaxis, all cases should be considered as a priority emergency even if bleeding is not active at presentation. Additional diagnostic information should be obtained from an endoscopic evaluation to decide which pouch needs to be operated on first. The least invasive and most effective management is TACE using fluoroscope guidance with occlusion on both sides of the arterial lesion and with the patient placed under general anaesthesia.

Key factors for a high success rate to prevent epistaxis are a combination of: 1) early diagnosis and referral of the case; 2) an experienced surgeon familiar with the endoscopic and angiographic anatomy of the guttural pouch region, and with the technique, and equipped with a fluoroscope to perform proper positioning of all coils; 3) specific instruments with a wide size range of plugs or coils; and 4) proper positioning of the horse to prevent any movements during surgery.

Author's declaration of interests

No conflicts of interest have been declared.

Source of funding

None.

Manufacturer's address

[1]Cook Medical, Bloomington, Indiana, USA.

References

Archer, R.M., Knight, C.G. and Bishop, W.J. (2012) Guttural pouch mycosis in six horses in New Zealand. *NZ Vet. J.* **60**, 203-209.

Baptiste, K.E. (2004) The mystery of guttural pouch mycosis: the paradox of advancing knowledge of a rare disease. *Vet. J.* **168**, 1-2.

Baptiste, K.E., Naylor, J.M., Bailey, J., Barbers, E.M., Post, K. and Thornhill, J. (2000) A function for guttural pouches in the horse. *Nature* **403**, 382-383.

Bayly, W.M. and Robertson, J.T. (1982) Epistaxis caused by foreign body penetration of a guttural pouch. *J. Am. Vet. Med. Ass.* **180**, 1232-1234.

Benredouane, K. and Lepage, O.M. (2012) Trans-arterial coil embolization of the internal carotid artery in standing horses. *Vet. Surg.* **41**, 404-409.

Bisdorff, A., Von Brevern, M., Lempert, T. and Newman-Toker, D.E. (2009) Classification of vestibular symptoms: towards an international classification of vestibular disorders. *J. Vestib. Res.* **19**, 1-13.

Cheramie, H.S., Pleasant, R.S., Dabareiner, R.M. and Carolan, R.O. (2000) Detachable latex balloon occlusion of an internbal carotid artery with an aberrant branch in a horse with guttural pouch (auditory tube diverticulum) mycosis. *J. Am. Vet. Med. Ass.* **216**, 888-891.

Colles, C.M. and Cook, W.R. (1983) Carotid and cerebral angiography in the horse. *Vet. Rec.* **19**, 483-489.

Cook, W.R. (1968) The clinical features of guttural pouch mycosis in the horse. *Vet. Rec.* **83**, 336-345.

Cousty, M., De Beauregard, T., Picandet, V. and Tessier, C. (2015) Ligation of the ipsilateral common carotid artery and topical medication for prevention of hemorrhage from guttural pouch mycosis in horses. In: *Proceedings – Large Animals, Annual Scientific Meeting ECVS* (Berlin) 24, 57.

Delfs, K.C., Hawkins, J.F. and Hogan, D.E. (2009) Treatment of acute epistaxis secondary to guttural pouch mycosis with transarterial nitinol vascular occlusion plugs in three equids. *J. Am. Vet. Med. Ass.* **235**, 189-193.

Deluzurieux, M., Desjardins, I., Nolf, M., Guidi, E., Depecker, M. and Cadoré, J.L. (2013) Endoscopic analysis of guttural pouch opening in horses. *J. Exp. Appl. Sci.* **1**, 10-24.

Dias, D.P.M., Macoris, D.G. and Alessi, A.C. (2016) Guttural pouch empyema secondary to a periocular foreign body. *Equine Vet. Educ*. **28**, 367-371.

Edwards, G.B. and Greet, T. (2007) Disorders of the guttural pouches. In: *Equine Respiratory Medicine and Surgery*. Eds: B.C. McCorum, P.M. Dixon, N.E. Robinson and J. Schumacher, Saunders Elsevier, Philadelphia. pp 419-436.

Ernst, N.S., Freeman, D.E. and MacKay, R.J. (2006) Progression of mycosis of the auditory tube diverticulum (guttural pouch) after arterial occlusion in a horse with contralateral temporohyoid osteoarthropathy. *J. Am. Vet. Med. Ass.* **229**, 1945-1948.

Ferro, J.M., Rodrigues, G., Canhao, P., Melo, T.P., Oliveira, V., Pinto, A.N., Crespo, M. and Salgado, A.V. (1996) Diagnosis of transient ischemic attack by the nonneurologist. A validation study. *Stroke* **27**, 2225-2229.

Freeman, D.E. and Donawick, W.J. (1980) Occlusion of internal carotid artery in the horse by means of a balloon tipped catheter: clinical use of a method to prevent epistaxis caused by guttural pouch mycosis. *J. Am. Vet. Med. Ass.* **176**, 236-240.

García-Covarrubias, L., Barrat, D.M., Barlett, R., Metzinger, S. and Van Meter, K. (2002) Invasive aspergillosis treated with adjunctive hyperbaric oxygenation: a retrospective clinical series at a single institution. *South. Med. J.* **95**, 450-456.

Khairuddin, N.H., Sullivan, M. and Pollock, P.J. (2015) Angiographic variation of the internal carotid artery and its branches in horses. *Vet. Surg.* **44**, 784-789.

Lepage, O.M. (2007) Disorders of the guttural pouches. In: *Equine Respiratory Disease*, Lekeux 2nd edn. International Veterinary Information Service, Ithaca, NY. www.ivis.org/special_books/lekeux/lepage.

Lepage, O.M. and Piccot-Crezollet, C. (2005) Transarterial coil embolization in 31 horses (1999–2002) with guttural pouch mycosis: a two years follow-up. *Equine Vet. J.* **37**, 430-434.

Lepage, O.M., Cadoré, J.L. and Perron-Lepage, M.F. (2004) The mystery of fungal infection in the guttural pouches. *Vet. J.* **168**, 60-64.

Léveillé, R., Hardy, J., Robertson, J. and Lepage, O.M. (1999) Transarterial occlusion of the internal and external carotid and maxillary arteries using embolization coils in healthy horses. *Vet. Surg.* **28**, 208.

Léveillé, R., Hardy, J., Robertson, J.T., Willis, M.A., Beard, W.L., Weisbrode, S.E. and Lepage, O.M. (2000) Transarterial occlusion of the internal and external carotid and maxillary arteries for prevention of hemorrhage from guttural pouch mycosis in horses. *Vet. Surg.* **29**, 389-397.

Ludwig, A., Gatineau, S., Reynaud, M.C., Cadoré, J.L. and Bourdoiseau, G. (2005) Fungal isolation and identification in 21 cases of guttural pouch mycosis in horses (1198-2002). *Vet. J.* **169**, 457-461.

Maninchedda, U., Lepage, O.M., Gangl, M. and Benredouane, K. (2015) Percutaneous ultrasound-guided arterial angiography for trans-arterial coil placement in anesthetized and standing horses. *Vet. Surg.* **44**, 322-327.

Muñoz Moran, J.A. and Lepage, O.M. (2014) Patologias de las bolsas guturales. *Equinus* **40**, 22-38.

Muñoz, J., Iglesias, M. and Lloret Chao, E. (2015) Ultrasound guided transarterial coil placement in the internal and external carotid artery in horses. *Vet. Surg.* **44**, 328-332.

Nagano, Y., Nishio, Y., Matsubara, N., Miyachi, S. and Fujimoto, H. (2010) Surgical support system for cerebral aneurysm coil embolization. *NTN Tech. Rev*. **78**, 122-128.

Nation, P.N. (1978) Epistaxis of guttural pouch origin in horses: pathology of three cases. *Can. Vet. J.* **19**, 194-197.

Pattamapaspong, N., Srisuwan, T., Sivassomboon, C., Nasuto, M., Suwannahoy, P., Settakorn, J., Kraisarin, J. and Guglielmi, G. (2013) Accuracy of radiography, computed tomography and magnetic resonance imaging in diagnosing foreign bodies in the foot. *Radiol. Med.* **118**, 303-310.

Piat, P., Cadoré, J.-L. and Barone, R. (2014) Endoscopic anatomy of the normal equine guttural pouch. In: *Proceedings – Large Animals, Annual Scientific Meeting ECVS* (Denmark) 23,124.

Rush, T. (2004) Noncontagious diseases of the upper respiratory tract. In: *Equine Respiratory Diseases*, Eds: B. Rush and T. Mair, Blackwell Publishing, Oxford. pp 78-79.

Sulzbach-Hoke, L.M., Ratcliffe, S.J., Kimmel, S.E., Kolansky, D.M. and Polomano, R. (2010) Predictors of complications following sheath removal with percutaneous coronary intervention. *J. Cardiovasc. Nurs.* **25**, E1-E2.

Taha, M.M., Sakaida, H., Asakura, F., Maeda, M., Toma, N., Sano, T., Hori, K., Matsushima, S. and Taki, W. (2007) Access site complications with carotid angioplasty and stenting. *Surg. Neurol.* **68**, 431-437.

The only dual ingredient injectable corticosteroid approved by the FDA for use in horses

The link between RAPID ONSET and LONG-ACTING RELIEF of pain & inflammation[1]

BetaVet® (betamethasone sodium phosphate & betamethasone acetate injectable suspension) is indicated for the control of pain and inflammation associated with osteoarthritis in horses. **Learn more at www.betavetequine.com or call 1-800-458-0163**.

Please see Brief Summary of Full Prescribing Information on the following page.

BetaVet®

betamethasone sodium phosphate & betamethasone acetate

INJECTABLE SUSPENSION

INDICATION: BetaVet® is indicated for the control of pain and inflammation associated with osteoarthritis in horses.

IMPORTANT SAFETY INFORMATION

For Intra-Articular (I.A.) Use in Horses.

CONTRAINDICATIONS: BetaVet® is contraindicated in horses with hypersensitivity to betamethasone. Intra-articular injection of corticosteroids for local effect is contraindicated in the presence of septic arthritis.

WARNINGS: Do not use in horses intended for human consumption. Clinical and experimental data have demonstrated that corticosteroids administered orally or parenterally to animals may induce the first stage of parturition when administered during the last trimester of pregnancy and may precipitate premature parturition followed by dystocia, fetal death, retained placenta, and metritis. Additionally, corticosteroids administered to dogs, rabbits and rodents during pregnancy have resulted in cleft palate in offspring and in other congenital anomalies including deformed forelegs, phocomelia and anasarca. Therefore, before use of corticosteroids in pregnant animals, the possible benefits to the pregnant animal should be weighed against potential hazards to its developing embryo or fetus. Human Warnings: Not for use in humans. For use in animals only. Keep this and all medications out of the reach of children. Consult a physician in the case of accidental human exposure.

PRECAUTIONS: Corticosteroids, including BetaVet®, administered intra-articularly are systemically absorbed. Do not use in horses with acute infections. Acute moderate to severe exacerbation of pain, further loss of joint motion, fever, or malaise within several days following intra-articular injection may indicate a septic process. Because of the anti-inflammatory action of corticosteroids, signs of infection in the treated joint may be masked. Due to the potential for exacerbation of clinical signs of laminitis, glucocorticoids should be used with caution in horses with a history of laminitis, or horses otherwise at a higher risk for laminitis. Use with caution in horses with chronic nephritis, equine pituitary pars intermedia dysfunction (PPID), and congestive heart failure. Concurrent use of other anti-inflammatory drugs, such as NSAIDs or other corticosteroids, should be approached with caution. Due to the potential for systemic exposure, concomitant use of NSAIDs and corticosteroids may increase the risk of gastrointestinal, renal, and other toxicity. Consider appropriate wash out times prior to administering additional NSAIDs or corticosteroids.

ADVERSE REACTIONS: Adverse reactions reported during a field study of 239 horses of various breeds which had been administered either BetaVet® (n=119) or a saline control (n=120) at five percent (5%) and above were: acute joint effusion and/or local injection site swelling (within 2 days of injection), 15% BetaVet® and 13% saline control; increased lameness (within the first 5 days), 6.7% BetaVet® and 8.3% saline control; loose stool, 5.9% BetaVet® and 8.3% saline control; increased heat in joint, 2.5% BetaVet® and 5% saline control; and depression, 5.9% BetaVet® and 1.6% saline control.

DOSAGE AND ADMINISTRATION: Shake well immediately before use. Use immediately after opening, then discard any remaining contents.

RX ONLY

References: 1. Trotter GW. Intra-articular corticosteroids. In: McIlwraith CW, Trotter GW, eds. *Joint Disease in the Horse*. Philadelphia: W.B. Saunders; 1996;237–256.

LUITPOLD ANIMAL HEALTH

BetaVet®

betamethasone sodium phosphate &
betamethasone acetate

INJECTABLE SUSPENSION

BRIEF SUMMARY OF PRESCRIBING INFORMATION

(Betamethasone Sodium Phosphate and Betamethasone Acetate Injectable Suspension) 6 mg betamethasone per mL
For Intra-Articular (I.A.) Use in Horses

CAUTION: Federal law restricts this drug to use by or on the order of a licensed veterinarian.

DESCRIPTION: BetaVet® is a sterile aqueous suspension of betamethasone acetate in betamethasone sodium phosphate injection. The combined betamethasone content of the suspension is 6 mg/mL where each mL contains 3.15 mg betamethasone (as betamethasone sodium phosphate); 2.85 mg betamethasone (as betamethasone acetate); 7.1 mg dibasic sodium phosphate; 3.4 mg monobasic sodium phosphate; 0.1 mg edetate disodium; and 0.2 mg benzalkonium chloride, as a preservative in water for injection. The pH is adjusted to between 6.8 and 7.2.

INDICATION: BetaVet® is indicated for the control of pain and inflammation associated with osteoarthritis in horses.

DOSAGE AND ADMINISTRATION: Shake well immediately before use. Using strict aseptic technique, administer 1.5 mL BetaVet® (9 mg total betamethasone) per joint by intra-articular injection. BetaVet® may be administered concurrently in up to 2 joints per horse. Use immediately after opening, then discard any remaining contents.

CONTRAINDICATIONS: BetaVet® is contraindicated in horses with hypersensitivity to betamethasone. Intra-articular injection of corticosteroids for local effect is contraindicated in the presence of septic arthritis.

WARNINGS: Do not use in horses intended for human consumption. Clinical and experimental data have demonstrated that corticosteroids administered orally or parenterally to animals may induce the first stage of parturition when administered during the last trimester of pregnancy and may precipitate premature parturition followed by dystocia, fetal death, retained placenta, and metritis. Additionally, corticosteroids administered to dogs, rabbits and rodents during pregnancy have resulted in cleft palate in offspring. Corticosteroids administered to dogs during pregnancy have also resulted in other congenital anomalies including deformed forelegs, phocomelia and anasarca. Therefore, before use of corticosteroids in pregnant animals, the possible benefits to the pregnant animal should be weighed against potential hazards to its developing embryo or fetus. **Human Warnings:** Not for use in humans. For use in animals only. Keep this and all medications out of the reach of children. Consult a physician in the case of accidental human exposure.

PRECAUTIONS: Corticosteroids, including BetaVet®, administered intra-articularly are systemically absorbed. Do not use in horses with acute infections. Acute moderate to severe exacerbation of pain, further loss of joint motion, fever, or malaise within several days following intra-articular injection may indicate a septic process. Because of the anti-inflammatory action of corticosteroids, signs of infection in the treated joint may be masked. Appropriate examination of joint fluid is necessary to exclude a septic process. If a bacterial infection is present, appropriate antibacterial therapy should be instituted immediately. Additional doses of corticosteroids should not be administered until joint sepsis has been definitively ruled out. Due to the potential for exacerbation of clinical signs of laminitis, glucocorticoids should be used with caution in horses with a history of laminitis, or horses otherwise at a higher risk for laminitis. Use with caution in horses with chronic nephritis, equine pituitary pars intermedia dysfunction (PPID), and congestive heart failure. Concurrent use of other anti-inflammatory drugs, such as NSAIDs or other corticosteroids, should be approached with caution. Due to the potential for systemic exposure, concomitant use of NSAIDs and corticosteroids may increase the risk of gastrointestinal, renal, and other toxicity. Consider appropriate wash out times prior to administering additional NSAIDs or corticosteroids.

ADVERSE REACTIONS: Adverse reactions reported during a field study of 239 horses of various breeds which had been administered either BetaVet® (n=119) or a saline control (n=120) were: acute joint effusion and/or local injection site swelling (within 2 days of injection), 15% BetaVet® and 13% saline control; increased lameness (within the first 5 days), 6.7% BetaVet® and 8.3% saline control; loose stool, 5.9% BetaVet® and 8.3% saline control; increased heat in joint, 2.5% BetaVet® and 5% saline control; depression, 5.9% BetaVet® and 1.6% saline control; agitation/anxiety, 4.2% BetaVet® and 2.5% saline control; delayed swelling of treated joint (5 or more days after injection), 2.5% BetaVet® and 3.3% saline control; inappetance, 3.4% BetaVet® and 2.5% saline control; dry stool, 1.7% BetaVet® and 0% saline control; excessive sweating, 0.8% BetaVet® and 0% saline control; acute non-weight bearing lameness, 0.8% BetaVet® and 0% saline control; and laminitis, 0.8% BetaVet® and 0% saline control.

CLINICAL PHARMACOLOGY: Betamethasone is a potent glucocorticoid steroid with anti-inflammatory and immunosuppressive properties. Depending upon their physico-chemical properties, drugs administered intra-articularly may enter the general circulation because the synovial joint cavity is in direct equilibrium with the surrounding blood supply. After the intra-articular administration of 9 mg BetaVet® in horses, there were quantifiable concentrations of betamethasone (above 1.0 ng/mL) in the plasma.

EFFECTIVENESS: A negative control, randomized, masked field study provided data to evaluate the effectiveness of BetaVet® administered at 1.5 mL (9 mg betamethasone) once intra-articularly for the control of pain and inflammation associated with osteoarthritis in horses. Clinical success was defined as improvement in one lameness grade according to the AAEP lameness scoring system on Day 5 following treatment. The success rate for horses in the BetaVet® group was statistically significantly different (p=0.0061) than that in the saline group, with success rates of 75.73% and 52.52%, respectively (back-transformed from the logistic regression).

ANIMAL SAFETY: A 3-week target animal safety (TAS) study was conducted to evaluate the safety of BetaVet® in mature, healthy horses. Treatment groups included a control (isotonic saline at a volume equivalent to the 4x group); 1X (0.0225 mg betamethasone per pound bodyweight; BetaVet®); 2X (0.045 mg betamethasone per pound bodyweight; BetaVet®) and 4X (0.09 mg betamethasone per pound bodyweight; BetaVet®). Treatments were administered by intra-articular injection into the left middle carpal joint once every 5-days for 3 treatments. Injection site reactions were the most common observations in all treatment groups. Injection site reactions were observed within 1 hour of dosing and included swelling at the injection site, lameness/stiffness of the left front limb, and flexing the left front knee at rest. The injection site reactions ranged from slight swelling (in many horses on multiple days in all treatment groups) to excessive fluid with swelling, pain, and lameness (4x group only). Injection site reactions were observed most commonly on treatment days, and generally decreased in number and severity over subsequent days. The incidence of injection site reactions increased after the second and third injection (number of abnormalities noted on day 10 > day 5 > day 0). In the BetaVet® treated groups the number and severity of the injection site reactions were dose dependent. The 4X BetaVet® group had the highest overall incidence of and severity of injection site reactions, which included heat, swelling, pain, bleeding, and holding the limb up at rest. The control group and 4X group (which received similar injection volumes) had a similar incidence of injection site reactions; however, the severity of reactions was greater in the 4X group. Absolute neutrophils were statistically significantly higher in the BetaVet® treated groups as compared to the control group. Trends toward a decrease in lymphocytes and eosinophils, and an increase in monocytes were identified in the BetaVet® treated groups after the initial dose of BetaVet®. Individual animal values for white blood cells generally remained within the reference range. BetaVet® treated horses also had a trend toward increased blood glucose after the initial dose. Some individual animals showed mild increases in blood glucose above the reference range.

STORAGE CONDITIONS
Store at 20° to 25°C (68° to 77°F) (See USP Controlled Room Temperature). **Protect from light.** Use carton to protect contents from light until used.

HOW SUPPLIED
BetaVet®, One 5 mL vial containing 30 mg betamethasone; packaged in boxes of 1.

SHAKE WELL BEFORE USING

NADA 141-418, Approved by FDA

LUITPOLD ANIMAL HEALTH

A Division of Luitpold Pharmaceuticals, Inc.
One Luitpold Drive | P.O. Box 9001 | Shirley, NY 11967

Review Article

Evaluation of poor performance in competition horses: A musculoskeletal perspective. Part 2: Further investigation

S. Dyson

Centre for Equine Studies, Animal Health Trust, Newmarket, Suffolk, UK.
Corresponding author email: sue.dyson@aht.org.uk

Keywords: horse; lameness; behaviour; scintigraphy; radiography; local analgesia

Summary

There is not a right and a wrong way of investigating musculoskeletal causes of poor performance in sports horses and the methods of investigation are, in part, determined by the clinical signs. Measurement of serum muscle enzyme concentrations before and after exercise is essential for recognition of primary muscle pathology. Many horses with multilimb lameness have a secondary reduced range of motion of the thoracolumbosacral region mimicking primary thoracolumbar pain. Radiographic examination of the thoracolumbar vertebrae may be confusing unless combined with diagnostic analgesia because many clinically normal horses have radiological abnormalities. Nuclear scintigraphy offers a method of evaluating a large proportion of the horse, but there are many false positive and false negative results. Diagnostic analgesia is the most reliable method of investigation but requires experience and skill in interpretation and is time consuming in a horse with multilimb lameness.

Introduction

This is the second of a 2 part article on the investigation of musculoskeletal causes of poor performance in sports horses. Part 1 described features of a horse's gait or behaviour which may be a manifestation of musculoskeletal pain and explained some of the terminology used by riders (Dyson 2016). Part 2 considers methods of investigation. There is not a right or a wrong way. There are many potential approaches. It must be borne in mind that more than one musculoskeletal problem may be present and a musculoskeletal injury and medical problem (e.g. gastric ulcer syndrome, recurrent airway obstruction) may coexist. This review aims to discuss which methods might provide useful information and pitfalls of interpretation.

Investigation of poor performance: what to do next and where is the evidence?

There have been no large scale retrospective reviews of the assessment of poor performance in sports horses. The results of nuclear scintigraphic evaluation of 141 sports horses were reported (Ehrlich *et al.* 1998), but the results were not correlated with in depth clinical investigations. There have been a number of clinical reports which indicate that often several problems coexist contributing to pain and poor performance (Dyson and Murray 2003, 2012; Girodroux *et al.* 2009; Zimmerman *et al.* 2011a; Dyson 2014a,c; Marneris and Dyson 2014; Barstow and Dyson 2015; Plowright and Dyson 2015; Dyson and Rasotto 2016). These reports indicate the crucial role of diagnostic analgesia for determination of the source(s) of pain causing lameness and also highlight the importance of ridden exercise.

In some instances it may be challenging to determine initially how much of the problem perceived by a rider is pain-related. It can therefore be valuable to assess the response to systemically administered analgesic drugs (e.g. phenylbutazone), bearing in mind the potential placebo effect for the rider. While recognising the placebo effect, in general terms an improvement in performance usually does indicate a pain-related problem. A failure to observe improvement does not preclude pain: some causes of pain, for example sacroiliac joint region pain may be unaffected. It is advised that a rider should keep a diary of the horse's performance prior to treatment, during treatment (7–14 days) and after treatment. A dose of phenylbutazone 4.4 mg/kg b.i.d. (i.e. 2 g b.i.d. for a 500 kg horse) is recommended.

The role of the rider in the performance of a horse has to be considered. Horses which are experiencing discomfort when ridden often become evasive and less forward going; less commonly they become 'buzzy' trying to 'run away from pain' (Dyson 2015). Either behaviour can become intimidating to a rider. Change to a more experienced, skilful or stronger rider may result in improved performance, at least on a temporary basis, but this does not preclude pain as an underlying cause. Horses can be made to cooperate, but most pain-free horses are not naturally evasive. There are aspects of equine behaviour that must be considered. Laying the ears back, baring the teeth, an open mouth, a 'painful expression', tension above the eyes, flaring of the nostrils are all potential indicators of pain (Dalla Costa *et al.* 2014) (**Fig 1**).

Serum muscle enzyme concentrations: pre- and post exercise and interpretation of results

A small group of horses have chronic recurrent exertional rhabdomyolysis (RER) without showing typical signs of tying-up, but are performing less well than previously. A small proportion of these horses have equine polysaccharide storage myopathy (Valentine 2003; Stanley *et al.* 2009); in the remainder the underlying cause can be difficult to define. There is no typical history for these horses, nor do they show characteristic clinical signs, but serum aspartate aminotransferase concentrations are usually permanently elevated to some degree, reflecting previous rhabdomyolysis episodes. Strenuous exercise usually provokes a rise in creatine kinase concentration. Thus measurement of serum

Fig 1: Facial expression as a manifestation of pain. a) This 10-year-old Warmblood advanced dressage horse had a history of tension, back stiffness and sporadic resistances. The horse exhibited poor hindlimb impulsion and engagement when ridden, hung on the right rein and bounced the rider out of the saddle in canter. Note the horse has its ears flat back with the neck extended. When pain was abolished by bilateral perineural analgesia of the deep branch of the lateral plantar nerve and infiltration of local anaesthetic solution around the sacroiliac joints, the horse was transformed and worked correctly on the bit, with the ears forward, an even contact in the rider's hands and swing through the back. b) This 7-year-old Irish mare had a right forelimb lameness when ridden and bilateral hindlimb lameness. The forelimb lameness was characterised by a markedly shortened cranial phase of the step, consistently worst when the rider sat on the right fore/left hind diagonal in trot. The horse was reluctant to trot and pinned its ears back and held the mouth open. When the rider sat on the opposite diagonal the forelimb lameness was much less obvious and the horse went forward more willingly with the ears forward.

muscle enzyme concentrations before and after exercise is crucial for identification of these horses.

Muscle biopsy and genetic testing

If serum muscle enzyme concentrations are chronically elevated then polysaccharide storage myopathy must be considered as a possible differential diagnosis. Muscle biopsy for histological assessment (Valentine 2003) and genetic testing are indicated (Stanley and Piercy 2007; McCue *et al.* 2008; Stanley *et al.* 2009).

Radiographic and ultrasonographic assessment of the thoracolumbar region: interpretation of results

To an extent, the thoracolumbosacral region is a mirror of a horse's musculoskeletal health and the way in which it works. Lameness may result in secondary epaxial muscle pain (Landman *et al.* 2004). Horses adapt to lameness by stiffening the thoracolumbar-sacral region (Buchner *et al.* 1996; Gómez Álvarez *et al.* 2007, 2008). As a result, there may be atrophy of the epaxial muscles and potentially a vicious cycle ensues. Reduction in muscular support of the thoracolumbar spine and reduced core strength may contribute to the development of thoracolumbar pain (Licka *et al.* 2009). Thoracolumbar pain results in reduced movement (Wennerstrand *et al.* 2004, 2009).

It is often assumed that problems which are manifest when a horse is ridden, particularly when characterised in part by trunk stiffness, are likely to be related to primary thoracolumbar pathology. However, lameness can present with similar clinical symptoms. It has been observed that some horses develop a coping strategy in association with either forelimb or hindlimb lameness (often mild and bilateral), becoming progressively stiffer and more restricted in their gaits (Zimmerman *et al.* 2011a). The clinical signs may mimic those of thoracolumbar pain, resulting in the horse being more reluctant to work 'on the bit' and to maintain a correct contact, becoming 'above the bit' and evasive. However, these signs may be abolished if pain causing lameness is alleviated by diagnostic analgesia (Dyson 2013a). Nonetheless, radiographic examination of the thoracolumbar region may be indicated particularly in those horses with pain on palpation and manipulation of the thoracolumbosacral region, abnormal muscle tension, limitation of passive movement and epaxial muscle atrophy. Examination of the summits of the spinous processes alone is inadequate and assessment should include the spinous processes in their entirety (Zimmerman *et al.* 2011b), articular process joints (APJs) (Girodroux *et al.* 2009) and vertebral bodies and intercentral articulations (Meehan *et al.* 2009).

The high prevalence of radiological evidence of impinging spinous processes in both clinically normal horses and lame horses (Erichsen *et al.* 2004; Zimmerman *et al.* 2011a,b) results in over diagnosis of impinging spinous processes as the primary problem (**Fig 2**). Thoracolumbar region pain and lameness often coexist. It has been suggested that altered movement associated with either forelimb or hindlimb lameness may result in previously asymptomatic lesions in the thoracolumbar region becoming symptomatic (Zimmerman *et al.* 2011a). Well ridden, such horses may cope despite lameness and/or thoracolumbosacral pain, but a change in rider to one less skilful may result in clinical signs becoming apparent. Alternatively, even with a good rider, clinical signs may be insidiously progressive until a major loss of performance is recognised. Diagnostic analgesia is crucial for accurate interpretation of the contribution of impinging spinous processes to thoracolumbar pain and in some horses for the detection of concurrent lameness.

The greater the severity of radiological abnormalities of impinging spinous processes, using a predetermined grading system (Zimmerman *et al.* 2011a), the more likely they were to be of clinical significance, especially when assessed in conjunction with the results of nuclear scintigraphy. However,



Fig 2: Lateral-lateral radiographic images of the mid- to caudal thoracic regions of 3 horses with evidence of impinging spinous processes (SPs). Cranial is to the left. a) There is impinging and/or overlapping of the dorsal aspect of the SPs of the 12th thoracic to 17th thoracic vertebrae. There are areas of increased opacity adjacent to the compact bone. At the time of clinical investigation this was an incidental finding. The horse's lack of hindlimb impulsion was improved hugely by abolition of a low grade bilateral hindlimb lameness. b) The SPs of the 13th thoracic to first lumbar vertebrae are extremely close throughout most of their length. There are focal areas of increased opacity and reduced opacity near the summits of several SPs. This Prix St Georges dressage horse was reluctant to go forwards when ridden and showed marked stiffness of the thoracolumbosacral region. No improvement in gait was seen after local anaesthetic solution was infiltrated around these SPs. However, desensitisation of the front feet and infiltration of local anaesthetic solution around the sacroiliac joints produced very substantial improvement in clinical signs. c) The SPs of the 13–18th thoracic vertebrae. The SPs of the 13th (T13), 14th (T14), 16th (T16) and 17th (T17) thoracic vertebrae are impinging. There is a well circumscribed radiolucent area in the cranial aspect of the SP of T14. There are multiple radiolucent zones in the areas of apposition of T16 and 17. There was huge improvement in clinical signs of working above the bit with poor hindlimb impulsion and thoracolumbar stiffness after infiltration of local anaesthetic solution around T13 and 14 and T16 and 17, indicating the likely clinical significance of these radiological findings in this horse.

nuclear scintigraphy had both false positive and false negative results for the determination of the clinical significance of impinging spinous processes (Zimmerman *et al.* 2011a,b). It should also be borne in mind that the spinous processes may be very close together throughout their length and while not causing pain, may limit flexibility of the spine and predispose to the development of pain elsewhere, for example the sacroiliac joints (Barstow and Dyson 2015).

The prevalence of osteoarthritis (OA) of the APJs in asymptomatic sports horses is unknown. Severity of clinical signs in 77 horses with a history of poor performance together with radiological evidence of OA of the caudal thoracic APJs was associated with the presence of concurrent osseous pathology of the thoracolumbar vertebrae (Girodroux *et al.* 2009). In a comparative study of 31 clinically normal sports horses in full work and 65 horses with back pain and radiographic evidence of OA of caudal thoracic APJs, there was an association between moderate or intense increased radiopharmaceutical uptake (IRU) in the articular processes and back pain (Gillen *et al.* 2009). Acquisition of high quality radiographs requires high exposures and careful collimation of the x-ray beam; interpretation can be confounded by superimposition of the mamillary processes. Lesions at the thoracolumbar junction may be obscured by the diaphragm.

Ultrasonography can be useful for assessment of the APJs; however, the absence of detectable abnormality does not preclude joint pathology such as alteration of joint space width and subchondral bone changes, which can only be identified radiographically. Assessment of the supraspinous ligament is easily performed, but interpretation of abnormalities is not straightforward because of the presence of lesions in asymptomatic horses (Henson *et al.* 2007).

Imaging the thoracolumbosacral region when clinically indicated is best done before diagnostic analgesia so that blocks of the back can be directed by the imaging findings and combined with other local analgesic techniques. (see

Diagnostic analgesia: where to start, how to proceed and how to interpret the results).

Scintigraphy: what to examine when and how to interpret the results

There is a temptation when faced with a horse performing poorly with no obvious underlying cause to suggest nuclear scintigraphic assessment, to include evaluation of the cervical and thoracolumbar regions, forelimbs, pelvis and hindlimbs. This is expensive, time consuming and often gives spurious false positive or false negative results. An excellent, provocative review article challenged whether we have evidence of validity of equine scintigraphy as a diagnostic test, the bias of many publications and the lack of gold standard comparisons (Archer *et al.* 2007). Interpretation is influenced by the age of the horse, work discipline, recent work history and lameness. For example, elite showjumpers have greater RU in the dorsal aspect of the central and third tarsal bones compared with horses from other sports, which presumably reflects the physiological stress imposed upon these bones under normal loading (Murray *et al.* 2004). Focal intense IRU may be seen in the dorsoproximal aspect of the diaphysis of the proximal phalanx unassociated with lameness, usually bilaterally symmetrically and sometimes in all 4 limbs (Bailey *et al.* 2007). This is seen most commonly in older Warmblood dressage horses, but can be seen in horses of any age or work discipline. The thickness of overlying musculature and thus attenuation of radioactivity, the conformation of the pelvis, shape of articulations and age of the horse may influence the appearance of the sacroiliac joint regions (Erichsen *et al.* 2002, 2003; Dyson *et al.* 2003a,b; Gorgas *et al.* 2009). Large, older horses, especially if overweight, may have relatively poor quality images because of prolonged RU in the soft tissues and inferior resolution of the bones and soft tissues.

Nuclear scintigraphy is very sensitive to alteration in bone turnover and IRU is not necessarily synonymous with pain and lameness (Dyson 2014b). Focal, intense, unilateral IRU can be seen at locations unrelated to a documented source of pain, apparently as an incidental finding (**Fig 3**). There may be no logical explanation for IRU at that site and the IRU may persist long-term. There are many instances in which scintigraphy yields negative results, particularly in association with some soft tissue injuries such as proximal suspensory desmopathy (Dyson *et al.* 2007) and many causes of stifle pain. Nonetheless, a negative bone scan does give useful information, making the presence of some conditions less likely (e.g. OA of the distal hock joints). However, scintigraphy is particularly useful in highlighting the presence of lesions unlikely to be detected by clinical examination and which do not respond to local analgesic techniques. Osseous cyst-like lesions in the humeral tubercles, trauma of the humeral head, enthesopathy or fracture of the third trochanter of the femur, greater trochanter of the femur or tuber ischia and stress fractures are typical examples, which may be investigated further using radiography and ultrasonography. However, these are relatively unusual causes of poor performance and are more likely to be associated with unilateral lameness. It must also be borne in mind that IRU may persist long-term, long after an injury has ceased to be of clinical significance e.g. following trauma to an ischial tuberosity. In many horses presented with a history of poor performance the results of nuclear scintigraphy are negative, or areas of IRU are identified which are of no current clinical significance.

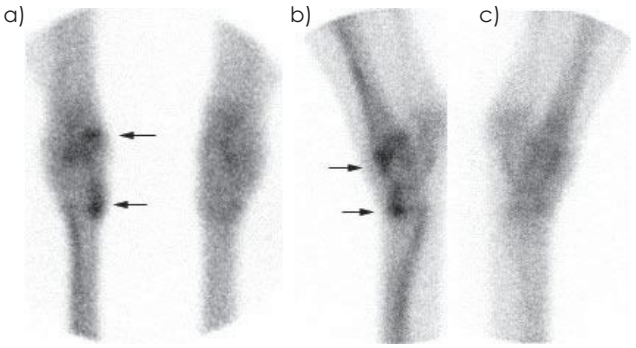

Fig 3: a) Plantar, b) left lateral and c) right lateral scintigraphic images of the hocks of a 10-year-old Grand Prix showjumper with poor performance, lacking hindlimb power and tending to jump from left to right, implying greater push off from the left hindlimb compared with the right. The lateral image of the right hindlimb has been scaled to match the left hindlimb. There is moderate focal increased radiopharmaceutical uptake (IRU) in the distal cranial and distal medial aspects of the left tibia (arrow) and in the dorsal and medial aspects of the subchondral bone of the left tarsometatarsal joint (arrow). These were incidental areas of IRU. Low grade bilateral hindlimb lameness (right>left) and hindlimb power were greatly improved after bilateral perineural analgesia of the deep branch of the lateral plantar nerve. There was no response to intra-articular analgesia of the left or right tarsometatarsal joints. There was ultrasonographic evidence of proximal suspensory desmopathy.

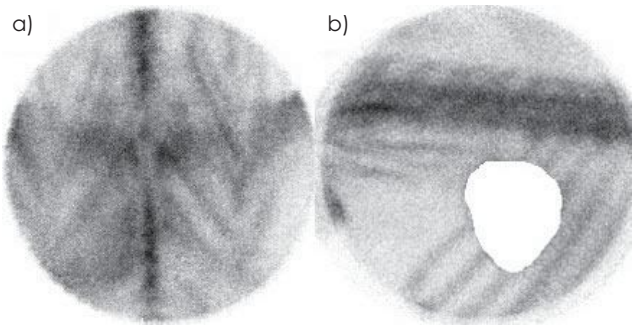

Fig 4: a) Dorsal scintigraphic image of the pelvis (cranial to the top) and b) right lateral oblique image of the caudal thoracic and lumbar regions of a 12-year-old Thoroughbred 4 star event horse with reduced performance. The kidney has been masked out in (b). The horse's hindlimb action had deteriorated and she lacked power. There are linear streaks of increased radiopharmaceutical uptake in the gluteal and psoas muscles, consistent with recurrent exertional rhabdomyolysis (RER). This was verified by abnormally high concentration of serum aspartate aminotransferase and increased creatine kinase after exercise compared with before exercise. The horse tested negative for equine polysaccharide storage myopathy.

Bone phase images may also highlight abnormal RU in muscles (Hornof and Koblik 1991; Ehrlich *et al.* 1998; Dyson 2014b) reflecting focal chronic fibrotic myopathy (which can be verified by ultrasonography), or chronic muscle strain. Increased RU in muscles in bone phase images may also be seen in either acute, exercise-induced myopathy or chronic RER (**Fig 4**), which is associated with increased serum

Fig 5: A 4-year-old Warmblood young event horse in right lead canter. a) The horse was reluctant to trot and kept breaking into canter, but in canter was consistently above the bit, with her ears back and constantly swished her tail. The thoracolumbosacral region was held stiffly. In trot the hindlimb gait had an irregular rhythm. Nuclear scintigraphic examination of the thoracolumbar and pelvic regions and hindlimbs revealed a normal pattern of radiopharmaceutical uptake. b) After bilateral perineural analgesia of the deep branch of the lateral plantar nerves and infiltration of local anaesthetic solution around the sacroiliac joints. Both analgesic techniques produced improvement in the mare's performance and she now worked consistently on the bit in trot with increased flexibility of the thoracolumbosacral region. In canter the mare had increased hindlimb impulsion and engagement with greater flexion of the lumbosacral joint. Note the ears are now forward. The forelimbs have increased lift compared with (a). The neck was bandaged to protect an intravenous catheter as she was extremely difficult to inject.

concentrations of creatine kinase and aspartate aminotransferase. Horses with chronic RER may never have shown typical signs of tying-up, but are usually undergoing investigation because of a reduced level of performance. However, not all horses with RER have IRU and whether the underlying pathological mechanisms differ in those that do or do not have IRU remains unanswered.

Thus when considering nuclear scintigraphy the cost benefit ratio must be carefully assessed. The examination should be targeted based on the clinical assessment. Nuclear scintigraphy is not a substitute for a comprehensive clinical assessment and diagnostic analgesia. It is generally of little value to investigate regions of IRU by radiography unless pain has been localised to that area using diagnostic analgesia.

Diagnostic analgesia: where to start, how to proceed and how to interpret the results

As with any lameness investigation, the key to accurate diagnosis of the cause(s) of poor performance is to identify the source(s) of pain. Many horses which present with poor performance, rather than overt lameness seen in hand, are lame in more than one limb and 3 or 4 limbs may be involved ± sacroiliac joint region pain and/or thoracolumbosacral pain. With experience, the number of lame limbs should be predictable based on a comprehensive clinical assessment, including ridden exercise (Dyson 2009, 2016). This observation is important because it will dictate how long needs to be set aside for the initial investigation using diagnostic analgesia (1–4 h), which techniques to use and the order in which they should be performed.

The start point is based on the results of the clinical assessment. For example, consider a horse with a low grade bilateral hindlimb lameness, characterised by a short stepping gait in hand, which shows exacerbation of lameness in one limb after proximal limb flexion (flexion of the coxofemoral, stifle and hock joints), no response to stifle flexion and no other localising clinical signs. It may be logical to first perform intra-articular analgesia of the tarsometatarsal joint, bearing in mind that if the response is positive then this does not necessarily imply that the joint is the primary source of pain. There is the potential to influence proximal suspensory ligament pain (Dyson and Romero 1993). Alternatively, if there are no localising clinical signs it would be reasonable to start with perineural analgesia of the plantar (at the junction of the proximal three-quarters and distal one-quarter of the metatarsus) and plantar metatarsal nerves (distal to the distal aspect of the second and fourth metatarsal bones) i.e. a 'low 4-point block', on the assumption that the response would be negative. If a lamer hindlimb can be detected ridden, the next step would be perineural analgesia of the deep branch of the lateral plantar nerve of that limb. However, if the principle clinical observation was lack of hindlimb impulsion and engagement, it would be reasonable to perform perineural analgesia of the deep branch of the lateral plantar nerve in both hindlimbs. On each occasion the horse is reassessed ridden, to include 10 m diameter circles in trot and any other movements that the horse found difficult prior to local analgesia, including canter. The latter is very important because a huge improvement may be seen in trot, with little alteration in the quality of canter, if there is coexistent sacroiliac joint region pain (Dyson and Murray 2003; Barstow and Dyson 2015). The degree of lameness (if present), the overall quality of movement and attitude to work, the posture, balance, rhythm and rideability of the horse and the comfort of the rider are assessed after each block (**Fig 5**). Grading lameness before and after diagnostic analgesia is important to facilitate recognition of improvement in lameness (Dyson 2011), but with low grade lameness manifest as poor performance features such as ease of turning, symmetry of contact with the rider's hands via the reins and mobility of the thoracolumbosacral spine should be assessed (Dyson 2016; see Videos 1 and 2 in Part 1, Supplementary information). It should be borne in mind that hindlimb toe drag may not be abolished in some horses with hindlimb lameness and in some horses toe drag may be

accentuated after diagnostic analgesia, despite other major improvements in the gait. The degree of improvement appreciated by a rider may be more than can be necessarily detected by observing the horse. This is when recognition of how normal horses work is hugely important.

If the clinical assessment suggests only forelimb pain, then in the absence of any localising clinical signs it would be logical in most horses to start with palmar digital nerve blocks in the lamer limb (if one limb is worse than the other). However, in the presence of effusion in a metacarpophalangeal joint and pain on passive flexion, a more targeted approach might be to first perform intra-articular analgesia of the joint. In some horses a lamer limb cannot be detected but the horse is short stepping bilaterally. It might be logical to assume that if pain arises from the front feet, desensitisation of one foot should result in the development of overt lameness in the contralateral limb. While this does occur in some horses, occasionally a horse continues to look short stepping until both front feet are desensitised simultaneously.

Some owners want or do not want specific diagnoses. Their judgement of improvement is therefore subject to bias. Owners may also be looking for perfection after nerve blocks rather than substantial improvement in performance; perfection is not always achievable and this needs to be explained. However, other riders are very perceptive of changes and are a huge asset in interpreting improvements in the gait and the horse's manner of working. Some riders do not have the skill to ride a horse sufficiently positively after diagnostic analgesia and unless the rider asks the horse to work correctly it may not do so. In such a situation it is invaluable to work together with a rider skilled in assessing a horse's responses after diagnostic analgesia, bearing in mind that at times the response is not instantaneous. The horse has to learn that it can move better without pain. If the owner either feels a huge difference before and after nerve blocks, or sees the difference, either live or on video recordings, it can help them to understand the degree of discomfort a horse may be experiencing, despite not showing obvious lameness.

It is beyond the scope of this review to describe all the nerve block combinations which may be required to improve the gait maximally. Common combinations of problems are bilateral hindlimb proximal suspensory desmopathy and bilateral front foot pain; bilateral hindlimb proximal suspensory desmopathy and sacroiliac joint region pain; hindlimb suspensory branch injury, bilateral hindlimb proximal suspensory desmopathy and unilateral or bilateral forelimb proximal suspensory desmopathy; bilateral hindlimb proximal suspensory desmopathy and bilateral metacarpophalangeal joint pain. The list is obviously endless, but with coexistent fore- and hindlimb lameness it does mean that short cuts may need to be taken in order to complete all the blocks required, while the first positive blocks remain effective. Assuming that the pitfalls are recognised and further investigation bears this in mind, this is an acceptable pragmatic approach.

For example, after a 'low 4-point block' of the left hindlimb, bilateral perineural analgesia of the deep branch of the lateral plantar nerve and infiltration of local anaesthetic solution around the sacroiliac joint regions, the hindlimb gait may be hugely improved in both trot and canter. However, the horse may still take short forelimb steps, with slightly lame steps with the right forelimb on the outside of a circle. Rather than perform palmar digital nerve blocks of the right forelimb, it might be best to perform palmar nerve blocks at the base of the proximal sesamoid bones. If the lameness was abolished and switched to overt left forelimb lameness, then this may reflect fetlock, pastern or foot pain. However, if lameness persisted, or was indeed accentuated, this may point to forelimb proximal suspensory desmopathy, requiring a 'low 4-point block' and then a method of subcarpal analgesia in the right forelimb. It is likely that additional blocks in the left forelimb would then be needed. These are common clinical scenarios and must be anticipated from the outset when planning the time required and estimated costs of investigation. The more complicated the lameness, the greater the need for experience in performing and interpretation of local analgesic techniques.

When all sources of pain are anaesthetised there is often a transformation in the quality of the balance and paces of the horse and the ease with which it can be ridden. This serves to highlight how much a horse may have compromised its movement to minimise pain and the overall level of pain that the horse had been experiencing.

Objective gait assessment: is there a place for it in the investigation of poor performance?

There is a growing body of evidence that there are potential benefits of objective gait assessment using inertial measurement units (IMUs), both for accurate determination of the lame limb and for quantification of improvement in lameness after diagnostic analgesia (Keegan *et al.* 2001; Kramer *et al.* 2004; Pfau *et al.* 2014). It may help some practitioners detect subtle unilateral lameness. However, with the way in which the technology is currently used, its usefulness in the investigation of low grade multilimb lameness remains to be determined. The technology allows quantification of movement of the head and tubera coxae and/or tubera sacrale, the latter reflecting the symmetry of hindlimb loading and propulsion. With a bilaterally symmetrical fore- or hindlimb gait abnormality manifest as reduced step length, with or without other changes in body posture and thoracolumbosacral movement, IMUs may not assist in identification of the lame limbs. Moreover, if low grade asymmetry is detected, such asymmetry may persist after diagnostic analgesia has resulted in huge improvement in the overall performance of the horse when ridden (Dyson 2014c).

Diagnostic imaging after local analgesia

Once pain has been localised to a region, comprehensive radiographic and ultrasonographic examinations are indicated, bearing in mind that local analgesic techniques are less specific than ideal. Palmar digital nerve blocks may influence pain not only emanating from the foot, but also the pastern region and occasionally the fetlock (Werpy 2012; Nagy and Malton 2015). Palmar metacarpal (subcarpal) nerve blocks may relieve carpal pain (Nagy *et al.* 2012). Thus imaging should include all areas from which pain could be arising.

More selective local analgesic techniques

The results of diagnostic imaging may guide the selection of more specific local analgesic techniques to rule in or rule out the significance of findings. For example, it is well recognised that perineural analgesia of the deep branch of the lateral plantar nerve is not specific for proximal metatarsal region pain, but can influence tarsal region pain (Claunch *et al.* 2013; Dyson 2013b; Davis *et al.* 2014; Contino *et al.* 2015). Radiological abnormalities of the centrodistal and tarsometatarsal joints often coexist with proximal suspensory desmopathy (Skelly-Smith *et al.* 2015). To determine the significance or otherwise of these radiological abnormalities it is essential to assess the response to intra-articular analgesia of the tarsometatarsal joint ± centrodistal joint.

If the principle cause of poor performance is bilateral front foot pain, then more selective local analgesic techniques, such as intra-articular analgesia of the distal interphalangeal joint and intrathecal analgesia of the navicular bursa, may be of benefit in order to target therapy. However, the nonspecificity of these techniques should be borne in mind (Schumacher *et al.* 2001a,b; Gough *et al.* 2002; Parkes *et al.* 2015).

Weighing-up the relative component of each source of pain for determining treatment and prognosis

Grading lameness before and after diagnostic analgesia (Dyson 2011) and describing and quantifying overall changes in gait and performance in walk, trot and canter (Dyson 2013a) are invaluable for trying to determine the relative contribution of different sources of pain to poor performance. This is important for determining both which problems are the most important to attempt to treat and the overall prognosis. For example, consider a horse in which the hindlimb gait in trot was hugely improved by bilateral perineural analgesia of the deep branch of the lateral plantar nerve (in association with proximal suspensory desmopathy) and there was improvement in the quality of the canter, but residual discomfort persisted in canter. Infiltration of local anaesthetic solution around the sacroiliac joints abolished the remaining clinical signs. This horse would be a good candidate for treatment, with a favourable prognosis. However, if the estimated improvement in quality of the gait in both trot and canter after bilateral perineural analgesia of the deep branch of the lateral plantar nerve was only 50%, with the remaining pain being associated with the sacroiliac joint region, the prognosis would be much less optimistic.

Prognosis is also influenced by other features such as conformation, chronicity of the problems, the horse's temperament and the sport in which the horse is engaged. A horse with straight hock conformation or static or dynamic hyperextension of the metatarsophalangeal joints in association with hindlimb proximal suspensory desmopathy is a poor candidate for long-term successful treatment (Dyson and Murray 2012). A horse with a lordotic conformation of the thoracolumbar region may not respond well to rehabilitation work in a Pessoa Training Aid (Walker *et al.* 2013). If a complex problem has retrospectively been present since purchase 9 months previously (and thus possibly much longer) and the horse has extreme thoracolumbosacral stiffness and atrophy of the epaxial musculature, rehabilitation will be much more challenging than in a horse with recent onset clinical signs. Just as in man, horses show various reactions to pain, some apparently having a much higher pain threshold or a willingness to work despite pain than others. As a general rule event horses which train in a variety of disciplines (cross train) and inherently enjoy jumping, can cope with chronic pain better than dressage horses.

Assessment of the ability of the rider to work with the problems

Successful rehabilitation often requires a team approach by the veterinarian, farrier, physiotherapist and/or chiropractor and saddle fitter, but the skill of the rider and their drive to achieve the end result must not be underestimated. If the rider is not capable of riding the horse correctly then the redevelopment of atrophied epaxial muscles and restoration of key core muscle strength are challenging. Correct use of training aids such as draw reins or a bungee, or the Equiband[1] system may be helpful. A committed amateur owner with the time and determination to perform carrot stretch exercises may achieve a better result than a multihorse rider who has no-one to delegate to. Access to facilities such as a horsewalker can be invaluable for active walking rehabilitation (in a Pessoa Training Aid) and for warm-up and warm down when ridden exercise is resumed.

Conclusions

Investigation of musculoskeletal causes of poor performance is challenging and time consuming. It requires a lameness expert who ideally has knowledge of horse sports and equitation. Comprehensive diagnostic imaging is not an appropriate substitute for careful clinical appraisal, including ridden exercise and diagnostic analgesia.

Author's declaration of interests

No conflicts of interest have been declared.

Ethical animal research

Approved by Ethical Review Committee of the Animal Health Trust.

Source of funding

None.

Manufacturer's address

[1]Equiband www.equicoreconcepts.com

References

Archer, D., Boswell, J., Voute, L. and Clegg, P. (2007) Skeletal scintigraphy in the horse: current indications and validity as a diagnostic test. *Vet. J.* **173**, 31-44.

Bailey, R., Dyson, S. and Parkin, T. (2007) Focal increased radiopharmaceutical uptake in the dorsoproximal diaphyseal region of the equine proximal phalanx. *Vet. Radiol. Ultrasound.* **48**, 460-466.

Barstow, A. and Dyson, S. (2015) Clinical features and diagnosis of sacroiliac joint region pain in 296 horses: 2004–2014. *Equine Vet. Educ.* **27**, 637-647.

Buchner, H.H., Savelberg, H.H., Schamhardt, H.C. and Barneveld, A. (1996) Head and trunk movement adaptations in horses with experimentally induced fore- or hindlimb lameness. *Equine Vet. J.* **28**, 71-76.

Claunch, K., Eggleston, R. and Baxter, G. (2013) Anesthetic diffusion following two approaches to block the deep branch of the lateral plantar nerve. *Proc. Am. Ass. Equine Practnrs.* **59**, 84.

Contino, E.K., King, M.R., Valdés-Martinez, A. and McIlwraith, C.W. (2015) In vivo diffusion characteristics after perineural injection of the deep branch of the lateral plantar nerve with mepivacaine or iohexol in horses. *Equine Vet. J.* **47**, 230-234.

Dalla Costa, E., Minero, M., Lebelt, D., Stucke, D., Canali, E. and Leach, M. (2014) Development of the horse grimace scale (HGS) as a pain assessment tool in horses Undergoing Routine Castration. *PLoS ONE* **9**, e92281. doi:10.1371/journal.pone.0092281.

Davis, W., Caniglia, C.J., Lustgarten, M., Blackwelder, T., Robertson, I. and Redding, W.R. (2014) Clinical and diagnostic imaging characteristics of lateral digital flexor tendinitis within the tarsal sheath in four horses. *Vet. Radiol. Ultrasound.* **55**, 166-173.

Dyson, S. (2009) The clinician's eye view of hindlimb lameness in the horse: technology and cognitive evaluation. *Equine Vet. J.* **41**, 99-100.

Dyson, S. (2011) Can lameness be reliably graded?. *Equine Vet J.* **43**, 379-382.

Dyson, S. (2013a) Equine lameness: clinical judgement meets advanced diagnostic imaging. *Proc. Am. Ass. Equine Practnrs.* **59**, 92-122.

Dyson, S. (2013b) Lameness associated with mineralisation of the central tarsal bone and a small osseous cyst-like lesion in two sports horses. *J. Equine. Vet. Sci.* **33**, 51-56.

Dyson, S. (2014a) Hindlimb lameness associated with proximal suspensory desmopathy and injury of the accessory ligament of the suspensory ligament: five horses. *Equine Vet. Educ.* **26**, 538-542.

Dyson, S. (2014b) Musculoskeletal scintigraphy of the equine athlete. *Semin. Nucl. Med.* **44**, 4-14.

Dyson, S. (2014c) Recognition of lameness: man versus machine. *Vet. J.* **201**, 245-248.

Dyson, S. (2015) Equine performance and equitation science: clinical issues. *J. Appl. Anim. Behav. Sci.* In press.

Dyson, S. (2016) Evaluation of poor performance in competition horses: a musculoskeletal perspective Part 1: clinical assessment. *Equine Vet. Educ.* **28**, 284-293.

Dyson, S. and Murray, R. (2003) Pain associated with the sacroiliac joint region: a clinical study of 74 horses. *Equine Vet. J.* **35**, 240-245.

Dyson, S. and Murray, R. (2012) Management of hindlimb proximal suspensory desmopathy by neurectomy of the deep branch of the lateral plantar nerve and plantar fasciotomy: 155 horses (2003–2008). *Equine Vet. J.* **44**, 361-367.

Dyson, S. and Rasotto, R. (2016) Idiopathic hopping-type forelimb lameness syndrome in ridden horses: 46 horses (2002-2014). *Equine Vet. Educ.* **28**, 30-39.

Dyson, S. and Romero, J.M. (1993) An investigation of injection techniques for local analgesia of the equine distal tarsus and proximal metatarsus. *Equine Vet. J.* **25**, 30-35.

Dyson, S., Murray, R., Branch, M., Whitton, C., Donovan, T. and Hardy, E. (2003a) The sacroiliac joints: evaluation using nuclear scintigraphy Part I: the normal horse. *Equine Vet. J.* **35**, 226-232.

Dyson, S., Murray, R., Branch, M. and Harding, E. (2003b) The sacroiliac joints: evaluation using nuclear scintigraphy Part 2: Lame horses. *Equine Vet. J.* **35**, 233-239.

Dyson, S., Weekes, J. and Murray, R. (2007) Scintigraphic evaluation of the proximal metacarpal and metatarsal regions of horses with proximal suspensory desmitis. *Vet. Radiol. Ultrasound.* **48**, 78-85.

Ehrlich, P., Seeherman, H., O'Callaghan, M., Dohoo, I. and Brimacombe, M. (1998) Results of bone scintigraphy in horses used for show jumping, hunting or eventing: 141 cases (1988-1994). *J. Am. Vet. Med. Ass.* **213**, 1460-1467.

Erichsen, C., Berger, M. and Eksell, P. (2002) The scintigraphic anatomy of the equine sacroiliac joint. *Vet. Radiol. Ultrasound.* **43**, 287-292.

Erichsen, C., Eksell, P., Widstrom, C., Berger, M., Holm, R. and Johnston, C. (2003) Scintigraphy of the sacroiliac joint region in asymptomatic riding horses: scintigraphic appearance and evaluation of results. *Vet. Radiol. Ultrasound.* **44**, 699-706.

Erichsen, C., Eksell, P., Roethlisberger Holm, K., Lord, P. and Johnston, C. (2004) Relationship between scintigraphic and radiographic evaluations of spinous processes in the thoracolumbar spine in riding horses without clinical signs of back problems. *Equine Vet. J.* **36**, 458-465.

Gillen, A., Dyson, S. and Murray, R. (2009) Nuclear scintigraphic assessment of the thoracolumbar synovial intervertebral articulations. *Equine Vet. J.* **41**, 534-540.

Girodroux, M., Dyson, S. and Murray, R. (2009) Osteoarthritis of the thoracolumbar synovial intervertebral articulations: clinical and radiographic features in 77 horses with poor performance and back pain. *Equine Vet. J.* **41**, 130-138.

Gómez Álvarez, C.B., Wennerstrand, J., Bobbert, M.F., Lamers, L., Johnston, C., Back, W. and van Weeren, P.R. (2007) The effect of induced forelimb lameness on thoracolumbar kinematics during treadmill locomotion. *Equine Vet. J.* **39**, 197-201.

Gómez Álvarez, C.B., Wennerstrand, J., Bobbert, M.F., Lamers, L., Johnston, C., Back, W. and van Weeren, P.R. (2008) The effect of induced hindlimb lameness on thoracolumbar kinematics during treadmill locomotion. *Equine Vet. J.* **40**, 147-152.

Gorgas, D., Luder, P., Lang, J., Doherr, M., Ueltschi, G. and Kircher, P. (2009) Scintigraphic and radiographic appearance of the sacroiliac region in horses with gait abnormalities or poor performance. *Vet. Radiol. Ultrasound.* **50**, 208-214.

Gough, M.R., Mayhew, I.G. and Munroe, G.A. (2002) Diffusion of mepivacaine between adjacent synovial structures in the horse. Part 1: forelimb, foot and carpus. *Equine Vet. J.* **34**, 80-84.

Henson, F.M., Lamas, L., Knezevic, S. and Jeffcott, L.B. (2007) Ultrasonographic evaluation of the supraspinous ligament in a series of ridden and unridden horses and horses with unrelated back pathology. *BMC Vet. Res.* **3**, 3.

Hornof, W. and Koblik, P. (1991) The scintigraphic detection of muscle damage. *Equine Vet. J.* **23**, 327-328.

Keegan, K.G., Pai, P.F., Wilson, D.A. and Smith, B. (2001) Signal decomposition method of evaluating head movement to measure induced forelimb lameness in horses trotting on a treadmill. *Equine Vet. J.* **33**, 446-451.

Kramer, J., Keegan, K.G., Kelmer, G. and Wilson, D.A. (2004) Objective determination of pelvic movement during hind limb lameness and pelvic height differences. *Am. J. Vet. Res.* **65**, 741-747.

Landman, M., de Blaauw, J., van Weeren, P.R. and Hofland, L. (2004) Field study of the prevalence of lameness in horses with back problems. *Vet. Rec.* **155**, 165-168.

Licka, T., Frey, A. and Peham, C. (2009) Electromyographic activity of the longissimus dorsi muscles in horses when walking on a treadmill. *Vet. J.* **180**, 71-76.

Marneris, D. and Dyson, S. (2014) Clinical features, diagnostic imaging findings and concurrent injuries in 71 sports horses with suspensory branch injuries. *Equine Vet. Educ.* **26**, 312-321.

McCue, M.E., Valberg, S.J., Lucio, M. and Mickelson, J.R. (2008) Glycogen synthase 1 (*GYS1*) mutation in diverse breeds with polysaccharide storage myopathy. *J. Vet. Intern. Med.* **5**, 1228-1233.

Meehan, L., Dyson, S. and Murray, R. (2009) Radiographic and scintigraphic evaluation of spondylosis in the equine thoracolumbar spine: a retrospective study. *Equine Vet. J.* **41**, 800-807.

Murray, R., Dyson, S., Weekes, J., Short, C. and Branch, M. (2004) Nuclear scintigraphic evaluation of the distal tarsal region in normal horses. *Vet. Radiol. Ultrasound.* **45**, 345-351.

Continued on page 409

THIS IS **MY HORSE**™

Ike was 17 the night we won our third consecutive Hunter Derby Finals, but he felt like he was 6 years old again! I get a little emotional thinking about it because he tries so hard for me. I know how lucky I am to have him in my life, so I'm particular about everything for him, including his nutrition. His diet makes a big difference in how he feels and performs— that's why I trust Platinum.

Liza Boyd

LIZA BOYD
3-time USHJA International Hunter Derby Champion,
3-time USEF Emerson Burr Trophy Winner,
Platinum Performance® Client since 2013

Liza Boyd is a sponsored endorsee and actual client.

Brunello

BRUNELLO
2-time USEF National Horse of the Year

© Shawn McMillen

THIS IS **MY PLATINUM**

Liza supplements Brunello with **Platinum Paks®** containing **Platinum Performance® CJ**, **Platinum Gastric Support,®** **Platinum Balance,®** and **Vitamin E**.

PLATINUM PERFORMANCE® CJ SUPPORTS:

- Joint Health
- Hoof Health
- Skin & Coat Health
- Performance & Recovery
- Digestive Health
- Bone & Tendon Health

PLATINUM GASTRIC SUPPORT® for Stomach & Hindgut Health
PLATINUM BALANCE® Daily Probiotic for Digestive Health
VITAMIN E® Antioxidant Support for Healthy Cells

PLATINUM PERFORMANCE®

877-586-3362
www.**PlatinumPerformance**.com

To find the right Platinum Performance® solution, and to learn about the science behind the supplements, call or visit our website, or speak with your equine veterinarian.

Review Article

Equine tapeworm infections: Disease, diagnosis and control

M. K. Nielsen

Department of Veterinary Science, M.H. Gluck Equine Research Center, University of Kentucky, Lexington, USA. Corresponding author email: martin.nielsen@uky.edu

Keywords: horse; tapeworm; diagnosis; colic; control

Summary

Equine tapeworm infection has gained increasing attention over the past few decades and a number of research studies have already been published. These focus primarily on the most common of the 3 tapeworm species, *Anoplocephala perfoliata*, although some new information has also been generated for the other two species, *Anoplocephala magna* and *Anoplocephaloides mamillana*. The preponderance of research studies have focused on development and validation of diagnostic techniques for tapeworm detection and the role of these parasites in equine gastrointestinal disease. Several diagnostic techniques have been found useful for diagnosis of *A. perfoliata* but each has its strengths and weaknesses. Egg counting techniques have been modified to achieve acceptable to good diagnostic performance but the trade-off is often a more time-consuming method. Validation studies indicate that these methods can reliably detect tapeworm burdens above 10 worms. Several enzyme-linked immunosorbent assays (ELISAs) have been developed and made commercially available. These can generate useful information about tapeworm exposure on the herd level but are less reliable for individual diagnosis. Unfortunately, none of the available diagnostic techniques are useful for evaluating anthelmintic treatment efficacy. Coproantigen testing may find use as a future diagnostic modality but further characterisation is required. The large body of scientific evidence supports an association between *A. perfoliata* infection and certain types of equine colic, although some discrepancy exists between studies. Tapeworm surveillance and control should be considered as part of the overall parasite control strategy. When properly used, the currently available diagnostic tools can guide the veterinarian to make strategic decisions regarding tapeworm control.

Introduction

Anoplocephalid cestodes of horses occur worldwide and are increasingly recognised as potential causes of various forms of colic. Three species are known to infect the horse; *Anoplocephala perfoliata*, *A. magna* and *Anoplocephaloides mamillana* (formerly known as *Paranoplocephala mamillana*). Of these, *A. perfoliata* is by far the most prevalent and the other two species are reported only sporadically (Borgsteede and van Beek 1998; Meana *et al.* 2005; Rehbein *et al.* 2013). Equine tapeworms have been the focus of numerous research studies in recent years. The majority of these have reported the development and evaluation of diagnostic tools for detection of tapeworm infection or investigated the role of these parasites in equine disease.

All anoplocephalid tapeworms utilise intermediate hosts, comprising numerous species of oribatid mites (Denegri 1993) ingested accidentally by horses during grazing. With some species variation, oribatid mites appear to prefer certain habitats over others and exhibit peak abundance at specific times during the year (van Nieuwenhuizen *et al.* 1994). This may partially explain geographic differences in prevalence. *Anoplocephala perfoliata*, however, is highly prevalent in numerous countries on several continents, representing a wide range of possible habitats (Bain and Kelly 1977; Slocombe 1979; Lyons *et al.* 1983, 2000; Reinemeyer *et al.* 1984; Owen *et al.* 1988; Benton and Lyons 1994; Fogarty *et al.* 1994; Bucknell *et al.* 1995; Borgsteede and van Beek 1996; Hinney *et al.* 2011; Rehbein *et al.* 2013; Tomczuk *et al.* 2015). A Spanish study has demonstrated seasonal variation for both *A. perfoliata* and *A. magna* (Meana *et al.* 2005). For both parasites, most patent infections are observed in the second half of the year, reflecting infections acquired and established over the preceding grazing season. The same observation has been made for *A. perfoliata* in Poland and Sweden where the highest worm counts were found in horses slaughtered during the fourth quarter of the year (Nilsson *et al.* 1995; Tomczuk *et al.* 2015). This suggests that these cestodes are adapted to a life cycle involving one parasite generation per year. Such epidemiological information is not available for *A. mamillana,* largely due to its rare and sporadic occurrence. Some evidence suggests that *A. perfoliata* used to be much less dominant decades ago and that *A. magna* was much more common than it is today (Tolliver *et al.* 1987; Chapman *et al.* 2002). The reasons for this possible change are not fully understood, although some researchers have suggested that frequent treatments with ivermectin may have caused an increase in prevalence and abundance of *A. perfoliata* (Geering and Johnson 1990; French *et al.* 1994).

Like the majority of mammalian tapeworms, both *A. mamillana* and *A. magna* reside in the small intestine, whereas *A. perfoliata* differs by its preference for the area around the ileocaecal junction in the caecum. Another important difference between these species is that only *A. perfoliata* has been reported to cause pathological reactions around their attachment site (**Fig 1**), characterised by hyperaemia, mucosal thickening and necrotic ulcers (Pearson *et al.* 1993; Nilsson *et al.* 1995; Williamson *et al.* 1997; Kjær *et al.* 2007). This may explain why only this species has been associated with clinical disease in horses.

The aim of this article is to review the current scientific literature on equine tapeworms, with the major focus on *A. perfoliata*. The purpose is not to provide an exhaustive scientific review but rather focus on information relevant to the equine veterinary practitioner tasked with making

Fig 1: Adult specimens of* Anoplocephala perfoliata *attached to the caecal mucosal membrane around the ileocecal junction in an adult horse.

decisions and recommendations regarding tapeworm control for their clients. Therefore, special attention will be given to diagnostic methods currently available and putative associations between tapeworms and disease.

Tapeworm diagnostics

A wide variety of techniques have been developed for diagnosing equine tapeworm infection and several of these have been made commercially available to veterinary practitioners. Thus, veterinary practitioners have several validated diagnostic options from which to choose and the available diagnostic techniques are presented and discussed in this article.

Coprological techniques

The traditional parasitological approach for diagnosing an intestinal helminth is a coprological analysis aimed at identifying tapeworm eggs (**Fig 2**). This has been attempted with several different approaches: sedimentation, qualitative flotation, faecal egg counting techniques and various combinations of these principles. It has often been argued that coprological tapeworm diagnosis is challenged by the egg shedding dynamic and distribution of eggs over the faecal matter because the eggs tend to be released in clumps contained within a tapeworm segment (Slocombe 1979; Beroza *et al.* 1986). This appears to be a plausible explanation but it is not supported by research evidence. Diagnostic parameters generated in studies validating a number of different coprological techniques are presented in **Table 1**. Only a few studies generated data on diagnostic specificity but these were in the 98–100% range (Proudman and Edwards 1992; Nilsson *et al.* 1995; Skotarek *et al.* 2010) indicating a low false-positive rate. The lowest diagnostic sensitivities (2.8 and 8%) were achieved with standard versions of the McMaster technique (Meana *et al.* 1998; Tomczuk *et al.* 2014). This has led researchers to experiment with various modifications attempting to optimise the method for tapeworm detection. Several of these modifications include increasing the amount of faeces used from the typical 3–5 to 30–50 g but these methods are generally considered more laborious and time consuming. It is interesting to note in **Table 1** that while the diagnostic sensitivity of techniques using a McMaster chamber seemed to improve with increased amounts of faeces, the opposite appeared to be the case for the Wisconsin-based techniques (cover slip method), where the highest sensitivity was achieved with 5 g. However, these values for diagnostic sensitivity and specificity should be interpreted with great caution as they are strongly influenced by the prevalence of the target organism in each study, which complicates a direct comparison. **Table 1** also suggests that centrifugation flotation greatly increases diagnostic sensitivity over methods based on passive flotation. One study found that a sucrose solution (specific gravity (SG) = 1.26) generated significantly higher *Anoplocephala* egg counts than zinc sulphate (SG = 1.30) and sodium chloride (SG = 1.20) (Rehbein *et al.* 2011), so it is possible that the choice of flotation medium can affect diagnostic performance as well but this is not yet fully investigated. The FLOTAC technique has been developed as a highly sensitive parasite egg counting technique with low variability (Cringoli *et al.* 2010) and one study found it to be more sensitive for diagnosing equine tapeworm infection than 2 other techniques (Chlastakova *et al.* 2009) but more work is needed to fully evaluate the FLOTAC technique for this application. One study has documented that the proportion of mature *A. perfoliata*

Fig 2: Eggs of* Anoplocephala perfoliata *with the characteristic pyriform apparatus (oncosphere) containing the hexacanth embryo. a) Illustrates the typical crest seen when focusing on the external features of the egg, while the image on the right (b) represents the D-shaped egg most often observed in faecal samples.

TABLE 1: Summary of validation studies conducted with various coprological egg detection techniques for diagnosing infection with *Anoplocephala perfoliata*

Technique	Amount (g)	Modification	Sensitivity (%)	Specificity (%)	Reference
Sedimentation	50	–	22.5	–	Williamson *et al.* (1998)
	50 (25)*	–	8.3	–	Tomczuk *et al.* (2014)
Flotation	5	–	16.7	–	Tomczuk *et al.* (2014)
	5	–	37.5	–	Williamson *et al.* (1998)
Sedimentation/flotation	50 (25)*	–	25	–	Williamson *et al.* (1998)
	50	–	58.3	–	Tomczuk *et al.* (2014)
McMaster†	5	Passive flotation	8	–	Meana *et al.* (1998)
	2	Passive flotation	2.8	–	Tomczuk *et al.* (2014)
	30	Centrifugation	23	100	Nilsson *et al.* (1995)
	40 (20)*	Centrifugation	42	–	Meana *et al.* (1998)
	40	Centrifugation	61	98	Proudman and Edwards (1992)
Wisconsin‡	5	Centrifugation	62	–	Slocombe (2004)
	10	Centrifugation	54	100	Skotarek *et al.* (2010)
	30	Centrifugation	46	–	Kjær *et al.* (2007)
	40 (20)*	Passive flotation	38	–	Meana *et al.* (1998)

*The initial amount of faeces weighed were divided between 2 techniques. †Includes all methods involving counting eggs in a McMaster chamber. ‡Includes all methods involving capturing eggs underneath a glass cover slip and counting them on a microscope slide.

tapeworms is highest during the first quarter of the year and that this was statistically associated with higher tapeworm egg counts and a larger proportion of egg count positive horses (Tomczuk *et al.* 2015). These authors also reported diagnostic sensitivities ranging from a low of 40% in the second quarter to 75% in the first quarter of the year, suggesting that optimal time for tapeworm egg detection would be winter and early spring in a temperate climate like in Poland. The highest reported diagnostic sensitivity of the coprological methods presented in **Table 1** is just above 60%, which illustrates a general problem with false-negative samples. However, it has been found that tapeworm burdens of 20 worms are about 90% likely to generate a positive coprological examination (Proudman and Edwards 1992; Meana *et al.* 1998; Kjær *et al.* 2007). This suggests that coprology can reliably detect the larger burdens more likely to cause disease. Overall, however, tapeworm egg counts do not appear to correlate with worm numbers (Proudman and Edwards 1992; Nilsson *et al.* 1995; Meana *et al.* 1998). One study reported that diagnostic sensitivity of the Cornell-Wisconsin egg counting technique was increased from 62 to 100% by examining samples 18 h after a tapeworm treatment (Slocombe 2004) and this has been supported by other studies reporting higher *Anoplocephala* egg counts and a higher percentage of positive samples 24 h post treatment (Hearn and Hearn 1995; Sanada *et al.* 2009; Elsener and Villeneuve 2011). Presumably, this is due to segments from dead tapeworms disintegrating within the intestine and releasing eggs into the intestinal lumen. This may be useful for the veterinary practitioner or referral clinician in clinical cases where tapeworm infection is suspected. The horse can be dewormed as part of the treatment plan and a faecal sample analysed 18–24 h post treatment to verify or reject the suspicion. Of further interest, one study recently reported that morphometric measures can be used to reliably differentiate between eggs of *A. perfoliata* and *A. magna*. All examined *A. perfoliata* eggs had an oncosphere diameter above 15 μm, whereas 97% of *A. magna* eggs were below this value (Bohorquez *et al.* 2014). This information could be of value to the practitioner since diagnosing *A. magna* would not have the same health implications as *A. perfoliata*. See **Fig 2** for an illustration of the oncosphere.

In summary, faecal egg counting techniques can be employed for diagnosing equine tapeworm infection and with the modifications described above, good diagnostic performance levels can be achieved. However, as a general rule, egg counting techniques optimised for tapeworm detection are more time-consuming than regular techniques and most often employ centrifugation in order to achieve this enhanced diagnostic performance.

Enzyme-linked immunosorbent assays (ELISAs)

Table 2 summarises results on diagnostic sensitivity and specificity from validation studies performed with various ELISAs. In the 1990s, 2 enzyme-linked immunosorbent assays (ELISAs) were developed for equine tapeworm diagnosis. One detected antibodies to a crude scolex antigen and a positive correlation to *A. perfoliata* worm counts was observed (Höglund *et al.* 1995). This assay was found to generate useful data on tapeworm exposure in cohorts of

TABLE 2: Data on diagnostic sensitivity and specificity for different enzyme-linked immunosorbent assays (ELISAs) developed for detection of *Anoplocephala perfoliata* infection in horses

Technique	Sensitivity (%)	Specificity (%)	Reference
Serum IgG(T)*	68	95	Proudman and Trees (1996a)
	68	71	Kjær *et al.* (2007)
	70	78	Skotarek *et al.* (2010)
	78	80	Pittaway *et al.* (2014)
Serum IgE*	44	82	Pittaway *et al.* (2014)
Saliva IgG(T)*	83	85	Unpublished data†
Coproantigen capture	74	92	Skotarek *et al.* (2010)

*These assays were all based on detecting antibodies to the same 12/13 kDa E/S antigens. †Personal communication by C. Austin (Austin Davis Biologics Ltd).

horses followed over the course of a year (Höglund *et al.* 1995, 1998) but data on diagnostic sensitivity and specificity were not generated and the assay was not made commercially available. The other ELISA was developed to detect serum antibodies to excretory/secretory (E/S) antigens and was reported with a diagnostic sensitivity and specificity of 68 and 95%, respectively (Proudman and Trees 1996a). The latter assay has been made commercially available at the Diagnosteq Laboratory in Liverpool, UK and a later modification of the same assay has been developed and made commercially available by Rossdales Veterinary Surgeons (Beaufort Cottage Laboratories, Newmarket, UK). This assay has been validated with a statistically significant positive correlation with tapeworm burdens with correlation coefficients in the range of 0.54–0.63 (Proudman and Trees 1996b; Kjær *et al.* 2007). It can generate information about the level of *Anoplocephala*-exposure in herds of horses, which is a useful aid in determining the timing and number of tapeworm-directed treatments on a given farm. This has been illustrated by an epidemiological study documenting that ELISA optic density (OD) responses follow a triphasic age-dependency pattern with horses aged 0.5–2 years exhibiting peak values followed by a decline in the 3–15 year-old range and increasing again in horses 16 years and older (Proudman *et al.* 1997). However, the assay is not regarded reliable for diagnosing infection at the individual horse level (Proudman and Trees 1996b; Kjær *et al.* 2007). There are several reasons for this. First of all, depending on their pretreatment OD value, horses can remain antibody-positive for up to 5 months following anticestodal treatment (Proudman and Trees 1996b; Abbott *et al.* 2008). Further, other studies have reported high levels of variability with ELISA results (Kjær *et al.* 2007; Back *et al.* 2013) and high antibody levels in tapeworm negative horses leading to a high proportion of false-positive results (Kjær *et al.* 2007). Finally, research performed in Spain has indicated that the assay may cross-react with E/S antigens from the less common small intestinal tapeworm *A. magna* (Bohorquez *et al.* 2012). Taken together, these findings suggest that the tapeworm antibody ELISA can overestimate the occurrence of the parasite, and results should be interpreted with caution.

One study attempted to develop an IgE-based antibody ELISA and evaluated both systemic antibody responses as well as detection of IgE-positive cells in the caecal mucosa (Pittaway *et al.* 2014). While *A. perfoliata*-specific antibodies were detected in the supernatant of caecal explant cultures from infected animals, the serum IgE ELISA was found to perform at a level substantially below the IgG(T) serum ELISA (**Table 2**) and is unlikely to be pursued further. A very recent addition to the palette of commercially available diagnostic assays for the equine tapeworm is a saliva antibody ELISA (EquiSal)[1] which measures antibodies to the same E/S antigens used in the serum ELISA described in the previous paragraph. The manufacturers of the salivary assay advertise diagnostic sensitivity and specificity both above 80% (**Table 2**) but this information has yet to be published in the peer reviewed literature. If verified, this suggests that the salivary ELISA could be performing at, or above, the level of the serum ELISA. However, given that the assay targets antibodies to the same antigens as used for the serum ELISA, it remains likely that the salivary assay will be subject to several of the same limitations in diagnostic performance as described for the serum ELISA above.

A coproantigen ELISA appears promising as a future diagnostic method (Kania and Reinemeyer 2005). This assay detects antigens released by worms into the intestinal contents and these may be distributed more evenly than the clustered eggs. This assay has been validated with 74% sensitivity and 92% specificity (Skotarek *et al.* 2010) (**Table 2**) which is at the level of, or better than, other validated tapeworm assays. Despite these encouraging findings, no further studies have been conducted with this assay.

Polymerase chain reaction

A polymerase chain reaction (PCR) assay has been developed for the detection of *A. perfoliata* DNA in faecal samples (Drögemüller *et al.* 2004). A PCR-based technique would be expected to perform with high diagnostic sensitivity but one field study demonstrated a performance only slightly better than detection of eggs with the modified egg counting technique (Traversa *et al.* 2008). This is below expectations for a PCR-based assay and may explain why this technique has not found wider use. More recently, a multiplex PCR assay was developed to simultaneously detect DNA from all three equine anoplocephalid parasites with a detection limit of 50 eggs per sample (Bohorquez *et al.* 2015). Although this technique appears promising, the diagnostic sensitivity may need improvement for such an assay to generate useful results in the field. One possible explanation for the apparent lack of diagnostic performance of both equine tapeworm PCR assays could be the choice of DNA extraction technique which in both cases is based on direct extraction from the faeces in a relatively small volume of sample. Experience with the egg counting techniques described in the previous section has clearly illustrated the importance of processing larger amounts of faeces in order to achieve good diagnostic performance and work with strongyle eggs has shown that faecal matter can negatively influence the efficiency of the PCR reaction (Harmon *et al.* 2006). Thus, it appears that the performance of these PCR assays could be significantly improved by optimising the DNA extraction technique.

Tapeworms and disease

In recent years, *A. perfoliata* has received growing attention as a potential pathogen which causes various types of colic in horses. Several case reports have reported an association between tapeworms and ileocaecal, caecocolic and caecocecal intussusception as well as caecal and ileal rupture (Foerner *et al.* 1980; Barclay *et al.* 1982; Beroza *et al.* 1986; Owen *et al.* 1989; Ryu *et al.* 2001). Although such disease associations are interesting, they should be interpreted cautiously because they do not establish a causal relationship (Holmes and Ramey 2007). Case–control studies represent a more solid approach for investigating associations between disease and various infectious agents. **Table 3** summarises the large body of evidence generated by case–control studies evaluating the role of *A. perfoliata* in equine colic. The table documents significantly increased odds ratios for tapeworms being present in colic cases vs. controls for the large majority of the studies conducted. In addition to the case–control studies, two other studies have associated pyrantel treatment with a lower colic incidence on horse farms with histories of frequent ivermectin treatment (Reeves *et al.* 1996; Little and Blikslager 2002). The cestocidal

TABLE 3: Summary of case–control studies evaluating the association between colic and *Anoplocephala perfoliata* in horses

Colic definition	Odds ratio	Reference
Tapeworm eggs in faeces		
Ileocaecal colic	3.45	Proudman and Edwards (1993)
All types	16.4	Back *et al.* (2013)
Ileal impaction	34	Proudman *et al.* (1998)
All types*	23.9	Proudman and Holdstock (2000)
All types	Nonsignificant	Trotz-Williams *et al.* (2008)
Tapeworm serum antibody ELISA		
Spasmodic colic	15.46 (OD>0.6)	Proudman *et al.* (1998)
Ileal impaction	44 (OD>0.2)	Proudman *et al.* (1998)
All types*	13.7 (OD>0.2)	Proudman and Holdstock (2000)
Ileocaecal colic	29.2 (OD>0.2)†	Boswinkel and Sloet van Oldruitenborgh-Oosterbaan (2007)
All types	Nonsignificant	Back *et al.* (2013)
All types	Nonsignificant	Trotz-Williams *et al.* (2008)

Data is organised by diagnostic method used to diagnose tapeworm infection (detection of eggs in faeces or detection of antibodies in serum). It presents the odds ratio for horses with colic testing positive for *A. perfoliata* in each study. For the studies using the serum antibody ELISA, the table includes the optic density (OD) cut-off value for diagnosing infection.
*Four of 15 cases confirmed as ileal impactions. †Odds ratio calculated by the author of this article based on data presented in the referenced article.

activity of pyrantel salts suggests that the lowered incidence of colics could be due to a reduction of tapeworm burdens. It is worth noting that several of the studies referenced in **Table 3** specifically document an association between tapeworms and ileocecal colic, whereas the few studies that failed to find an association used much broader case definitions. Colic is a symptom complex with a complicated multifactorial aetiology and *A. perfoliata* is likely to be associated with a subset of the underlying pathologies, such as the ileocecal colic types, whereas the parasite is less likely to be associated with several other conditions also leading to colic. One finding worth noting from the Canadian epidemiological study reporting no association between colic and tapeworm antibody OD values (Trotz-Williams *et al.* 2008), was a significant correlation between OD values and access to pasture. Although it is not surprising that horses on pasture have greater exposure to tapeworm infections than stabled horses, this strongly suggests that access to pasture could be a confounding factor in studies using anti-tapeworm antibody ELISA OD values for evaluating the pathological role of tapeworms.

It is important for a practitioner to recognise that while the large body of evidence documents that horses with ileocaecal colic are statistically more likely to harbour *A. perfoliata* infection, the actual risk of disease associated with this parasite has not been quantified in the general horse population. A couple of reasons for this are that a large majority of tapeworm infections do not lead to any type of disease or discomfort in the horses and that the general incidence of colic in a given horse population is relatively low. This makes it very difficult to assess the risk of colic in infected vs. noninfected horses in a longitudinal study design.

It is worth noting that studies utilising experimental infections to evaluate the causal relationship between *A. perfoliata* and intestinal disease have not been performed. Such studies could provide important insights. Abattoir surveys have related tapeworm burdens to the degree of local pathological damage (Nilsson *et al.* 1995; Williamson *et al.* 1997; Kjær *et al.* 2007) but horses admitted for slaughter were not reported as showing clinical signs. It is clear that although *A. perfoliata* is prevalent in horse establishments more evidence is needed to illuminate the circumstances under which this parasite causes disease.

Anthelmintic treatment

Two anthelmintics are available for treatment of equine tapeworms; pyrantel pamoate and praziquantel. Initial work with pyrantel pamoate paste at the dosage labelled for nematode control (6.6 mg base/kg) indicated good activity against *A. perfoliata* with reductions above 80% (Lyons *et al.* 1989). This is worth noting as it is often wrongly assumed that pyrantel salts given at the nematocidal dosage do not have any efficacy against equine tapeworms. However, research has shown that by increasing the pyrantel dosage to 13.2 mg base/kg, the efficacy against *A. perfoliata* was increased to about 95% (Marchiondo *et al.* 2006; Reinemeyer *et al.* 2006). Thus, 13.2 mg base/kg was chosen as the labelled dosage for equine tapeworm treatment. Praziquantel was introduced for equine treatment in the late 1990s and is mostly marketed in combination with ivermectin or moxidectin, although a formulation with praziquantel-only is available in some countries. Formulations of equine oral paste products containing praziquantel and given at the 1.0 mg/kg bwt dose rate have confirmed high efficacy against all three equine anoplocephalid parasite species (Rehbein *et al.* 2007; Slocombe *et al.* 2007).

To date, anthelmintic resistance has not been reported in any of the equine tapeworms. It is possible that resistance has not yet developed which could be explained by the fact that products with label claims for these parasites have not been available for as long as some of the nematocidal anthelmintics. Another plausible reason is that none of the currently available tapeworm diagnostics have been found useful for evaluating treatment efficacy. In general, the egg counting techniques suffer from low to moderate sensitivities (**Table 1**) which will cause problems detecting lower egg numbers possibly present post treatment. The antibody detection techniques, on the other hand, suffer from low specificity which means that samples can remain positive for

several months following anthelmintic treatment. Thus, in general, the currently available diagnostic techniques are likely to either overestimate or largely underestimate anthelmintic efficacy if employed in some sort of a tapeworm reduction assay. Work performed in sheep indicates that a coproantigen reduction test was reliable for assessing the efficacy of triclabendazole and closantel against the liver fluke *Fasciola hepatica* (Gordon *et al.* 2012) and it appears plausible that the coproantigen ELISA developed and validated for diagnosing *A. perfoliata* (Skotarek *et al.* 2010) could be employed for this purpose. However, this has yet to be scientifically evaluated.

Discussion

Incorporating some element of tapeworm monitoring into a surveillance-based parasite control strategy has proven to be somewhat challenging (Nielsen *et al.* 2014). The available body of evidence suggests that *A. perfoliata* is common on different continents and in different climates around the world but that the prevalence can vary in the range of 20–80% (Bain and Kelly 1977; Slocombe 1979; Lyons *et al.* 1983, 2000; Reinemeyer *et al.* 1984; Owen *et al.* 1988; Benton and Lyons 1994; Fogarty *et al.* 1994; Bucknell *et al.* 1995; Borgsteede and van Beek 1996; Hinney *et al.* 2011; Rehbein *et al.* 2013). Thus, the parasite should be expected to be present in most equine establishments but not necessarily in every single horse. Therefore, it is theoretically feasible to target only the infected animals in a selective treatment approach similar to what is recommended for strongyle control (Kaplan and Nielsen 2010) but the available evidence suggests that only the laborious and time-consuming coprological techniques (**Table 1**) are suitable for this purpose. Thus, while a proportion of horses in a given herd may not necessarily need a cestocidal treatment, it appears to be a reasonable precautionary procedure to treat these rather than leave them untreated. At the same time, it is not a feasible goal to completely prevent tapeworm egg shedding throughout the grazing season either. Indeed, treating more frequently than once or twice a year should be justified by clinical or diagnostic evidence of a tapeworm problem and should be carried out with caution as anthelmintic resistance is just as biologically feasible in equine tapeworms as has been experienced with strongyles and ascarids in horses. Therefore, it is a pragmatic solution to include one or 2 targeted tapeworm treatments delivered to all horses present on a given farm and this is outlined in recently published parasite control guidelines (Nielsen *et al.* 2013). The timing of such treatments will depend on the parasite transmission dynamics on the given equine operation but in temperate climates, tapeworm burdens generally accumulate over the course of the grazing season (Meana *et al.* 2005), so the autumn or early winter appears to be an appropriate time for treatments. However, this may be substantially different for warmer climates where the summers may be too dry and hot for tapeworm transmission.

Consequently, some form of tapeworm surveillance can provide helpful information to the practitioners and their clients. A practitioner is faced with a number of decisions regarding tapeworm control on a given horse farm. These include when to treat, how many times to treat within a calendar year and at which age to start considering including a tapeworm treatment in foals, weanlings and yearlings. One of the available serum or saliva ELISAs (**Table 2**) can generate information about the relative level of tapeworm exposure which will help the practitioner reaching an informed evidence-based decision. The coprological techniques for tapeworm egg detection may be too laborious and time-consuming for large scale surveillance in veterinary practice but they remain very useful diagnostic techniques for usage in individual horses because they can reliably detect the larger tapeworm burdens (>20 worms) more likely to cause clinical issues.

Among the equine helminth parasites, *A. perfoliata* is the best characterised as a pathogen involved with clinical disease as the number of well performed case–control studies greatly exceeds any other equine gastrointestinal parasite (**Table 3**). A likely reason for the general lack of similar data for equine nematodes is the absence of useful diagnostic tests targeting relevant species and stages, although recent progress has been made (Andersen *et al.* 2013). In the case of *A. perfoliata,* the work conducted during the 1990s focused on evaluating and refining coprological methods as well as developing novel serological assays has enabled the case–control studies referenced in this article. Thus, it is important to recognise that the relative absence of similar data for other common equine parasites does not necessarily mean that they are less pathogenic. The pathogenic role of *A. perfoliata* just happens to be more thoroughly evaluated at this point.

In summary, a good amount of useful scientific evidence regarding equine tapeworms has been produced in the last couple of decades but several issues still remain to be resolved. Despite several diagnostic techniques being validated and available, none of these appear to be useful for evaluating anthelmintic treatment efficacy. Thus, the quest for novel and improved diagnostic methods should be continued. Further, ileocaecal colic has been statistically associated with *A. perfoliata* infection in several case–control studies but the actual risk of colic in infected horses has not been quantified. Consequently, more epidemiological studies are needed to elucidate the circumstances under which *A. perfoliata* causes colic.

Author's declaration of interests

The author has no conflict of interests to declare.

Ethical animal research

Ethical review not applicable for this review article.

Source of funding

This article was not financially supported.

Acknowledgements

Ms Jennifer Bellaw and Ms Holli Gravatte are warmly acknowledged for their assistance with the figures. Dr Craig Reinemeyer provided valuable help reviewing the manuscript before submission.

Manufacturer's address

[1]Austin Davis Biologics Ltd., Great Addington, UK.

References

Abbott, J.B., Mellor, D.J., Barrett, E.J., Proudman, C.J. and Love, S. (2008) Serological changes observed in horses infected with *Anoplocephala perfoliata* after treatment with praziquantel and natural reinfection. *Vet. Rec.* **162**, 50-53.

Andersen, U.V., Howe, D.H., Olsen, S.N. and Nielsen, M.K. (2013) Recent advances in diagnosing pathogenic equine gastrointestinal helminths: the challenge of prepatent detection. *Vet. Parasitol.* **192**, 1-9.

Back, H., Nyman, A. and Lind, E.O. (2013) The association between *Anoplocephala perfoliata* and colic in Swedish horses – A case control study. *Vet. Parasitol.* **197**, 580-585.

Bain, S.A. and Kelly, J.D. (1977) Prevalence and pathogenicity of *Anoplocephala perfoliata* in a horse population in South Auckland. *N. Z. Vet. J.* **25**, 27-28.

Barclay, W.P., Phillips, T.N. and Foerner, J.J. (1982) Intussusception associated with *Anoplocephala perfoliata* infection in five horses. *J. Am. Vet. Med. Ass.* **180**, 752-753.

Benton, R.E. and Lyons, E.T. (1994) Survey in central Kentucky for prevalence of *Anoplocephala perfoliata* in horses at necropsy in 1992. *Vet. Parasitol.* **55**, 81-86.

Beroza, G.A., Marcus, L.C., Williams, R. and Bauer, S.M. (1986). Laboratory diagnosis of *Anoplocephala perfoliata* infection in horses. *Proc. Am. Ass. Equine Practnrs.* **32**, 435-439.

Bohorquez, A., Meana, A. and Luzon, M. (2012) Differential diagnosis of equine cestodosis based on E/S and somatic *Anoplocephala perfoliata* and *Anoplocephala magna* antigens. *Vet. Parasitol.* **190**, 87-94.

Bohorquez, A., Meana, A., Pato, N.F. and Luzon, M. (2014) Coprologically diagnosing *Anoplocephala perfoliata* in the presence of *A. magna*. *Vet. Parasitol.* **204**, 396-401.

Bohorquez, A., Luzon, M., Hernandez, R.M. and Meana, A. (2015) New multiplex PCR method for the simultaneous diagnosis of the three known species of equine tapeworm. *Vet. Parasitol.* **207**, 56-63.

Borgsteede, F.H. and van Beek, G. (1996) Data on the prevalence of tapeworm infestations in horses in the Netherlands. *Vet. Quart.* **18**, 110-112.

Borgsteede, F.H.M. and van Beek, G. (1998) Parasites of stomach and small intestine of 70 horses slaughtered in the Netherlands. *Vet. Quart.* **20**, 31-34.

Boswinkel, M. and Sloet van Oldruitenborgh-Oosterbaan, M.M. (2007) Correlation between colic and antibody levels against *Anoplocephala perfoliata* in horses in the Netherlands. *Tijdschr. Diergeneeskd.* **132**, 508-512.

Bucknell, D.G., Gasser, R.B. and Beveridge, I. (1995) The prevalence and epidemiology of gastrointestinal parasites of horses in Victoria. *Int. J. Parasitol.* **25**, 711-724.

Chapman, M.R., French, D.D. and Klei, T.R. (2002) Gastrointestinal helminths of ponies in Louisiana: a comparison of species currently prevalent with those present 20 years ago. *J. Parasitol.* **88**, 1130-1134.

Chlastakova, I., Vavrouchova, E., Kamler, M., Bodecek, S. and Koudela, B. (2009) Comparison of coprological and molecular techniques for the diagnosis of *Anoplocephala perfoliata* infection of the horse. In: *World Association for the Advancement of Veterinary Parasitology Congress*. Calgary, Canada, Abstracts. p 161.

Cringoli, G., Rinaldi, L., Maurelli, M.P. and Utzinger, J. (2010) FLOTAC: new multivalent techniques for qualitative and quantitative copromicroscopic diagnosis of parasites in animals and humans. *Nat. Protoc.* **5**, 503-515.

Denegri, G.M. (1993) Review of oribatid mites as intermediate hosts of tapeworms of the Anoplocephalidae. *Exp. Appl. Acarol.* **17**, 567-580.

Drögemüller, M., Beelitz, P., Pfister, K., Schnieder, T. and von Samson-Himmelstjerna, G. (2004) Amplification of ribosomal DNA of Anoplocephalidae: *Anoplocephala perfoliata* diagnosis by PCR as a possible alternative to coprological methods. *Vet. Parasitol.* **124**, 205-215.

Elsener, J. and Villeneuve, A. (2011) Does examination of fecal samples 24 hours after cestocide treatment increase the sensitivity of *Anoplocephala* spp. detection in naturally infected horses? *Can. Vet. J.* **52**, 158-161.

Foerner, J.J., Phillips, T.N. and Barclay, W.P. (1980) Surgical diseases of the large intestine. *Proc. Am. Ass. Equine Practnrs.* **26**, 231-234.

Fogarty, U., Del Piero, F., Purnell, R.E. and Mosurski, K.R. (1994) Incidence of *Anoplocephala perfoliata* in horses examined at an Irish abattoir. *Vet. Rec.* **134**, 515-518.

French, D.D., Chapman, M.R. and Klei, T.R. (1994) Effects of treatment with ivermectin for five years on the prevalence of *Anoplocephala perfoliata* in three Louisiana pony herds. *Vet. Rec.* **135**, 63-65.

Geering, R.R. and Johnson, P.J. (1990) Equine tapeworms more prevalent. *Vet. Rec.* **127**, 96.

Gordon, D.K., Zadoks, R.N., Stevenson, H., Sargison, N.D. and Skuce, P.J. (2012) On farm evaluation of the coproantigen ELISA and coproantigen reduction test in Scottish sheep naturally infected with *Fasciola hepatica*. *Vet. Parasitol.* **187**, 436-444.

Harmon, A.F., Zarlenga, D.S. and Hildreth, M.B. (2006) Improved methods for isolating DNA *from Ostertagia ostertagi* eggs in cattle feces. *Vet. Parasitol.* **135**, 297-302.

Hearn, F.P.D. and Hearn, E.E. (1995) A simple diagnostic technique to better determine the prevalence of tapeworms. *J. Equine. Vet. Sci.* **15**, 96-98.

Hinney, B., Wirtherle, N.C., Kyule, M., Miethe, N., Zessin, K.H. and Clausen, P.H. (2011) Prevalence of helminths in horses in the state of Brandenburg, Germany. *Parasitol. Res.* **108**, 1083-1091.

Höglund, J., Ljungstrom, B.L., Nilsson, O. and Uggla, A. (1995) Enzyme-linked immunosorbent assay (ELISA) for the detection of antibodies to *Anoplocephala perfoliata* in horse sera. *Vet. Parasitol.* **59**, 97-106.

Höglund, J., Nilsson, O., Ljungstrom, B.L., Hellander, J., Lind, E.O. and Uggla, A. (1998) Epidemiology of *Anoplocephala perfoliata* infection in foals on a stud farm in south-western Sweden. *Vet. Parasitol.* **75**, 71-79.

Holmes, M.A. and Ramey, D.W. (2007) An introduction to evidence-based veterinary medicine. *Vet. Clin. N. Am.: Equine Pract.* **23**: 191-200.

Kania, S.A. and Reinemeyer, C.R. (2005) *Anoplocephala perfoliata* coproantigen detection: a preliminary study. *Vet. Parasitol.* **127**, 115-119.

Kaplan, R.M. and Nielsen, M.K. (2010) An evidence-based approach to equine parasite control: it ain't the 60s anymore. *Equine Vet. Educ.* **22**, 306-316.

Little, D. and Blikslager, A.T. (2002) Factors associated with development of ileal impaction in horses with surgical colic: 78 cases (1986–2000). *Equine Vet. J.* **34**, 464-468.

Kjær, L.N., Lungholt, M.M., Nielsen, M.K., Olsen, S.N. and Maddox-Hyttel, C. (2007) Interpretation of serum antibody response to *Anoplocephala perfoliata* in relation to parasite burden and faecal egg count. *Equine Vet. J.* **39**, 529-533.

Lyons, E.T., Tolliver, S.C., Drudge, J.H., Swerczek, T.W. and Crowe, M.W. (1983) Parasites in Kentucky thoroughbreds at necropsy: emphasis on stomach worms and tapeworms. *Am. J. Vet. Res.* **44**, 839-844.

Lyons, E.T., Drudge, J.H., Tolliver, S.C., Swerczek, T.W. and Collins, S.S. (1989) Determination of the efficacy of pyrantel pamoate at the therapeutic dose rate against the tapeworm *Anoplocephala perfoliata* in equids using a modification of the critical test method. *Vet. Parasitol.* **31**, 13-18.

Lyons, E.T., Swerczek, T.W., Tolliver, S.C., Bair, H.D., Drudge, J.H. and Ennis, L.E. (2000) Prevalence of selected species of internal parasites in equids at necropsy in central Kentucky (1995–1999). *Vet. Parasitol.* **92**, 51-62.

Marchiondo, A.A., White, G.W., Smith, L.L., Reinemeyer, C.R., Dascanio, J.J., Johnson, E.G. and Shugart, J.I. (2006) Clinical field efficacy and safety of pyrantel pamoate paste (19.13% w/w pyrantel base) against *Anoplocephala* spp. in naturally infected horses. *Vet. Parasitol.* **137**, 94-102.

Meana, A., Luzon, M., Corchero, J. and Gómez-Bautista, M. (1998) Reliability of coprological diagnosis of *Anoplocephala perfoliata* infection. *Vet. Parasitol.* **74**, 79-83.

Meana, A., Pato, N.F., Martin, R., Mateos, A., Perez-Garcia, J. and Luzon, M. (2005) Epidemiological studies on equine cestodes in central Spain: infection pattern and population dynamics. *Vet. Parasitol.* **130**, 233-240.

Nielsen, M.K., Pfister, K. and von Samson-Himmelstjerna, G. (2014) Selective therapy in equine parasite control – application and limitations. *Vet. Parasitol.* **202**, 95-103.

Nielsen, M.K., Mittel, L., Grice, A., Erskine, M., Graves, E., Vaala, W., Tully, R.C., French, D.D., Bowman, R. and Kaplan, R.M. (2013) AAEP Parasite Control Guidelines. American Association of Equine Practitioners. Online at http://www.aaep.org (on 24.03.13).

Nilsson, O., Ljungström, B.L., Höglund, J., Lundquist, H. and Uggla, A. (1995) *Anoplocephala perfoliata* in horses in Sweden: prevalence, infection levels and intestinal lesions. *Acta Vet. Scand.* **36**, 319-328.

Owen, R., Jagger, D.W. and Quan-Taylor, R. (1988) Prevalence of *Anoplocephala perfoliata* in horses and ponies in Clwyd, Powys and adjacent English marshes. *Vet. Rec.* **123**, 562-563.

Owen, R., Jagger, R. and Quan-Taylor, D.W. (1989) Caecal intussusceptions in horses and the significance of *Anoplocephala perfoliata*. *Vet. Rec.* **124**, 34-37.

Pearson, G.R., Davies, L.W., White, A.L. and O'Brien, J.K. (1993) Pathological lesions associated with *Anoplocephala perfoliata* at the ileo-caecal junction of horses. *Vet. Rec.* **132**, 179-182.

Pittaway, C.E., Lawson, A.L., Coles, G.C. and Wilson, A.D. (2014) Systemic and mucosal IgE antibody responses of horses to infection with *Anoplocephala perfoliata*. *Vet. Parasitol.* **199**, 32-41.

Proudman, C.J. and Edwards, G.B. (1992) Validation of a centrifugation/flotation technique for the diagnosis of equine cestodiasis. *Vet. Rec.* **131**, 71-72.

Proudman, C.J. and Edwards, G.B. (1993) Are tapeworms associated with equine colic? A case control study. *Equine Vet. J.* **25**, 224-226.

Proudman, C.J. and Trees, A.J. (1996a) Use of excretory/secretory antigens for the serodiagnosis of *Anoplocephala perfoliata* cestodosis. *Vet. Parasitol.* **61**, 239-247.

Proudman, C.J. and Holdstock, N.B. (2000) Investigation of an outbreak of tapeworm-associated colic in a training yard. *Equine Vet. J.* **32**, 37-41.

Proudman, C.J. and Trees, A.J. (1996b) Correlation of antigen specific IgG and IgG(T) responses with *Anoplocephala perfoliata* infection intensity in the horse. *Parasite Immunol.* **18**, 499-506.

Proudman, C.J., French, N.P. and Trees, A.J. (1998) Tapeworm infection is a significant risk factor for spasmodic colic and ileal impaction colic in the horse. *Equine Vet. J.* **30**, 194-199.

Proudman, C.J., Holmes, M.A., Sheoran, A.S., Edwards, S.E.R. and Trees, A.J. (1997) Immunoepidemiology of the equine tapeworm *Anoplocephala perfoliata*: age-intensity profile and age-dependency of antibody subtype responses. *Parasitology* **114**, 89-94.

Reeves, M.J., Salman, M.D. and Smith, G. (1996) Risk factors for equine acute abdominal disease (colic): results from a multicenter case–control study. *Prev. Vet. Med.* **26**, 285-301.

Rehbein, S., Visser, M. and Winter, R. (2013) Prevalence, intensity and seasonality of gastrointestinal parasites in abattoir horses in Germany. *Parasitol. Res.* **112**, 407-413.

Rehbein, S., Visser, M., Yoon, S. and Marley, S.E. (2007) Efficacy of a combination ivermectin/praziquantel paste against nematodes, cestodes and bots, in naturally infected ponies. *Vet. Rec.* **161**, 722-724.

Rehbein, S., Lindner, T., Visser, M. and Winter, R. (2011) Evaluation of a double centrifugation technique for the detection of *Anoplocephala* eggs in horse faeces. *J. Helminthol.* **85**, 409-414.

Reinemeyer, C.R., Smith, S.A., Gabel, A.A. and Herd, R.P. (1984) The prevalence and intensity of internal parasites of horses in the U.S.A. *Vet. Parasitol.* **15**, 75-83.

Reinemeyer, C.R., Hutchens, D.E., Eckblad, W.P., Marchiondo, A.A. and Shugart, J.I. (2006) Dose-confirmation studies of the cestocidal activity of pyrantel pamoate paste in horses. *Vet. Parasitol.* **138**, 234-239.

Ryu, S.H., Bak, U.B., Kim, J.G., Yoon, H.J., Seo, H.S., Kim, J.T., Park, J.Y. and Lee, C.W. (2001) Cecal rupture by *Anoplocephala perfoliata* infection in a thoroughbred horse in Seoul Race Park, South Korea. *J. Vet. Sci.* **2**, 189-193.

Sanada, Y., Senba, H., Mochizuki, R., Arakaki, H., Gotoh, T., Fukumoto, S. and Nagahata, H. (2009) Evaluation of marked rise in fecal egg output after bithionol administration to horse and its application as a diagnostic marker for equine *Anoplocephala perfoliata* infection. *J. Vet. Med. Sci.* **71**, 617-620.

Skotarek, S.L., Colwell, D.D. and Goater, C.P. (2010) Evaluation of diagnostic techniques for *Anoplocephala perfoliata* in horses from Alberta, Canada. *Vet. Parasitol.* **172**, 249-255.

Slocombe, J.O.D. (1979) Prevalence and treatment of tapeworms in horses. *Can. Vet. J.* **20**, 136-140.

Slocombe, J.O.D. (2004) A modified critical test for the efficacy of pyrantel pamoate for *Anoplocephala perfoliata* in equids. *Can. J. Vet. Res.* **68**, 112-117.

Slocombe, J.O.D., Heine, J., Barutzki, D. and Slacek, B. (2007) Clinical trials of efficacy of praziquantel horse paste 9% against tapeworms and its safety in horses. *Vet. Parasitol.* **144**, 366-370.

Tolliver, S.C., Lyons, E.T. and Drudge, J.H. (1987) Prevalence of internal parasites in horses in critical tests of activity of parasiticides over a 28-year period (1956–1983) in Kentucky. *Vet. Parasitol.* **23**, 273-284.

Tomczuk, K., Kostro, K., Szczepaniak, K.O., Grzybek, M., Studzińska, M., Demkowska-Kutrzepa, M. and Roczeń-Karczmarz, M. (2014) Comparison of the sensitivity of coprological methods in detecting *Anoplocephala perfoliata* invasions. *Parasitol. Res.* **113**, 2401-2406.

Tomczuk, K., Kostro, K., Grzybek, M., Szczepaniak, K., Studzińska, M., Demkowska-Kutrzepa, M. and Roczeń-Karczmarz, M. (2015) Seasonal changes of diagnostic potential in the detection of *Anoplocephala perfoliata* equine infections in the climate of Central Europe. *Parasitol. Res.* **114**, 767-772.

Traversa, D., Fichi, G., Campigli, M., Rondolotti, A., Iorio, R., Proudman, C.J., Pellegrini, D. and Perrucci, S. (2008) A comparison of coprological, serological and molecular methods for the diagnosis of horse infection with *Anoplocephala perfoliata* (Cestoda, Cyclophyllidea). *Vet. Parasitol.* **153**, 271-277.

Trotz-Williams, L., Physick-Sheard, P., McFarlane, H., Pearl, D.L., Martin, S.W. and Peregrine, A.S. (2008) Occurrence of *Anoplocephala perfoliata* infection in horses in Ontario, Canada and associations with colic and management practices. *Vet. Parasitol.* **153**, 73-84.

van Nieuwenhuizen, L.C., Verster, A.J.M., Horak, I.G., Krecek, R.C. and Grimbeek, J.R. (1994) The seasonal abundance of oribatid mites (Acari: Cryptostigmata) on an irrigated Kikuyu grass pasture. *Exp. Appl. Acarol.* **18**, 73-86.

Williamson, R.M.C., Gasser, R.B., Middleton, D. and Beveridge, I. (1997) The distribution of *Anoplocephala perfoliata* in the intestine of the horse and associated pathological changes. *Vet. Parasitol.* **73**, 225-241.

Williamson, R.M.C., Beveridge, I. and Gasser, R.B. (1998) Coprological methods for the diagnosis of *Anoplocephala perfoliata* infection of the horse. *Aust. Vet. J.* **76**, 618-621.

Review Article

Equine placenta – A clinician's perspective. Part 2: Abnormalities

M. Pozor

Department of Large Animal Clinical Sciences, University of Florida College of Veterinary Medicine, Gainesville, USA.
Corresponding author email: pozorm@ufl.edu

Keywords: horse; placenta; mare; fetal membranes; placentitis; retained; burns technique

Summary

Any insufficiency of the equine placenta has dramatic effects on the developing equine fetus. Placental abnormalities, such as the separation of the chorioallantois from the maternal endometrium or torsion of the umbilical cord, lead to fetal demise, premature labour or abortion. These conditions are each associated with characteristic lesions on the equine placenta, which can be found during a detailed examination. These findings can be very helpful for diagnosing problems and implementing appropriate treatments for mares and affected newborn foals. Furthermore, the retention of the entire placenta or any small fragment thereof can cause metritis, laminitis and sepsis. The prompt diagnosis and aggressive treatment of this condition is necessary to save the mare from becoming seriously ill. Therefore, a thorough evaluation of the equine placenta is a crucial element of the *post partum* evaluation of every brood mare.

Introduction

An equine veterinarian should examine the equine placenta immediately after the mare expels it *post partum*. An accurate assessment of specific placental lesions becomes difficult when the placenta has been stored for a prolonged time (Pozor 2015). Furthermore, a detailed evaluation of the completeness of the chorioallantois is crucial for the mare's health and for her future reproductive career. This paper describes specific placental lesions and their clinical significance, and addresses the retention of the equine placenta in respect to a mare's health.

Placental lesions

Chorioallantois (often referred to as chorion or allantochorion)

The placental lesions that have clinical significance for a newborn foal and for a *post partum* mare are most commonly found at the area of the cervical star of the chorioallantois. A thick and bright red surface of the chorioallantois on the chorionic side, in the vicinity of the cervical star, is usually a tell-tale sign of premature placental separation (the separation of the chorioallantois from the endometrium). A thickened cervical star cannot rupture spontaneously during parturition, and the intact chorioallantoic sac appears at the vulvar lips instead of the fetal forelimbs first and the fetal head soon after. This scenario is called a 'red bag'. While this condition usually results from the bacterial infection of the chorioallantois (Morresey 2004; Schlafer 2004), it can also be caused by a failure of the thinning process of the chorioallantois, a process that normally occurs during the last few days of pregnancy (Rossdale and Ricketts 2002). Therefore, premature induction of parturition in mares may lead to 'red bag' delivery and possible fetal loss. One should also consider fescue toxicosis, resulting from digestion of grass infested with an endophytic fungus, *Acremonium coenophialu*, as a possible cause of thickened chorioallantois and a 'red bag' delivery (Cross 2011). This problem occurs primarily in the USA and Canada. Actual separation between chorionic villi and endometrial crypts may happen acutely, during parturition itself, but it may be initiated hours, days, or even weeks prior to delivery, when the disease develops slowly over time. In the case of bacterial infection, bacteria invade the chorioallantois through the cervix, causing ascending placentitis (Calderwood Mays *et al.* 2002; Macpherson 2005). This starts from a thickened, congested chorioallantois at the cervical star, which appears bright red upon evaluation (Schlafer 2004) (**Fig 1a**,**b**). Later in the disease process, this area becomes necrotic, avillous, and pale-to-cream in colour (**Fig 1c**). This disease mostly affects the cervical star area and uterine body. An obvious line of demarcation between affected and healthy tissues is often observed (**Fig 1c**). Occasionally, the disease may extend to the allantoic side, where neovascularisation and chronic adenomatous hyperplasia develops; this can be identified by raised, wart-like lesions (Hong *et al.* 1993a; Shivaprasad *et al.* 1994). The fetus is usually severely compromised by decreased nourishment and oxygenation. In order to confirm a diagnosis of bacterial placentitis in mares, a swab of the affected areas needs to be taken. The most frequent bacteria isolated from these samples are *Streptococcus equi* ssp. *zooepidemicus*, *Escherichia coli*, *Klebsiella pneumonia*, *Pseudomonas aeruginosa* and *Leptospira* spp. (Giles *et al.* 1993; Smith *et al.* 2003).

In contrast to ascending placentitis, focal mucoid placentitis does not affect the cervical area, but causes characteristic lesions in other regions of the chorion. These lesions are avillous and are covered with large amounts of mucoid-purulent material. The inflammatory process often extends to the allantoic side and leads to focal adenomatous hyperplasia. This form of placentitis is most often caused by the Gram-positive branching bacilli formerly called *Nocardioform actinomycetes* (Erol *et al.* 2012), and is called nocardioform placentitis (**Fig 2**). The disease affects the ventral aspect of the base of the gravid horn as well as the junction of the horn with the uterine body (**Fig 2b**). Unfortunately, the route of transmission of the nocardiaform placentitis is still unknown. Surprisingly, experimental intrauterine, intravenous or intrapharyngeal infections of pregnant mares with 2 causative organisms of nocardioform

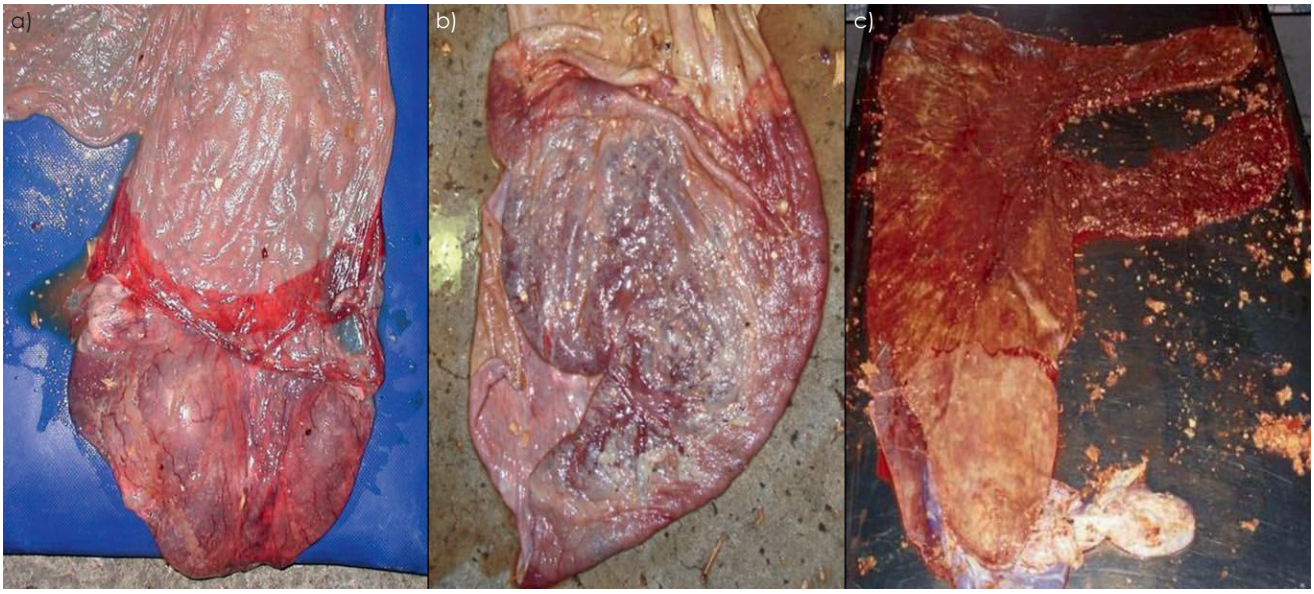

Fig 1: Ascending placentitis: bright-red changes at cervical star (a); very thick, red changes at cervical star, covered by purulent exudate (b); pale/cream colour changes at cervical star as a result of chronic ascending placentitis (c).

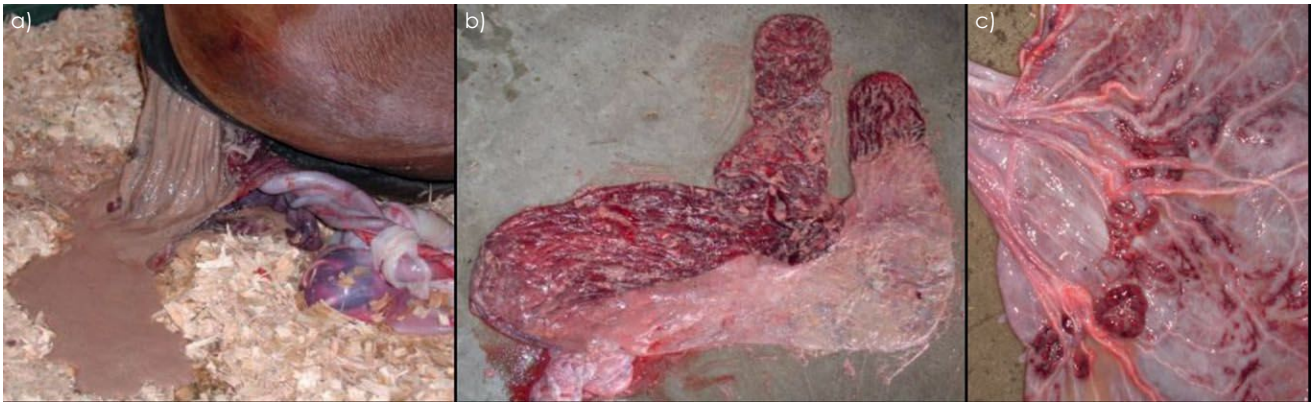

Fig 2: Nocardioform placentitis: purulent material expelled during parturition (a); placenta with typical lesions (b); adenomatous hyperplasia (c).

placentitis, *Amycolatopsis* sp. and *Crosiela equi*, do not result in placentitis (Canisso *et al.* 2013). Cases of nocardioform placentitis can be sporadic or they can appear in large numbers at once in the form of an outbreak (Erol *et al.* 2012). The disease results in late-term abortions, stillbirths, prematurity or full-term foals that may be normal and healthy or that may be small and weak. The focal mucoid placentitis may also develop as a consequence of the digestion of a large amount of shed processionary caterpillar exoskeletons (*Ochrogaster lunifer*) (Cawdell-Smith *et al.* 2013). While the main features of an exposure of pregnant mares to processionary caterpillars are amnionitis, funisitis and allantoitis, often leading to abortion, the placentae from a small number of affected mares have well-demarcated avillous areas on the chorionic surface, which are covered by thick and tan in colour mucus. Placentae of two out of 12 mares treated with a slurry of shed processionary caterpillar exoskeletons by nasogastric intubation developed focal mucoid placentitis involving chorion at the base of the gravid horn and in the middle of the nongravid horn, or at the tip of the pregnant horn (Cawdell-Smith *et al.* 2013). One of the foals resulting from these two pregnancies was born 5 weeks prematurely, while the other foal was grossly normal.

'Blood-borne' placentitis, resulting in gross lesions disseminated throughout the entire chorioallantois, occurs rarely in horses (Whitwell 2011). Two serovars of *Leptospira* spp. are most often isolated from the affected placentae and aborted fetuses: serovar Pomona type kenewicki, with serovars Grippothyphosa and Hardjo appearing less frequently (Divers 2015). The abnormal chorion has multiple areas of necrosis that appear dark red, reddish brown or tan (Poonacha *et al.* 1993). A thick layer of reddish brown necrotic mucoid exudate occasionally covers them. Greenish lesions and nodular cystic masses or cysts are often present on the allantoic side of the chorioallantois (chronic adenomatous hyperplasia). The cervical star area has normal gross appearance (Sebastian *et al.* 2005).

Fungal placentitis is also rare in mares. Infection with filamentous fungi such as *Aspergillus* sp. may mimic bacterial placentitis, since it mainly affects the area at the cervical star (Hong *et al.* 1993b). In such cases, this region becomes thick and leathery, preventing it from rupturing during fetal delivery. This type of mycotic placentitis may be extensive and involve the allantoic side as well, where hyperplastic changes are often found. Other types of mycotic placentitis may appear as multifocal granulomas (*Histoplasma* sp.) or as a diffuse, necrotising, proliferating inflammation (*Candida* sp.) (**Fig 3**).

Amnioallantois (also referred to as amnion or amnioallantois)

Amnioallantois can also be directly affected by severe bacterial or mycotic placentitis. In such cases, this usually thin and transparent membrane is significantly thickened and opaque or white (**Fig 4a**). The vessels become abnormally prominent, convoluted and congested. If the fetus is stressed prior to birth as a result of hypoxia or infection, meconium is released, staining the amnioallantois yellow or green (**Fig 4b**). The infection usually spreads to this membrane through the umbilical cord, which becomes inflamed (funisitis). Severe cases of amnioallantoitis, usually called amnionitis, include the necrosis, congestion and oedema of the amnioallantois and umbilical cord. In less severe cases, only a roughened, irregular amniotic membrane covering the umbilical cord is observed (Schlafer 2004). Another form of equine amnionitis associated with early fetal death or late abortion has been also described, known as equine amnionitis and fetal loss. This syndrome is caused by the exposure of pregnant mares to large quantities of various species of caterpillar. In the USA, the Eastern Tent Caterpillar was the source of the outbreak of mare reproductive loss syndrome that devastated the equine industry in 2001 and 2002 (Webb *et al.* 2004). Different species of caterpillars (including processionary caterpillars, White Cedar Moth caterpillars and Mistletoe Moth caterpillars) as well as a plant (pennyroyal) were implicated in a similar condition in Australia (Perkins 2005). Recently, a group of researchers clearly showed that the digestion of large amounts of processionary caterpillars by pregnant mares leads to the rapid migration of setal fragments from the caterpillars through the intestines to various organs, including the uterus. These setal fragments have been proposed to act as bacterial vectors, causing amnionitis, funisitis, allantoitis and fetal loss (Todhunter *et al.* 2014a,b).

Umbilical cord

The umbilical cord should be inspected during the routine evaluation of the equine placenta. The normal morphology of the umbilical cord, its length and its attachment patterns were described in the first part of this paper (Pozor 2015). The attachment site should be localised first. Abnormal attachment, occasionally observed, is often consistent with an inappropriate fixation position of the conceptus in the uterus or with the disorientation of the conceptus post fixation (Wilsher *et al.* 2009). Ventral cord attachment may result in prolonged gestation length, intrauterine growth retardation and the inability of the foal to adjust to the outside environment. The length of the cord should be measured, and the number of twists should be counted and recorded. Excessively long umbilical cords (approximately >85 cm at term) may cause degenerative changes in the microcotyledons, placental insufficiency and compromised fetal growth or abortion (Schlafer 2004). Abnormal length may also contribute to the development of umbilical cord torsion (**Fig 5**), significantly restricting the blood flow from the placenta to the fetus and *vice versa*. More than 4 or 5 twists of the cord are enough to occlude the umbilical vessels (Schlafer 2011); they then become enlarged and congested (**Fig 5**). The urachus may also be occluded and distended when the amniotic segment of the umbilical cord becomes twisted. Occasionally, the umbilical cord wraps around the hindlimb of the fetus, or other extremity, causing fetal hypoxia. The fetus often dies acutely as a result, which results in abortion. Rarely, the enlarged and ossified remnant of the yolk sac compresses the vessels of the umbilical cord, causing fetal demise and abortion. Significant dilations of the umbilical vessels, caused by excessive pressure, may also be found on the allantoic side of the placenta. The clinical significance of this feature, however, has yet to be determined (Smith *et al.* 2003). Various anomalies in the number of major blood vessels in the equine umbilical cord were recently reported (Wilsher *et al.* 2011). Among 5 cases with these abnormalities, 2 had an atypical arrangement of umbilical arteries and 3 had supernumerary vessels in the umbilical cord. Fetal health and post natal development were normal in all 5 cases. Since similar abnormalities are

Fig 3: Candida placentitis: diffuse, necrotising, proliferating inflammation.

Fig 4: Amnioallantois: thickened membrane (a); meconium-stained amnioallantois (b).

Fig 5: Umbilical cord lesions: umbilical cord torsion (a); umbilical cord wrapped around the hindlimb of the fetus (b); severely congested umbilical cord due to torsion (c).

associated with congenital deformities in human infants, the authors suggest that the umbilical vessels should be evaluated in cases of the congenital malformation of equine fetuses (Wilsher *et al.* 2011).

Obtaining samples

Upon identifying any of these abnormalities, a veterinarian should immediately prepare a plan of action. Prompt intervention and appropriate treatment may be warranted, even necessary, to save the foal and help the mare prepare her reproductive tract for the next pregnancy (Morresey 2004). The immediate submission of the entire placenta with (if dead at birth) or without a fetus to a diagnostic laboratory is highly recommended. However, performing a detailed examination in the field has its advantages, including fast clinical diagnosis, the observation of fresh samples and lower costs (Schlafer 2004). Regardless of where an examination is performed, swabs of the chorionic surface should be taken for bacterial and/or fungal culture and sensitivity testing. Making impression slides and taking small samples of tissues for histopathological evaluation will help obtain even more information about the case. Full-thickness samples of the chorioallantois are taken from the cervical star, the body, the nongravid horn (midsection), the gravid horn (midsection) and the base of the gravid horn (Schlafer 2004) (**Fig 6a**). Furthermore, veterinarians are encouraged to take samples from the umbilical cord, amnioallantois and all abnormal areas, and submit these for analysis (**Fig 6b**). They should also enter all relevant information on an evaluation form, including drawings of all pathological lesions (Pozor 2015). Digital photography is also a highly recommended and useful tool. These photographs can be submitted together with the tissues to a diagnostic laboratory or sent to a specialist for consultation.

Retained placenta

A mare's retention of placenta (fetal membranes) is a serious condition. This occurs in approximately 2–10.5% of foalings in mares, but its incidence is higher in Friesian mares as well as in draught mares (up to 54%) (Sevinga *et al.* 2004; Rapacz *et al.* 2012; O'Brien 2015). Furthermore, the placenta is often retained after dystocia, caesarean delivery, prolonged gestation and hydrops conditions, as well as in mares with low serum calcium concentrations, or with low expression of oxytocin receptors in placental tissues (Sevinga *et al.* 2002a; Threlfall 2011; O'Brien 2015; Rapacz-Leonard *et al.* 2015). Stillbirths and a lack of nursing and oxytocin release may also contribute to the presence of a retained placenta. Normally, expulsion of the fetal membranes in mares starts immediately after the rupture of the umbilical cord, which leads to the disseminated collapse of placental blood vessels and shrinkage of the microvilli, which slide out of the endometrial crypts (Rapacz *et al.* 2012; O'Brien 2015). This process begins in the gravid horn. The chorioallantois starts invaginating, and the entire placenta is successfully expelled due to uterine contractions, abdominal straining and the increasing weight of the hanging membranes. If any elements in this highly synchronised process fail to occur, the placenta will be retained within the uterus for a prolonged period. Recently, it

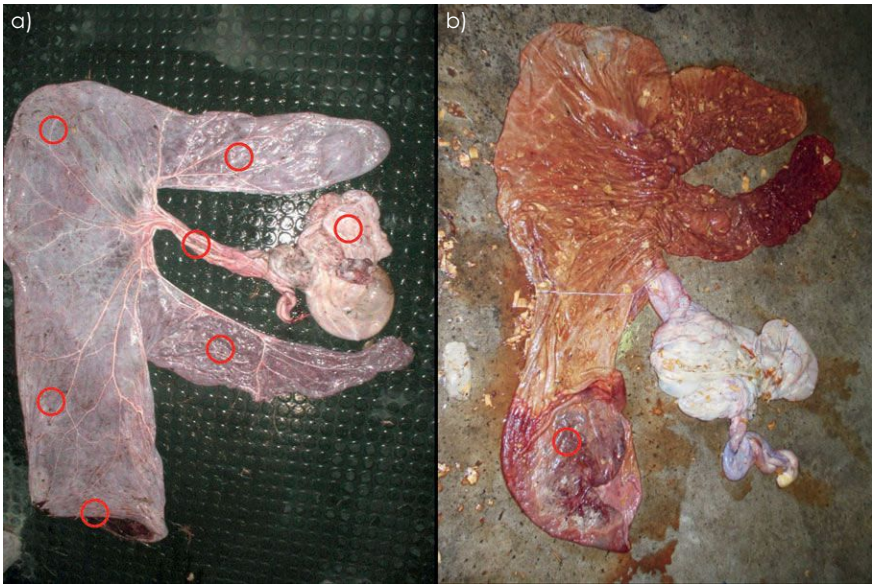

Fig 6: Sites from which to take samples for histopathology, based on Schlafer (2004): cervical star, body, nongravid horn, gravid horn (base and midsection), amnioallantois, umbilical cord (a); abnormal cervical star (or other abnormal areas, b).

Fig 7: Examples of retained and retrieved pieces of chorioallantois.

was shown that the vast majority of retained fetal membranes in draught mares (88%) are caused by a failure of the chorionic villi to become detached from the corresponding crypts in the maternal endometrium ('placental adhesions'), with only small numbers of cases due to uterine inertia (5.5%) or other problems (Rapacz *et al.* 2012; O'Brien 2015). The authors of these investigations found that placental adhesions are associated with 4 histological abnormalities in the chorioallantois: (i) fibrosis in the villi and the stromal connective tissue; (ii) overdevelopment of the stromal connective tissue; (iii) oversized epithelium cells in the nongravid horn; and (iv) underdevelopment of the villi. This last finding is surprising, since it was previously postulated that more branched, larger villi and more placental folding (Allen *et al.* 2002) make the nongravid horn of the chorioallantois especially prone to retention (O'Brien 2015). Unfortunately, the retention of even a small fragment of the chorioallantois (**Fig 7**) is just as dangerous to a mare as the retention of the entire equine placenta. The retained tissues undergo quick autolysis, which is followed by massive bacterial growth,

severe inflammation and the absorption of toxins, leading to endotoxaemia and laminitis. The consequences of untreated retained placenta or a placental fragment in horses can include metritis, laminitis, septicaemia or even death.

Regardless of the amount of retained tissue, treatment must be immediate. Oxytocin administration is the standard treatment for retained placenta and should be initiated as early as 3 h *post partum*. Oxytocin injection promotes uterine contractions and facilitates the release of microvilli from the endometrial crypts. There are several methods to administer oxytocin. Frequent boluses of 10–20 iu i.v. or 5–40 iu i.m. every 2–4 h are usually given for the first 3–6 h. The administration of higher doses of oxytocin is contraindicated, as this leads to the development of strong uterine cramping, which can hold retained tissue in place and thus prevent expulsion. If oxytocin administration is ineffective, a slow i.v. infusion of 60–100 iu in 0.5–2 l of a 0.9% saline solution over 30–60 min can be conducted, followed by 5–10 min of walking (Troedsson *et al.* 1997). This technique is effective if performed within the first 12 h of parturition, and is usually well tolerated. However, some mares may show signs of significant discomfort. If the mare is hospitalised, 40–60 iu in 5 l of lactated Ringer's solution can be given as a slow i.v. drip.

The re-distention of the chorioallantois, called the 'Burns technique', is also a valid option if the chorioallantois is intact, with no tears (Burns *et al.* 1977). In this method, the chorioallantois is distended with large amounts (up to 12 l) of a weak (<2%) povidone-iodine solution in water or 0.9% saline solution through a sterile stomach tube and tied with umbilical tape or held closed by the operator's hand (Troedsson *et al.* 1997). Fluid is maintained in the allantoic cavity for up to several minutes prior to expulsion. It is believed that this method releases endogenous oxytocin, stretching the endometrium and facilitating sliding of the chorionic villi from the endometrial crypts in order to expel the fluid-filled fetal chorioallantois successfully. If this technique is performed properly, the chorioallantoic sack begins to bulge out of the vulva during the administration of

Fig 8: Burns technique. Locating an entrance to the chorioallantroic sac (a); inserting a stomach tube into the chorioallantoic sac (b); progressive expulsion of the chorioallantois (c–f).

Fig 9: Removal of the retained placenta using a new 'Dutch technique': a stallion catheter is threaded through a hose connector and a shut-off coupling, then connected to a hose (a); a cut is made in the umbilical vessel (b); the stallion catheter is inserted into the umbilical vessel (c); allantoic vessels are filled with water, and the chorioallantoic sac is gradually expelled (d–g).

fluid into the allanotic cavity, and the entire chorioallantois is expelled several minutes later (**Fig 8**). Caution is required in order to avoid tearing off the tip of the nongravid horn as the heavy, fluid-filled sac is quickly expelled.

A similar principle may be responsible for the successful outcome of another technique, described (http://youtu.be/mfjR-MTg6 ng) by a group of Dutch veterinarians from the Veterinary Practice Doetinchem-Zeddam (Dierenartsen Praktijk Doetinchem-Zeddam). The advantage of this method is that the membranes do not have to be intact, only access to the umbilical cord is necessary. One of the umbilical vessels is catheterised with a small tube (i.e. a stallion catheter), which is connected to a water hose using a hose connector and a shut-off coupling (**Fig 9a**). The operator makes a small, longitudinal incision into the lumen of an umbilical vessel, introducing the catheter several inches into this vessel (**Fig 9b,c**). The operator's hand holds the vessel clamped around the catheter while water flows at a slow to moderate rate, distending the placental vasculature (**Fig 9d–f**). Steady, moderate, but not strong traction is applied as water is administered. Within 5–10 min, the chorioallantois begins to bulge out, with the allantoic side out, and the membranes are expulsed (**Fig 9g**). In cases of draught mares, a larger catheter or even a stomach tube may be required (I. Canisso, personal communication).

Some practitioners attempt to remove the equine placenta manually by twisting the fragment of the fetal membranes that hang freely from a mare's vulva, or by applying gentle traction until the entire chorioallantois is exteriorised. Caution must be exercised, however, with this technique, which can break off numerous villi, providing material for further bacterial growth and endotoxaemia (Troedsson *et al.* 1997). Uterine haemorrhage can even result if this procedure is carried out too vigorously. However, when performed properly, and done within the first few hours *post partum*, manual removal of the fetal membranes does not have negative effects on mares' future fertility (Sevinga *et al.* 2002a,b; Cuervo-Arango and Newcombe 2009). When only a small fragment of chorioallantois (placental tag) is retained, manual manipulations within the uterus are often helpful (**Fig 10**). Localising a placental tag may be facilitated by infusing a large amount of fluid (saline or lactated Ringer's solution) into the uterus. The operator's hand reaches far into the nongravid horn, which has been expanded by fluid, gently grabbing the retained tissues. If these tissues are held by the strongly contracted uterine horn, they may be gently pulled out. However, if they are still attached to the uterine endometrium, a long piece of umbilical tape or suture material may be attached to the retained tissues and exteriorised at the vulvar lips. A small plastic bottle with approximately 150 ml of water or a plastic rectal sleeve with a half-handful of rectal lube is tied to the end to provide gentle tension and to promote expulsion.

If the placenta is retained as a result of dystocia, if it is not expelled after initial treatment with oxytocin, or if the mare shows any signs of systemic disease, broad-spectrum

Fig 10: Retained fragment of the nongravid horn of chorioallantois: chorioallantois with missing tip of the nongravid horn (*, a); small weight attached to the placental tag (b); large-volume lavage of the mare's uterus (c); retrieved placental tag (d).

antibiotics must be given for at least 5–7 days to prevent bacterial growth. Anti-inflammatory drugs (flunixin meglumine, pentoxifylline) are also given to prevent endotoxaemia and laminitis. Administration of i.v. fluids spiked with 125 ml of calcium borogluconate (23%) is recommended as well. Lavage the uterus with large amounts of 0.9% saline or lactated Ringer's solution 1–3 times a day. Homemade (nonsterile) saline can be made in large batches by mixing 8.5 g of table salt (NaCl) with one litre of tap water, resulting in approximately 0.95 mol/l NaCl solution (Brinsko 2001). Use a sterile stomach tube and a stomach pump to infuse a large volume of this fluid (up to 10 l). The operator uses a hand to protect the tip of the tube in order to prevent the uterine wall and fetal membranes from being sucked into the tube. Complete retrieval of the infused fluid may be difficult in mares with retained placentae. There is no consensus regarding the clinical significance of uterine lavages in mares with retained placentae. Some clinicians suggest that these procedures may enhance the absorption of endotoxins and translocate bacteria from the uterine lumen and from the decomposing fetal membranes to the bloodstream (Canisso *et al.* 2013). Likewise, there is no agreement on the necessity of aggressive preventive procedures against laminitis. Many clinicians implement cold-water hosing or icing of all feet within the first 24 h after parturition. Others prefer using supportive footing and special pads on the front feet. Regardless of the treatment plan chosen by the clinician, affected mares have to be monitored closely for any signs of systemic disease or laminitis through daily observation and routine blood work. The foal heat breeding of a mare that had a retained placenta *post partum* is not recommended.

Conclusions

The equine placenta is a marvellous organ that nourishes the equine fetus throughout pregnancy. Furthermore, it is an open book for the clinician when evaluated *post partum*. It conveys priceless information about the care needed by both foal and mare. However, it can also be deadly if it does not function properly. When the placenta detaches from the maternal endometrium due to disease, the fetus is trapped '*in utero*', frequently with severe consequences, including fetal death. When retained in the uterus *post partum*, the placenta can be a silent killer of the mare. It becomes a petri dish for deadly bacteria, causing a metritis/laminitis/sepsis complex. Therefore, clinicians must always remember to evaluate the equine placenta for completeness and for any signs of pathology.

Author's declaration of interests

No conflicts of interest have been declared.

Ethical animal research

Ethical review not applicable for this review article.

Source of funding

None.

References

Allen, W.R., Wilsher, S., Stewart, F., Stewart, F., Ousey, J., Ousey, J. and Fowden, A. (2002) The influence of maternal size on placental, fetal and postnatal growth in the horse II. Endocrinology of pregnancy. *J. Endocrinol.* **172**, 237-246.

Brinsko, S.P. (2001) How to perform uterine lavage: indications and practical techniques. *Proc. Am. Ass. Equine Practnrs.* **47**, 407-411.

Burns, S.J., Judge, N.G., Martin, J.E. and Adams, L.G. (1977) Management of retained placenta in mares. *Proc. Am. Ass. Equine Practnrs.* **12**, 381-390.

Calderwood Mays, M.B., LeBlanc, M. and Paccamonti, D. (2002) Route of fetal infection in a model of ascending placentitis. *Theriogenology* **58**, 791-792.

Canisso, I.F., Rodriguez, J.S., Sanz, M.G. and Countinho da Silva, M.A. (2013) A clinical approach to the diagnosis and treatment of retained fetal membranes with an emphasis placed on the clinically ill mare. *J. Equine. Vet. Sci.* **33**, 570-579.

Cawdell-Smith, A.J., Todhunter, K.H., Perkins, N.R. and Bryden, W.L. (2013) Exposure of mares to processionary caterpillars (*Ochrogaster lunifer*) in early pregnancy: an additional dimension to equine amnionitis and fetal loss. *Equine Vet. J.* **45**, 755-760.

Cross, D.L. (2011) Fescue toxicosis. In: *Equine Reproduction*, 2nd edn., Eds A.O. McKinnon, E.L. Squires, W.E. Vaala and D.D. Varner, Wiley-Blackwell, Ames. pp 2418-2427.

Cuervo-Arango, J. and Newcombe, J.R. (2009) The effects of manual removal of placenta immediately after foaling on subsequent fertility parameters in the mare. *J. Equine. Vet. Sci.* **29**, 771-774.

Divers, T.J. (2015) Leptospirosis. In: *Robinson's Current Therapy in Equine Medicine 7*, Eds, K.A. Sprayberry and N.E. Robinson, Elsevier Saunders, St Louis. pp 178-180.

Erol, E., Sells, S.F., Williams, N.M., Kennedy, L., Locke, S.J., Labeda, D.P., Donahue, J.M. and Carter, C.N. (2012) An investigation of a recent outbreak of nocardioform placentitis caused abortions in horses. *Vet. Microbiol.* **158**, 425-430.

Giles, R.C., Donahue, J.M., Hong, C.B., Tuttle, P.A., Petrites-Murphy, M.B., Poonacha, K.B., Roberts, A.W., Tramontin, R.R., Smith, B. and Swerczek, T.W. (1993) Causes of abortion, stillbirth, and perinatal death in horses: 3,527 cases (1986-1991). *J. Am. Vet. Med. Ass.* **203**, 1170-1175.

Hong, C.B., Donahue, J.M., Giles, R.C. Jr, Petrites-Murphy, M.B., Poonacha, K.B., Tramontin, R.R., Tuttle, P.A. and Swerczek, T.W. (1993a) Adenomatous hyperplasia of equine allantoic epithelium. *Vet. Pathol.* **30**, 171-175.

Hong, C.B., Donahue, J.M., Giles, R.C. Jr, Petrites-Murphy, M.B., Poonacha, K.B., Roberts, A.W., Smith, B.J., Tramontin, R.R., Tuttle, P.A. and Swerczek, T.W. (1993b) Etiology and pathology of equine placentitis. *J. Vet. Diagn. Invest.* **5**, 56-63.

Macpherson, M.L. (2005) Treatment strategies for mares with placentitis. *Theriogenology* **64**, 528-534.

Morresey, P.R. (2004) How to perform a field assessment of the equine placenta. *Proc. Am. Ass. Equine Practnrs.* **50**, 409-414.

O'Brien, P. (2015) Retained fetal membranes. In: *Equine Medicine 7*, Eds K.A. Sprayberry and N.E. Robinson, Elsevier Saunders, St. Louis. Missouri. pp 713-716.

Perkins, N.R. (2005) *Equine amnionitis and foetal loss (EAFL)*. Hunter Valley Equine Research Centre, Scone, Australia.

Poonacha, K.B., Donahue, J.M., Giles, R.C., Hong, C.B., Petrites-Murphy, M.B., Smith, B.J., Swerczek, T.W., Tramontin, R.R. and Tuttle, P.A. (1993) Leptospirosis in equine fetuses, stillborn foals, and placentas. *Vet. Pathol.* **30**, 362-369.

Pozor, M.A. (2015) Equine placenta – A clinician's perspective Part 1: normal placenta – Physiology and evaluation. *Equine Vet. Educ.* **28**, 327-334.

Rapacz, A., Padzior, K., Ras, A., Rotkiewicz, T. and Janowski, T.E. (2012) Retained fetal membranes in heavy draft mares associated with histological abnormalities. *J. Equine. Vet. Sci.* **32**, 38-44.

Rapacz-Leonard, A., Ras, A., Calka, J. and Janowski, T.E. (2015) Expression of oxytocin receptors is greatly reduced in the placenta of heavy mares with retained fetal membranes due to secondary uterine atony. *Equine Vet. J.* **47**, 623-626.

Rossdale, P.D. and Ricketts, S.W. (2002) Evaluation of the fetal membranes at foaling. *Equine Vet. Educ.* **5**, 78-82.

Schlafer, D.H. (2004) Postmortem examination of the equine placenta, fetus and neonate, methods and interpretation of findings. *Proc. Am. Ass. Equine Pract.* **50**, 144-161.

Schlafer, D.H. (2011) Examination of the placenta. In: *Equine Reproduction*, 2nd edn., Eds A.O. McKinnon, E.L. Squires, W.E. Vaala and D.D. Varner, Wiley-Blackwell, Ames. pp 99-110.

Sebastian, M., Giles, R., Roberts, J., Poonacha, K., Harrison, L., Donahue, J. and Benirschke, K. (2005) Funisitis associated with leptospiral abortion in an equine placenta. *Vet. Pathol.* **42**, 659-662.

Sevinga, M., Barkema, H.W. and Hesselink, J.W. (2002a) Serum calcium and magnesium concentrations and the use of a calcium-magnesium-borogluconate solution in the treatment of Friesian mares with retained placenta. *Theriogenology* **57**, 941-947.

Sevinga, M., Hesselink, J.W. and Barkema, H.W. (2002b) Reproductive performance of Friesian mares after retained placenta and manual removal of the placenta. *Theriogenology* **57**, 923-930.

Sevinga, M., Barkema, H.W., Stryhn, H. and Hesselink, J.W. (2004) Retained placenta in Friesian mares: incidence, and potential risk factors with special emphasis on gestational length. *Theriogenology* **61**, 851-859.

Shivaprasad, H.L., Sundberg, J.P., McEntee, K., Gordon, L., Johnstone, A.C., Lombardo de Barros, C.S. and Hoffman, R.L. (1994) Cystic adenomatous hyperplasia of the equine allantois: a report of eight cases. *J. Vet. Diagn. Invest.* **6**, 107-110.

Smith, K.C., Blunden, A.S., Whitwell, K.E., Dunn, K.A. and Wales, A.D. (2003) A survey of equine abortion, stillbirth and neonatal death in the UK from 1988 to 1997. *Equine Vet. J.* **35**, 496-501.

Threlfall, W.R. (2011) Retained fetal membranes. In: *Equine Reproduction*, 2nd edn., Eds A.O. McKinnon, E.L. Squires, W.E. Vaala and D.D. Varner, Wiley-Blackwell, Ames. pp 2520-2529.

Todhunter, K.H., Cawdell-Smith, A.J., Bryden, W.L., Perkins, N.R. and Begg, A.P. (2014a) Processionary caterpillar setae and equine fetal loss: 1. Histopathology of experimentally exposed pregnant mares. *Vet. Pathol.* **51**, 1117-1130.

Todhunter, K.H., Cawdell-Smith, A.J., Bryden, W.L., Perkins, N.R. and Begg, A.P. (2014b) Processionary caterpillar setae and equine fetal loss: 2. Histopathology of the fetal-placental unit from experimentally exposed mares. *Vet. Pathol.* **51**, 1131-1142.

Troedsson, M.H., Spensley, M. and Fahning, M. (1997) Retained fetal membranes. In: *Current Therapy in Equine Medicine 4*, Ed N.E. Robinson, W.B. Saunders, Philadelphia. pp 560-561.

Webb, B.A., Barney, W.E., Dahlman, D.L., DeBorde, S.N., Weer, C., Williams, N.M., Donahue, J.M. and McDowell, K.J. (2004) Eastern tent caterpillars (*Malacosoma americanum*) cause mare reproductive loss syndrome. *J. Insect Physiol.* **50**, 185-193.

Whitwell, K.E. (2011) Abortions and stillbirths: a pathologist's overview. In: *Equine Reproduction*, 2nd edn., Eds A.O. McKinnon, E.L. Squires, W.E. Vaala and D.D. Varner, Wiley-Blackwell, Ames. pp 2339-2349.

Wilsher, S., Ousey, J. and Allen, W.R. (2009) Abnormal umbilical cord attachment sites in the mare: a review illustrated by three case reports. *Equine Vet. J.* **41**, 930-939.

Wilsher, S., Ousey, J., Whitwell, K., Crowhurst, J.S., Cabrillo, I.J. and Allen, W.R. (2011) Three types of anomalous vasculature in the equine umbilical cord. *Equine Vet. Educ.* **23**, 109-118.

The Long Story

Purina® Well-Gel™ is recovery nutrition at its best, but don't take our word for it. Take Amigo's.

Amigo was a successful 9-year-old competitive endurance horse until, during a pasture accident, a large tree limb penetrated his left thoracic cavity. At the referral hospital, his prognosis for survival was given as 2% and he arrested shortly after arrival.

But Amigo didn't die that day. He survived, only to develop severe pleuropneumonia which left him completely inappetent.

For 28 days, Purina® Well-Gel™ was enterally administered. The highly digestible, fiber-added complete enteral diet provided Amigo with essential nutrients and energy, high-quality protein to help maintain muscle mass, and digestible fiber to support hindgut function. It gave him a chance for survival.

Seven years later he's a healthy, active 16-year-old horse.

So we can say that Purina® Well-Gel™ meets 100% of a horse's daily NRC requirement for protein, vitamins and minerals*, supplying the complete nutrition needed for a complete recovery.

But Amigo says it best.

The Short Story

Animals speak louder than words.™ Purina® Well-Gel™ is sold exclusively to veterinarians. Your Purina expert can tell you more than this ad ever could: 800-227-8941.

FEED GREATNESS™

***When fed as directed.** |

Amigo's story is provided as an individual's experience with Purina® horse products and is not a representation of actual results that can be guaranteed. Because of factors outside of Purina Animal Nutrition LLC's control, individual results to be obtained, including but not limited to: financial performance, animal condition, health or performance cannot be predicted or guaranteed by Purina Animal Nutrition LLC.

Hypothesis Article

Bit-induced asphyxia in the racehorse as a cause of sudden death

W. R. Cook

Cummings School of Veterinary Medicine, Tufts University, North Grafton, Massachusetts, USA.
Corresponding author email: drcook@bitlessbridle.com

Keywords: horse; sudden death; asphyxia; bit

Summary

The prevention of sudden death requires removal of its cause and this is unknown. The author's hypothesis is that bit-induced asphyxia, partial or complete, is a cause of sudden death. *Antemortem* data on bit-induced asphyxia were compared with *post mortem* data on sudden deaths to explore a possible cause-and-effect relationship. Causal categories from sudden death necropsy data were reclassified. Those causing a horse to fall (cardiopulmonary failures) were considered primary effects and those resulting from a fall (CNS trauma and haemorrhagic shock) secondary effects. Cardiac failure from negative pressure pulmonary oedema caused by bit-induced obstruction of the nasopharynx was consistent with the hypothesis. In 1988, asphyxia from recurrent laryngeal neuropathy was posited as a cause of exercise-induced pulmonary haemorrhage (EIPH). It is now suggested that the bit is another cause of asphyxia; EIPH is a sign of negative pressure pulmonary oedema which, in turn, causes cardiac failure and sudden death. By breaking the airtight lip-seal at exercise, a bit dissipates negative pressure in the oral compartments, destabilises the soft palate and obstructs the nasopharynx. Bitted rein pressure, kinking the airway and rendering parts of it flaccid, is a further cause of asphyxia. The data comparison supports a unifying hypothesis on 4 problems currently considered idiopathic; that the bit is an ultimate cause of palatal instability, dynamic collapse of the upper respiratory tract, EIPH and sudden death. Bitless training and racing trials are recommended as a means of demonstrating that bitless racing is possible, preferable and predicted to reduce the prevalence of all 4 problems.

Introduction

An apparently healthy horse at the start of a race can die before the finish or soon after, yet the cause is unknown. For many years, mostly since 1990, some racetrack jurisdictions have mandated necropsy of every horse that dies but frequently a cause is not identified. A feature of those causes identified in a multicentre study is that they were proximate causes (Lyle *et al.* 2011). For example, when pulmonary failure was implicated this did not lead to prevention, as the ultimate cause of pulmonary failure was not explained. A proximate cause describes the pathology but an ultimate cause also names the aetiology. The inevitable variables of delay before necropsy, *post mortem* protocols, multiple pathologists and reporting policies hinder comparisons of data from different racing jurisdictions. Even within a racing jurisdiction, there is seldom a predominance of one cause. The exception is a survey of 11 cases in which 9 were attributed to EIPH (Gunson *et al.* 1988).

The most comprehensive survey to date collated 268 necropsy reports of sudden death from 6 racing jurisdictions (Lyle *et al.* 2011). Sudden death was defined as "acute collapse and death in a closely observed and previously apparently healthy Thoroughbred racehorse, during, or within 1 h after, exercise". Horses subjected to euthanasia 'in extremis' and others with "concurrent trauma that could have contributed to death" (presumably catastrophic limb injuries) were excluded, as were horses in which death occurred beyond 1 h post exercise. Opinions were reported as definitive, presumptive or unexplained. A definitive cause of death was reported in 143 (53%). From these, 80 (56%) were attributed to "cardiac and/or pulmonary failure". Within this group, 50 (63%) were attributed to 'pulmonary haemorrhage'. A total of 13 proximate causes of death were identified and "pulmonary haemorrhage was described in 70% (188/268) of cases but death was only attributed to this lesion in 18% (50/268)….".

The speed with which death occurs suggests its cause, there being few things that can kill a horse in seconds. Falls and fractures of the skull or neck are 2 but this begs the question as to what caused the fall. Asphyxia seems likely. A horse can survive for weeks without food, days without water but only seconds without air. Aside from asphyxia, only cardiac failure kills as quickly. As primary cardiac disease in the racehorse is thought rare and as cardiac failure can be a sequel to asphyxia, asphyxia is clearly a candidate for the cause of sudden death. Yet neither in Lyle *et al.* (2011) or in a study of risk factors for sudden death (Lyle *et al.* 2012) is the word asphyxia mentioned. Until the rules of racing are changed, the bit - not being a variable - is ineligible for study as a risk factor. Nevertheless, beyond racing, bit-heightened risk for both horse and rider is recognised (Jahiel 2014).

Asphyxia from laryngeal paraplegia was reported after a general anaesthetic when extubation resulted in pulmonary oedema. During recovery, a 'pink foamy fluid' discharged from the lower airway (Abrahamsen *et al.* 1990). Similarly, pulmonary oedema in 3 horses was reported to be associated with transient asphyxia and pulmonary haemorrhage (Kollias-Baker *et al.* 1993).

By category, asphyxia is still a proximate cause. The ultimate cause must be some as yet unacknowledged factor. As EIPH occurs in nearly every racehorse, that factor has to be extraordinarily prevalent. Asphyxia was proposed as a cause of EIPH by Cook *et al.* (1988) and attributed to recurrent laryngeal neuropathy. More recently, Cook (2000, 2014a,b) has proposed that asphyxia is also caused by nasopharyngeal obstruction associated with soft palate instability and dorsal displacement and this, in turn, by bit-induced loss of negative pressure in the oral compartments at exercise. Indisputably, a bit is omnipresent in the racehorse.

Commenting on an editorial by Trope (2015) about palatal dysfunction, Cook (2015a,b) noted that there is nothing intrinsically wrong with the soft palate and the fault lies with our expectation that it should function normally with a painful foreign body in the mouth.

Risk factors for sudden death are the same as those for catastrophic musculoskeletal injuries (Lyle *et al.* 2012). The authors concluded that "a generic approach to reduce catastrophic musculoskeletal injury and sudden death may be possible". They hoped that their study would stimulate hypothesis-led investigations into the cause of sudden death. In response, the protocols for 14 experiments were outlined to test a hypothesis related to the one now under consideration (Cook 2014b).

In the meantime, the Lyle *et al.* (2011) data can be examined to test the hypothesis that asphyxia is a cause of sudden death.

Materials and methods

Necropsy data from Lyle *et al.* (2011) were analysed to distinguish between primary and secondary effects (**Table 1**) and interpreted alongside pathophysiology data on the bit (Cook 1999, 2000, 2002, 2014a,b, 2015a,b; Cook and Strasser 2003; Cook and Mills 2010) and recurrent laryngeal neuropathy (Cook *et al.* 1988).

Results

Post mortem data

From the Lyle data it is deduced that cardiopulmonary failures were the primary causes of death (**Table 1**). Within this category, the evidence is consistent with pulmonary failure being the initiator from pulmonary oedema and cardiac failure the terminator.

As CNS trauma and haemorrhagic shock are to be expected when a 600 kg animal (carrying weight) hits the ground at 60 km/h, it is inferred that these are secondary causes.

Two primary effects (cardiopulmonary failure and pulmonary haemorrhage) accounted for 152 of 210 attributions (72%) (**Table 1**). Eight secondary effects accounted for 57 (27%). The greater uniformity of prior-to-the-fall, primary effects, is consistent with the asphyxia hypothesis. The greater diversity of after-the-fall, secondary effects, is consistent with the more random nature of trauma.

The most frequently reported lesion in *post mortem* data was pulmonary haemorrhage with 188/268 (70%) cases. In the horse, a causal mechanism for pulmonary haemorrhage is asphyxia (Cook *et al.* 1988). Rather than EIPH, a more accurate name would be one that describes its aetiology, i.e. negative pressure pulmonary oedema (Cook 2014a). As judged by bronchoalveolar lavage, pulmonary oedema is common in the racehorse.

Another cause of pulmonary oedema in man is traumatic brain injury, i.e. neurogenic pulmonary oedema (O'Leary 2011). If a racehorse is not already dying from negative pressure oedema, it could die from neurogenic oedema because of CNS trauma during a fall. The 'CNS trauma' category in the necropsy data is consistent with the hypothesis, as falls follow asphyxia.

In man, neurogenic pulmonary oedema can also result in myocardial stunning and overt myocardial injury (O'Leary 2011). The gross and histological cardiac lesions occasionally reported in the Lyle data could be so interpreted.

The Lyle data includes 58/268 (22%) 'unexplained' deaths. This is consistent with the hypothesis as bit-induced asphyxia is dynamic and, with one possible exception, leaves no pathognomic evidence. The absence of a lesion pathognomic for asphyxia is typical in man. It is the reason why waterboarding (laryngospasm-induced asphyxia) is selected as a method of interrogation.

Several other explanations can be proposed for the 'unexplained' category.'

TABLE 1: Reformatted data for 210 necropsy reports of sudden death from Table 2 of Lyle *et al.* (2011), excluding 'unexplained' deaths

	Categories	Cause of death	Number	Percentage	Number (%)
Prior to fall	**Cardiac failure and/or pulmonary failure**	**Cardiac failure**	**16**	**7.6**	**152**
		Cardiopulmonary failure	**2**	**1.0**	**(72)**
		Pulmonary failure	**11**	**5.2**	
		Pulmonary haemorrhage	**50**	**24.0**	
		Pulmonary thrombosis	**1**	**0.5**	
	Miscellaneous	**Chronic pulmonary change**	**5**	**2.4**	
	Presumptive diagnosis	Cardiac failure	40	19.0	
		Cardiopulmonary failure	27	12.9	
At the fall	**CNS trauma**	**CNS haemorrhage**	**3**	**1.4**	**57**
		Cervical vertebral fracture	**11**	**5.2**	**(27)**
		Skull fracture	**2**	**1.0**	
		Skull and cervical vertebral fracture	**1**	**0.5**	
		Vertebral instability	**1**	**0.5**	
	Haemorrhagic shock	**Disseminated haemorrhage**	**5**	**2.4**	
		Idiopathic extrapulmonary vascular rupture	**24**	**11.4**	
		Pelvic fracture	**9**	**4.3**	
		Pulmonary vessel rupture	**1**	**0.5**	
	Multiple	**Pulmonary failure and CNS trauma**	**1**	**0.5**	**1**
Total			**210**	**100**	

Line items are listed as primary cardiopulmonary factors (before-a-fall, red font) and secondary traumatic factors (after-a-fall, purple font). The causes of death classified by the attending pathologists as 'definitive' are in bold type and 'presumptive' in unbold.

a) It appears that none of the 268 larynges were examined. Yet evidence published before most of the data were gathered showed that recurrent laryngeal neuropathy is a cause of asphyxia. Examination of the laryngeal musculature was recommended in cases of sudden death (Cook *et al.* 1988).
b) Scabbard trachea appears to be a common deformity in the horse (B.J. Smith 1991, unpublished data). The deformity could be interpreted as tangible evidence of repeated episodes of asphyxia (Cook 2014b) but its occurrence is overlooked by current necropsy protocols whereby the trachea is opened longitudinally.
c) If the necropsy was delayed, pulmonary oedema may have dispersed. The pulmonary congestion that persists is often interpreted as a *post mortem* artefact.
d) The bit as a cause of asphyxia (Cook 1999) was not considered.

Antemortem data

Respiratory pathophysiology and aerodynamics predict, as follows, that bit-induced nasopharyngeal obstruction in the horse, an obligate nose-breather, precipitates a cascade of sequentially more distal airway obstructions during strenuous exercise, ending in pulmonary barotrauma and cardiac failure:

1 A bit in the mouth of a galloping horse triggers digestive system reflexes (salivation, mastication and deglutition) in conflict with the respiratory, cardiovascular and musculoskeletal system reflexes required.
2 At the gallop, a horse takes approximately 2 and a half deep breaths a second; about 30 breaths a furlong. Far fewer than 30 strangulated breaths could account for negative pressure pulmonary oedema, exhaustion and a faltering gait.
3 One or 2 bits and often a tongue-tie, break the airtight lip-seal.
4 Negative pressure in the oral compartments is dissipated. Atmospheric pressure destabilises the soft palate.
5 The soft palate elevates during inspiration, obstructing the nasopharynx.
Elevation and dorsal displacement of the soft palate constitute dynamic collapse of the nasopharynx which, in turn, favours collapse of the aryepiglottic folds, vocal cords, laryngotracheal membrane, dorsal tracheal membrane and, over time, scabbard trachea. The left arytenoid cartilage is especially likely to undergo dynamic collapse in those horses (the majority) with a degree of recurrent laryngeal neuropathy.
6 Even if the abductor muscles of the larynx were healthy, they might, like limb muscles, become fatigued from bit-induced hypoxia, resulting in dynamic collapse of both arytenoids.
7 Other bit-induced factors that contribute to nasopharyngeal asphyxia include flexion of the atlanto-occipital joint, mobility of the tongue (placement over the bit, retraction causing epiglottal retroversion, elevation of the soft palate and constant jostling of nasopharynx and larynx), gaping of the jaw, salivation and swallowing.
8 Bitted rein pressure disrupts the rhythm of breathing (E.F.F. Hanson, personal communication). As breathing is synchronised with striding, this too will be interrupted and could account for stumbling.
9 A bit may induce pharyngeal pain, gag reflexes, and angina - the word derives from the Latin verb *angere,* to choke. The mechanism may be referred pain in the trigeminal nerve, as it is for bit-induced headshaking. The sensory nerves of the soft palate derive from the maxillary branch of the trigeminal nerve.
10 Loss of the airtight seal at the ostium intrapharyngium causes temporary or permanent epiglottal entrapment by exposing mobile oropharyngeal mucosa to inspiratory suction.
11 Nasopharyngeal obstruction leads to negative pressure pulmonary oedema (Bhaskar and Fraser 2011).
12 A principle of gas flow in an obstructed tube is that negative pressure strengthens as distance from the point of obstruction increases. Accordingly, the negative pressure generated in the nasopharynx will be stronger in the larynx, stronger still in the cervical trachea and most severe in the lung. Within the lung, negative pressure will peak in the most caudal alveoli of the caudal lobe, hence the bilaterally caudal distribution of pulmonary oedema lesions.
13 Hypoxia causes pulmonary vasoconstriction and this, in turn, is another cause of pulmonary oedema (Oswalt *et al.* 1977). Exercise-induced hypoxaemia occurs in the horse (Wagner *et al.* 1989).
14 Premature fatigue of skeletal musculature from bit-induced hypoxia could cause loss of muscle tone and lead to musculoskeletal injuries from mild to catastrophic.
15 Cardiac arrest occurs as a sequel to pulmonary oedema (O'Leary 2011).
16 The horse falls from respiratory distress and muscle weakness, if not from cardiac arrest.
17 Pulmonary oedema in man causes intense chest pain, a sense of drowning, fear and panic. It is possible that a horse experiences something similar.

In addition, the bit can cause asphyxia in other ways. At rest, a horse's airway is zigzagged, with a hairpin bend at the throat and a tortuous bend at the thoracic inlet. During a gallop at liberty the airway straightens out considerably and its throat and neck sections are stretched longitudinally. Air flows best through an unkinked, taut tube. When fully stretched, soft-walled sections will resist dynamic collapse. An immobile tongue and jaw will serve to steady the pharynx and larynx, an otherwise highly mobile section of the airway. In the racehorse, the head and neck are seldom fully extended; the airway is bent and less taut; tongue and jaw movement agitate throat and larynx.

Discussion

A 'closely observed' racehorse will not, it is assumed, have atrial fibrillation or cardiac disease. This being ruled-out, asphyxia seems the most likely cause of sudden death.

Syncope is not an all inclusive hypothesis as it does not explain palatal instability or EIPH. Nevertheless, as 'acute collapse' is part of the definition of sudden death (Lyle *et al.* 2011) and has been associated with syncope by Lyle *et al.* (2010), it needs consideration. If cardiac failure from syncope occurred during a race, asphyxia would not be implicated, although the bit could still be the ultimate cause. It is conceivable that a neurological conflict between breathing and swallowing in the bitted horse could stimulate the

carotid sinus, reduce blood flow to the brain, cause loss of muscle tone and cardiac failure. Death would be silent. In man, 'carotid sinus syncope' occurs and 'swallowing syncope' (Farb and Valenti 1999); syncope is associated with emotional stress, pain, overheating, dehydration, heavy sweating and exertion (all of which occur in the racehorse); neurally mediated syncope is the most common form and is most prevalent in the paediatric population. The racehorse is, after all, only a child, so bit-induced syncope is feasible but bit-induced asphyxia is a better fit.

As judged by 'Results', the *ante-* and *post mortem* evidence is consistent with the asphyxia hypothesis. Three explanations for asphyxia during strenuous exercise can be considered; recurrent laryngeal neuropathy, rein-induced poll flexion and palatal instability. Recurrent laryngeal neuropathy is common enough to account for pulmonary haemorrhage but racehorses with severe neuropathy are eliminated in early training so, although mild and moderate neuropathy may be contributory factors, neuropathy by itself it is not a sufficient explanation for sudden death. The second explanation, rein tension with kinking of the upper airway at nasopharynx and thoracic inlet (a 'concertina' effect), is an undoubted cause of asphyxia and could, therefore, account for pulmonary oedema and sudden death, especially in harness racing where rein tensions can be extreme. Nevertheless, in most cases, the bit-induced 'concertina' effect may be a contributory factor rather than the sole factor. Palatal instability, on the other hand, is considered to be quite sufficient, on its own, to choke a horse and cause sudden death.

Bit-induced nasopharyngeal obstruction and the abnormally intense suction pressures that follow is a proposed mechanism for dynamic collapse of the larynx and cervical trachea and for drawing blood-stained oedema fluid from the pulmonary capillaries into the pulmonary interstitium, alveoli and lower airways.

In the paddock before a race, many horses will not have recovered from pulmonary damage incurred during previous races or training gallops yet will be 'apparently healthy'.

Death from asphyxia in horses is not always preceded by stridor and its absence from the case history of a horse that dies suddenly does not disprove the hypothesis. Complete obstruction of an airway results in the ominous absence of all respiratory noise. Asphyxia could be silent during an episode of pharyngospasm (triggered by angina, a gag reflex or attempt to swallow saliva) or laryngospasm (caused by inhalation of saliva or recurrent laryngeal neuropathy). Both could be followed by vagal inhibition and cardiac failure. On the other hand, partial airway obstruction may not be enough to generate stridor, yet enough to generate pulmonary oedema and its sequel, cardiac failure. This explanation for silent death during a race is, therefore, the same as that for post race death, which also occurs without stridor.

No matter how many items of evidence can be mustered in support of a hypothesis this does not prove it but a hypothesis can be disproved by even one valid item of refutation (Popper 1959). The asphyxia hypothesis may appear to be falsified by the fact that 148:268 (43%) of horses died after exercise. However, death from pulmonary oedema after relief of an airway obstruction is a recognised danger (Oswalt *et al.* 1977; Weissman *et al.* 1984; Wyn-Jones *et al.* 1986).

Recommendations

1 A comprehensive case history to be provided when a 'sudden death' cadaver is submitted for necropsy.
2 The necropsy to include an examination of laryngeal musculature and tracheal cross-sections.
3 *Post mortem* evidence to be reported in the light of *ante mortem* evidence.
4 Pathologists to give an opinion - albeit tentative - on an ultimate cause of death. In this way, reports from different laboratories might show closer agreement.
5 Bitless training trials to be witnessed by stewards of racing, with a view to the introduction of bitless racing trials and the eventual approval of bitless racing.
6 Necropsy data on 'catastrophic musculoskeletal injuries' to be reviewed alongside 'sudden death' data.
7 Exercise-induced pulmonary haemorrhage to be renamed 'negative pressure pulmonary oedema'.

Conclusion

The evidence supports the prediction by Lyle *et al.* (2012) that sudden death and catastrophic musculoskeletal injury may share a common cause. Bit-induced asphyxia and its effects are preventable. As a bit is currently mandated by the rules of racing, administrators are urged to explore bitless alternatives and update a rule incompatible with equine physiology. Sudden death is a management problem and requires a management solution. A bitted rein-aid has been shown in other disciplines to be a handicap to communication and a hazard to the health and safety of horse and rider. The discipline of racing is no different. There is ample evidence that removal of an oral foreign body will banish oral pain, allow a racehorse to breathe freely and improve its quality of life. In addition, this step is predicted to reduce the prevalence not only of sudden death but also that of EIPH, palatal dysfunction, catastrophic and noncatastrophic limb injuries. As a corollary, injuries to exercise riders and jockeys will be reduced and improvement can be anticipated in racehorse longevity, performance and the public image of racing. Excuses for the use of race-day furosemide in the USA will be nullified.

Author's declaration of interests

Dr Cook is currently Chairman and majority shareholder of BitlessBridle Inc. and owner of a US patent on a bitless bridle.

Source of funding

For the last 15 years, Dr Cook's research has been funded by BitlessBridle Inc.

References

Abrahamsen, E.J., Bohanon, T.C., Bednarski, R.M., Hubbell, J.A.E. and Muir, W.W. (1990) Bilateral arytenoid cartilage paralysis after inhalation anaesthesia in a horse. *J. Am. Vet. Med. Assoc.* **197**, 1363-1365.

Bhaskar, B. and Fraser, J.F. (2011) Negative pressure pulmonary oedema revisited: pathophysiology and review of management. *Saudi J. Anaesth.* **5**, 308-313.

Cook, W.R. (1999) Pathophysiology of bit control in the horse. *J. Equine. Vet. Sci.* **19**, 196-204.

Cook, W.R. (2000) A solution to respiratory and other problems caused by the bit. *Pferdeheilkunde* **16**, 333-351.

Cook, W.R. (2002) Bit-induced asphyxia in the horse: elevation and dorsal displacement of the soft palate at exercise. *J. Equine. Vet. Sci.* **22**, 7-14.

Cook, W.R. (2014a) An endoscopic test for bit-induced nasopharyngeal asphyxia as a cause of exercise-induced pulmonary haemorrhage in the horse. *Equine Vet. J.* **46**, 256-257.

Cook, W.R. (2014b) A hypothetical etiological relationship between the horse's bit, nasopharyngeal asphyxia and negative pressure pulmonary oedema. *Equine Vet. Educ.* **26**, 381-389.

Cook, W.R. (2015a) One swallow makes a runner. *Vet. Rec.* **176**, 180.

Cook, W.R. (2015b) One swallow makes a runner. *Vet. Rec.* **176**, 469-470.

Cook, W.R. and Mills, D.S. (2010) Preliminary study of jointed snaffle vs. crossunder bitless bridles in four horses. *Equine Vet. J.* **41**, 827-830.

Cook, W.R. and Strasser, H. (2003) *Metal in the Mouth: the Abusive Effects of Bitted Bridles*. Sabine Kells, Qualicum Beach, BC, Canada. pp 14-37.

Cook, W.R., Williams, R.M., Kirker-Head, C.A. and Verbridge, D.J. (1988) Upper airway obstruction (partial asphyxia) as the possible cause of exercise induced pulmonary haemorrhage in the horse: an hypothesis. *J. Equine. Vet. Sci.* **8**, 11-26.

Farb, A. and Valenti, S.A. (1999) Swallow syncope. *Md. Med. J.* **48**, 151-154.

Gunson, D.E., Sweeney, C.R. and Soma, L.R. (1988) Sudden death attributable to exercise-induced pulmonary hemorrhage in racehorses: nine cases (1981-1983). *J. Am. Vet. Med. Assoc.* **193**, 102-106.

Jahiel, J. (2014) Increase comfort, reduce risk: the bitless bridle. Equestrian Medical Safety Association Newsletter, Fall issue, pp 5-12. Online at http://emsaonline.net/wp-content/uploads/gravity_forms/1-5f7def01e62df8eee656c247c514b181/2015/01/emsa-news-fall-2014.pdf

Kollias-Baker, C.A., Pipers, F.S., Heard, D. and Seeherman, H. (1993) Pulmonary edema associated with transient airway obstruction in three horses. *J. Am. Vet. Med. Assoc.* **202**, 1116-1118.

Lyle, C.H., Turley, G., Blissitt, K.J., Pirie, R.S., Mayhew, I.G., McGorum, B.C. and Keen, J.A. (2010) Retrospective evaluation of episodic collapse in the horse in a referred population: 25 cases (1995-2009). *J. Vet. Intern. Med.* **24**, 1498-1502.

Lyle, C.H., Uzal, F.A., McGorum, B.C., Aida, H., Blissitt, K., J, C., J.T, C., Gardner, J.T., Horadagoda, N., Kusano, K., Lam, K., Pack, J.D., Parkin, T.D., Slocombe, R.F., Stewart, B.D. and Boden, L.A. (2011) Sudden death in racing Thoroughbred horses: an international multicenter study of *post mortem* findings. *Equine Vet. J.* **43**, 324-331.

Lyle, C.H., Blissitt, K.J., Kennedy, R.N., McGorum, B.C., Newton, J.R., Parkin, T.D.H., Stirk, A. and Boden, L.A. (2012) Risk factors for race-associated sudden death in Thoroughbred racehorses in the UK 2000-2007. *Equine Vet. J.* **44**, 459-465.

O'Leary, R. (2011) Neurogenic pulmonary oedema. *Cont. Educ. Anaesth. Crit. Care Pain* **11**, 87-92.

Oswalt, C.E., Gates, G.A. and Holmstrom, F.M.G. (1977) Pulmonary edema as a complication of acute airway obstruction. *J. Am. Med. Assoc.* **238**, 1833-1835.

Popper, K.R. (1959) *The Logic of Scientific Discovery*, Routledge, London. p 17.

Trope, G.D. (2015) Palatal dysfunction in horses: where next? *Vet. Rec.* **176**, 17-18.

Wagner, P.D., Gillespie, J.R., Landgren, G.L., Fedde, M.R., Jones, B.W., DeBowes, R.M., Pieschl, R.L. and Erickson, H.H. (1989) Mechanism of exercise-induced hypoxaemia in horses. *J. Appl. Physiol.* **66**, 1227-1233.

Weissman, C., Damask, M.C. and Yang, J. (1984) Noncardiogenic pulmonary edema following laryngeal obstruction. *Anesthesiol* **60**, 163-165.

Wyn-Jones, G., Jones, R.S. and Church, S. (1986) Temporary bilateral carotid artery occlusion as an aid to nasal surgery in the horse. *Equine Vet. J.* **18**, 125-128.

Continued from page 386

Nagy, A. and Malton, R. (2015) Diffusion of radiodense contrast medium after perineural injection of the palmar digital nerves. *Equine Vet. Educ.* **27**, 648-654.

Nagy, A., Bodó, G. and Dyson, S. (2012) Diffusion of contrast medium after four different techniques for analgesia of the proximal metacarpal region: an in vivo and in vitro study. *Equine Vet. J.* **44**, 668-673.

Parkes, R., Newton, R. and Dyson, S. (2015) Is there an association between clinical features, response to diagnostic analgesia and radiological findings in horses with a magnetic resonance imaging diagnosis of navicular disease or other injuries of the podotrochlear apparatus? *Vet J.* **204**, 40-46.

Pfau, T., Spicer-Jenkins, C., Smith, R.K., Bolt, D.M., Fiske-Jackson, A. and Witte, T.H. (2014) Identifying optimal parameters for quantification of changes in pelvic movement symmetry as a response to diagnostic analgesia in the hindlimbs of horses. *Equine Vet. J.* **46**, 759-763.

Plowright, E. and Dyson, S. (2015) Concurrent proximal suspensory desmopathy and injury of the accessory ligament of the deep digital flexor tendon in forelimbs or hindlimbs of 19 horses. *Equine Vet. Educ.* **27**, 355-364.

Schumacher, J., Schumacher, J., De Graves, F., Schramme, M., Smith, R., Coker, M. and Steiger, R. (2001a) A comparison of the effects of local analgesic solution in the navicular bursa of horses with lameness caused by solar toe or solar heel pain. *Equine Vet. J.* **33**, 386-389.

Schumacher, J., Schumacher, J., De Graves, F., Steiger, R., Schramme, M., Smith, R. and Coker, M. (2001b) A comparison of the effects of two volumes of local analgesic solution in the distal interphalangeal joint of horses with lameness caused by solar toe or solar heel pain. *Equine Vet. J.* **33**, 265-268.

Skelly-Smith, E., Ireland, J. and Dyson, S. (2015) The centrodistal joint interosseous ligament region in the tarsus of the horse: Normal appearance, abnormalities and possible association with other tarsal lesions, including osteoarthritis. *Equine Vet. J.* Epub ahead of print; doi 10.1111/evj.12457

Stanley, R.L. and Piercy, R.J. (2007) Breed susceptibility in equine polysaccharide storage myopathy. *Equine Vet. Educ.* **19**, 143-145.

Stanley, R., McCue, M., Valberg, S., Mickelson, J., Mayhew, J., McGowan, C., Hahn, C., Patterson-Kane, J. and Piercy, R.J. (2009) A glycogen synthase 1 mutation associated with equine polysaccharide storage myopathy and exertional rhabdomyolysis occurs in a variety of UK breeds. *Equine Vet. J.* **41**, 597-601.

Valentine, B. (2003) Equine polysaccharide storage myopathy. *Equine Vet. Educ.* **15**, 254-262.

Walker, V., Dyson, S. and Murray, R. (2013) Effect of a Pessoa training aid on temporal, angular and linear variables of the working trot. *Vet. J.* **198**, 404-411.

Wennerstrand, J., Johnston, C., Roethlisberger-Holm, K., Erichsen, C., Eksell, P. and Drevemo, S. (2004) Kinematic evaluation of the back in the sport horse with back pain. *Equine Vet. J.* **36**, 707-711.

Wennerstrand, J., Gomez Alvarez, C.B., Meulenbelt, R., Johnston, C., van Weeren, P.R., Roethlisberger-Holm, K. and Drevemo, S. (2009) Spinal kinematics in horses with induced back pain. *Vet. Comp. Orthop. and Traumatol.* **22**, 448-454.

Werpy, N. (2012) Metacarpophalangeal joint lesions identified on MRI with lameness that resolves with palmar digital analgesia and intra-articular analgesia. *Proc. Am. Ass. Equine Practnrs.* **58**, 534.

Zimmerman, M., Dyson, S. and Murray, R. (2011a) Close, impinging and overriding spinous processes in the thoracolumbar spine: the relationship between radiological and scintigraphic findings and clinical signs. *Equine Vet. J.* **44**, 178-184.

Zimmerman, M., Dyson, S. and Murray, R. (2011b) Comparison of radiographic and scintigraphic findings of the spinous processes in the equine thoracolumbar region. *Vet. Radiol. Ultrasound.* **52**, 661-671.

Correspondence

Letter to editor: Maxillary odontogenic myxoma in young horses: Six cases (2003–2011)

We write after reading the paper by Fjordbakk *et al.* (2015) published in a recent issue of *Equine Veterinary Education*.

We just wanted to make the authors aware of our report in the Australian Veterinary Journal (Hilbert *et al.* 1988) in which we described 16 horses that were presented with tumours of the paranasal sinuses. Thirteen of these horses were 3 years of age or younger. While the tumours varied in their histological appearance, the terms myxomatous or myxofibromatous were used to describe their nature.

We concede that our cases were not defined as arising from dental elements and we did not have the benefit of computed tomography. However, we think there are enough similarities that our report should have been referenced in this paper.

Thank you for your consideration.

Yours faithfully,

B. J. HILBERT
Equine Surgery, Veterinary Clinical Centre, Charles Sturt University, Wagga Wagga, New South Wales, Australia.

References

Fjordbakk, C.T., Pekárková, M., Dolvik, N.I. and Teige, J. (2015) Maxillary odontogenic myxoma in young horses: Six cases (2003–2011). *Equine Vet. Educ.* **27**, 569-573.

Hilbert, B.J., Little, C.B., Klein, K. and Thomas, J.B. (1988) Tumours of the paranasal sinuses in 16 horses. *Aust. Vet. J.* **65**, 86-88.

Continued from page 365

surgery to resolve the primary cause where appropriate (Conwell *et al.* 2010).

Author's declaration of interests

No conflicts of interest have been declared.

Source of funding

None.

References

Alexander, G.R., Tweedie, M.A., Lescun, T.B. and McKinnon, A.O. (2004) Haemoperitoneum secondary to granulosa cell tumour in two mares. *Aust. Vet. J.* **82**, 481-484.

Beachler, T.M., Bailey, C.S., McKelvey, K.A., Davis, J.L., Edwards, A., Diaw, M., Vasgaard, J.M. and Whitacre, M.D. (2016) Haemoperitoneum in a pregnant mare with an ovarian haematoma. *Equine Vet. Educ.* **28**, 359-363.

Conwell, R.C., Hillyer, M.H., Mair, T.S., Pirie, R.S. and Clegg, P.D. (2010) Haemoperitoneum in horses: a retrospective review of 54 cases. *Vet. Rec.* **167**, 514-518.

Dechant, J.E., Nieto, J.E. and LeJeune, S.S. (2006) Hemoperitoneum in horses: 67 cases (1989–2004). *J. Am. Vet. Med. Ass.* **229**, 253-258.

Epstein, K.L. (2014) Coagulopathies in horses. *Vet. Clin. N. Am.: Equine Pract.* **30**, 437-452.

Fletcher, D.J., Brainard, B.M., Epstein, K., Radcliffe, R. and Divers, T. (2013) Therapeutic plasma concentrations of epsilon Aminocaproic acid and tranexamic acid in horses. *J. Vet. Intern. Med.* **27**, 1589-1595.

Gatewood, D.M., Dougless, J.P., Cox, J.H., DeBowes, R.M. and Kennedy, G.A. (1990) Intra-abdominal hemorrhage associated with a granulosa-thecal cell neoplasm in a mare. *J. Am. Vet. Med. Assoc.* **196**, 1827-1828.

Gray, S.N., Dechant, J.E., LeJeune, S.S. and Nieto, J.E. (2015) Identification, management and outcome of postoperative hemoperitoneum in 23 horses after emergency exploratory celiotomy for gastrointestinal disease. *Vet. Surg.* **44**, 379-385.

Green, S.L., Specht, T.E., Dowling, S.C., Nixon, A.J., Wilson, J.H. and Carrick, J.B. (1988) Hemoperitoneum caused by rupture of a juvenile granulosa cell tumor in an equine neonate. *J. Am. Vet. Med. Ass.* **193**, 1417-1419.

Heidmann, P., Tournquist, S.J., Qu, A. and Cebra, C.K. (2005) Laboratory measures of hemostasis and fibrinolysis after intravenous administration of ε-aminocaproic acid in clinically normal horses and ponies. *Am. J. Vet. Res.* **66**, 313-318.

Hurcombe, S.D., Mudge, M.C. and Hinchcliff, K.W. (2007) Clinical and clinicopathologic variables in adult horses receiving blood transfusions: 31 cases (1999–2005). *J. Am. Vet. Med. Ass.* **231**, 267-274.

Klohnen, A. (2012) Evaluation of horses with signs of acute and chronic abdominal pain. In: *Advances in Equine Laparoscopy*, Ed: C.A. Ragle, Wiley Blackwell, Danvers, Massachusetts. pp 93-118.

Luethy, D., Habecker, P., Murphy, B. and Nolen-Walston, R. (2016) Clinical and pathological features of pheochromocytoma in the horse: a multi-center retrospective study of 37 cases (2007–2014). *J. Vet. Intern. Med.* **30**, 309-313.

Maxson, A.D., Giger, U., Sweeney, C.R., Tomasic, M., Saik, J.E., Donawick, W.J. and Cothran, E.G. (1993) Use of a bovine hemoglobin preparation in the treatment of cyclic ovarian hemorrhage in a miniature horse. *J. Am. Vet. Med. Ass.* **203**, 1308-1311.

Mudge, M.C. (2014) Acute hemorrhage and blood transfusions in horses. *Vet. Clin. N. Am.: Equine Pract.* **30**, 427-436.

Pauwels, F.E., Wigley, S.J., Munday, J.S. and Roe, W.D. (2012) Bilateral ovarian adenocarcinoma in a mare causing haemoperitoneum and colic. *N. Z. Vet. J.* **60**, 198-202.

Pusterla, N., Fecteau, M.-E., Madigan, W.D., Wilson, W.D. and Magdesian, K.G. (2005) Acute hemoperitoneum in horses: a review of 19 cases (1992–2003). *J. Vet. Intern. Med.* **19**, 344-347.

Ross, R., Dallap, B.L., Dolente, B.A. and Sweeney, R.W. (2007) Pharmacokinetics and pharmacodynamics of ε-aminocaproic acid in horses. *Am. J. Vet. Res.* **68**, 1016-1021.

Sedrish, S.A. and Johnson, P.J. (1997) Theriogenology question of the month. Excessive hemorrhaging from ovarian hematomas on both ovaries. *J. Am. Vet. Med. Ass.* **212**, 87-89.

Tomlinson, J.E., Taberner, E., Boston, R.C., Owens, S.D. and Nolen-Walston, R.D. (2015) Survival time of cross-match incompatible red blood cells in adult horses. *J. Vet. Intern. Med.* **29**, 1683-1688.

Correspondence

Reply to letter to editor: Maxillary odontogenic myxoma in young horses: Six cases (2003–2011)

Thank you for giving us the opportunity to respond to the comments from Dr Hilbert regarding our article published in *Equine Veterinary Education* (Fjordbakk *et al.* 2015).

Myxomatous lesions affecting the paranasal sinuses in horses have been described for centuries; the condition is for instance thoroughly described in a veterinary surgery textbook published in 1922 with references to an even earlier text dated 1892 (Mørkeberg 1922). Due to the unspecific characteristics of myxoid stroma combined with the difficulties in determining histogenesis of these lesions, we believe that the term 'myxoma' has been used to describe several clinical entities in horses as is the case in human medical literature (Allen 2000). However, neither in the early texts nor in the case series by Hilbert *et al.* (1988) describing tumours of the paranasal sinuses in 16 horses diagnosing myxofibromas in 6 cases and myxomatous cysts in an additional 3 horses, are tooth involvement resembling the medical clinical entity of odontogenic myxoma described.

The expansive nature of myxomatous lesions combined with advanced secondary changes such as bone destruction and inflammatory changes complicates exact diagnosis. Indeed, the resulting abnormal sinonasal architecture might obscure interpretation of 2-dimensional diagnostic imaging techniques such as radiographs. In our case series we found the use of computer tomographic imaging extremely useful in recognising the extent of the lesions as well as the structures involved. However, tooth involvement compatible with odontogenic myxomas was identified in plain radiographs in all cases (Fjordbakk *et al.* 2015). The unavailability of modern advanced diagnostic imaging modalities should therefore not preclude the diagnosis of odontogenic myxoma when present.

Sincerely,

C. T. FJORDBAKK
Department of Companion Animal Clinical Sciences, Faculty of Veterinary Medicine and Biosciences, Norwegian University of Life Sciences, Oslo, Norway

References

Allen, P.W. (2000) Myxoma is not a single entity: a review of the concept of myxoma. Review article. *Ann. Diagn. Pathol.* **4**, 99-123.

Fjordbakk, C.T., Pékarková, M., Dolvik, N.I. and Teige, J. (2015) Maxillary odontogenic myxoma in young horses: six cases (2003–2011). *Equine Vet. Educ.* **27**, 569-573.

Hilbert, B.J., Little, C.B., Klein, K. and Thomas, J.B. (1988) Tumours of the paranasal sinuses in 16 horses. *Aust. Vet. J.* **65**, 86-88.

Mørkeberg, A.W. (1922) Sygdomme i næsehulen: Myxomalacia concharum et ossium faciei. In: *Haandbog i Veterinærkirurgi 1. del: Hovedets sygdomme [Danish]*. Kandrup & Wunsch Bogtrykkeri, Copenhagen, Denmark. pp 28-42.

AAEP marketplace

AAEP marketplace

AAEP marketplace

AAEP marketplace

AAEP marketplace

AAEP marketplace

Safety In Numbers

Some dewormers claim just one dose of their product is the best way to deworm your horse, but that's simply not true.

Demand Safety: *You won't find a laundry list of warnings and precautions on the PANACUR® (fenbendazole) POWERPAC label because fenbendazole has a unique mode of action that makes it safe for horses of all ages, sizes, and body conditions.*

Demand Efficacy: *PANACUR® POWERPAC is the only dewormer FDA approved to treat ALL STAGES of the encysted small strongyle.*[1] *Other dewormers miss a critical stage, EL_3, which can account for up to 75% of the encysted small strongyle burden. Plus, it's the best choice for treating ascarids — which are not just a problem in young horses!*

So when it comes to which dewormer to trust, don't forget there's safety in numbers.

Consult your veterinarian for assistance in the diagnosis, treatment and control of parasitism.

Do not use in horses intended for human consumption. When using PANACUR® (*fenbendazole*) Paste 10% concomitantly with trichlorfon, refer to the manufacturers labels for use and cautions for trichlorfon.

[1] PANACUR® (*fenbendazole*) POWERPAC Equine Dewormer product label.

The Science of Healthier Animals

2 Giralda Farms • Madison, NJ 07940 • merck-animal-health-usa.com • 800-521-5767

MERCK Animal Health

American Association of Equine Practitioners

2016 ANNUAL CONVENTION & TRADE SHOW

62nd Annual Convention & Trade Show

Make a splash!

December 3-7, 2016

Orange County Convention Center

Save $115 when you register by September 1!

www.aaep.org/info/annual-convention

ORLANDO