Proceedings of the 68th Annual Convention of the American Association of Equine Practitioners

Program Chair: Robert P. Franklin, DVM, DACVIM

ACKNOWLEDGMENTS
Erin Contino, MS, DVM, DACVSMR, Educational Programs Committee Chair
Carey M. Ross, Scientific Publications Coordinator

Published by the American Association
of Equine Practitioners

ISSN 0065-7182
© American Association of Equine Practitioners, 2022

Policy Statement

The primary purpose of publishing the Proceedings is to provide documentation of the scientific presentations in abstract form, available at the AAEP Annual Convention. Its further purpose is to offer easily accessible information that will assist the AAEP membership, and others in the equine industry, in the daily responsibility of providing the best possible care for the horse.

Mission Statement

To improve the health and welfare of the horse, to further the professional development of its members, and to provide resources and leadership for the benefit of the equine industry.

Future AAEP CE Dates

2023	24th Resort Symposium	Grand Cayman	January 23–25
2023	Focus on Podiatry	Lexington, Kentucky	TBD
2023	New Practitioner Symposium	Lexington, Kentucky	October 6–8
2023	69th Annual Convention	San Diego, California	November 29–Dec 3
2024	70th Annual Convention	Orlando, Florida	December 7–11
2025	71st Annual Convention	Denver, Colorado	December 6–10
2026	72nd Annual Convention	Las Vegas, Nevada	December 6–10

Want to know how your AAEP Annual Convention program came together?

The Scientific Review & Editorial Committee (SREC) and the Educational Programs Committee (EPC) are charged with creating and reviewing educational content to produce high-quality CE for the AAEP. The SREC is composed of AAEP member volunteers from both small and large private practices as well as academia and industry. Members include both general practitioners and specialists.

The San Antonio program includes invited papers for the "In-depth" and "How to" sessions as well as sessions comprised of papers that independent authors submitted for consideration. Topic choices for the invited "In-depth" and "How to" sessions are based on member feedback from AAEP CE Needs Analysis surveys. Topic session leaders are selected by the Program Chair, and then these session leaders invite a slate of speakers to prepare the papers that become an "In-depth" overview or a series of related "How to" talks. Although invited, these papers undergo a rigorous peer review process by the SREC.

Papers submitted by independent authors are each assigned 3 reviewers from the SREC. The reviewers do not know the names of the authors. Content is scored using the criteria of Study Design, Study Quality, Innovation and Impact, Practicality, and Manuscript Quality. This year 122 papers were submitted for the 59 available slots on the program.

Non-scientific sessions addressing business, ethical, and industry concerns are also planned as the scientific program materializes. Speakers who are invited to participate in these sessions prepare papers that are also reviewed by members of the SREC for inclusion in the Proceedings.

The peer review process for the AAEP Proceedings is rigorous. It requires an enormous effort by every one of the 50+ members of the SREC to create the best possible program for the AAEP membership. Many volunteer hours were spent putting together the San Antonio program, so please thank them for all their hard work creating this program for you.

From Your President

American Association of Equine Practitioners
4075 Iron Works Parkway • Lexington, KY 40511
859.233.0147
fax: 859.233.1968
www.aaep.org

Dear AAEP Members, Family, and Friends:

It is my pleasure to welcome you all to San Antonio, Texas and the AAEP 68th Annual Convention and Trade Show.

The 2022 Program Chair and President-Elect Dr. Rob Franklin is also happy to welcome us to his home state and has worked really hard with the Educational Programs Committee (EPC) to pull together an excellent program. There is plenty of scientific content included but also lots of time to explore other content that really matters to our profession including business, well-being, and the next generation. A huge shout out to some of the many tireless volunteers of this organization who all contributed time and effort to this program including the Educational Programs Committee and the Scientific Review and Editorial Committee. A special thank you to the AAEP staff, as well as EPC leaders Drs. Erin Contino and Luke Bass. One last word of appreciation – the speakers! THANK YOU! We couldn't do this without all of you.

As you explore the convention venue, please take time to thank our Educational Partners in the Trade Show – AAEP is grateful for their presence here this week, as well as throughout the year. They are ever supportive of our daily work and are our faithful partners in the well-being of the horse. We couldn't do our jobs without them, and we benefit enormously from their generous participation in our organization.

This has been a challenging year for AAEP and many of our members, with issues in recruiting and retaining horse doctors and staff. Last year at the convention, we were hearing from the Recruitment and Retention Task Force led by Dr. Carol Clark about perspectives of students, new graduates, and practice owners. This year, we are moving towards a different place thanks to the hard work and vision of many. For me, this visit marks the second time I have been to Texas this year – the first time was in April to convene a Practitioner's Summit in Dallas to explore the current crisis and to strategize about plans for action. Next, the Board of Directors created an operational plan to address this issue head on and in the summer, they approved the creation of the Commission on Sustainability in Equine Practice with several important subcommittees including internships, students, practice culture, emergency coverage, and compensation. All these groups have dedicated members working on these critical elements and this year's convention will mark an important step in beginning to craft solutions that can be shared and scaled up across our ranks.

Rest assured that the profession is not the only part to our strategic plan. The Board of Directors remains committed in other key areas – education and the horse. You will hear about all the great work that members are doing throughout this convention. Supporting efforts in all areas of the strategic plan is a key priority of this organization and we are extremely grateful to everyone who has donated to The Foundation for the Horse. It is through this foundation and its tireless supporters that we have the resources to make significant change. If you have not done so yet please stop by to contribute what you can – time, treasure, or talent! Thank you for helping us meet our ambitious $10M fundraising goal to support work on behalf of the horse!

Finally, make sure to take a moment to kick back and enjoy a conversation with a friend. Convention is a special time of year when we see old friends and make new ones. Remember that we need one another. Make time to lift up colleagues who are struggling so they can stand shoulder to shoulder beside us and pave the way for those that are coming behind us so they don't have to trip and stumble like we did.

Best wishes for a fantastic 2022 Convention! I can't wait to see you around here!

It is an honor to serve this organization,



Emma K. Read, DVM, MVSc, DACVS
AAEP 2022 President

Raising the Standard in Horse Health

From the Program Chair and President-Elect

American Association of Equine Practitioners
4075 Iron Works Parkway • Lexington, KY 40511
859.233.0147
fax: 859.233.1968
www.aaep.org

Howdy! Bienvenidos! Bienvenue! Welcome to Tejas, *The Friendly State*, a place steeped in history of horses and a century's old gathering spot for people from all over the world. Texas has flown six flags since the Spanish occupied it in 1519 and will be a great sight for attendees everywhere to join us for the 68th AAEP Convention in San Antonio, a UNESCO world heritage site. There is something special about the Mission City, its picturesque Riverwalk, and indigenous and Hispanic culture for everyone to have an educational and enjoyable time.

As program chair for 2022 convention, I've had the privilege of working with the Educational Programs Committee, led by Drs. Erin Contino and Luke Bass. They have put together a program rich in the latest advancements, along with practical sessions to implement into practice right away.

My deep appreciation goes to the AAEP staff as well as my colleagues on the Board for their support. The AAEP is lucky to have such wonderful people working hard behind the scenes!

Some highlights at the convention this year will be. . .

- Dr. John Townsend will deliver the Keynote on Boundaries: When to say Yes, and How to Say No When You Need to." Practitioners have struggled with setting personal and professional boundaries so Dr. Townsend will provide key skills and principles to take charge of our lives in practice and at home!
- The Kester News Hour – A format including anchors, a forecaster, sportscaster, and field reporter promises to be a fast-paced bundle of the latest information.
- The Frank J. Milne State-of-the-Art Lecture will be delivered by renowned equine orthopedic surgeon, Dr. Susan Stover.
- In-depth sessions on joint therapies in the field, pain management, endometritis, crosstalk when combining diagnostic approaches, preventative medicine, and advancements in inertial sensors for the diagnosis of lameness.
- "How-to" topics are mixed throughout the sessions for practical information that can be implemented immediately, plus a "Back to Basics" session.
- Sessions focusing on mare and stallion theriogenology, medicine, surgery, dentistry, imaging, and lameness/rehabilitation.
- Monday afternoon will update the work of the AAEP Commission on Equine Veterinary Sustainability, an effort led by AAEP members to implement solutions of our profession's current pain points.
- Business sessions on profitability, building and managing wealth, motivating staff, and managing accounts receivable.
- Ethics will be an early riser with practical case-based scenarios and a panel discussion.
- An AAEP/AAEVT Joint roundtable discussion will help us improve our partnership.
- Dry Labs on Dystocia, Ophthalmology, Cervical Imaging, Skull Radiology, plus Mini Labs (free, come and go) on the stifle and distal limb injections.
- A Trade Show of more than 300 exhibitors with a wine reception on Saturday, product demonstrations by exhibitors, and the AAEP General Store.
- Extended Student Program dry labs offering hands-on practical skills plus the Avenues Career Night networking opportunity for students to meet with practices offering internship and externship positions.
- Many interactive Table Topics sessions and Meet the Expert sessions.
- A Healthy Practice session on time management, work:life balance, parenting and communication skills, and every morning features Partner Sunrise Sessions that offer healthcare and practice topics, along with a complimentary breakfast.
- Special events like 'Storytelling Texas Style' with proceeds going to The Foundation for the Horse and don't forget the After Party on Monday night.

This program would not be possible without the Educational and Media Partners. They provide generous support to the AAEP and its many programs throughout the year. A huge thank you is extended to them and the many sponsors for helping make the AAEP Convention possible.

Rob Franklin, DVM Dip. ACVIM
2022 President-Elect and Program Chair

Raising the Standard in Horse Health

2022 AAEP Board of Directors

President
Emma K. Read, DVM, MVSc, DACVS

President-Elect
Robert P. Franklin, DVM, DACVIM

Vice President
Katherine S. Garrett, DVM, DACVS

Emma Adam, DVM, PhD, DACVIM, DACVS
Jackie Marie Christakos, DVM
Erin Denney-Jones, DVM
Amanda M. House, DVM, DACVIM

Executive Director
David L. Foley, CAE

Immediate Past President
Scott A. Hay, DVM

Treasurer
Amy L. Grice, VMD, MBA

P.O. Eric Mueller, DVM, PhD, DACVS
Sarah Reuss, VMD, DACVIM
James A. Zeliff, DVM, MBA

2022 AAEP Awards

Distinguished Life Member – Dr. Richard D. Mitchell
The AAEP Distinguished Life Member designation is awarded to a member in recognition of outstanding contribution to the association throughout their career.

Distinguished Educator Award (Academia) – Dr. Harold C. Schott, II
Awarded to an individual educator, who by his or her actions and commitment has demonstrated a significant impact on the development and training of equine practitioners.

Sage Kester Beyond the Call Award – Dr. Nathaniel A. White, II
This award is named in honor of its first recipient, the late General Wayne O. "Sage" Kester, DVM, and represents the highest honor bestowed by the AAEP upon a current or former member. The award is presented to an individual who has made significant and long-lasting contributions to equine veterinary medicine and the community. This individual not only possesses the qualities of a leader with a strong commitment to the health and welfare of the horse, but also impacts and improves the lives of others through service above self.

General Guidelines for All Papers
69th AAEP Convention
San Diego, CA
November 29 - December 3, 2023

ALL papers must be submitted online at

https://s3.goeshow.com/aaep/annual/2023/AAEP.cfm

by March 15, 2023, 3:00 p.m. E.T.

ALL papers must be submitted online by March 15, 2023, 3:00 p.m. E.T. Under no circumstances will submissions received after the deadline be considered or reviewed. ALL deadlines must be followed to have the published Proceedings available at the meeting.

Failure to adhere to the following format will result in non-acceptance. It is the author's responsibility to convince the Scientific Review & Editorial Committee (SREC) of the value of the submission, as well as to portray to the reader the contents of the presentation. Specific instructions for Scientific papers, "How to" papers, Review papers, Abstracts, and Business papers can be found in their respective sections.

Formatting and Style:

- 12 point, Times New Roman font
- Double-spaced
- 1" margins

Proceedings should be written in the third person. Avoid the use of the first person and pronouns such as I, we, my, mine, us, our, ours.

Example of first vs. third Person:
Rather than stating in the first person: "We concluded from our results that A plus B did not equal C", use the third person: "The results of the study indicated that A plus B did not equal C".

All medications, supplies, and equipment used should be described using generic names. Trade names and addresses of commercial products critical to the technique can be included in footnotes.

Dosages, weights and measures should be expressed entirely in metric units and with specific time intervals.

Example:
22 mg/kg, q 12 h, IV (not 10mg/lb, BID, IV)

Section Headings:

Please refer to the specific guidelines for your paper to see required section headings.

Recommended Nomenclature:

Anatomy and anatomic planes should be described using standard nomenclature following the guidelines developed by Nomina Anatomica Veterinaria (http://www.wava-amav.org/downloads/nav_2012.pdf)

Acknowledgments:

i. Declaration of Ethics
ii. Conflicts of Interest
iii. Funding/Material/Technical Support

General acknowledgment considerations:

- Acknowledgments should include financial, material, and technical support for the work performed.
- If your paper or presentation references the use of a compounded pharmaceutical, please be certain that you are familiar with the FDA guidelines on the use of compounded pharmaceuticals and that the product you reference is in compliance. See section below regarding papers using compounded medications or medical devices.
- All submissions should cite levels of evidence-based medicine.

Declaration of Ethics:

- A Declaration of Ethics statement should be included in the paper under the Acknowledgments section. Authors must declare if they have adhered to the Principles of Veterinary Medical Ethics of the AVMA https://www.avma.org/KB/Policies/Pages/Principles-of-Veterinary-Medical-Ethics-of-the-AVMA.aspx)
- You should plan to include any ethical considerations as part of your oral presentation if your paper is accepted.

Conflicts of Interest:

- The American Association of Equine Practitioners' (AAEP) policy requires that authors must disclose and describe the nature of any actual or potential financial and/or personal relationships they have with companies that manufacture or sell products that figure prominently in the submission or with companies that manufacture or sell competing products (this includes ownership, employment, consultancy arrangements, or service as an officer or board member). The submitting author is required to confirm whether they or any co-authors listed have any actual or potential conflicts of interest, and to provide details during the online submission process.

Example of COI Statement:
Dr. John Doe has no conflict of interest. Dr. Jane Doe has served as a paid technology analyst for the venture capitalists that initiated the formation of Company ABC and served as a member of the Board of Directors of Company ABC from its inception until 2008. Company ABC is currently commercializing the use of Product XYZ. Dr. Jane Doe has also served as a paid consultant and continues to serve on the Company ABC Advisory Board.

It is the Submitting author's responsibility to ensure that all authors adhere to this policy.

Funding Sources:

- Authors are expected to acknowledge all sources of funding or support for the work described and to disclose to the SREC any financial interest (including ownership, employment, consultancy arrangements, or service as an officer or board member) they have with companies that manufacture or sell products that figure prominently in the paper or with companies that manufacture or sell competing products. Such an interest will not necessarily influence the decision to accept or reject a submission for the program but must be included in the Acknowledgments section of the paper.

References:

References should conform to JAVMA's guidelines.

References to published works should be limited to what is relevant and necessary. Number references in the text with superscript numbers consecutively in the order in which they are first cited. Under References, list all authors when there are three or fewer; list only the first three and add "et al." when there are four or more. The author is responsible for the formatting and accuracy of all reference citations. Since readers frequently depend upon the reference citations to guide them in further reading, it is imperative that the citations are correct so that libraries can locate the papers a reader may wish to obtain.

Examples:

Journal article:

1. Auer JA, Martens RJ, Williams EH. Periosteal deformities in foals. *Am J Vet Res* 1982;181:459–466.
2. Murphy CJ, Lavoie JP, Groff J, et al. Bilateral eyelid swelling attributable to lymphosarcoma in a horse. *J Am Vet Med Assoc* 1989;194:939–942.

Some common journal abbreviations include: *Acta Vet Scand, Am J Vet Res, Can J Vet Res, Can Vet J, Cornell Vet, Compend Contin Educ Pract, Equine Vet J, Equine Vet J Suppl, J Am Vet Med Assoc, J Vet Diagn Invest, J Vet Intern Med, Prev Vet Med, Vet Clin North Am Equine Pract, Vet Radiol, Vet Rec, Vet Surg.* Other journal names should be abbreviated in accordance with the National Library of Medicine and *Index Medicus*.

Book:

1. Turner AS, McIlwraith CW. *Techniques in large animal surgery*. Philadelphia: Lea and Febiger, 1982;186–191.
2. Banks P, Bartley W, Birt LM. *The biochemistry of the tissues 2nd ed*. London: John Wiley & Sons, 1968;24.
3. Devlin TM, ed. *Textbook of biochemistry with clinical correlations*. New York: John Wiley & Sons, 1982;14–36.

Chapter in a book:

1. Axelrod B. Glycolysis. In: Greenberg DM, ed. *Metabolic pathways, vol 1. 3rd ed.* New York: Academic Press, 1967;112–145.
2. Kainer RA. Functional anatomy of equine locomotor organs. In: Stashak TS, ed. *Adams' lameness in horses 4th ed*. Philadelphia: Lea and Febiger, 1987;12–18.

Proceedings:

1. Divers TJ. Acute renal failure in horses and cattle, in *Proceedings*. 3rd Am Coll Vet Int Med Forum 1985;93–95.
2. Lamb CR, Koblik PD, O'Callaghan MW, et al. Comparison of bone scintigraphy and radiography as aids in the evaluation of equine lameness: Retrospective analysis of 275 cases, in *Proceedings*. Am Assoc Equine Pract 1989;35: 359–368.

Footnotes:

References to dissertations, theses, abstracts, personal communications, and papers submitted but not yet accepted for publication should be footnoted:

a. Jones CD. The selective advantage of the ABO blood groups [thesis]. Ithaca, NY: Cornell University; 1990.

b. Bramlage LR. Lexington, KY. (personal communication) 1996.

c. Smith AB. Unpublished data. January 1990.

Product and Equipment Names:

Products and equipment should be identified by chemical or generic names or descriptions. All products should be footnoted, along with the manufacturer's full address. A trade name may be included in a lettered footnote along with the name and location (city, state, and zip code) of the manufacturer when the product or equipment was essential to the outcome of the experiment or treatment.

Example:
All horses were sedated with a combination of detomidine HCL[a] (10-20 mg/kg IV) and butorphanol tartrate[b] (0.01-0.02 mg/kg IV).
[a] Dormosedan® Orion Corporation, Espoo, Finland.
[b] Torbugesic®, Fort Dodge Animal Health, Fort Dodge, IA 50501.

Figures:

- Figures should be cited in the text in parentheses (Fig. 1) consecutively in the order of which they are first mentioned.
- The figure itself should also be numbered to correspond to the citation in the text.
- Figures must include captions, 40 words or fewer.

Tables:

Tables should be self-explanatory and should supplement the text. Provide a concise, descriptive title for each table.

Figures, tables, and text should all be included in the same document when submitting a paper online.

Permissions:

If you wish to use previously published material, including text, photographs, or drawings, you must acknowledge the original source and submit written permission from the copyright holders (author and publisher) to reproduce the material. Provide this permission with your submission.

IACUC Approval:

AAEP is dedicated to the humane use of animals in scientific research in accordance with the Institutional Animal Care and Use Committee (IACUC).

Compounded Medications and Medical Devices:

To be considered for selection in the Annual Convention program, abstracts that include the use of compounded drugs must adhere to the tenets described in the AAEP Equine Veterinary Compounding Guidelines (2005). Specifically, compounded drug or medical devices cannot be used in lieu of an FDA-approved product if the approved product has a label indication for the purpose or condition being evaluated or described in the paper.

An exception to this policy will be made for abstracts reporting clinical trials conducted in fulfillment of the requirements for the approval of a new drug (FDA) or biologic (USDA).

Submitted papers that use compounded drugs or medical devices will be reviewed by an outside individual with expertise in this area selected by the Educational Programs Committee (EPC). The individuals will then make a recommendation to the SREC about the suitability of the submission for potential inclusion in the program.

Adherence to Peer-Supported Clinical Guidelines:

The AAEP is sensitized to having people use the term "Standard of Care" from the podium. If you plan to do this, please include this in your abstract or written submitted material so the SREC can confirm its agreement with your statement. Definitions of "Standard of Care" are listed below:

- A diagnostic and treatment process that a clinician should follow for a certain type of patient, illness, or clinical circumstance. Adjuvant chemotherapy for lung cancer is "a new standard of care, but not necessarily the only standard of care." (New England Journal of Medicine, 2004).
- In legal terms, the level at which the average, prudent provider in a given community would practice. It is how similarly qualified practitioners would have managed the patient's care under the same or similar circumstances. The medical malpractice plaintiff must establish the appropriate standard of care and demonstrate that the standard of care has been breached.

Submission Deadline:

ALL papers must be submitted online by ***March 15, 2023, 3:00 p.m. E.T.*** Under no circumstances will submissions received after the deadline be considered or reviewed. ALL deadlines must be followed to have the published Proceedings available at the meeting.

Pre-Press Approval:

Authors will have final approval at the page proof stage. Changes/updates in numbers, dosages or inappropriate grammar may be made within one week of receiving page proofs. Final grammatical changes will be the decision of the editors. Substantial changes or removal of any data will result in forfeiture of complimentary registration and travel, and exclusion from the program.

Honorarium:

Presenting authors will receive one complimentary registration and a check for $550 to help support travel.

Mentors for Authors:

Paper submissions by private practitioners and first-time authors are highly encouraged. The AAEP has a list of members in various areas of expertise who have agreed to volunteer their time to mentor an author who needs guidance. To see this list, email Carey Ross at cross@aaep.org.

Submission Types:

All submissions should strictly adhere to these guidelines with consideration of the Specific Guidelines for each submission type below.

- Scientific papers: may include case series with follow-up data, or the results of experimental or observational studies.
- "How to" papers: describe and explain a technique or procedure used in equine veterinary medicine or the equine industry.
- Review papers: update the membership on a new subject or gather information that may be conflicting allowing the membership to make judgments as to its utility.
- Abstracts: a shorter version of a full research paper to present the latest information without compromising the ability to publish or present elsewhere.
- Business and Lifestyle papers: while the focus may vary between conferences, experienced practitioners present information germane to the operational, financial, and strategic aspects of equine practice.

Scientific Papers: Guidelines for Authors
69th AAEP Convention
San Diego, CA
November 29 - December 3, 2023

ALL papers must be submitted online at
https://s3.goeshow.com/aaep/annual/2023/AAEP.cfm
by March 15, 2023, 3:00 p.m. E.T.

Please make sure you have reviewed the General Guidelines.

Authors who do ***not*** intend to publish in a refereed journal are welcome to submit a Scientific Paper.

The quality of the Scientific Paper will determine the selection. Missing data or proposed, but not completed, procedures will exclude the Scientific Paper from consideration. AAEP invites information dealing with any subject germane to equine practice, but special consideration will be given to presentations by practitioners and material with practical content or new information. At least one author of a report describing diagnosis, treatment, or the interpretation of medical information should be a veterinarian.

Scientific papers should be formatted as described in the General Guidelines and should be no fewer than 600 words, with no upper word limit.

Section Headings:

Headings should include (but are not limited to) the following:

1. Paper Title
2. Take Home Message
3. Introduction
4. Materials and Methods
5. Results
6. Discussion
7. Acknowledgments
   i. Declaration of Ethics
   ii. Conflicts of Interest

iii. Funding/Material/Technical Support
8. References

Paper Title:

The title should clearly identify the technique or procedure that will be presented.

> Example:
> An investigation of regions desensitized following intra-articular analgesia of the coffin joint.

Take Home Message:

This should be a concise summary of the main conclusion and should be no longer than two or three sentences (approximately 50 words)

> Example:
> Local anesthetic injected into the coffin joint is not selective for only this joint. Such injections will desensitize much of the navicular bone and its suspensory ligaments.

Introduction:

The rationale for the submission should be given briefly and significant published work acknowledged here. The clinical significance should also be included, as well as a clear statement of the objective or purpose of the submission. The statement of objectives is usually found in the last sentence of the Introduction.

Materials & Methods:

This Materials and Methods section should describe experimental methodology in the case of a didactic study or, in the case of a clinical study, should include a description of the population from which the animals were selected and how they were selected for inclusion in the report.

Data obtained and how they were obtained must be described. A description of the statistical methods used to summarize data, test hypotheses, and characterize the significance of results should also be included. Normality of the data should be described, and statistical analysis should be appropriate for the distribution of the data (parametric or non-parametric). For weights and measures, metric units should be used. Dosages should be expressed entirely in metric units and with specific time intervals.

> Example:
> 22 mg/kg, q 12 h, IV (not 10mg/lb, BID, IV)

Results:

The Results section should include actual results with numbers and data must be presented. When possible, quantify findings (mean, median, proportion) and present them with appropriate estimates of measurement error or uncertainty (such as standard deviation (SD), standard error (SE) or confidence interval) in addition to the results of hypothesis testing. If the data can be well represented with a graph or figure, these are encouraged if subsequent publication is not anticipated. If numbers and data are not presented due to concerns regarding publication in a refereed journal, indications of relative differences between groups such as odds ratios, % change, and significant differences must be included in the submission to be considered acceptable. In these instances, the authors should submit the data in the form of means, standard deviations, or other descriptions of comparisons among groups in an appendix, which will not be published and only used for review purposes.

Discussion:

In the Discussion section, important findings documented in the results of the study should be stated. Results should be related to other work which has been done and how the results differ or agree with previously published work and why any differences may have occurred should be discussed. The practical take home message for the equine practitioner should be clearly defined and stated in the summarizing final statement. This statement may be longer but should be similar in content to the take home message at the beginning of the paper.

The following items must be fully explained in the paper: the number of horses that have been worked on, how many will be affected, and evidence that the procedure works and is safe.

Acknowledgments:

i. Declaration of Ethics
ii. Conflicts of Interest
iii. Funding/Material/Technical Support

Full instructions for Acknowledgments can be found in the General Guidelines.

References:

Full instructions for References can be found in the General Guidelines.

References should conform to JAVMA's guidelines.

References to published works should be limited to what is relevant and necessary. Number references in the text with superscript numbers consecutively in the order in which they are first cited. Under References, list all authors when there are three or fewer; list only the first three and add "et al." when there are four or more. The author is responsible for the formatting and accuracy of all reference citations. Since readers frequently depend upon the reference citations to guide them in further reading, it is imperative that the citations are correct so that libraries can locate the papers a reader may wish to obtain.

The "How to" Paper: Guidelines for Authors
69th AAEP Convention
San Diego, CA
November 29 - December 3, 2023

ALL papers must be submitted online at
https://s3.goeshow.com/aaep/annual/2023/AAEP.cfm
by March 15, 2023, 3:00 p.m. E.T.

Please make sure you have reviewed the General Guidelines.

"How to" papers are presented to describe and explain a technique or procedure used in equine veterinary medicine or the equine industry. The technique should be relatively new or not widely understood or used in practice. The goal of the "How to" paper is to give equine veterinarians the information they need to critically evaluate the pros and cons of the technique and implement it in their practice if they choose.

"How to" papers should be formatted as described in the General Guidelines and should be no fewer than 600 words, with no upper word limit.

Section Headings:

Headings should include (but are not limited to) the following:

1. Paper Title
2. Take Home Message
3. Introduction
4. Materials and Methods
5. Results
6. Discussion
7. Acknowledgments
   i. Declaration of Ethics
   ii. Conflicts of Interest
   iii. Funding/Material/Technical Support
8. References

Paper Title:

The title should begin with 'How to' and clearly identify the technique or procedure that will be presented.

> *Example:*
> How to Obtain Diagnostic Dental Radiographs

Take Home Message:

This should be a concise summary of the main conclusion and should be no longer than two or three sentences (approximately 50 words)

> *Example:*
> This paper will help practitioners improve their skills in dental radiography, which will improve recognition of radiographic signs of dental and paradental pathology.

Introduction:

The rationale for the submission should be given briefly and significant published work acknowledged here. The clinical significance should also be included, as well as a clear statement of the objective or purpose of the submission. The statement of objectives is usually found in the last sentence of the Introduction.

Materials & Methods:

The Materials and Methods section should explain exactly how the technique is performed so that another veterinarian familiar with the subject area could follow your example. You may use a step-by-step method for the paper and the presentation. All medications, supplies, and equipment used should be described using generic names. Trade names and addresses of commercial products critical to the technique can be included in footnotes.

Results:

The Results section should include a summary of what happens when you use this technique. The number of horses treated in this manner and an assessment of the outcome should be included. You may use personal assertions or data to assert its value, but you must explain how you determined that the technique works.

Discussion:

In the Discussion section, you can give your personal views as to why you think the technique works. Discuss the pros and cons of your approach. Explain how the technique has helped you in your practice and why this should be important to your colleagues. The end of the discussion should contain a summary of the technique and its advantages in the take home message. Case selection, case study number, and case follow-up should all be included.

Acknowledgments:

i. Declaration of Ethics
ii. Conflicts of Interest
iii. Funding/Material/Technical Support

Full instructions for Acknowledgments can be found in the General Guidelines.

References:

Full instructions for References can be found in the General Guidelines.

References should conform to JAVMA's guidelines.

References to published works should be limited to what is relevant and necessary. Number references in the text with superscript numbers consecutively in the order in which they are first cited. Under References, list all authors when there are three or fewer; list only the first three and add "et al." when there are four or more. The author is responsible for the formatting and accuracy of all reference citations. Since readers frequently depend upon the reference citations to guide them in further reading, it is imperative that the citations are correct so that libraries can locate the papers a reader may wish to obtain.

Review Paper: Guidelines for Authors
69th AAEP Convention
San Diego, CA
November 29 - December 3, 2023

ALL papers must be submitted online at
https://s3.goeshow.com/aaep/annual/2023/AAEP.cfm
by March 15, 2023, 3:00 p.m. E.T.

Please make sure you have reviewed the General Guidelines.

Review papers are presented for the purpose of updating the membership on a new subject or for gathering information that may be conflicting. The aim of the paper is to help the membership put the information in perspective, and to make judgments on conflicting information. A review paper will not principally present original data; the goal is to clarify existing knowledge on a subject and help the membership better use the information in their day-to-day practice.

Review papers should be formatted as described in the General Guidelines and should be no fewer than 600 words, with no upper word limit. The content of review articles should

be organized with headings and subheadings that provide a logical flow to the material presented.

Section Headings:

Headings should include (but are not limited to) the following:

1. Paper Title
2. Take Home Message
3. Introduction
4. Review of Topic/Information
5. Discussion
6. Acknowledgments
   i. Declaration of Ethics
   ii. Conflicts of Interest
   iii. Funding/Material/Technical Support
7. References

Paper Title:

The paper should be titled "Review of Some Subject" and should clearly identify the topic that will be presented.

> *Example:*
> Review of Upper Respiratory Dysfunction in Horses During High-Speed Exercise

Take Home Message:

A "Take Home Message" should be provided that summarizes the practical application of the information for the practitioner. This should be a concise summary of the main conclusion and should be no longer than two or three sentences (approximately 50 words).

> *Example:*
> There are many upper respiratory conditions that can impact a horse's performance during high-speed exercise. Differentiating between these conditions allows for the most appropriate treatment and optimizes outcome.

Introduction:

The Introduction should define the subject matter and put it in context, explaining why the review is necessary. The purpose of the review paper should be clearly stated in the Introduction. Clinical significance should also be included, as well as a clear statement of the objective or purpose of the submission. The statement of objectives is usually found in the last sentence of the Introduction.

Review of Topic/Information:

Review of significant published information should be included here. Agreement and disagreement within the subject matter should be identified along with the strengths and limitations of the information sources. Subheadings can be used within this section to break down the material, as appropriate. Reference should be made to the authors who generally support the opinions stated.

Discussion:

In the Discussion section, the author can give his/her personal views or commentary of the reviewed topic/ information. The author's perspective, including his/her own interpretation of the information if it is different from previously published opinions, should be included. The end of the discussion should contain a summary and the conclusion that the author has drawn for the audience, based upon the reviewed data.

Acknowledgments:

i. Declaration of Ethics
ii. Conflicts of Interest
iii. Funding/Material/Technical Support

Full instructions for Acknowledgments can be found in the General Guidelines.

References:

Full instructions for References can be found in the General Guidelines.

References should conform to JAVMA's guidelines.

References to published works should be limited to what is relevant and necessary. Number references in the text with superscript numbers consecutively in the order in which they are first cited. Under References, list all authors when there are three or fewer; list only the first three and add "et al." when there are four or more. The author is responsible for the formatting and accuracy of all reference citations. Since readers frequently depend upon the reference citations to guide them in further reading, it is imperative that the citations are correct so that libraries can locate the papers a reader may wish to obtain.

Abstracts: Guidelines for Authors

For those who intend to publish in a refereed journal

69th AAEP Convention
San Diego, CA
November 29 - December 3, 2023

ALL papers must be submitted online at
https://s3.goeshow.com/aaep/annual/2023/AAEP.cfm
by March 15, 2023, 3:00 p.m. E.T.

Please make sure you have reviewed the General Guidelines.

To encourage submission of the newest scientific information for inclusion in the AAEP Annual Convention program and simultaneously not jeopardize future publication of this material in a refereed journal, the following criteria have been developed for these submissions of Scientific Papers that will be published in the AAEP Proceedings.

In such instances, the published abstract should be approximately 250 words. These "abbreviated abstracts" should follow a structured format with the same headings (see below) as the full-length scientific paper. Please be aware that the Take Home Message is included in the total word count. The abbreviated abstract does not need references, but appropriate acknowledgments should be included. Note this abbreviated abstract is not required for Review, How-to, or In-Depth Papers. **A 1500-word long paper** conforming to the General Guidelines must also be submitted to allow the reviewers to assess the experimental design, materials and methods, statistical analyses, results (with graphs, tables, charts, etc.) and a discussion of the results as it pertains to interpretation and conclusions. The submitting author must include a statement that only the short abstract can be published in the AAEP Convention Proceedings. It remains the author's responsibility to preserve their right to publish in a refereed journal by contacting the respective journal to discuss their prior-publication criteria so that an accepted abbreviated abstract will not jeopardize publication in the refereed journal. These submitted

abbreviated abstracts should be identified with the words "RESEARCH ABSTRACT" at the end of the title.

Guidelines for Abstracts

- Abstracts should be approximately 250 words. They can be longer; however, this is dependent on the journal in which the author wishes to submit the full paper. Journals differ in what they consider to be "prior publication", e.g., some journals will allow an author to submit an abstract up to 1000 words whereas other journals allow fewer words (250). It is the author's responsibility to contact the respective journal to discuss their prior-publication criteria so that their accepted abbreviated abstract will not jeopardize their publication in the refereed journal.

Section Headings:

Headings should include (but are not limited to) the following:

1. Paper Title
2. Take Home Message
3. Introduction
4. Materials and Methods
5. Results
6. Discussion
7. Acknowledgments
   i. Declaration of Ethics
   ii. Conflicts of Interest
   iii. Funding/Material/Technical Support
8. References are required for the full paper but not the abstract

Paper Title:

The title should clearly identify the technique or procedure that will be presented.

> *Example:*
> An investigation of regions desensitized following intra-articular analgesia of the coffin joint.

Take Home Message:

This should be a concise summary of the main conclusion and should be no longer than two or three sentences (approximately 50 words)

> *Example:*
> Local anesthetic injected into the coffin joint is not selective for only this joint. Such injections will desensitize much of the navicular bone and its suspensory ligaments.

Introduction:

The rationale for the submission should be given briefly and significant published work acknowledged here. The clinical significance should also be included, as well as a clear statement of the objective or purpose of the submission. The statement of objectives is usually found in the last sentence of the Introduction.

Materials & Methods:

The Materials and Methods section should describe experimental methodology in the case of a didactic study or, in the case of a clinical study, should include a description of the population from which the animals were selected and how they were selected for inclusion in the report.

Data obtained and how they were obtained must be described. A description of the statistical methods used to summarize data, test hypotheses, and characterize the significance of results should also be included. Normality of the data should be described, and statistical analysis should be appropriate for the distribution of the data (parametric or non-parametric). For weights and measures, metric units should be used. Dosages should be expressed entirely in metric units and with specific time intervals.

Results:

The Results section should include actual results with numbers and data must be presented. When possible, quantify findings (mean, median, proportion) and present them with appropriate estimates of measurement error or uncertainty (such as standard deviation (SD), standard error (SE) or confidence interval) in addition to the results of hypothesis testing. If the data can be well represented with a graph or figure, these are encouraged if subsequent publication is not anticipated. If numbers and data are not presented due to concerns regarding publication in a refereed journal, indications of relative differences between groups such as odds ratios, % change, and significant differences must be included in the submission to be considered acceptable. In these instances, the authors should submit the data in the form of means, standard deviations, or other descriptions of comparisons among groups in an appendix, which will not be published and only used for review purposes.

> *Example:*
> 22 mg/kg, q 12 h, IV (not 10mg/lb, BID, IV)

Discussion:

In the Discussion section, important findings documented in the results of the study should be stated. Results should be related to other work which has been done and how the results differ or agree with previously published work and why any differences may have occurred should be discussed. The practical take home message for the equine practitioner should be clearly defined and stated in the summarizing final statement. This statement may be longer, but should be similar in content to the take home message at the beginning of the paper.

The following items must be fully explained in the paper: the number of horses that have been worked on, how many will be affected, and evidence that the procedure works and is safe.

Acknowledgments:

i. Declaration of Ethics
ii. Conflicts of Interest
iii. Funding/Material/Technical Support

Full instructions for Acknowledgments can be found in the General Guidelines.

References:

References are not required for the abstract, but must be included in the long paper. Full instructions for References can be found in the General Guidelines.

References should conform to JAVMA's guidelines.

References to published works should be limited to what is relevant and necessary. Number references in the text with superscript numbers consecutively in the order in which they are first cited. Under References, list all authors when there are three or fewer; list only the first three and add "et al." when there are four or more. The author is responsible for the formatting and accuracy of all reference citations. Since readers frequently depend upon the reference citations to guide them in

further reading, it is imperative that the citations are correct so that libraries can locate the papers a reader may wish to obtain.

When submitting online, please put both papers in one document; the short abstract should be first, followed by the full-length scientific paper.

A full paper must be included with all abstracts to be considered for the program.

Business and Lifestyle Papers: Guidelines for Authors 69th AAEP Convention San Diego, CA November 29 - December 3, 2023

ALL papers must be submitted online at https://s3.goeshow.com/aaep/annual/2023/AAEP.cfm by March 15, 2023, 3:00 p.m. E.T.

Please make sure you have reviewed the General Guidelines.

The general theme for the 2023 Business Sessions is "Back to Basics." Some potential topics are listed below, and practitioners with expertise or experience in these areas are encouraged to submit papers to be considered for presentation. Please keep in mind that accepted papers are allotted a total speaking time of 20 minutes (15 minutes presentation time + 5 minutes questions). The following topic suggestions are intended to spark ideas that relate to the theme; however, we also welcome paper submissions on any topic pertaining to the Business of Practice.

Potential Topics:

- Business 101
- Cash management and cash flow
- Reading financial and P&L statements
- Improving communication with clients and staff
- Hiring, attracting, and retaining employees/ veterinarians
- Risks for privacy and malware

Guidelines:

Failure to adhere to the following format will result in non-acceptance. It is the author's responsibility to convince the Scientific Review & Editorial Committee (SREC) of the value of the submission, as well as to portray to the reader the contents of the presentation. You may request examples of previously accepted Business papers from cross@aaep.org.

Business papers should be formatted as described in the General Guidelines and should be no fewer than 600 words, with no upper word limit.

Section Headings:

Headings may include (but are not limited to) the following:

1. Paper Title
2. Take Home Message
3. Introduction
4. Solutions
5. Results
6. Discussion
7. Acknowledgments
   i. Declaration of Ethics
   ii. Conflicts of Interest
   iii. Funding/Material/Technical Support
8. References

Paper title:

The title should clearly identify the topic that will be presented.

> *Example:*
> Breaking the Silence: Disclosing Medical Errors

Take Home Message:

This should be a concise summary of the main conclusion and should be no longer than two or three sentences (approximately 50 words).

> *Example:*
> In circumstances where a medical error results in an adverse outcome, a thoughtful response on the part of the veterinarian, staff, and practice is required. This paper will review communication techniques for constructively responding to these difficult situations.

Introduction:

Significant published work should be acknowledged here. A clear statement of the business challenge, or the objective or purpose of the submission, should be included. The statement of objectives is usually found in the last sentence of the Introduction.

Solution:

A description of a single or multiple business solutions should be explained in detail.

Results:-

Any results should be presented in this section. If the data can be well represented with a table or figures, these are encouraged.

Discussion:

Important findings documented in the solution or results of the study should be stated. Solutions or results can be related to other work that has been done and how the results differ. The practical take home message for the equine practitioner should be clearly defined and stated in the summarizing final statement. This statement may be longer but should be similar in content to the take home message at the beginning of the paper.

Acknowledgments:

i. Declaration of Ethics
ii. Conflicts of Interest
iii. Funding/Material/Technical Support

Full instructions for Acknowledgments can be found in the General Guidelines.

References:

Full instructions for References can be found in the General Guidelines.

References should conform to JAVMA's guidelines.

References to published works should be limited to what is relevant and necessary. Number references in the text with superscript numbers consecutively in the order in which they are first cited. Under References, list all authors when there are three or fewer; list only the first three and add "et al." when there are four or more. The author is responsible for the formatting and accuracy of all reference citations. Since readers frequently depend upon the reference citations to guide them in further reading, it is imperative that the citations are correct so that libraries can locate the papers a reader may wish to obtain.

Contents

General Guidelines for Authors vi
Scientific Papers: Guidelines for Authors viii
The "How to" Paper: Guidelines for Authors ix
Review Paper: Guidelines for Authors x
Abstracts: Guidelines for Authors xi
Business and Lifestyle Papers: Guidelines for Authors xiii

Joint Therapies in the Field: What to Use and How

Intra-Articular Therapies in the Field: Traditional Options for Injections 1
D. Reese Hand, DVM, DACVS

How to Use Polyacrylamide Hydrogel as an Intra-Articular Therapy 3
Scott McClure, DVM, PhD, DACVS, DACVSMR

How to Use Stanozolol as an Intra-Articular Therapy 6
Scott McClure, DVM, PhD, DACVS, DACVSMR

The Use of Intra-Articular Alpha-2 Macroglobulin in Ambulatory Practice 9
Christina Russillo, DVM

Important Considerations for Using Platelet Rich Plasma in the Field 13
Mark Revenaugh, DVM

Inflammation, Infection, or Both? Root Causes of Endometritis

Clinical Overview of Endometritis: Causes and Methods of Diagnosis 17
Maria R. Schnobrich, VMD, DACT

Breeding the Young Mare Versus the Teenager: Impact on the Incidence of Endometritis 22
T.A.E. Stout, MA, VetMB, PhD, DECAR

A Tutorial on Biofilm in the Uterus 27
Ryan A. Ferris, DVM, MS, DACT

Responsible Use of Antimicrobial Agents to Treat Bacterial Endometritis in Mares 31
Tamara Dobbie, DVM, DACT

A Menu for Treating Postmating-Induced Endometritis: When Antimicrobials Are Not the Only Answer 37
Ryan A. Ferris, DVM, MS, DACT

The Enigma of Fungal Endometritis: Detection and Resolution 41
T.A.E. Stout, MA, VetMB, PhD, DECAR

Use of Biologic Agents to Treat Endometritis: Is There Evidence to Support This? 46
Marco A. Alvarenga, DVM, MS, PhD

Medicine I: Drugs, Disease Surveillance, and Disasters

Voluntary Surveillance Program for Equine Influenza Virus in the United States During 2008-2021 56
Duane E. Chappell, DVM

Investigation of the Use of Non-Invasive Samples for the Molecular Detection of EHV-1 in Horses with Clinical and Subclinical Infection 58
Danielle Price, DVM

Investigation of the Role of Healthy and Sick Equids in the COVID-19 Pandemic Through Serological and Molecular Testing 60
Kaila O.Y. Lawton

A Fresh Look at the SarcoFluor Antibody Test for the Detection of Specific Antibodies to *Sarcocystis neurona*, Agent of Equine Protozoal Myeloencephalitis 62
Pranav Pandit, BVSc & AH, MPVM, PhD

Intravenous Calcium Administration as Part of a Fluid Resuscitation Protocol: A Randomized, Blinded Clinical Trial 64
Langdon Fielding, DVM, MBA, DACVECC, DACVSMR

Effect of Time and Autologous Serum Addition on the Analysis of Cerebrospinal Fluid in Horses 66
Camilla Quattrini, DVM

How to Respond and Extricate Equines Trapped in Mud Scenarios 68
Rebecca Husted, PhD

Comparison of Technique: Intrathecal Mepivacaine and Intravenous Pentobarbital for Humane Equine Euthanasia 83
Kate Alexander, DVM

Detection of Levamisole and Its Metabolites in Horses After an Oral Levamisole Administration over Seven Days 85
Emma Adam, DVM, PhD, DACVIM, DACVS

Business of Practice: Motivating Staff, Retention, and Teamwork

Building a Team-Based Culture 87
Miranda P. Gosselin, DVM

Maximizing Utilization of Technicians in Equine Practice 90
Kelly A. Zeytoonian, DVM, MBA, CERP

Frank J. Milne State-of-the-Art Lecture

Skeletal Injuries in Equine Athletes – Pathogenesis and Training Concepts for Injury Prevention 95
Susan Stover, DVM, PhD, DACVS

Business of Practice: Managing Accounts Receivable

Accounts Receivable – Culture, Process, and Impact 105
Robert P. Magnus, DVM, MBA

How Practices Can Reduce Accounts Receivable by Moving to Payment at the Time of Service 108
Wendy Krebs, DVM

How to Decrease Accounts Receivable in an Ambulatory Practice 111
Linda Hagerman, DVM

Why Employees Quit: Psychological Safety is Key for Reducing Turnover and Improving the Bottom Line 113
Stacey Cordivano, DVM

How to Use a Mentorship Framework to Support an Early Career Veterinarian 117
Cara Wright, DVM, MS, ICVA

Review of Good Record Keeping: Will Your Documentation Defend You? 121
Cynthia G. MacKenzie, DVM

Having a Difficult Conversation – Speaking Your Truth Effectively 124
Amy L. Grice, VMD, MBA

Mindfulness: A Powerful Tool for Sustainable Equine Practice 130
Tovah Caldwell, BSc.H, DVM, MA

Boundaries: Telephone Time and Wellness in Equine Practice 137
Mary Beth Whitcomb, DVM, MBA, ECVDI (LA-Associate)

Crosstalk: Combining Diagnostic Approaches for Case Success

The Role of Magnetic Resonance Imaging 141
Michael Schramme, DVM, CertEO, PhD, HDR, MRCVS, DECVS, DACVS, DECVSMR, AECVDI

Nuclear Scintigraphy Use in Musculoskeletal Injury and Lameness 151
Ryland B. Edwards, III, DVM, PhD, DACVS, DACVSMR

Positron Emission Tomography 158
Mathieu Spriet, DVM, MS, DACVR, DECVDI, DACVR-EDI

Computed Tomography 166
Kyla Ortved, DVM, PhD, DACVS, DACVSMR

Back to Basics: Foundational Clinical Skills for Equine Practice

Emergency Triage of the Equine Neonate 172
Tiffany L. Hall, DVM, DACVIM, DACVECC

Dentistry Examination in the Adult Horse 175
Nicola Pusterla, DVM, PhD, DACVIM, DAVDC-Equine

Ophthalmic Examination in the Horse 180
Stephanie C. Bell, DVM, DACVO

Upper and Lower Respiratory Exams in the Adult Horse 186
Emily Sundman, DVM, DABVP (Equine Practice)

Emergency Colic and Gastrointestinal Examination in the Horse 190
Andrew T. Willis, DVM, DACVIM (LAIM)

The Equine Neurologic Exam 198
Sally DeNotta, DVM, PhD, DACVIM

Mechanical Objectives: Simplifying the Approach to Equine Podiatry 206
Britt Conklin, DVM

Radiographing the Lame Horse: How to Acquire and Interpret Diagnostic Radiographs 211
David M. Dutton, DVM, DACVS

Use of Ultrasound for Diagnosis of Common Soft Tissue Injuries 216
Tyler E. Tipton, DVM, DACVS-LA

Medicine II: Anti-Inflammatories, Cataracts, and Endocrine Disease

Congenital and Juvenile Cataracts in Horses 220
Kelly E. Knickelbein, VMD, DACVO

Effects of Phenylbutazone, Firocoxib, and Dipyrone on the Diuretic Effect of Furosemide in Horses 222
Julianne M. White, DVM, MBA

Comparison of Whole Blood and Plasma Equine Insulin Concentrations Using a Novel Stall-Side Insulin Assay and Reference Radioimmunoassay 224
Emily Berryhill, DVM, DACVIM

How to Interpret the Phosphorylated Neurofilament Heavy Biomarker Test 226
Carrie J. Finno, DVM, PhD, DACVIM (LAIM)

Long-Term Response of Equids with Pituitary Pars Intermedia Dysfunction to Treatment with Pergolide 230
Harold C. Schott II, DVM, PhD, DACVIM

Review of Factors to Consider When Using the Oral Sugar Test to Diagnose Insulin Dysregulation 232
Amanda Adams, PhD

Review of Considerations When Feeding the Equid with Insulin Dysregulation 235
P.A. Harris, MA, VetMB, PhD, DipECVCN, MRCVS, RCVS Specialist Clinical Nutrition (equine)

Ertugliflozin in the Management of Hyperinsulinemia and Laminitis 239
Tania Sundra, BSc.(Hons), BVMS, MANZCVS (Equine Medicine)

Right Dorsal Colitis: Is This Similar to Cystic Fibrosis in People? 241
Anje G. Bauck, DVM, PhD

Red Cell Distribution Width Values and Red Cell Distribution Width to Platelet Ratio in Thoroughbred Foals in the First 24 Hours of Life 243
Rebeca Scalco, DVM

Building and Managing Wealth as an Equine Practitioner

Climbing Mt. Debt: Navigating Student Loans and Repayment Strategies 245
Tony Bartels, DVM, MBA

Paying off Student Debt Utilizing the Dave Ramsey Method 249
Caitlin Daly, DVM

Practice Ownership – The Key to Financial Health 252
Amy L. Grice, VMD, MBA

Seeding the Field to Grow Future Owners 257
Ciera Guardia, DVM

Building Wealth – Outside of Your Practice 260
John A. Chalk, Jr., JD, CPA, CFP®

Harvesting the Value of Smaller Practices: Mergers, Partnerships, or Sale to Individuals 263
Amy L. Grice, VMD, MBA

Selling to a Corporate Entity 268
Andrew R. Clark, DVM, MBA

Theriogenology - Mare

How to Milk Mares and Maintain Milk Production 271
Scott Austin, DVM, MS, DACVIM

Behavior and Perinatal Parameters of Mule Foals 274
Yatta Linhares Boakari, DVM, MsC, PhD

Abnormal Mare Behavior Is Not Often Associated with Changes in Hormonal Markers of Granulosa Cell Tumors: A Retrospective Study 276
Lauren Huggins, VMD, MS

Evaluation of IgG Content of Mare Colostrum in the Postpartum Period 278
Emily May, DVM

Ovum Pick up in a Clinical Program Can Induce Mild Transient Discomfort in Mares 280
Soledad Martin-Pelaez, DVM

Ovarian Removal Before or After Euthanasia for Postmortem Gamete Retrieval: An Assessment of Pentobarbital Concentration in the Follicular Fluid 282
Soledad Martin-Pelaez, DVM

Deslorelin Acetate is Effective to Induce Ovulation During Early and Late Fall Despite Lower Endometrial Edema in the Latter 284
Kianna M. Spencer, DVM

Follicular and Systemic Metabolic Alterations in Obese Mares Can Be Mitigated by Dietary Supplementation 286
Giovana D. Catandi, DVM

Sports Medicine, Lameness, and Rehabilitation

Influence of Chronic Lameness on Thoracolumbar Musculus Multifidus Structure in the Horse 288
Hayley M. Sullivan, DVM, MS

Clinical Field Study to Evaluate Injectable Pentosan Polysulfate for the Control of Clinical Signs Associated with Osteoarthritis in Horses 290
Scott McClure, DVM, PhD, DACVS, DACVSMR

Managing Proximal Suspensory Desmopathy in Horses: A Review 297
Erin Contino, MS, DVM, DACVSMR

Safety Validation of Equine Blood Flow Restriction Training: A Pilot Investigation 304
Sherry A. Johnson, DVM, MS, DACVSMR

Systematic Review of the Association Between Intra-Synovial Corticosteroid Use and Laminitis: What Is the Evidence? 306
Paula Keiko Anadão Tokawa, DVM

Residual Anti-Inflammatory Effects of Intra-Articular Triamcinolone Acetonide and Betamethasone in an Equine Acute Synovitis Model 308
Emma Partridge, BS

How to Manage the Upright/Low-Grade Club Foot with a Rocker Shoe 310
Ramon Batalla, MV

The Ridden Horse Pain Ethogram and the Performance of Sports Horse: A Review 316
Sue Dyson, VetMB, PhD

Rein-Lameness Associated with Inflammation of the Equine Temporomandibular Joint 326
Nathalie A. Reisbig, VetMed, MSc, PhD

Business of Practice: Profitability

Profitability Implications of Revenue and Expenses 328
John A. Chalk, Jr., JD, CPA, CFP®; and Robert P. Magnus, DVM, MBA

Taking Control of Cost of Goods Sold with Focused Inventory Management 331
Danika Kent Dostal

Innovative Diagnostic Technologies

Use of Equinosis Q with Lameness Locator to Evaluate Lameness in Horses 335
Kevin G. Keegan, DVM, MS, DACVS

Inertial Measurement Units: What Are They and How Can They Be Used? 345
Valerie J. Moorman, DVM, MS, DACVS-LA, PhD

Big Data and Body-Mounted Inertial Sensors 349
Kevin G. Keegan, DVM, MS, DACVS

Use of Biometric Wearable Sensors to Identify Subtle Gait Abnormalities in Thoroughbred Racehorses 355
Scott Palmer, VMD, DABVP, Eq Practice

How to Integrate a Novel Objective Gait Analysis System into Daily Practice 357
Marcus Swail, BVMS, Cert Eq Sports Med, MRCVS

Pain Management: Different Modalities

The Physiology of Pain 366
Kristen Messenger, DVM, PhD, DACVAA, DACVCP

Pharmacology of Pain Control 369
Kristen Messenger, DVM, PhD, DACVAA, DACVCP

Performance Horse Pain Management 371
Lori A. Bidwell, DVM, DACVAA, CVA

Theriogenology - Stallion

How to Manually Analyze a Stallion's Breeding Records 374
Regina M. Turner, VMD, PhD, DACT

Retrograde Flushing Followed by Slicing Float-up Enhanced Epididymal Sperm Recovery Without Affecting Cryopreservation in Stallions 380
Igor Canisso, DVM, MSc, PhD, DACT, DECAR

The Ability of Donkey Sperm for Cooling: Effect of Extender Base and Removal of Seminal Plasma on Sperm Parameters and Fertility Rates 382
Lorenzo G.T.M. Segabinazzi, DVM, MS, PhD

Sperm Filter and Re-extension of Cooled-Shipped Semen as an Alternative to Circumvent Poor Cooling Ability of Stallions 384
Lorenzo G.T.M. Segabinazzi, DVM, MS, PhD

How to Evaluate and Diagnose a Disorder of Sexual Development in the Horse 386
Patrick M. McCue, DVM, PhD, DACT

Decreased Equine Chorionic Gonadotropin Secretion Following Hysteroscopic-Guided Injection of an Immunomodulator 394
Maria R. Schnobrich, VMD, DACT

In-Depth: Preventative Medicine: Being Proactive in Practice

Arthritis Prevention in Sport Horses 396
Caitlin O'Shea, VMD, MS, DACVS-LA, CVA

Metabolic Disease in the Older Horse: Focus on Prevention 401
Katherine E. Wilson, DVM, MS, DACVIM

Preventive Medicine Strategies for Equine Asthma: Current Evidence and Future Directions 406
M. Katie Sheats, DVM, PhD, DACVIM (LA)

Preventative Dentistry 414
Apryle Horbal, VMD, MPhil, MRCVS, DAVDC-EQ

Imaging: Scans, Sesamoids, and Subchondral Changes

Subchondral Lucencies of the Medial Femoral Condyle in Yearling and 2-Year-Old Thoroughbred Sales Horses 424
Frances Peat, BVSc, PhD, DACVSMR

Radiological Findings in the Proximal Sesamoid Bones of Yearling and 2-Year-Old Thoroughbred Sales Horses 426
Frances Peat, BVSc, PhD, DACVSMR

How to Evaluate and Balance the Distal Limb Using Specific Anatomical and Radiographic Parameters 428
Mariah D. Kerr, DVM

Evaluation of the Suspensory Ligament in Quarter Horses Used for Cutting 436
Hayley M. Sullivan, DVM, MS

Ultrasonographic Comparison of the Intermediate Patellar Ligament in Warmbloods Versus Quarter Horses 438
Joanna Cannon, DVM

The Accuracy of Ultrasound to Detect Changes in Cervical Facet Joint Effusion—A Cadaveric Study 440
Lauren A. Scott

Blinded Versus Ultrasound-Guided Low-Volume Injection of Tibial and Fibular Nerves in Equine Cadaver Limbs 442
Sandro Colla, DVM, MS

How to Use Power Doppler in Musculoskeletal Ultrasonography in the Horse 444
Rob van Wessum, DVM, MS, DACVSMR (EQ)

Comparison of 16-MHz and 9-MHz Ultrasonography to Low-Field Magnetic Resonance Imaging of the Distal Suspensory Apparatus 449
Mathias Ankjær Dinesen, DVM

Surgery and Dentistry

How to Diagnose Equine Odontoclastic Tooth Resorption and Hypercementosis in the Equine 451
Olivia James, BVSc (Hons), MANZCVS (Equine Dentistry), CMAVA, DICEVO, DAVDC (Equine)

Evaluation of Frontal and Infra-Trochlear Nerve Blocks for Frontonasal Sinusotomy in Standing Horses 455
Shyla Giancola, DVM

Medial Femoral Condyle Subchondral Cysts Treated with Transcondylar Lag Screw: Outcome in 58 Quarter Horses 457
María Isabel Calero, DVM

Recurrent Colic: An Important yet Poorly Understood Problem 464
Louise L. Southwood, BVSc, PhD, DACVS, DACVECC

Referral of Horses with Colic: A Time to Review 470
David E. Freeman, MVB, PhD, DACVS

Retrospective Study Evaluating Clinical Outcomes of Foals with Surgical Strangulating Lesions of the Small Intestine 476
Sara J. Erwin, BS

Author Index 478

Subject Index 482

Intra-Articular Therapies in the Field: Traditional Options for Injections

D. Reese Hand, DVM, DACVS

There are multiple options for intra-articular (IA) joint therapy that can safely be used in the field without specialized equipment and be cost effective. Author's address: Equine Sports Medicine and Surgery, 2991 West I-20 South Frontage Road, Weatherford, TX 76086; e-mail: drhand@hotmail.com © 2022 AAEP.

1. Introduction

Intra-articular (IA) injections are one of the most frequently performed procedures in an equine veterinary practice. This practice is performed in hospital and field conditions. Osteoarthritis is the most common reason for IA therapy and is a very common clinical problem in today's horses. The primary goal of IA therapies is to provide symptom modifying and/or disease modifying effects.[1,2] Practitioners are faced with multiple options for IA therapy. Therapies include, but are not limited to, corticosteroids, hyaluronic acid (HA), and a variety of biologicals. It is important to understand the different types of therapies and the use of therapies in specific situations. This discussion will focus on the traditional treatments used for equine IA therapy.

2. Materials and Methods

The specific procedure for injecting a joint will not be discussed in this paper but rather the focus will be on the most common medications and doses used to treat osteoarthritis or synovitis. This discussion will be limited to IA corticosteroids and HAs.

3. Results

From a cross-sectional survey of AAEP members from April to May 2020[3], the following are the results of the most common corticosteroids used: triamcinolone acetonide (TCA), methylprednisolone acetate (MPA) and betamethasone esters (BME). TCA was the most frequently used medication to treat high motion joints. The most common reported dose for TCA ranged from 5–10 mg per joint. Methylprednisolone acetate was the most frequent therapy used in low-motion joints. The most common reported dose of MPA ranged from 20–40 mg per joint followed by 40–80 mg per joint. Betamethasone esters were reported as the third most common corticosteroid used in both high and low motion joints. The most common dose for betamethasone was 4–6 mg/joint followed by 6–12 mg/joint. Isoflupredone acetate and dexamethasone sodium phosphate were also choices for therapy but were used by less than 10% of respondents. The most common reported dose per joint of isoflurane acetate was 5–10 mg and for dexamethasone was 4–10 mg. In the survey, many of the respondents always or occasionally included amikacin when injecting a joint. This dose ranged from 50–125 mg per joint. Recent literature would caution against using amikacin routinely in joint injections

NOTES

however as it has been found to be detrimental to cartilage.[4] The choice of HA or polysulfated glycosaminoglycans (PSGAGs) in combination with corticosteroids is a common practice. There are multiple options available including but not limited to HA and PSGAGs.[a-d] The dose for HA commonly used is 10–22 mg per joint and PSGAGs is 250 mg per joint. Choices of which HA to use is often based on clinical preference, cost, and availability. High motion joints are often treated with higher molecular weight options to improve viscosity and reduce friction[5,6]

Intra-articular injections performed in the field setting have special considerations that differ from those that exist when the patient is treated in a hospital. Attention to sterility should be closely monitored when performing IA injections in the field. Due to these field conditions, many clinicians will often add antibiotics to injections. Additionally, when in the field, availability and accessibility without preparation of the product is an important factor. Many of the specialized or biologicals require special processing or temperature constraints that make it impractical for the field use. For this reason, the ease of off the shelf products such as corticosteroids and HA are appealing for IA treatments in the field. Even though these drugs have been used routinely for decades in horses, inherent risks remain. These include but are not limited to joint sepsis, laminitis, and overall joint impact. Literature will support that septic arthritis is uncommon following IA therapies.[7–9] It has also been found that IA corticosteroids have not been shown to increase the risk of joint infection.[5,6] TCA is one of the most commonly used IA therapies, concerns with its use have been discussed relating to its association with laminitis. Historically, clinicians have stayed below the total body dose of 18 mg due to this association. However, TCA does not appear to increase the risk of laminitis in healthy horses,[10–12,] and a safe total body dose has not yet been established.[3] Doses up to total body dose of 40 mg have been used with no effects of laminits.[10] MPA has been a long-standing joint treatment; however, recent surveys have shown the single joint dose decreasing from 40–80 mg to 20–40 mg per joint.[3] This is largely associated with evidence of harmful effects on cartilage metabolism.[14,15]

4. Discussion

With the growing interest in athletic and pleasure use of horses, the need for management of soreness will continue in the equine patient. Corticosteroids used by themselves or combined with HA or PSGAGs have proven for decades to be successful in managing osteoarthritis as well as synovitis in the equine patient. Overall, the use of corticosteroids is very economical. Even with the combination of HA or PSGAGs, the costs are within most client's budgets to treat their horses. When guidelines are followed, traditional joint therapies are very economical, readily available, and successful for the management of joint conditions in the field.

Acknowledgments

Declaration of Ethics

The Author and the paper have adhered to the Principles of Veterinary Medical Ethics of the AVMA.

Conflict of Interest

The Author has no conflicts of interest and there are no conflicts or financial interests associated with this paper.

References and Footnotes

1. Mcllwraith CW. Licensed medication, "generic" medications, compounding, and nutraceuticals-What has been scientifically validated, where do we encounter scientific mistruth, and where are we legally? in *Proceedings*. Am Assoc Equine Prac 2004;50:459–475.
2. Frisbie DD. Principles of treatment of joint diseases. In: Auer JA, Stick JA, editors. *Equine Surgery*, St. Louis, MO: Saunders, Elsevier 2006 p. 1055-1072.
3. Zanotto GM, Frisbie DD. Current joint therapy usage in equine practice: Changes in the last 10 years. *Equine Vet J* 2021;00:1–7.
4. Pezzanite LM, Hendrickson DA, Dow S, et al. Intra-articular administration of antibiotics in horses: Justifications, risks, reconsideration of use and outcomes. *Equine Vet J* 2022;54:24–38.
5. Gustafson SB, Mcllwraith CW, Jones RL, et al. Comparison of the effect of polysulfated glycosaminoglycan, corticosteroid, and sodium hyaluronate in the potentiation of a sub infective dose of *Staphylococcus aureus* in the midcarpal joint of horses. *Am J Vet Res* 1989;50:2014–2017.
6. Antonacci JM, Schmidt TA, Serventi LA, et al. Effects of equine joint injury on boundary lubrication of articular cartilage by synovial fluid: Role of hyaluronan. *Arthritis Rheum* 2012;64:2917–2926.
7. Steel CM, Pannirselvam RR, Anderson GA. Risk of septic arthritis after intra-articular medication: A study of 16,624 injections in Thoroughbred racehorses. *Aust Vet J* 2013;91:268–273.
8. Smith LCR, Wylie CE, Palmer L, et al. Synovial sepsis is rare following intrasynovial medication in equine ambulatory practice. *Equine Vet J* 2019;51:595–599.
9. Krause DM, Pezzanite LM, Griffenhagen GM, et al. Comparison of equine synovial sepsis rate following intrasynovial injection in ambulatory versus hospital settings. *Equine Vet J* 2022;54: 523–530.
10. McCluskey MJ, Kavenagh PB. Clinical use of triamcinolone acetonide in the horse (205 cases) and the incidence of glucocorticoid induced laminitis associated with its use. *Equine Vet Educ* 2010;16:86–89.
11. Bathe AP. The corticosteroid laminitis story: 3. The clinician's viewpoint. *Equine Vet J* 2007;39:12–13.
12. Haseler CJ, Jarvis GE, McGovern KF. Intrasynovial triamcinolone treatment is not associated with incidence of acute laminitis. *Equine Vet J* 2021;53:895–901.
13. Hammersley E, Duz M, Marshall J. Clinical Research Abstracts of the British Equine Veterinary Association Congress 2015. *Equine Vet J* 2015;47:24–24.
14. Chunekamrai S, Krook LP, Lust G, et al. Changes in articular cartilage after intra-articular injections of methylprednisolone acetate in horses. *Am J Vet Res* 1989;50:1733–1741.
15. Frisbie DD, Kawcak CE, Baxter GM, et al. Effects of 6a-methylprednisolone acetate on an equine osteochondral fragment exercise model. *Am J Vet Res* 1998;59:1619–1628.

[a]Hyvisc, Boehringer-Ingelheim Vetmedica, St. Joseph, MO 64506.
[b]Legend, Merial Inc., Duluth, GA 30096-4640.
[c]Polyglycan, Bimeda, Inc., Oakbrook Terrace, IL 60181.
[d]Adequan, Luitpold Pharmaceutical, Shirley, NY 11967.

How to Use Polyacrylamide Hydrogel as an Intra-Articular Therapy

Scott McClure, DVM, PhD, DACVS, DACVSMR

Author's address: Midwest Equine Surgery and Sports Medicine, 2615 Eastgate Drive, Boone, IA 50036; e-mail: srmeqdr@gmail.com. © 2022 AAEP.

1. Introduction

Polyacrylamide hydrogels (PAHGs) are 3-dimensional structures of acrylamide that can be made with variable degrees of cross-linkages, resulting in a wide range of physical properties.[1] These hydrogels are inert and biocompatible, giving them many applications ranging from gel electrophoresis to tissue augmentation. Polyacrylamide hydrogels have been shown to exhibit low coefficients of friction and have been used for contact lenses and as acellular cartilage implants.[2,3] Viscosupplementation has been an objective of intra-articular therapy for management of osteoarthritis, and PAHGs can provide a synthetic joint lubrication. The objective of viscosupplementation is to restore the normal lubrication in joints with inflammation and cartilage surface damage.

Polyacrylamide hydrogels are being utilized as a device for intra-articular lubrication in both humans[4,5] and horses.[6-8] This inert material has mechanical properties similar to normal synovial fluid and has recently been shown to effectively decrease friction in both mechanical and interleukin-1β–induced surface-damaged cartilage.[9,10] The polyacrylamide hydrogels have been shown to decrease lameness in horses for prolonged periods of time after treatment administration.[7,8]

A prospective study of polyacrylamide hydrogel for the treatment of osteoarthritis in 43 horses reported a significant decrease in lameness; 82.5% of the 43 horses were sound at the 2-year follow-up.[6] In 12 horses with proximal interphalangeal joint osteoarthritis, 8 horses were sound 6 months after treatment.[7] Both of these studies utilized a 2.5% polyacrylamide material designed to be a bulking agent. Another polyacrylamide hydrogel being used in humans with osteoarthritis consists of 4% polyacrylamide, and this polymer was specifically designed to be minimally reactive in the joint.[8] In this study of 28 horses that met inclusion criteria, there was a significant ($P < .001$) decrease in median lameness score with 23 of 28 (82%) horses improved based on study criteria.

The PAHGs are often discussed interchangeably, but the manufacturers agree that they may not act similarly. A common misunderstanding is that the difference between the 2 commercially available materials is the concentration. One product is a 4% PAHG[a] and the other a 2.5% PAHG.[b] However, the reason there is a wide range of applications of PAHGs is because they can be very different based on monomer content and percent cross-linkage.[11] There is not a direct comparison available, but published histologic evaluation of synovial membranes from joints treated with the 2 products is dissimilar.[12,13] The 4% PAHG[a] has been shown to adhere to the cartilage and synovial membrane surface and remain on the surface, particularly in areas of damaged cartilage.[10,12] The 2.5% PAHG[b] has been noted to be within the synovial membrane with multiple macrophagic cells for prolonged periods of time.[13]

NOTES

2. Case Selection

As a newer therapy, initial case selection tended toward chronic osteoarthritic horses refractory to multiple therapies. The general trend was that these horses would improve approximately 1 lameness grade following treatment and maintain that improvement for 90 to 120 days. As veterinarians became more knowledgeable of the PAHGs, the trend has been toward treating horses earlier in the disease process. Horses that have been treated 1 to 2 times with more traditional hyaluronic acid and corticosteroids may now be treated with PAHG before the osteoarthritis progresses further. Based on anecdotal reports, most joints in the horse have been treated with PAHG. Some of the more common applications are noted below.

The metacarpo/metatarsophalangeal joints in both sport and racehorses may be the most frequently treated joints, likely because of the incidence of pathology. There may be some thickening or filling of the joint notable in the palmar/plantar pouches after treatment that persists 2 to 4 weeks after administration. Repeated administration of 4% PAHG[a] up to 4 times at 45-day intervals in metacarpophalangeal joints did not result in any negative effects on cartilage, synovium, or biomarkers of cartilage metabolism.[c] Distal interphalangeal joints in sport horses may be the next most common application.

Due to the large size of the stifle joint, some practitioners have used a "double dose" of PAHG when treating stifles. When utilizing 4% PAHG,[a] the 2.5-mL dose should be an adequate volume to coat the articular surfaces, so a single dose is likely adequate. On the other end of the scale, tarsometatarsal and distal intertarsal joints are likely well coated with 1 mL of PAHG. Similarly, when managing bilateral navicular syndrome cases, a syringe may be split between the 2 bursae.

3. Administration

Since PAHGs tend to be more viscous than most materials clinicians are used to administering, the "feel" of the material going readily into the joint is different. Larger gauge needles, 18 or 19 ga, are indicated to improve ease of administration. Smaller gauge needles can be used, though the injection should be done slowly and with care to avoid displacing the needle or disconnecting the needle from the syringe due to pressure. The PAHG is not eliminated quickly as would a periarticular corticosteroid, so confirmation of intra-articular placement is useful.

It is not expected that PAHGs carry an elevated risk for infection following intra-articular injection. The addition of antibiotics can be considered, however, based on the clinician's preference. Due to their inert and insoluble characteristics, PAHGs are not known to interact with intra-articular antibiotics commonly utilized in the horse and have been seen combined in some studies.[14] Standard aseptic site preparation, with sterile injection technique, remains the most important method to prevent contamination of the injection site.

Corticosteroids are commonly utilized intra-articular, often in combination with viscosupplements, to control pain and inflammation. There are no known corticosteroid/PAHG combinations that cause interactions between the products. Concurrent administration has been reported by clinicians using PAHG, though no formal investigation has been performed. It is suggested by 2.5% PAHG[b] to avoid concurrent corticosteroid administration with their product to prevent downregulating synovial fibroblasts, which encourage cellular proliferation and vessel ingrowth across the gel incorporated into the synovial membrane. The 4% PAHG[a] is dissimilar in its interaction with the synovial membrane; therefore, this mechanism is not relevant when considering its administration with corticosteroids.[12,13] A double-blinded positive controlled study comparing 2.5% PAHG,[b] sodium hyaluronate, and triamcinolone acetonide found that 2.5% PAHG[b]-treated carpal joints produced significantly more lame-free horses at 4 weeks and 6 weeks postinjection ($P = .042$, $P = .019$, respectively) than hyaluronate or triamcinolone.[15]

It is recommended that horses are rested for 2 to 3 days, followed by walking exercise for a week, and then low-impact exercise with a gradual return to full exercise over 2 to 3 weeks. This is a longer period than many therapies, but the response to therapy does not occur rapidly. Response to treatment varies. Some cases show improvement within days after injection, while others may take up to 30 days. Generally, a gradual improvement is seen between 1 and 3 weeks. If some improvement is noted, but the lameness is not eliminated, the veterinarian should consider a second dose at 5 to 6 weeks after the initial injection.

4. Limitations

Polyacrylamide is not a quick fix for lameness. Horses require some rest following therapy, and there may be a slow improvement over 2 to 3 months. Injection technique is important to ensure the PAHG is within the synovial cavity.

There have been a few horses that have had an increased lameness for 2 to 4 weeks following administration. There are 2 potential causes of this, and both may be correct. Periarticular administration can result in swelling and effusion. The PAHG is hydrophilic, resulting in a filling of the joint space. The PAHG in 2.5% PAHG[b] was designed as a tissue filler, so it will remain in the subcutaneous tissue an extended period. Second, there is the occasional horse that will have an increased lameness and synovitis after work, in the first week or two after treatment. Two plausible explanations for this are impingement of the synovium that may be thicker following administration of the PAHG and pushing of the PAHG into

subchondral defects. Overall, knowledge is still limited relative to some of the other joint therapies.

5. Conclusions

The understanding of how and when to utilize PAHGs is rapidly evolving. Case selection, injection technique, and post-treatment-controlled exercises are important to successfully add these materials to any practice. There are differences in the PAHGs available, so veterinarians need to be familiar with the product they are using and how to best utilize the material.

Acknowledgments

Declaration of Ethics

The Author has adhered to the Principles of Veterinary Medical Ethics of the AVMA.

Conflict of Interest

The Author has completed research funded by Nucleus Regenerative Therapies.

References and Footnotes

1. Baker BA, Murff RL, Milam VT. Tailoring the mechanical properties of polyacrylamide based hydrogels. *Polymer* 2010;51(10):2207–2214.
2. Bonyadi SZ, Atten M, Dunn AC. Self-regenerating compliance and lubrication of polyacrylamide hydrogels. *Soft Matter* 2019;15(43):8728–8740.
3. Dunn AC, Sawyer WG, Angelini TE. Gemini interfaces in aqueous lubrication with hydrogels. *Tribol Lett* 2014; 54(1):59–66.
4. Zar VV, Zagorodniy NV, Martinov DV. Effectiveness and safety of injectable endoprosthetics of synovial fluid by cross-linked polymer Noltrex for treatment OA knee. *Eur J Muscl Dis* 2012;1:23–32.
5. Zargorodny NV, Karpovich NI, Abdulkhabirov MA, et al. New biopolymer medical device named Noltrex in combine treatment of gonarthrosis. *Zemskiy Vrach* 2012;6:49–52.
6. Tnibar A, Schougaard H, Camitz L, et al. An international multi-centre prospective study of the efficacy of an intraarticular polyacrylamide hydrogel in horses with osteoarthritis: A 24 months follow-up. *ACTA Vet Scand* 2015;57:1–8.
7. Janssen I, Koene M, Lischer C. Intraartidulare applicakation von polyacrylamide hydrogel zur behandlung von osteoarthritis des hufgelenkes: Fallserie von 12 pferden. *Pherdeheilkunde* 2012;28:650–656.
8. McClure SR, Wang C. A preliminary field trial evaluating the efficacy of 4% polyacrylamide hydrogel in horses with osteoarthritis. *J Equine Vet Sci* 2017;54:98–102.
9. Zar VV, Troitsky VM, Stepanov AI, et al. Future of viscoelastic behavior of 3-D structure of artificial and natural samples of articular liquids at the pressure 0.1–100 MPa. Materials of 16th chemical thermodynamics international conference. Vol. 1. Suzdal, 2.
10. Vishwanath K, McClure, Bonassar LJ. Polyacrylamide hydrogel lubricates cartilage after biochemical degradation and mechanical injury [published online April 5, 2022]. *J Orthop Res*.
11. Denisin AK, Pruitt BL Tuning the range of polyacrylamide gel stiffness for mechanobiology applications. *ACS Appl Mater Interfaces* 2016;8:21893–21902.
12. McClure SR, Yaeger M, Wang C. Clinical and histologic evaluation of polyacrylamide gel in normal equine metacarpal/metatarsal-phalangeal joints. *J Equine Vet Sci* 2017;54:70–77.
13. Christensen L, Camitz L, Illigen KE, et al. Synovial incorporation of polyacrylamide hydrogel after injection into normal and osteoarthritic animal joints. *Osteoarthritis Cartilage* 2016;24:1999–2002.
14. de Clifford LT, Lowe JN, McKellar CD, et al. Use of a 2.5% cross-linked polyacrylamide hydrogel in the management of joint lameness in a population of flat racing Thoroughbreds: A pilot study. *J Equine Vet Sci* 2019;77:57–62.
15. de Clifford LT, Lowe JN, McKellar CD, et al. A double-blinded positive control study comparing the relative efficacy of 2.5% polyacrylamide hydrogel (PAAG) against triamcinolone acetonide (TA) and sodium hyaluronate (HA) in the management of middle carpal joint lameness in racing Thoroughbreds. *J Equine Vet Sci* 2021;107:103780.

[a]Noltrex®Vet, RC Bioform, LLC, Moscow, Russia.
[b]Arthramid® Vet, Contura International A/S, 2860, Søborg, Denmark.
[c]McClure SR, unpublished data, January 2022.

How to Use Stanozolol as an Intra-Articular Therapy

Scott McClure, DVM, PhD, DACVS, DACVSMR

Author's address: Midwest Equine Surgery and Sports Medicine, 2615 Eastgate Drive, Boone, IA, 50036; e-mail: srmeqdr@gmail.com. © 2022 AAEP.

1. Introduction

Stanozolol is a synthetic anabolic steroid that can reduce inflammatory processes and act on synoviocytes and chondrocytes promoting anabolic processes when administered intra-articular.[1] Stanozolol acts via local autocrine response stimulating production of anabolic growth factors. Stanozolol reduces apoptosis in equine chondrocytes in vitro by a combination of stimulating insulin-like growth factor-1 production and decreasing nitric oxide production.[1] In vitro gene expression of inflammatory mediators matrix metallopeptidase-13, matrix metalloproteinase-1, interleukin-6, and cyclooxygenase-2 was decreased in normal and interleukin-1β-exposed equine chondrocytes.[2] In humans with chronic osteoarthritis, decreased joint pain was associated with increased transforming growth factor-β1 (TGF-β1).[3] One in vitro study demonstrated that there was a dose-dependent increase in matrix production stimulated by increased TGF-β1 synthesis with the inclusion of stanozolol.[4]

A dose response study utilizing doses of 1, 2.5, and 5 mg of stanozolol in the metacarpophalangeal joint has been completed.[5] During the study, the authors noted mild increase in effusion in the joints that had been treated with stanozolol. All horses in the study started with a baseline lameness of 2/5 utilizing the AAEP lameness grading scale. Outcome was time to a decrease of lameness by at least 1 grade. The results showed that these lamenesses were improved at all 3 of the dosages of intra-articular stanozolol. However, the lamenesses improved the fastest following the 5-mg dose administered twice, 1 week apart, resulting in 5 of 6 horses with a lameness score of 0 or 1. The lameness decreased by more than 50% at all doses after 4 injections.

An abstract published in 2012, on the retrospective evaluation of the use of stanozolol in performance horses, evaluated 60 horses, 50 being racehorses, many of which were refractory to previous treatments.[6] Horses received a mean of 4 treatments of 5 mg intra-articular at weekly intervals. There was greater than 6-month follow-up available for 77% of the cases. There were no adverse reactions and a beneficial effect in 39% of cases, uncertain in 39%, and not beneficial in 22%. In another study that was double blinded, weekly intra-articular doses of 5 mg of stanozolol were administered to horses with acute and chronic osteoarthritis.[7] Acute osteoarthritis was defined as less than 1 month of symptoms, with chronic osteoarthritis being more than 1 month of symptoms. The maximum treatment period was 21 days and 35 days for acute and chronic groups, respectively. A positive outcome was at least a 1-grade reduction in AAEP lameness score. The lameness score was 0/5 in 15 of 21 horses in the acute group after 2 treatments and in 7 of 19 horses in the chronic group after 4 treatments. They also examined the quality of the synovial fluid at the time of each injection, which was considered to be subjectively normal only in the acute group after the third

NOTES

treatment. Similar to what was noted by Rinnovati et al. in the dose response study, there was a mild swelling of the treated joints for a few days after treatment that regressed rapidly and spontaneously and did not require intervention.

2. Case Selection

Because stanozolol is not a mainstream therapeutic with Food and Drug Administration approval, much of the information provided here is opinion from veterinarians rather than evidence-based. In the author's opinion, stanozolol is an underutilized intra-articular therapy, likely a result of limits of availability and controlled substance regulations and performance-enhancing drug testing regulations. Stanozolol should not be considered a quick fix as the overall goal of stanozolol is for it to allow healing of the joint including cartilage, synovium, subchondral bone cartilage, and associated ligaments and menisci. Therefore, this therapy should include a rest and rehabilitation schedule. In most cases, a series of injections are performed at weekly or greater intervals. With these factors in mind, the author feels the two more common applications are osteochondrosis lesions in young horses and performance horses with lameness localized to the joint but less likely to have osteoarthritic degeneration to the point that returning the joint to normal function is unlikely.

Subchondral cysts of the medial femoral condyle, when identified in young horses, anecdotally have been one of the more frequent uses of stanozolol. Early screening of western performance horses for subchondral cysts is frequently performed due to the relatively high incidence in this population. Resolution of the cysts have been reported anecdotally following serial intra-articular administration of stanozolol. Administration of stanozolol into the lining of the subchondral cyst via ultrasound guidance or during arthroscopy is also discussed, and this may also be done in concert with a transcondylar screw. Furthermore, in the author's opinion, the application of stanozolol in horses with meniscal injuries in conjunction with rest and a rehabilitation program may provide a positive outcome.

Racehorses with palmar/plantar osteochondral disease can be difficult to confirm diagnostically and are consistently difficult to manage. Anecdotal reports of 5-mg weekly serial intra-articular stanozolol treatments and a controlled exercise program have improved the likelihood of return to performance of these horses.

3. Administration

It is important that the 5 mg/mL micronized stanozolol in suspension be used for intra-articular administration. The micronized particle size is used for intra-articular therapy because the large crystals in the intramuscular product may potentially damage the joint. Stanozolol is frequently dispensed in a 5-mL vial, with 5-mg/mL concentration. With a 5-mg dose, there are multiple doses in a vial. The suspension needs to be established by agitation of the vial prior to drawing a dose from the bottle. The micronized stanozolol is not viscus and is easily administered with routine intrasynovial injection techniques. There can be some increased joint effusion following treatment, as noted in the two studies above.[6,7] There will be an occasional flare that can be managed with phenylbutazone and ice. The coadministration of a corticosteroid may inhibit the desired anabolic pathways, so this is not routinely performed. It is utilized with and without the addition of hyaluronic acid, and the addition of antimicrobials can be done based on the veterinarian's preference.

4. Limitations

The primary limitations to stanozolol use are availability and controlled substance requirements in addition to the lack of large case-controlled studies. There is not a major manufacturer source available in the United States. In Europe, stanozolol is commercially available.[a] In the United States, 5 mg/mL micronized stanozolol is available from compounding pharmacies. The compounding pharmacy guidelines can require extensive information about the patient/client that is being treated. The pharmacies must be licensed to ship to the practitioner's state, so this can also be a limiting factor. Stanozolol is a prohibited substance in many testing jurisdictions because of the anabolic effects of larger doses administered intramuscularly. Stanozolol is banned by the Fédération Équestre Internationale. It is a prohibited substance with the United States Equestrian Federation with an estimated 47-day withdrawal. Stanozolol is prohibited or banned in most racing jurisdictions, potentially uniform rules will provide more consistent guidelines. The potential effects of international travel and sales of horses need to be considered.

A typical systemic dose administered intramuscularly is 0.55 mg/kg, resulting in the administration of 250 mg or more.[8] Systemic doses administered intramuscularly can be detected for prolonged periods of time. The administration of 5 mg micronized stanozolol intra-articular is detected in plasma for a relatively brief time, but contamination, injection technique, and combination therapy can all potentially result in violation of foreign substance rules. The disposition of stanozolol in plasma after intra-articular administration of 5 mg stanozolol administered into both the right and left tarsocrural joints of 12 sound horses was determined.[9] The drug was quickly found in systemic circulation and was eliminated rapidly and could not be detected after 36 hours following intra-articular administration. Particle size of the stanozolol, joint health, periarticular administration, and additional factors can all result in a different outcome following administration.

5. Conclusion

Stanozolol can be a useful component for managing joint disease. It is an affordable disease-modifying drug. Commonly used corticosteroids are potent anti-inflammatories that can be beneficial in the management of joint disease. Stanozolol has some anti-inflammatory effects but also stimulates production of anabolic cytokines including insulin-like growth factor-1 and TGF-β1. The veterinarian needs to be aware of forbidden substance regulations when utilizing stanozolol.

Acknowledgments

Declaration of Ethics

The Author has adhered to the Principles of Veterinary Medical Ethics of the AVMA.

Conflict of Interest

The Author has no conflicts of interest.

References and Footnote

1. Saleri R, Dondi M, Bianchi E. Stanozolol inhibits nitric oxide production by horse chondrocyte cell culture. *Bone* 2004;34:34–73.
2. Martins MC, Peffers MJ, Lee K, et al. Effects of stanozolol on normal and IL-1β-stimulated equine chondrocytes in vitro. *BMC Vet Res* 2018;14:103.
3. Shehata M, Schwarzmeier JD, Hilgarth M, et al. Effect of combined spa-exercise therapy on circulating TGF-beta1 levels in patients with ankylosing spondylitis. *Wien Klin Wochenschr* 2006;118:266–772.
4. Falanga V, Greenberg AS, Zhou L, et al. Stimulation of collagen synthesis by the anabolic steroid stanozolol. *J Invest Dermatol* 1998;111:1193–1197.
5. Rinnovati R, Romagnoli N, Spadari A. Dose-finding study for intra articular treatment with Stanozolol in horses. *J Equine Vet Sci* 2015;35:860–864.
6. Ramzan P, Somerville G, Shepherd M, et al. Preliminary clinical impressions on the use of stanozolol as a novel intra-articular therapy for athletic horses: 60 cases. Proceedings of *the European Veterinary Conference – Voorjaarsdagen*. Amsterdam, the Netherlands, April 7, 2012.
7. Spadari A, Rinnovati R, Babbini S, et al. Clinical evaluation of intra-articular administration of Stanozolol to manage lameness associated with acute and chronic osteoarthritis in horses. *J Equine Vet Sci* 2015;35:105–110.
8. Moeller BC, Sams RA, Guingab-Cagmat JD, et al. Pharmacokinetics of stanozolol in Thoroughbred horses following intramuscular administration. *J Vet Pharmacol Ther* 2013;36:201–204.
9. Romagnoli N, Zaghini A, Fedrizzi G, et al. Disposition of Stanozolol in plasma after intra-articular administration in the horse. *J Equine Vet Sci* 2016;47:16–19.

[a]Sungate®, ACME, Cavriago, Italia.

The Use of Intra-Articular Alpha-2 Macroglobulin in Ambulatory Practice

Christina Russillo, DVM*; Hannah Jarvis, DVM; Abigail Atkins, DVM; Susan Johns Price, DVM; John Caldwell, DVM; and A. Kent Allen, DVM

Authors' address: Virginia Equine Imaging, 2716 Landmark School Road, The Plains, VA 20198; e-mail: crussillovei@gmail.com. *Corresponding and presenting author. © 2022 AAEP.

1. Introduction

Osteoarthritis and inflammatory joint disease are common causes of lameness and poor performance in sport horses.[1,2] This degenerative process is largely driven by upregulation of cartilage matrix degrading proteases and proinflammatory cytokines within the affected joint.[3] These inflammatory mediators and catabolic processes result in the loss of articular cartilage, leading to pain and further degradation of the joint.[3]

The traditional use of steroid injections into joints affected with osteoarthritis has been hypothesized to have deleterious effects on cartilage over time, as well as other endocrine related side effects, which limits their judicious use in equine practice.[4–6] More recently, a variety of orthobiologics have become available for equine practitioners to treat inflamed joints, but most are not designed to directly target the active process that leads to cartilage degradation.[2,7–9]

Alpha-2 macroglobulin (A2M) has recently emerged as a potential treatment of cartilage-based pathology and inflammatory arthritides due to its chondroprotective effects.[10] The treatment of joint- and disk-related injuries with concentrated A2M has been well documented in human, canine, and equine medicine.[11–13] A2M is a large (720 kD), acute phase protein that is a part of the innate immune system.[14] It is a negative regulator of catabolic factors associated with inflamed joints.[10] A2M's major functions include the nonspecific inhibition of all 4 classes of proteases: cysteine, serine proteases, aspartic, and metalloproteinases.[15] Additionally, A2M can affect cytokine modulation and gene regulation.[10,16]

Notably, the A2M molecule has the unique ability to inhibit the inflammatory cascade by baiting and trapping the harmful proteases that are responsible for cartilage catabolism.[17] The matrix metalloproteinase (MMP) and a disintegrin metalloproteinase 7 with thrombospondin motif (ADAMTS) are integral in the process of articular cartilage degradation, and studies have shown that A2M inhibits these degrading enzymes in a concentration-dependent manner.[17–21] After binding proteases, the A2M molecule undergoes a conformational change to allow it to be removed from circulation through phagocytosis and excreted via the bloodstream.[22] A2M has also been demonstrated to bind to proinflammatory cytokines, most notably IL-1 and TNF-α, within the synovial fluid of inflamed equine joints (Fig. 1).[10,12,22–24]

A2M is mainly synthesized by hepatocytes and in smaller amounts by macrophages, synoviocytes, and articular cartilage.[10] There are higher levels of A2M in plasma in comparison to synovial fluid in part due to the large molecular weight of A2M, which prevents its diffusion into the joint.[10] In order to isolate and concentrate the A2M molecule, blood is collected from that patient and is then spun and filtered using an Alpha2EQ mini kit.[a] This is a portable, point-of-care

NOTES

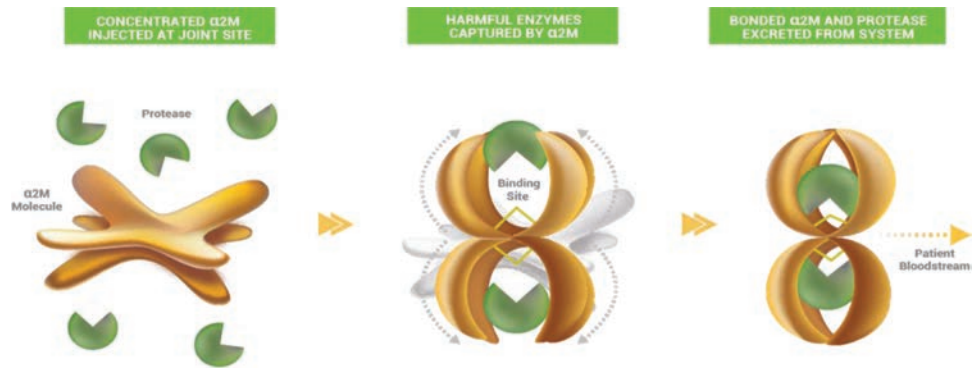

Fig. 1. Alpha-2 macroglobulin mechanism of protease inhibition via "bait and trap."

system that allows practitioners to collect, process, and treat affected equine joints within 60 minutes.

2. Materials and Methods

Considerations

For best results, a 3-day washout period following administration of alpha-2 agonist sedatives and a 5-day washout period following administration of nonsteroidal anti-inflammatory drugs should be observed.[b] There are no known negative interactions with bisphosphonate medications, shockwave therapy, or laser therapy.

The portable centrifuge and processing equipment should be set up in a clean, enclosed environment, such as an exam or tack room. The provided sterile drape should be laid out over a work surface (the author of this paper often uses a table or the centrifuge's travel case as a work surface) and the contents of the Alpha 2EQ MiniKit[b] laid out. Before prepping for blood collection, it is recommended to organize the equipment so that the blood can be processed efficiently after collection. Necessary processing equipment, except for ACD-A,[c] and step-by-step instructions are included in the kit.

Blood Collection

The patient's jugular vein should be aseptically prepped for blood draw. Then, 6 mL ACD-A should be drawn into two 60-mL syringes using sterile technique. Using a 19-gauge or larger needle or butterfly, perform sterile venipuncture and carefully draw 34 mL of blood for a total volume of 40 mL. Disconnect the syringe, recap, and invert 7 times to adequately mix the blood and anticoagulant before recapping and setting aside on a sterile field. Repeat these steps for the second 60-mL syringe. After blood has been collected for processing, the horse may be sedated and anti-inflammatory medications can be used, including at the time of administration. Once blood has been collected, it should be processed within 30 minutes.

Processing

Sterilely connect the 60-mL syringes to a 1.5-inch blunt needle. Dispense 10 mL of the anticoagulated blood into each of the 8 vacutainer tubes provided. In a balanced manner, place all 8 filled vacutainers into the centrifuge, and close and lock the centrifuge lid. Select 3400 rpm for 10 minutes and ensure that the brake is disengaged before pressing "Start." Once this spin cycle is complete, remove each vacutainer one at a time, alcohol wipe the septum, and connect the vacutainer to the vacutainer access device. Using the stopcock attached to the vacutainer access device, aspirate the plasma from each of the 8 vacutainers.

To begin the concentration process, remove the 2 conical tubes from their sterile packaging and place in the provided stabilization holders. Then, remove the 50-mL syringe that contains the plasma from the vacutainer access device and attach a 4-inch aspiration needle to the syringe. Inject 19 mL of the plasma into each of the 2 conical tubes. Any additional plasma left in the syringe may be discarded. Next, place the conical tubes into the conical tube holders in the centrifuge using a balanced technique. Again, select 3400 rpm for 10 minutes and ensure that the brake is disengaged before pressing "Start." Immediately following the spin cycle completion, place the conical tubes into the stabilization holders. Using an alcohol wipe, swipe off the septum of each conical tube. Then, connect a 4-inch aspiration needle to a new 50-mL syringe and draw off the concentrated plasma into the syringe, taking care not to aspirate the last 1 mL above the filter of the concentrated plasma. Typically, the volume of Alpha2EQ injectate obtained is between 29 and 32mL. Use a sterile female adapter to transfer the Alpha2EQ from the 50-mL syringe into smaller syringes. The choice of syringe size and volume of injectate can be tailored to the patient's treatment plan. Once processed, the Alpha2EQ product is stable for up to 4 hours at room temperature or for up to 12 hours if it is stored in the refrigerator. Based on results of comparative Trypsin assays, the biological activity of the molecule has been validated after storage at –18°C for up to 6 months. Further testing is ongoing to establish viability of the molecule at 1 year.[d]

Storage

Any excess Alpha2EQ injectate that will not be immediately used can be stored in a capped syringe or vial in a

Table 1. Volumes of Alpha2EQ Used for Various Equine Joints

Volume for Injections			
Site	Volume	Site	Volume
Cervical facets	2–4 cc	Navicular bursa	2–3 cc
Digital sheath	4–8 cc	Tibiotarsal joint	4–5 cc
Distal interphalangeal joint	3–5 cc	Sacroiliac	5–10 per site
Fetlock	4–5 cc	Small tarsal joints	2–3 cc
Intralesional/perilesional	Varies on site	Medial femoral tibial	8+ cc

residential freezer at –18°C. The authors of this paper recommend storing the unused injectate in 4-mL aliquots using 6-mL syringes that have been drawn back to 5 mL to allow for expansion during freezing and then placed in a sterile sleeve. The sterile sleeve or other container should be labeled with the patient information and expiration date prior to storage.

Injection Therapy

In order to determine which joints would benefit from intra-articular therapy of Alpha2EQ, a thorough clinical examination should be performed with particular attention paid to degree of lameness, joint effusion, and diagnostic imaging findings.[1,25] In Table 1, the volumes of Alpha2EQ used for various equine joints are summarized. All injections are administered using standard intra-articular and intralesional injection technique.

3. Results

To establish the efficacy of joint injection therapy using Alpha2EQ, the results from intra-articular joint therapy using Alpha2EQ performed by the author's clinic between January 2020 and September 2021 were evaluated. There was a total of 180 individual horses and 893 individual injections performed. Across these cases, there was only 1 reported case of a joint flare. Table 2 summarizes the number and sites of the injections.

Three injection sites were chosen to further evaluate based on the ease of ability to compare clinical parameters: the distal interphalangeal (DIP) joint, the tarsometatarsal and distal intertarsal joints, and the cervical dorsal articular facet joints. The following selection criteria were applied to the new data set: horses must have been in active training at the time of injection, horses could not have received adjunct treatments (such as shockwave), and horses could not have received any additional injection therapies in the same limb. All horses were presented for a recheck examination within 8 weeks of injection. The clinical parameters evaluated included joint effusion, lameness grade according to the American Association of Equine Practitioners (AAEP) scale, response to flexion test, and pain on palpation. A scoring system based on clinical examination findings was applied to numerically represent findings (Table 3).

Table 2. Summary of Number and Sites of Injections

Joint Injections with Alpha2EQ			
Site	No. of Injections	Site	No. of Injections
Bursa	31	Coffin	133
Pastern	8	Fetlock	81
Carpus	13	Elbow	3
Shoulder	3	Hock	221
Stifle	52	Back	106
Sacroiliac	44	Neck	173
Tendon sheaths	11	Soft tissue	14

Distal Interphalangeal Joint

A total of 38 coffin joint injections on 19 horses were analyzed and 78.9% of those cases had improvement in at least one clinical parameter. The average initial effusion score was 2.3, and the average postinjection effusion score was 1.3. The average initial lameness grade was 1.4 and the average postinjection lameness grade was 0.5.

Tarsometatarsal and Distal Intertarsal Joints

A total of 28 sets of injections on 14 horses were analyzed. All horses presented for bilateral lower hock joint injection therapy for sport-associated distal tarsitis. Horses were excluded if there was concurrent concern for soft tissue injury in the pelvic limb. Overall, 85.7% had improved flexion responses. At recheck examination, 57.2% of the horses had 1 grade of improvement and 10.7% of horses had 2 grades of improvement to flexions.

Cervical Dorsal Articular Facet Joint

A total of 48 dorsal articular facet joint injections on 14 horses were analyzed. Pain improved on 71.4% of cases and 42.9% improved 2 grades, 17.8% improved 1 grade, and 10.7% improved 3 grades.

4. Discussion

The advent of the Alpha2EQ mini kit[a] provides equine ambulatory practitioners with a portable, easy-to-use mechanism to isolate and concentrate A2M for intra-

Table 3. Scoring System

0	Sound/no significant findings
1	Mild
2	Mild to moderate
3	Moderate
4	Moderate to severe
5	Severe

articular injection. There are additional advantages of this orthobiologic for managing inflammatory joint disease when compared to alternative products on the market, namely, the large injectate volume achieved and stability as a frozen product for up to 6 months or more. As an orthobiologic, Alpha2EQ offers a nondoping approach to managing inflammatory synovitis, which is an advantage for clients competing in high-performance equine sport. The mechanisms of action of the molecule are not impacted by the use of sedatives and nonsteroidal anti-inflammatory medications at the time of treatment. Based on results within a population of sport horses competing in various disciplines, injection therapy with Alpha2EQ has proven to be effective at managing acute and chronic inflammatory synovitis. Specifically, there was a reduction in lameness as well as joint effusion and there was improvement of flexion test response and a reduction of pain on palpation. Since these data were compiled retrospectively, there was no case control comparison, which the authors recognize is a limitation on the results. However, the veterinarians involved were senior practitioners in an established sports medicine practice that follows a uniform examination protocol and uses the accepted AAEP lameness scale.

Acknowledgments

Declaration of Ethics

The Author has adhered to the Principles of Veterinary Medical Ethics of the AVMA.

Conflict of Interest

Dr. Christina Russillo has served on the scientific advisory board of Astaria Global since 2020. Dr. A. Kent Allen has served on the scientific advisory board of Ataria Global since 2020. Astaria Global is the parent company that manufactures the Alpha2EQ mini kit. Drs. Hannah Jarvis, Abigail Atkins, Susan Johns Price, and John Caldwell have no conflicts of interest. There has been no financial compensation in exchange for the use of the Alpha2EQ mini kit.

References and Footnotes

1. McIlwraith CW, Frisbie DD, Kawcak CE. The horse as a model of naturally occurring osteoarthritis. *Bone Joint Res* 2012;1:297–309.
2. Caron JP. Intra-articular injections for joint disease in horses. *Vet Clin North Am Equine Pract* 2005;21:559–573.
3. Loeser RF, Goldring SR, Scanzello CR, et al. Osteoarthritis: A disease of the joint as an organ. *Arthritis Rheum* 2012;64: 1697–1707.
4. McIlwraith VW. Review of the scientific basis for use of intra-articular corticosteroids in the horse, in *Proceedings*. Am Assoc Equine Pract 2010;56:19–23.
5. Bailey SR. Corticosteroid-associated laminitis. *Vet Clin North Am Equine Pract* 2010;26:277–285.
6. McIlwraith CW. The usefulness and side effects of intra-articular steroids: What do we know?, in *Proceedings*. Am Assoc Equine Pract 1992;38:21–30.
7. Linardi RL, Dodson ME, Moss KL, et al. The effect of autologous protein solution on the inflammatory cascade in stimulated equine chondrocytes. *Front Vet Sci* 2019;6:64.
8. Garbin LC, Olver CS. Platelet-rich products and their application to osteoarthritis. *J Equine Vet Sci* 2020;86:102820.
9. Frisbie DD, Kawcak CE, Werpy NM, et al. Clinical, biochemical, and histologic effects of intra-articular administration of autologous conditioned serum in horses with experimentally induced osteoarthritis. *Am J Vet Res* 2007;68:290–296.
10. Wang S, Wei X, Zhou J, et al. Identification of alpha2-macroglobulin as a master inhibitor of cartilage-degrading factors that attenuates the progression of posttraumatic osteoarthritis. *Arthritis Rheumatol* 2014;66:1843–1853.
11. Enghild JJ, Salvesen G, Brew K, et al. Interaction of human rheumatoid synovial collagenase (matrix metalloproteinase 1) and stromelysin (matrix metalloproteinase 3) with human Alpha2-Macroglobulin and chicken ovostatin. *J Biol Chem* 1989;264:8779–8785.
12. Garner BC, Kuroki K, Stoker AM, et al. Expression of proteins in serum, synovial fluid, synovial membrane, and articular cartilage samples obtained from dogs with stifle joint osteoarthritis secondary to cranial cruciate ligament disease and dogs without stifle joint arthritis. *Am J Vet Res* 2013;74:386–394.
13. Cote N, Trout DR, Hayes MA. Interaction of transforming growth factor beta-1 with Alpha2-Macroglobulin from normal and inflamed equine joints. *Can J Vet Res* 1998;62:279–286.
14. Buresova V, Hajdusek O, Franta Z, et al. IrAM—An alpha2-macroglobulin from the hard tick Ixodes ricinus: Characterization and function in phagocytosis of a potential pathogen Chryseobacterium indologenes. *Dev Comp Immunol* 2009;33: 489–498.
15. Verma S, Dixit R, Pandey KC. Cysteine proteases: Modes of activation and future prospects as pharmacological targets. *Front Pharmacol* 2016;7:107.
16. Borth W. Alpha2-Macroglobulin, a multifunctional binding protein with targeting characteristics. *FASEB J* 1992;6: 3345–3353.
17. Barrett AJ, Starkey PM. The interaction of alpha2-macroglobulin with proteinases. *Biochem J* 1973;133:709–724.
18. Liu C-J. The role of ADAMTS-7 and ADAMTS-12 in the pathogenesis of arthritis. *Nat Clin Pract Rheumatol* 2009 ;5:38–45.
19. Burrage PS, Mix KS, Brinckerhoff CE. Matrix metalloproteinases: Role in arthritis. *Front Biosci* 2006;11:529–543.
20. Luan Y, Kong L, Howell DR, et al. Inhibition of ADAMTS-7 and ADAMTS-12 degradation of cartilage oligomeric matrix protein by alpha2-macroglobulin. *Osteoarthritis Cartilage* 2008;16:1413–1420.
21. Tortorella MD, Arner EC, Hills R, et al. Alpha2-Macroglobulin is a novel substrate for ADAMTS-4 and ADAMTS-5 and represents an endogenous inhibitor of these enzymes. *J Biol Chem* 2004;279:17554–17561.
22. Rehman A, Ahsan H, Khan F. Alpha2-Macroglobulin: A physiological guardian. *J Cell Physiol* 2013;228:1665–1675.
23. Kobayashi M, Squires GR, Mousa A, et al. Role of interleukin-1 and tumor necrosis factor α in matrix degradation of human osteoarthritic cartilage. *Arthritis Rheum* 2005;52 :128–135.
24. Borth W, Luger TA. Identification of alpha2-macroglobulin as a cytokine binding plasma protein. *J Biol Chem* 1989;264:5818–5825.
25. Mitchell RD. Distal limb lameness in the sport horse: a clinical approach to diagnosis, in *Proceedings*. Am Assoc Equine Pract 2013;59:244–249.

[a]Astaria Global, LLC, Alpha2EQ MiniKit, Houston TX 77024.

[b]Astaria Global, Inc., Houston, TX, internal data, 2020.

[c]*Citra*Labs, Braintree MA 02184.

[d]S. Shoemaker, personal communication, 2022.

Important Considerations for Using Platelet Rich Plasma in the Field

Mark Revenaugh, DVM

Author's address: Northwest Equine Performance, 25230 S Eldorado Road, Mulino, OR 97042-9618; e-mail: mark@equinepi.com. © 2022 AAEP.

1. Introduction

Orthobiologics are becoming mainstream therapies in equine practice. General knowledge about best practices for use of platelet-rich plasma (PRP) in horses is lacking because the science around its use continues to evolve rapidly. Specifically, inconsistency in study design, PRP characteristics, and outcome parameters have resulted in inconsistent results. In one systematic review of clinical and experimental data on humans and horses, beneficial effects were observed in 46.7% of patients, with an absence of positive results in 43.3% of patients.[1] Issues pertaining to indications, characterization of PRP, and methodology will be discussed. This paper will identify key variables in the formation and utilization of PRP in horses.

2. Materials and Methods

Platelets are naturally occurring cells in the bloodstream. Following their formation by megakaryocytes, platelets are located throughout the vascular system. When exposed to injured endothelium, platelets degranulate, releasing growth factors from alpha granules, initiating the clotting cascade, and stimulating angiogenesis. Introduction of large numbers of platelets into an injury is thought to create an overall anabolic effect by augmenting tissue healing and inflammation locally. Key regenerative growth factors stored in alpha granules, and their basic functions can be found in Table 1.

Blood is processed in various fashions dependent upon equipment. Most PRP systems are either "buffy coat" based or "plasma" based. Buffy-coat-based systems tend to yield higher white blood cells (WBCs) with lower platelet numbers. Because of the high variability of equine hematocrit values as well as many unique kits and protocols in most PRP semiautomated commercial systems, there is a high degree of variability produced of platelet numbers, concentrations, and additional contents.[2] The double spin technique has been described for maximizing platelet number.[3,4]

Characterization of PRP preparations is critical in terms of optimizing protocols and formulations. Parameters such as presence WBCs and red blood cells in the preparation, as well as whether the horse is being treated with an antiplatelet medication such as aspirin, firocoxib, or other nonsteroidal anti-inflammatory drug, may affect response to treatment and have a significant effect on the efficacy of the end product.

It is unclear how platelet numbers and concentrations affect safety and efficacy. However, to be classified as PRP, platelet numbers must be substantially greater than baseline plasma. When choosing a system, it is important to consider cost of the equipment, cost of the "kits," whether the system is "open" or "closed," and whether the system is portable and durable. It is recommended that the clinician test individual samples to determine platelet numbers and concentrations they are delivering. This can be accomplished by taking a whole blood sample and

NOTES

Table 1. Key Growth Factors Stored in Alpha Granules and Their Function

Growth Factor	Function
PDGF	Stimulates cell proliferation, chemotaxis, and differentiation
	Stimulates angiogenesis
TGF-β	Stimulates production of collagen type I and type III, angiogenesis, re-epithelialization, and synthesis of protease inhibitors to inhibit collagen breakdown
VEGF	Stimulates angiogenesis by regulating endothelial cell proliferation and migration
EGF	Influences cell proliferation and cytoprotection
	Accelerates re-epithelialization
	Increases tensile strength in wounds
	Facilitates organization of granulation tissue
bFGF	Stimulates angiogenesis
	Promotes stem cell differentiation and cell proliferation
	Promotes collagen production and tissue repair
IGF-1	Regulates cell proliferation and differentiation
	Influences matrix secretion from osteoblasts and production of proteoglycan, collagen, and other noncollagen proteins

Abbreviations: PDGF, platelet-derived growth factor; TGF-β, transforming growth factor β; VEGF, vascular endothelial growth factor; EGF, epidermal growth factor; bFGF, basic fibroblast growth factor; IGF-1, insulin-like growth factor 1. Reproduced with permission from William C. *Atlas of Interventional Orthopedics Procedures*.

documenting platelet count. A 1-mL sample can also be submitted of the undiluted PRP generated by the equipment (request sample to be agitated before PRP levels measured as platelets tend to clump). The ratio of platelets in PRP over platelets in whole blood provides a concentration factor. Generally, most preparations should yield 4x to 10x concentration.

Oftentimes there is additional plasma (platelet-poor plasma) that is generally discarded despite having potential valuable ingredients. In addition to measuring platelet numbers in the PRP sample, quantifying presence of WBCs can also be useful. Generally, neutrophils have an inflammatory effect on surrounding structures and are not desirable for most PRP preparations. In one study, comparison between human tissue treated with leukocyte-rich PRP and leukocyte-poor PRP resulted in greater cell death in synovial cells treated with the leukocyte rich preparations.[5] However, in instances of chronic injury, neutrophils may help in breaking down fibrosis and undesired debris. Monocytes, on the other hand, may be helpful in producing additional anti-inflammatory products and growth hormones and may be of value to keep in the PRP being produced.

It is unclear how many platelets should be used in optimal concentrations in treating different tissue types. PRP samples can also be lysed by putting them through one or more freeze/thaw cycles or by exposing the samples to excessive positive or negative pressure.

3. Results

Although use of PRP for treatment of soft-tissue injuries has been well documented, published results are contradictory. In equine practice, PRP is used widely in soft-tissue injuries. Increasingly, PRP is used for treatment to synovial structures. The Equine Clinicians Data Initiative was created in 2021, with the goal of capturing large case numbers of naturally occurring cases. At this time, the group consists of 7 equine practices contributing data on the following:

1. Adverse events
2. Basic demographics of horses treated
3. Outcome parameters
4. Perception of efficacy from vet and trainer

Preliminary signalment data suggest that PRP is being used widely in treatment of soft-tissue injury (Fig. 1) and joint disease. Additionally, PRP is used for treatment of spinal injuries in humans (Fig. 2) and horses.

4. Discussion

Numerous therapeutic treatment options currently exist for treatment of soft-tissue injuries and joint-related injuries in horses. In many horses, use of corticosteroids is contraindicated due to underlying metabolic or medical issues. Production of PRP in the field requires relatively inexpensive equipment and kits as well as requiring a significant amount of time to process. Despite these "hassle" factors, PRP is becoming a mainstream therapeutic option for many equine sports medicine practitioners. Additionally, the onset of action is less predictable than with corticosteroid use in joints. Adverse reaction includes regional swelling, discomfort, and transient lameness. Small-scale studies tracking human patients' response to PRP injections into the lumbar spine suggest a longer period of benefit is enjoyed in patients treated with PRP versus corticosteroids (Fig. 2).

Standardization of dosage, concentration, and optimal time of delivery is needed. It is the author's impression that the use of PRP in joints creates a regional therapeutic benefit and carries a lower likelihood of "masking" a nearby injury. Additionally, there appear to be some horses that are "nonresponders" who appear to not benefit from treatment. Depending on the specifics of each case, the author prefers a minimum 2-week window prior to competition following treatment to PRP. It is also worth noting that in human athletes, the World Anti-Doping Agency initially prohibited PRP in 2010 but subsequently allowed use of PRP in 2011 due to lack of definitive evidence of effect from treatment. As of 2022, the Fédération Équestre Internationale allows use of PRP on horses out of competition, at home, and with adequate withdrawal time. With United States Equestrian Federation rules, PRP is permitted, adhering to the "12-hour" rule and a 4-day intra-arterial injection withdrawal time.

Important considerations when using PRP on equine patients include the following:

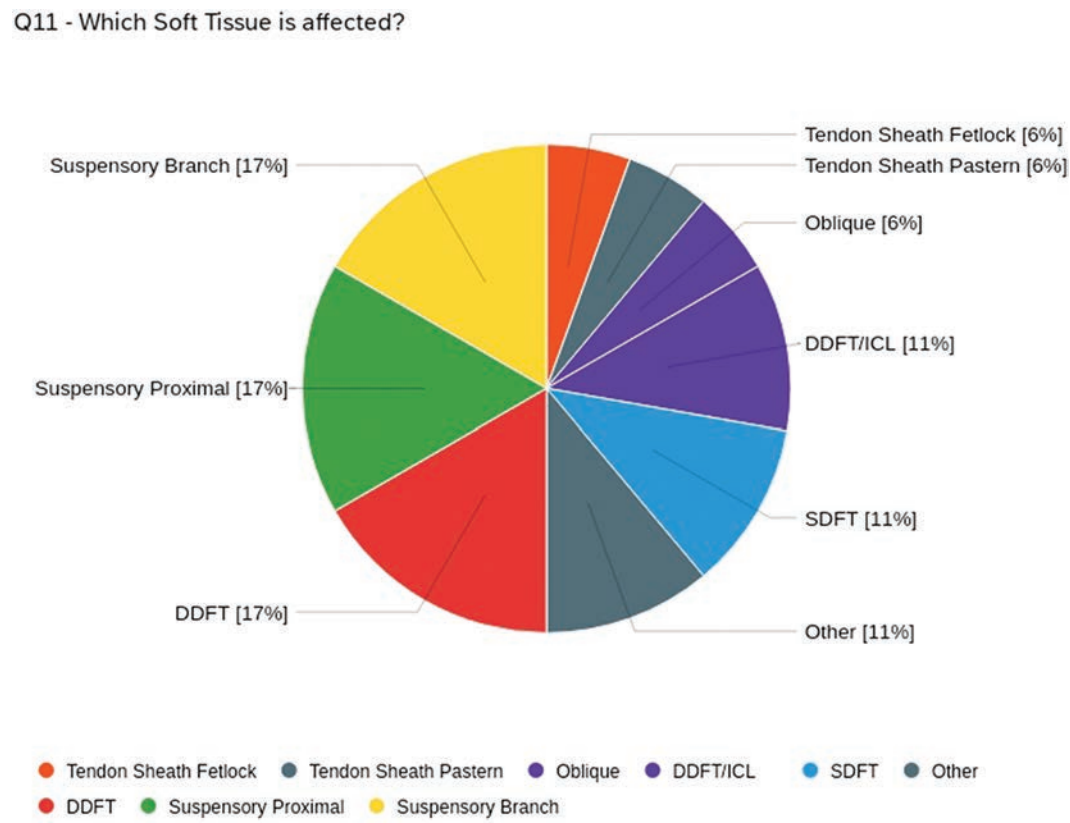

Fig. 1. Sample demographic information from the Equine High Performance Sports Group Data Tracking Program (preliminary results 2021). Used with permission. DDFT, deep digital flexor tendon; SDFT, superficial digital flexor tendon; ICL, inferior check ligament.

1. Is the patient currently being treated with a nonsteroidal anti-inflammatory drug? This may mitigate the treatment to some extent.
2. What is the actual platelet number (dose) being administered?
3. Are red blood cells or WBCs included in the preparation (intentionally or unintentionally)?

Due to the potential for accelerated healing, it is advisable to re-evaluate the patient at shorter time intervals than

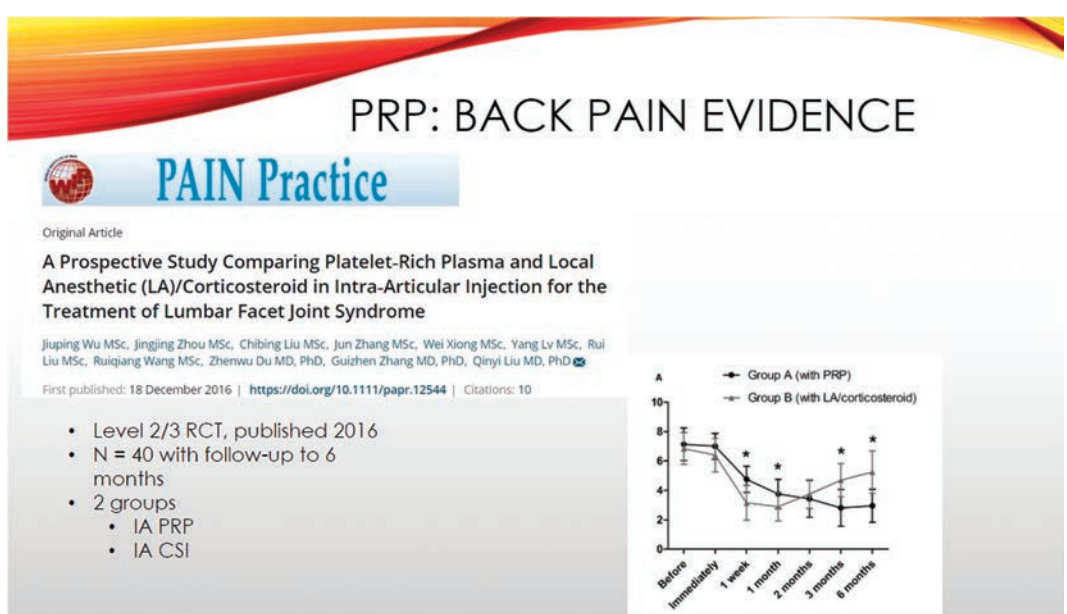

Fig. 2. Summary slide of comparison between corticosteroid and PRP use in human patients with back pain. Used with permission, Chris Williams, MD, Interventional Orthopedics of Atlanta.

may otherwise be customary. If healing is accelerated, the role of rehabilitation becomes increasingly important.

5. Conclusion

It appears that use of PRP often has symptom-modifying as well as disease-modifying properties in many clinical scenarios. Standardization of technique is needed for critical assessment of the use of PRP in horses.

Acknowledgments

Declaration of Ethics

The Author has adhered to the Principles of Veterinary Medical Ethics of the AVMA.

Conflict of Interest

The Author has no conflicts of interest.

References

1. Brossi PM, Moreira JJ, Machado TS, et al. Platelet-rich plasma in orthopedic therapy: A comparative systematic review of clinical and experimental data in equine and human musculoskeletal lesions. *BMC Vet Res* 2015;11:98.
2. Fitzpatrick J, Bulsara MK, McCrory PR, et al. Analysis of platelet-rich plasma extraction: Variations in platelet and blood components between 4 common commercial kits. *Orthop J Sports Med* 2017;5:2325967116675272.
3. Fukuda K, Kuwono A, Kuroda T, et al. Optimal double-spin method for maximizing the concentration of platelets in equine platelet-rich plasma. *J Equine Sci* 2020;31:105–111.
4. Radtke AV, Goodale MB, Fortier, LA. Platelet and leukocyte concentration in equine autologous conditioned plasma are inversely distributed by layer and are not affected by centrifugation rate. *Front Vet Sci* 2020;12:173.
5. Braun HJ, Kim HJ, Chu CR, et al. The effect of platelet-rich plasma formulations and blood products on human synoviocytes: Implications for intra-articular injury and therapy. *Am J Sports Med* 2014;42:1204–1210.

Clinical Overview of Endometritis: Causes and Methods of Diagnosis

Maria R. Schnobrich, VMD, DACT

Author's address: Rood and Riddle Equine Hospital, PO Box 12070, Lexington, KY 540850-2070; e-mail: mschnobrich@roodandriddle.com. © 2022 AAEP.

1. Introduction

Endometritis is inflammation of the endometrial lining of the uterus that, without resolution, results in a decrease in fertility due to a pathologic change in the uterine environment. Because only the superficial layers are involved, endometritis, unlike metritis, does not result in systemic disease and life-threatening sequelae such as laminitis and sepsis. Despite this, it is a major cause of reproductive loss and infertility in the mare, being the third most common medical condition in the mare, and persistent mating-induced endometritis (PMIE) is reported in 15% to 35% of mares after breeding.[1–3] The causes of endometritis are many and ultimately result in a reduced ability of the uterus to resolve inflammation and clear inflammatory debris. Factors that cause or predispose a mare to endometritis include anatomic defects, degenerative changes of the endometrium, endocrinopathy, decreased immune function, exposure to infectious pathogens with varying virulence, and contamination such as occurs in mating (PMIE) or postfoaling. These alterations in the uterine environment and endometrial lining, including its secretory properties and immune function, can become chronic and persist in a state of dysfunction and inflammation. The challenge to the practitioner is identifying when endometritis is present, if it is a normal physiological response or an abnormal state that requires intervention, what the inciting cause is, and whether there is an infectious component, and developing an appropriate treatment for resolution.

2. Normal Endometrial Inflammatory Response

It is a normal physiologic response of the mare's endometrium to become inflamed following breeding or foaling. This inflammation induces changes in uterine contractility, secretions, and immune functions that help evacuate contaminants (semen, debris, microbes) from the uterus and restore uterine health in a timely fashion. Following breeding, spermatozoa, debris, and bacteria in the uterus induce inflammation by activating the immune system.[1–3] Neutrophils are recruited to invade the uterine lumen and phagocytize debris, semen, and microorganisms.[4] The inflamed endometrium increases secretions and releases prostaglandin F2 alpha ($PGF_{2\alpha}$). Prostaglandin secretion results in increased myometrial contractions that expel debris and fluid from the uterus.[5] In normal mares at about 6 hours after breeding, anti-inflammatory cytokines that modulate the immune response are upregulated. These cytokines include interleukin (IL)-1 receptor antagonist, IL-10, and IL-6.[6–8] Once the proinflammatory cytokines are down-regulated (IL1β, chemokine ligand 8 [CXCL8, formerly known as IL8], and TNFα) and the uterus has cleared the stimulus of inflammation, the uterus returns to a more normal milieu.[6–8] This is noted ultrasonographically by the absence of fluid in the uterine lumen 24 to 36 hours after breeding and a decrease in edema following ovulation.[4,6,8] When the normal uterine clearance mechanisms, anatomic barriers, and immune response fail to resolve inflammation, chronic endometritis ensues. This can be infectious or noninfectious based

NOTES

on the inciting cause and progression of the condition. Normal mares that resolve breeding-associated inflammation 24 to 36 hours after breeding are referred to as "resistant" to PMIE. Resistant mares are able to resolve this breeding-induced inflammation in a short time frame (96 hours).[4,8] "Susceptible" or "problem mares" are mares that cannot resolve the inflammatory insult of breeding within 48 hours of breeding. Susceptible mares also experience prolonged inflammation, uterine fluid accumulation, and uterine fluid neutrophilia beyond 96 hours.[4,9–14] Additionally, these mares are unable to clear intrauterine bacterial challenge with *Streptococcus equi zooepidemicus* within 96 hours, compared to "resistant" mares.[15,16]

3. Persistent Mating-Induced Endometritis

The diagnosis of mares with persistent mating-induced endometritis (PMIE) includes transrectal palpation and ultrasound findings 24 hours after breeding that include > 2 cm of intrauterine fluid and excessive endometrial edema relative to time of ovulation (edema should decrease within the periovulatory window and after ovulation).[14–17] Predisposing factors for mares with PMIE include anything that impedes uterine clearance and resolution of infectious or noninfectious contamination. Anatomic defects would include a pendulous uterus, a cervix that fails to relax, scar tissue that traps debris and infectious agents, and large endometrial cysts that mechanically block uterine clearance mechanisms. Immunologic effects that predispose mares to PMIE are exacerbated proinflammatory responses (as seen in aged mares) and endocrinopathies that cause inappropriate or ineffective immune responses such as pituitary pars intermedia dysfunction and equine metabolic syndrome.[16–19] The type of pathogen introduced may also affect the mare's ability to respond effectively.[20] Virulence of pathogens as enhanced by a protective biofilm may make the likelihood of persistent infection and chronic endometritis more likely.[20,21]Additionally, degenerative changes of the endometrium such as poor lymphatic drainage, decreased normal mucus production, and impaired mucociliary apparatus can lead to an increased susceptibility to PMIE.[19] When managing a mare with a history of PMIE, or that has predisposing factors (aged, poor anatomy of the reproductive tract) for PMIE, it is helpful to understand the mare's prior reproductive history. Ideally, the mare is available to observe through a complete estrous cycle prior to breeding. This allows the practitioner to determine the underlying cause for failure of appropriate uterine response. Furthermore, serial examinations allow the veterinarian to determine when the issue is occurring and to prospectively treat for optimal uterine health. For example, if the mare begins to accumulate fluid early in the cycle, ecbolic agents (oxytoxin 10 IU, IM twice a day) or a prebreeding lavage (lactated Ringer's solution lavage until efflux clears) can be utilized to assist in clearance.[19,22] Postbreeding lavages administered 4 to 6 hours after breeding help remove inflammation, debris, and cytokines that prolong the inflammatory response.[23] Antibiotics and immune modulators (dexamethasone, platelet rich plasma, mycobacterium cell wall extract) are used in some cases of mares with impaired anatomy or decreased immune function to help prophylactically decrease an excessive inflammatory response associated with PMIE and aid in pathogen killing.[24,27] With vigilant examinations, PMIE mares are often easily identified in the peribreeding period, which allows for prompt treatment. It can be challenging to diagnose the inciting cause or reason for persistent inflammation in mares with chronic endometritis and thus, poses a challenge to the practitioner. This population of mares has endometritis that developed from mating, contamination, or other factors, and the clinician must identify the cause of persistent endometritis so an appropriate treatment plan can be made.

4. Chronic Endometritis

Chronic endometritis (infectious and noninfectious) can present in a variety of ways clinically as there are many different factors that can cause the endometrium not to be able to resolve inflammation. The diagnosis of endometritis must be made with careful assessment of the mare's history, systemic health, reproductive anatomy, and results from diagnostic sampling of the uterus. Differentiation of infectious versus noninfectious endometritis is traditionally made with diagnostic tools such as aerobic culture of the endometrium (swab, small-volume lavage, or biopsy) and cytology. The history of a mare with endometritis often includes decreased pregnancy rates; increased pregnancy loss before 40 days of gestation; previous identification of uterine inflammation and infection on uterine cytology, culture, and/or biopsy; irregular estrous cycles; and shortened return to estrus due to endometrial inflammation causing premature luteolysis.[5,14,28,29] The reproductive tract can look variable based on the inciting cause, distribution, and severity of the endometritis. Mares may have significant bacterial load and deep endometrial inflammation, with few ultrasonographic signs and negative result on swab culture and cytology. In *E. coli* infections, it has been shown that often the endometrial cytology is negative, whereas *S. equi* subsp. *zooepidemicus* infections result in more exudative reactions and endometrial cytologies are often positive.[30] Because of the variation in presentation, if one is suspicious of endometritis based on clinical findings, further diagnostic tests are indicated. Diagnostic sampling of the uterus is essential to determine if inflammation is present, and this is performed using uterine cytology and/or histology (biopsy). Endometrial cytology specimens are obtained with a guarded cotton-tip swab, cytobrush, or low-volume uterine lavage.[30–33] The degree of inflammation, cell types present, presence of urine crystals, mucous, debris, hyphae, yeast, and bacteria all help to understand the factors affecting the uterine environment. Inflammation is generally categorized as mild (normal), moderate, or severe. The following categories

may be used to define the endometrial inflammation: normal (no white blood cells [WBC] to rare WBC/100 epithelial cells [EC]), mild inflammation (1–2 WBC/100 EC), moderate inflammation (3–5 WBC/100 EC), and severe inflammation (>5 WBC/100 EC).[32] Endometrial biopsy has traditionally been the gold standard of diagnosis of endometritis.[34–36] This allows assessment of the inflammatory cell character and distribution and severity of inflammation. Endometrial biopsies can be useful for identifying chronic endometritis when traditional cytologic sampling fails to identify inflammation.[34–36]

5. Noninfectious vs. Infectious Endometritis

Noninfectious endometritis can occur when there is contamination (air or urine) that continues to inflame the endometrium or when inflammation from foaling or caustic agents does not resolve but does not contain an infectious component. Post-mating-induced endometritis is often noninfectious. Identification of infectious endometritis is best achieved with diagnostic tests that identify microbes, such as aerobic culture of uterine swab, lavage efflux, or endometrial biopsy.[14,19] Aerobic culture of uterine biopsy is the most sensitive and specific means of diagnosing infectious endometritis.[31,34,39] Aerobic culture of low-volume lavage efflux and subjective character of lavage fluid have been reported as also being sensitive for detecting microbial organisms that may be harder to detect (*E. coli*, fungal organisms).[40] Polymerase chain reaction and next-generation sequencing of uterine samples are also helpful for detecting difficult infectious organisms, but these tests are less readily available.[41] Disruption of biofilm, "activation" of latent infections, and biofilm assessment have been proposed as novel diagnostic tools to identify underlying infections and susceptibility to nonantimicrobial agents not identified with traditional methods.[20,42–44] These methods employ infusions of either biofilm disruptors or inflammation-inducing agents that stimulate suspected latent bacteria to replicate and make them easier to identify and treat.[20,42–44]

Using currently available diagnostic tests, it is essential to incorporate all available information to make an appropriate diagnosis. Assessment of medical and reproductive history and evaluation of the mare's reproductive tract in estrus and diestrus (to include transrectal evaluation, vaginal speculum examination, and digital cervical evaluation) allow identification of anatomic findings that may contribute to subfertility. Intrauterine fluid, uterine edema, a cervix that fails to close, evidence of air in the vagina or uterus, and/or hyperemic vaginal mucosa during diestrus are not normal findings.[19] During estrus, hyperemia of mucosal surfaces, excessive endometrial edema, excessive intrauterine fluid accumulation >2 cm at any time (particularly if echogenic), and failure of the cervix to dilate are abnormalities that warrant further investigation.[2,4,5,17] Culture and cytology samples are often taken during estrus as there is a decreased chance of obtaining a false negative sample. Furthermore, the mare's immune system is better prepared to respond to iatrogenic contamination introduced during sample taking. Moderate inflammation and any significant growth on aerobic culture of the endometrium suggests that the mare has endometritis and may require treatment. Hysteroscopy is used in cases of persistent endometritis despite appropriate treatment or when ultrasonography reveals significant abnormalities of the uterus (hyperechoic debris that persists, abnormal fluid accumulations). Once endometritis is diagnosed, the inciting cause must be identified in order to formulate an appropriate and successful treatment. History is again important as dystocia or unusual intrauterine treatments can often cause issues that must be addressed to abate the inflammation (cervical defects, uterine adhesions). Anatomic factors that cause chronic endometritis are important to identify and resolve as often without their resolution, no intrauterine treatment will be curative. Failure of the vulva, vestibuo-vaginal fold, and/or cervix to protect the uterus from contamination must be addressed, most often surgically (Caslick's, cervical repair). Recto-vaginal fistulas, urine pooling, and aspiration of air into the reproductive tract are not as common causes of contamination but must also be ruled out in cases of chronic endometritis. Adhesions, diverticulae, scar tissue, and large cysts can form areas of debris and pathogen accumulation, which may alter normal uterine clearance mechanisms. Evaluation of the systemic health of the mare is equally essential as immune function and ability to resolve uterine infections may be compromised by poor body condition, endocrinopathy (pituitary pars intermedia dysfunction, equine metabolic syndrome), excessive body condition, pain, or stress.

6. Summary

Endometritis is a condition that involves both normal and abnormal progressive uterine responses to inflammatory factors such as sperm, microbes, and debris. The challenge for the clinician is differentiating the abnormal uterine response and implementing appropriate treatment. Careful evaluation of the mare, appropriate diagnostic tools, and interpretation of results can aid in identification of pathology and lead to appropriate treatment. Unfortunately, there is no single test with perfect sensitivity or specificity for identifying causes of endometritis. Therefore, practitioners must rely on complete clinical evaluation of the mare to institute effective treatments. Fortunately, the majority of pathologic endometritis cases can be correctly identified and easily diagnosed in routine broodmare practice.

Acknowledgments

Declaration of Ethics

The Author has adhered to the Principles of Veterinary Medical Ethics of the AVMA.

Conflict of Interest

The Author has no conflicts of interest.

References

1. Traub-Dargatz JL, Salman MD, Voss JL. Medical problems of adult horses, as ranked by equine practitioners. *J Am Vet Assoc* 1991;198:1745–1747.
2. Zent WW, Troedsson MHT, Xue J-L. Postbreeding uterine fluid accumulation in a normal population of Thoroughbred mares: A field study, in Proceedings. Am Assoc Equine Pract 1998;44:64–65.
3. DeHaan KG, Ferris RA, McCue PM. Incidence rate and effects of persistent mating-induced endometritis (PMIE) in Quarter Horse mares, in *Proceedings. Society for Theriogenology* 2014;6.
4. Woodward EM, Troedsson MH. Inflammatory mechanisms of endometritis. *Equine Vet J* 2015;47:384–389.
5. LeBlanc M, Causey R. Clinical and subclinical endometritis in the mare: Both threats to fertility. *Repro Dom Anim* 2009;44:10–22.
6. Troedsson MH. Uterine clearance and resistance to persistent endometritis in the mare. *Therio* 1999;52:461–471.
7. Troedsson MH, Loset K, Alghamdi AM, et al. Interaction between equine semen and the endometrium: The inflammatory response to semen. *Anim Reprod Sci* 2001;68:273–278.
8. Woodward EM, Christoffersen M, Campos J, et al. Endometrial inflammatory markers of the early immune response in mares susceptible or resistant to persistent breeding-induced endometritis. *Reproduction* 2013;145:289–296.
9. Fedorka CE, Scoggin KE, Woodward EM, et al. The effect of select seminal plasma proteins on endometrial mRNA cytokine expression in mares susceptible to persistent mating-induced endometritis. *Reprod Domest Anim* 2017;52:89–96.
10. Alghamdi A, Troedsson MH, Laschkewitsch T, et al. Uterine secretion from mares with post-breeding endometritis alters sperm motion characteristics in vitro. *Therio* 2001;55:1019–1028.
11. Alghamdi AS, Foster DN, Troedsson MH. Equine seminal plasma reduces sperm binding to polymorphonuclear neutrophils (PMNs) and improves the fertility of fresh semen inseminated into inflamed uteri. *Repro* 2004;127:593–600.
12. Alghamdi AS, Madill S, Foster DN, et al. Equine sperm-neutrophil binding. *Biol Reprod* 2015;92:94.
13. Card C. Post-breeding inflammation and endometrial cytology in mares. *Therio* 2005;64:580–588.
14. Canisso IF, Segabinazzi LGTM, Fedorka CE. Persistent breeding-induced endometritis in mares—A multifaceted challenge: From clinical aspects to immunopathogenesis and pathobiology. *Int J Mol Sci* 2020;21:1432.
15. Christoffersen M, Woodward E, Bojesen AM, et al. Inflammatory responses to induced infectious endometritis in mares resistant or susceptible to persistent endometritis. *BMC Vet Res* 2012;8:41.
16. Christoffersen M, Söderlind M, Rudefalk SR, et al. Risk factors associated with uterine fluid after breeding caused by *Streptococcus zooepidemicus*. *Therio* 2015;84:1283–1290.
17. Samper J. A review of a practitioner's perspective on endometrial edema. *Pferdeheilkunde* 2010;26:14–18.
18. Woodward EM, Christoffersen M, Campos J, et al. Susceptibility to persistent breeding-induced endometritis in the mare: Relationship to endometrial biopsy score and age, and variations between seasons. *Therio* 2012;78:495–501.
19. LeBlanc M. Advances in the diagnosis and treatment of chronic infectious and post–mating-induced endometritis in the mare. *Repro Domestic Anim* 2010;45:21–27.
20. Ferris RA. Current understanding of bacterial biofilms and latent infections: A clinical perspective. *Rev Bra Reprod Anim* 2017;41:74–80.
21. Beehan DP, Wolfsdorf K, Elam J, et al. The evaluation of biofilm-forming potential of *escherichia coli* collected from the equine female reproductive tract. *J Equine Vet Sci* 2015;35:935–939.
22. Vanderwall DK, Woods GL. Effect on fertility of uterine lavage performed immediately prior to insemination in mares. *J Am Vet Med Assoc* 2003;222:1108–1110.
23. Brinsko SP, Varner DD, Blanchard TL. The effect of uterine lavage performed four hours post-insemination on pregnancy rates in mares. *Therio* 1991;35:1111–1119.
24. Rogan D, Fumuso E, Rodríguez E, et al. Use of a mycobacterial cell wall extract (MCWE) in susceptible mares to clear experimentally induced endometritis with *Streptococcus zooepidemicus*. *J Eq Vet Sci* 2007;27:112–117.
25. Bucca S, Carli A, Buckley T, et al. The use of dexamethasone administered to mares at breeding time in the modulation of persistent mating induced endometritis. *Therio* 2008;70:1093–1100.
26. Bermudez V, Sifontes L, Navarro N, et al. Effects of intrauterine infusion of sodium ceftiofur on the endometrium of mares, in *Proceedings*. Am Assoc Equine Pract 1995;41:261–263.
27. Woodward EM, Christoffersen M, Horohov D, et al. The effect of treatment with immune modulators on endometrial cytokine expression in mares susceptible to persistent breeding-induced endometritis. *Equine Vet J* 2015;47:235–239.
28. Rebordão MR, Galvão A, Szóstek A, et al. Physiopathologic mechanisms involved in mare endometrosis. *Reprod Dom Anim* 2014;49:82–87.
29. Fumuso EA, Aguilar J, Giguère S, et al. Immune parameters in mares resistant and susceptible to persistent post-breeding endometritis: Effects of immunomodulation. *Vet Immunol Immunopathol* 2007;118:30–39.
30. Riddle WT, LeBlanc MM, Stromberg AJ. Relationships between uterine culture, cytology and pregnancy rates in a Thoroughbred practice. *Therio* 2007;68:395–402.
31. Diel de Amorim M, Gartley CJ, Foster RA, et al. Comparison of clinical signs, endometrial culture, endometrial cytology, uterine low-volume lavage, and uterine biopsy and combinations in the diagnosis of equine endometritis. *J Equine Vet Sci* 2016;44:54–61.
32. Ferris RA, Bohn A, McCue PM, et al. Equine endometrial cytology: Collection techniques and interpretation. *Equine Vet Educ* 2015;27:316–322.
33. Bohn AA, Ferris RA, McCue PM. Comparison of equine endometrial cytology samples collected with uterine swab, uterine brush, and low-volume lavage from healthy mares. *Vet Clin Pathol* 2014;43:594–600.
34. Nielsen JM, Nielsen FH, Petersen MR, et al. Diagnosis of equine endometritis – Microbiology, cytology and histology of endometrial biopsies and the correlation to fertility. *Pferdeheilkunde* 2012;28:8–13.
35. Nielsen JM, Troedsson MH, Pedersen MR, et al. Diagnosis of endometritis in the mare based on bacteriological and cytological examinations of the endometrium: Comparison of results obtained by swabs and biopsies. *J Equine Vet Sci* 2010;30:27–30.
36. Nielsen JM. Endometritis in the mare: A diagnostic study comparing cultures from swab and biopsy. *Therio* 2005; 64:510–518.
37. Ball BA, Shin SJ, Patten VH, et al. Use of a low-volume uterine flush for microbiologic and cytologic examination of the mare's endometrium. *Therio* 1988;29:1269–1283.
38. Cocchia N, Paciello O, Auletta L, et al. Comparison of the cytobrush, cotton swab, and low-volume uterine flush techniques to evaluate endometrial cytology for diagnosing endometritis in chronically infertile mares. *Therio* 2012;77:89–98.
39. Christoffersen M, Brandis L, Samuelsson J, et al. Diagnostic double-guarded low-volume uterine lavage in mares. *Therio* 2015;83:222–227.
40. Katila T. Evaluation of diagnostic methods in equine endometritis. *Reprod Biol* 2016;16:189–196.

41. Schnobrich MR, Bradecamp E, Scoggin C. Next generation DNA sequencing, culture and cytology results in 29 mares with suspected endometritis. *Clin Therio* 2018;10:338.
42. Petersen MR, Møller Nielsen J, Lehn-Jensen H, et al. *Streptococcus equi* subspecies zooepidemicus resides deep in the chronically infected endometrium of mares. *Clin Therio* 2009;2009:393–409.
43. Petersen MR, Skive B, Christoffersen M, et al. Activation of persistent *Streptococcus equi* subspecies zooepidemicus in mares with subclinical endometritis. *Vet Microbiol* 2015;179:119–125.
44. Von Dollen KA, Wolfsdorf K, Levkulic S, et al. How to use N-Acetylcysteine to enhance diagnosis of bacterial endometritis in barren mares, in *Proceedings*. Am Assoc Equine Pract 2021;67:261–263.

Breeding the Young Mare Versus the Teenager: Impact on the Incidence of Endometritis

T.A.E. Stout, MA, VetMB, PhD, DECAR

Author's address: Department of Clinical Sciences, Faculty of Veterinary Medicine, Utrecht University, Yalelaan 114, 3584 CM Utrecht, The Netherlands; e-mail: t.a.e.stout@uu.nl. © 2022 AAEP.

1. Summary

Sport horse mares presented for breeding in Europe typically fall into two age categories, 3 to 4 years old and late teens, reflecting the loss of elite 6- to 15-year-olds to a competitive career. The two groups differ markedly with respect to their susceptibility to persistent breeding-induced endometritis (PBIE), where aspects of susceptibility can be further influenced by whether the mare has ever carried a foal to term and, if so, how long ago she last foaled. Young maiden and foaling mares are typically resistant to PBIE. By contrast, mares that retire from a successful sporting career in their late teens are often nulliparous but still affected by age-related changes that increase their susceptibility to endometritis. These age-related predispositions include chronic endometrial degeneration, reduced myometrial contractility, and pituitary pars intermedia dysfunction (PPID). Recently retired sport horses may also have poor perineal conformation as a result of low body-fat reserves. Moreover, the cervix of aged maiden mares is often fibrotic and fails to relax adequately during estrus, impeding evacuation of the inflammatory fluids resulting after breeding. Conversely, maiden mares will not be affected by conditions associated with multiparity, such as a pendulous uterus, or foaling-induced damage to the caudal reproductive tract. This paper assesses the relative susceptibility of young versus teenage mares, and broodmare versus embryo donors, to endometritis and discusses strategies to reduce the impact of PBIE on the success of breeding the aged maiden mare.

2. Introduction

Show jumping and dressage mares are only allowed to compete at the highest level beyond 7 years of age. However, if they are successful, they may continue to compete until their mid-teens. As a result, jumping and dressage mares are typically presented for breeding either when they are 3 to 4 years old, i.e., before they enter serious training and competition, or when they have retired from competition at around 14 to 16 years of age. In short, an elite dressage, show jumping, or eventing mare's competitive career will often extend beyond the time at which her fertility starts to decline (approximately 14 years).[1] Given that owners are likely to want progeny from proven performers, this presents a dilemma as to whether competing or breeding should take precedence. This can, in part, be tackled by using the mare as an embryo or oocyte donor during her sporting career.[2] However, riders often complain that managing mares for insemination and embryo collection, and in particular the related increased frequency of estrus, compromises training and performance. Furthermore, there have been suggestions that the physiological stress of training

NOTES

and competition could compromise fertility and embryo quality.[3] Oocyte recovery by ovum pick-up (OPU) has the advantage that it can be performed as a one-off, outpatient procedure; moreover, intracytoplasmic sperm injection and in vitro embryo production may yield multiple embryos such that there is less need to repeat oocyte recovery sessions.[4] Nevertheless, OPU is an invasive procedure, and actively competing mares more often suffer postprocedure discomfort, normally for only 1 to 3 days, but occasionally for longer (7 to 10 days).

A reasonable proportion of serious breeders preempt the issue of fertility decline during a competitive career by breeding mares when they are 3 to 4 years old, before they enter serious training or competition, either to carry a foal or to yield embryos. Clearly, these young mares are ideal candidates for breeding in terms of their expected fertility, while giving birth can help to protect against or at least delay the onset of cervical fibrosis. Alternatively, of course, carrying a foal to term itself carries a risk of serious complications that could compromise future fertility, including cervical tears. On the other hand, using mares exclusively as embryo donors over the course of many years, and never allowing them to foal, appears to exacerbate the fibrotic changes to the cervix more commonly associated with the aged maiden mare. The alternative to breeding at a young age is to wait until a mare's competitive career is over before she becomes a broodmare or embryo donor. Despite never having had a foal, these teenage mares will still be affected by age-related changes that increase the likelihood that they will be susceptible to PBIE. And, since endometritis is one of the most common reasons for mares failing to establish or maintain pregnancy after breeding,[5] anticipating and preventing or treating PBIE is an important aspect of managing older mares in the peri-insemination period.

3. Endometritis and Fertility

Uterine infection and/or inflammation can be detrimental to fertility in numerous ways. First, if the infection and/or inflammation is pre-existing, the neutrophils already recruited to the uterus may capture, bind, and phagocytose the spermatozoa soon after they are deposited in the uterus, thereby reducing the likelihood of conception. Second, the persistence of uterine inflammation beyond day 6 after ovulation can interfere with the establishment of pregnancy, either by a direct toxic effect on the embryo when it enters the uterine lumen or because the inflammation stimulates endometrial $PGF_{2\alpha}$ release leading to premature luteolysis or luteal compromise. In the longer term, persistent or recurrent uterine inflammation may lead to a disturbed uterine environment and accelerate the development of chronic degenerative changes in the endometrium (endometrosis), both of which compromise the ability to maintain pregnancy.

4. Breeding-Induced Endometritis

During the last 20 years, it has also become increasingly clear that endometritis is not always a result of microbial infection. In fact, it is now accepted that the most common instigator of endometritis is mating or insemination and that a transient uterine inflammation is the normal physiological response to the intrauterine deposition of semen (thus, breeding-induced endometritis).[6] Furthermore, the spermatozoa themselves appear to be the primary instigator of the inflammatory reaction, which presumably serves to aid the elimination of "excess" spermatozoa that do not make it through the utero-tubal junction and into the oviductal sperm reservoir within the first 4 hours after insemination.[5] This breeding-induced inflammatory reaction consists of two major components: 1) physical clearance of fluid, spermatozoa, contaminating microorganisms, and inflammatory products produced in response to insemination. This mechanical clearance is primarily a result of myometrial contractions that initially help to transport spermatozoa toward the oviduct but are subsequently more important in eliminating uterine fluid and the other remnants of insemination through the cervix. This physical clearance is further supported by mucociliary action and lymphatic drainage, with the latter becoming increasingly important as the cervix tightens and local immunity wanes following ovulation.[7] 2) The second arm of the inflammatory response is a cascade of immune system responses that further help to eliminate foreign material and restore the uterus to a "clean," noninflamed state. Since it would not be sensible to develop immunological memory to spermatozoa, much of the immune response is initiated via nonspecific receptors and involves innate pathways including the complement system, proinflammatory cytokines, and neutrophils where the latter play a crucial role in trapping spermatozoa and bacteria either by direct ligand-receptor binding or by extruding their DNA to form so-called neutrophil extracellular traps.[5]

The uterine inflammatory response begins within 2 hours after insemination and peaks at around 4 to 8 hours, both in terms of neutrophil recruitment and proinflammatory cytokine production, after which a combination of mechanical clearance of the stimuli and a shift in the balance of cytokines toward anti-inflammatory mediators should serve to dampen the response and ensure that uterine clearance is completed by 48 hours after breeding.[6] The mare's intrinsic reaction is further modified by various components of seminal plasma, which can augment uterine contractility and suppress the inflammatory response, most importantly shortening the duration of the inflammatory reaction. For example, seminal plasma contains prostaglandins that can stimulate myometrial contractions and factors that inhibit neutrophil trapping and phagocytosis of live spermatozoa (CRISP 3) but enhance that of dead spermatozoa (lactoferrin), thereby enhancing the likelihood that live spermatozoa

reach the oviduct after insemination, even in the presence of pre-existing inflammation.[8]

5. Persistent Breeding-Induced Endometritis

A young, reproductively healthy mare will resolve the breeding-induced inflammation within 24 to 48 hours.[6] Since it is not practical to monitor the elimination of neutrophils or the change in the balance between anti- and proinflammatory cytokines, the elimination of ultrasonographically visible uterine fluid and reduction in uterine edema are the most useful proxies for the successful completion of uterine clearance. In young, healthy mares, this usually takes up to 6 hours after breeding with fresh semen but often takes longer after frozen semen insemination (12 hours).[5] In mares "susceptible" to postbreeding endometritis, however, the normal uterine defense mechanisms are compromised such that the clearance of spermatozoa and inflammatory debris is not completed within 48 hours, and significant uterine fluid accumulation (> 2 cm) will persist beyond the 6- to 12-hour time windows quoted above. As a result, it is advisable to check susceptible mares relatively soon after artificial insemination, e.g., 4 to 6 hours, to enable timely initiation of treatments to enhance uterine clearance and/or modulate the inflammatory response. These additional treatments may be as simple as the use of ecbolics, such as oxytocin, to stimulate myometrial contractions and enhance the expulsion of fluid or uterine lavage with sterile 0.9% saline or lactated Ringer's solution (LRS) to remove the fluid and any offending spermatozoa, bacteria, and inflammatory byproducts that it might contain. Early and aggressive management of PBIE very much improves the likelihood of rapid resolution and reduces the risk of secondary infection. Therefore, in practice, it is important to identify mares likely to be susceptible to PBIE so that they can be monitored more intensively around the time of insemination, both to minimize the number of inflammatory challenges (i.e., inseminations) and, following insemination, to ensure the rapid completion of uterine clearance and dampening of the inflammatory cascade. While susceptibility to PBIE may only become evident following the first insemination, the aged maiden mare is an obvious candidate for closer monitoring, and a thorough initial examination may reveal predispositions to PBIE that need to be addressed.

6. Old Maiden Mare Issues

When presented with a teenage maiden mare recently retired from competition, it is important to remember that she has no breeding history and, therefore, may have undiagnosed congenital anomalies or problems normally diagnosed in 3- to 4-year-olds. Recently retired sport horses may also be slow to start cycling at the start of the year because of low body-fat reserves or treatments received during their competitive career. The lack of body fat may also predispose to poor perineal conformation, adding an extra predisposition to pneumo- and urovagina and pre-existing infective endometritis. As a result, during the first examination, more attention should be paid to carefully checking whether the mare requires a Caslick's procedure and for the presence of intrauterine fluid or inappropriate edema (i.e., more edema than is consistent with cycle stage and follicle development).[7] Since both fluid and excessive edema are indicators of inflammation, if they are present, it is advisable to collect a uterine sample for cytological and microbiological investigation to rule out a pre-existing infection. Even if the fluid proves to be sterile and free of inflammatory cells, it can be advantageous to lavage the mare's uterus with LRS prior to insemination.[9] In some cases, the fluid recovered may be very turbulent, suggesting excess mucus. A mucolytic agent, such as N-acetyl cysteine, can help to breakdown excess mucus by reducing disulphide bonds,[6] thereby facilitating removal. In older maiden mares and older mares that have been used as embryo donors without ever giving birth, it is important to check cervical relaxation during estrus, preferably by digital examination. The cervix can be fibrotic, long, and tortuous. The fibrotic nature of the cervix becomes increasingly severe with an increasing number of years without foaling, and this change can significantly interfere with postbreeding uterine clearance. Cervical relaxation can be assisted by manual dilation at the time of insemination and in combination with uterine lavage and/or ecbolic treatment at the first postbreeding examination. In severe cases, topical application of prostaglandin E products, e.g., 1 mg of misoprostol (PGE1: Cytotec tablets dissolved in 0.9% saline or crushed and mixed with sterile gel) or 1 mg of prostin E2 (PGE2; either in tablet or gel form), at around 4 to 6 hours after insemination may further enhance cervical relaxation and assist the evacuation of accumulated fluid. Probably the best long-term remedy for cervical fibrosis, however, is foaling since parturition involves a complete remodeling of cervical architecture at the level of the cells and extracellular matrix. The owners of a mare intended as an embryo donor may take some convincing that it is better to keep her in foal because establishing pregnancy in these mares may be a challenge.

7. Age-Related Degenerative Changes

Chronic endometrial degeneration is known to be more a factor of age than parity in mares. Therefore, a career as a sport horse is not protective against endometrial degeneration; in fact, years of barrenness may even hasten fibrotic changes.[10] Although the extent of fibrotic degeneration, and therefore the prognosis for carrying a foal to term, can be examined via an endometrial biopsy, there are no treatments proven to reverse the degenerative process. This means that a biopsy is most useful for highlighting the likely challenge and/or helping to make the decision of whether to let the mare carry a pregnancy or to use her

primarily as an embryo or oocyte donor. Symptomatic treatment for endometrial degeneration can include more frequent use of ecbolics postinsemination, since endometrial degeneration has been associated with reduced myometrial contractility as a result of an accumulation of nitric oxide,[5] and hysteroscopic removal of large endometrial cysts using electrocautery or an Nd:YAG laser. Older mares are also more likely to be affected by oviductal blockage, and repeated failure to establish pregnancy or recover an embryo without any obvious underlying cause are reasons to consider oviductal therapies. Laparoscopic[11] or intrauterine application of PGE2 or hysteroscopic hydrotubation[12] are all therapies known to restore oviductal patency. PPID is another condition of the older horse that can predispose mares to PBIE by compromising the normal immune response. Proper diagnosis of PPID and management using pergolide can help normalize both the postbreeding inflammatory reaction and possible abnormalities of cyclicity.[13]

8. Breeding Management of the Teenage Mare

Since it is safest to assume that a teenage maiden mare is at increased risk of susceptibility to PBIE, efforts should be made to ensure a minimal number of inseminations per cycle. This will include frequent (at least daily) monitoring of follicle development, combined with the use of an ovulation-inducing agent (i.e., human chorionic gonadotropin [hCG] or a gonadotropin-releasing hormone [GnRH] analog); in addition, flushing the uterus with LRS to remove fluid 0 to 2 hours prior to insemination can help provide a "clean" starting point, and timing the insemination further in advance of ovulation than normal (e.g., 18–24 hours instead of 6–12 hours) will allow extra time to resolve any issues with persistent uterine inflammation. Following insemination, early (4–6 hours postinsemination) identification and removal of fluid using a combination of large-volume uterine lavage, uterotonic agents such as oxytocin or a $PGF_{2\alpha}$ analog, and cervical dilation is also essential to limiting the duration of the uterine inflammatory response.[6] With respect to the uterotonic drugs, some studies suggest that lower doses of oxytocin (5–10 IU) may be more effective in promoting uterine clearance than higher doses (> 20 IU) because the latter cause a nonproductive uterine "spasm" rather than waves of contraction.[14] And while $PGF_{2\alpha}$ analogs, such as cloprostenol, are useful alternatives to oxytocin because of their longer duration of action (4–5 hours compared to < 45 minutes), their use postovulation is not recommended because it will compromise subsequent corpus luteum function.[15] In some susceptible mares, conventional treatments appear to be inadequate to resolve the postbreeding inflammatory reaction in a timely fashion, and it may be worth considering the use of systemic corticosteroids to modulate the inflammatory reaction. Both a single large dose of dexamthosone[16] and daily administration of prednisolone[17] have been reported to improve the likelihood of pregnancy or embryo recovery in susceptible mares. Corticosteroids also appear to limit postinsemination edema and fluid accumulation and correct deviations in the balance between pro- and anti-inflammatory cytokines reported during PBIE.

9. Conclusions

Sport horse mares submitted for breeding often fall into two distinct populations. Young mares prior to a competitive career are typically resistant to PBIE and require little specific postbreeding management; moreover, having a foal at a young age may help delay the subsequent development of cervical fibrosis. Mares retired to breeding after a successful competitive career present a different challenge and are commonly affected by fibrotic degeneration of both the cervix, which interferes with the ability to relax and allow the elimination of fluid, and the endometrium, which may compromise both myometrial contractility and the ability to provide an environment conducive to embryo development and placentation. One of the most important aspects of managing the retired sport horse mare is therefore early postbreeding monitoring for fluid and simple but aggressive therapies to enhance uterine clearance and limit the duration of inflammation.

Acknowledgments

Declaration of Ethics

The Author has adhered to the Principles of Veterinary Medical Ethics of the AVMA.

Conflict of Interest

The Author has no conflicts of interest.

References

1. Morris LHA, Allen WR. Reproductive efficiency of intensively managed Thoroughbred mares in Newmarket. *Equine Vet J* 2002;34:51–60.
2. Cuervo-Arango J, Claes AN, Stout TA. A retrospective comparison of the efficiency of different assisted reproductive techniques in the horse, emphasizing the impact of maternal age. *Theriogenology* 2019;132:36–44.
3. Mortensen CJ, Choi YH, Hinrichs K, et al. Embryo recovery from exercised mares. *Anim Reprod Sci* 2009;110:237–244.
4. Stout TA. Clinical application of in vitro embryo production in the horse. *J Equine Vet Sci* 2020;89:103011.
5. Troedsson MH. Breeding-induced endometritis in mares. *Vet Clin North Am Equine Pract* 2006;22:705–712.
6. Morris LHA, McCue PM, Aurich C. Equine endometritis: A review of challenges and new approaches. *Reproduction* 2020;160:R95–R110.
7. LeBlanc MM. Advances in the diagnosis and treatment of chronic infectious and post-mating-induced endometritis in the mare. *Reprod Dom Anim* 2010;45:21–27.
8. Troedsson MHT, Esteller-Vico A, Scoggin KE, et al. Equine seminal plasma derived lactoferrin regulates binding of polymorphonuclear neutrophils to spermatozoa. *J Equine Vet Sci* 2014;34:49.
9. Vanderwall DK, Woods GL. Effect on fertility of uterine lavage performed immediately prior to insemination in mares. *J Am Vet Med Assoc* 2003;222:1108–1110.

10. Schöniger S, Schoon H-A. The healthy and diseased equine endometrium: A review of morphological features and molecular analyses. *Animals* 2020;10:625.
11. Allen WR, Wilsher S, Morris L, et al. Laparoscopic application of PGE2 to reestablish oviducal patency and fertility in infertile mares: A preliminary study. *Equine Vet J* 2006;38:454–459.
12. Inoue Y. Hysteroscopic hydrotubation of the equine oviduct. *Equine Vet J* 2013;45:761–765.
13. Johnson PJ, Messer NT, Venkataseshu KG. Pituitary pars intermedia dysfunction (equine Cushing's syndrome). In: McKinnon AO, Squires WL, Vaala W, Varner DD, eds. *Equine reproduction* 2nd ed. Chichester: Wiley-Blackwell, 2011;2791–2795.
14. Madill S, Troedsson MHT, Santschi EM, et al. Dose-response effect of intramuscular oxytocin treatment on myometrial contraction of reproductively normal mares during oestrus. *Theriogenology* 2002;58:479–482.
15. LeBlanc MM, Causey RC. Clinical and subclinical endometritis in the mare: Both threats to fertility. *Reprod Dom Anim* 2009;44:10–22.
16. Bucca S, Carli A, Buckley T, et al. The use of dexamethasone administered to mares at breeding time in the modulation of persistent mating induced endometritis. *Theriogenology* 2008; 70:1093–1100.
17. Dell'Aqua JA, Papa FO, Lopes MD, et al. Modulation of acute uterine inflammatory response after artificial insemination with equine frozen semen. *Anim Reprod Sci* 2006;94:270–273.

A Tutorial on Biofilm in the Uterus

Ryan A. Ferris, DVM, MS, DACT

Author's address: Summit Equine, Inc., 6460 Hwy 219 NE, Gervais, OR 97026; e-mail: ryanferrisdvm@gmail.com. © 2022 AAEP.

1. Introduction

Most encounters between bacteria and the equine endometrium lead to an acute period of subclinical infection and occasionally clinical symptoms. Following an acute infection in the majority of mares, the invading bacteria will be eliminated, and the infection will be resolved. However, in a minority of cases, small numbers of bacteria survive and cause persistent infections that can be difficult to eliminate. The development of acute and chronic cases of endometritis is the result of deficiencies in the mare's ability to eliminate an infection and the causative bacteria's unique pathogenic properties.

The mare's uterine defense mechanisms to bacterial infection are well understood and consist of physical, immunological, and mechanical barriers.[1] Bacteria utilize numerous methods to survive degradation by the host immune system and antibiotic therapy. One survival tool utilized by bacteria is the production of a biofilm. Biofilms allow bacteria to be unrecognized by the host immune system, prevent exposure to antibiotics, and allow for exchange of genetic material leading to antibiotic resistance.[2]

The purpose of this review is to describe how alterations to host defenses in combination with the pathogenicity of bacteria result in chronic cases of bacterial endometritis.

2. Pathophysiology

The presence of bacteria within the uterine lumen results in a rapid influx of neutrophils, immunoglobulins, and serum proteins. Neutrophils from susceptible mares have reduced in vitro ability to phagocytize bacteria as compared to resistant mares. The inflammation associated with the innate immune system results in fluid production into the uterine lumen.[3–5]

The final defense mechanism against bacterial endometritis is mechanical uterine clearance of bacteria and inflammatory products. Several studies have shown that mares susceptible to uterine infections have decreased clearance of uterine fluid as compared to resistant mares.[6–10] After intrauterine inoculation with bacteria, susceptible and resistant mares have similar uterine myometrial contractions for 6 to 8 hours postinoculation, but it depresses in susceptible mares after 8 hours.[11–13] Failure to clear bacteria and inflammatory products from the uterus results in continued activation of the innate immune system, which then leads to a further increase in inflammatory cells, immunoglobulins, and serum proteins reaching the uterus, which continues to activate the innate immune system.

Bacterial Lifestyle

Bacteria are capable of living in two different lifestyles: planktonic or biofilm states. Planktonic bacteria are single bacterial cells that are free flowing in suspension. Bacteria in this lifestyle are utilizing available nutrients for procreation. These individual cells are relatively susceptible to recognition and degradation by the host immune system. They are also susceptible to changes in environment (desiccation, lack of nutrients, etc.) and are more sensitive to antibiotics. However, the planktonic cell paradigm does

NOTES

not accurately reflect the growth of bacteria that are associated with a biofilm.[2]

In the last several decades, the biofilm state has been considered to be the more prevalent lifestyle with ~80% of the overall world bacterial biomass living in a biofilm.[14] In natural environments, these biofilms are invariably a multispecies microbial community-harboring bacteria that stay and leave with purpose, share their genetic material at high rates, and fill distinct niches within the biofilm.[14]

The first step in biofilm formation is migration and adherence to a surface; a medical example of a surface would be bone, orthopedic implants, or epithelium throughout the body. Individual bacteria will migrate (if capable) until other bacteria (same species or other) are encountered and microcolonies start to form. At this point, the planktonic and biofilm lifestyles can be differentiated from each other. This transition to a biofilm lifestyle is associated with downregulation of genes associated with flagella present in a planktonic state. Additionally, there is an upregulation of genes associated with polysaccharide production increase leading to production of an exopolysaccaride (EPS) matrix that forms the scaffold for the biofilm community.

Clinically, biofilms significantly interfere with traditional methods for treating chronic bacterial infections. Bacteria within a biofilm are protected from the host immune system as white blood cells have reduced ability to move and function, and the thick layer of EPS prevents antibodies from reaching bacteria deep within the biofilm. Biofilms protect bacteria from antibiotics by providing a diffusion barrier that decreases the amount of antibiotics that reach the bacterial colonies. This creates a microenvironment that slows down bacterial metabolism and, therefore, replication of bacteria. Slowed replication makes bacteria more resistant to antimicrobial agents.[15–20]

As antimicrobial agents come in contact with the biofilm, the agents must traverse through a layer of thick EPS, DNA, RNA, lipids, and proteins in order to reach bacteria buried deep within this protective barrier. Bacteria in the outer region may be killed, but a decrease in the level of antibiotics reaching the inner-layer bacteria contributes to the formation of a nidus for chronic infection.

The thick layer of EPS found in biofilms not only prevents antibiotics from penetrating but also limits the diffusion of oxygen and nutrients. Oxygen and nutrient deprivation consequently result in a decreased bacterial metabolic rate as compared to planktonic bacteria. Reduced metabolic rate impairs bacterial multiplication, which further enhances antimicrobial resistance.[11,20–22]

It has been proposed that, in the horse, biofilms play an important role in chronic uterine infections resistant to antimicrobials due to biofilm production.[23] Additionally, acute and chronic nonhealing wounds on the distal equine limb showed greater incidence of biofilm-producing bacteria as compared to a skin sample near the wound.[24] Therefore, there is evidence for bacterial biofilm production in the horse.

Biofilms in the Horse

Evaluation of bacteria isolated from the equine uterus suggests that the majority of isolates of *Streptococcus equi* subsp. *zooepidemicus*, *Escherichia coli*, *Pseudomonas aeruginosa*, and *Klebsiella pneumonia* produce biofilm in vitro.[25] In the horse, using a model of infectious endometritis, a biofilm-involved infection has been able to be successfully established.[25] The adherent biofilm material is multifocal, with the greatest adherence occurring between the tissue folds and in the uterine horns.[25] The bacteria were identified with greater numbers deep in the endometrial glands as compared to the luminal surface.[25] An alteration in the host immune response was identified, with reduced polymorphic neutrophils (PMNs) surrounding areas of adherent biofilm as compared to areas free of bacteria.[25] Unfortunately, no clinical diagnostic tests are available for the detection of a biofilm-related infection.[25] In human medicine, a biofilm is suspected if appropriate antibiotic therapy is administered and the infection is unable to be eliminated; potentially, similar criteria and treatment recommendations are warranted for uterine infections in the horse.

3. Treatment Options for Biofilms

Bacteria residing in a biofilm can be up to 1000 times more resistant to treatment with antibiotics as compared to free-living (planktonic) bacteria. Administration of antibiotics alone is not effective in eliminating chronic bacterial infections suspected of involving a biofilm in both human and veterinary medicine.[13] The goal in treating a biofilm-associated infection is to remove the biofilm material and kill the bacteria residing within the biofilm.

A series of in vitro and in vivo studies were conducted to assess biofilm dispersal and/or bacterial killing for antibiotics and nonantibiotic agents alone or in combination against Gram-negative bacteria.[25] Data indicated that antibiotics and nonantibiotic agents are more effective against biofilm if administered concurrently (i.e., in the same syringe).[25] Table 1 describes treatments for infusion into the equine uterus based on the in vitro data. The treatments contain the minimum amount of antibiotic or nonantibiotic agent needed to be effective in killing *E. coli*, *K. pneumoniae*, and *P. aeruginosa*. Treatments should be administered every 24 hours for a minimum of 3 treatments. Using this treatment protocol, complete biofilm dispersal and bacterial killing were achieved, in vitro. In all cases, antibiotic sensitivity testing should be performed to optimize treatment success. Bacteria inherently resistant to an antibiotic will still be resistant when that antibiotic is used in combination with a nonantibiotic agent.

It is important to note that some nonantibiotic agents and antibiotics should not be combined in the same syringe. For example, the in vitro data indicated that mixing acetylcysteine with antibiotics in the same syringe resulted in reduced activity of the antibiotics. If a clinician is electing to use acetylcysteine, an option is to use it as an intrauterine infusion to break up mucous;

Table 1. Antibiotic and Nonantibiotic Combinations for the Treatment of Biofilm-Associated Bacterial Endometritis in Mares

Tris-EDTA – final concentration in the syringe should be 50 mM Tris and 3.5 mM EDTA
Note: Tris-EDTA and Tricide are similar; however, Tricide is not equivalent to Tris-EDTA in regard to bacterial killing.
To make Tris-EDTA: 16-oz bottle of Dechra Triz-EDTA crystals; add 8 oz of sterile water (this is different than the bottle instructions). The 2x concentration of Tris-EDTA solution will be further diluted by the antibiotics below to the proper final concentration.

Antibiotic	Drug Amount	Tris-EDTA	QS	Final Volume	Notes
Amikacin (250 mg/mL)	4 mls (1 gram)	30 mL	16 mL sterile fluid (saline, LRS, sterile H_2O)	60 mL	10 mL of 8.4% sodium bicarbonate should be added to the amikacin
Ceftiofur (1 gram reconstituted in 20 mL)	20 mls (1 gram)	30 mL	10 mL sterile fluid (sterile H_2O)	60 mL	
Ciprofloxacin (10 mg/mL)	40 mls (400 mg)	40 mL	0	80 mL	Split between 2 syringes

H_2O_2 – 1% final concentration in the syringe
A 3% stock solution is available at many drug stores and veterinary distributors.

Antibiotic	Drug Amount	H_2O_2	QS	Final Volume	Notes
Amikacin (250 mg/mL)	4 mL (1 gram)	20 mL	26 mL sterile fluid (saline, LRS, sterile H_2O)	60 mL	10 mL of 8.4% sodium bicarbonate should be added to the amikacin
Ciprofloxacin (10 mg/mL)	40 mL (400 mg)	20 mL	0	60 mL	

DMSO – 30% final concentration in the syringe
99% stock solution is used for calculations below.

Antibiotic	Drug Amount	DMSO	QS	Final Volume	Notes
Ceftiofur (1 gram reconstituted in 20 mL)	20 mL (1 gram)	20 mL	20 mL sterile fluid (sterile H_2O)	60 mL	
Ciprofloxacin (10 mg/mL)	40 mL (400 mg)	20 mL	0	60 mL	

DMSO, dimethyl sulfoxide; H_2O_2, hydrogen peroxide; QS, quantum sufficit.

however, a large-volume uterine lavage should be performed prior to instillation of antibiotics into the uterus.

4. Summary

Treatment of biofilm-associated endometritis in the horse can be frustrating due to the lack of clear diagnostic techniques to know if a biofilm is involved. Fortunately, there are proven in-vitro- and in-vivo-based treatment protocols that can effectively treat uterine infections suspected of involving a biofilm. A thorough understanding of the lifestyle difference between planktonic and biofilm-associated lifestyles can help guide clinicians in case selection and treatment options available currently and in the future.

Acknowledgments

Declaration of Ethics

The Author has adhered to the Principles of Veterinary Medical Ethics of the AVMA.

Conflict of Interest

The Author has no conflicts of interest.

References

1. LeBlanc MM, Causey RC. Clinical and subclinical endometritis in the mare: Both threats to fertility. *Reprod in Dom Anim* 2009;44:0–22.
2. Donlan RM, Costerton JW. Biofilms: Survival mechanisms of clinically relevant microorganisms. *Clin Microbiol Rev* 2002;15:167–193.
3. Troedsson MHT, Liu IKM, Thurmond M. Function of uterine and blood-derived polymorphonuclear neutrophils in mares susceptible and resistant to chronic uterine infection: Phagocytosis and chemotaxis. *Biol of Reprod* 1993;49:507–514.
4. Ohman T, Klein C, Doty A, et al. The phagocytic function of blood-derived polymorphonuclear neutrophils after administration of dexamethasone for the modulation of post-breeding endometritis in the mare. *Pferdeheilkunde* 2011;27:267–270.
5. Troedsson MH, Liu IK, Thurmond M. Immunoglobulin (IgG and IgA) and complement (C3) concentrations in uterine secretion following an intrauterine challenge of *Streptococcus zooepidemicus* in mares susceptible to versus resistant to chronic uterine infection. *Biol of Reprod* 1993;49:502–506.
6. Allen WE, Pycock JF. Cyclical accumulation of uterine fluid in mares with lowered resistance to endometritis. *Vet Rec* 1988;122:489–490.
7. LeBlanc MM. Persistent mating induced endometritis in the mare: Pathogenesis, diagnosis and treatment. In: Ball BA, ed. *Recent advances in equine reproduction*. Ithaca: International Veterinary Information Service, 2003.
8. Causey RC. Making sense of equine uterine infections: The many faces of physical clearance. *Vet J* 2006;172:405–421.
9. Samper JC. Uterine edema in the mare. In: Samper JC, ed. *Equine breeding management and artificial insemination*. St Louis: Saunders Elsevier, 2009;133–138.
10. LeBlanc MM, Asbury AC, Lyle SK. Uterine clearance mechanisms during the early postovulatory period in mares. *Am J Vet Res* 1989;50:864–867.
11. Troedsson MH, Liu IK, Ing M, et al. Multiple site electromyography recordings of uterine activity following an intrauterine bacterial challenge in mares susceptible and resistant to chronic uterine infection. *J Reprod and Fertil* 1993;99:307–313.

12. Troedsson MHT, Wistrom AOG, Liu IKM, et al. Registration of myometrial activity using multiple-site electromyography in cyclic mares. *J Reprod and Fertil* 1993;99:299–306.
13. Jefferson KK, Goldmann DA, Pier GB. Use of confocal microscopy to analyze the rate of vancomycin penetration through staphylococcus aureus biofilms. *Antimicrob Agents Chemother* 2005;49:2467–2473.
14. Flemming HC, Wuertz S. Bacteria and archaea on Earth and their abundance in biofilms. *Nat Rev Microbiol* 2019; 17:247–260.
15. Brown MR, Allison DG, Gilbert P. Resistance of bacterial biofilms to antibiotics: A growth-rate related effect? *J Antimicrob Chemother* 1988;22:777–780.
16. Anwar H, Strap JL, Costerton JW. Establishment of aging biofilms: Possible mechanism of bacterial resistance to antimicrobial therapy. *Antimicrob Agents Chemother* 1992;36:347–351.
17. Stewart PS, Costerton JW. Antibiotic resistance of bacteria in biofilms. *The Lancet* 2001;358:135–138.
18. Shah D, Zhang Z, Khodursky A, et al. Persisters: A distinct physiological state of *E. coli*. *BMC Microbiol* 2006;6:53.
19. Chiang WC, Pamp SJ, Nilsson M, et al. The metabolically active subpopulation in pseudomonas aeruginosa biofilms survives exposure to membrane-targeting antimicrobials via distinct molecular mechanisms. *FEMS Immunol Med Microbiol* 2012;65:245–256.
20. Williamson KS, Richards LA, Perez-Osorio AC, et al. Heterogeneity in pseudomonas aeruginosa biofilms includes expression of ribosome hibernation factors in the antibiotic-tolerant subpopulation and hypoxia-induced stress response in the metabolically active population. *J Bacteriol* 2012;194: 2062–2073.
21. Walters MC, Roe F, Bugnicourt A, et al. Contributions of antibiotic penetration, oxygen limitation, and low metabolic activity to tolerance of pseudomonas aeruginosa biofilms to ciprofloxacin and tobramycin. *Antimicrob Agents Chemother* 2003;47:317–323.
22. LeBlanc MM. Advances in the diagnosis and treatment of chronic infectious and post-mating-induced endometritis in the mare. *Reprod Domest Anim* 2010;45:21–27.
23. Pezzanite L, Hendrickson DA. Controlling wound bacteria and biofilm, in *Proceedings*. Am Assoc Equine Pract 2021;67:58–63.
24. Loncar KD, Ferris RA, McCue PM, et al. In vitro biofilm disruption and bacterial killing using non-antibiotics compounds against gram-negative equine uterine pathogens. *J Equine Vet Sci* 2017;53:94–99.
25. Ferris RA, McCue PM, Borlee GI, et al. In vitro efficacy of nonantibiotic treatments on biofilm disruption of Gram-negative pathogens and an in vivo model of infectious endometritis utilizing isolates from the equine uterus. *J Clin Microbiol* 2016;54:631–639.

Responsible Use of Antimicrobial Agents to Treat Bacterial Endometritis in Mares

Tamara Dobbie, DVM, DACT

Author's address: New Bolton Center, School of Veterinary Medicine, University of Pennsylvania, 382 West Street Road, Kennett Square, PA 19348; e-mail: dobbie@vet.upenn.edu. © 2022 AAEP.

1. Introduction

Antimicrobial resistance is both a veterinary and global challenge. The incidence of resistance affects all body systems, including the reproductive tract. In horses, a study by Davis et al.[1] revealed resistance patterns for common uterine pathogens, most notably *Streptococcus equi* subsp. *zooepidemicus* (*S. zooepidemicus*) and *Escherichia coli* (*E. coli*), over a 5-year period in Florida. *E. coli* isolates demonstrated an increased resistance to trimethoprim sulfonamide and ampicillin over the course of the study period. The resistance patterns of *S. zooepidemicus* did not increase over time; however, there was a significant amount of resistance to oxytetracycline throughout the study, and *S. zooepidemicus* was found to be highly resistant to enrofloxacin in the first 3 years of the study.

The challenge to slowing bacterial resistance to antimicrobials is in the hands of veterinarians and the research community so that educated selection of antimicrobials is based on efficacy and pharmacokinetics of commonly used antibiotics. To increase antimicrobial stewardship, antibiotics should be used when there is a confirmed infection, and treatment should be based on antimicrobial sensitivity. The unfettered use of postbreeding antibiotic infusions in mares is a practice with questionable efficacy that has potential to accelerate bacterial resistance to antibiotics in equine reproductive medicine. Following a review of the literature, Cooke concluded that routine postbreeding antibiotic infusions are not justified and should only be used in mares susceptible to endometritis. Cooke evaluated 11 papers that focused on intrauterine antibiotics and endometritis in the horse. None of the studies showed a significant increase in pregnancy rates following postbreeding antibiotic infusions.[2] In a recent study by Bailey, pregnancy rates were similar in young Thoroughbred mares administered intrauterine antibiotic infusions after breeding compared with untreated mares.[a] There does not appear to be a clear advantage to routine uterine antimicrobial administration in the postbreeding period. Instead, antimicrobial use is best directed at mares with clear indication of bacterial endometritis. Not only is this the best practice for veterinary patients, but many of the antibiotics that are routinely used to treat bacterial endometritis and other uterine conditions are also considered critical to human health.[3] According to the World Health Organization in 2018, the following antibiotics were listed as critically important or highly important antimicrobials for human health: gentamicin, ampicillin, ciprofloxacin, sulfamethoxazole, and trimethoprim, to name a few—a sobering realization that emphasizes the need for their judicious use.[4]

2. Bacterial Endometritis

Bacterial endometritis is a common cause of reduced fertility in the mare.[5] The most common infectious agents involved in the disease are *S. zooepidemicus*

NOTES

and *E. coli*.[6–8] The standard method for the diagnosis of bacterial endometritis is endometrial culture and cytology using a double-guarded culture swab and cytology brush, respectively.[9] It has been suggested that scientists and clinicians should come to a consensus on uniform thresholds when evaluating samples. The proposed criteria for inflammation would vary depending on the sample type, with 2% polymorphonuclear leukocytes (PMN) for uterine swabs, 1% PMN for cytobrushes and biopsies, and > 3 PMN/high power field for samples from a low-volume uterine lavage or a uterine biopsy. The proposed criterion for endometrial infection would be > 4 colony forming units of a pathogenic monoculture or a mixed culture of *E. coli* and *S. zooepidemicus*.[10] If the culture and cytology results do not correlate, meaning there is a positive culture and negative cytology or vice versa, then a diagnosis of bacterial endometritis becomes more challenging. *E. coli* often fails to produce cytologic evidence of infection,[1,8] and it may go undetected with a standard swab culture.[10] In situations where the culture and cytology are incongruent, other more sensitive diagnostics such as low-volume uterine lavage, endometrial biopsy, and polymerase chain reaction to identify microbial DNA can be used to confirm the diagnosis.[7,11,12] Once a diagnosis of bacterial endometritis has been made, an appropriate antibiotic can be selected based on the results of the endometrial culture and sensitivity. False positive diagnoses of bacterial endometritis are likely very high given that many practitioners will treat a mare with laboratory results that are less than conclusive than those described above, and some will treat based on clinical signs alone, even in the absence of growth on culture or cytologic evidence of inflammation.

3. Antimicrobial Therapy to Treat Bacterial Endometritis in Mares

When using antibiotics to treat bacterial endometritis in mares, it is important to select an appropriate antibiotic for the situation, use the correct dose, provide the best route of administration, and treat for the appropriate duration for the isolated organism. The common methods for antimicrobial administration for mares with bacterial endometritis are intrauterine infusion and systemic administration.

4. Intrauterine Antimicrobial Therapy

Intrauterine infusion is a common route for antimicrobial administration in mares with bacterial endometritis.[13] It is possible to achieve higher drug concentrations in the uterine lumen and endometrium after intrauterine therapy than with systemic therapy.[14] In some cases, the total amount of antimicrobial necessary for treatment is lower with intrauterine administration.[15] Additionally, intrauterine administered antimicrobials concentrate locally in the genital tract, thereby producing minimal disturbances in the microbiome of other body systems.[16]

However, intrauterine antibiotic administration can cause inflammation in the uterus that may persist for many days following treatment and may negatively impact the ability of the mare to become pregnant.[14] Intrauterine antibiotic therapy during diestrus can place the mare at risk for the development of a fungal endometritis or infection with another bacterial pathogen.[17] For this reason, it is preferable to use intrauterine therapy when the mare is in estrus. Uterine lavage is often used in conjunction with intrauterine antimicrobial infusion when treating mares with bacterial endometritis. Exudate within the uterine lumen may inactivate or dilute the antimicrobial to the point where it is no longer effective. Uterine lavage before antibiotic infusions will remove inflammatory debris and improve the contact of the antibiotic with the uterine lumen and endometrium.[13]

The volume of antibiotic required to ensure uniform distribution throughout the uterus without loss through the cervix ranges from 50 to 200 mL.[14] One report suggests that at least 60 mL of fluid is required to cover the entire endometrial surface of a normal mare.[18] Conversely, overdistention of the uterus and loss of antibiotic through the mare's cervix during estrus may contribute to treatment failure or even bacterial resistance if an insufficient dose of antibiotic is used for treatment.[19]

The duration of intrauterine antimicrobial therapy traditionally ranges from 3 to 7 days, but the time frame appears to be based on convenience rather than on conclusions derived from scientific studies.[18] It has been recommended that mares with mild uterine infections, based on endometrial biopsy, be treated for 3 days. Recommended treatment time for mares with moderate infections is 5 days of intrauterine therapy, and mares with severe infection should be treated for 7 days.[20] Proper hygiene is important when performing intrauterine treatments so that pathogenic bacteria from the clitoris or vestibule are not introduced or fecal contamination does not occur.[21] If an examination per rectum is planned prior to intrauterine infusion, washing and drying the perineum and then inserting a rolled feminine pad into the mare's vestibule prior to entering the rectum helps to prevent fecal contamination of the caudal reproductive tract during transrectal examination.

Antimicrobials used for intrauterine therapy are generally infused into the uterine body. Alternatively, antimicrobials may be infused into the mare's uterus via the deep horn infusion technique. Half of the antimicrobial solution can be infused into the tip of the left uterine horn, and the remaining solution can be infused into the tip of the right uterine horn. The entire infusion can be done with a single deep horn AI pipette. To date, this technique has not been compared to traditional uterine body infusions to determine if one is more efficacious than the other. However, intuitively, it seems that the deep horn technique might better ensure distribution of the antimicrobial solution through the uterus.

5. Systemic Antimicrobial Therapy

Antimicrobials may also be administered systemically to treat bacterial endometritis. One of the main advantages of systemic therapy is the ability to treat a mare during any stage of the estrous cycle. Treatment is not limited to estrus, which allows the duration of therapy to be extended to 10 to 14 days, and even longer if necessary.[13] Theoretically, systemic antimicrobial therapy results in tissue concentrations within the genital tract that are comparable to those in the blood and may be a better treatment option for bacteria,[14] such as *Streptococci*, that may be dormant or reside deeper in the endometrium.[16] Systemic antimicrobial therapy eliminates iatrogenic contamination of the uterus during treatment and prevents the dilution or inactivation of antibiotics by intraluminal exudates.[22] Systemic antimicrobial administration also reduces potential endometrial irritation and allows for treatment around the time of insemination without risk to the sperm or changing the intrauterine environment.[13] However, systemic antimicrobial administration can cause widespread disturbances in the body's microbiome with resultant colitis and diarrhea.[16,23]

6. Antimicrobials Used in Equine Reproductive Practice

Beta Lactam Antibiotics

Penicillins

Penicillins are time-dependent, bactericidal antimicrobials. Penicillins are most effective against Gram-positive bacteria and have limited Gram-negative activity.[23,24] The most common formulations used in equine reproduction include procaine penicillin G, potassium penicillin, ampicillin, and ticarcillin. Ampicillin is better able to penetrate the outer wall of Gram-negative bacteria, giving it a better spectrum of activity against *E. coli* and *Proteus spp.*[23] Ticarcillin has been shown to have good activity against *E. coli*, *Pseudomonas aeruginosa*, and *Proteus*.[13] Penicillins are administered both systemically and intrauterine to treat bacterial endometritis in mares.[13,24] Limited studies have evaluated the use of penicillins to treat bacterial endometritis. In one study, intrauterine infusion of 3 g ampicillin diluted in 60 mL of sterile water produced endometrial concentrations above minimum inhibitory concentration (MIC) for *Streptococcal spp.* at 24 hours.[19] Ticarcillin (6 g) administered intrauterine in two different volumes of sodium chloride (250 mL vs. 60 mL) produced tissue concentrations that were higher, for a longer period, after the larger volume was infused, likely due to slower absorption of the larger volume. Unfortunately, endometrial concentrations of the antibiotic were only evaluated for 6 hours following the infusion, and the time above MIC for common bacterial pathogens was not addressed.[25]

Ticarcillin plus clavulanic acid were administered intrauterine (6 g and 0.2 g, respectively, in 100 mL of saline) and intravenously (50 mg/kg ticarcillin and 1.67 mg/kg clavulanic acid). Tissue concentrations of ticarcillin were higher following intrauterine administration when compared with intravenous administration; however, tissue concentrations declined rapidly, leading the authors to conclude that frequent administration of ticarcillin would be necessary to maintain drug concentrations above MIC for susceptible pathogens.[26] The authors failed to define what was meant by "frequent." They also concluded that the addition of clavulanic acid to ticarcillin for the treatment of bacterial endometritis was questionable given its low concentrations and short duration of activity in tissue fluids.

Cephalosporins

Cephalosporin antibiotics are commonly used to treat bacterial endometritis in the mare.[13,22,24] The different formulations are ceftiofur sodium, ceftiofur hydrochloride, and ceftiofur crystalline-free acid.[24] Ceftiofur is a third-generation time-dependent, bactericidal cephalosporin with a broad spectrum of activity against Gram-positive and some Gram-negative organisms.[23,24] Several studies have been conducted using various ceftiofur formulations intrauterine and systemically to determine if the antibiotics are available at concentrations sufficient to treat *S. zooepidemicus* and *E. coli*, the two most common pathogens involved in bacterial endometritis.

Intrauterine administration of ceftiofur sodium (1 g every 24 hours) was shown to achieve appropriate endometrial concentrations to combat *Streptococcal* bacterial endometritis but often inadequate concentrations to treat *E. coli* bacterial endometritis The study found that the active metabolite of ceftiofur (desfuroylceftiofur acetamide) maintained concentrations above MIC_{90} (minimum inhibitory concentration to inhibit growth in 90% of isolates) in the endometrium for *S. zooepidemicus* for 24 hours following a 1-g infusion of ceftiofur sodium in mares with experimentally induced *S. zooepidemicus* endometritis. The active metabolite was able to maintain concentrations above MIC_{90} for *E. coli* in the endometrium of healthy mares for 48 hours but was unable to maintain MIC_{90} concentrations in the endometrium of all the experimentally infected mares for 24 hours, leading the authors to conclude that ceftiofur sodium (1 g intrauterine once daily) may not be an appropriate standalone treatment for *E. coli* bacterial endometritis.[27]

There is conflicting evidence whether ceftiofur sodium or ceftiofur hydrochloride administered intramuscularly can achieve adequate endometrial concentrations to treat common pathogens involved in bacterial endometritis. In one study,[28] normal mares were administered a single intramuscular injection of ceftiofur hydrochloride at a dose of 2.2 mg/kg. Serum and endometrial concentrations of ceftiofur were maintained above the MIC for *S. zooepidemicus* and *E. coli* for 24 hours after drug administration. In a different study,[29] normal mares were administered

ceftiofur sodium at a dose of 2 mg/kg intramuscularly every 12 hours for 5 treatments. Active metabolites of ceftiofur (desfuroylceftiofur) were not detected in the endometrium following the last treatment. When normal mares were administered ceftiofur crystalline-free acid (6.6 mg/kg), endometrial concentrations of the active metabolite (desfuroylceftiofur acetamide) were detected above MIC for *S. zooepidemicus* for 96 hours following a single intramuscular injection. Repeated injections of ceftiofur crystalline-free acid (0, 4, 11, and 18 days) prolonged tissue concentrations above MIC for S. *zooepidemicus* for 25 days.[30]

Aminoglycosides

Aminoglycosides are concentration-dependent, bactericidal antimicrobials[23,24] that are most effective against aerobic Gram-negative bacteria and *Staphylococcal spp*.[24] Gentamicin and amikacin are the two most used aminoglycosides in equine reproduction. Gentamicin, administered intravenously at a dose of 6.6 mg/kg, produced serum, intrauterine fluid, and endometrial tissue concentrations that were greater than the MIC values reported for common uterine pathogens for 24 hours.[31] Gentamicin has also been shown to be an effective treatment when administered by intrauterine infusion. Ovariectomized pony mares were administered an intrauterine infusion of 2.5 g of gentamicin (50 mL of 5% aqueous solution) for 5 days. Endometrial tissue concentrations on day 5 were higher than the MIC for susceptible reproductive bacteria. The authors concluded that repeated intrauterine treatments with gentamicin produced bactericidal concentrations within the endometrium.[32] Similarly, amikacin administered by intrauterine infusion (2 g in 200 mL sterile saline) produced endometrial tissue concentrations above MIC for 24 hours for species of *Pseudomonas, E. coli*, and *Staphylococcus*.[33] A study by Orsini et al.[34] several years later corroborated these findings and found intrauterine therapy with amikacin to be superior to intramuscular administration based on tissue concentrations, cost, and the risk for morbidity associated with systemic administration.

Gentamicin and amikacin have an acidic pH that can be irritating to the endometrium,[20] and for that reason, both antimicrobials should be buffered with an equal volume of 8.4% bicarbonate to avoid irritation of the endometrial lining.[13,22] Aminoglycosides work best in an alkaline environment, and tissue damage and bacterial death can decrease the uterine pH and render aminoglycosides ineffective. For this reason, a uterine lavage should be performed prior to the infusion of aminoglycosides.[13] Practitioners often mix aminoglycosides and beta lactam antibiotics (penicillins) together in the same syringe for uterine infusion. Such practices should be discouraged because the acidic aminoglycosides can diminish the effectiveness of penicillin G (potassium and procaine) in the low-pH environment.[15]

Fluoroquinolones

Fluoroquinolones are concentration-dependent, bactericidal antimicrobials with activity against most Gram-negative aerobic bacteria, including *P. aeruginosa* and *Enterobacteriacaea*. Fluoroquinolones have limited activity against Gram-positive bacteria.[23] Enrofloxacin and ciprofloxacin (the active metabolite of enrofloxacin) are two fluoroquinolones used in equine reproduction.[24] While commonly used off-label in equine medicine, enrofloxacin is not licensed for use in the horse in the United States.[13] When administered systemically at 5 mg/kg intravenously, enrofloxacin reached adequate concentrations in the endometrium to treat susceptible bacteria found in endometritis.[35,36] A study by Ellerbrock et al.[37] treated pregnant and nonpregnant mares with intravenous enrofloxacin (5 mg/kg) and oral compounded enrofloxacin (7.5 mg/kg) and found both were appropriate to treat susceptible bacteria with an MIC < 0.25 mcg/mL. The authors concluded that drug dosages may need to be adjusted with bacteria with MIC > 0.25 mcg/mL. Endometrial tissue concentrations were not assessed in the study, but the authors stated fluoroquinolones penetrate most tissues well.

However, intrauterine infusion of enrofloxacin is not recommended. Once daily intrauterine infusion of enrofloxacin for 3 days caused severe, acute mucosal necrosis and significant endometrial fibrosis and inflammation.[38] Intrauterine infusion of a water-based suspension of enrofloxacin (50 mL of 2.5% suspension[b] administered daily for 3 days caused a transient inflammatory reaction in the uterus but no long-term effects. However, the concentration of the drug in the endometrium was not clear based on time of testing. Enrofloxacin is a concentration-dependent antimicrobial; therefore, the authors concluded that drug concentrations closer to the time of infusion might be more accurate.[39]

Ciprofloxacin (60 mL of 10 mg/mL solution) was infused intrauterine into mares in estrus. Antimicrobial concentrations were measured in the luminal fluid and endometrial tissues following infusion. Ciprofloxacin concentration far exceeded MIC_{90} of *E. coli*, *K. pneumoniae*, *P. aeruginosa*, and *S. zooepidemicus* throughout the 24-hour period. Very little systemic absorption of the antimicrobial occurred following intrauterine infusion, thereby reducing the risk of systemic side effects. No adverse uterine effects were seen following intrauterine infusion.[40]

Sulfonamides

Potentiated sulfonamides (sulfonamides combined with trimethoprim) are time-dependent, bactericidal antimicrobials with a broad spectrum of activity against Gram-positive and Gram-negative bacteria.[24,41] The two most common formulations used in equine practice are trimethoprim sulfamethoxazole and trimethoprim sulfadiazine.

A study by Brown et al.[42] showed trimethoprim sulfamethoxazole administered at a dose of 15 mg/kg PO

Table 1. Summary of Intrauterine Antimicrobials Shown to Concentrate in the Endometrial Tissue of Normal Mares

Antimicrobial	Dosage	Frequency	Vehicle	Purported Spectrum of Activity
Amikacin	2 g	q 24 h	200 mL sterile saline	*Pseudomonas*, *E. coli*, *Staphylococcal spp.*
Ampicillin	3 g	q 24 h	60 mL sterile water	*Streptococcal spp.*
Ceftiofur	1 g	q 24 h	60 mL sterile saline	*S. zooepidemicus*, *E. coli* (once daily infusion may be inadequate for isolates with MIC_{90} >2 μg/mL)[a]
Ciprofloxacin	600 mg	q 24 h	60 mL of a 10 mg/mL solution	*E. coli*, *K. pneumoniae*, *P. aeruginosa*, *S. zooepidemicus*
Gentamicin	2.5 g	q 24 h	50 mL of a 5% aqueous solution	Susceptible bacteria

Abbreviation: MIC_{90}, minimum inhibitory concentration to inhibit growth in 90% of isolates.
[a] Mares in the study had experimentally induced *S. zooepidemicus* endometritis.

Table 2. Summary of Systemic Antimicrobials Shown to Concentrate in the Endometrial Tissue of Normal Mares

Antimicrobial	Dosage	Frequency	Vehicle	Purported Spectrum of Activity
Ceftiofur crystalline free acid	6.6 mg/kg	q 96 h	IM	*S. zooepidemicus*
Doxycycline	10 mg/kg	q 12 h	PO	Susceptible Gram-positive pathogens (MIC ≤ 0.25 μg/mL); (*S. zooepidemicus*, *S. aureus*)
Enrofloxacin	5 mg/kg	q 24 h	IV	Susceptible Gram-negative bacteria + *S. zooepidemicus*
Gentamicin	6.6 mg/kg	q 24 h	IV	Common equine pathogens with an MIC ≤ 4μg/mL
Trimethoprim sulfadiazine	24 mg/kg	q 12 h	PO	*S. zooepidemicus* and *E. coli*

Abbreviations: IM, intramuscular; PO, per oral; IV, intravenous; MIC, minimum inhibitory concentration.

q 12 h for 5 treatments attained endometrial concentrations sufficient to treat *C. pseudotuberculosis*, *Staphylococcal spp*., and *S. zooepidemicus*. Recently, it was shown that the oral administration of trimethoprim sulfadiazine suspension (24 mg/kg q 12 hours for 5 treatments) resulted in endometrial concentrations sufficient to treat *E. coli* and *S. zooepidemicus* based on MIC values.[43]

Tetracyclines

Tetracyclines are generally bacteriostatic antimicrobials but may be bactericidal at high concentrations.[23] Tetracyclines have a broad spectrum of activity against Gram-negative and Gram-positive bacteria but a limited spectrum of activity against common equine endometrial pathogens.[44] The two common formulations of this drug used in equine practice are oxytetracycline and doxycycline. Both antimicrobials are generally administered systemically.

Oxytetracycline has been infused into the uterus of normal mares (6 g once daily for 3 consecutive days). Oxytetracycline concentrations in the endometrium remained above MIC for several common uterine pathogens (*E. coli*, *S. zooepidemicus*, *K. pneumoniae*, and *P. aeruginosa*) up to 8 hours postinfusion. Oxytetracycline infusion produced only transient uterine inflammation.[45]

Little work has been done to evaluate the use of doxycycline to treat mares with endometritis. In one study, systemically administered doxycycline (10 mg/kg, PO, q 12 h) showed that concentrations of doxycycline in the endometrium of normal mares may be sufficient to treat susceptible Gram-positive pathogens (MIC ≤ 0.25 mcg/mL).[46]

In summary, to better understand the best practice for treating bacterial endometritis, more studies are needed. Drug absorption and endometrial tissue concentrations of antimicrobials may be affected by the route of administration, volume of infusion, and dose of the drug, as well as the inflammatory state of the uterus and even the stage of the estrous cycle. To date, few studies have critically evaluated the efficacy of commonly used antimicrobials in mares with bacterial endometritis. For now, treatment of bacterial endometritis should be based on culture and sensitivity. The antimicrobials used for treatment should have demonstrated efficacy in their ability to concentrate in the endometrium at levels sufficient to combat common uterine pathogens (Tables 1 and 2). Before initiating intrauterine treatment for bacterial endometritis, a uterine lavage should be performed to rid the uterus of debris and bacteria. Whenever possible, nonantimicrobial therapies should be an integral part of the treatment for bacterial endometritis. And finally, the longstanding, indiscriminate use of postbreeding uterine infusions should be discouraged.

Acknowledgments

Declaration of Ethics

The Author has adhered to the Principles of Veterinary Medical Ethics of the AVMA.

Conflict of Interest

The Author has no conflicts of interest.

References and Footnotes

1. Davis HA, Stanton MB, Thungrat K, et al. Uterine bacterial isolates from mares and their resistance to antimicrobials: 8296 cases (2003-2008). *J Am Vet Med Assoc* 2013;242:977–983.
2. Cooke CD. Prophylactic intra-uterine antimicrobial therapy. *Equine Vet Educ* 2015;27:554–555.

3. Raidal SL. Antimicrobial stewardship in equine practice. *Aust Vet J* 2019;97:238–242.
4. World Health Organization. *Critically important antimicrobials for human medicine 6th rev*. Geneva: World Health Organization, 2018;14–15.
5. Brook D. The diagnosis of equine bacterial endometritis. *Compend Contin Educ Vet* 1984;6:S300–S306.
6. Divine C, Daniels J, Bisiau C, et al. *Streptococcus equi* subspecies *zooepidemicus* endometritis in mares: Culture, cytology, and antimicrobial susceptibility tests. *Clinical Theriogenology* 2020;12:389.
7. LeBlanc M, Magsig J, Stromberg AJ. Use of a low-volume uterine flush for diagnosing endometritis in chronically infertile mares. *Theriogenology* 2007;68:403–412.
8. Riddle WT, LeBlanc MM, Stromberg AJ. Relationships between uterine culture, cytology, and pregnancy rates in a Thoroughbred practice. *Theriogenology* 2007;68:395–402.
9. Ferris RA. Practical diagnostics and therapeutics in bacterial endometritis. *Clinical Theriogenology* 2017;9:357–367.
10. Katila T. Evaluation of diagnostic methods in equine endometritis. *Reprod Biol* 2016;16:189–196.
11. Ferris RA, Veir JK, Lappin MR, et al. Development and comparison of sampling techniques for a broad range, semiquantitative polymerase chain reaction assay for detection of bacterial DNA in the equine uterus. *J Equine Vet Sci* 2014;34:687–693.
12. Nielsen JM, Nielsen FH, Petersen MR, et al. Diagnosis of equine endometritis – Microbiology, cytology and histology of endometrial biopsies and the correlation to fertility. *Pferdeheilkunde* 2012;28:8–13.
13. LeBlanc MM. The current status of antibiotic use in equine reproduction. *Equine Vet Educ* 2009;21:156–167.
14. Bennett DG. Therapy of endometritis in mares. *J Am Vet Med Assoc* 1986;188:1390–1392.
15. Dascanio JJ. How and when to treat endometritis with systemic or local antibiotics, in *Proceedings*. Am Assoc Equine Pract 2011;57:24–31.
16. Canisso IF, Segabinazzi LGTM, Fedorka CE. Persistent breeding-induced endometritis in mares – A multifaceted challenge: From clinical aspects to immunopathogenesis and pathobiology. *Int J Mol Sci* 2020;21:1432.
17. Hinrichs K, Spensley MS, McDonough PL. Evaluation of progesterone treatment to create a model for equine endometritis. *Equine Vet J* 1992;24:457–461.
18. Threfall WR, Carleton CL. Treatment of uterine infections in the mare. In: Morrow DA, ed. *Current therapy in theriogenology 2nd ed*. Philadelphia: WB Saunders Company, 1986;730–737.
19. Love CC, Strzemienski PJ, Kenney RM. Endometrial concentrations of ampicillin in mares after intrauterine infusion of the drug. *Am J Vet Res* 1990;51:197–199.
20. Brinsko SP, Blanchard TL, Varner DD, et al. Endometritis. In: Brinsko SP, Blanchard TL, Varner DD, Schumacher J, Love C, eds. *Manual of equine reproduction 3rd ed*. Maryland Heights: Mosby Elsevier, 2011;73-84.
21. Hinrichs K, Cummings MR, Sertich PL, et al. Clinical significance of aerobic bacterial flora of the uterus, vagina, vestibule, and clitoral fossa of clinically normal mares. *J Am Vet Med Assoc* 1988;193:72–75.
22. Scoggin CF. Endometritis: Nontraditional therapies. *Vet Clin North Am Equine Pract* 2016;32:499–511.
23. Haggett EF, Wilson WD. Overview of the use of antimicrobials for the treatment of bacterial infections in horses. *Equine Vet Educ* 2008;20:433–448.
24. Lu KG. Update on antimicrobial therapy in mare reproduction. *Clinical Theriogenology* 2013;5:503–515.
25. Spensley MS, Baggot JD, Wilson WD, et al. Pharmacokinetics and endometrial tissue concentrations of ticarcillin given to the horse by intravenous and intrauterine routes. *Am J Vet Res* 1986;47:2587–2590.
26. Van Camp SD, Papich MG, Whitacre MD. Administration of ticarcillin in combination with clavulanic acid intravenously and intrauterinely to clinically normal oestrous mares. *J Vet Pharmacol Ther* 2000;23:373–378.
27. Scott CJ, Dujovne GA, Christensen BW, et al. Endometrial tissue concentrations of ceftiofur derivatives following intrauterine infusion in both non-infected and mares with experimentally induced endometritis. *Clinical Theriogenology* 2016;8:113–119.
28. Witte TS, Bergwerff AA, Scherpenisse P, et al. Ceftiofur derivatives in the serum and endometrial tissue after intramuscular administration in healthy mares. *Theriogenology* 2010;74:466–472.
29. Cervantes CC, Brown MP, Gronwall R, et al. Pharmacokinetics and concentrations of ceftiofur sodium in body fluids and endometrium after repeated intramuscular injections in mares. *Am J Vet Res* 1993;54:573–575.
30. Scofield D, Black J, Wittenburg L, et al. Endometrial tissue and blood plasma concentration of ceftiofur and metabolites following intramuscular administration of ceftiofur crystalline free acid to mares. *Equine Vet J* 2014;46:606–610.
31. Witte TS, Hahn K, Duerr S. Concentrations of gentamicin in serum, intrauterine fluid, and endometrial tissue after intravenous administration in healthy mares. *J Equine Vet Sci* 2018;66:115.
32. Pedersoli M, Fazeli MH, Haddad NS, et al. Endometrial and serum gentamicin concentrations in pony mares given repeated intrauterine infusions. *Am J Vet Res* 1985;46:1025–1028.
33. Caudle AB, Purswell BJ, Williams DJ, et al. Endometrial levels of amikacin in the mare after intrauterine infusion of amikacin sulfate. *Theriogenology* 1983;19:433–439.
34. Orsini JA, Park MI, Spencer PA. Tissue and serum concentrations of amikacin after intramuscular and intrauterine administration to mares in estrus. *Can Vet J* 1996;37:157–160.
35. Papich MG, Van Camp SD, Cole JA, et al. Pharmacokinetics and endometrial tissue concentrations of enrofloxacin and the metabolite ciprofloxacin after IV administration of enrofloxacin to mares. *J Vet Pharmacol Ther* 2002;25:343–350.
36. González C, Moreno L, Fumuso E, et al. Enrofloxacin-based therapeutic strategy for the prevention of endometritis in susceptible mares. *J Vet Pharmacol Ther* 2010;33:287–294.
37. Ellerbrock RE, Curcio BR, Zhong L, et al. Pharmacokinetics of intravenous and oral administration of enrofloxacin to the late-term pregnant and non-pregnant mares. *Equine Vet J* 2020;52:464–470.
38. Rodriguez JS, Han S, Nielsen S, et al. Consequences of intrauterine enrofloxacin infusion on mare endometrium. *J Equine Vet Sci* 2012;32:106–111.
39. Schnobrich MR, Pearson LK, Barber BK, et al. Effects of intrauterine infusion of a water-based suspension of enrofloxacin on mare endometrium. *J Equine Vet Sci* 2015;35:662–667.
40. Trundell DA, Ferris RA, Hennet MR, et al. Pharmacokinetics of intrauterine ciprofloxacin in the mare and establishment of minimum inhibitory concentrations for equine uterine bacterial isolates. *J Equine Vet Sci* 2017;54:54–59.
41. Prescott JF. Sulfonamides, diaminopyrimidines, and their combinations. In: Giguere S, Prescott JF, Baggot JD, Walker RD, Dowling PM, eds. *Antimicrobial therapy 4th ed*. Ames: Blackwell Publishing, 2006;249–262.
42. Brown MP, Gronwall R, Castro L. Pharmacokinetics of body fluid and endometrial concentrations of trimethoprim-sulfamethoxazole in mares. *Am J Vet Res* 1988;490:918–922.
43. Davolli GM, Beavers KN, Medina V, et al. Concentrations of sulfadiazine and trimethoprim in blood and endometrium of mares after administration of an oral suspension. *Equine Vet J* 2018;67:27–30.
44. del Castillo JRE. Tetracyclines. In: Gigure S, Prescott JF, Dowling PM, eds. *Antimicrobial therapy in veterinary medicine 5th ed*. Hoboken: John Wiley & Sons, 2013;259–265.
45. Ros BD, Willsallen C, Norman ST. The renaissance of oxytetracycline – A treatment for equine endometritis, in *Proceedings. Australian College of Veterinary Scientist Annual Conference* 2010;70–71.
46. Bryant JE, Brown MP, Gronwall RR, et al. Study of intragastric administration of doxycycline: Pharmacokinetics including body fluid, endometrial and minimum inhibitory concentrations. *Equine Vet J* 2010;32:233–238.

[a]Bailey CS. Lexington, KY (personal communication) 2022.
[b]Rood and Riddle Pharmacy, Lexington, KY 40511.

A Menu for Treating Postmating-Induced Endometritis: When Antimicrobials Are Not the Only Answer

Ryan A. Ferris, DVM, MS, DACT

Author's address: Summit Equine, Inc., 6460 Hwy 219 NE, Gervais, OR 97026; e-mail: ryanferrisdvm@gmail.com. © 2022 AAEP.

1. Postmating-Induced Endometritis

Persistent mating-induced endometritis (PMIE), a noninfectious inflammatory condition of the uterus, is one of the most common reproductive abnormalities encountered.[1,2] Persistent mating-induced endometritis refers to the accumulation and retention of inflammatory fluid in the uterus for more than 48 hours after breeding.[3–5] Mares with fluid present in the uterus 48 hours after breeding are considered susceptible to developing postmating-induced endometritis. Mares free of inflammation 48 hours postbreeding are considered resistant to postmating-induced endometritis. Failure to evacuate intrauterine fluid and the inflammation that follows leads to reproductive inefficiency and significant economic loss to the mare owner.[6,7]

Mares with PMIE typically appear normal (i.e., no intrauterine fluid is seen on ultrasound and negative findings on endometrial culture and cytology). In some cases, mares with PMIE will build exuberant edema as estrus progresses. Mares at risk for PMIE are often older (>15 years of age), have poor conformation of vulva or a pendulous uterus, and have a Kenny biopsy score of 2 or greater.[8,9] A thorough history is often the most rewarding element of a diagnostic workup for identifying mares prone to developing PMIE; mares with a history of recurring embryonic loss or failure to conceive are at a higher risk for developing PMIE.[10] Additionally, if a mare has developed PMIE in previous seasons, problems with fluid clearance will continue in the future.

One of the key differences in differentiating PMIE from infections endometritis is that mares with PMIE have normal endometrial culture and cytology prior to breeding.[10] PMIE is an inflammatory response to the spermatozoa, not an infectious event. Mares being treated for PMIE typically do not require antibiotic intervention as an active infection is not present.[10] The use of antibiotics in the treatment of PMIE should only be considered if the uterus is inoculated with significant and known quantities of bacteria during the breeding or treatment period. Examples of this would be semen with high levels of bacteria or contamination during a uterine lavage.

The goal for treating mares with PMIE is to assist in clearing the inflammatory fluid from the uterine lumen and to decrease the inflammation in the endometrium.[10] The severity of PMIE varies greatly, and every mare does not need to receive all available treatments. The veterinarian should develop a treatment plan for each mare that results in elimination of intrauterine fluid by 48 hours after ovulation.

NOTES

2. Treatment Options

Removal of Inflammatory Products from the Uterus

Oxytocin (10–20 IU, IM, or IV, q 4–6 hours) is the first line of defense and is administered to most mares with PMIE.[11–13] Oxytocin induces progressive uterine contractions capable of clearing intrauterine fluid. Mares with a small volume of fluid in the uterine lumen and an open cervix may be treated successfully with oxytocin alone. Administration of greater than 20 IU of oxytocin induces the myometrium to spasm and not have normal myometrial waves associated with uterine clearance.[12]

An alternative ecbolic agent is prostaglandin $F_{2\alpha}$ ($PGF_{2\alpha}$), which can cause prolonged uterine contraction as compared to oxytocin (5 hours vs 40 minutes, $PGF_{2\alpha}$ vs oxytocin) A dosage of 250 μg cloprostenol sodium can be administered intramuscularly, to aid in clearance of intrauterine fluid.[14–16] In the author's experience, most mares will respond to oxytocin and cloprostenol sodium similarly with effective fluid clearance after treatment. However, in the author's clinical program, there are mares that repetitively have not cleared fluid following oxytocin treatment and will effectively clear this fluid with cloprostenol sodium treatment. Administration of cloprostenol sodium prior to ovulation can be effective at clearing uterine fluid. However, administration postovulation results in altered corpus luteum development, reduction in systemic progesterone concentrations, and reduced pregnancy rates.[16]

Acupuncture, both in its traditional needle form and through electrical stimulation, has been anecdotally suggested to improve uterine fluid evacuation. While many of these reports appear promising, a controlled blinded clinical study did not show an advantage of acupuncture in treating fluid postbreeding as compared to traditional therapies like oxytocin.[16] However, it should be noted the number of mares treated was small and the acupuncture points treated may be different between previous anecdotal evidence and this controlled study.[17,18] If fluid remains following oxytocin or prostaglandin administration, or in cases of moderate to severe PMIE (>2 cm fluid depth), uterine lavage is typically performed.[15] Uterine lavage removes the spermatozoa and prevents induction of further inflammation, and also removes the inflammatory cells and mediators from the uterine lumen. The uterus can be lavaged with either lactated Ringer's solution or sterile physiologic saline as soon as 4 to 6 hours after breeding without adversely lowering pregnancy rates.[19]

Recent work in 2020 compared a routine uterine lavage at either 1 hour or 4 hours after deep horn insemination.[20] Pregnancy rates were found not to be different in a controlled study of normal mares.[20] These findings indicate that within 1 hour after deep horn insemination, the spermatozoa required for fertilization will be protected in the mare's oviduct. A follow-up study indicated that subfertile mares had a higher pregnancy rate after a uterine lavage 1 hour after deep horn insemination as compared to 4 hours.[20] This increase in pregnancy rates may be due to removing the stimuli (spermatozoa) for continued inflammation from the uterus quickly and starting to focus on decreasing inflammation postmating. It is important to note that the suggested adjustment in time from breeding to lavage from 4 hours to 1 hour was specifically focused on mares bred by deep horn insemination and not using a routine body insemination.[20]

An interesting finding associated with increased development of PMIE was stall confinement during breeding management.[17] In 1 study, mare confinement in 12 × 12 stalls during breeding management was associated with up to 78% of susceptible mares accumulating fluid postbreeding.[17] The use of lunging at a trot for 15 minutes (6, 12, 24, 30, 36, 48 hours postmating) in the 48 hours postbreeding dramatically reduced the rate of fluid retention by 66% in susceptible mares after breeding.[17] Exercise, when possible, is a simple tool to aid in uterine fluid evacuation in the periovulatory period.[17]

Modulation of Inflammation

Dexamethasone, a glucocorticoid, can be used to modulate inflammation during the breeding process. Bucca et al[21] showed that administration of dexamatho-sone (50 mg, IV, at the time of breeding) resulted in increased pregnancy rates in mares that had at least 3 risk factors for developing PMIE: abnormal reproductive history, positive endometrial culture, >2 cm endometrial fluid prior to breeding, abnormal perineal conformation, abnormal cervix, postbreeding endometrial fluid >1.5 cm, postfoaling vulvoplasty, abnormalities of the reproductive tract, and postbreeding fluid persisting after 36 hours after mating. This enhancement in pregnancy rates is likely due to altering proinflammatory cytokines after breeding in mares.[22] As the dexamethasone is altering inflammation in abnormal mares, there is no effect on pregnancy rates when administered to normal mares. Lower doses of dexamethasone were not shown to be as effective in reducing inflammation after breeding,[23] and long-term dexamethasone administration was associated with ovulation failure in some mares.[24] Daily administration of prednisolone (0.1 mg/kg every 12 hours) 4 treatments before breeding and 1 treatment at the time of breeding was associated with an increase in pregnancy rates.[25]

The majority of nonsteroidal anti-inflammatory drugs have resulted in lack of clinical improvement in PMIE and associated with increased incidence of anovulatory follicle formation.[26,27] Administration of firocoxib, a COX-2 selective anti-inflammatory drug, was shown to modulate inflammation in mares prone to PMIE when administered from ovulation induction until 24 hours after artificial insemination (AI). Treatment resulted in decreased migration of white blood cells into the uterine lumen and reduced

inflammatory mediators. The dose of firocoxib used in this study was 0.2 mg/kg as compared to the more commonly used dose of 0.1 mg/kg, once daily (after a single loading dose of 0.3 mg/kg).[28]

Bacterial cell wall extracts have been investigated regarding their effects on uterine immune system and enhancement of pregnancy rates. While the majority of work is focused on clearance and treatment of infectious endometritis, a study in 2012 evaluated the immune response to spermatozoa. Mares were treated with 1.5 mg Settle IV[a] 24 hours prior to insemination. Overall, a downregulation of IL-1 messenger RNA was found in this population of susceptible mares 6 hours after AI.[22] Large-scale clinical trials showing alterations in pregnancy rates using bacterial cell wall extracts are limited in the treatment of PMIE.

Mucolytics and Chemical Curettage

Not uncommonly, the lavage effluent from mares with PMIE contains excessive quantities of mucus.[29] Chronic uterine inflammation often results in production of exuberant production of mucus, which manifests as a thick mucus layer overlying the endometrium. Mucolytic agents such as N-acetylcysteine, or other agents focusing on stopping mucous production, including dimethyl sulfoxide or kerosene, can be used with beneficial effects in some mares. N-acetylcysteine disrupts disulfide bonds in mucus, making it less viscous. Infusion of 3.3% N-acetylcysteine (30 mL of a 20% solution diluted in 150 mL saline solution) has been associated with an increase in pregnancy rates in mares that have excessive mucus accumulation.[30]

Infusion of a 30% solution of dimethyl sulfoxide into the uterus results in improvement of biopsy grade, and treated mares tend to have an increased pregnancy rate.[31] Although intrauterine infusion of kerosene is associated with a severe endometritis and necrosis of the luminal epithelium, 50% of treated mares with a category II or III biopsy score became pregnant on the subsequent cycle and carried foals to term.[32] It is thought that the severe inflammation and necrosis results in removal of mucus and exudate from the uterine epithelium.[32] Kerosene treatment typically consists of infusion of 50 to 500 mL of kerosene undiluted into the uterus. Typically, lower volumes are used during diestrus and larger volumes during estrus to account for an open vs closed cervix. Uterine lavage and ecbolics are used 12 to 18 hours later to remove residual kerosene and debris from the uterus.

3. Platelet-Rich Plasma

Platelet-rich plasma (PRP) is a filtrate of whole blood plasma with a high concentration of platelets. PRP contains various growth factors and cytokines that act in an anti-inflammatory manner throughout the body. This therapy has become common to reduce PMIE inflammation and fluid accumulation postbreeding.[33–38] Common time points to use PRP are 48 and 24 hours prior to breeding and 6 and 24 hours postbreeding.

4. Summary

Multiple treatments have been utilized to treat PMIE in the horse. The clinician is faced with the challenge of how to select these treatment options in clinical practice. Overall, as the severity of PMIE increases, the treatments required to manage fluid retention and uterine inflammation are increased. The best approach to treating mares with PMIE is to obtain a thorough history, perform serial examinations, and optimize the treatment regimen for each, individual mare.

Acknowledgments

Declaration of Ethics

The Author has adhered to the Principles of Veterinary Medical Ethics of the AVMA.

Conflict of Interest

The Author has no conflicts of interest.

References and Footnote

1. Traub-Dargatz JL, Salman MD, Voss JL. Medical problems of adult horses, as ranked by equine practitioners. *J Am Vet Med Assoc* 1991;198:1745–1747.
2. Troedsson MH, Loset K, Alghamdi AM, et al. Interaction between equine semen and the endometrium: The inflammatory response to semen. *Anim Reprod Sci* 2001;68:273–278.
3. Allen WE, Pycock JF. Cyclical accumulation of uterine fluid in mares with lowered resistance to endometritis. *Vet Rec* 1988;122:489–490.
4. Causey RC. Making sense of equine uterine infections: The many faces of physical clearance. *Vet J* 2006;172:405–421.
5. Samper J. Uterine edema in the mare. In: Samper J, ed. *Equine Breeding Management and Artificial Insemination*. St Louis, MO: Elsevier; 2009;133–138.
6. Betteridge K, Eaglesome M, Mitchell D, et al. Development of horse embryos up to twenty two days after ovulation: Observations on fresh specimens. *J Anat* 1982;135:191–209.
7. Neely DP, Kindahl H, Stabenfeldt GH, et al. Prostaglandin release patterns in the mare: Physiological, pathophysiological, and therapeutic responses. *J Reprod Fert Supp* 1979;27:181–189.
8. Scoggin CF. Not just a number: Effect of age on fertility, pregnancy and offspring vigour in Thoroughbred broodmares. *Reprod Fertil Dev* 2015;27:872–879.
9. Woodward EM, Christoffersen M, Campos J, et al. Susceptibility to persistent breeding-induced endometritis in the mare: Relationship to endometrial biopsy score and age, and variations between seasons. *Theriogenology* 2012;78:495–501.
10. Canisso IF, Segabinazzi LGTM, Fedorka CE. Persistent breeding-induced endometritis in mares—a multifaceted challenge: From clinical aspects to immunopathogenesis and pathobiology. *Int J Mol Sci* 2020;21:1432.
11. Cadario ME, Thatcher WW, Klapstein E, et al. Dynamics of prostaglandin secretion, intrauterine fluid and uterine clearance in reproductively normal mares and mares with delayed uterine clearance. *Theriogenology* 1999;52:1181–1192.
12. Madill S, Troedsson MHT, Santschi EM, et al. Dose response effect of intramuscular oxytocin treatment on

myometrial contraction of reproductively normal mares during estrus. *Theriogenology* 2002;58:479–481.
13. Campbell MLH, England GCW. A comparison of the ecbolic efficacy of intravenous and intrauterine oxytocin treatments. *Theriogenology* 2002;58:473–477.
14. Brendemuehl JP. Effect of oxytocin and PGF2α on luteal formation, function and pregnancy rates in mares. *Theriogenology* 2002;58:623–626.
15. LeBlanc MM. Persistent mating-induced endometritis. In: Sprayberry KA, Robinson E, eds. *Current Therapy in Equine Medicine*. 5th ed. St Louis, MO: Elsevier Saunders; 2003;234–237.
16. Nie GJ, Johnson KE, Wenzel JGW, et al. Effect of periovulatory ecbolics on luteal function and fertility. *Theriogenology* 2002;58:461–463.
17. Swift LA, Christensen BW, Samocha MB, et al. Randomized comparative trial of acupuncture and exercise versus uterine ecbolics in the treatment of persistent postbreeding endometritis in mares. *J Equine Vet Sci* 2020;86:102821.
18. Rathgeber RA. Use of acupuncture in equine reproduction, in *Proceedings*. Am Assoc Equine Pract 2011;57:138–140.
19. Brinsko SP, Varner DD, Blanchard TL. The effect of uterine lavage performed four hours post insemination on pregnancy rate in mares. *Theriogenology* 1991;35:1111–1119.
20. Samper JC, Kovacsy S, Cadario ME, et al. One-hour post-breeding lavage does not affect pregnancy rates in mares bred with frozen semen, in *Proceedings*. Am Assoc Equine Pract 2020;66:130–131.
21. Bucca S, Carli A, Buckley T, et al. The use of dexamethasone administered to mares at breeding time in the modulation of persistent mating induced endometritis. *Theriogenology* 2008;70:1093–1100.
22. Woodward EM, Christoffersen M, Horohov D, et al. The effect of treatment with immune modulators on endometrial cytokine expression in mares susceptible to persistent breeding induced endometritis. *Equine Vet J* 2014;47:235–239.
23. Vandaele H, Daels P, Piepers S, et al. Effect of post-insemination dexamethasone treatment on pregnancy rates in mares. *Anim Reprod Sci* 2010;121:110–112.
24. Ferris RA, McCue PM. The effects of dexamethasone and prednisolone on pituitary and ovarian function in the mare. *Equine Vet J* 2010;42:438–443.
25. Dell'Aqua JA, Papa FO, Lopes MD, et al. Modulation of acute uterine inflammatory response after artificial insemination with equine frozen semen. *Anim Reprod Sci* 2006;94:270–273.
26. Armstrong DT. Prostaglandins and follicular functions. *J Reprod Fertil* 1981;62:283–91.
27. Cuervo-Arango J. The effect of treatment with flunixin meglumine at different times relative to hCG administration on ovulation failure and luteal function in mares. *Anim Reprod Sci* 2011;127:84–90.
28. Friso M, Segabinazzi LGTM, Cyrino M, et al. Periovulatory administration of firocoxib did not alter ovulation rates and mitigated post-breeding inflammatory response in mares. *Theriogenology* 2019;138:24–30.
29. Causey RC. Mucus and the mare: How little we know. *Theriogenology* 2007;68:386–394.
30. Gores-Lindholm A, Ahlschwede S, Causey R, et al. Effect of intra-uterine infusion of diluted N-acetylcysteine on equine endometrium, in *Proceedings*. Am Assoc Equine Pract 2009; 55:326.
31. Ley WB, Bowen JM, Sponenberg DP, et al. Dimethyl sulfoxide intrauterine therapy in the mare: Effects upon endometrial histological features and biopsy classification. *Theriogenology* 1989;32:263–276.
32. Bracher V, Neuschaefer A, Allen WR. The effect of intrauterine infusion of kerosene on the endometrium of mares. *J Reprod Fertil Suppl* 1991;44:706–707.
33. Segabinazzi LGTM, Canisso IF, Podico G, et al. Intrauterine blood plasma platelet-therapy mitigates persistent breeding-induced endometritis, reduces uterine infections, and improves embryo recovery in mares. *Antibiotics* 2021;10:490.
34. Segabinazzi LG, Friso AM, Correal SB, et al. Uterine clinical findings, fertility rate, leucocyte migration, and COX-2 protein levels in the endometrial tissue of susceptible mares treated with platelet-rich plasma before and after AI. *Theriogenology* 2017;104:120–126.
35. Reghini MFS, Ramires Neto C, Segabinazzi LG, et al. Inflammatory response in chronic degenerative endometritis mares treated with platelet-rich plasma. *Theriogenology* 2016;86:516–522.
36. Metcalf ES, Scoggin K, Troedsson MHT. The effect of platelet-rich plasma on endometrial pro-inflammatory cytokines in susceptible mares following semen deposition. *J Equine Vet Sci* 2012;32:498.
37. Metcalf ES. The effect of platelet-rich plasma (PRP) on intraluminal fluid and pregnancy rates in mares susceptible to persistent mating-induced endometritis (PMIE). *J Equine Vet Sci* 2014;34:128.
38. Pasch L, Schmidt A, King W. Clinical observations after pre breeding intrauterine plasma infusion in 18 mares inseminated with thawed frozen semen. *J Equine Vet Sci* 2021;99:103389.

[a]Settle IV®, Novavive USA, Inc., Athens, GA 30601.

The Enigma of Fungal Endometritis: Detection and Resolution

T.A.E. Stout, MA, VetMB, PhD, DECAR

Author's address: Department of Clinical Sciences, Faculty of Veterinary Medicine, Utrecht University, Yalelaan 114, 3584 CM Utrecht, The Netherlands; e-mail: t.a.e.stout@uu.nl. © 2022 AAEP.

1. Summary

Fungal endometritis is an uncommon problem in mares and can be challenging both to diagnose and to resolve. Molds or yeasts are estimated to account for less than 7% of diagnosed endometritides. It is assumed that fungal colonization is opportunistic, developing into a clinical infection only in a chronically disturbed uterine environment; pneumovagina, recalcitrant bacterial or breeding-induced endometritis, necrotic foci, and intrauterine antibiotic therapy have all been cited as predisposing factors. However, because the exact conditions that facilitate fungal colonization of the uterus are not known, there is no single treatment or combination of therapies proven to offer a high likelihood of resolution. On the other hand, recent studies have examined in vitro sensitivity of common fungal pathogens with the aim of identifying "best choice" antimycotic agents, and post-treatment pregnancy rates have been reported to be higher than previously assumed. Nevertheless, it is essential to augment intrauterine antimycotic therapy by treating for a potential reservoir of infection in the caudal reproductive tract (vagina and clitoral fossa) and correcting any suspected predispositions (e.g., inadequate vulval seal). In the author's experience, the chronicity of fungal infection affects amenability to resolution, and multimodal therapy based around > 5 days of antimycotic therapy is central to successful clearance. If antimycotic treatment is not successful, then a period of breeding rest, or other strategies to encourage the re-establishment of uterine and vaginal environments capable of withstanding fungal proliferation, can be effective.

2. Introduction

Fungal endometritis is an uncommon problem in mares, with a reported incidence of 1% to 7% of diagnosed uterine infections.[1,2] The molds and yeasts most commonly detected are *Aspergillus spp.* and *Candida spp.*, respectively, although a wide range of other organisms has been reported.[1,3,4] Most fungal organisms that enter the uterus probably derive from environmental sources, with the skin and feces considered to be important potential reservoirs. Fungi have also been cultured from the urethra of stallions and are fairly common contaminants of stored or transported semen;[5] while there are no conclusive reports of fungal endometritis as a result of mating with an infected stallion, it is important to consider the possibility of the stallion or semen as a source.

Fungal endometritis is almost certainly an opportunistic condition, relying on previous disturbance, compromise, or overload of the normal uterine defense mechanisms or a more generalized immunosuppression or compromise. This is presumably why fungal endometritis is commonly associated with a history of uncorrected pneumovagina,[6] recurrent bacterial or persistent post-breeding endometritis, and/or intrauterine antibiotic therapy aimed at treating or preventing bacterial

NOTES

infection.[1–4,7] Prolonged local antibiotic therapy has been proposed to disturb the vaginal or uterine microbiome and disrupt the mechanisms that normally prevent molds or yeasts from becoming established.[6,8] At present, although preliminary studies have been reported, the normal composition of a mare's uterine microbiome has yet to be established, and it is unclear to what degree it varies between physiological and pathological states.[9] Indeed, it is more likely that the problem starts within the caudal reproductive tract, where antibiotics that "leak back" after intrauterine infusion disturb the "commensal" flora, resulting in an altered vaginal pH and, possibly, the elimination of bacteria capable of secreting antifungal substances, all of which may reduce the barrier to fungal proliferation. Indeed, it has been proposed that the molds or yeasts that colonize the uterus are often harbored in a "reservoir" in the vagina, vestibulum, and clitoral fossa[1] and carried iatrogenically into the uterus during insemination or other intrauterine treatments. Other factors thought to predispose to fungal endometritis include systemic immune deficiency or endocrine disorders[1] and the presence of a necrotic focus in the uterus or vagina, e.g., following dystocia or placental retention.[10]

While the response of fungal endometritis to treatment is often described as poor, ease of resolution may in part depend on coinfection with other organisms, the duration of infection prior to diagnosis, and the identity of the causal organism. For example, *Candida spp.* have been reported to penetrate deeper into the endometrium and/or grow intracellularly, where they are more resistant to clearance by antimicrobials administered via the intrauterine route. Both intracellular colonization and an untreated reservoir of infection in the caudal reproductive tract are cited as explanations for the high rate of treatment failure and/or recrudescence.[1,11]

3. Clinical Signs and Diagnosis

Mares diagnosed with fungal endometritis are typically older mares with a prolonged history of difficulty in becoming pregnant, often associated with multiple attempts to treat other uterine infections or combat inflammatory reactions. In this respect, 95/128 (74%) mares diagnosed with fungal endometritis at Utrecht University during 1987 to 2001 were barren at the start of the breeding season.[11] In common with other reports, most of the mares for which the information was recorded also had a recent history of intrauterine antibiotic therapy (52/60: 87%) and/or pneumovagina (58/152: 35%). Other factors commonly encountered in the history of mares with fungal endometritis include dystocia or retention of the fetal membranes (18%), early embryonic death (13%), and abortion (7%).[11] Typically, mares suffering from fungal endometritis show obvious signs of uterine inflammation such as copious uterine fluid (33%)[11] and vaginal discharge that can vary in color (white-grey-yellow) and consistency (thick mucoid to watery). Freeman et al.[12] reported a greyish vulval discharge to be common among mares affected by fungal endometritis.

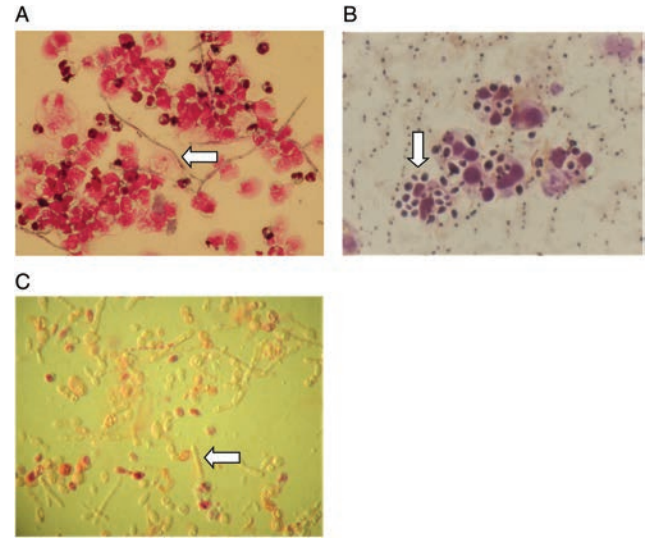

Fig. 1. The various morphological forms of fungi (white arrows) as detected cytologically. A, Elongated fungal hyphae; B, Yeast spores with characteristic capsule (engulfed by neutrophils); C, Pseudohyphae.

Definitive diagnosis of fungal endometritis is usually based on a combination of cytological examination and aerobic culture of uterine material recovered using guarded swabs, cytology brushes, or low-volume lavage. If there is a suspicion of fungal endometritis, it is important to alert the laboratory since culture on low-pH, bacteria-inhibiting Sabouraud's dextrose agar will reduce the likelihood of missing molds or yeasts due to bacterial overgrowth. In addition, a culture should not be declared negative for fungi until 5 days of incubation because fungal growth can be very slow.[12] Cytological examination will often, but not always, reveal signs of an ongoing inflammation (e.g., frequent neutrophils) and may also reveal obvious yeast spores, pseudohyphae, or, less commonly, elongated fungal hyphae (Fig. 1). Yeasts are oval to spherical in shape, are around 3 to 5 μm in length, and typically have a surrounding capsule with a low affinity for dyes that, therefore, remains clear after staining.[1,4] *Candida albicans* can easily be misdiagnosed because cultured colonies resemble bacteria while, on superficial examination, a gram or Diff-Quick stained group of yeasts can be mistaken for staphylococci. Endometrial biopsies have also been advocated for the diagnosis of fungal endometritis, either as a more reliable source of material for seeding culture plates[2] or for investigating the likely success of treatment; fungal elements deep in the endometrium (more reliably identified using Gomori's methenamine silver stain)[4] and extensive endometrial fibrosis, whether a predisposing cause or a result of the fungal infection, are associated with poor subsequent fertility.[10]

Metabolic tests can help to better specify the identity of fungal organisms, while DNA-based tests

(polymerase chain reaction, sequencing, whole genome amplification) and mass spectrometry are being developed for more accurate diagnosis and discrimination of fungal identity. Currently, there are still a number of practical drawbacks, such as the need for prior culture to either increase fungal load or narrow down candidates on the basis of colony appearance, or costs (e.g., sequencing platforms) that have made widespread commercialization difficult and mean that the range of fungi that can easily be detected is limited.

4. Prognosis and Treatment

The prognosis for mares diagnosed with fungal endometritis is generally considered to be poor, either because the organisms are difficult to eliminate or because they subsequently return. The reasons for failure to clear fungal infections include resistance of invasive organisms to intrauterine or systemic therapy, inadequate duration of treatment, and failure to adequately address predisposing factors or to eliminate the reservoir of infective organisms in the caudal reproductive tract. On the other hand, some cases of fungal endometritis recover spontaneously or following non-specific therapies aimed primarily at re-establishing the normal flora and environment within the caudal vagina (e.g., removal of a necrotic focus; introduction of "normal" bacteria, e.g., via "raw" stallion semen), presumably because this corrects the disturbances that permitted initial fungal colonization. For this reason, attempts to resolve fungal endometritis should include correction of any suspected predispositions (e.g., poor vulval closure) and treatments to clear inflammatory products and reduce the load of infective organisms; e.g., large-volume uterine lavage combined with uterotonic drugs (e.g., oxytocin) to promote uterine emptying, with the possible adjunct of mucolytics such as N-acetyl cysteine to remove mucus accumulations that may hinder access of antimicrobials to the causal organisms.

Given the difficulty in resolving fungal endometritis, it is not surprising that many treatments have been tried, using either specific antifungal agents or more general means of killing, combatting, or removing the organisms. However, because it is rare for any single clinic to see large numbers of cases, few treatment protocols have been subjected to controlled clinical trials. Nonspecific intrauterine treatments described anecdotally to be effective include 0.05% povidone-iodine solution, 2% acetic acid,[6,11] 1% to 3% hydrogen peroxide, and 10% to 20% dimethyl sulfoxide.[4] Of these, intrauterine povidone-iodine infusion should be used with caution since there are reports of overly concentrated solutions or nonpovidone iodine causing severe endometrial damage, including fibrosis and adhesion formation.[13] Similarly, while the author commonly infuses 250 mL of 2% acetic acid into the uterus as part of the treatment for fungal endometritis, the acetic acid is washed out with lactated Ringer's solution (LRS) 3 to 5 minutes after infusion because it causes significant uterine irritation characterized by serous exudation and sloughing of endometrial tissue over the following 1 to 2 days. While this may sound counterproductive, it is possible that in the case of invasive yeasts or molds, endometrial debridement facilitates access to, or removal of, the fungi. Of 33 mares treated by uterine infusion of 2% acetic acid for 1 to 3 consecutive days, 11 were cleared of fungal infection (33% of mares; 22% of 49 treatment cycles).[11]

The specific antifungal agents are divided into two major classes: the polyenes and the imidazoles, where the former are generally fungicidal and the latter are mostly fungistatic.[4] The polyenes include amphotericin B and nystatin, whereas clotrimazole, ketaconazole, and fluconazole are all examples of imidazoles.[4,14] If available, antimycotic susceptibility screening can aid in the selection of an appropriate antifungal.[1] If not, antimycotic selection can be based on availability of a suitable formulation, supported by the report that the in vitro sensitivity of 69 fungi isolated from the uterus of mares and tested at Cornell University was 100% to nystatin, 96% to amphotericin B, 81% to ketoconazole, and 80% to clotrimazole.[4] In fact, imidazoles are considered effective candidacidals, and because they work more effectively in an acid environment, acetic acid lavage prior to the onset of treatment may be advantageous.[1,11] With respect to the route of administration, systemic administration of antifungals generally requires long periods of treatment (weeks) and is associated with high costs and significant side effects, not least because many are poorly absorbed from the gastrointestinal tract. Fluconazole is a notable exception since it is relatively inexpensive and has good gastrointestinal availability, and it has therefore been proposed as the drug of choice for systemic (oral) therapy, starting from the onset of estrus and continuing until 2 days after ovulation;[4] however, recurrence of infection after fluconazole treatment is reported to be common.

The author prefers intrauterine administration of antifungals, starting as early as possible in estrus to allow a long duration of treatment (> 5 days) in the period that the uterus is endocrinologically primed to clear infection most effectively. Suggested drugs and doses for daily intrauterine treatment of fungal or yeast endometritis include nystatin (0.5–2.5 million units), amphotericin B (100–200 mg), fluconazole (100 mg), and clotrimazole (500–700 mg).[7] While the response to therapy is anecdotally considered to be disappointing, it is possible that this in part relates to short-lasting or intermittent periods of administration. In a clinical trial in which the experimental imidazole, parconazole, was infused daily for 6 or 10 days into the uterus of mares suffering from fungal endometritis at Utrecht University, the causal agent was eliminated from 27 of 81 mares treated at 135 cycles (i.e., 33% of mares and 20% of treatment cycles), whereas shorter (2–3 day) treatment durations were invariably ineffective.[11] In the author's experience, 5 consecutive days of intrauterine nystatin infusion offers a similar likelihood of resolution (20% of treated cycles). Based on the above experiences, current fungal endometritis

treatment protocol involves a single 250-mL infusion of 2% acetic acid, which is flushed out with 3 L of LRS within 5 minutes, followed by intrauterine infusion of 50 mL of a 10-mg/mL clotrimazole solution. Clotrimazole infusion is repeated for 6 consecutive days, after first removing any accumulated fluid by lavage with LRS, and is combined with daily topical application of clotrimazole cream to the vagina and clitoris. Initial results are promising, and recently, Nielsen et al.[2] reported pregnancy in 24/50 mares (48%) treated for fungal endometritis using 3 consecutive days of uterine lavage with 0.9% saline followed by the introduction of a 100-mg clotrimazole tablet.

In the early 2000s, lufenuron, the benzoylphenyl urea derivative used for flea control in dogs and cats, was popular for treating fungal endometritis in mares, based on a report of the successful resolution of fungal endometritis in 4 mares treated with a single intrauterine administration of 540 mg of lufenuron.[15] The rationale for this treatment centered on the fact that lufenuron's primary anti-insecticidal property is the ability to interfere with chitin biosynthesis. Since fungi also incorporate chitin into their cell walls, it was proposed that lufenuron might inhibit fungal growth. However, fungal endometritis was not cleared in any of 3 mares treated with 540 mg of lufenuron in the author's clinic, and subsequent studies have failed to demonstrate any in vitro antifungal activity of lufenuron (e.g., against *Aspergillus* or *Fusarium spp.*)[16] such that it is unclear whether lufenuron, or other chitin synthesis inhibitors, are effective in the treatment of fungal infections in the uterus of mares or in other situations.

As indicated above, an important adjunct to intrauterine antifungal treatment is topical treatment of the vagina and clitoris (e.g., with clotrimazole cream) to remove any reservoir of organisms that might otherwise lead to reinfection. Two further observations worthy of mention are the following: (1) The clearance of uterine fungal infection has been noted in a handful of mares allowed a prolonged period of breeding rest (months) following apparently unsuccessful antifungal treatment. It is possible that a combination of reducing the number of infectious organisms by treatment combined with a long period of rest to encourage restoration of the normal vaginal microenvironment was sufficient to facilitate "spontaneous" clearance. (2) Following treatment for fungal endometritis, mares commonly develop bacterial endometritis (62/148: 41%, predominantly *Streptococcus equi zooepidemicus*).[11] Although there is clearly a concern that the bacteria may mask the continuing presence of fungi, the post-treatment streptococcal infection often appears to be an indicator of successful fungal elimination. Moreover, the streptococcal infection is readily resolved by intrauterine antibiotic treatment, which does not appear to retrigger the fungal infection.

5. Conclusions

Fungal endometritis is an uncommon problem that can be challenging to resolve. At present, a combination of nonspecific therapy with 2% acetic acid or 1% to 3% hydrogen peroxide and/or > 5 days intrauterine therapy with a specific antifungal agent (e.g., clotrimazole, nystatin, or amphotericin B) appears to offer the best chance (20%–50%) of resolving the fungal infection and establishing pregnancy. While contemporaneous correction of any anatomical abnormalities and treating a potential reservoir of infection in the caudal reproductive tract or correcting any generalized immune compromise may reduce the risk of reinfection, a second estrus may be required to complete elimination of the fungus or to resolve a subsequent bacterial endometritis. Significant improvements in therapy are likely to require a clearer understanding of the conditions that permit the establishment and maintenance of fungal infection in the mare's uterus.

Acknowledgments

Declaration of Ethics

The Author has adhered to the Principles of Veterinary Medical Ethics of the AVMA.

Conflict of Interest

The Author has no conflicts of interest.

References

1. Dascanio JJ, Schweizer C, Ley WB. Equine fungal endometritis. *Equine Vet Educ* 2010;13:324–329.
2. Nielsen JM, Fog P, Bojesen AM. Impact of yeast endometritis on fertility in the mare. *J Equine Vet Sci* 2021;99:103409.
3. Pugh DG, Bowen JM, Kloppe LH, et al. Fungal endometritis in mares. *Comp Cont Educ Pract Vet* 1986;8:S173–S182.
4. Coutinho da Silva MA, Alvarenga MA. Fungal endometritis. In: McKinnon AO, Squires WL, Vaala W, Varner DD, eds. *Equine reproduction 2nd ed*. Chichester: Wiley-Blackwell, 2011;2643–2651.
5. Malmgren L, Olsson Engvall E, Engvall A, et al. Aerobic bacterial flora of semen and stallion reproductive tract and its relation to fertility under field conditions. *Acta Vet Scand* 1998;39:173–182.
6. Zafracas AC. Infection of the genital tract in Thoroughbred mares. *J Reprod Fert* 1975;23:349–351.
7. Troedsson MHT. Diseases of the uterus. In: Robinson N, ed. *Current therapy in equine medicine 4th ed*. Philadelphia: W.B. Saunders Company, 1997;517–524.
8. Chengappa MM, Maddux RL, Greer SC, et al. Isolation and identification of yeasts and yeast-like organisms from clinical sources. *J Clin Microbiol* 1984;19:427–428.
9. Heil BA, Paccamonti DL, Sones JL. Role for the mammalian female reproductive tract microbiome in pregnancy outcomes. *Physiol Genomics* 2019;51:390–399.
10. Hurtgen JP, Cummings MR. Diagnosis and treatment of fungal endometritis in mares, in *Proceedings*. Society for Theriogenology, 1982;82.
11. Stout TAE. Fungal endometritis in the mare. *Pferdeheilkunde* 2008;24:83–87.
12. Freeman KP, Roszel JF, Slusher SH, et al. Mycotic infections of the equine uterus. *Equine Pract* 1986;8:34–42.

13. Perkins NR. Equine reproductive pharmacology. *Vet Clin North Am Equine Pract* 1999;15:687–704.
14. Carter GR, Chengappa MM. Introduction to the fungi and fungous infections. In: Carter GR, Chengappa MM, Roberts AW, Claus GW, Rikihisa Y, eds. *Essentials of veterinary microbiology*. Philadelphia: Williams & Wilkins, 1995;251–256.
15. Hess MB, Parker NA, Purswell BJ, et al. Use of lufenuron as a treatment for fungal endometritis in four mares. *J Am Vet Med Assoc* 2002;15:266–267.
16. Scotty NC, Evans TJ, Giuliano E, et al. In vitro efficacy of lufenuron against filamentous fungi and blood concentrations after PO administration in horses. *J Vet Intern Med* 2005;19:878–882.

Use of Biologic Agents to Treat Endometritis: Is There Evidence to Support This?

Marco A. Alvarenga, DVM, MS, PhD*; and Lorenzo G.T.M. Segabinazzi, DVM, MS, PhD

Authors' addresses: São Paulo State University, Botucatu, SP, Brazil. 18618-970 (Alvarenga); Ross University School of Veterinary Medicine, PO Box 334, Basseterre, St. Kitts, West Indies (Segabinazzi); e-mail: marco.alvarenga@unesp.br. *Corresponding and presenting author. © 2022 AAEP.

1. Introduction

Endometritis, inflammation, or/and infection of the endometrium is the most common cause of subfertility in equine species.[1] This condition can be caused by infectious (i.e., fungus and bacteria) or non-infectious agents (i.e., sperm),[2] infectious endometritis plays a major role in equine subfertility.[3,4]

Mares can be classified as resistant or susceptible to endometritis due to the ability to clear the uterus after breeding.[5] Mares susceptible to endometritis have a delayed and prolonged uterine inflammation post-breeding, leading to a hostile uterine environment for establishing a pregnancy.[6,7] In addition, this hostile environment predisposes to uterine infection since pathogenic and opportunistic microorganisms may gain access to the uterus during breeding. It is also important to note that many susceptible mares already have an adverse environment (i.e., uterine fluid accumulation and endometrial inflammation) even before breeding, which can be harmful to the sperm. Therefore, therapies to mitigate endometrial inflammation and improve the uterine environment are required to improve the fertility rates of susceptible mares.

Traditionally, therapies for endometritis have included ecbolic agents (i.e., oxytocin, prostaglandin), uterine lavages, anti-inflammatories, and antibiotics.[3] However, some mares, particularly aged mares, fail to respond to traditional therapies. As a result, alternative treatments have been developed to improve fertility rates in mares with endometritis that is difficult to resolve.

Biologic agents, such as platelet-rich plasma (PRP), autologous conditioned serum (ACS), mesenchymal stem cells (MSC), and the MSC-conditioned medium (MSC-CM) have become prominent therapies in human and veterinary medicine. In the last ten years, these therapies have been tested and used to treat mares with endometritis with promising results.[8–15] This manuscript provides an overview of biological agents that can be used to treat mares with endometritis and how each one of them can be helpful in broodmare practice.

2. Methods

Platelet-Rich Plasma

Platelet-rich plasma (PRP) has become a popular therapy to treat mares that fail to become pregnant due to uterine problems. PRP mitigates post-breeding inflammatory response[9,11–15] and reduces the risk of uterine infections,[9] which makes the PRP a good alternative to treat mares with endometritis.

Platelet-rich plasma is a fractionate of whole blood plasma with high platelet concentration. The platelets

NOTES

are cytoplasmatic fragments of the megakaryocytes that carry numerous growth factors (e.g., vascular endothelial growth factor, transforming growth factor β), cytokines (e.g., TNF-α and CLX8), and antimicrobial peptides (e.g., platelet basic protein, RANTES, thymosin beta-4). These growth factors, cytokines, and antimicrobial peptides are released after platelet activation and act in an anti-inflammatory matter. Even though the mechanisms of PRP to mitigate inflammation are not yet well elucidated, the suppression of inflammatory markers (e.g., COX-2, metalloproteinase-3, TNF-α, IL1β, IL6, CXCL8) has been described in several in vitro studies,[16–18] as well as in mares treated with intrauterine infusion of PRP.[9,13] In addition, PRP has demonstrated antimicrobial activity against microorganisms-causing endometritis[19–21] and reduced post-breeding uterine infections in mares susceptible to endometritis.[9]

Many protocols can be used to produce PRP.[22] Automated commercial and manual protocols have been described. These protocols differ in time to prepare, costs, practicality, volume of blood needed, and materials required for processing. Therefore, the protocol used will depend on the practitioner's choice. In addition, variations of PRP quality can be observed between practitioners, methods, and animals. Although not all the protocols available to produce PRP will be overviewed in this study, the authors will comment on the most commonly used and proposed therapies in mares. Additional protocols can be reviewed in other manuscripts.[22,23] In addition, a commercially available lyophilized PRP[a] has been recently described for use in broodmare practice.[24]

Many clinicians have employed protocols using vacutainer tubes or blood transfusion bags to produce PRP with good results for intrauterine infusion in mares. The vacutainer tubes protocol is the most commonly used in the field. Using this protocol, blood is collected in 4.5 mL vacutainer tubes containing 3.2% sodium citrate to produce PRP. Blood tubes are centrifuged at $120 \times g$ for 10 min. After centrifugation, the top third layer of the plasma is discarded, while the remaining plasma adjacent to the buffy coat is recovered as PRP (Fig. 1). The amount of blood collected to produce PRP by this method depends on the practitioner's choice or the number of tubes placed in the centrifuge.

To produce PRP using a blood transfusion bag, blood is collected in a 450 mL blood transfusion bag containing 63 mL of citrate-phosphate-dextrose solution with adenine as an anticoagulant (CPD-A). Four hundred milliliters of whole blood are split into eight 50-mL tubes and centrifuged at $400 \times g$ for 15 min. After the first centrifugation, the plasma fraction is recovered and transferred into 15-mL conical tubes. This fraction is submitted to centrifugation at $1000 \times g$ for 10 min. After the second centrifugation, 2.5 mL of plasma at the bottom of each tube is preserved as PRP (Fig. 1). This method produces around 40 to 50 mL of PRP for intrauterine infusion.

Practitioners have recently described another protocol that involves harvesting blood in a 60 mL syringe prefilled with 7 mL of CPD-A. The mixed-blood is transferred to a 50-mL falcon tube and centrifuged at $400 \times g$ for 15 min. After centrifugation, the whole plasma fraction (~30 mL) is used for intrauterine infusion (Fig. 1). Many different protocols to obtain PRP have been used to treat mares with uterine problems. The number of treatments, the time that therapy was implemented, and the volume of PRP used for intrauterine infusion varies between studies.[9,11–15,24] Independent of these differences, PRP therapy was able to reduce uterine inflammatory markers and improve the fertility rates of mares in all reports.[9,11–15,24] Results of PRP therapy in mares are highlighted in Table 1.

In one of the authors' studies,[9] mares received four uterine infusions of PRP (Fig. 2). In this study, the treatments were performed 48 and 24 h before and six and 24 h after breeding. The authors observed a significant benefit of those treatments in mitigating endometrial inflammation and uterine infections. However, implementing four treatments can be timing-consuming and expensive. Therefore, some practitioners have chosen only one or two treatments in a cycle to employ PRP therapy, as reported in other studies.[11–15] In the author's experience, the best time to infuse PRP in mares to improve the uterine environment, mitigate post-breeding inflammation, and increase the chances of a mare becoming pregnant are 24 h before and 4-6 h after breeding. Practitioners can modify the protocol to best fit their practice.

3. Platelet Lysate

Platelet lysate (PL) is derived from freeze-thawing PRP. The PL contains all growth factors and cytokines released by the platelets after activation.[25,26] Platelets are activated during cryopreservation, and the bioactive molecules released during this process are preserved in the PL.[25,26] An advantage of PL compared to PRP is that this platelet-derived product can be frozen and stored long-term, making it available for immediate patient use.

The processing of PL is simple. After PRP is obtained, it is diluted with platelet-poor plasma (PPP) obtained during the processing protocol to bring a final volume of 10 to 20 mL. Thereafter, the PRP alone or the PRP+PPP should be frozen at −80°C. The freezing process will cause platelet disruption/activation, and the PL containing platelet-released growth factors will be obtained.[27] PL can be frozen stored until needed. Before intrauterine infusion, PL must be at room temperature (20-25°C). Of interest, this therapy has been recently implemented to treat horses with osteoarthritis injuries.[28,29] In a recent report, PL reduced PMN counts, intrauterine fluid accumulation, and edema score of mares susceptible to endometritis after breeding.[30] Results of mares treated with PL are highlighted in Table 1.

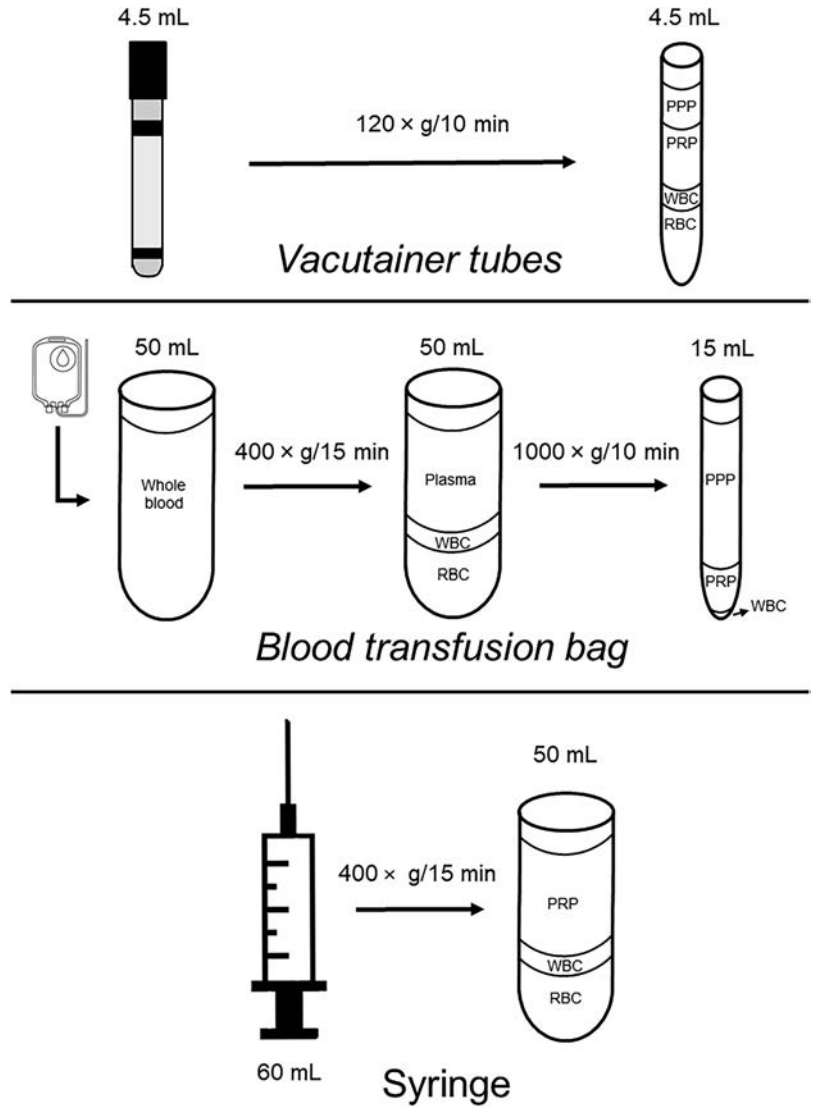

Fig. 1. Diagram of three commonly used methods to prepare platelet-rich plasma (PRP) for intrauterine infusions in mares. Vacutainer tubes containing 3.2% sodium citrate. Blood transfusion bag containing 63 mL of citrate-phosphate-dextrose solution with adenine as an anticoagulant (CPD-A). A 60 mL syringe prefilled with 7 mL of anticoagulant (CPD-A). PPP, platelet-poor plasma; WBC, white blood cells; RBC, red blood cells. Adapted from Segabinazzi et al., 2021.[23]

4. Autologous Conditioned Serum

Autologous conditioned serum (ACS) is a whole serum-containing elevated concentration of anti-inflammatory cytokines and growth factors such as IL-1Rα, TGFβ, FGF-2, and IL-10.[31] There are two commercially available methods to produce ACS, the IRAP[b], and IRAP II[c]. These methods consist of stimulating white blood cells, most specifically the monocytes, to secrete anti-inflammatory cytokines and growth factors. The monocytes are stimulated to produce regenerative and anti-inflammatory proteins without adding drugs. For this, the whole blood is incubated with sterile borosilicate glass beads for 24 h and then centrifuged. After centrifugation, the serum-containing anti-inflammatory properties is harvested. In one study, IRAP II produced a better anti-inflammatory cytokine profile than IRAP in the horse.[31]

Autologous conditioned serum has been used to treat various musculoskeletal conditions in both humans and horses.[32–34] In one study, ACS (IRAP II) was tested for intrauterine infusion in normal mares.[10] The primary finding was a reduction in the neutrophil counts in endometrial cytology after sperm challenge was observed. (Table 1). Further studies are needed to address the effect of ACS in mares susceptible to endometritis.

5. Mesenchymal Stem Cells

Stem cells have been used to treat many human and veterinary medicine conditions due to their regenerative and immunomodulatory properties. These cells have the ability to differentiate into different lineages (e.g., skeletal myoblasts, renal parenchyma, hepatic epithelium, gut and skin epithelia, neuroectodermal cells, and endometrial cells.[35,36]

Table 1. Uterine Inflammatory Markers and Fertility Rates of Mares Treated with Different Biologic Agents

Mare	Volume of Treatment	Concentration	Time of Treatment	Type of AI	Inflammatory Markers	Fertility	Reference
PRP							
Barren mares	10 mL (PRP+PPP)	Not available	24-36 h before AI	Not available	PRP reduced IUF, and expression of IL1β, IL6, CXCL8 and iNOS	Control: 19% (3/19) PRP: 67% (16/24)	Metcalf et al., 2012[13] Metcalf, 2014[14]
One negative cycle	15 mL (6 mL PRP + 9 mL PPP)	Not available	44 h before AI	Frozen-thawed semen	No difference in IUF	Control: 0% (0/18) PRP: 61% (11/18)	Pasch et al., 2021[15]
Susceptible to PBIE	20 mL PRP	$7 \pm 0.3 \times 10^9$ platelets	24 h before or 4 h after AI	Fresh semen	PRP reduced PMN counts and endometrial expression of COX2	Control: 31% (3/13); PRP 24 before AI: 69% (9/13) PRP 4 h after AI: 58% (8/13)	Segabinazzi et al., 2017[11]
Mares with CDE	20 mL PRP	$\sim 5 \times 10^9$ platelets	4 h after AI	Fresh semen	PRP reduced PMN counts and IUF	Not available	Reghini et al., 2016[12]
Susceptible to PBIE	40 mL PRP	$24.9 \pm 1.2 \times 10^9$ platelets	48 and 24 h before, and 6 and 24 h after AI	Fresh semen	PRP reduced PMN counts, IUF, and IL1β and CXCL8 Plasma P4 concentrations were increased	Control: 33% (4/12) PRP: 83% (10/12)	Segabinazzi et al., 2021[9]
Barren mares	20 mL of PRP or 20 mL of reconstituted L-GF^{equina}	$\sim 4 \times 10^9$ platelets	Second day after the end of estrus	Fresh semen	Not available	Control: 6.25% (4/32) PRP: 50% (16/32) L-GF^{equina}: 66.7% (6/9)	Dawod at al., 2021[24]
Susceptible to PBIE	10 mL of PL	2.4×10^9 platelets	24 h before AI	Frozen-thawed semen	PL reduced PMN counts, IUF and edema score	Control: 14% (2/14) PL: 25% (3/12)	Colombo et al., 2022[30]
ACS							
Normal mares	20 mL of ACS		24 h before AI	Dead sperm	ACS reduced PMN counts	Not available	Ferris et al., 2014[10]
MSCs							
Normal mares	20 mL of lactate ringer	20 million allogenic MSCs	24 h before AI	Dead sperm	MSCs reduced PMN counts, and IL1, and increased IL1Ra	Not available	Ferris et al., 2014[10]
Mares with CDE	20 ml of 0.9% sodium chloride	2×10^7 allogenic MSCs	During estrus	-	Downregulated the expression of molecules associated with the development of pathological fibrosis (e.g., cytokeratin, vimentin, smooth muscle actin, and laminin) and promoted glandular epithelial cell proliferation	Not available	Mambelli et al., 2014[46]

(continued on next page)

Table 1. (Continued)

Mare	Volume of Treatment	Concentration	Time of Treatment	Type of AI	Inflammatory Markers	Fertility	Reference
MSC-CM							
Susceptible to PBIE	30 mL of MSC-CM	–	24 h before AI	Fresh semen	MSC-CM reduced PMN counts, IUF, IL6, and increased IL10	Control: 42.9% (3/7) MSC-CM: 85.7% (6/7)	Tongu et al., 2021[8]
Susceptible to PBIE	15 mL of MSC-CM	–	Semen was supplemented with MSC-CM at the time of AI	Fresh semen	MSC-CM reduced PMN counts, IUF, IL6, and increased IL10	Control: 42.9% (3/7) MSC-CM: 57.1% (4/7)	Tongu et al., 2021[8]
Normal mares	15 mL of MSC-CM	–	Semen was supplemented with MSC-CM at the time of AI	Fresh semen	MSC-CM reduced PMN counts	Control: 76.9% (10/13) MSC-CM: 69.3% (9/13)	Tongu et al., 2021[8]
Barren mares	30 mL of MSC-CM	–	24 h before AI	Cooled semen	MSC-CM reduced PMN and IL6	Control: 25% (1/4) MSC-CM: 50% (2/4)	Segabinazzi & Alvarenga (data not published)
Barren mares	30 mL of MSC-CM	–	12 h before AI	Frozen semen	MSC-CM reduced PMN and IL6	Control: 25% (1/4) MSC-CM: 25% (1/4)	Segabinazzi & Alvarenga (data not published)

Abbreviations: PRP, platelet-rich plasma; PPP, platelet-poor plasma; PL, platelet lysate; ACS, autologous conditioned serum; MSCs, mesenchymal stem cells; MSC-CM, mesenchymal stem cells-conditioned medium; IUF, intrauterine fluid; PMN, polymorphonuclear neutrophil; COX2, cyclooxygenase-2; IL1β, interleukin-1β; IL6, interleukin-6; CXCL8, chemokine ligand 8 (interleukin-8); iNOS, nitric oxide synthase; AI, artificial insemination; PBIE, post-breeding induced endometritis; CDE, chronic degenerative endometritis; P4, progesterone.

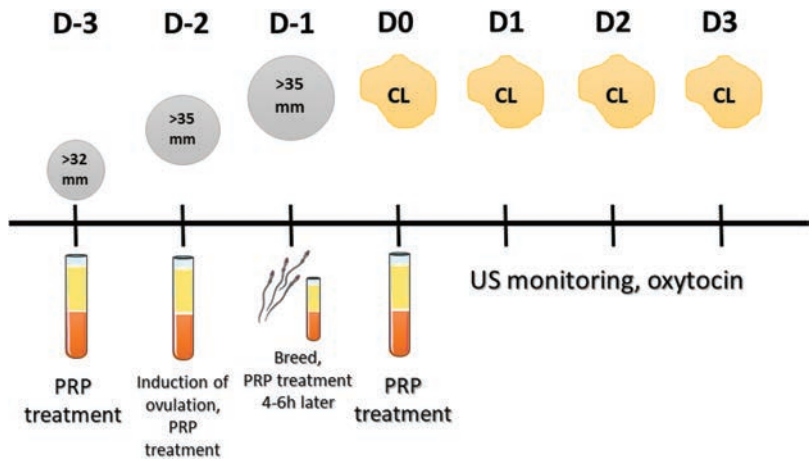

Fig. 2. Protocol for intrauterine infusion of PRP in mares.[9]

There are two major types of stem cells: embryonic stem cells and adult stem cells. Embryonic stem cells have greater potential to differentiate, however, embryonic stem cells have not been used in depth due to legal and ethical considerations. In addition, embryonic stem cells have been associated with tumorigenesis potential.[37,38] Using adult mesenchymal stem cells (MSCs) is less problematic. Mesenchymal stem cells are stromal cells that can exhibit multilineage differentiation. MSCs can be isolated from various tissues, such as bone marrow, fatty tissue, dental pulp, umbilical cord, amniotic membrane, endometrium, menses blood, and more.[39,40]

The ability to cultivate and isolate MSCs in vitro is a distinct advantage of this therapy in both human and veterinary medicine.[39,40] In equine medicine, bone marrow and adipose are the most commonly used sources of stem cells[41,42] and have been used as regenerative therapy in treatment of cartilage and tendinous tissue.[43,44] Although stem cells have not yet been employed to treat uterine problems in mares, some studies have reported promising results using stem cells in the injured endometrium and also for modulation of endometrial inflammation.[10,45,46]

Because of the regenerative potential of stem cells, this therapy has been employed to treat injured tissues that have complex regeneration. Regeneration of the endometrium has been indicated in one study using rats as an experimental model treated with stem cells.[47] In mares suffering from CDE, intrauterine infusion of MSCS therapy may induce early (7 days) and prolonged (60 days) remodeling of the endometrium and promote glandular epithelial cells proliferation.[46] Preliminary results of one of the authors' studies have demonstrated that endoscopic endometrial injections of MSCs may reduce endometrial fibrosis and improve the endometrial biopsy score[48] of mares suffering from CDE. For endometrial injection of MSCs, a flexible endoscope and injection needles coupled to a Teflon catheter are used. Mares are restrained in an examination stock and sedated (e.g., xylazine or detomidine). The endoscope is passed manually through the vagina and cervix, and then the uterus is insufflated with air to allow visualization of the entire endometrial surface. Injections of 0.5 mL of the MSCs solution are performed following a horizontal line from the extremity of one uterine horn to the other (Fig. 3). The amount of MSCs used for this therapy depends on the practitioner's choice. The authors suggest a concentration between 12 to 20 million cells for endometrial injections.[49]

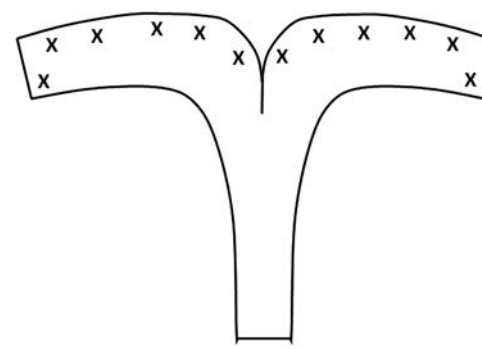

Fig. 3. Diagram for endometrial injection of stem cells (Alvarenga & Segabinazzi, 2016).[49]

Although there is a lack of information on MSCs therapy aiming to treat endometritis in mares, this therapy has been reported to decrease neutrophil numbers and increase anti-inflammatory ILRN expression in normal mares.[10] Despite the regenerative potential of MSCs, these cells also secrete a wide range of bioactive molecules (PGE2, TGFβ, IL-10, IL-1Ra, CXL8, HGF, and iNOS), which can drive the modulation of the inflammatory process.[50–52] The immunomodulatory capacity of MSCs has been reported to treat acute and chronic inflammation[53] and has been successfully used to treat inflammatory conditions in horses (e.g., osteoarthritis, tendinitis, and tendon and ligament injuries).[54,55] These data demonstrate the potential of stem cells therapy to treat uterine diseases

in mares, which should be further explored. Data of uterine MSCs therapy in mares are highlighted in Table 1.

6. Mesenchymal Stem Cell-Conditioned Medium

Mesenchymal stem cell-conditioned medium (MSC-CM) is the culture medium used for in vitro stem cells culture and growth. MSCs secrete a wide range of paracrine signaling molecules, such as cytokines, chemokines (e.g., IL10, CXL8, and IL1Ra) and growth factors (e.g., TGFb, PGE2, and HGF).[50–52] MSC-CM contains the same bioactive molecules which modulate inflammation and tissue repair.[56–58] Although the employment of MSC-CM as therapy is relatively new, some reports have already shown the immunoregulatory capacity of this therapy in acute and chronic inflammatory conditions in a variety of species,[59,60] including horses.[61]

In a recent study,[8] MSC-CM mitigated the endometrial inflammatory response in mares susceptible to endometritis. After breeding, mares treated with MSC-CM had reduced intrauterine fluid accumulation and neutrophil counts. In addition, MSC-CM therapy downregulated IL6 and upregulated IL10 in the uterus of susceptible mares. Although fertility rates were not statistically affected in that study, a numerical increment was observed. A small number of animals was used in this study which may have contributed to lack of difference in pregnancy rates. In a recent study[d], intrauterine infusion of MSC-CM was used to treat barren mares (n = 8) (data nonpublished). Inflammatory markers (e.g., neutrophils, cytokines, and intrauterine fluid accumulation) were downregulated by MSC-CM therapy. However, MSC-CM did not reduce uterine infections or improve the fertility of barren mares. Data of MSC-CM treatment in broodmare practice are highlighted in Table 1.

Although much more must be explored in MSC-CM therapy before the treatment is implemented in equine practice, the authors' results encourage the use of this therapy to treat uterine inflammatory conditions in mares. In addition, MSC-CM has the benefit in that it is not a cell suspension and can therefore be easily manufactured, lyophilized, stored, and transported. Moreover, MSC-CM does not require tests to determine compatibility with possible recipients, thus avoiding potential rejection.[58,61] Further studies are needed to evaluate and understand the effect of MSC-CM therapy in barren mare's practice.

7. Discussion

Endometritis in mares has been traditionally treated with multi-modal therapies.[3] These therapies consist of the use of ecbolic drugs (e.g., oxytocin, prostaglandin), uterine lavage, mucolytic and antiseptic agents, anti-inflammatory drugs, and antibiotics. However, some mares fail to respond to traditional therapies, and alternative treatments have been researched for those mares. The increasing incidence of antibiotic-resistant microorganisms increases the necessity of alternatives.[3,4]

Among the biologic therapies, PRP has been tested the most and has been used in the practice.[9,11–15] Besides the ability to mitigate the post-breeding inflammation in mares susceptible to endometritis, PRP has also been described to reduce the risk of uterine infections in susceptible mares.[9] In vitro studies have described the antimicrobial potential of PRP, even against some bacteria causing endometritis in mares (e.g., *Staphylococcus aureus*, *Escherichia coli*, and *Klebsiella pneumoniae*).[19,20,62,63] Most importantly, in all reports, using PRP to treat mares has improved fertility rates.[9,11–15] All these facts have made PRP gain popularity in equine reproductive practice. In addition, other types of platelet-derived products, such as PL and a commercially available lyophilized PRP,[1] have been tested with success on the treatment of mares suffering from endometritis.[24,30] Therefore, platelet-derived therapies can be considered an efficient therapy for broodmare practice.

While other biologic therapies (e.g., ACS, MSCs, MSC-CM) have not been tested for antimicrobial properties in mares, all of them have proven to reduce the uterine inflammatory reaction after sperm challenge in mares.[8,10] Although not all these therapies have been tested in mares susceptible to endometritis but the MSC-CM, they might be helpful approaches to control the exacerbated endometrial inflammation in this category of mares. The uterine inflammatory response in susceptible mares starts even before the sperm challenge. Mares susceptible to endometritis have an imbalance in the endometrial cytokines profile, with pro-inflammatory cytokines (e.g., IL1β, IL6, CXCL8, and TNFα) upregulated in the endometrium even before contact with antigens (sperm or bacteria).[64,65] In addition, these mares are unable to produce sufficient anti-inflammatory cytokines (e.g., IL10 and IL1Rα), which delays the resolution of the inflammatory process.[64,66] As a result, an exacerbated and delayed inflammatory reaction with a high influx of inflammatory cells into the uterine lumen causes intrauterine fluid accumulation, which produces a hostile uterine environment.[6] In one study testing intrauterine therapy with MSCs and ACS 24 h before breedings, the authors observed a reduction in inflammatory markers but not a reduction in intrauterine fluid accumulation after sperm challenging in mares.[10] Fertility was not tested in that study. However, the results reported in the mentioned study are encouraging since only mares considered normal were enrolled.[10] Mares considered normal or resistant to endometritis do not present exacerbated and delayed post-breeding inflammatory reaction;[65] so they are not prone to changes using immunomodulatory therapies.[8,64,67] Therefore, the results described by the authors[10] encourage research with ACS and MSCs in mares susceptible to endometritis. An additional benefit of MSC use has been shown in mares with CDE. In this population of mares, MSCs effectively house in the periglandular space of the endometrium and modulate expression patterns

(e.g., cytokeratin, vimentin, α-smooth muscle actin, and laminin) associated with the development of pathological fibrosis in the horse endometrium.[45,46] Preliminary results of the authors' group demonstrate that MSCs may improve the endometrial score of mares suffering from CDE.[68] Moreover, in rats as an experimental model, MSCs regulated endometrial inflammatory cytokines, regenerated endometrial cells, and upregulated markers for endometrial receptivity (integrin agb3 and leukemia inhibitory factor).[47] It is well known that mares with a higher grade of endometrial fibrosis are more prone to develop endometritis and have fewer chances to carry a pregnancy to term.[48] Therefore, MSCs might have a potential application in mares with CDE and must be further explored. Of interest, the MSC-CM has shown potential to mitigate post-inflammatory response in mares susceptible to endometritis.[8] In this study, the intrauterine infusion of MSC-CM, before breeding or mixed with semen, increased intrauterine expression of IL10, and reduced post-breeding intrauterine fluid accumulation, endometrial PMNs counts, and uterine expression of IL6 in mares susceptible to endometritis. Although fertility rates were not changed in the study, a positive numerical difference (2-fold) could be observed after MSC-CM therapy. In addition, it was interesting that MSC-CM was not harmful to the sperm when semen was supplemented with MSC-CM, which opens an alternative for the time of treatment using this therapy. Another important benefit of MSC-CM is that it is not a cell suspension; therefore, it does not require tests to determine compatibility with possible recipients.[58,61] Moreover, MSC-CM can be frozen or manufactured, lyophilized, packaged, and transported, which makes this therapy available more quickly than others (e.g., PRP, MSCs, ACS) for immediate application.

In summary, biologic therapies provide an excellent treatment for alleviating post-breeding inflammation in mares. The regulation of the inflammatory factors and the inflammatory process create a better uterine environment both for the sperm and the embryo entering the uterus. Although much more must be explored in biological therapies to treat uterine problems in mares, the evidence so far is encouraging.

Acknowledgments

The Authors would like to thank FAPESP (São Paulo Research Foundation, SP, Brazil) and USDA Animal Health Hatch funds for funding some of the key studies described in this manuscript.

Declaration of Ethics

The Authors have adhered to the Principles of Veterinary Medical Ethics of the AVMA.

Conflict of Interest

The Authors have no conflicts of interest.

References and Footnotes

1. Troedsson MHT. Uterine clearance and resistance to persistent endometritis in the mare. *Theriogenology* 1999;52:461–471.
2. Troedsson MH, Liu IK, Crabo B. Sperm transport and survival in the mare. *Theriogenology* 1998;49:905–915.
3. Canisso IF, Segabinazzi LGTM, Fedorka CE. Persistent breeding-induced endometritis in mares — A multifaceted challenge: from clinical aspects to immunopathogenesis and pathobiology. *IJMS* 2020;21:1432.
4. Riddle WT, LeBlanc MM, Stromberg AJ. Relationships between uterine culture, cytology and pregnancy rates in a Thoroughbred practice. *Theriogenology* 2007;68:395–402.
5. Carnevale EM, Ramirez RJ, Squires EL, et al. Factors affecting pregnancy rates and early embryonic death after equine embryo transfer. *Theriogenology* 2000;54:965–979.
6. Troedsson MHT. Therapeutic considerations for mating-induced endometritis. *Pferdeheilkd. Equine Med* 1997;13: 516–520.
7. Troedsson MH, Liu IK. Uterine clearance of non-antigenic markers (51Cr) in response to a bacterial challenge in mares potentially susceptible and resistant to chronic uterine infections. *J Reprod Fertil Suppl* 1991;44:283–288.
8. Tongu EAdO, Segabinazzi LGTM, Alvarenga ML, et al. Allogenic mesenchymal stem cell-conditioned medium does not affect sperm parameters and mitigates early endometrial inflammatory responses in mares. *Theriogenology* 2021;169: 1–8.
9. Segabinazzi LGTM, Canisso IF, Podico G, et al. Intrauterine blood plasma platelet-therapy mitigates persistent breeding-induced endometritis, reduces uterine infections, and improves embryo recovery in mares. *Antibiotics* 2021; 10:490.
10. Ferris RA, Frisbie DD, McCue PM. Use of mesenchymal stem cells or autologous conditioned serum to modulate the inflammatory response to spermatozoa in mares. *Theriogenology* 2014;82:36–42.
11. Segabinazzi LG, Friso AM, Correal SB, et al. Uterine clinical findings, fertility rate, leucocyte migration, and COX-2 protein levels in the endometrial tissue of susceptible mares treated with platelet-rich plasma before and after AI. *Theriogenology* 2017;104:120–126.
12. Reghini MFS, Ramires Neto C, Segabinazzi LG, et al. Inflammatory response in chronic degenerative endometritis mares treated with platelet-rich plasma. *Theriogenology* 2016;86:516–522.
13. Metcalf ES, Scoggin K, Troedsson MHT. The effect of platelet-rich plasma on endometrial pro-inflammatory cytokines in susceptible mares following semen deposition. *J. Equine Vet. Sci* 2012;32:498.
14. Metcalf ES. The effect of Platelet-Rich Plasma (PRP) on intraluminal fluid and pregnancy rates in mares susceptible to persistent mating-induced endometritis (PMIE). *J. Equine Vet. Sci* 2014;34:128.
15. Pasch L, Schmidt A, King W. Clinical observations after pre breeding intrauterine plasma infusion in 18 mares inseminated with thawed frozen semen. *J Equine Vet Sci* 2021; 99:103389.
16. Kim H-J, Yeom JS, Koh Y-G, et al. Anti-inflammatory effect of platelet-rich plasma on nucleus pulposus cells with response of TNF-α and IL-1. *J Orthop Res* 2014;32:551–556.
17. Sundman EA, Cole BJ, Karas V, et al. The anti-inflammatory and matrix restorative mechanisms of platelet-rich plasma in osteoarthritis. *Am J Sports Med* 2014;42:35–41.
18. Wu C-C, Chen W-H, Zao B, et al. Regenerative potentials of platelet-rich plasma enhanced by collagen in retrieving pro-inflammatory cytokine-inhibited chondrogenesis. *Biomaterials* 2011;32:5847–5854.
19. Anitua E, Alonso R, Girbau C, et al. Antibacterial effect of plasma rich in growth factors (PRGF®-Endoret®) against Staphylococcus aureus and Staphylococcus epidermidis strains. *Clin Exp Dermatol* 2012;37:652–657.
20. Álvarez M, López C, Giraldo C, et al. In vitro bactericidal activity of equine platelet concentrates, platelet poor plasma,

and plasma against methicillin-resistant Staphylococcus aureus. *Arch med vet* 2011;43:155–161.
21. Bielecki TM, Gazdzik TS, Arendt J, et al. Antibacterial effect of autologous platelet gel enriched with growth factors and other active substances. *J Bone Joint Surg Br* 2007;89:417–420.
22. Segabinazzi LGTM, Canisso IF. How to prepare platelet-rich plasma for use in reproductive practices with mares. *AAEP proceedings* vol. 67, 2021, 253–260.
23. Segabinazzi LGTM, Podico G, Rosser MF, et al. Three manual noncommercial methods to prepare equine platelet-rich plasma. *Animals* 2021;11:1478.
24. Dawod A, Miro J, Elbaz HT, et al. Effect of intrauterine infusion of equine fresh platelets-rich plasma (PRP) or lyophilized PRP (L-GFequina) on ovarian activity and pregnancy rate in repeat breeder purebred Arabian mares. *Animals* 2021;11:1123.
25. Soares CS, Babo PS, Reis RL, et al. Platelet-derived products in veterinary medicine: A new trend or an effective therapy? *Trends Biotechnol* 2020;20:30206–30207.
26. Roffi A, Filardo G, Assirelli E, et al. Does platelet-rich plasma freeze-thawing influence growth factor release and their effects on chondrocytes and synoviocytes? *Biomed Res Int* 2014;2014:692913.
27. Doucet C, Ernou I, Zhang Y, et al. Platelet lysates promote mesenchymal stem cell expansion: A safety substitute for animal serum in cell-based therapy applications. *J Cell Physiol* 2005;205:228–236.
28. Perrone G, et al. Treatment with platelet lysate inhibits proteases of synovial fluid in equines with osteoarthritis. *J. Equine Vet. Sci* 2020;88.
29. Tyrnenopoulou P, Diakakis N, Karayannopoulou M, et al. Evaluation of intra-articular injection of autologous platelet lysate (PL) in horses with osteoarthritis of the distal interphalangeal joint. *Vet. Q* 2016;36:56–62.
30. Colombo I, Mislei B, Mari G, et al. Effect of platelet lysate on uterine response of mares susceptible to persistent mating-induced endometritis. *Theriogenology* 2022;179:204–210.
31. Hraha TH, Doremus KM, Mcilwraith CW, et al. Autologous conditioned serum: The comparative cytokine profiles of two commercial methods (IRAP and IRAP II) using equine blood. *Equine Vet J* 2011;43:516–521.
32. Frisbie DD, Kawcak CE, Werpy NM, et al. Clinical, biochemical, and histologic effects of intra-articular administration of autologous conditioned serum in horses with experimentally induced osteoarthritis. *Am J Vet Res* 2007;68:290–296.
33. Baltzer AWA, Moser C, Jansen SA, et al. Autologous conditioned serum (Orthokine) is an effective treatment for knee osteoarthritis. *Osteoarthritis Cartilage* 2009;17:152–160.
34. Wehling P, Moser C, Frisbie D, et al. Autologous conditioned serum in the treatment of orthopedic diseases: The Orthokine® therapy. *BioDrugs* 2007;21:323–332.
35. Grove JE, Bruscia E, Krause DS. Plasticity of bone marrow-derived stem cells. *Stem Cells* 2004;22:487–500.
36. Du H, Taylor HS. Contribution of Bone Marrow-Derived Stem Cells to Endometrium and Endometriosis. *Stem Cells* 2007;25:2082–2086.
37. Wu DC, Boyd AS, Wood KJ. Embryonic stem cell transplantation: potential applicability in cell replacement therapy and regenerative medicine. *Front Biosci* 2007;12:4525–4535.
38. Baker DEC, Harrison NJ, Maltby E, et al. Adaptation to culture of human embryonic stem cells and oncogenesis in vivo. *Nat Biotechnol* 2007;25:207–215.
39. Caplan AI. Mesenchymal stem cells. *J Orthop Res* 1991; 9:641–650.
40. Ding DC, Shyu WC, Lin SZ. Mesenchymal stem cells. *Cell Transplant* 2011;20:5–14.
41. Smith RKW, Webbon PM. Harnessing the stem cell for the treatment of tendon injuries: Heralding a new dawn? *Br J Sports Med* 2005;39:582–584.
42. Koch TG, Betts DH. Stem cell therapy for joint problems using the horse as a clinically relevant animal model. *Expert Opin Biol Ther* 2007;7:1621–1626.
43. Fortier LA, Smith RK. Evidence for stem cells in cartilage regeneration. *AAEP Proc* 2007;53:329–334.
44. Fortier LA, Smith RKW. Regenerative medicine for tendinous and ligamentous injuries of sport horses. *Vet Clin North Am Equine Pract* 2008;24:191–201.
45. Mambelli LI, Winter GHZ, Kerkis A, et al. A novel strategy of mesenchymal stem cells delivery in the uterus of mares with endometriosis. *Theriogenology* 2013;79:744–750.
46. Mambelli LI, Mattos RC, Winter GHZ, et al. Changes in expression pattern of selected endometrial proteins following mesenchymal stem cells infusion in mares with endometriosis. *PLoS One* 2014;9:e97889.
47. Zhao J, Zhang Q, Wang Y, et al. Uterine infusion with bone marrow mesenchymal stem cells improves endometrium thickness in a rat model of thin endometrium. *Reprod Sci* 2015;22:181–188.
48. Kenney RM, Doig PA. Equine endometrial biopsy. In Morrow DA, ed. *Current Therapy in Theriogenology*. W.B. Saunders Company, Philadelphia, PA; 1986, 723-729.
49. Alvarenga MA, do Carmo MT, Segabinazzi LG, et al. Feasibility and Safety of Endometrial Injection of Autologous Bone Marrow Mesenchymal Stem Cells in Mares. *J. Equine Vet. Sci* 2016;42:12–18.
50. Carrade DD, Lame MW, Kent MS, et al. Comparative analysis of the immunomodulatory properties of equine adult-derived mesenchymal stem cells. *Cell Med* 2012;4:1–12.
51. Gugjoo MB, Amarpal, Makhdoomi DM, et al. Equine mesenchymal stem cells: Properties, sources, characterization, and potential therapeutic applications. *J. Equine Vet. Sci* 2019;72:16–27.
52. da Silva Meirelles L, Fontes AM, Covas DT, et al. Mechanisms involved in the therapeutic properties of mesenchymal stem cells. *Cytokine Growth Factor Rev* 2009;20:419–427.
53. Iyer SS, Rojas M. Anti-inflammatory effects of mesenchymal stem cells: Novel. *Expert Opin Biol Ther* 2008;8:569–582.
54. Frisbie DD, Kisiday JD, Kawcak CE, et al. Evaluation of adipose-derived stromal vascular fraction or bone marrow-derived mesenchymal stem cells for treatment of osteoarthritis. *J Orthop Res* 2009;27:1675–1680.
55. Frisbie DD, Smith RKW. Clinical update on the use of mesenchymal stem cells in equine orthopaedics. *Equine Vet J* 2010;42:86–89.
56. Hao P, Liang Z, Piao H, et al. Conditioned medium of human adipose-derived mesenchymal stem cells mediates protection in neurons following glutamate excitotoxicity by regulating energy metabolism and GAP-43 expression. *Metab Brain Dis* 2014;29:193–205.
57. Maia L, Dias MC, Moraes CND, et al. Conditioned medium : A new alternative for cryopreservation of equine umbilical cord mesenchymal stem cells. *Cell Biol Int* 2017;41:239–248.
58. Pawitan JA. Prospect of stem cell conditioned medium in regenerative medicine. *Biomed Res Int* 2014;2014:965849–965814.
59. Ahmadi M, Rahbarghazi R, Aslani MR, et al. Bone marrow mesenchymal stem cells and their conditioned media could potentially ameliorate ovalbumin-induced asthmatic changes. *Biomed. Pharmacother* 2017;85:28–40.
60. Pouya S, Heidari M, Baghaei K, et al. Study the effects of mesenchymal stem cell conditioned medium injection in mouse model of acute colitis. *Int Immunopharmacol* 2018; 54:86–94.
61. Lange-Consiglio A, Rossi D, Tassan S, et al. Conditioned medium from horse amniotic membrane-derived multipotent progenitor cells: Immunomodulatory activity in vitro and first clinical application in tendon and ligament injuries in vivo. *Stem Cells Dev* 2013;22:3015–3024.
62. Burnouf T, Chou M-L, Wu Y-W, et al. Antimicrobial activity of platelet (PLT)-poor plasma, PLT-rich plasma, PLT gel, and solvent/detergent-treated PLT lysate biomaterials against wound bacteria. *Transfusion* 2013;53:138–146.

63. Gilbertie JM, Schaer TP, Schubert AG, et al. Platelet-rich plasma lysate displays antibiofilm properties and restores antimicrobial activity against synovial fluid biofilms in vitro. *J Orthop Res* 2020;38:1365–1374.
64. Fumuso E, Giguère S, Wade J, et al. Endometrial IL-1β, IL-6 and TNF-α, mRNA expression in mares resistant or susceptible to post-breeding endometritis. Effects of estrous cycle, artificial insemination and immunomodulation. *Vet Immunol Immunopathol* 2003;96:31–41.
65. Woodward EM, Christoffersen M, Campos J, et al. Endometrial inflammatory markers of the early immune response in mares susceptible or resistant to persistent breeding-induced endometritis. *Reproduction* 2013;145:289–296.
66. Fumuso E, Aguilar J, Giguere S, et al. Interleukin-8 (IL-8) and 10 (IL-10) mRNA transcriptions in the endometrium of normal mares and mares susceptible to persistent post-breeding endometritis. *Anim Reprod Sci* 2006;94:282–285.
67. Fumuso EA, Aguilar J, Giguère S, et al. Immune parameters in mares resistant and susceptible to persistent post-breeding endometritis: effects of immunomodulation. *Vet. Immunol. Immunopathol* 2007;118:30–39.
68. Segabinazzi LGTM, Carmo MT, Fonseca-Alves CE, et al. Endometrial injection of mesenchymal stem cells may revert endometriosis in mares, in *Proceedings*. Therio Conference, 2022, Bellevue, WA.

[a]GFequina L, Cairo Medical Centre Blood Bank, Cairo, Egypt.
[b]Dechra, Dusseldorf, Germany.
[c]Arthrex, Bonita Springs, FL 34134.
[d]Alvarenga M, Segabinazzi GTM, unpublished data, 2022.

Voluntary Surveillance Program for Equine Influenza Virus in the United States During 2008-2021

Duane E. Chappell, DVM*; D. Craig Barnett, DVM; Kaitlyn James, MPH, PhD; Bryant Craig, DVM; Fairfield Bain, DVM, MBA, DACVIM, DACVECC, DACVP; Earl Gaughan, DVM, DACVS; Chrissie Schneider, DVM, MS, DABVP; Wendy Vaala, VMD, DACVIM; Samantha M. Barnum, MS; and Nicola Pusterla, DVM, PhD, DACVIM, DAVDC-Equine

A voluntary upper respiratory biosurveillance program received 9,740 nasal swab submissions from 42 states during the years 2008-2021 with an equine influenza virus (EIV) positivity rate via qPCR of 9.9%. Horses < 9 years of age with history of recent travel and disease occurrence during winter and spring were most represented. These findings support the need for diagnostics to differentiate causative pathogens. Authors' addresses: 196 Woodridge Drive, Lancaster, KY 40444 (Chappell); 31568 Beaver Creek Road, Paola, KS 66071-7426 (Barnett); 119 Blueberry Hill Lane, North Andover, MA 01845 (James); 1605 Irvine Drive, Edmond, OK 73025 (Craig); 25 Vista De Oro, Placitas, NM 87043 (Bain); 5860 Sioux Drive, Sedalia, CO 80135 (Gaughan); 1207 Slade Avenue, Columbus, OH 43235 (Schneider); S1476 Pleasant View Road, Alma, WI 54610 (Vaala); University of California-Davis, School of Veterinary Medicine, Veterinary Medicine and Epidemiology, One Shields Avenue, Davis, CA 95616 (Barnum, Pusterla); e-mail: duane.chappell@merck.com. *Corresponding and presenting author. © 2022 AAEP.

1. Introduction

Equine influenza virus (EIV) is a highly contagious and rapidly spreading pathogen, leading to predictable and repeatable clinical signs of fever, nasal discharge, and cough. Due to similarity in clinical signs with other upper respiratory pathogens, differentiation is critical for appropriate management decisions, treatment protocols, and biosecurity actions. The purpose of this ongoing surveillance program is pathogen differentiation for disease and biosecurity management decisions and evaluation of vaccination protocols.

2. Materials and Methods

Nasal swabs and whole blood from equids with acute onset of fever and respiratory signs were submitted to a diagnostic laboratory for qPCR evaluation for equine herpesvirus-1 and -4, EIV, equine rhinitis A and B virus,

Research Abstract—for more information, contact the corresponding author

NOTES

and *Streptococcus equi subspecies equi*. A questionnaire was included with each submission. Diagnostic testing was performed with real-time qPCR within 24 hours of sample arrival. Basic frequency statistics and multivariate logistic regression models were utilized to determine the associations between risk factors and EIV positivity.

3. Results and Discussion

A total of 966 positive samples for EIV were received from 35 states with a positivity rate of 9.9%. While EIV affected all ages, breeds and was reported throughout all seasons, Quarter Horses ranging between 1-9 years of age with a recent travel history during winter and spring seasons were most commonly infected.

Acknowledgments

A sincere thank you to the participating veterinarians and veterinary clinics who have submitted and continue to submit respiratory samples to this ongoing respiratory surveillance program. The results we have reviewed today reflect your desire to know more about equine infectious respiratory disease.

Funding Source

This ongoing respiratory biosurveillance study is funded by Merck Animal Health.

Declaration of Ethics

The Authors have adhered to the Principles of Veterinary Medical Ethics of the AVMA.

Conflict of Interest

Sample selection and submission to this voluntary program is determined by the submitting veterinarian. The following co-authors are employed by Merck Animal Health: Drs. Duane Chappell, Bryant Craig, Fairfield Bain, Chrissie Schneider, and Wendy Vaala. The following co-authors were previously employed by Merck Animal Health: Drs. Craig Barnett and Earl Gaughan during the time of this study. Dr. Nicola Pusterla and Samantha Mapes are employed by UC Davis School of Veterinary Medicine where the PCR laboratory is located. Dr. Kaitlyn James has served as a paid independent statistician by Merck Animal Health to provide analysis for this project.

Investigation of the Use of Non-Invasive Samples for the Molecular Detection of EHV-1 in Horses with Clinical and Subclinical Infection

Danielle Price, DVM; Samantha Barnum, MS; Jenny Mize; and Nicola Pusterla, DVM, PhD, DACVIM, DAVDC-Equine*

The sampling of noninvasive swabs from the muzzle/nares should facilitate the identification of equine herpesvirus (EHV)-1 shedders during an outbreak, allowing for prompt isolation and implementation of biosecurity measures. Authors' addresses: Steinbeck Peninsula Equine Clinics, Menlo Park Clinic, Menlo Park, CA 94028 (Price, Mize); Department of Medicine and Epidemiology, School of Veterinary Medicine, University of California–Davis, Davis, CA 95616 (Barnum, Pusterla); e-mail: npusterla@ucdavis.edu. *Corresponding and presenting author. © 2022 AAEP.

1. Introduction

While the collection of whole blood and nasal secretions from horses with clinical disease for the molecular testing of equine herpesvirus (EHV)-1 is considered the diagnostic gold standard and is well justified by all stakeholders, the testing in contact horses is sometimes difficult to justify, mostly because of the owners' perception that nasal swabs are invasive and cause momentary discomfort. The purpose of this study was to explore sampling options for a reliable and logistically more feasible protocol during a large EHV-1 outbreak.

2. Materials and Methods

Seventeen horses with clinical infection as well as 19 healthy herdmates, all part of an equine herpesvirus myeloencephalopathy (EHM) outbreak, were enrolled in the study. Following owners' consent for study enrollment, each horse was sampled 2 to 4 times at intervals of 2 to 6 days during the outbreak. All samples were collected using 6-in. rayon-tipped swabs. Nasal secretions were used as the gold standard sample type. Additional samples, including swabs from the muzzle/nares, swabs from the front limbs, rectal swabs, swabs of the feed bin, and swabs of the water trough, were collected as well. All swabs were tested for the presence of EHV-1 by quantitative polymerase chain reaction (qPCR), targeting the *gB* and *ORF 30* gene.

3. Results and Discussion

A total of 94 sets of swabs were collected from the study horses during the outbreak. With the exception of 2

Research Abstract—for more information, contact the corresponding author

NOTES

EHV-1 qPCR-positive swabs from 2 different horses (1 nasal and 1 muzzle/nares swab), all remaining swabs collected from healthy herdmates tested qPCR negative for EHV-1. For horses with clinical infection, EHV-1 was detected in 31 nasal swabs, 30 muzzle/nares swabs, 7 front limb swabs, 7 feeders, 6 water troughs, and 6 rectal swabs. Not all positive muzzle/nares swabs correlated with a positive nasal swab from the same set, but all other positive swabs did correlate with a positive nasal swab in their respective set. The agreement between nasal swabs and muzzle/nares swabs was 74%. Agreement between nasal swabs and the other 4 swab types was low.

Acknowledgments

The Authors would like to thank the management of the horse facility and all horse owners for participating in this study.

Funding Source

This research was funded by an Advancement in Equine Research Award, Boehringer, Ingelheim Animal Health.

Declaration of Ethics

The Authors have adhered to the Principles of Veterinary Medical Ethics of the AVMA.

Conflict of Interest

The Authors have no conflicts of interest.

Investigation of the Role of Healthy and Sick Equids in the COVID-19 Pandemic Through Serological and Molecular Testing

Kaila O.Y. Lawton; Rick M. Arthur, DVM; Benjamin C. Moeller, PhD, DABT; Samantha M. Barnum, MS; and Nicola Pusterla, DVM, PhD, DACVIM, DAVDC-Equine*

Horses may act as incidental host and experience silent infection following spillover from humans with COVID-19. SARS-CoV-2-infected humans should avoid close contact with equids during the time of their illness. Authors' addresses: Department of Medicine and Epidemiology, (Lawton, Barnum, Pusterla), KL Maddy Equine Analytical Chemistry Laboratory and Department of Molecular Biosciences (Moeller), School of Veterinary Medicine (Arthur), University of California-Davis, Davis, CA 95616; e-mail: npusterla@ucdavis.edu. *Corresponding and presenting author. © 2022 AAEP.

1. Introduction

While horses are apparently susceptible to SARS-CoV-2 infection based on the homology between the human and the equine ACE-2 receptor, no clinical or subclinical infection has yet been reported in the equine species. The aims of the present study were to determine if SARS-CoV-2 could be detected in nasal secretions of equids with acute onset of fever and respiratory signs using quantitative polymerase chain reaction (qPCR) and to investigate the seroprevalence against SARS-CoV-2 in a cohort of healthy racing horses with possible exposure to humans with SARS-CoV-2 infection.

2. Materials and Methods

To investigate the possible clinical role of SARS-CoV-2 in equids, nasal secretions from 667 horses with acute onset of fever and respiratory signs were tested for the presence of SARS-CoV-2 by qPCR. The samples were collected from January to December of 2020 and submitted to a commercial molecular diagnostic laboratory for the detection of common respiratory pathogens (equine influenza virus, equine herpesvirus types 1 and 4, equine rhinitis A and B viruses, *Streptococcus equi* subspecies *equi*). Additional serum samples from a separate cohort of healthy horses were tested for antibodies to SARS-CoV-2 using an

Research Abstract—for more information, contact the corresponding author

NOTES

enzyme-linked immunosorbent assay targeting the receptor-binding domain of the spike protein. The serum samples were collected in 2020 from a cohort of 587 racing Thoroughbreds in California after track personnel tested qPCR-positive for SARS-CoV-2.

3. Results and Discussion

While 241/667 (36%) equids with fever and respiratory signs tested qPCR-positive for at least one of the common respiratory pathogens, not a single horse tested qPCR-positive for SARS-CoV-2. Amongst the healthy racing Thoroughbreds, 35/587 (5.9%) horses had detectable antibodies to SARS-CoV-2. Similar to dogs and cats, horses do not seem to develop clinical SARS-CoV-2 infection. However, horses may act as incidental host and experience silent infection following spillover from humans with COVID-19.

Acknowledgments

Funding Sources

This study was funded by an Advancement in Equine Research Award from Boehringer Ingelheim Animal Health and by the Center for Equine Health, School of Veterinary Medicine, University of California, Davis, with additional contributions from public and private donors.

Declaration of Ethics

The Authors have adhered to the Principles of Veterinary Medical Ethics of the AVMA.

Conflict of Interest

The Authors have no conflicts of interest.

A Fresh Look at the SarcoFluor Antibody Test for the Detection of Specific Antibodies to *Sarcocystis neurona*, Agent of Equine Protozoal Myeloencephalitis

Pranav Pandit, BVSc & AH, MPVM, PhD*; Woutrina Smith, DVM, PhD; Carrie J. Finno, DVM, PhD, DACVIM (LAIM); Monica Aleman, MVZ, PhD, DACVIM (LAIM, Neurology); Patricia Conrad, DVM, PhD, DACVIM; Andrea Packham, MS; Kevin Woolard, DVM, PhD, DACVP; and Nicola Pusterla, DVM, PhD, DACVIM, DAVDC-Equine

When used individually, cerebrospinal fluid indirect fluorescent antibody test (IFAT) antibodies show higher accuracy in assessing the true status of *Sarcocystis neurona* neuroinvasion in horses when compared to serum IFAT alone, and cerebrospinal fluid with serum IFAT testing in combination provides higher accuracy than individual sample IFATs. Authors' address: School of Veterinary Medicine, University of California-Davis, One Shields Avenue, Davis, CA 95616; e-mail: pspandit@ucdavis.edu. *Corresponding and presenting author. © 2022 AAEP.

1. Introduction

This study evaluated a previously validated fluid indirect fluorescent antibody test (IFAT) for the detection of antibodies specific to *S. neurona* in serum and cerebrospinal fluids (CSF) of naturally infected horses. Additionally, the diagnostic performance with the inclusion of phosphorylated neurofilament heavy protein concentrations in serum and CSF was also evaluated.

2. Materials and Methods

The SarcoFluor IFAT test was evaluated for 134 horses across three clinical groups: equine protozoal myeloencephalitis (EPM)-positive horses (EPM+, n = 21), EPM-negative horses (EPM−, $n = 60$) showing neurological signs and confirmed neurological disease (cervical vertebral malformation, neuroaxonal dystrophy, equine degenerative myeloencephalopathy), and EPM-negative horses with no neurological signs and no neurological abnormalities on histology (control, $n = 53$). Positive controls were identified based on histological lesions compatible with *S. neurona* infection and parasites demonstrated in lesions by immune staining on histopathology. Logistic regression was used to compare testing regimens for correctly identifying *S. neurona* infections in horses.

Research Abstract—for more information, contact the corresponding author

NOTES

3. Results and Discussion

When differentiating between EPM+ horses and EPM− horses with other neurological diseases, the combination of serum and CSF SarcoFluor testing added more information to the model accuracy than either test alone. The likelihood ratio of a positive test was highest at serum:CSF ratio of 32. Models involving serum and CSF for phosphorylated neurofilament heavy protein did not identify cutoffs that showed statistically significant likelihood ratios for a positive test and showed lower area under the curve.

Acknowledgments

Funding Sources

This research was funded by the Center for Equine Health, School of Veterinary Medicine, University of California-Davis, with additional contributions from public and private donors.

Declaration of Ethics

The Authors have adhered to the Principles of Veterinary Medical Ethics of the AVMA.

Conflict of Interest

All Authors work for the School of Veterinary Medicine, University of California-Davis, which markets the SarcoFluor for diagnostic purposes.

Intravenous Calcium Administration as Part of a Fluid Resuscitation Protocol: A Randomized, Blinded Clinical Trial

Langdon Fielding, DVM, MBA, DACVECC, DACVSMR*; Dustin Major, DVM, DACVS; Emma Deane, DVM, DACVECC; Jennifer Mayer, DVM, DACVECC; and Gary Magdesian, DVM, DACVIM, DACVECC, DACVCP

Intravenous calcium administration at 0.4 mg/kg/minute for 60 minutes as part of resuscitation fluids will decrease heart rate and diminish improvements in gastrointestinal sounds in exhausted horses. Authors' address: Loomis Basin Equine Medical Center, 2973 Penryn Road, Penryn, CA 95363; e-mail: lfielding@lbemc.com. *Corresponding and presenting author. © 2022 AAEP.

1. Introduction

The addition of calcium to resuscitation fluids is a common practice even though studies evaluating the effects of calcium have been performed primarily in healthy horses. This study tested the hypothesis that intravenous calcium administration will affect heart rate, gastrointestinal sounds, and electrolytes in metabolically unstable endurance horses.

2. Materials and Methods

Sixteen endurance horses eliminated from a 100-mile (161-km) endurance ride that required intravenous fluid therapy were enrolled. Horses were randomly assigned to receive 0.4 mg/kg/minute of calcium (23% calcium gluconate) over approximately 1 hour diluted in 10 L of a non-calcium-containing isotonic crystalloid or 10 L of a non-calcium-containing isotonic crystalloid. Biochemistry profiles were determined on blood samples collected before and after treatment. Physical examinations were performed before and after treatment where gastrointestinal sounds were defined as 0 (absent), 1 (diminished), or 2 (normal). Heart rate was recorded every 15 minutes. Data were compared using 2-way analysis of variance with repeated measures.

3. Results

Calcium administration was associated with lower heart rates 45 minutes after starting the infusion ($p = 0.002$) but less improvement in gastrointestinal sounds compared to controls ($p = 0.030$). An increase in plasma phosphorous concentration ($p = 0.030$) and a decrease in muscle enzyme activity (creatine kinase, aspartate transaminase) were also observed ($p = 0.046$).

4. Discussion

Intravenous calcium supplementation decreases heart rate and diminishes improvement in gastrointestinal sounds.

Research Abstract—for more information, contact the corresponding author

NOTES

Acknowledgments

Funding Source

Financial support was provided by the Western States Trail Foundation.

Declaration of Ethics

The Authors have adhered to the Principles of Veterinary Medical Ethics of the AVMA.

Conflict of Interest

The Authors have no conflicts of interest.

Effect of Time and Autologous Serum Addition on the Analysis of Cerebrospinal Fluid in Horses

Camilla Quattrini, DVM*; Rebeca Scalco, DVM; Pouya Dini, DVM, PhD, DECAR, DACT; Bill Vernau, BSc, BVMS, DVSc, DACVP; and Monica Aleman, MVZ, PhD, DACVIM (LAIM, Neurology)

Cerebrospinal fluid (CSF) collection can be performed in the field, but storage of the sample at 4°C for more than 48 hours might impair correct cytological evaluation. Addition of autologous serum to an aliquot of the sample improves the preservation of cells morphology up to 96 hours post collection. Authors' addresses: University of California, Davis, One Garrod Drive, Davis, CA 95616; e-mail: cquattrini@ucdavis.edu. *Corresponding and presenting author. © 2022 AAEP.

1. Introduction

Cerebrospinal fluid (CSF) is highly labile and delayed processing might alter analysis results. The objective of this study was to determine effects of time and addition of autologous serum on CSF analysis results.

2. Methods

Ten adult horses were used in this prospective study. CSF samples were collected from all immediately after euthanasia. Serum was collected before euthanasia. Samples were divided into 15 aliquots (2 mL each); 1 aliquot was submitted for CSF analysis within 60 minutes of collection. In 7 aliquots, 4 drops of autologous serum (200 μL) were added and stored at 4°C (serum group); the remaining 7 were stored unaltered at 4°C (control group). Total nucleated cell count (TNCC) and cell morphology score were done at T4, T8, T12, T24, T48, T72 and T96 hours post collection. Protein concentration was measured in unaltered aliquots at T0 and T96 hours.

3. Results

Cell morphology scores were significantly different in the control group at T72 and T96 compared to T0 ($P < 0.05$); no change was observed in the serum group.

4. Conclusions and Clinical Importance

Storage of CSF at 4°C for more than 48 hours might result in cellular morphological changes that could alter cytological evaluation. Addition of autologous serum to an aliquot of the sample improves cell morphology preservation up to 96 hours post

Research Abstract—for more information, contact the corresponding author

NOTES

collection. The sample should be immediately divided in 2 aliquots: one plain CSF for proteins-related essays, and the second should contain autologous serum (2 drops per 1 ml of CSF). Plain blood collection tubes or cryovials can be used for storage and shipment.

Acknowledgments

Declaration of Ethics

The Authors have adhered to the Principles of Veterinary Medical Ethics of the AVMA.

Conflict of Interest

The Authors have no conflicts of interest.

How to Respond and Extricate Equines Trapped in Mud Scenarios

Rebecca Husted, PhD

Equines are frequently entrapped in mud situations—in their own paddock, on trail rides, or when they escape their normal pasture. Equines do not actually sink like shown in movies; they "float" on the surface of most mud environments. Literally thousands of images can be pulled up on internet searches of horses entrapped in a variety of scenarios and positions. The purpose of this article is to suggest how to respond to a call that a horse is "stuck in mud" and to provide guidelines and best practices to assist the responding equine veterinarian to function in an efficient, effective, and safe manner to direct equine extrication from a mud entrapment scenario. Modern techniques for manipulation of entrapped horses place emphasis on the use of common tools, flat and looped webbing, occasional specialized equipment, and proper positioning of a team of personnel to achieve effective results for various mud rescue situations encountered in a practitioner's daily work. **Note:** Methodology and procedures for equine field medicine, first aid treatment, and field euthanasia as often required on scene are well covered in other sources and thus will not be addressed in detail here.
Author's address: Technical Large Animal Emergency Rescue, Inc., 1787 GA Highway 18 E, Macon, GA 31217; e-mail: delphiacres@hotmail.com. © 2022 AAEP.

1. Introduction

It is important for the veterinarian and their staff to be able to direct the safe, efficient, and effective extrication of equines from mud entrapment (Fig. 1). Success depends on the veterinarian's ability to interact with other responders while utilizing appropriate equipment and techniques to extricate the animal. Major safety concerns are inherent to mud and water scenarios (hypothermia, crush syndrome, drowning, "vacuum" effect of mud), and well-intentioned responders have been injured or crushed by struggling horses in mud situations[1] and even killed by their own horse in such scenarios.[2] Responders prepare for two scenarios —owners/bystanders that might be involved or injured and an equine patient that is medically stressed, trapped, potentially injured, and unpredictable.

From the Horse's Perspective

Entrapment in mud is very different from what humans perceive it to be. Horses that appear to be lying calmly are actually very stressed and have been struggling to self-rescue, sometimes for hours. Recumbent or trapped horses often lie quietly for a few minutes due to exhaustion, but their instinct is "a down horse is a dead horse"; they will usually struggle intermittently. They do not comprehend that arriving humans are there to assist; instead, they interpret new noises and activity as threats to their survival and may panic and struggle harder. Thus, safe manipulation of horses from mud

NOTES

Fig. 1. Mud entrapment presents significant challenges to responding equine veterinarians including egress/access, personal safety, interactions with other emergency responders, and field conditions for handling and treatment of the horse(s). Left photo—Initial efforts using the saddle as a pulling point was a good strategy for a pilot line, but the leather failed, and that position on the diaphragm causes panic in the horse. Right photo—As more responders arrived with ground pads of plywood, a simple forward assist was employed to pull the exhausted horse to solid ground. Note that the head should be lifted to protect the eye; both the head and the tail should not be used as pulling points. Photo courtesy FAFC, Southard, NJ, January 2022.

entrapment requires knowledge of behavior and anatomy to prevent injury when placing webbing or slings,[2] as well as proper personnel positioning (Table 1).

Successful responses to mud rescue scenarios are intimately tied to a practitioner's expertise and advice. Every entrapment is different, and thus there is no standard operating procedure that can be applied to every situation. However, best practices in equine technical rescue do exist for safer, more efficient approaches to these scenarios. (Note: "Best practices" refers to procedures that produce superior results in particular types of situations and constantly evolve based on knowledge and technology available at the time.) Slides, drags, vertical lifts, and assists are basic to technical large animal emergency rescue—a specialty type of heavy rescue for some fire and rescue emergency response services. Callouts of emergency responders for equine mud entrapment frequently result in a request for a local veterinarian through dispatch at the local 911 center. In this article, it is assumed the veterinarian is responding (Fig. 2) and wants to proceed with an effective plan for extrication.

Example 1: Dr. Erica Koch gets an evening call from 911 dispatch and the horse owner requesting assistance for a mud rescue of a horse trapped for several hours about a half mile (1 km) from the trailhead (December 2020). She deployed to the parking lot and was assisted by fire/rescue personnel to hike to the actual location of the animal (off trail, laterally recumbent in thick, wet mud and chunks of ice, getting dark and below freezing temperatures). After providing treatment in situ, the animal was manually manipulated with webbing out of the mud onto a tarp, and the tarp was dragged to flat ground where the animal stood and walked to the trailhead, where it was loaded into a trailer and delivered to Dr. Koch's clinic for follow-up care (hypothermic and dehydrated).

Example 2: The owner was riding along the Columbia Riverbank, Washington when the horse slipped into the mud (Fig. 3). She called 911 for assistance, and they reached out to a local technical large animal emergency rescue (TLAER) team to respond to the location. Meanwhile, the owner discussed options with the TLAER team leader, who suggested they give the animal room to move and stop pulling on the head. The owner let the horse relax, and it self-extricated a few minutes later before the arrival of deploying first responders.

2. Understanding the Problem

Mud entrapment is fundamentally a small surface area problem. Equines have a much greater weight on a tiny surface area of their hooves and long legs—like a large drum walking on toothpicks. Thus, they easily flounder into unstable ground where a human can stand (Fig. 4).

Based on the fluid physics, the less an animal moves, the easier it is to extricate as struggling causes a dewatering "vacuum effect," creating suction around the extremities as the particles of sand and soil pack around them. Since horses do not understand "Stop struggling!" like humans would be ordered to do, distraction with hay or grass may be attempted. As they become more exhausted and depressed, horses stop struggling, and their medical condition deteriorates as hypothermia and crush syndrome become more likely.

Equines do not sink like shown in movies—they actually "float" on the surface of most mud environments due to their large lungs and gaseous intestinal production. Upon arrival to the scene, they will tend to have their head and neck and 6 to 12 inches of topline and hindquarters out of the mud, with their nostrils flaring due to desperate efforts to escape (Fig. 5).

Pressure applied to the chest and abdomen of a horse (especially by mud, also by webbing or slings) causes a physiological response (squeeze or sulk) that minimizes effort to struggle, resulting in diminished efforts by the animal to get up, especially if excitement is managed well by the animal handler. This physical "sedative effect" has been utilized by farriers, veterinarians, and horsemen throughout history to cause horses to become quiescent for various procedures. However, it is dangerous to personnel when the pressure is relieved; the horse may give an explosive effort or reactions—be ready to step back.

Table 1. Best Practices for Mud Extraction

- Assess the situation, call for resources, make a good plan, bring needed resources and personnel to the scene, and prepare for the extrication. Communicate with various groups and develop a coordinated effort that incorporates safety for the horse and humans. When performed in the dark, the rain, or on steep hazardous terrain, the rescue is that much more challenging.
- Get scene lighting by fire/rescue early; they can provide medical rehabilitation, first aid, and heating and cooling resources for both people and animals.
- Helmets should be worn when working with recumbent animals, especially by the animal handler.
- Animal handler should have a lead rope and halter available to catch and control the horse (or use an emergency rope halter). Control of the head is crucial so that the extricated animal does not get loose after extrication. Opposition reflex will occur if the head or legs are pulled upon, with counter-productive results. Slapping or stimulating a downed horse or pulling on the head (opposition reflex) is not helpful.
- Note that no one needs to pet the horse or get into the mud. Well-intentioned owners and responders may get into the mud to assist the animal; encourage them to stay out of the dangerous zone (near head, neck, and limbs) where a floundering horse can crush or drown a human. Do not allow people to wade into the mud; they should be working from on top of the mud (using ground pads of plywood or similar methods for spreading human weight on top of the mud.)
- Allow the animal to self-rescue where possible; first, remove obstacles such as trees or debris, but leave the legs, head, and neck free to move so that the animal can balance itself and make active efforts to extricate itself.
- Plywood or other slick substrates are not recommended to be placed in front of the horse; horses physically cannot perform the maneuver of lifting their front ends and then pulling themselves forward, or they slip off it.
- Do not attach slings or webbing to the head, neck, tail, or legs to pull. Be cautious and remind others to stay out of the kill zone near the legs. The abdomen and chest are better anchor points for webbing or slings for manipulations and drags out of the mud.
- Do not use the tail as an attachment point for any mechanical manipulations and do not tie it to anything—only careful manual shifting of the recumbent horse by no more than 2 people. The tail can be broken, seriously injured, or traumatically amputated by application of excessive force.
- Use blindfolds while horses are recumbent to protect the downside eye and relax the animal. Ensure it is easily removable or fastened so that it will fall off on its own if the person handling the animal loses control. Protect the downside eye (e.g., Häst Becker head protector,[a] personal flotation device from the fire truck, or similar equipment). Horses use their head and neck as a lever to rise and when struggling may cause serious injury to an unprotected eye.
- Sedation and/or anesthesia should be carefully evaluated by the practitioner based on the animal's medical status, time in situ, and potential for injury to a person or itself.
- Use wide, flat webbing with looped ends or continuous loops (instead of ropes) for any type of manipulation; the greater surface area provided by webbing/continuous loops minimizes injury to the skin. Use soft padding to protect soft tissue structures. Animals can be rolled laterally onto the ground pads, rescue glide sled, or a tarp for sliding to solid ground.
- Assists and drags/slides employed by the responder are most effective. Use the pectoral and pelvic girdles as attachment points for webbing used in manipulations. The muscle and bone structures here will protect the delicate soft structures (nerve, blood vessels, organs, tendons, and ligaments) beneath.
- Always treat dead and live animals with respectful and professional methods; anyone could be watching or taking video. Social media is ever present.

If responders find the animal(s) trapped much deeper—where the withers and hip are covered with mud—check if the mud is under the surface of water, which may indicate that people have started digging by hand or with mechanical equipment, effectively burying the animal as the mud slows and fills into the holes they attempted to dig. Digging is not recommended except in a few cases of very dry soil or to move obstacles blocking the path of extrication. Take control and tell responders to stop digging by hand or with machinery while a plan is made (Fig. 6) to get webbing around the abdomen and chest of the equine for a forward assist, sideways slide, or vertical lift manipulation. Simultaneously, a path should be created for extrication.

When manipulated out of entrapment onto flat ground and then allowed into sternal recumbency, most horses will rise and stand on their own when they are ready. Thus, facilitating self-rescue with assists or drags/slides is a best practice that prevents the practitioner from having to use more complicated slings and vertical lifts (except when animals are below ground such as in a well or hole in mud). Horses in some scenarios may have special medical concerns such as severe injuries, stress, shock, hyper or hypothermia, dehydration, crush syndrome, and/or exhaustion and may require intensive medical intervention.

Time course of the rescue is often very long measured from when the animal went into the mud; techniques and tools that make responses more efficient are preferred. By the time it is recognized by the owner or other people, 911 services are called out, they call the veterinarian, and upon arrival, several hours usually have passed, and the animal is medically becoming more delicate by the moment. Practitioners should involve 911 personnel from the very beginning (mud in a paddock, trail ride emergency, septic tank, deep well, out on the mudflats, etc.) because it speeds up the overall efficiency of the response.[3] Fire/rescue departments have the techniques and expertise to stabilize the situation and provide safety and security to all the responders; after all, they do extrications of people from unusual situations as a matter of course. Very few owners have the equipment, training, and expertise to

Fig. 2. A horse trapped in mud and ice off trail—picture taken right before dark. Owner called 911 and her veterinarian—this photo is taken before responders arrived. Photo courtesy Keaghan Pike with Wakefield Fire Rescue and Dr. Erica Koch.

attempt equine extrications safely on their own—it takes teamwork to achieve safety and efficiency for all on scene. Hypothermia is common and is dependent on how stressed the animal is, environmental conditions, body size of the animal, presence of flowing water, etc. Prevention and aggressive treatment should be initiated immediately to minimize the effects. Accidental hypothermia after extrication can be prevented by correct core rewarming strategies to prevent the "after drop" effect of cooling on the heart and core.[4]

Responders in mud field environments must consider many variables: safety (for the human responders and the animal), resources (people, equipment, tools, logistics), environment (precipitation, cold, heat, humidity), medical (stability of the patient, arrival time of treatment), and unusual situational concerns such as accessibility, structural integrity, or hazards (e.g., Is the horse partially hanging from a bridge, trapped in mud under a large dead tree, or "down" in mud at the bottom of a well? Is the "mud" actually a septic tank? What other hazards are involved?)

In the past, human emergency responders extricated animals without veterinary assistance, and minimal attention to the health status of the horse was paid. Why? The common assumption was that horses were big and strong, but several hours to days after seemingly "successful" rescues, untreated equine victims often died "unexpectedly". Today, responders are taught that horses are medically fragile and need veterinary attention immediately. They utilize the "golden hours" concept to track the steadily deteriorating medical condition (Fig. 7) of affected equine victims.[5] The fundamental challenge on any large animal mud rescue scene is to balance the need to extricate and transport with safety for all personnel while providing medical care to the patient.

It is known that winch cables and ropes around the neck or attached to the tail, legs, or head are dangerous to the animal and should never be used. These poor "rescue" methods used in the past reflect human instincts to solve a problem but often caused iatrogenic injury in the equine victim (traumatic amputations [Figs. 8 and 9] lacerations, asphyxiation, corneal damage, myopathy, neurologic injury, etc.).[b-d] Modern large animal mud rescue techniques and training are based on research and development into these scenarios and are more efficient, safer for both responders and the equine victim, and prevent iatrogenic injuries.

The unusual places and orientations (Table 2) that animals commonly are found require appropriate personal protective equipment such as helmets and may require specialty tools (mud lance[e] for injection of air or water into the mud to break the suction, Nicopolous needle[f] for guided placement of a pilot line, and webbing around the body of the animal). Strategies and equipment to mitigate these situations are available. Team training using mannequins is an excellent way to practice these techniques and utilize this specialized but easily locally made equipment (Fig. 10).

Fig. 3. A healthy horse was accidentally ridden into this muddy area. Left—Photo transmitted via text to the Mustangs to the Rescue TLAER rescue team to understand the situation and evaluate equipment to deploy to this location. Right—Owner and friend used field expedient methods to cut reeds and grass from the riverbank to put under the horse's head and neck to protect the eye, letting the horse relax and not pulling on the head. Soon after this photo was taken, the horse was able to self-extricate by pushing itself out of the mudhole and was led back to the trailhead. Photo courtesy owner via Mustangs to the Rescue TLAER team, Bend, OR.

Fig. 4. Example view of the surface area problem for horses getting into unstable ground (mud). A 1000-lb (450-kg) horse with a large hoof (#2 shoe size) would be walking on a much smaller surface area than a 200-lb (90-kg) person with a man's size 12 US boot, making it much easier to get stuck in the mud. Photos courtesy Farrier Stephen Marshall.

Fig. 5. Upon arrival to the well-lit mud rescue scene in the woods, Dr. Koch planned with the owner and fire rescue personnel present to use webbing to manipulate the horse out of the mud laterally onto a tarp and then worked as a team to drag the tarp to solid ground and allowed the horse to stand there. Later, it was walked into a trailer for transport to a clinic for follow-up. Photo courtesy Wakefield Fire Rescue and Dr. Erica Koch.

Fig. 6. One team is encircling webbing around the horse's abdomen and chest to create a harness for sideways drag/slide with a rope mechanical advantage system to get the animal onto a tarp, while another team is making a safe egress path by cutting trees and pulling debris out of the way to pull the tarp to solid ground. Note excellent scene lighting and use of personal protective equipment by most responders. Photo courtesy Wakefield Fire Rescue and Dr. Erica Koch.

3. Materials and Methods

Recommended Equipment for Field Rescues

Basic equipment and tools will facilitate extrication of horses trapped in mud scenarios. Mud entrapment is a common emergency response for practitioners; it makes sense to be prepared.

Personal Kit

- Gloves (high dexterity)
- Boots (with or without steel toe)
- Protective headwear (helmet with chinstrap; Occupational Safety and Health Administration approved)
- Protective goggles or glasses (especially when using air injection)
- Knife and/or multitool
- Ear protection

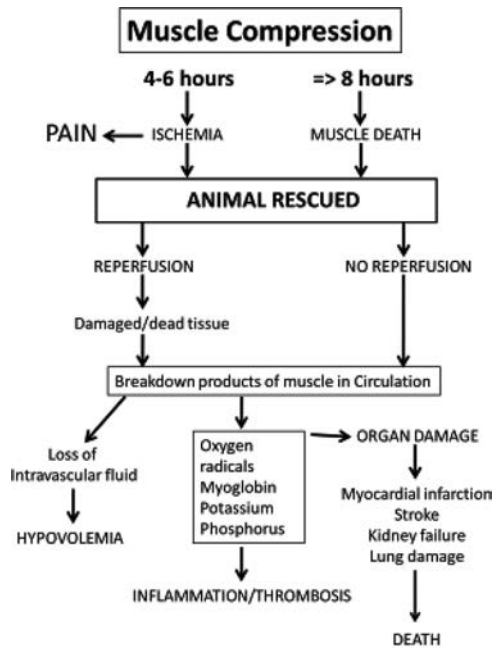

Fig. 7. The processes ongoing within an equine trapped in mud scenarios, if not addressed in a timely manner, can contribute to organ failure and death. With permission from Gimenez T. The golden hours of equine emergency rescue. *Equine Vet* 2012;2:26–29.

- Professional shirt/jacket or scrubs with your logo to identify yourself; reflective and bright colors are helpful when near traffic

Mud Rescue Response Kit

- Cell phone to call 911 for scene safety and assistance from fire rescue department
- A good first aid kit for both equines and humans
- Flashlight or portable lighting
- Mechanical advantage rope kit, carabiners, etc.
- Harness for human
- A battery-powered reciprocating saw capable of cutting metal or wood that may entrap extremities
- Pool noodles—used to put under the "chin" of a horse trapped in mud and water at risk of drowning and allows the horse to relax the head on something with buoyancy and not have to fight to keep its nostrils above water
- An extensible cane/pole to manipulate webbing or induce sedation (via pole syringe) without having to get too close or in the mud; an aluminum boat hook or painter's pole extendable to 4 m or pike pole off the fire truck works well
- Good-quality hay to allow trapped or extricated horses to eat and relax while waiting for extrication or while in transport after extrication to definitive veterinary care
- Emergency rope halters to catch loose horses (there may be others around the trapped horse)
- Insulated horse blanket (heavy duty)

Fig. 8. This horse was attempted to be removed from a mud scenario by using its tail as an anchor point with mechanical means. Traumatic amputation of the tail has occurred. Anecdotally, the animal was provided treatment and survived a few weeks but was eventually euthanized. Photo courtesy Allan Schwartz (New Zealand, circa 1999).

- Nicopolous needle (large-diameter 6-foot [2-m] metal conduit that looks like a surgical C-shaped needle, shaped to fit around the chest or abdomen, used to "thread" a pilot line under the entrapped animal in the mud and may be outfitted with capability to push air or water pressure through it)
- Mud lance/jetting wand/air knife (long PVC or metal hollow poles outfitted to inject low-pressure air or water into the mud deep below the entrapped horse around the extremities; airline can be taped to the length of a broom handle to fashion a field expedient by the fire fighters, with a self-contained breathing apparatus bottle and a regulator; Fig. 11)
- Several 8-cm-wide webbings 7 to 10 m long with sewn loops at each end (or tow strap, or 12-foot continuous loop round slings around the chest and abdomen to manipulate and maneuver the animal into a safer position, using a forward assist, sideways drag/slide, or vertical lift method; Table 3). The head, neck and tail are never safe anchor points with which to drag an animal out of anything—they can be severely injured or traumatically amputated.
- Large rescue glide[h] or 4Hooves large animal rescue sked system[i]
- Towel or blanket to cover the head to calm the animal, Häst Becker head protector or similar whole-head protection (or human life vest, towel, sweatshirt, etc.) to protect the downside eye
- Heavy-duty tarps (various uses for staging, ground pad, drags, protection)

Frequency of Mud Rescue Entrapment and Similar Situations

Currently, there is minimal scientifically maintained or reported data or system available for tracking the

Fig. 9. A previously deceased horse was lifted by tractor within minutes of confirmation of death to demonstrate what can happen. Traumatic separation of the tail is obvious—the skin above the anus tore, as did the muscles, and bony column has separated at the level of the joint at the base of the tail (left). Dissection of this traumatic separation of muscles, nerves, and bone/joint in the tail of this euthanized horse (right). Do not use the tail as an anchor point for pulling an animal out of mud. Photos courtesy Dr. Rebecca Husted.

Table 2. Types of Recumbency Common in Mud Scenarios

Lateral: Common position (on its side) in many technical rescue mud scenarios.
Posterior: Animals that fall into holes, ditches, or other obstacles where the rump is well below the rest of their body; mud may be deep or shallow.
Dorsal: Befalls horses that slip, fall, or are thrust into a tight space and end up on their backs with their hooves pointed upward; this might be a riverbank, ditch, hole, or creek. Patency of the airway is a big concern here.
Sternal: Horse is laying on its ventral surface with legs either trapped in a downward position (various) or folded and resting upon them.
The sheer weight of the animal contributes over time to compartment/crush syndromes, myopathies, or neuropathies—victim should be attended to quickly—within 4 hours of being recumbent for best opportunity at full recovery.

Once extricated to flat ground, sternal is a preferred position for completed technical rescue scenarios at the final hand off to the veterinarian; this is the "recovery position" for downed equines. Given appropriate time and treatment, most horses will rise on their own.

number of horse mud rescue entrapments. A literature search reveals very little information about frequency, extrication methods, or treatment of injuries involved in mud rescue of equines. This is a gap in knowledge and, and it represents a rich opportunity both for research and statistical analysis.

Thus, knowledge in response to mud extrication—or suggestions for better prevention and response—come from the author's extensive collection of journalistic and anecdotal reports, unpublished data from colleagues, hundreds of full-scale mud rescue training events with mannequins placed into scenarios duplicating past situations, professional firefighters sharing their career knowledge, actual owner accounts, social media postings/photos, and personal reports from veterinarians/technicians/nurses that have responded to these scenarios.

Worst-Case Scenarios

Eighteen horses trapped in mud in southern China in April 2020 recently were highlighted on YouTube—the firefighter's desperate attempts to assist the horses over 3 hours demonstrate the challenges with attempting to extricate exhausted equids in these situations (Fig. 17; https://www.scmp.com/video/china/3079174/firefighters-rescue-18-horses-trapped-deadly-mud-northern-china).

In another difficult mud rescue scenario in the United States, five horses ended up trapped in a muddy area of a pasture near Indianapolis, Indiana, and they were attended by the large animal rescue team from Morgantown, Indiana. They quickly contacted a veterinarian and worked as a team using forward assists and sideways drags to remove all the horses in less than 2 hours from when these horses went into the mud. They were fortunate that the weather cooperated and that the horses were found in daylight (Fig. 18).

Factors to Consider Before Responding

- Time: Responding may cause the practitioner to miss their normal calls for part of the day. Will 911 dispatch provide a police escort to the scene? How far is it to the scene?
- Environmental conditions: Is it raining, cold, or dark?

Fig. 10. Mud rescue best practices are learned using a realistic Requip™ training mannequin.[g] Here, firefighters in safety harnesses and personal protective equipment are approaching the animal on top of ground pads. Using reach tools and a Nicopolous needle with injected low-pressure air to force the mud aside and allow them to emplace a pilot line, they will then floss the webbing under the chest and abdomen. The veterinarian and animal handler are standing at the head of the animal where they can observe behavior. The horse has on a head protector (in this case, a human personal flotation device from a local fire truck) and pool noodles under the chin to keep the nostrils out of the mud. A sideways drag/slide manipulation onto the ground pads will be performed to get the animal out of the situation. Photo courtesy Little Fork Volunteer Fire Rescue, Rixeyville, VA.

- Payment and liability: Will the veterinarian get paid for their services/medications? Emergency response services do not charge for extrications. For the practitioner, these are difficult questions. Check with the state veterinarian's office for legal advice on liability and requesting payment, even just to cover costs. Practitioners cannot afford to respond to many of these scenarios if required to donate time, effort, drugs, and expertise.
- Training: Incident command system (ICS) protocols (utilized by all 911 professional emergency response services) and rescue procedures are crucial for safety. Emergency rescue requires training to handle the wide variety of mud scenarios encountered.
- Equipment: The basic load of equipment needed by the practitioner will include field medical equipment, lengths of webbing for manipulations, and various tools. Responding 911 services rarely have specialty types of large animal rescue equipment (mud lance, rescue glide, Nicopolous needle, etc.). However, a variety of useful extrication equipment used for a variety of rescue situations will be brought to the scene by fire/rescue services, as well as plenty of manual help.



Fig. 11. A horse trapped in a muddy part of its own pasture for several hours. First, the responding large animal rescue team emplaced 2 webbing straps for sideways drag/slide in the simple configuration, using the Nicopolous needle to get around the chest and abdomen down in the mud. Now they are utilizing mud lances to inject low-pressure air down to the mud around the hooves—over 5 feet down. Once they break the suction effect, simultaneously, the sideways drag manipulation is used to get the animal onto its side with the legs out of the mud and to flat ground. Photo courtesy Large Animal Rescue Team, KY.

Risk Assessment/Animal Evaluation

It is important to perform a risk assessment and not jump into the mud next to the horse. Both the veterinarian and the incident commander should work together to decide at what point the horse(s) can be approached safely for evaluation. A good risk assessment should evaluate the "risk versus benefit" of various strategies for extrication of the horse(s) and should involve the veterinarian's opinion (e.g., If the animal is not savable, why risk anyone's life to extricate it and why make it suffer? The owner should be coached on the necessity for humane euthanasia). No one should get close to horses in mud until there is safe access/egress established (mud or ground pads, plywood, or other flat accessibility equipment). If much of the body is under the mud, a full physical exam is impossible, but a basic assessment should include the following:

- Primary triage
- Initial first aid and early treatment
- Extrication and follow-up treatment
- Secondary triage
- Transport to definitive care location for further treatment and observation

Veterinarians should consider wearing a minimum level of personal protective equipment (gloves, coveralls, helmet) and a harness if below-grade rescues (wells, ditches, etc.) are to be performed.

Concerns with Sedation or Anesthesia Use in Mud Scenarios

Coordination between the veterinarian and the response team increases the efficiency of veterinary

Table 3. Basic Manipulations for Mud Rescue

FORWARD ASSIST – Allows the legs and head to be free so that the horse can use their own muscular effort to self-rescue by moving forward, usually to solid ground. Minimize entanglement and clear obstacles and egress routes so that when the animal begins to move, it can (Fig. 12). There are three configurations of this method.

1. SIMPLE/BASIC – This configuration of the forward assist is the simplest to attach and remove and easiest to learn; however, it is also most subject to slipping and is not appropriate for vertical lift from posterior recumbency (out of manholes, etc. where only the forequarters and head are within reach.) A 10-m piece of webbing is laid over the animal's withers at the halfway point, and then each end of the webbing is wrapped under the chest at the sternum and pulled anteriorly between the legs and attached with a carabiner to a long rope for manual pulling.
2. CINCH/LARKSFOOT – This configuration literally cinches around the animal's chest, minimizing the chance of webbing slippage. It is commonly used to tie an animal off in its current position (on a bridge for example) so that it cannot fall further into trouble. One 10-m piece of webbing with loops at each end is wrapped around the animals' chest at the withers, and then one end of the webbing is fed through the loop at the other end, fed anteriorly between the front legs, and attached with a carabiner to a long rope for manual pulling.
3. WIDENER/SWISS SEAT FORWARD ASSIST – This configuration cinches around the animal's entire forequarters and pectoral girdle, minimizing slippage while effectively doubling the surface area of the webbing on the animal's skin, therefore reducing the chance of injury from pressure used to pull the animal out of entrapment. While slightly more difficult to envelope around the animal in the mud, and taking more time to remove, it does not come off the animal if properly placed (Fig. 13).

   One 10-m piece of webbing is held at the animal's chest below the thoracic inlet at the halfway point, and then each end of the webbing is wrapped over the withers, around each side of the animal, down under the chest at the sternum (through the mud with a pilot line initially), pulled anteriorly between the front legs, and fed up through the existing webbing at the thoracic inlet; then, both looped ends are attached with a carabiner to a long rope for manual pulling. For horses trapped in mud in posterior recumbency (but below ground in wells, manholes, etc.), the loop of webbing may be attached to an overhead lifting point to perform a vertical lift using a crane.

BACKWARD DRAG/SLIDE – This drag method is useful when access from the front or sides of the animal in the mud is not possible or practical. This is similar to the simple forward assist, but the webbing is threaded over the hips and between the back legs; then, both looped ends are attached with a carabiner to a long rope for manual pulling (Fig. 14).

SIDEWAYS DRAG/SLIDE – This drag method is useful for providing numerous manual pulling points and minimizing the animal's instinct to struggle while moving the animal up a bank or to the side on flat muddy ground.

There are two configurations of this method: SIMPLE/BASIC and HAMPSHIRE SLIP. Both require 2 pieces of 5-m-long, 10-cm-wide webbing (10-m length for draft horses.) It is preferred that the head be controlled by the animal handler to reduce possible injury to the eye or facial paralysis. The weight of the animals' body is used to the advantage of the rescuers to keep it recumbent while increasing the surface area of the animal in contact with the unstable ground surface (mud, etc.) while being moved to safe ground.

1. SIMPLE/BASIC (Fig. 15) – This configuration can be used to pull the animal sideways along the ground, on top of the surface of mud, up a bank in a modified low-angle vertical lift, or to roll and maneuver the animal into a different position. Two pieces of 3-m webbing are separately flossed under the animal into position (front position) around the abdomen directly behind the front legs and (back position) around the abdomen directly in front of the back legs.
2. HAMPSHIRE SLIP – This configuration can be used to pull the animal sideways without causing it to roll or struggle out of position. This method has been used in serious mud entrapment scenarios in the United Kingdom to move a floundering horse in quicksand over 200 m to safe solid ground. Two pieces of 3-m webbing are separately flossed under the animal into position (front position) around the abdomen directly behind the front legs, and then the top portion of the strap is fed between the front legs, under the neck of the animal, back to the rescuers at the dorsal aspect of the animal, around the abdomen directly in front of the back legs then fed between the back legs (back position), and under the tail and back to the rescuers at the dorsal aspect of the animal.

VERTICAL LIFT – This is the least preferred option because it usually involves heavy equipment, greater coordination, and expense. Sedation is normally required, with close coordination between the operator of the equipment, animal handler, and attending veterinarian. Vertical lifting has been well covered in the veterinary literature for a large variety of slinging equipment and methods of horses—most commonly used by emergency responders and veterinarians in technical rescue scenarios is the simple vertical lift web sling (Fig. 16; commercial versions available include the Häst Becker sling[j] and the Loops system[k]).

A major concern with implementing vertical lift slings is that personnel must be trained in their use to maximize safety when working around a trapped, frightened animal to prevent injuries. Initial sedation or light anesthesia of the animal is essential for placement in a sling to prevent it from struggling and injuring itself or rescuers.

Vertical lift sling systems may visually appear to place significant pressure on the abdominal area of the animal; however, abdominal, thoracic, and pulmonary perfusions have not been observed to be significantly impaired in rescued animals lifted in this manner for 2 to 12 minutes (>20-minute lifts in training scenarios with demonstration animals over 300+ training evolutions, over 200 reported rescue efforts.) Pregnant mares have been successfully lifted using this technique.[6] Contact pressure is minimized when using wider straps for the lift because they increase the surface area of the contact points on the animal. When used in conjunction with appropriate lifting equipment, simple vertical lift slings can provide a suitable and affordable means of short-term vertical lift of large animals.

medical treatment on scene and facilitates extrication. If forced to anesthetize a horse in water or a muddy environment, ensure the nostrils do not go into the water as the horse goes unconscious as the head and neck are very heavy. Have a plan for support and buoyancy. Remember that certain drugs can impact maintenance of physiologic thermal balance and hypothermia (Fig. 19).

Fig. 12. Left photo—A realistic Requip™ mannequin is used to demonstrate the forward assist simple configuration placement of looped end webbing while the animal's hind end is trapped in mud. Right—Mannequin in mud is haltered, head protected, and given buoyancy (pool noodles under the chin or head are effective), while another team prepares the employ of a Nicopolous needle to place a pilot line and then webbing in a simple configuration around the animal's body. Photo courtesy Dr. Rebecca Husted.

Fig. 13. A Widener/Swiss seat configuration of the forward assist using webbing is utilized to pull this mare trapped in mud and reeds next to the Deschutes River (water temperature 55 °F) in August 2020. The operations person in the left photo is directing the haul by 12 personnel to assist the horse forward. In the right photo, the horse is standing immediately after extrication and is being evaluated by Dr. Cassee Terry. It has on a Häst Becker head protector.[a] Photos courtesy Mustangs to the Rescue TLAER team, Bend, OR.

Special Concerns Special to Technical Extrication in Mud Scenarios

Older animals, animals possibly enduring a laminitis episode, or similarly sensitive animals should be evaluated for preexisting conditions for which the animal was "self-medicating" by stepping into the cool mud willingly and then becoming unable to extricate itself.

Even when a trained large animal rescue team effects an efficient rescue and an on-scene veterinarian treats the animal immediately, the animal can still die.[7] Failing to treat equines for crush syndrome and accidental hypothermia in cold or wet situations immediately after the extrication is a common cause of death. Recumbent animals entrapped in mud scenarios are subject to abnormal orientation, shock,

Fig. 14. A 2500-lb, 20-hand-tall Belgian horse laid down in the unstable ground that was the previous grave of a buddy horse and became trapped. Here, rescuers are using a backward drag manipulation method with webbing and rescue glide/sked[g,h] tucked under the horse to minimize injury. Here, a small tractor was used to pull this huge horse—use of mechanical equipment must be carefully coordinated with the operator and signaler. Photo courtesy Tori and Justin McLeod, 4Hooves Equine Services, NC.

Fig. 15. A horse is accidentally ridden off the trail and trapped in a wooded area in mud for several hours, December 2020. Firefighters used a sideways drag/slide manipulation (note that webbing is much preferred to rope), used in this instance to pull the horse laterally onto plywood, and then allowed it to stand on solid ground. Several personnel are standing in a dangerous place where the legs could injure them—remind responders to stay on the dorsal side of the horse away from the legs. Photo courtesy Patterson Fire Rescue, NY.

hypothermia, and ischemia with subsequent hyperemia and reperfusion injuries. Crush injury in equines that have been recumbent for long periods or impinged by weight of other animals or objects in mud entrapment can cause latent injuries that might not be recognized on scene. These factors over a prolonged period (>4–6 hours) have been shown to cause localized and distant organ injury or death in the horse, as well as muscle death and ongoing injury after 6 to 7 hours, especially in sedated and anesthetized horses. The mud response scenario with very high reperfusion injury and mortality rate is any entrapment for over 12 hours; 24 hours or more has an extremely poor prognosis. Horses are capable of surviving mud entrapment with aggressive warmed fluid therapy and immediate thermal support. Animals in shock, with severe injuries, with poor body condition, or that are geriatric should be triaged efficiently.

(Note: These factors must be considered to provide appropriate and timely prophylactic treatment to the animal—treatment methods are well covered elsewhere in the literature.)

4. Discussion

Incident Command Response Framework

The practitioner is just one member of a large group of emergency responders responding under a common protocol known as the ICS. The basic principles of ICS are fully applicable to mud rescue:

- Planning: An action plan must be developed.
- Team approach: Every responder is part of a team and knows their job.
- One coordinator: The incident commander coordinates the response; they are the leader and shoulder the responsibility for the entire scene.
- Safety: Safety is priority, for both the animal victim and all human rescuers.
- No freelancing: Individuals responding/acting on their own constitute a risk and a liability to others. The incident commander has the authority to remove them from the scene.

When the Call Comes to the Office

The caller may be a 911 dispatcher, client, or unknown horse owner or bystander. If the caller is a 911 dispatcher, ask them to send the fire/rescue department and law enforcement to the scene for life safety. If the owner is calling you, ask them to also call 911 for assistance and life safety prevention.

Preliminary Information to Obtain During the Call

- Name and contact information of caller
- Exact location and clear directions to the scene or closest access
- Number of horses involved
- Brief description of the situation—advise caller to text photos if possible

- Photos or short videos of the scene should be requested; they allow you to develop plans and coordination while responding

Fig. 16. A draft horse trapped in a muddy hole in pasture (left photo) at least 6 hours before discovery by owners. A simple web sling with vertical lift was used to extricate the horse with a large excavator and then used to support the exhausted animal until it could stand. The veterinarian on scene provided immediate treatment—rectal temperature was 96.3 °F upon extrication and the animal survived. Photo courtesy Samantha Ellis.

Fig. 17. A variety of methods were used in this scenario; however, not all were the best way to extricate the horses. Forward assist (putting the webbing around the chest as they did here) is an excellent way to do this, but responders must realize that although humans are able to walk on the crusty surface of the mud, horses weigh more and break through more easily. Yelling or whistling does not motivate horses; instead, efforts should focus on commands used to coordinate the extrication. Photo courtesy screenshot from video, South China News Channel.

The Role and Responsibilities of the Practitioner

Different from clinical and field practice, there are many dangers in field environments where the veterinarian is not the "authority having jurisdiction" over the scene (the authority having jurisdiction will be the fire department or police officer that arrived first), and the practitioner is expected to fit into the working model of ICS on scene. The incident commander is ethically and legally responsible for the safety and lives of all personnel and the victim on their scene. The incident commander will assist the animal(s) when the scene is stable, people have been taken care of, and it is safe to do so.

The veterinarian or their technician/nurse should direct medical stabilization and handling but should not pull on assist/extrication devices or perform the actual extrication—let the professional emergency responders do their job. By taking a management and advisory role, and a less hands-on approach for the extrication, the practitioner can plan and prepare for treatment and transport options, advise the IC and the owner, and prevent injury to themselves by staying out of the danger zone.

Interaction with the Owner/Bystanders

Allowing horse owners or bystanders to take charge of an extrication attempt is dangerous and unsafe to everyone else on scene. The owner is important as a source of information and for authorization of the horse's treatment, transport to definitive treatment area, or decisions on sedation and euthanasia. If possible, keep owners out of the way of the rescue efforts—many animal owners will be emotional, while veterinarians have training to remain calm, make rational decisions, and handle the situation professionally. Close coordination with the owner can ensure better outcomes based on diagnosis and early treatment options, or at the least in euthanasia being selected for induction at a rational point.

Make the Assessment

Upon arrival to the scene, the veterinarian should meet the incident commander, look at the entire scenario, and come up with an incident plan. The scene needs to be stabilized and people extricated before the animal(s) are extricated. Horses can perceive and may react to everything going on (voices, tools, vehicles, footsteps, extrication equipment), which is another reason for a good plan and efficient extrication strategy before getting too close. Approach slowly while talking to the horse(s), evaluating their stress and orientation—ask fire/rescue personnel to provide lighting for everyone's safety. Are animal(s) dead or alive?

Fig. 18. Left photo: There are 5 horses in this mud scenario and 3 miniature horses standing with their trapped friends. Right photo: Using sideways drag with webbing to extricate each horse. Photo courtesy Brandon Shireman, Morgantown TLAER team, Indiana.

Fig. 19. This horse was found by the owner; 911 dispatch sent a specialist large animal rescue team and a veterinarian to the scene. Pool noodles are used to keep the nostrils out of the muddy water, and painted plywood ground pads are used to safely work around the animal for sling emplacement. The horse was extricated successfully using the Becker sling for a vertical lift and returned to the owner's property but was hypothermic (2 °F below normal rectal temperature) and died the next morning in its stall, probably due to accidental hypothermia. Photo courtesy City of Milton Georgia TLAER team.

Fig. 20. Triage of multiple entrapped equines (here, a mule and a horse) should be efficient and possibly visual only at first. Conduct a cursory inspection of all animals that you can safely reach, and then attempt to assist animals that are easiest to extricate first, especially those with cooperative dispositions or in the best position for efficient rescue. Provide treatment in situ to those waiting. Here, the responder in the mud should be on a board instead. The mule was deemed easier to extricate in the first attempt, although the horse was more amenable to the process. Both were eventually extricated and provided treatment. Photo courtesy Marion County Fire Rescue, TN.

Obvious injuries? Haltered? What obstacles exist? Can you assist the horse to extricate itself?

Ask yourself questions based on the scenario: How much equipment do you need, and how far is it to bring to the scene? Difficult scenarios will require tree- or metal-cutting equipment to access the animal(s) or to provide a clear egress path for extrication—firefighters know how to do that.

Animal Handler

If possible, assign personnel with advanced horse handling expertise or an equine technician/nurse. Most police and fire officers do not have experience with horses, and animal-handling skills for emergency situations are a specialty skill set. Lack of training may cause them to underestimate the extreme weight, strength, and reflexive speed of a trapped or injured horse.

The handler at the head of the animal (if it is a safe place to be) is in the best position to advise about the medical status, potential behavior or reactions of the animal, approach techniques, and body positioning. The importance of safe positions around the horse should be emphasized by the handler to operational personnel who may forget as they work around the horse.

Triage When Multiple Horses Are Involved

Triage is common for veterinarians involved in response to mud entrapment as more than one animal can get trapped in the same situation (Fig. 20). The

level of triage applied to the scene will vary with the amount of personnel available, equipment and supplies, and the efficiency of the extrication. Primary triage should be conducted in an efficient manner and perhaps visually only, and secondary triage may be conducted at the clinic or an off-site field hospital. Conduct a cursory inspection of all animals that you can safely reach; then, salvage animals first that are easiest to extricate, have cooperative dispositions, and present the least threatening injuries. Severely injured horses must be evaluated for euthanasia; for animals that have a more reasonable chance of survival, support in situ or extricate and evaluate. Documentation of injuries with pictures or video of animals before euthanasia is wise practice. Expectant animals (ones that have the poorest prognosis) should be euthanized efficiently to prevent suffering, based on resources and personnel.

Field Euthanasia

Before providing medical attention or euthanasia to horse(s), consult with the owner/agent about possible treatment/cost and prognosis. Exhausted, stressed, hypothermic, and dehydrated animals often stay recumbent for a long time after being extricated from mud; this is not always an indicator of a poor prognosis, and sternal recumbency is recommended. Some owners refuse veterinary attention to horses even in cases where the prognosis is good or fail to authorize euthanasia. Check local and state regulations that affect these decisions about animal welfare and ownership.

The practitioner must be prepared to perform field euthanasia for animals trapped over 24 hours, in shock, or severely injured where venous access is impossible—the veterinarian will need to direct the performance of euthanasia with a firearm by a police officer with guidance as to landmarks,[5,8] proper bullet placement, and angle of introduction. The person performing euthanasia should be willing to follow the veterinarian's instructions to ensure proper landmarks for placement of the projectile. In the absence of projectile weapons, field euthanasia may include intrathecal injection of lidocaine into the atlanto-occipital space in sedated animals or exsanguination (jugular vein or posterior vena cava per rectum) in unconscious animals.

Proactive Involvement and Training

Practitioners can contact their 911 call center dispatch and ask if there is a local, regional, or state team or fire department/rescue squad with training in methods and procedures to safely perform equine mud rescue. These teams may be private, associated with a veterinary clinic or school, or with a fire department. Provide your 24-hour contact information to the local 911 emergency dispatch center.

Over the last 30 years, an increasing number of professional emergency responders and veterinarians have received training in technical emergency and disaster rescue of large animals (TLAER) and animal search and rescue for equines. These courses are aligned with National Fire Protection Association Standards for Technical Rescue 1006, 2500, and 150—which include teaching proper and safe tactics, use of realistic training mannequins to practice hands-on procedures and techniques for mud rescue, extrication of large animals, and dealing with unusual scenes.

5. Conclusion

Local equine practitioners are the responders of choice due to their expertise in horse behavior, handling, and medical knowledge—a mud rescue is never simple or easy. Prior preparation and communication with local law enforcement and fire/rescue groups, training in simple techniques and best practices, along with specialized equipment will contribute to improved outcomes. With emphasis on appropriate protective equipment for personnel (i.e., helmets) and the entrapped horse, appropriate mud rescue manipulation techniques, and proper positioning of personnel, the veterinary practitioner and their staff can assist the rescue team to achieve safe and effective results when moving recumbent horses trapped in various mud situations.

Acknowledgments

Declaration of Ethics

The Author has adhered to the Principles of Veterinary Medical Ethics of the AVMA.

Conflict of Interest

The Author has no conflicts of interest.

References and Footnotes

1. Dobson C. Woman stuck in bog trying to save her horse. Manchester Evening News. November 17, 2016. Available from: https://www.manchestereveningnews.co.uk/news/greater-manchester-news/woman-gets-stuck-mud-trying-12188439.
2. Blair A. Zara Buren, 14, drowns trying to save her horse in mud while riding with her mother. Daily Star. September 25, 2020. Available from: https://www.dailystar.co.uk/news/world-news/girl-14-who-drowned-quicksand-22744253.
3. Gimenez T, Gimenez R, May K, eds. *Technical large animal emergency rescue*. New York: John Wiley & Sons, 2008;149–167.
4. Gimenez T. Accidental hypothermia in the horse: A review for emergency responders. 2011. Available from: http://www.saveyourhorse.com/The%20Hypothermic%20Horse.pdf. Accessed February 26, 2022.
5. American Veterinary Medical Association. AVMA guidelines for the euthanasia of animals. Available from: https://www.avma.org/KB/Policies/Documents/euthanasia.pdf. Accessed March 11, 2021.
6. Gimenez T. The golden hours of equine emergency rescue. *Equine Vet* 2012;2:26–29.
7. Gimenez R, Smith S. How to manipulate a recumbent horse (entrapment, clinical, or technical emergency rescue situations, in *Proceedings*. Am Assoc Equine Pract 2017;63:403–412.
8. Iowa State University. Procedures for humane euthanasia. Available from: https://vetmed.iastate.edu/vdpam/about/production-animal-medicine/dairy/dairy-extension/humane-euthanasia. Accessed March 11, 2022.

[a]Häst head protector, Häst, PSC, Floyd, VA. http://rescue.hastpsc.com/804-286-0832

[b]Personal communication, A. Schwartz

[c]Personal communication, K. Bell

[d]Personal communication, K. Becker

[e]Häst mud lance, Häst, PSC, Floyd, VA. http://rescue.hastpsc.com/products/water/lances/lances.html 804-286-0832

[f]Nicopolous needle, Häst, PSC, Floyd, VA. http://rescue.hastpsc.com/products/water/nicopolous/needle.html804-286-0832

[g]Resquip horse mannequin, 4Hooves Large Animal Services. LLC, Biscoe, NC. https://4hoovessmart.com/online-store, (910) 494-8210 or (919) 201-6789, NC4HLAS@gmail.com

[h]Rescue glide, LARGE, Inc., Inman, SC. 864-270-1344 or benmccracken@rescueglides.com

[i]Large animal relocator sked system, 4Hooves Large Animal Services, LLC, Biscoe, NC. https://4hoovessmart.com/online-store/ols/categories/large-animal-skid-relocation-system, (910) 494-8210 or (919) 201-6789, NC4HLAS@gmail.com

[j]Häst Becker sling, Häst, PSC, Floyd, VA. http://rescue.hastpsc.com/ 804-286-0832

[k]Loops equine rescue system, UC Davis, CA. https://loopsrescue.com/ or LoopsRescue@gmail.com

Comparison of Technique: Intrathecal Mepivacaine and Intravenous Pentobarbital for Humane Equine Euthanasia

Kate Alexander, DVM†; Luke Bass, DVM, MS, DABVP (Equine)*; Embry Simon, BS; Khursheed Mama, DVM, DACVAA; and Sangeeta Rao, BVSc, MVSc, PhD

When compared to intravenous pentobarbital, intrathecal mepivacaine increased time of cessation of vital parameters. Subjective scores for lateral recumbency were smoother after induction of general anesthesia and subsequent intrathecal mepivacaine euthanasia when compared with lateral recumbency scores for euthanasia via intravenous pentobarbital. While intrathecal mepivacaine euthanasia requires some instruction on appropriate technique, there are multiple benefits compared to intravenous pentobarbital euthanasia. Authors' address: Department of Clinical Sciences, Colorado State University, Fort Collins CO, 80523; e-mails: lukebass@colostate.edu; kate.alexander@colostate.edu *Corresponding author; †presenting author. © 2022 AAEP.

1. Introduction

This study compared euthanasia using intrathecal mepivacaine or intravenous pentobarbital following adjunctive drugs. Intrathecal lidocaine was approved as a method of euthanasia by the AVMA in 2020 and has gained interest due to the recent pentobarbital shortage. This study aims to assess general anesthesia using ketamine/midazolam induction and subsequent intrathecal mepivacaine for euthanasia in horses and compares it to a traditional euthanasia method using a single intravenous injection of pentobarbital for induction of general anesthesia and euthanasia. Atlanto-occipital puncture was performed in both groups to facilitate blinding of anesthesiologist reviewers. Mepivacaine was chosen due to common availability of this drug for equine practitioners. Quantitative (timed) and qualitative parameters were assessed.

2. Materials and Methods

Horses were randomly assigned to one of two treatment groups: intrathecal mepivacaine or intravenous pentobarbital for euthanasia. Following intravenous catheter placement, all horses were sedated with detomidine (0.02 mg/kg). The intrathecal mepivacaine group was anesthetized prior to intrathecal injection of mepivacaine into the cerebellomedullary cistern via atlanto-occipital spinal tap. The remaining horses were induced and euthanized using intravenous pentobarbital and atlanto-

Research Abstract—for more information, contact the corresponding author

NOTES

occipital puncture with an intrathecal saline injection to provide blinding. Time from detomidine administration to cessation of vital parameters (respirations, pulse, corneal reflex, and ECG) was recorded for each horse. All euthanasias were captured on video for subsequent review by a blinded anesthesiologist, using an independent scale to assess quality of sedation, anesthesia induction, and lateral recumbency. The data was described using means if normality was met and compared between two groups using a T-test. If normality was not met, the data was described using medians and compared between groups using a Wilcoxon 2-sample test. A p-value of 0.05 was used as criteria for statistical significance.

3. Results

Time from detomidine administration to cessation of each vital parameter was significantly longer in the intrathecal mepivacaine group. While there was no statistically significant difference in qualitative scores between groups for sedation or induction, lateral recumbency was subjectively smoother in the intrathecal mepivacaine group (intrathecal mepivacaine mean score of 1.0708 and intravenous pentobarbital mean score of 1.3783, $P = 0.0028$).

4. Discussion

Intrathecal mepivacaine euthanasia was safe and effective, like results previously reported for intrathecal lidocaine. Advantages over pentobarbital include easier drug access, improved quality of recumbency, and a potentially lower risk of environmental contamination and scavenger animal poisoning.

Acknowledgments

Funding Source

Funding for this study was provided by Zoetis.

Declaration of Ethics

The Authors have adhered to the Principles of Veterinary Medical Ethics of the AVMA. This project was approved by the university Clinical Research Board.

Conflict of Interest

The Authors have no conflicts of interest.

Detection of Levamisole and Its Metabolites in Horses After an Oral Levamisole Administration over Seven Days

Emma Adam, DVM, PhD, DACVIM, DACVS*; Mary Scollay, DVM; Bruce Howard, DVM; John Taormina, DVM; Petra Hartmann, MS, FAORC; and Heather Knych, DVM, PhD, DACVCP

Levamisole disposition varies between horses with detection lasting for days to weeks following multiple doses. Authors' addresses: Gluck Equine Research Center, University of Kentucky, Lexington, KY 40546 (Adam); Racing Medication and Testing Consortium, 821 Corporate Drive, Lexington, KY 40503 (Scollay); Kentucky Horse Racing Commission, 4063 Iron Works Pkwy, Building B, Lexington, KY 40511 (Howard, Taormina); Industrial Laboratories, 6116 E Warren Avenue, Wheat Ridge, CO 80222 (Hartmann); KL Maddy Equine Analytical Pharmacology Lab, University of California-Davis, School of Veterinary Medicine, Davis, CA 95616 (Knych); e-mail: emma.adam@uky.edu. *Corresponding and presenting author. © 2022 AAEP.

1. Introduction

Levamisole is sometimes administered to racehorses to treat equine protozoal myeloencephalitis (EPM) or pharyngeal lymphoid hyperplasia. Metabolites of levamisole, aminorex and pemoline, are ARCI Class I Foreign Substances. The presence of levamisole and some metabolites in post-race regulatory samples is prohibited. Previous studies have examined single doses of the drug, and the paucity of data on the disposition of levamisole after multiple, consecutive doses led to this study being performed. This study examined the disposition of levamisole in serum and urine after 7 days of a typical dosing regimen.

2. Materials and Methods

Six healthy Thoroughbred geldings were treated with 500 mg of levamisole hydrochloride orally at 12-hour intervals for 7 days. Serum and urine samples were analyzed over a 28-day period and pharmacokinetic parameters determined.

3. Results

The terminal half-life of levamisole in serum was highly variable between horses. Following the final dose: serum levamisole was above LOD in 5/6 horses for 3-14 days (one horse remained over LOD on the last testing day), compound II was below LOD in all 6 horses by 14 days. Aminorex and pemoline were

Research Abstract—for more information, contact the corresponding author

NOTES

not detected in serum in the post-administration period.

In urine following the final dose, levamisole was below LOD on Day 6 and aminorex was below LOD on Day 3. Compound II was above LOD in 4/6 horses on the last day of sampling (Day 28).

4. Discussion

Levamisole and its metabolites were detected for an extensive period of time after completion of a 7-day course.

Acknowledgments

The Authors wish to thank New Vocations Farm, for providing the horses. Chris Ware, for assisting in processing samples, and Robin Sauer, LVT for assisting in levamisole administration.

Declaration of Ethics

The Authors have adhered to the Principles of Veterinary Medical Ethics of the AVMA.

Conflict of Interest

The Authors have no conflicts of interest.

Building a Team-Based Culture

Miranda P. Gosselin, DVM

Recruitment and retention of veterinary talent is a priority for every equine veterinary practice owner. Practices that invest in developing a team-based culture can reduce employee turnover, enhance the workplace environment, and improve profitability. Author's address: Millbrook Equine Veterinary Clinic, 3967 Rte 44, Millbrook NY 12545-5116; e-mail: mepgosselin@gmail.com. © 2022 AAEP.

1. Introduction

Equine veterinary medicine is experiencing a hiring crisis. While the United States economy is posting record low unemployment rates,[1] the number of practices looking for talent has never been higher. The demand for equine veterinary medicine has surged during the pandemic, and practices are desperately searching for new associate veterinarians, licensed and unlicensed technicians, and office staff. Less than 1% of new veterinary graduates are interested in equine practice and more than 50% of those young vets leave equine practice in the first 5 years.[2] Of those veterinary teams, support staff included, that are still in the equine trenches, many are overworked and experiencing burnout.[3] The revolving door, or high employee turnover model for veterinary talent and support staff is no longer sustainable. Practices hoping to hire and retain talent, should consider that potential employees are looking for purpose and flexibility in the workplace. Employees want to feel respected and valued, products of a healthy practice culture. It is not enough to start a veterinary business, hire some employees, schedule appointments and go to work. Instead, practices that want to avoid crippling staffing shortages must reduce employee turnover and invest in establishing a healthy, team-based practice culture.

2. It All Begins with Mission, Vision, and Core Values

The mission statement, vision statement, and core values are the foundation to every culture. A group of people working together toward a shared goal, or team, cannot work together or understand the goal without establishing these concepts. While it is hard for many veterinary business owners to work through this process, it is essential that everyone understands the goals of the organization from the owner to the stall cleaner. These concepts should be discussed regularly and updated as needed.

3. Lead with Empathy

A healthy culture is a product of healthy leadership. Practice owners or partnership groups cannot build a great culture if toxicity is the default. This can be the product of damaged relationships between partners or the way individual partners view their employees. Practice owners must be critical of their existing culture and recognize how and where they fall short as leaders. It is not fair for owners to expect the rest of

NOTES

the team to build and carry the culture. Successful leaders will own their mistakes, ask for feedback, and understand the roles that others play in the organization. Trust and vulnerability are the glue that holds a team together. Gratitude is essential.

4. Hire and Fire to Improve Culture

Considering the current job market, it may be tempting to hire anyone that has a pulse and is available to work. However, practices must use extreme caution when hiring and select people that complement their culture rather than strictly mirror it. Instead of hiring clones, selecting for candidates with similar backgrounds, education, and experience, practices should attempt to grow their organizations through consolidating a diverse group of people. Remember that it only takes a single toxic person to poison a culture.[4] Hire carefully to avoid bringing these people on board and do not hesitate to remove them if they cannot tow the proverbial party line. Write clear job descriptions and update them regularly. When practices hire for personality and culture fit, it becomes easier to move people around in an organization, if they could contribute more or find more satisfaction in another position.

5. Communicate, Communicate, and (When in Doubt) Communicate Some More

True teambuilding hinges on communication. Without communication, managers cannot delegate, teams cannot function effectively and efficiently, and organizations cannot grow and develop. Proactive communication is not micromanagement. Where micromanagement hones in on what a team member does not perform, proactive communication serves as a method of support with regular check ins designed to coach and mentor. Proactive communication also requires active listening and a basic understanding of the speaker's communication style. Personality profiles are a valuable tool designed to tease out an individual's preferred method of communication. Practices with healthy cultures enjoy communicating. Team members huddle-up at communal spaces to chat and share ideas, engage in casual conversation, and gather after work to socialize.

6. Candid Feedback is Valuable

Successful practice owners are not afraid to give or receive feedback. Employee feedback should be doled out in a timely and respectful fashion, never in front of an audience or after an extended period of time. At the same time, successes should be shared and celebrated with the team during meetings, via Slack or email, and in the office (i.e., praise wall). Good leaders never take credit for other's success but always bear the responsibility when the team falls short. Take every opportunity to express gratitude when team members excel and help the organization shine. Practice owners should not hide from feedback, both from employees and clients. Engagement surveys, 360-degree reviews, and exit interviews are simply a waste of time if the content is not taken seriously and issues are not further explored by management.

7. Compensation Matters

While this seems like an obvious statement, practices that are electing to invest in their team are reducing employee turnover because employees feel valued. Practices must offer competitive wages to both veterinarians and hourly employees. Pay attention to what local businesses are paying and meet or exceed those rates. Consider compensating veterinarians with a high base salary and an annual production bonus. Veterinarians will work more collaboratively and spend less time fighting over clients and services. Practice owners are starting to think outside the box with other forms of compensation/benefits. Potential employees are looking for flexible scheduling, shared on-call, paid time off, student debt support, cooperative childcare, paid family leave, health insurance, and retirement investment opportunities. Employee compensation is no longer "one size fits all, "as each employee values different benefits. Practices can mix and max benefits to personalize and enhance compensation packages for each individual.

8. Conclusion

Equine veterinary practice is driving away veterinary talent. Practice owners need to start actively shaping their business culture to attract and retain employees. This can be accomplished by setting core values/vision/mission, leading by example, hiring and firing for culture fit, communicating proactively, encouraging feedback, and providing fair compensation for employees. Practices that successfully improve culture will experience a workplace that is more pleasant and productive, which will reduce employee turnover and increase profitability.

Acknowledgments

Declaration of Ethics

The Author has adhered to the Principles of Veterinary Medical Ethics of the AVMA.

Conflict of Interest

The Author has no conflicts of interest.

References

1. Amadeo K. Unemployment rate by year since 1929 compared to inflation and GDP, unemployment rate history. The Balance. 2022, Jan 28. Accessed March 1, 2022. https://www.thebalance.com/unemployment-rate-by-year-3305506
2. American Association of Equine Practitioners. Economic report. 2019, Apr 1. Accessed March 1, 2022. https://aaep.org/sites/default/files/Dcocuments/2019%20FINAL_AVMA_AAEP_Equine_Report.pdf

3. Grice A. Effects of the Covid pandemic on equine practice. 2021, Oct 7. Accessed March 1, 2022. https://equimanagement.com/articles/effects-of-the-covid-19-pandemic-on-equine-practice
4. Farnell R. Toxic followership and what can be done. 2021, Jun 21. Accessed April 25, 2022. https://www.psychologytoday.com/us/blog/leading-high-performing-team/202106/toxic-followership-and-what-can-be-done

Maximizing Utilization of Technicians in Equine Practice

Kelly A. Zeytoonian, DVM, MBA, CERP

This presentation and proceedings will outline weaknesses in the standard veterinary medicine model of technician roles. The benefits of technicians working to the high end of their skill set will be defined, and tools to implement change within everyday practice will be provided. Author's address: PO Box 620071, Woodside, CA 94062; e-mail: info@starwoodveterinaryconsulting.com. © 2022 AAEP.

1. Introduction

The veterinary industry at large has experienced exponential growth through the global pandemic. In 2020, veterinary industry revenue increased by 7.7%.[1] Growth was attributed to an increase in pet ownership and increased disposable income. The equine sector is no different. An August 2020 survey[2] performed by Dr. Amy Grice revealed that a majority of respondents indicated they were either not affected by COVID or experienced an increase in revenue following onset of the pandemic. Doctors entering the equine veterinary industry have decreased in the past decade (Fig. 1 below) despite the ongoing need for equine veterinarians—creating obvious challenges and maybe not so obvious opportunities for licensed and unlicensed veterinary technicians (the term "technician" will be used throughout this paper and is all-encompassing).

2. Discussion

It is the author's opinion that the equine veterinary industry is historically lacking in technician utilization. A number of factors or perceptions likely contribute and are discussed in the next section.

Historic Model of Veterinarians Working Solo and Relying on Horse Owners to Assist

Sadly, 16% of the 524 respondents work without any assistance (Fig. 2).[3] Increasing concerns of safety and newer practitioners' desire to find efficiencies that improve work-life satisfaction are driving the demand for support team hires, in the author's experience.

Higher Technician Pay Driving Employees to the Small Animal Sector

Numbers directly comparing small animal to large animal technician salaries are difficult to come by. Anecdotally, the author has observed average hourly rates of $2 to $5 more in small animal compared to equine. A recent survey of American Association of Equine Veterinary Technicians and Assistants members[4] (licensed, unlicensed, and practice manager roles combined) shows the most common hourly wage category is $15 to $20. See the figure below for details.

A May 2019 survey[5] explored why veterinary respondents had left or considered leaving equine

NOTES

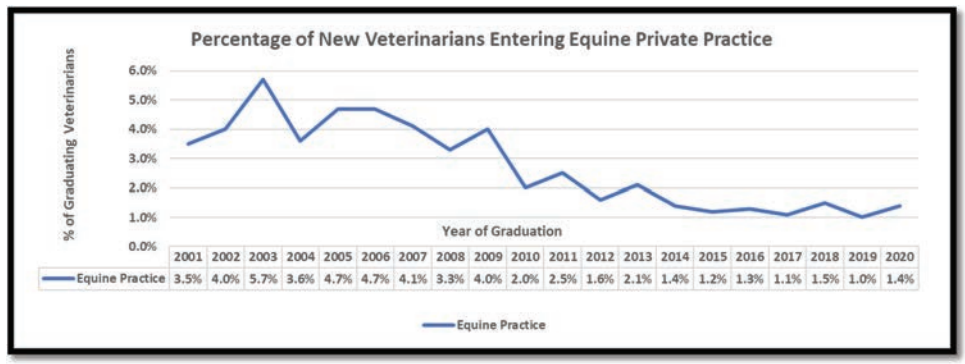

Fig. 1. Percentage of new graduates entering private equine practice.[3]

practice. The option "low salaries and compensation" was in the top 5 for responses. While the survey focuses on veterinarians, it is the author's opinion that a similar trend would be identified in technicians given a similar survey.

Difficulties of Generating Enough Revenue to Support Additional Team Members

When technicians are underutilized, it is more difficult to generate revenue that supports additional support team members or higher wages. That said, the AVMA-AAEP Equine Economic Survey[3] measured veterinary salaries by practice size (Fig. 4). Practices with multiple employees showed a trend in increasing veterinarian salaries as additional team members were hired. A solo practitioner adding an assistant earned just $126.99 less[3] in salary for the year—a small price to pay for a myriad of benefits. After a practice employs a range of 5 to 9 staff members, veterinary income rises —likely a reflection of more efficient workflow and division of labor. Equine veterinarians can also learn from small animal counterparts who average twice as many support team members per veterinarian.[6] For equine, ratios range from 1:0.5 (mobile) to 1:1.5 (combined ambulatory and hospital). These numbers compare to average small animal predominant clinic ratios of 1:3. While vet-to-staff ratios are not the only factor, the author believes they play a big part in the disparity between equine and small animal average annual doctor revenue—with small animal vets producing $200,000 more on average.[3] While there are logistical hurdles to overcome—one can only fit so many assistants in a work truck—a comparison to small animal financials and placing value on safety and career satisfaction quickly supports the hiring of additional assistance. The information provided above helps summarize why veterinarians need additional help and shows that it is possible to create additional value for the practice with more assistance. The following section will help start a conversation with a practice's owner and management to 1) hire additional help and 2) utilize technicians to the top of their skill set.

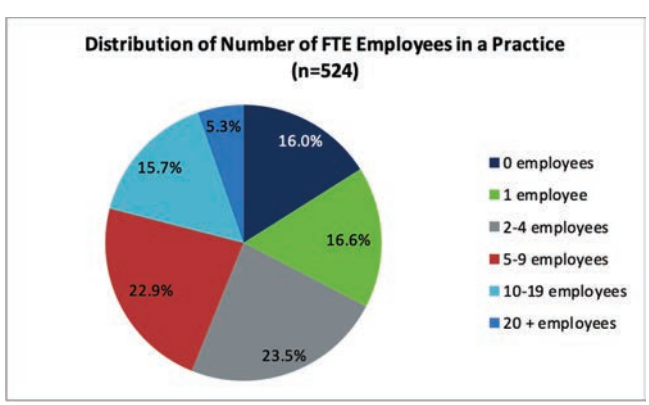

Fig. 2. Number of full-time equivalent (FTE) employees (including veterinarians and support team) in responding practices.[3]

3. Solution

Technicians are an integral part of the equine veterinary clinic and need to be recognized and utilized. In many states, a technician can do bandage changes, give intravenous and intramuscular medications, perform laser/shockwave therapy, and operate radiograph equipment while under the indirect supervision of a veterinarian. Indirect supervision implies that a

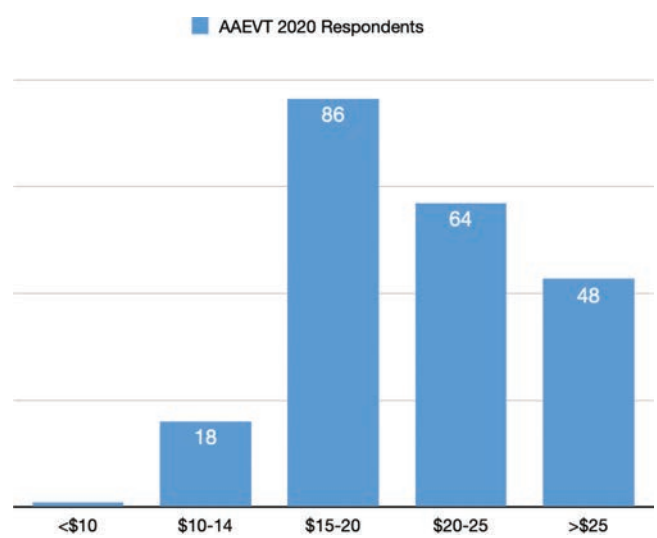

Fig. 3. Hourly wage breakdown of 2020 American Association of Equine Veterinary Technicians and Assistants (AAEVT) survey respondents.[4]



Fig. 4. Veterinarian's income based on number of staff members in a practice.[3]

veterinarian is not physically on site where care is being provided to a patient, but the veterinarian has given direct orders for patient care. Remember that each state's veterinary medical board has a different policy for appropriate direct and indirect supervision of tasks. Consult with your veterinary medical board for state-specific guidelines.[7]

Technician appointments have the mutual benefit of improving employee satisfaction for support team members who now have a more integral role in patient care and doctors who have additional time to complete medical records, see more advanced cases, or take an afternoon off. The following section will detail how a practice can better utilize support team members and implement technician-driven appointments.

4. How-To

- Gain buy-in from doctors and practice owners. Remind them salaries for veterinarians increase as the team grows (Fig. 4).
- Consult with your state's veterinary medical board to determine tasks that licensed and unlicensed team members can perform with direct or indirect supervision.
- Assess your practice's current use of technicians and assistants. How do you compare to participants of the 2019 AVMA-AAEP Equine Economic Survey? Are support team members performing all the tasks they can legally? Figure. 5 can be used as a talking point with your team.
- Agree upon communication flow should a concern arise during a technician visit. A doctor should be available remotely to field any questions. Video chat is a great way to receive real-time feedback if something unexpected occurs.
- Schedule dedicated time for solo appointments or "double up" on patient visits at the same location.
- Educate clients on the benefits of technician appointment slots (more accessibility, financial savings, etc.).
- Enhance client comfort with nondoctor visits. Writing a blog post or presenting at a client education seminar are both ways for technicians to gain confidence from clients.
- Commit to improving technical skills during doctor appointments so technicians can continue offering a wider range of services.
- Negotiate a pay increase that reflects the added doctor efficiency or solo revenue produced by the technician. As a basic rule of thumb, revenue should increase by 1.5 times the pay increase for the practice to break even. This suggestion accounts for the cost of goods sold, payroll tax, worker's compensation, etc.
- Share the following excerpt from the October 2020 *Equine Veterinary Journal* with your owner or practice manager:

How do you know if you can afford a technician? Some simple numbers can get you started: The nationwide average salary according to the Bureau of Labor Statistics for a registered technician in 2020 was $17.43/hour, with a range from $12/hour to $25/hour. A 2019 report from the Veterinary Hospital Managers Association reports a range of $16.85–$21.93 for credentialed technicians. Data specific to equine technicians was collected by the American Association of Equine Veterinary Technicians in 2020 and is shared in Figure 3. Self-reported wages were predominantly in the $15–20/hour range. This report is also broken down by state and time in the industry for easier comparison of wages. Since registered technicians are licensed individuals, continuing education and licensing fees are something to consider. Additional benefits are clinic and location-

	Licensed Technician (n=222)		Non-licensed Technicians/Veterinary Assistants (n=394)	
	Obs.	Percent	Obs.	Percent
Administer anesthesia	168	75.7%	141	35.8%
Setting up diagnostic imaging equipment (radiography, ultrasonography, endoscopy)	191	86.0%	362	91.9%
Obtaining radiographic studies	163	73.4%	211	53.6%
Perform other diagnostic imaging studies (e.g. nuclear scintigraphy, MRI)	54	24.3%	45	11.4%
Administer vaccinations	141	63.5%	163	41.4%
Place IV catheters	184	82.9%	152	38.6%
Administer treatments or set up fluids through catheter	189	85.1%	258	65.5%
Administer IV injections (no catheter)	172	77.5%	171	43.4%
Administer IM injections (other than vaccinations)	190	86.5%	256	65.0%
Perform routine treatments - e.g., apply foot wrap, apply leg wrap, apply topical medications	186	83.8%	284	72.1%
Collect venous blood samples	198	89.2%	260	66.0%
Perform laboratory tests in house - e.g., set up bacterial cultures, use CBC/chemistry analysis machines, perform quantitative fecal exams, cytology	196	88.3%	280	71.1%
Perform aseptic preparation for procedures	201	90.5%	333	84.5%
Prepare injections for doctor use	191	86.0%	305	77.4%
Communicate with clients - e.g. Give care instructions, report laboratory results, make appointments	174	78.4%	260	66.0%
Write invoices for work performed by veterinarian	170	73.9%	264	67.0%
Assist in surgical procedures	162	76.6%	245	62.2%

Fig. 5. Practice utilization of licensed and unlicensed technicians.[3]

dependent, but the practice can expect to invest an additional $6,000–11,000 in employee benefits, payroll taxes, and worker's compensation. See Table 1 for general assumptions:

5. Conclusion

Industry leaders are predicting a deficit in veterinarians and veterinary support team members for the next decade. Now is the time to start rethinking the current equine veterinary practice model and allow technicians to start working at the top of their skill set in order to recruit and retain these valuable team members. Clinics who embrace this changing model will find themselves working more safely and efficiently, resulting in client satisfaction, employee fulfillment, and business success.

Table 1. Considerations for Hiring

National median salary – $36,260
Payroll tax (variable by state) – $2700
Health insurance – $3000–$6000
Dental/vision – $600
CE – $500–$1000
Worker's comp (state and policy variability) – $500–$2000
PTO, sick days – $500
Uniform – $300

Acknowledgments

Thank you to the technicians, assistants, and entire support staff of Starwood Equine!

Declaration of Ethics

The Author has adhered to the Principles of Veterinary Medical Ethics of the AVMA.

Conflict of Interest

The Author offers and provides business consulting services to veterinarians and veterinary practices through Starwood Veterinary Consulting, Inc., of which she is a shareholder.

References

1. IBIS World. 2021 veterinary services industry in the US – Market research report. Available from: https://www.ibisworld.com/united-states/market-research-reports/veterinary-services-industry/. Accessed October 11, 2021.
2. Grice AL. Effects of the COVID-19 pandemic on equine practice. Available from: https://equimanagement.com/articles/effects-of-the-covid-19-pandemic-on-equine-practice/. Accessed May 7, 2022.
3. American Association of Equine Practitioners. AVMA-AAEP Equine Economic Survey. 2019. Available from: https://aaep.org/sites/default/files/Documents/2019%20FINAL_AMVA_AAEP_Equine_Report.pdf. Accessed October 12, 2021.
4. American Association of Equine Veterinary Technicians. 2020 membership survey responses. Raw data provided by Deb Reeder.
5. EquiManagement. Leaving equine veterinary practice. Available from: https://equimanagement.com/articles/leaving-equine-veterinary-practice. Accessed April 23, 2022.
6. American Veterinary Medical Association. The market for veterinary services. 2018. Available from: https://www.avma.org/sites/default/files/resources/2018-econ-rpt3-veterinary-services.pdf. Accessed October 12, 2021.
7. American Veterinary Medical Association. Veterinary state board websites. Available from: https://www.avma.org/advocacy/state-and-local-advocacy/veterinary-state-board-websites. Accessed April 23, 2022.
8. Wright C, Zeytoonian K. How to improve practice efficiency, revenue and job satisfaction by hiring a licensed veterinary technician, in *AAEP News*. *Equine Vet Educ* 2021;33:3–4.

Additional Resources

- https://www.avma.org/resources-tools/practice-management/utilizing-veterinary-technicians-improve-practice-success
- https://www.aaevt.org/online-certificate-program/

Skeletal Injuries in Equine Athletes – Pathogenesis and Training Concepts for Injury Prevention

Susan Stover, DVM, PhD, DACVS

Author's address: University of California-Davis, School of Veterinary Medicine, One Shields Avenue, Davis, CA 95616; e-mail: smstover@ucdavis.edu. © 2022 AAEP.

1. Introduction

While it is rewarding to successfully diagnose and treat an individual horse for an injury and see the horse return to performance, it is equally rewarding and possibly more impactful to use knowledge and expertise to help clients train their horses to optimize performance with low risk for injury. This paper is a brief reminder that the impact of skeletal injuries on horse attrition and industry costs; then builds the foundation for understanding the need for skeletal adaptation to sport horse demands, the mechanisms for injury and adaptation, and the contributing factors to sport horse injuries; and lastly reviews concepts of training to shift the balance to adaptation and optimal performance.

2. Cost of Poor Performance and Attrition

The cost of poor performance, inability to perform, and attrition from equine sport can be huge. Musculoskeletal injuries have a large detrimental impact on the sport horse industries. Injuries result in loss of horses from training and racing, racehorse deaths, jockey injury and deaths, and poor public perception of the racing industry. Inability to train racehorses in New York occurred for 8.1% of potential training days, 72.1% due to lameness.[1] Insidious, but devastating, outcomes include the adverse effects on industry economics.[2] As an example, median financial return was $23,000 less for yearling Thoroughbred horses being broke and conditioned for 2-year-old in-training sales that lost 13 to 108 days of training compared to horses that lost only 1 to 11 days of training.[3] Economic wastage in 2011 was estimated at almost $3 million each month in California racehorses and over $81 million per month nationally, based on ~3% of horses lost from racing each month and median yearling auction price.[a] The estimate does not include costs associated with training, treatment, rehabilitation, shoeing, and other expenses to prepare and keep horses in training and competition. High turnover of sport horses results in poor return on owner investments. Consequently, elucidating and managing the causes of skeletal injury should be key goals of the sport horse industries.

3. Skeletal Adaptation

The skeleton is an energetically expensive part of the body. Mineralization imparts bones with the necessary stiffness and strength to support the body and allow for locomotion. However, mineralized tissues are dense and heavy and thus energetically expensive to carry and move. Consequently, the skeleton is dynamic and continually adapts, gaining or removing bone material in response to the most recent loading (exercise) conditions. The process is analogous to gaining or losing muscle mass with exercise or inactivity, respectfully.

NOTES

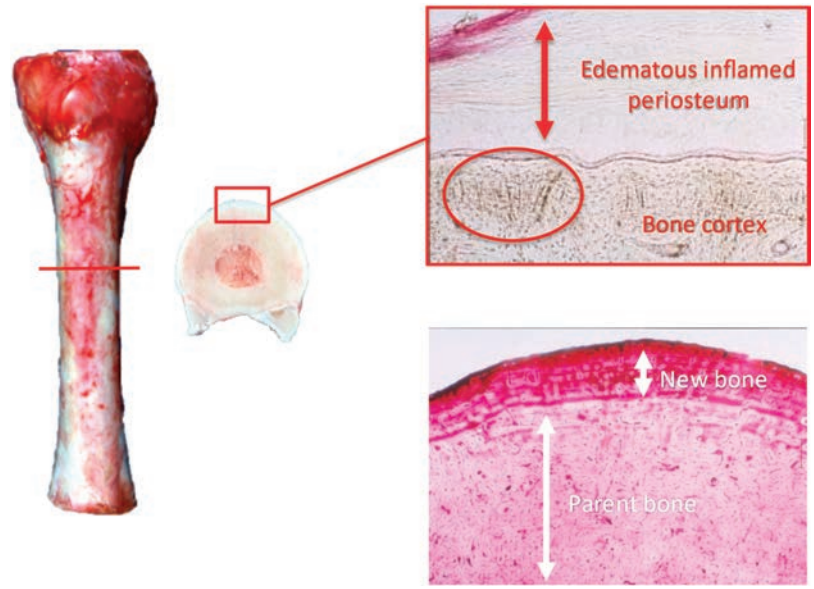

Fig. 1. Dorsal aspect of the third metacarpal bone of a racehorse that had dorsal metacarpal disease (bucked shins) evidenced by a region of red, edematous, thickening in the middle of the diaphysis. A transverse section at the level of the line through the metacarpus illustrates the outer cortical region visualized in the undecalcified histologic sections stained en bloc with basic fuchsin (box). The upper micrograph illustrates the junction of the inflamed periosteum overlying cortical bone beneath the periosteal surface. Radially oriented microcracks (ellipse) are coincident with collagen fibers extending to the periosteum. Periosteal osteoblasts are stimulated to form new bone on the periosteal surface (modeling), which enlarges the cross-sectional area of the bone, reduces bone stresses (and thus strains) with the recently acquired higher loads, and reduces susceptibility of the bone to damage at the new level of exercise intensity. Note that there are no resorption bays (porosities) in the cortex. The bone tissue will self-repair the microcracks without bone remodeling.

Bone damage occurs when higher than expected (recent) loads (stresses) cause bones to deform (strain) excessively. The most easily observable forms of damage histologically are diffuse damage and microcracking. One mechanism for preventing excessive deformation and consequent bone damage formation is to enlarge the bone structure. The stress (stress = load/bone area) associated with high loads is reduced when bones get larger and the strains (deformations) within bone material become smaller because strain is proportional to stress for a given bone material. This process occurs during growth. Bones not only get longer but also get larger in diameter to support increasing body mass.

Sport horse training involves increases in bone loads, whether by inducing faster speed, higher jumps, or unique gymnastics. Ideally, the increase in exercise intensity is graduated, allowing for skeletal adaptation to small increments in skeletal loads. So, what happens to induce skeletal adaptation?

Slightly higher than expected loads or a change in expected activity cause submicroscopic- or microscopic-level damage to bone tissue, typically evidenced microscopically by diffuse en bloc basic fuchsin staining (diffuse damage). Diffuse damage is capable of self-repair without inducing remodeling (bone resorption followed by bone formation)[4] because surrounding osteocytes are not perturbed.[5] This "nondestructive" type of damage only transiently reduces the stiffness (modulus) of the locally affected bone material.[4] Further, bone damage near osteoblast or osteogenic precursor (bone lining cell) covered bone surfaces can induce bone formation (modeling; Fig. 1). Bone modeling at sites of nondestructive bone damage alter the size and/or shape of the bone structure and protect against further damage at the same new load level or activity (Fig. 2). Ideally, training is increased gradually to allow for skeletal adaptation to increasing loads and exercise intensity. Further, only a

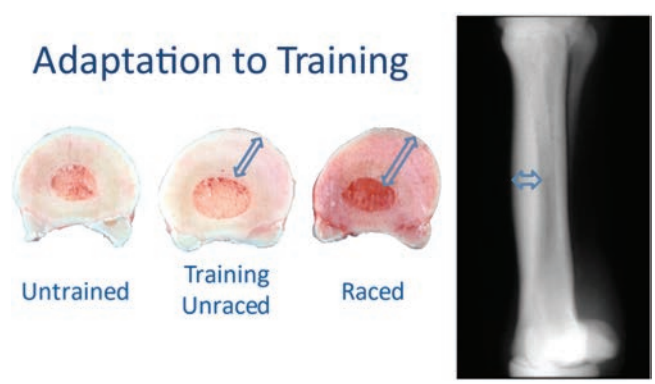

Fig. 2. Transverse sections from 3 different racehorses illustrating the adaptation that the dorsomedial aspect of the metacarpal cortex is making in response to the higher magnitude of bone strain and change in strain orientation that occur locally in response to initiation and maintenance of high-speed activities (breezing at racing speeds and racing).[7] Dorsomedial cortical expansion is the modeling response to outer cortical nondestructive damage, which reduces bone stresses and strains by increasing bone cross-sectional area. Adapted bones are resistant to recurrence of dorsal metacarpal disease.



Fig. 3. Left, Scanning electron micrograph of a transverse section from the intact humerus of a racehorse that had a catastrophic fracture of the contralateral humerus. The soft tissues (including cells) have been removed. Microcracks (red lines) are illustrated that obstruct canalicular flow of nutrients from vessels in the Haversian canals to osteocytes in lacunae between cracks. Absence of osteocyte lacuna between cracks is indicative of lacunar mineralization secondary to osteocyte death. Subsequently, osteoclasts are targeted to remove damaged bone (crack in resorption bay).[10] Right, Lower power scanning electron micrograph from the same specimen illustrating focal osteopenia in a region of high-density microdamage. Normal bone porosity for this site is only present in the lower left corner of the image.

small exposure to the new load level is sufficient to generate a bone modeling response.[6] Increased bone material reduces bone strains at the new exercise level and prevents further damage.

4. Bone Injury

Bones incur a spectrum of bone damage. Mild, nondestructive bone damage promotes skeletal adaptation. Large increases in bone loads, excessive loads, numerous repeated loads, or repeated loads on compromised bone tissue can produce more severe bone damage. For example, continued high-intensity exercise on metacarpi with dorsal metacarpal disease before adaptation is completed can lead to incomplete cortical fracture (stress fracture) or catastrophic complete bone fracture.[8]

More severe forms of damage compromise osteocyte viability[9] and induce bone remodeling (Fig. 3).[5] The resorption of damaged bone material causes a transient focal osteopenia until remodeling (bone formation) comes to completion. Incomplete cortical stress fractures are a manifestation of this process (Fig. 4). Detection of a "bone fracture" on radiographic images is visualization of the porosities associated with a plane of microdamage. Delayed visualization after time of injury is the result of the time needed for bone resorption to create sufficient porosities for radiographic visualization.

During repair, transient osteopenia compromises the strength and stiffness of the bone material.[11,12] Consequently, repeating the most recent intense loads is more damaging because bone stresses, and thus deformations, are higher because of the reduced amount of bone material at the affected site. Further, this weakened site acts as a stress riser that can promote complete bone fracture under otherwise normal loading circumstances (Fig. 5). However, on completion of modeling (periosteal callus and trabecular thickening) and intracortical remodeling, the bone structure is stronger and the bone material is tougher, further resisting microcrack initiation and propagation and increasing fatigue life.[13,14]

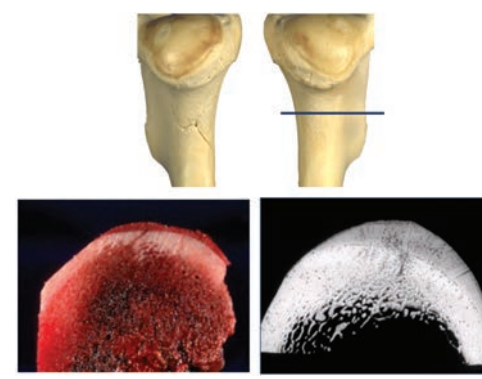

Fig. 4. Fresh (left) and radiographic (right) images of a transverse section taken at the level of the blue line through intact humeri of racehorses that had a complete fracture associated with a stress fracture of the contralateral humerus. The linear red discoloration in the white compact bone material of the fresh gross specimen corresponds to the roughly linear regions of intracortical radiolucencies on the radiographic image. Note the periosteal apposition of fresh, red, vascular woven bone on the fresh specimen and the gray (less mineralized) newer bone on the radiographic image. Periosteal modeling will contribute to increasing bone cross-sectional area and adaptation to the more intensive loading conditions provided that intracortical remodeling continues to completion (new bone formation).

5. Subchondral Bone Adaptation and Injury

Subchondral bone tissues respond to increases in loading by the same processes that occur in cortical bone tissues. Mild, subclinical damage that resolves without remodeling induces trabecular thickening and subchondral sclerosis through micromodeling (Fig. 6). The addition of bone material is expected to increase the stiffness, strength, and fatigue life of the bone structure,[15,16] reducing bone deformations and

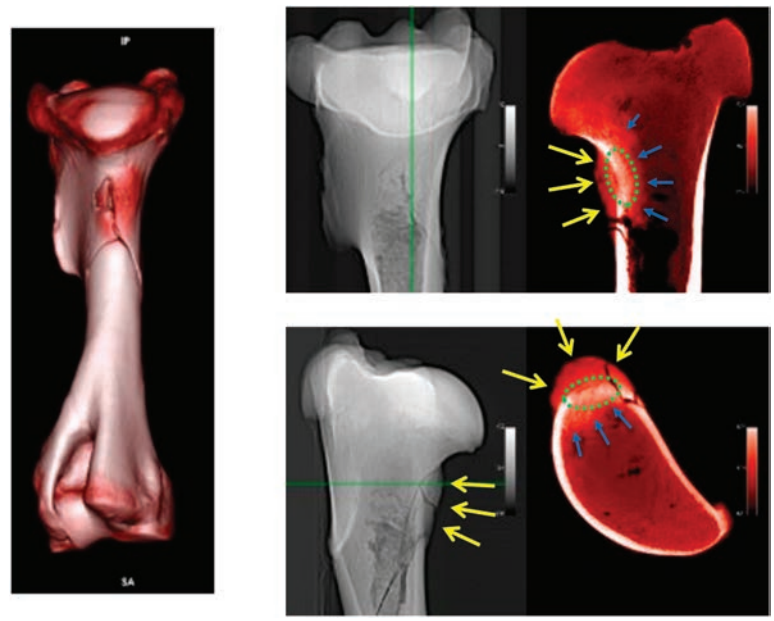

Fig. 5. Left, Caudal view of a reconstructed computed tomography scan of a humerus that had a catastrophic complete fracture through an osteopenic focus associated with a stress fracture. Compact bone material is white and porous bone material is red. Right, Caudocranial (center top) and lateromedial (center bottom) projections illustrate the level (green lines) of sagittal (right top) and transverse (right bottom) sections viewed on the respective right computed tomography sections. Most relevant to complete fracture are the intracortical porosities (dotted green ellipses) that promoted fracture. Periosteal woven bone callus (yellow arrows) and trabecular thickening (blue arrows) are attempts to buttress the associated cortical weakness.

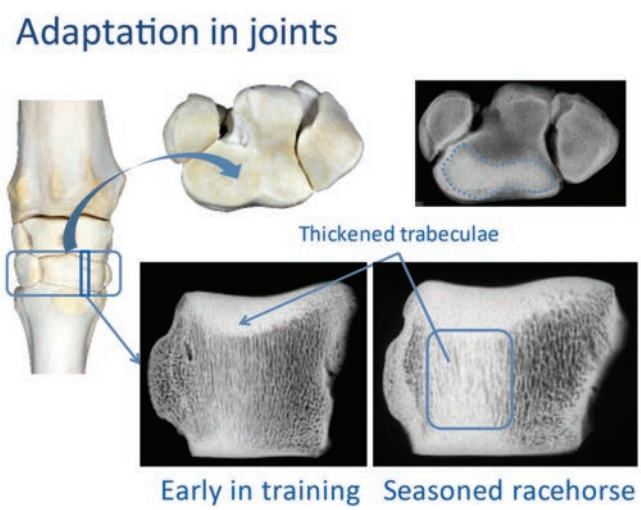

Fig. 6. Top image, Proximodistal (top right) radiograph of the proximal row of carpal bones illustrates sclerosis (dotted blue area) in the dorsal aspect of the third carpal bone. Bottom images, Radiographs of parasagittal sections of the third carpal bones of two different racehorses. The horse in the early stages of training (left) has compaction of subchondral trabeculae bone that resulted in typical crescent-shaped sclerosis. Thickened trabeculae bridge the proximal and distal regions of subchondral sclerosis in the seasoned racehorse (right). These changes are adaptations to increased bone loading associated with increased exercise intensity and are the result of micromodeling on trabecular surfaces. Note the absence of regions of local porosities.

damage under well-adapted circumstances for the exercise intensity.

However, similar to cortical bone, subchondral bone is susceptible to different levels of microdamage. Changes in subchondral bone have been implicated in the progression of osteoarthritis in humans and horses.[17–20] Microdamage that devitalizes bone tissue is repaired by remodeling. The first stage of repair by remodeling is bone resorption, which can create a focal porosity that acts like a stress riser and may facilitate complete fracture (Figs. 7 and 8).[21]

Given time and absence of injurious loads, damaged subchondral bone tissue is capable of repair and regeneration. Subchondral support of overlying articular cartilage maintains cartilage health. However, if loading is continued on osteopenic subchondral bone, the overlying articular cartilage loses support.[17] Subsequent cartilage collapse into the underlying bone defect results in osteoarthrosis (Figs. 9 and 10).

6. Factors That Influence the Balance Between Adaptation and Injury

Increased loading is required to induce adaptation to new loading circumstances. Training is needed to increase ability and performance. Knowledge of the factors that affect the amount and severity of bone damage incurred during training are helpful to achieve bone and joint adaptation without overt injury.

Although bones can be fractured in a single large traumatic accident, fractures in athletes are the result of smaller repetitive loads. Bone, like other materials, will fatigue with repeated loading. Eventually, bones

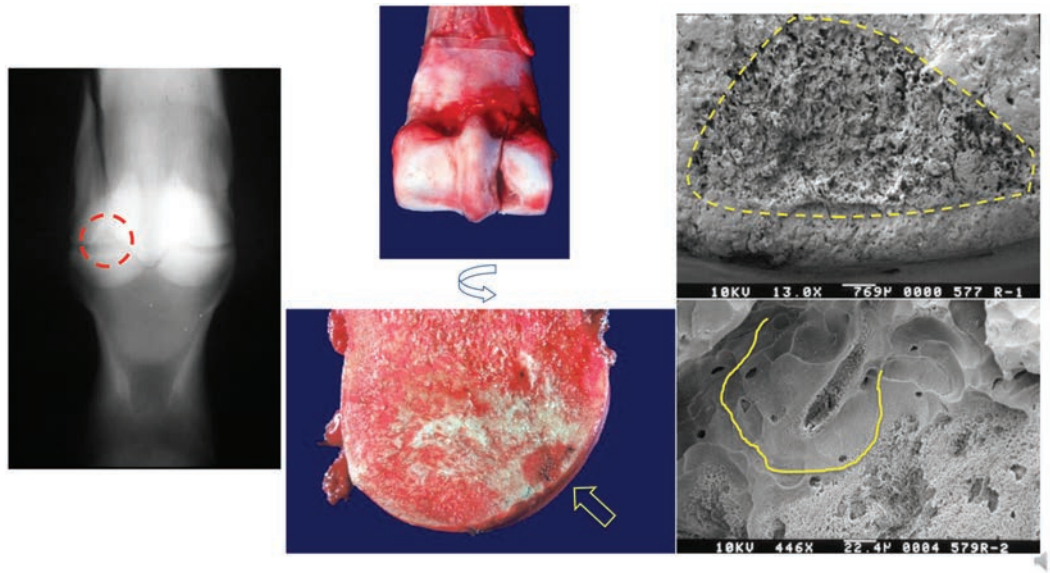

Fig. 7. Left, Dorsopalmar skyline (125°) radiographic projection of the fetlock joint illustrating a complete lateral condylar fracture associated with a subchondral bone porosity. Middle, Reconstructed lateral condylar fracture (top) illustrates the void created by articular fragmentation and the face of the lateral fracture segment (bottom) illustrates a semicircular reddish (vascular) region (yellow arrow) within a large crescentic region of sclerosis. Right, Scanning electron micrograph of the red region demonstrates a focal region of osteopenia (top) with extensive resorption bays (yellow dashed line) surrounded by compacted trabecular bone. Higher magnification (bottom) illustrates osteoclastic resorption bays overlying a large microcrack (yellow line) and new woven bone in the lower right corner.



Fig. 8. The osteopenic subchondral lesion acts like a stress riser on a snack bag. The stress riser facilitates tearing of the bag (fracture of the bone) in a predictable manner with low force.

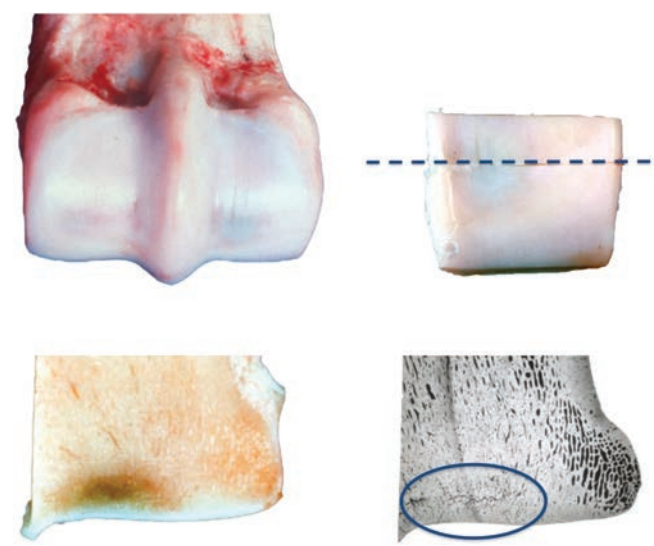

Fig. 9. Distopalmar aspect of a metacarpal condyle with the beginning stages of palmar osteochondral disease evidenced by subtle bluish discoloration beneath the articular surface palmar to the transverse ridge (upper left). Transverse section of the condyle at the level of the dashed line (upper right) reveals a dark discolored subchondral bruise (lower left). Radiograph of the section illustrates the microcracks that disrupt vascularization of subchondral bone between the cracks and the articular surface.

will fail if repeatedly loaded in the laboratory.[22,23] The relationship between number of repeated loads required for bone failure is exponential (Fig. 11). Higher loads create markedly more damage in far fewer cycles than low loads. Each loading cycle (stride of the horse) induces some level of damage in the bone material. Bone can sustain low level loads for a long time; nondestructive damage is continually self-repaired. Conversely, fewer large loads may induce destructive damage that requires remodeling for repair, increasing susceptibility to more damage with continued loading. At an extreme, the bone will ultimately fail (i.e., fracture) due to accumulation and propagation of cracks through the process of fatigue.

Importantly, biologically, only a small number of higher than the most recent loads (4–36 cycles, or strides/gymnastics, of loading) are sufficient to stimulate adaptive modeling responses.[6] Excessive and repetitive high loads only cause more bone damage, which can promote injury. A common cause of injury is overtraining. Further, once an equine athlete has achieved a high level of adaptation and performance, few loads are required to maintain the adaptation.

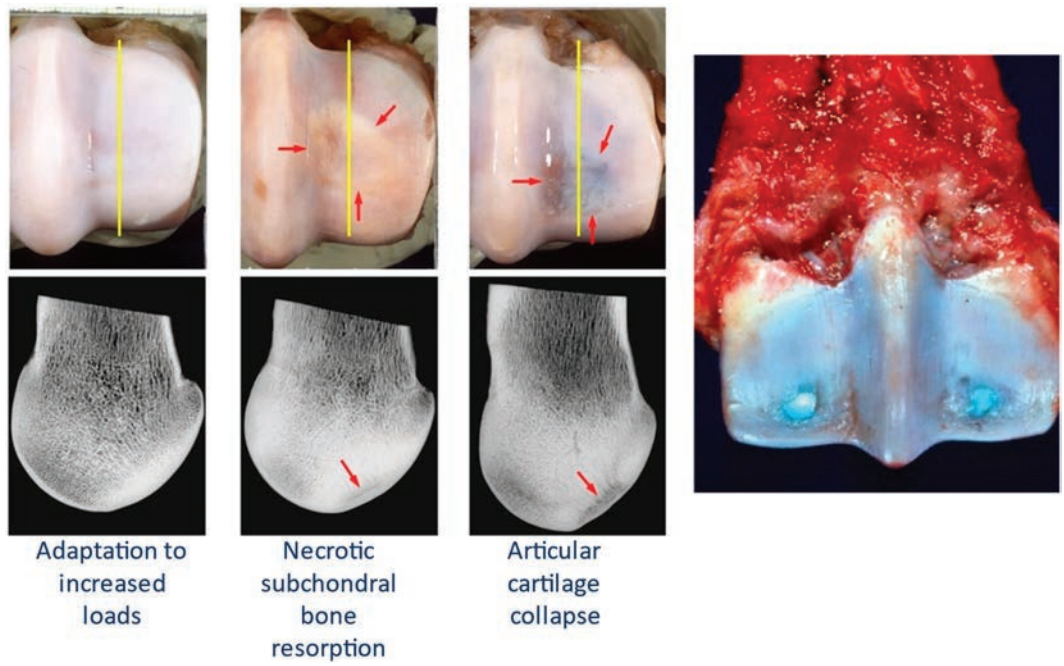

Fig. 10. Left panel, Distal condyles (top) and radiographs of sagittal sections (bottom) at the level of the yellow lines on the condyles illustrate the progression of (1) sclerosis mediated adaptation to increased loading (left), (2) subchondral bone osteopenia secondary to damage resorption with an intact subchondral plate (middle), and (3) extensive subchondral resorption with collapse of the articular surface (right). Right panel, Articular cartilage collapse secondary to loss of subchondral support manifests as irreversible osteoarthrosis.

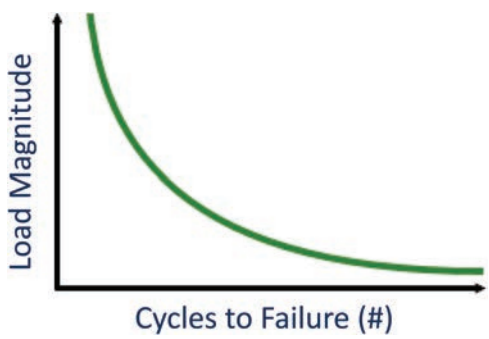

Fig. 11. The nature of the relationship between number of loads required for bone failure is nonlinear, with the highest loads having a much larger effect than low loads.

However, the loading circumstances must be relevant to the intended performance so bone structures see the stresses and strains that are unique to the relevant sport. Each equestrian sport produces unique bone stresses and strains. For example, while swimming may maintain cardiovascular fitness, swimming reduces loads on bones. In response, bones may lose bone material and become less able to sustain loads incurred on return to racing or jumping. While varied training activities are beneficial to skeletal health, training for sport specific activities is a necessary component to be competitive without injury.

A key strategy for increasing skeletal fitness and optimizing performance is to manage the relationship between the rate of accumulation of bone damage with repetitive loading and the rate that damage can be repaired. Injury occurs when damage accumulation exceeds damage repair.[11] Adaptation occurs when damage repair exceeds damage accumulation.

The rate that damage can be repaired through remodeling is time limited. Osteoclasts remove damaged bone material very rapidly (within days to weeks). However, osteoblasts are much slower at rebuilding high-quality cortical osteons (requiring months). In the healthy equine athlete, the time required for healing can be prolonged by adverse conditions (such as continued loading on damaged bone material), but the time required for healing cannot be shortened less than the time for normal repair. Consequently, the goal is to keep the rate of damage accumulation below the threshold for repair.

One key to managing the rate of damage accumulation and extending the fatigue life of bones, that is, the likelihood for training and competing without injury, is to manage the load level that horses incur with each stride or athletic maneuver. Known strategies include managing hoof conformation (e.g., avoid long toe underrun heel hoof conformation) and shoeing (e.g., avoid unbalancing the hoof with asymmetric traction devices), which can increase the lever arm of the ground reaction force about the fetlock.[24,25] Another strategy is to minimize the magnitude of the ground reaction force that is transferred from the ground to the hoof through selection and management of arena and race surfaces.[26–29] Because of the exponential nature of the relationship between load magnitude with damage and fatigue life, managing the load to the limb during each stride or activity

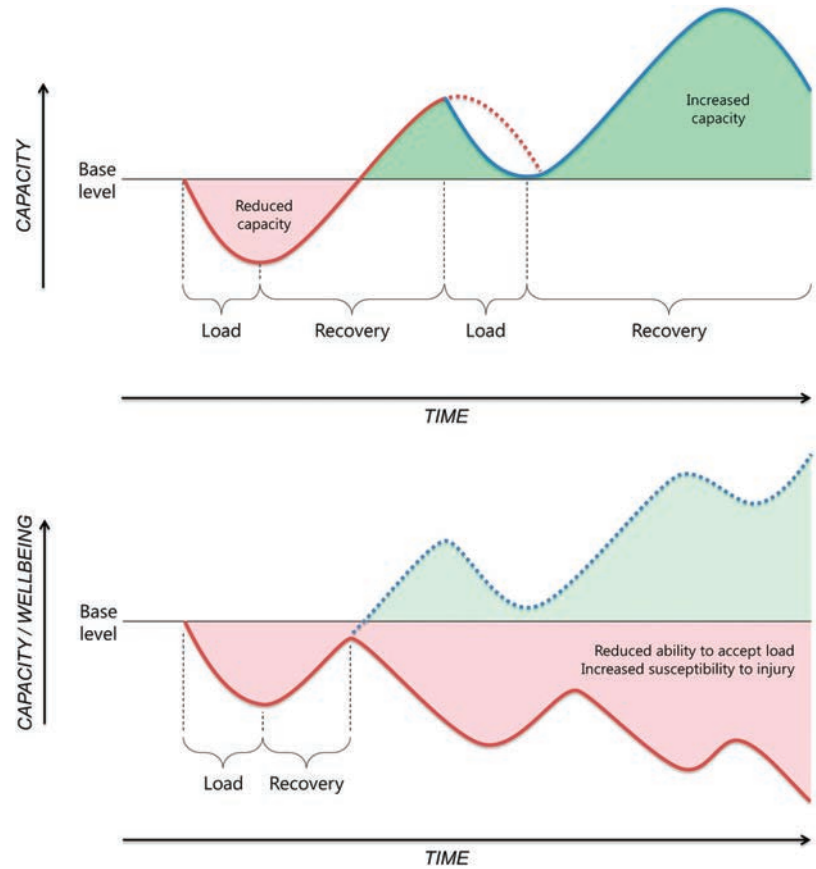

Fig. 12. Conceptual visualization of training frequencies that either increase (top) or decrease (bottom) fitness. Top, A stimulus (load) transiently decreases strength (reduced capacity). Adequate recovery time allows for adaptation and increased capacity. The subsequent load transiently decreases capacity; however, this capacity is still above the original capacity level. The related adaptive response further increases capacity. This sequence of training events enhances fitness. Bottom, When consecutive stimuli are administered too frequently, there is insufficient time for recovery and adaptation. Consequently, the second stimulus is applied to compromised (reduced capacity) tissue. The result is even further damage and further reduced capacity. This sequence of training events promotes injury. From Soligard T, Schwellnus M, Alonso J-M, et al. How much is too much? (Part 1) International Olympic Committee consensus statement on load in sport and risk of injury. *Br J Sports Med* 2016;50:1030–1041. With permission from *Br J Sports Med*.

can have a large effect on risk for skeletal injury.[30] Other strategies include managing the intensity of the activity (e.g., height of jump).

The second key to managing the rate of damage accumulation is to manage the rate of loading, that is, the number of repetitions of an activity (e.g., strides, jumps, piaffes, cattle worked, etc.) over time. Each loading event incurs some level of bone damage, with the severity of damage related to the magnitude of loading. The rate of loading-produced damage must be less than the rate of repair. And the bone must be allowed to recover, that is, repair the damage and adapt. Further, stimulation of adaptation by gradual increased or altered loads will enhance resistance to damage accumulation.

Training – Adaptation or Injury

Skeletal adaptation occurs through a biological response to a stimulus created by a load that exceeded the level or intensity of recent load events. The stimulus causes some level of damage that transiently weakens the skeletal structure or material.[4] When the damage is nondestructive and further is allowed to repair, the skeleton will respond to the stimulus by adapting to become stronger and more resistant to damage with a repeated bout of the same load. Training ideally produces a subsequent stimulus of slightly greater magnitude after tissue adaptation peaks. Over time, the athlete increases in fitness and achieves optimal performance without injury (Fig 12).[31]

When the loading bouts are too frequent, recovery (repair of damaged tissue) is not achieved. Subsequent loading bouts further weaken compromised tissue by incurring additional damage, which is magnified by the imposition of a stimulus on already weakened tissue.

Monitoring Injury Risk Through Changes in Training Intensity

Insight into the influence of training on propensity for adaptation or injury can be further attained from human sport.[31] A common approach to assessing risk for injury is to examine the acute:chronic workload

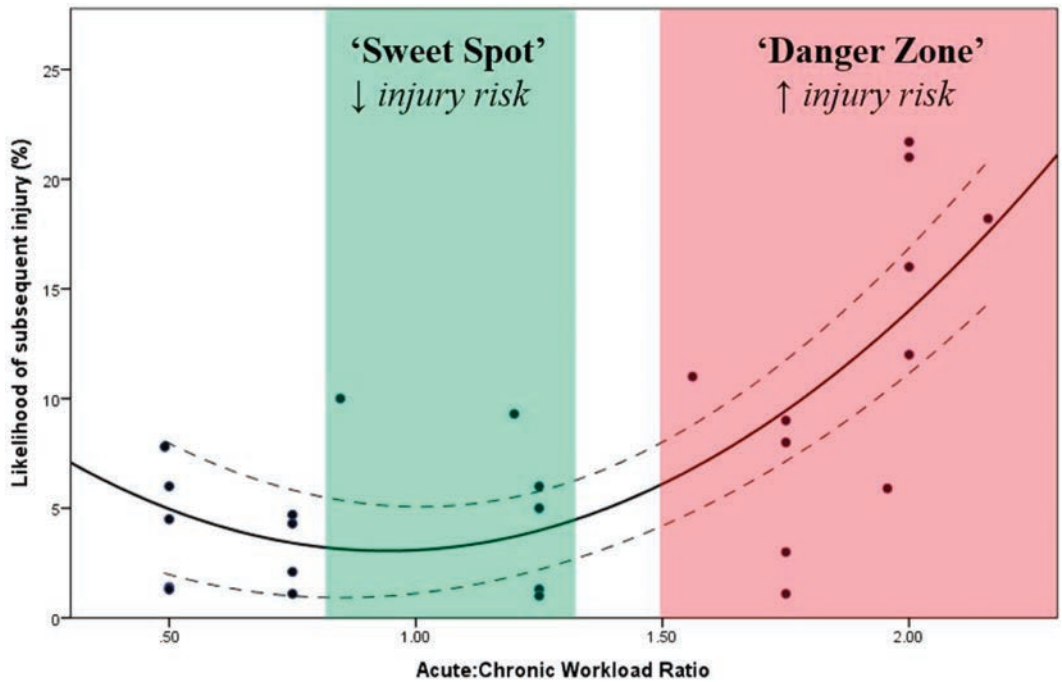

Fig. 13. Risk for injury associated with the ratio of acute and chronic workloads. From Windt J, Gabbett TJ. How do training and competition workloads relate to injury? The workload-injury aetiology model. *Br J Sports Med* 2017;51:428–435. With permission from *Br J Sports Med*.

Chronic workload (% of normal average)								
	110	4.7	4.1	3.6	3.4	3.2	3.3	3.5
	100	4.3	3.7	3.4	3.3	3.3	3.6	4.0
	90	3.9	3.5	3.3	3.3	3.6	4.2	4.9
	80	3.5	3.3	3.3	3.7	4.3	5.3	6.6
	70	3.3	3.3	3.7	4.6	5.8	7.5	9.5
	60	3.3	3.8	4.9	6.6	8.8	11.6	14.9
	50	4.0	5.5	7.9	11.0	14.9	19.6	25.1
	40	6.6	10.1	14.9	20.9	28.2	36.7	46.5
	30	14.9	23.2	33.7	46.5	61.4	78.6	98.0
		60	70	80	90	100	110	120
		Acute workload (% of normal average)						

For example, if an athlete returned to sport and had a normal 100% loading week (acute workload) but if over the past 4 weeks due to the rehabilitation of their injury had only averaged 40% of their normal load (chronic workload), we could expect the likelihood of suffering an injury in the following week to be 28%.

Fig. 14. Likelihood of suffering an injury with known acute and chronic workloads. From Blanch P, Gabbett TJ. Has the athlete trained enough to return to play safely? The acute:chronic workload ratio permits clinicians to quantify a player's risk of subsequent injury. *Br J Sports Med* 2016;50:471–475. With permission from *Br J Sports Med*.

ratio.[32] While periods of time vary among studies, acute workload is typically quantified over the previous week, and chronic workload is typically quantified over a month. Conceptually, the acute workload is thought to represent "fatigue" from recent events, and the chronic workload is a reflection of "fitness."[31] If the acute:chronic workload ratio is low, the athlete is considered fit for the recent activity. If the acute:chronic workload ratio is high, the athlete has had a recent increase in workload or intensity of training. A high acute:chronic workload ratio has been associated with higher risk of injury than a low ratio. However, the "U"-shaped relationship between workload and injury demonstrates that both inadequate and excessive workloads are associated with injury (Fig. 13).[33]

High-Risk Times for Injury

Three general causes of injury typically occur in 3 respective high-risk periods for injury. Injuries related to insufficient conditioning to increasing levels of exercise occur *early in the course of training and competition*. The rate of increasing level of training exceeds the rate that the skeleton can model and adapt to sustain the increasing loads without injury. In racehorses, humeral, scapular, and tibial stress-fracture-related complete fractures commonly occur early in a racehorse's career[34–36] and are consistent with injury after a high increase in training load observed in human athletes.[37]

Insufficient conditioning may also play a role on injury risk *after return to training after layup* and rehabilitation.[38–40] If an athlete returned to their previous level of training after reducing their workload during rehabilitation, their risk for injury would increase because of the rapid rise in workload after deconditioning during rehabilitation (Fig. 14).[38–40] Horses that sustain a stress-fracture-related complete humeral fracture commonly incur this fracture within 10 to 21 days following a return from layup.[41] It is important that the physical capacity of the athlete is maintained during rehabilitation.[40]

At the other end of the spectrum, injuries can occur from excessive workloads (Fig. 12). Injuries due to overtraining occur *later in a horse's career*. In racehorses, fetlock proximal sesamoid bone injuries

commonly occur in older horses undergoing continuous high-intensity training.[42,43]

In summary, understanding the biological concepts that underpin skeletal adaptation and responses to injury are useful in informing the training and competition of horses to yield optimized performance with low injury risk. For sport horse industries, consideration should be given to competition schedules relative to the number of horses available for competition to allow horses to train and compete at a level that allows for recovery and adaptation after events. For horses with injuries, consideration should be given to the activities during rehabilitation and their influence on deconditioning and reconditioning of skeletal structures relative to the cardiovascular, respiratory, and muscular systems.

Acknowledgments

Declaration of Ethics

The Author has adhered to the Principles of Veterinary Medical Ethics of the AVMA.

Conflict of Interest

The Author has no conflicts of interest.

References and Footnote

1. Palmer S, Gomez AMM, Mohammed HO. Attrition of Thoroughbred and Standardbred racehorses at New York Racetracks due to exercise and non-exercise related fatalities during the 2016-2019 racing seasons. *J Equine Vet Sci* 2021; 104:103703.
2. Rossdale PD, Hopes R, Digby NJ, et al. Epidemiological study of wastage among racehorses 1982 and 1983. *Vet Rec* 1985;116:66–69.
3. Hernandez J, Hawkins DL. Training failure among yearling horses. *Am J Vet Res* 2001;62:1418–1422.
4. Seref-Ferlengez Z, Basta-Pljakic J, Kennedy OD, et al. Structural and mechanical repair of diffuse damage in cortical bone in vivo. *J Bone Miner Res* 2014;29:2537–2544.
5. Cardoso L, Herman BC, Verborgt O, et al. Osteocyte apoptosis controls activation of intracortical resorption in response to bone fatigue. *J Bone Miner Res* 2009;24:597–605.
6. Rubin CT, Lanyon LE. Kappa Delta Award paper. Osteoregulatory nature of mechanical stimuli: Function as a determinant for adaptive remodeling in bone. *J Orthop Res* 1987; 5:300–310.
7. Nunamaker DN, Butterweck DM, Provost MT. Fatigue fractures in Thoroughbred racehorses: Relationships with age, peak bone strain, and training. *J Orthop Res* 1990;8:604–611.
8. Gray SN, Spriet M, Garcia TC, et al. Preexisting lesions associated with complete diaphyseal fractures of the third metacarpal bone in 12 Thoroughbred racehorses. *J Vet Diagn Invest* 2017;29:437–441.
9. Verborgt O, Gibson GJ, Schaffler MB. Loss of osteocyte integrity in association with microdamage and bone remodeling after fatigue in vivo. *J Bone Miner Res* 2000;15:60–67.
10. Mori S, Burr DB. Increased intracortical remodeling following fatigue damage. *Bone* 1993;14:103–109.
11. Martig S, Chen W, Lee PV, et al. Bone fatigue and its implications for injuries in racehorses. *Equine Vet J* 2014;46:408–415.
12. Entwistle RC, Sammons SC, Bigley RF, et al. Material properties are related to stress fracture callus and porosity of cortical bone tissue at affected and unaffected sites. *J Orthop Res* 2009;27:1272–1279.
13. Gibson VA, Stover SM, Gibeling JC, et al. Osteonal effects on elastic modulus and fatigue life in equine bone. *J Biomech* 2006;39:217–225.
14. Hiller LP, Stover SM, Gibson VA, et al. Osteon pullout in the equine third metacarpal bone: Effects of ex vivo fatigue. *J Orthop Res* 2003;21:481–488.
15. Martig S, Lee PV, Anderson GA, et al. Compressive fatigue life of subchondral bone of the metacarpal condyle in Thoroughbred racehorses. *Bone* 2013;57:392–398.
16. Martig S, Hitchens PL, Lee PVS, et al. The relationship between microstructure, stiffness and compressive fatigue life of equine subchondral bone. *J Mech Behav Biomed Mater* 2020;101: 103439.
17. Bani Hassan E, Mirams M, Ghasem-Zadeh A, et al. Role of subchondral bone remodelling in collapse of the articular surface of Thoroughbred racehorses with palmar osteochondral disease. *Equine Vet J* 2016;48:228–233.
18. Burr DB, Radin EL. Microfractures and microcracks in subchondral bone: Are they relevant to osteoarthrosis? *Rheum Dis Clin North Am* 2003;29:675–685.
19. Lacourt M, Gao C, Li A, et al. Relationship between cartilage and subchondral bone lesions in repetitive impact trauma-induced equine osteoarthritis. *Osteoarthritis Cartilage* 2012;20:572–583.
20. Burr DB, Schaffler MB. The involvement of subchondral mineralized tissues in osteoarthrosis: Quantitative microscopic evidence. *Microsc Res Tech* 1997;37:343–357.
21. Shaffer SK, To C, Garcia TC, et al. Subchondral focal osteopenia associated with proximal sesamoid bone fracture in Thoroughbred racehorses. *Equine Vet J* 2021;53:294–305.
22. Martin RB, Stover SM, Gibson VA, et al. In vitro fatigue behavior of the equine third metacarpus: Remodeling and microcrack damage analysis. *J Orthop Res* 1996;14:794–801.
23. Gibson VA, Stover SM, Martin RB, et al. Fatigue behavior of the equine third metacarpus: Mechanical property analysis. *J Orthop Res* 1995;13:861–868.
24. Kane AJ, Stover SM, Gardner IA, et al. Hoof size, shape, and balance as possible risk factors for catastrophic musculoskeletal injury of Thoroughbred racehorses. *Am J Vet Res* 1998;59:1545–1552.
25. Kane AJ, Stover SM, Gardner IA, et al. Horseshoe characteristics as possible risk factors for fatal musculoskeletal injury of Thoroughbred racehorses. *Am J Vet Res* 1996;57: 1147–1152.
26. Setterbo JJ, Fyhrie PB, Hubbard M, et al. Dynamic properties of a dirt and a synthetic equine racetrack surface measured by a track-testing device. *Equine Vet J* 2013;45:25–30.
27. Tranquille CA, Walker VA, Hernlund E, et al. Effect of superficial harrowing on surface properties of sand with rubber and waxed-sand with fibre riding arena surfaces: A preliminary study. *Vet J* 2015;203:59–64.
28. Hernlund E, Egenvall A, Hobbs SJ, et al. Comparing subjective and objective evaluation of show jumping competition and warm-up arena surfaces. *Vet J* 2017;227:49–57.
29. Setterbo JJ, Garcia TC, Campbell IP, et al. Hoof accelerations and ground reaction forces of Thoroughbred racehorses measured on dirt, synthetic, and turf track surfaces. *Am J Vet Res* 2009;70:1220–1229.
30. Parkin TD. Equine injury database. The Jockey Club. 2022. Available from: https://jockeyclub.com/default.asp?section=Advocacy&area=10.
31. Soligard T, Schwellnus M, Alonso JM, et al. How much is too much? (Part 1) International Olympic Committee consensus statement on load in sport and risk of injury. *Br J Sports Med* 2016;50:1030–1041.
32. Andrade R, Wik EH, Rebelo-Marques A, et al. Is the acute: Chronic workload ratio (ACWR) associated with risk of time-loss injury in professional team sports? A systematic review of methodology, variables and injury risk in practical situations. *Sports Med* 2020;50:1613–1635.
33. Gabbett TJ. The training-injury prevention paradox: Should athletes be training smarter and harder? *Br J Sports Med* 2016;50:273–280.

34. Samol MA, Uzal FA, Hill AE, et al. Characteristics of complete tibial fractures in California racehorses. *Equine Vet J* 2021;53:911–922.
35. Vallance SA, Entwistle RC, Hitchens PL, et al. Case-control study of high-speed exercise history of Thoroughbred and Quarter Horse racehorses that died related to a complete scapular fracture. *Equine Vet J* 2013;45:284–292.
36. Stover SM, Johnson BJ, Daft BM, et al. An association between complete and incomplete stress fractures of the humerus in racehorses. *Equine Vet J* 1992;24:260–263.
37. Windt J, Gabbett TJ. How do training and competition workloads relate to injury? The workload-injury aetiology model. *Br J Sports Med* 2017;51:428–435.
38. Blanch P, Gabbett TJ. Has the athlete trained enough to return to play safely? The acute: Chronic workload ratio permits clinicians to quantify a player's risk of subsequent injury. *Br J Sports Med* 2016;50:471–475.
39. Gabbett TJ. The training-performance puzzle: How can the past inform future training directions? *J Athl Train* 2020; 55:874–884.
40. Gabbett TJ. How much? How fast? How soon? Three simple concepts for progressing training loads to minimize injury risk and enhance performance. *J Orthop Sports Phys Ther* 2020;50:570–573.
41. Carrier TK, Estberg L, Stover SM, et al. Association between long periods without high-speed workouts and risk of complete humeral or pelvic fracture in thoroughbred racehorses: 54 cases (1991–1994). *J Am Vet Med Assoc* 1998; 212:1582–1587.
42. Anthenill LA, Stover SM, Gardner IA, et al. Risk factors for proximal sesamoid bone fractures associated with exercise history and horseshoe characteristics in Thoroughbred racehorses. *Am J Vet Res* 2007;68:760–771.
43. Cresswell EN, Ruspi BD, Wollman CW, et al. Determination of correlation of proximal sesamoid bone osteoarthritis with high-speed furlong exercise and catastrophic sesamoid bone fracture in Thoroughbred racehorses. *Am J Vet Res* 2021;82:467–477.

[a]Arthur RM. (Personal communication) 2012.

Accounts Receivable – Culture, Process, and Impact

Robert P. Magnus, DVM, MBA

Accounts receivable (AR) management is not difficult if everyone is aligned with the processes and policies of the business. Taking a proactive approach with accounts will improve cash flow and the overall financial health of the practice. Take the time to make AR a priority throughout the practice with all employees and stakeholders. No one likes to work for free or chase after outstanding AR from the hard work of the staff and doctors. Author's address: 1025 N Morgan Road, Oconomowoc, WI 53066; e-mail: bmagnus@OculusInsights.net. © 2022 AAEP.

1. Introduction

One of the key drivers for a sustainable practice is healthy (low) accounts receivable (AR). The business may be growing at incredible rates, yet if the AR is too high, cash is not accessible. Available cash directly affects the ability to proactively move the practice forward by investing in staff and new opportunities. Cash flow impacts the ability to pay bills, repair and buy new equipment, hire a new associate and staff, and can significantly hamper profitability if AR is poorly managed. This presentation will delve into the cashflow implications of accounts receivable using case examples and sharing dashboard ideas and metrics like average days AR to help fine-tune this important operational item. The presentation details, case examples, and sample tools in the slide deck will be provided after the presentation.

2. Discussion

The importance of AR is obvious, and yet why do many practices struggle? The answer is straightforward and takes effort: the business needs the right processes in place, a positive culture, and all staff including the doctors aligned to be successful. In this program the invoicing process, timing on billing, payment terms (the good, the bad, the ugly), and setting AR policies will be presented in case report format. The impact of well-managed AR can be significant on many fronts.

3. Practice Culture

A look at practice culture is another important factor when invoices are not paid. Culture refers to the beliefs and behaviors that determine how a company's employees and management interact and handle outside business transactions like outstanding invoices. Often, a practice culture is implied, not expressly defined, and develops organically over time from the cumulative traits of the people the company hires. Successful practices develop their culture among a shared group of core values that guides behavior. If everyone is not on board with process and policies, the outcome will be less than ideal. Yes, just one person

NOTES

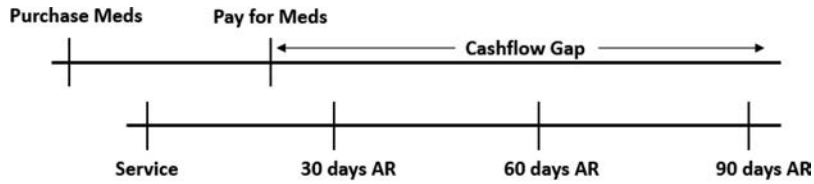

Fig. 1. Cashflow Gap.

$$\text{Average Days AR per Month} = \frac{\text{Average Month AR (EOM AR/12)}}{\text{Average Daily Sales (Revenue / 365)}}$$

Fig. 2. Average Days Accounts Receivable Formula. *EOM mean (End of Month).

who is not aligned can be devastating to the practice cash flow and culture.

4. Cash Flow

Whether keeping up with pharmaceutical bills or making the months payroll are struggles, understanding how AR relates to cash in the bank and the timing of invoices are important concepts. If a gap develops meaning bills are due and there is no cash, often AR is the problem. In essence if practices/practitioners have to pay for medications before receiving money for using those medications (client invoices) it is hard to keep up with those bills and others in the practice. A cash flow gap (Fig. 1) will be reviewed in case presentations.

5. Keeping Score

Monitoring the business proactively is very important. The key is the word "proactive." This is done with defining metrics and key performance indicators (KPIs) that help tell a story about AR. One of the best metrics is a measure called Average Days AR. When calculated monthly it provides a very quick snapshot of the practice. This KPI measures how many days it takes on average to receive money beginning from the day the service was provided. The calculation is in Fig. 2 For example, if payment terms for clients are net 30 days, KPI should never be above 30 days. Creating a custom AR dashboard (example in Fig. 3) that is monitored monthly will illustrate if AR policies are effective. The result of proactive monitoring is an increase in cash flow and more.

6. Impact

Finally, how does a poorly managed (low) AR impact the business? The lack of cash is obvious,

AR MONTHLY DASHBOARD

Sample Practice — **2021**

Annual Sale Estimate @ ___% Growth **$1,650,000**

Month	Gross Sales	Average Days AR	Total Dollars 61+ Days AR	TOTAL AR	Average Day Sales	*Est*. % of +61 Annual Sales	% of Monthly Sales
Target		<12 Days	<$10,000	< $60,000	$6,000	<0.4%	< 6.0%
January	$105,000	24.0	$7,968	$81,225	$3,387	0.48%	7.59%
February	$166,000	12.0	$13,947	$68,634	$5,724	0.85%	8.40%
March	$99,000	27.2	$13,111	$86,826	$3,194	0.79%	13.24%
April	$145,000	14.4	$13,672	$67,489	$4,677	0.83%	9.43%
May	$205,000	10.3	$21,726	$68,180	$6,613	1.32%	10.60%
June	$180,000	12.9	$16,522	$77,510	$6,000	1.00%	9.18%
July	$178,000	13.9	$14,998	$79,836	$5,742	0.91%	8.43%
August	$104,000	24.7	$16,008	$82,890	$3,355	0.97%	15.39%
September	$234,000	7.2	$14,167	$56,412	$7,800	0.86%	6.05%
October	$170,000	11.0	$14,764	$60,193	$5,484	0.89%	8.68%
November	$111,000	19.5	$13,763	$72,141	$3,700	0.83%	12.40%
December	$88,000	15.9	$13,585	$45,089	$2,839	0.82%	15.44%
Running Total	**$1,785,000**						
AVERAGE	**$148,750**	**16.1**	**$14,519**	**$70,535**	**$4,876**	**0.88%**	**10.40%**

ANNUAL TRENDS	2021	2020	2019	2018
MONTHLY AVERAGE AR	$70,535	$76,073	$98,766	$104,965
MONTHLY AVER. +61 DAYS	$14,519	$17,161	$19,022	$20,223
AVERAGE MONTH DAYS A/R	16.1	18.1	24.1	31.3

Fig. 3. Sample AR Dashboard.

but what is the impact on the value of the business, or how would an investor, potential new partner, or banker view the practice financial health? The program will conclude with examples of both well managed and poorly managed AR and how this affects practice value in addition to improving cash from one year to the next.

Acknowledgments

Declaration of Ethics

The Author has adhered to the Principles of Veterinary Medical Ethics of the AVMA.

Conflict of Interest

Dr. Magnus DVM, MBA owns the business consulting firm Oculus Insights, LLP and is a paid consultant for numerous equine practices, private equity investors, and animal health industry companies. He provides business tools and support for the global equine veterinary industry. Dr. Magnus has no conflicts of interest in this presentation.

How Practices Can Reduce Accounts Receivable by Moving to Payment at the Time of Service

Wendy Krebs, DVM

Author's address: Bend Equine Medical Center, 19121 Couch Market Road, Bend OR 97703; e-mail: wendykrebsdvm@bendequine.com. © 2022 AAEP.

1. Introduction

Most veterinarians bring to the table a healthy sense of responsibility for their patients, a strong desire to heal them regardless of finances, and no particular love of difficult financial discussions with clients. On the other hand, veterinarians also have amazing teams, from associate vets to support staff, that absolutely deserve to be well compensated and probably do not want to wait 90 days for that compensation. In fact, with the veterinarian and veterinary support staff wage increases the profession has seen over the last year and a half (which are well deserved), and a paucity of equine veterinarians coming down the pipeline, it is critical to have healthy cash flow to compensate them or there will ultimately not be staff to run the hospitals.

One of the most important tenets of healthy cash flow is a healthy and low accounts receivable (A/R). An important metric that allows scaling of A/R is the days sales outstanding, or DSO. This essentially means how many of a practice's days of production are tied up at any given time as unpaid A/R.

Many practices have DSOs well in excess of 30 days, especially if they have traditionally not operated on a payment at time of service model. This has the following concerning implications for cash flow and business:

1. Hospitals with high DSO numbers are paying staff well before the client pays the hospital. If veterinarians are compensated on paid invoices only, they may be waiting a long time to be paid as well. That is likely to be a source of discontent, especially if it is essentially the practice's fault that invoices are not being promptly collected on. This cash flow pinch may severely impact a practice's ability to make facility improvements, purchase new equipment, etc.
2. Practices may be paying their vendors for products prior to the client paying them. In a perfect world, a hospital will have negotiated terms with vendors that allow them to collect from clients before the invoice comes due with the vendor. This falls under the smart business concept of "using other peoples' money," which is the opposite of letting the clients use a hospital's money free of charge!
3. The longer invoices are outstanding, the lower the chances they will ever be paid in full. Anything over 90 days is at significantly greater risk of default; Marsha Heinke estimates collection probability at 65% to 80%.[1]
4. If partners are contemplating the sale of a practice at any point in the next few years, at the time of the practice's sale, the A/R balance (especially anything over 90 days) may not be paid out fully to the seller, meaning partners

NOTES

could be leaving a great deal of money on the table that really should have already been safely in their bank account.

2. Solutions

A practice acknowledges that their A/R could be healthier and recognizes it is important to improve it for the health of the practice. But where do managers even start on the process of improving it? First, managers should know the practice's A/R metrics and start to evaluate and monitor them frequently and regularly. Awareness of the practice's average A/R balance is a good place to start, but it can be too easy to excuse an A/R that has suddenly ballooned since the practice had "such a busy month last month." Managers should hold themselves more accountable, ideally, by taking the extra step of determining their current DSO and watching it carefully.

DSO is easy to calculate. For any given period—for example, the year—take the A/R at the beginning of the period and the end of the period and average them. Take that average A/R × 365 days and then divide by total gross income during that period. For example, if a clinic started 2022 off with $93,000 in A/R and ended the year with $74,000, the average A/R for the year was $83,500. Multiply $83,500 × 365 days = $30,477,500 and then divide by the practice's gross income for the year, e.g., $4,000,000. Your DSO is 7.5 days.

A key step in reducing DSO is to bill at the time of service rather than at the end of the month. How can a manager transform a practice from an end of the month billing paradigm to payment at the time of service? Remember this is a process, and not an overnight one, especially if a practice has successfully trained their clients over the course of decades that they can pay whenever they please. One way is to start with new clients, and as the practice gets more comfortable with this, it becomes easier and just part of the routine.

1. First, and most important, get the practice team and veterinarians on board by educating them on the importance of the change, and set DSO goals—maybe even with rewards for the team when they are reached.
2. Work with the practice's support staff to establish clear expectations of clients that are communicated and acknowledged in writing in advance of care. Ask every new client to put a credit card on file; they will be sent a payment agreement that must be completed prior to any services being provided. The agreement should allow the practice to charge that credit card upon completion of services or after a quick verification with the client with a total before it is processed. Note that this will require that the practice have a system compliant with payment card industry standards for saving the credit card to avoid liability for fraud. Ideally, staff members should not have access to the card number itself but just have a portal that allows them to identify the card by the last four numbers and run it with the client's permission. Portraying this to clients as a convenience and time saver for them generally is well received, and many of them seem to love to tell us to "just put it on the card." Some large farms or accounts may not wish to do this, but if 80% of clients can be put on this system, the improvement in cash flow and time an A/R team will save will be remarkable!
3. Develop accurate and comprehensive estimate templates for all commonly performed procedures or conditions that require hospitalization and require the low end of the estimate as a deposit. Require that hospitalized patient invoices be paid every 48 hours so they do not grow and grow and surprise clients, and require that the full balance be paid at the time the animal goes home. Some clients become a lot less understanding and appreciative of the work that went into a $2500 colic hospitalization bill 30 days after the fact. This may require dedicating more staff to keep invoices updated so that they are ready at the time of discharge or use of an electronic whiteboard that makes invoicing more automated and accurate.
4. Make invoicing quick for the doctor/assistant team by using bundles or therapeutic packages in a practice's software such that a commonly performed procedure can be invoiced out in 2 minutes. If veterinarians or staff are not creating invoices for clients until the end of the month, every other measure becomes a moot point. And what are the odds they are going to remember the three extra tubes of banamine and 28 tubes of GastroGard they passed out at the end of a farm call to Mr. Smith a month ago?
5. Completely eliminate or greatly tighten up the practice's internal payment plans. Very few veterinarians make good bankers. Instead, have actual banks do the banking. CareCredit and Scratch Pay are two of many banks that would love to take over that A/R and know how to do it. Yes, they charge the practice a little more than a regular credit card, but increase fees enough to cover that and move on.

3. Discussion

Recruitment of equine veterinarians has increasingly become a challenge in part because of the comparatively low compensation the equine field offers

compared to small animal veterinary practice. A key factor in improving practices' profitability and ability to appropriately compensate their veterinarians is reducing A/R. When managers get weak in the knees, they should remind themselves that almost no small animal veterinarians allow any sort of billing and in fact think equine practitioners are resistant in this respect. Or they should consider their dentist, who is likely excellent at getting a signed estimate for any work they propose for patients and certainly does not let them walk out the door without payment of the estimated after insurance responsibility. More attention paid to good business practices will ultimately improve the sustainability of equine practice.

Acknowledgments

Declaration of Ethics

The Author has adhered to the Principles of Veterinary Medical Ethics of the AVMA.

Conflict of Interest

The Author has served as a paid consultant for Synchrony Financial/CareCredit.

Reference

1. Heinke M, McCarthy J. *Practice made perfect: A complete guide to veterinary practice management 2nd ed*. Lakewood: AAHA Press, 2001.

How to Decrease Accounts Receivable in an Ambulatory Practice

Linda Hagerman, DVM

Providing an outstanding medical service to clients is often not the most difficult challenge equine practitioners face. Providing a prosperous career for ourselves and our employees is of paramount importance for survival and therefore our patients. Collecting payment at time of service and having a low accounts receivable is just one of the many ways to ensure this. Author's address: Tacoma Equine Hospital, 3112 156th Street E, Tacoma, WA 98446-1522; e-mail: drlinda@tacomaequine.com. © 2022 AAEP.

1. Introduction

Equine veterinary practice is highly rewarding, but it is not an easy career and equine ambulatory practice can be a hard way to make a living. Managing the business while juggling the challenges of daily appointments in addition to emergencies is difficult. Consequently, the overall success of any practice is sometimes determined more by business skills than veterinary skills. This paper will discuss some processes that may help facilitate collecting money at time of service and therefore keeping accounts receivable low.

2. Materials and Methods

Develop a Culture of Collection

It's important to develop the culture of collecting payment at time of service early in your career. This is a philosophy that should be in place at the start of your business. Both solo practitioners and group practices can establish this culture. Young veterinarians, due to their high debt load, are often better at thinking about being paid, so harness their motivation and that energy. In a group practice, foster a team approach by talking about accounts receivable and strategizing easy ways to get paid, but have one person leading the collections strategy.

Take Time to Work on Your Business

It's hard to say no to a horse in need, and sometimes you won't be able to, but taking time to develop and maintain your business and carry out an accounts receivable strategy should also be treated as an emergency. Set aside a day to work on the business (i.e., no appointments). Set that expectation with yourself and your clients.

Manage Expectations

During the appointment scheduling call or text, have the receptionist give the client an estimate and get a verbal approval that the estimate is agreed to. During the appointment, keep the client informed of the charges, and when recommending other treatments, make sure they know how that will affect the bill and get verbal approval to continue.

NOTES

Logistics

- Have the statement billing period from the previous 16th to the current 15th of the month. When clients pay their bills near the end of the month, your practice's statement is sitting there waiting.
- Offer Care Credit, cash, debit/credit card options, as well as PayPal and other online options.
- Be prepared to text or call clients who owe money relentlessly (in some areas, it's legal to contact clients in arrears once per day).
- Go to small claims court or send clients to a collection agent if they don't pay. The news will travel that your practice expects to get paid and this will naturally, eventually, weed out those who don't intend to pay.
- The COVID touchless protocol has made getting credit cards on file the norm for people, so take advantage of this.
- Use card readers in the field to get credit or debit card payments.
- Do not accept checks from first-time clients.
- Do payment plans only for clients who have established credit with the business, half down and half in 2 weeks, and have them sign a legal document promising to pay with the terms specifically outlined. Follow up with small claims court if they don't fulfill their promise to pay.
- Some clients will send a small amount of money to put on their account every month and then schedule their services when they have accumulated enough.

Be Selective

Say no or be especially suspicious about a new client calling with an emergency that has you driving past 2 or 3 other veterinarians.

Be Known as "Expensive"

Clients expect to pay "a lot" when they see you and are often overprepared for their bill, even though in reality it's not much more than other clinics. The reputation has created the value.

Get Business Consulting Help

Join a Veterinary Management Group (VMG) group or hire a private equine veterinary consulting firm to help analyze your practice, keep you engaged with the process of bettering the business, hold you accountable to work on the practice, and give you different ideas of how to do business.

3. Results

At this stage, performance can be measured and you have a way to periodically monitor it for continuous improvement. One easy calculation is that accounts receivable total should be less than 9% of revenue. Another is to know the days outstanding or the days to collection number that your practice has and challenge yourself to get it as low as possible. The formula for that is as follows:

Amount of accounts receivable (A/R) at the beginning of the period + Amount of A/R at the end of the period/2 = Average A/R. Take Total Sales divided by Average A/R = % of A/R to sales. Take that percent × 365 = Days outstanding or days to collection.

4. Discussion

Veterinarians have been trained to excel in medicine but not as well in business. Decreasing accounts receivable by collecting payment at time of service and having a low A/R will create a profitable practice that offers good work/life balance.

Acknowledgments

Many heartfelt thanks to my employees who not only make it easy to operate my practice but are the reason for my success.

Declaration of Ethics

The Author has adhered to the principles of veterinary medical ethics of the AVMA.

Conflict of Interest

The Author has no conflicts of interest.

Why Employees Quit: Psychological Safety is Key for Reducing Turnover and Improving the Bottom Line

Stacey Cordivano, DVM

Creating a psychologically safe workplace has a direct correlation to employee engagement and innovation by enhancing team performance. Increasing interpersonal risk-taking within your veterinary team will improve your bottom line by decreasing staff turnover and increasing staff productivity.
Author's address: Clay Creek Equine Veterinary Services, LLC, 415 Spring Mill Road, Chadds Ford, PA 19317; e-mail: claycreekequine@gmail.com. © 2022 AAEP.

1. Introduction

As the equine veterinary industry faces unprecedented rates of attrition, in combination with an historically low entrance rate of veterinarians into the field, practice owners' focus must be on retaining current employees. Studies have shown psychological safety within the workplace to be one of the most important factors leading to team effectiveness, learning behaviors, and employee satisfaction in organizations where knowledge work is required.[1,2] Additionally, the presence of psychological safety within an organization can clearly be correlated with company performance.[3] The objectives of this discussion are to introduce the idea of psychological safety to veterinary professionals, provide evidence that including psychological safety within a workplace will help decrease staff turnover and increase staff productivity, and introduce methods to implement this idea in a veterinary organization.

2. Solution

Psychological Safety: What It Is and What It Is Not

Psychological safety is defined as the belief that the work environment is safe for interpersonal risk taking.[1] It has also been explained in the following way: "Psychological safety is a condition in which you feel (a) included, (b) safe to learn, (c) safe to contribute, and (d) safe to challenge the status quo - all without fear of being embarrassed, marginalized or punished in some way."[4] Globally, studies have shown that only 47% of all employees feel that their workplaces are psychologically safe.[5]

A work climate where candor is allowed and expected, mistakes are forgiven, asking for help is not seen as a weakness, and questioning current norms can occur without fear is the basis for a psychologically safe environment. Once this culture has been established, team members often begin to feel more engaged, innovative, and productive. It should also be noted that creating this environment is an active

NOTES

process, not a set-it-and-forget-it task. The effort to make an organization safer must be championed by the leadership team. Owners and managers who are able to be vulnerable enough to display these behaviors are imperative to creating a workplace culture that actually adopts the ideas of psychological safety.

The term psychological safety may sound soft. It is far from that. Organizational psychologist Adam Grant describes it this way, "What you're aiming for on a team, is a commitment to high standards and the psychological safety to be candid with each other as you try to achieve them."[6] It does not mean that people need to be nice all of the time. It is not about putting all of your trust in one key person. It is not about decreasing the standards to which you hold your employees. In fact, once team safety has been established, the opposite is true of most of these myths. Instead of walking lightly around someone's feelings, when there is an atmosphere of established psychological safety, candid discussions can be held more easily. Once the team has developed a safety net that does not rely on a single person or specific instance, performance goals can increase for everyone. When expectations are not met, the environment of mutual respect and vulnerability allows for frank discussions about how to improve performance. Mistakes and failures are also reported sooner, allowing for earlier correction or intervention. According to Dr. Amy Edmondson, a pioneer in this field, "psychological safety sets the stage for a more honest, more challenging, more collaborative, and thus also more effective work environment."[7]

3. Discussion

The practice of veterinary medicine is certainly the type of environment where learning and collaboration are required for success. Veterinary clinics also definitively fall under the category of VUCA; this is what Dr. Edmonson calls a company that confronts volatility, uncertainty, complexity, and ambiguity. She has proven that psychological safety is directly tied to the bottom line of any VUCA organization due to the fact that "employee observations, questions, ideas and concerns can provide vital information about what is going on - in the market and in the organization."[7]

It is not a difficult jump to make the assumption that employees who are more engaged are of more benefit to an organization. This idea has been well-studied in human healthcare in relation to costs and medical errors. "Disengaged employees lead to safety risks and staff turnover. Turnover means higher recruiting and training costs, as well as a high percentage of less experienced workers on staff."[7]

Staff turnover costs contribute to a significant decrease in overall profitability for veterinary practices. According to Gallup, the annual turnover rate for all jobs in the US in 2017 was 26.3% and the cost to replace an employee can range from 50-200% of their annual salary.[8] Veterinary practices actually have a much higher range of turnover rates, ranging from 30-50%.[9] The 2021 AVMA Economic State of the Profession Report states that 38% of veterinarians have considered and 25% are seriously considering leaving practice. Forty-seven percent of those veterinarians cite work culture as a top reason for leaving the profession.[10] A 2020 study out of the UK showed that 43.7% of veterinarians surveyed reported that they were likely or very likely to leave their employment within two years. Top reasons for their desire to leave included work-life balance, management, and salary.[11]

The data is clear in affirming that teams with high psychological safety also have higher performance measures.[1–4] "At a general level, employees who are highly engaged in their work roles not only focus their physical effort on the pursuit of role-related goals, but are also cognitively vigilant and emotionally connected to the endeavor."[12] An in-depth example of this work is a multi-year study of teams at Google, which was code-named Project Aristotle. Of all the attributes that helped explain team performance (clear goals, dependable colleagues, personally meaningful work, and a belief that your work has impact), a team was never measured to be "high performing" without the presence of psychological safety.[2] These outcomes can be explained by the fact that interpersonal safety within a team allows for increased learning, collaboration, and innovation. When psychological safety is not present, "people at work are not only failing to speak up with potentially threatening or embarrassing content, they are also withholding ideas for improvement."[7] Additionally, in healthcare-specific settings, employees who feel as though they work in a psychologically safe environment are able to support and bond with patients more easily, are able to provide better clinical outcomes, and are more easily able to learn from failure.[13]

How to Do It

Building a framework of psychological safety is the responsibility of leaders at all levels in an organization. In the context of veterinary medicine, in particular, an important place to start involves the idea of Leadership Inclusiveness. Edmondson describes three behavioral attributes of inclusive leaders: they are those who are approachable and accessible, they proactively invite insight from staff and employees, and finally, they admit their fallibility.

Designing structures that allow for input and invite participation is an important aspect of being an accessible leader in a psychologically safe organization. No longer being seen as a boss who has all of the answers, but instead, one who is looking for contributors with crucial knowledge and insight is a necessary reframe. Another important step toward approachability is to clearly outline the values of the company. If employees share these values, it is easy for them to align their purpose and contribution to the organization's values. With that, the values must have clear,

actionable behaviors that are continuously demonstrated and reinforced by leaders.

A key tool used by inclusive leaders is proactive inquiry. This is defined as "purposeful probing to learn more about an issue, citation, or person."[7] Developing a genuine interest and concern in other people's responses to a question is an imperative start to the formation of psychological safety. It is human nature to assume that one has a good sense of the organization, when in fact, the realities faced by employees are often very different than those of the management team. Cultivating team collaboration encourages a broader perspective for all. A powerful question generates deeper curiosity and invites creativity while channeling attention and forward progress.

The final characteristic of an inclusive leader is the ability to admit fallibility. By personally demonstrating vulnerability, admitting that mistakes are a part of innovation, the team is then allowed to have an open discussion regarding trials and failure. "A learning mindset, which blends humility and curiosity" diminishes the risk of being the boss who thinks they know it all.[7] By destigmatizing failure and reframing it as a way to learn and improve performance, leaders are able to show employees that the organization's values are upheld while still focusing on personal and professional improvement.

Google's re: Work platform offers a concise summary of additional ways to foster psychological safety within your team.[14] Included are veterinary examples below each idea.

1. **Demonstrate engagement**

   - During weekly team meetings, a practice owner would be fully present and focused on the team's discussion. They would ask follow-up questions, offer input, and be interactive to demonstrate that they are truly listening to any concerns that are brought up during the meeting.

"It makes total sense that you're struggling with getting Coggin's test submissions completed since we are down a team member in the lab. Instead of waiting until the end of the day to start processing the bloodwork like we've always done, perhaps you could start entering them as soon as they are dropped off by the different veterinarians."

2. **Show understanding**

   - When a problem is brought to a veterinarian's attention (owner hears from associate vet or associate vet hears from technician), the veterinarian recaps what they've just heard, validates that they understand how that issue could be causing negative feelings, and asks questions about how to help the person move forward.

"I hear that you're feeling really frustrated about Client X always calling your cell phone after hours. We have made her aware of our emergency line policy. Do you have any ideas on things we could say to her to ease the pressure she puts on you?"

3. **Be inclusive in interpersonal settings**

   - A practice owner must be available and approachable. They could make specific office hours where drop-in visits are encouraged, or they could set aside time to meet with employees individually.
   - A veterinarian could also share information about how to best communicate with them: "I do really well with email but have a hard time processing face-to-face meetings without a little bit of prep."
   - Expressing gratitude for the team's contributions is also crucial during group gatherings. Take this time to be specific and encourage others to share their wins as well.

4. **Be inclusive in decision-making**

   - A practice owner has been approached by a pharmaceutical rep with a great deal on a new vaccine product. It would require changing the practice's current protocols and reminder systems. The owner solicits input from the veterinarians about how hard the protocol change will be for them in the field and also asks the front office staff if they have time to go through the entire patient list to change the reminder statuses. The owner would then take into account the cost savings as well as the effect on all of their employees before making a final decision.

5. **Show confidence and conviction without appearing inflexible**

   - During a clinic-wide staff meeting, the practice owner and practice manager thank everyone for the effort that was made on a recent social media campaign that was launched to generate new business for the newly built hospital. They admit that while much effort went into this idea, no change has been seen in the number of referral cases over the past two months. The management reassures everyone that business is doing well but they are still pursuing other ways in which to involve the local veterinarians. Being vulnerable enough to admit that this particular social media idea was not successful leads to an opportunity for the team to

offer up new and creative ideas and also demonstrates that failure is a part of the growth process.

An Important Note for All Veterinary Medical Professionals

While the role of a veterinarian denotes a certain level of leadership within any organization, a specific individual may not always be the decision-maker. If one wishes to advance to the level of psychological safety within the organization without support from the top, there are specific actions that can be taken. Asking questions with good intention and actively listening to other people's ideas conveys respect and reinforces the idea that all members of the team are valued. Being vulnerable, interested, and available shows a willingness to take an interpersonal risk; this will demonstrate an effort to create psychological safety within the smaller group dynamic. Creating a small space of safety and excellence within the larger context of the organization will make an impact on the effectiveness of that specific subgroup.

The Enduring Work

In the veterinary workplace, where stress is high, collaboration is key, and clinical outcomes are dependent on well-functioning teams, psychological safety is crucial. Once the leadership team is active in creating this environment, focus then shifts to providing an appreciation for the rest of the team's contributions of candor and feedback. If standards of safety and inclusion are not met, clear action should be taken against those who are unwilling to contribute to the collective environment. Team leaders must continually encourage and reinforce the goal of progress, not perfection. If they can stay open to new ideas and feedback, there is no doubt that management will see the benefit of more engaged and productive employees when evaluating their financial bottom line.

Acknowledgments

Declaration of Ethics

The Author has adhered to the Principles of Veterinary Medical Ethics of the AVMA.

Conflict of Interest

The Author has no conflicts of interest.

References

1. Edmondson AC. Psychological safety and learning behavior in Work Teams. *Administrative Science Quarterly* 1999;44:350–383.
2. Google re:Work. Guide: Understand team effectiveness. Available online at: https://rework.withgoogle.com/print/guides/5721312655835136/. Accessed January 15, 2022.
3. Baer M, Frese M. Innovation is not enough: Climates for initiative and psychological safety, process innovations, and firm performance. *J Organiz Behav* 2003;24:45–68.
4. Clark TR. 2020. *The 4 Stages of Psychological Safety: Defining the Path to Inclusion and Innovation*. Oakland, CA: Berrett-Koehler Publishers, Inc.
5. Ipsos. 2012. Half (47%) of Global Employees Agree Their Workplace is Psychologically Safe and Healthy: Three in Ten (27%) Say Not. Available online at: https://www.ipsos.com/en-us/half-47-global-employees-agree-their-workplace-psychologically-safe-and-healthy-three-ten-27-say. Accessed February 15, 2022.
6. Ted. 2021. Is It Safe to Speak Up at Work? *Work Life with Adam Grant*, from TED, July 20, 2021. Available online at: https://www.ted.com/podcasts/worklife/is-it-safe-to-speak-up-at-work-transcript. Accessed March 3, 2022.
7. Edmondson AC. *The fearless organization: Creating psychological safety in the workplace for learning, innovation and growth*. Hoboken, NJ: John Wiley and Sons, Inc, 2019
8. Gallup. This Fixable Problem Costs U.S. Businesses $1 Trillion. Available online at: https://www.gallup.com/workplace/247391/fixable-problem-costs-businesses-trillion.aspx. Accessed March 1, 2022.
9. Penn Foster, Inc. The State of the Industry: Veterinary Practice Challenges and Goals in 2020. Available online at: https://partners.pennfoster.edu/blog/2020/may/veterinary-practice-challenges-and-goals-in-2020. Accessed March 1, 2022.
10. AVMA. 2021. Economic State of the Veterinary Profession. Available online at: https://ebusiness.avma.org/ProductCatalog/product.aspx?ID=2000
11. Hagen JR, Weller R, Mair TS, et al. Investigation of factors affecting recruitment and retention in the UK veterinary profession. *Vet Rec* 2020;187:354.
12. Ashforth BE, Humphrey RH. Emotion in the workplace: A reappraisal. *Human Relations* 1995;48:97–125.
13. Grailey KE, Murray E, Reader T, et al. The presence and potential impact of psychological safety in the healthcare setting: An evidence synthesis. *BMC Health Serv Res* 2021;21:773.
14. Google re:Work. How to foster Psychological Safety on your teams. Available online at: https://docs.google.com/document/d/1PsnDMS2emcPLgMLFAQCXZjO7C4j2hJ7znOq_g2Zkjgk/edit. Accessed March 2, 2022.

How to Use a Mentorship Framework to Support an Early Career Veterinarian

Cara Wright, DVM, MS, ICVA

Author's address: 3128 Indian Way, Lafayette, CA 94549; e-mail: cara.wright.dvm@gmail.com.
© 2022 AAEP.

1. Introduction

Integrating a new graduate into practice is an exciting and rewarding, yet challenging, prospect. A thriving mentorship program has distinct steps and timelines, clear advancement between steps, and regular meetings to assess progress while providing constructive feedback. Recognition of challenges and setting realistic expectations are vital to creating a strong mentorship program. This presentation will summarize the challenges that exist for integrating new graduates into practice and give clear recommendations for overcoming these challenges.

2. Challenges

Certain challenges exist for all doctors, regardless of experience level, when starting at a new clinic: new software, new team members, new protocols and workflow, and new inventory. These issues affect the efficiency of any veterinarian, much less one fresh out of school. The challenges for a new graduate are compounded by issues specific to them alone including adjusting to workflow in private practice as compared to the university setting, new interpersonal dynamics with clients, other doctors, and support staff.

Expectations of case workup in private practice often differ from the university experience. New graduates can become frustrated when a definitive diagnosis is elusive, and gold-standard treatment is not an option. Case workups will often take more time and can lead to frustration on behalf of both staff and clients.

Communications, both with clients and peers, are a soft skill that takes time and experience to develop. Often, a new graduate can get sidelined by certain overeager types of clients or bulldozed by stronger personalities. Newer graduates may not have experience being leaders in an established workplace and may struggle with giving direction to support staff.

Lastly, a new graduate may get over-scheduled due to increased demands on the practice. Over-scheduling, or scheduling without needed support, can hamper growth of veterinary skills and confidence. A busy practice that needs doctors to see cases may not schedule the new doctor in a way that increases their confidence with practice flow, equipment use, and case workup.

3. Solutions

Organizational

Organizational strategies in staffing and scheduling should be utilized to mitigate some of the efficiency challenges. Assigning an experienced technician with a new graduate will increase efficiency when finding medications and supplies in the practice vehicle, offer technical support when setting up and utilizing equipment, and provide guidance when using practice software. Additionally, when faced with a stressful case, it's helpful to have an experienced assistant. "Dr.

NOTES

Wright, would you like me to clip this wound for you?" is a nice reminder of what needs to be done when the new practitioner may be feeling overwhelmed.

A senior clinician checking over medical records and billing upon case completion will help train the new graduate in practice billing policies, as well as medical record style, and expedite confidence in these tasks. University-setting medical records are often longer and more detailed than what is practical in the field. This also provides the opportunity for case discussion, and a chance to dissect how the appointment went outside of earshot of the clients.

Scheduling

Setting realistic time management expectations of the new doctor is integral for success in practice, especially when it comes to the length of time it may take for case workups at the start of a career. This is relevant for both staff who schedule time for appointments, as well as the new doctor for working within the designated time frame. Allotting more time for appointments at the start of employment will ensure the new doctor will not feel rushed or unable to complete their desired case work up. This also decreases the chances of being late to other scheduled appointments, which can start a relationship with a new client in a stressful manner. In the author's experience, an additional fifteen minutes per routine appointment provides an adequate buffer. By giving the new graduate time to sharpen their exam routine, basic technical skills, and client communication including history taking, treatment recommendations, and expectations, their chances of success on future "fire-engine days." will be increased.

The author's practice has successfully used a graduated appointment schedule for a new doctor, accounting for both appointment type and time requirements. This allows for the growth of both skills and confidence. Using the phased approach gives the doctor time to establish relationships with minimal on-site hiccups, which will increase the acceptance of the doctor by the clients. The timing of each phase listed below is practice-dependent and should be modified to best suit the needs of your practice. An example for a graduated schedule of appointments is below.

- Phase 1: Shadow other doctors for both routine and emergency cases, meet clients, learn farm locations, practice using software, write medical records and billing for cases seen with senior clinician; senior clinician to revise/edit for completeness of record and accuracy of charges.
- Phase 2: Schedule solo basic wellness and simple appointments; these provide opportunity for direct client interaction and communication in a non-stressful environment with a high likelihood for success and confidence-building. Examples of these appointments include vaccines, routine dentals, bandage changes, lasers, shockwaves.
    - A senior clinician still double-checks records/billing for completeness.
    - Emergency coverage can be added once all parties feel comfortable and the new doctor has appropriate back up if needed.
    - In the author's practice, the new doctor accompanies senior clinicians on emergencies for six months and then begins to take primary emergency coverage; during this time, a senior clinician is available by phone and able to meet on the farm if needed for assistance.
- Phase 3: Continue to schedule complex cases/equipment with senior clinicians (lameness, gastroscope, etc.) even as the new doctor increases the frequency of seeing their own appointments. Joint appointments with a senior clinician will provide increased exposure to difficult cases and examples of client communication while simultaneously building skillset and confidence.
    - The newer doctor is responsible for writing medical records while the senior clinician provides a final review.
    - The newer doctor should take charge as much as possible in these appointments with the senior clinician present for advice and support as needed.

Communications

Fostering effective client communication skills should begin with the opportunity to practice callbacks on routine cases. This allows the new doctor to become comfortable speaking with clients while simultaneously reducing the pressure of communicating a diagnosis and treatment plan. Ensure that when they are working with other clinicians that they are present for the entire workup and conversation and not distracted by cleaning or putting away equipment. Remember that a new doctor is not a technician. Witnessing another clinician's client communication is where they will pick up case-related communication skills. Triaging ER phone calls is often stressful for new doctors. Doing so succinctly and successfully takes time, experience, and practice. Answering the daytime emergency calls for the practice is an opportunity to have these types of conversations while still having the support staff and other clinicians available for questions and assistance.

Case Outcome/Expectations

Helping the doctor navigate the gray area of case workups will help them form new roadmaps to case resolutions in the context of general practice as opposed to the university setting. Limitations of equipment in the field, client budget, and practicality of treatments are all topics that can cause stress and insecurity to a new graduate coming from the

SKILL/ COMPETENCY	Not attempted	Attempted, needs practice	Attempted, going well	Displays unassisted comprehension	Metrics for comprehension	Opportunities for learning
Rectal palpation for colic					Palpate 3-5 normal horses; recognize normal vs abnormal	Practice on Dr. X's retired broodmare
Pass nasogastric tube					Pass tube 5 times	
Remove horseshoe					Successfully remove shoe	Spend a day with farrier
Flush nasolacrimal duct					Pass through both nasal and ocular puncta	
Discuss radiographs with the farrier					Procure appropriate measurements in software; communicate desired outcomes	

Fig. 1. Examples from skills matrix (the complete document is available upon request, cara.wright.dvm@gmail.com).

university. Discussion of best on farm options available will help create confidence in case workups away from school.

Directing doctors to the medical records of similar cases is a good, low-effort way to compare notes. Weekly or bi-weekly case rounds allow discussion of cases and an opportunity to ask questions that may have arisen once off the farm.

Using a Skills Matrix

A skills matrix and a timeline helps new graduates reach expectations while ensuring that certain skills or case types don't get overlooked. A timeline is necessary to ensure accountability, but flexibility is important. Clear metrics are imperative to chart progress to ensure that the doctor has had enough opportunities to become proficient. For example, if a new graduate has only seen two colics in two months, this means they are likely not feeling as comfortable with that skillset simply due to a lack of exposure. Amending the timeline and creating other opportunities to practice those skills ensures the graduate has enough chances to become comfortable with a particular skill. This may seem like extra work for the practice but garnering the skills that are needed to operate independently early on with guidance will create confidence on behalf of both parties.

A skills matrix displays the skills or competencies needed, along with the current and desired proficiency level. At regular check-ins, both the supervising clinicians and the new grad rate the new grad on each skill. Any discrepancies in perceived skill levels are addressed. The author's practice holds these reviews monthly. Plans of action are established to ensure opportunities to practice skills- What opportunities for learning/practice are coming up in the schedule to help fill in some of the gaps? Are there upcoming clinics? Is there a broodmare herd or a supportive client that can be utilized?

The skills matrix in Figure 1 was derived from the AAEP Core Competencies list.[1] It was then broken into several larger categories, such as routine procedures, radiographs, dentistry, nerve blocks, euthanasia, and soft skills. Soft skills include tasks such as "write clear discharge instructions in lay terminology, effectively and briefly communicate treatment plans over the telephone, converse with farriers as peers about a case." Paperwork is a category that is often overlooked. Paperwork skillsets should include uploading and completing a Coggins and health certificate, submitting lab work appropriately, uploading radiographs, processing payments, and other practice-specific administrative tasks.

Giving Feedback

Providing effective feedback to a new graduate is the cornerstone of growth and improvement. Although varying personality types will receive and respond to feedback differently, following general guidelines is helpful for mentors. First, ask if the doctor is open to hearing some feedback. This ensures an open mindset for constructive thoughts. When providing feedback,

utilizing a structure that reinforces the good while providing suggestions for improvements will maintain a positive outlook on the situation and increases the likelihood that the recipient will stay open to the feedback given. Using affirmative statements help the new doctor become aware of areas of emerging strength, and can build confidence. An example of an affirmative statement is "patient assessments were accurate" or "identified appropriate treatments for likely diagnosis."

One method of providing constructive feedback involves using the structure "What went well ... but even better yet." Questions such as "What did you do well?", "What do you wish you had done differently?", and "What did you learn?" are all helpful when debriefing a situation. Giving feedback in a timely manner is also imperative to keep the content fresh and action items ready to be implemented.

4. Conclusion

By using the techniques outlined above, every practice can successfully integrate a new graduate into their practice by providing clear expectations, timelines for improvement, and constructive feedback. This will build confidence and enable the new graduate to become an integral part of the practice sooner rather than later.

Acknowledgments

Declaration of Ethics

The Author has adhered to the Principles of Veterinary Medical Ethics of the AVMA.

Conflict of Interest

The Author has no conflicts of interest.

Reference

1. "Core Competencies for New Veterinary School Graduates in Equine Practice." https://aaep.org/sites/default/files/2021-02/AAEP_Core_Competencies_2020.pdf. Accessed July 15, 2020.

Review of Good Record Keeping: Will Your Documentation Defend You?

Cynthia G. MacKenzie, DVM

Maintaining good medical records in equine practice regardless of discipline is necessary from many standpoints: medical, legal, regulatory, and ethical. This paper will provide a review of these concepts so that equine practitioners can evaluate their current format against these standards. Author's address: AVMA Trust, 1931 N Meacham Road, Suite 106, Schaumburg, IL 60173; e-mail: vetmack98@gmail.com. © 2022 AAEP.

1. Introduction

The importance of producing and maintaining good medical records in equine practice cannot be overstated. While medical records have always been a legal requirement of veterinary practice regardless of practice type, they also represent an equine veterinarian's defense should a lawsuit or board complaint arise. The American Association of Equine Practitioners (AAEP) has addressed this critical topic in the past focusing on the nuances of equine practice as a hindrance in the record keeping process as well as how to create a legally defensible medical record.[1] Recently, AAEP's Ethics Committee has highlighted the need of good medical records as part of several excerpts in their "Ethical Practice" series. One article discussed medical records having an increased accountability in racetrack practice and that traditionally this type of practice has used invoices only as part of their record keeping.[2] Another "Ethics in Action" segment looked at a veterinary license defense claim where a state veterinary board fined an AAEP member for not having medical records.[3] Lastly, The American Veterinary Medical Association's (AVMA) Professional Liability Insurance Trust (PLIT) has seen an increase in the number of malpractice claims and board complaints in the US in recent years.[4,5]

The AVMA PLIT program has been reviewing malpractice claims since the early 1960s. During this time, the program has identified four key principles to help veterinarians minimize the likelihood of a malpractice claim or a board complaint. One of the four principles revolves around medical records and the need to maintain good documentation in practice. The other principles are practicing good medicine, keeping people and patients safe, and practicing good communication. In reviewing equine malpractice claims through the program, the author has observed that equine veterinary medical records have historically contained less information than what is required by most state licensing boards. So, due to the rise in both malpractice claims and board complaints, equine practitioners may be at a disadvantage from a defense perspective should they have a lawsuit filed against them or be subject to a veterinary license defense claim.

NOTES

2. Medical

From a medical standpoint, records exist for documenting examinations, treatment, communication, and the continuity of care. Records should be accurate, clear, and timely. Whether handwritten or digital, they must be legible and easy to follow. A SOAP (subjective, objective, assessment, plan) format is highly recommended. Minimum requirements for medical records vary from state to state based on the state's veterinary practice act. Equine practitioners should review these requirements against their current practice to see if the minimum information is being captured in their current record keeping format. If practitioners are licensed in multiple states, medical records should meet the standard of the state with the most requirements. Complete and legible medical records are imperative both in hospital and in ambulatory practice. The quality of care will be judged on the documentation within the medical records. Documentation should show sound professional judgment based on information available at that time. For example, if a lameness exam is done with nerve blocks or joint blocks to localize the affected area, a thorough understanding of the results, i.e., percentage of lameness improved, should be documented to justify the recommended course of treatment. In addition, good documentation will ensure continuity of care should the horse be moved or treated by another equine veterinarian. A good rule to follow is that any equine practitioner who reads a medical record should be able to pick up where the last veterinarian left off with treatment of that horse. Items to include in medical records are written consent forms, anesthesia logs, surgery reports, physical exam findings, daily boarding sheets, reproduction exams, diagnostics recommended and declined by the client, lab results, estimate sheets, and all communication including texts, e-mails, voice messages and verbal conversations. The practice owns these records, including original radiographs. The client of the records is entitled to copies upon request within a reasonable time period. Consult your state veterinary practice act for specifics regarding providing records to clients. And remember to check with your state veterinary practice act as to ALL specific record keeping requirements, including how long records should be maintained (see below under regulatory for an example of a state veterinary practice act). Lastly, medical records also are an open component of communication practices. Depending on what record keeping system is used in the practice, texts, emails, voicemail messages, social media posts, and verbal conversations should be captured and maintained as part of the medical record. Documented conversations around risks help show informed consent particularly if a compounded or off-label medication is going to be used.

3. Legal

Medical records are a legal document and are required to be maintained under the law of the state practice act. From a defense standpoint, if something was not written in the medical record, it did not happen. Equine practitioners can benefit from using a SOAP format to avoid legal pitfalls. Licensing boards and attorneys prefer to see medical records in the SOAP format, and they should be accurate and up to date. Using a medical software system that has time and date stamps is preferable. If doing ambulatory work, utilize a system that syncs automatically, and if it does not, then have the record updated within 24 hours of the last visit. Many state practice acts will stipulate a timeframe in which a record must be updated. Amendments should also be date and time stamped along with the justification for the amendment. Telemedicine is being utilized more frequently by equine veterinarians and this type of technology has many benefits both to the practitioner and the client. These visits should be maintained in the formal medical record. Guidelines around telemedicine continue to evolve and practitioners need to be aware of the legalities of utilizing telemedicine in their state. Most states and the AVMA Principles of Veterinary Medical Ethics (PVME) still require that a valid veterinary-client-patient relationship (VCPR) exists in order to diagnose, prescribe medication, or treat an animal.[a] The AVMA has resources on telemedicine and these should be consulted to ensure that current methods are within the legal scope of practice for the state(s) that the veterinarian is licensed in.[b] Finally, the medical record is not only a legal document, but also a confidential one and veterinary practices need to ensure that client confidentiality is maintained. Medical records should only be released to the client upon request. Some states have seen amendments to state practice acts in this area of confidentiality to allow for more transparency within horse racing jurisdictions among trainers, veterinarians, and regulatory authorities.

4. Regulatory

Horse racing is just one area where veterinary medical records are used for regulatory purposes. The increase in oversight on many racetracks has cast a spotlight on the medical record keeping practices of equine racetrack practitioners. This is one area where historically, the medical records were comprised mostly of invoices which represents a violation of most state practice acts. The increase in regulatory requirements on many racetracks has brought awareness to the medical record keeping area of racetrack practice with many practitioners now believing the lack of detailed medical records as substandard practice.[2] State licensing boards regulate veterinary medicine through enforcement of the veterinary state practice act. Licensing boards may find in favor of the veterinarian's medical treatment based on a license defense claim but will issue a fine for lack of proper medical records since the board has access to review all the medical records when a client complaint is filed. This is where equine practitioners need to be aware of the minimum record keeping requirements for their state and address their current format of medical records against this standard. For example,

below is the veterinarian patient record keeping section of the Texas Veterinary Practice Act.[c]

- Current through Reg. 47, No. 6; February 11, 2022, this is a summary of the important points:
  - A legible document identifying the client, species, breed, sex, description, and patient history
  - Name address phone number
  - Prior client records
  - Ancillary test results including laboratory, imaging, procedures
  - Differential diagnosis
  - Treatments which include dates, including call backs and returns
  - Appropriate controlled substance documentation
  - Alternative therapies and referrals
  - Outcomes
  - Official health documents

5. Ethical

Keeping good medical records is a matter of ethics. Equine practitioners have always understood the medical, legal, and regulatory reasons behind good record keeping but may not have considered that keeping good medical records also represents an aspect of ethics. The AVMA PVME includes language on medical records and the need to comply with standards established by state and federal law, which as listed in the above section includes specific requirements for record keeping.[a] Equine practitioners have Ethical Guidelines from the AAEP, and under the Standards of the Profession, practitioners are to "comply with the laws, regulations and standard of care of their appropriate jurisdiction."[c] The AAEP, as previously mentioned, has included this topic within their "Ethical Practice" segments. Dr. Dunlavy is quoted in one of these articles as saying "the accountability of complete medical records is an ethical goal that we should all strive for."[2]

6. Research

One benefit regarding keeping good medical records, particularly electronic records, is the potential for doing research. Medical records represent a wealth of information that when catalogued into a format that allows for data mining can be very beneficial in providing valuable information to the profession in terms of research papers. One publication reviewed a method for mining electronic medical records citing that exploitation of clinical experiences within electronic medical records has the potential to revolutionize veterinary medical research.[6]

7. Summary

Medical records are a necessary part of equine clinical practice and practitioners need to be aware of all the medical, legal, regulatory, and ethical reasons for producing and maintaining good medical records in practice. These reasons should be evaluated carefully amongst equine veterinarians to ensure that their current record keeping formats are meeting all standards, especially in current times where veterinarians are having to defend themselves more than ever due to the rising number of malpractice claims and board complaints. Should an equine practitioner be faced with either an allegation of negligence, demand for monetary compensation, or a board complaint, they should seek guidance from their professional liability carrier.

Acknowledgments

Declaration of Ethics

The Author has adhered to the Principles of Veterinary Medical Ethics of the AVMA.

Conflict of Interest

The Author is currently employed by the AVMA Trust and has no conflicts of interest.

References and Footnotes

1. Sedrish S. How to create and maintain a legally defensible medical record to protect your clinic, in *Proceedings*. Am Assoc Equine Pract 2013;59:282–285.
2. Dunlavy K. The Hawthorne effect and racetrack practice. *Equine Vet Educ* 2020;9:2.
3. "Ethics in Action" *Equine Vet Educ* 2021;2:IV.
4. AVMA PLIT Newsletter 2020;39(4):2.
5. AVMA PLIT Newsletter 2019;38(3):1.
6. Duz M, Marshall JF, Parkin T. Validation of an Improved Computer-Assisted Technique for Mining Free-Text Electronic Medical Records. *JMIR Med Inform* 2017;5:e17.

[a]American Veterinary Medical Association Principles of Veterinary Medical Ethics

[b]American Veterinary Medical Association Telemedicine Policy. Currently under review. 2022.

[c]Texas Veterinary Practice Act. Section 573.52

[d]American Association of Equine Practitioners Code of Ethics

Having a Difficult Conversation – Speaking Your Truth Effectively

Amy L. Grice, VMD, MBA

With planning beforehand, difficult conversations can be less stressful and more productive. Author's address: PO Box 192, Virginia City, MT 59755; e-mail: amyvmdmba@gmail.com. © 2022 AAEP.

1. Introduction

Difficult conversations take place frequently in most people's lives, whether to resolve conflict, voice disagreement, or share feedback that may be hard for the recipient to hear. People generally fall along a spectrum in their comfort level with crucial communication. Many people fear conflict and avoid it whenever possible. At the opposite extreme, some have a pattern of high-conflict behavior that increases conflict rather than reducing or resolving it. Still others are aware of their own biases in perception, communicate their feelings without difficulty, and are neither judgmental nor reactive. This presentation will explore each of these patterns, offer a framework for having difficult conversations, and suggest best practices for achieving the desired result.

2. Discussion

Many difficult conversations arise due to conflict or disagreement between two parties. Disagreements can be over values, motivations, perceptions, ideas, desires, and/or behaviors. When a conflict triggers strong feelings, a threat to a core need is often present. These core needs are to feel safe and secure, to feel respected and valued, and/or to continue to have a strong relationship. Conflict resolution allows people to find a peaceful solution to a disagreement among them. The disagreement may be personal, financial, political, or emotional, but it arises from two parties having different needs or desires. When a dispute arises, often the best course of action is negotiation through conversation to resolve the disagreement. These difficult conversations can build increased trust and stronger relationships when they are handled well.

Conflict Avoidance

Conflict avoidance is common among those in the helping professions. Those who are conflict avoidant view conflict as a threat to their survival and so they often have an instinctive reaction to stay far away from difficult conversations. Often early experiences in their lives have created a people-pleasing behavior that expresses itself as a fear of upsetting others. They expect that speaking their truth will make things worse and expect negative outcomes if they share their thoughts, opinions, and feelings. Sometimes they ignore the issue by simply denying it exists. They may detour the issue by

NOTES

pivoting to a new subject. Commonly, those who are unnerved by conflict may simply shut down and withdraw.

At work, these employees are generally seen as "nice" and have a reputation for never causing conflict.[1] As a partner or an associate, this can look like going silent and enduring uncomfortable situations instead of expressing issues openly until enough pressure has built up that they explode. Explosions are rarely effective conversations. In addition, some conflict avoidant people talk incessantly about their issues with others but never with the person with whom they have an issue. This triangulation is unhealthy and lowers morale in the workplace.

Maslow's hierarchy of needs is a pyramid. After the basic needs of food, water, and shelter are met, safety and security are next in importance. Following these are love, acceptance, and belonging.[2] Human behavior is shaped by seeking to fill these needs. When acceptance and belonging are missing, loneliness, depression, and anxiety often follow. It makes sense that people who have experienced lack of acceptance of their ideas or feelings will try to avoid feeling this way again. It challenges their core need of feeling valued, safe, and secure. People want to belong, and fear being ostracized. This leads to fear of conflict.

When people who are conflict-avoidant encounter a difficult situation with others, they have a reaction in their limbic system, preventing them from thinking clearly. They simply want to flee, as their heart beats faster and blood surges to their muscles to help them run faster to survive. Sometimes people actually leave the physical location as fast as they can. When a practice owner has this tendency, their employees are typically frustrated that they cannot be heard. When employees have this trait, they typically store up resentment because they are afraid to tell their truth and either poison the well with triangulation or find another job.

Being comfortable with conflict management is essential for a healthy business. According to Stuart Hearn, "It can take time to change company culture, but it's worth it in the long run. Help your employees reframe conflict as something constructive. We don't want conflict to be aggressive or unnecessarily confrontational, but debate and disagreement can be useful and beneficial for business. It can help if you demonstrate to your employees that management values variance of opinion. Employees should feel on solid ground and be secure in the knowledge that if they stand up against an idea or process, they won't have to worry about their job."[3]

High-Conflict Personality

Unfortunately, there are some individuals who make effective communication very difficult due to possessing a high-conflict personality trait. People who exhibit high-conflict behavior have a pattern that increases conflict rather than reducing or resolving it. This pattern repeats in almost all situations in disagreements with many different people. It is important to recognize that the cause of the escalation of the interaction is not the actual issue that prompted the conversation but is the person's high-conflict personality and how they approach problem-solving.

Typically, someone who has a high-conflict personality will exhibit a pattern of blaming others, zero-sum-game thinking, and extreme emotional outbursts.[4] The intensity of the blaming behavior is often unreasonable for the type of disagreement and may be particularly harsh when directed at those in authority or those who are close to them. It stems from the heightened degree of threat that they feel. Because they feel as though they might not survive if they don't prevail, they focus on attacking and blaming someone else, often in extreme ways. In contrast to their blame of others, they usually see no fault in themselves and see themselves as free of all responsibility for the problem. Whatever early experience they have had that has shaped them presents as fight rather than flight.[5]

Because those with this personality trait tend to react rather than taking time to analyze the situation, hear different points of view, and consider several possible solutions rationally; compromise and flexibility seem impossible to them. Due to the high threat that they feel by not being in total control of the outcome, they often predict extreme outcomes if others do not handle things the way that they want and react in extreme ways, even quitting a job or ending a relationship suddenly. This heightened threat response also explains their often very emotional outbursts that can include intense fear, anger, yelling, or disrespect that can be quite surprising. Afterward, they may have regret but also may defend their actions as totally appropriate.[5] Because of these individuals, not all efforts at effective communication will be successful.

High Self-Awareness

Those with healthy responses to conflict generally have high self-awareness and can comfortably speak to others with whom they disagree. They recognize the importance of considering the other party's concerns, understand that their perception is not the absolute truth, and are able to empathize with those who struggle more with communication (Fig. 1).

Mindfulness has been shown to help effective communication. It is a specific state of attention which involves a constant focus on what is happening at the present time in a way that is neither judgmental nor evaluative. Components of mindfulness include observing, describing, acting with awareness, nonjudging, and non-reactivity. In a study of mindfulness, relationship quality, and conflict resolution strategies used by partners in close relationships, the researchers found that acting with awareness, dialogue, and avoiding conflict escalation strategy were predictors of relationship quality.[6] These

Healthy Responses	Unhealthy Responses
The capacity to recognize and respond to the things that matter to the other person	An inability to recognize and respond to the things that matter to the other person
Calm, non-defensive, and respectful reactions	Explosive, angry, hurtful, and resentful reactions
A readiness to forgive and forget, and to move past the conflict without holding resentments or anger	The withdrawal of approval, resulting in rejection, isolation, shaming, and fear of loss of personal or professional relationship
The ability to seek compromise and avoid punishing	An inability to compromise or see the other person's side
A belief that facing conflict head on is the best thing for both sides	The fear and avoidance of conflict; the expectation of bad outcomes

Fig. 1. Healthy and unhealthy responses to conflict.

same qualities are key tenets of effective conflict resolution.

Resolving Conflict with a Difficult Conversation

Conflicts continue to fester when ignored. Because a conflict involves a perceived (or occasionally real) threat to a person's well-being and survival, the resulting discomfort persists until the problem is faced and resolved. People respond to conflicts based on their perceptions of the situation, not necessarily with an objective review of the facts. Perceptions are influenced by a person's life experiences, culture, values, and beliefs. Conflicts trigger strong emotions. If one isn't comfortable with strong emotions or is unable to manage one's own emotions in times of stress, resolving conflict successfully will be difficult.

It is best to think of conflicts as an opportunity for growth. When a person can resolve conflict in a relationship, the experience builds trust. People feel more secure knowing their relationship can survive challenges and disagreements. With multiple successes, previous life experiences that led to conflict avoidance or high-conflict personality can begin to have less power. Seeking counseling to process these challenges can be life-changing for some.

Successfully resolving conflict depends on the ability to manage stress quickly, control emotional responses and behavior, pay attention to the feelings being expressed by others, and be aware and respectful of differences. Some of the most important information exchanged during conflicts is communicated nonverbally. Nonverbal communication is conveyed by emotionally driven facial expressions, posture, gesture, pace, tone, and intensity of voice, and makes up 70-90 percent of the total message received. Being mindful of non-verbal signals is part of facilitating the most effective interchange.

If one of the parties insists on finding solutions that are strictly rational, while ignoring feelings, their ability to face and resolve differences will be impaired. Emotional awareness helps a person understand what is troubling another person and understand what is really troubling themselves. It also assists them in staying motivated until the conflict is resolved, communicating clearly and effectively, and influencing others to a maximal extent.

Working hard to see the situation through a different lens, the lens of the other party, builds empathy and more effective resolution of conflict. When a person demonstrates genuine caring about others' outcomes, obviously values a future relationship, and aims for mutual gain, fear decreases. By focusing on what is in common rather than on differences, and interests (e.g., why you want it) rather than positions (e.g., what you want), the more successful one will be in meeting the needs of all parties. This is also facilitated by an open exchange of information between sides, and an enlargement of the benefit of agreement through innovative ideas. The following is a recipe for conducting a difficult conversation. Completing the difficult conversation worksheet (Table 1)[7] is recommended prior to the conversation. Before having a difficult conversation:

- Ask yourself what you really want. What is your desired outcome?
- Stop assuming the worst and acting in ways that confirm your "story" and looking for evidence that confirms your story.
- Ask yourself what the other side of the story might be. Nothing ruins a good story like hearing the other side.
- Ask yourself what role you might have played in the situation. What is your responsibility?

Setting the stage for having a difficult conversation:

- Distill all the behaviors that illustrate the problem into a statement of the real issue, as you see it.
- Invite the other party to a private safe space and be ready to have the conversation immediately even if you are trying to schedule it at a future time.
- Think about the conversation as a negotiation where everyone's needs matter.

During the difficult conversation:

Table 1. Difficult Conversation Worksheet [7]

Difficult Conversation Worksheet: (Adapted from Susan Scott "Fierce Conversations")
1. The issue is: (Be concise. In one or two sentences, describe the heart of the problem, challenge, or conflict, as you see it.)
2. What is the value of resolving the issue? What is at risk if the issue is not resolved?
3. The ideal – best case outcome would be: (What would you really like to happen, recognizing that it is not necessarily predictable)
4. Relevant data and background information: (Short bullet points on how, when, why, where it started, who are the key players, the forces at work, today's status, future impact, etc.)
5. What are the major obstacles to resolution, as you see them?
6. What are your major assumptions: (What "story" are you telling yourself?)
7. What do you think the other party's assumptions are? (What "story" could they be telling themselves?)
8. What emotions are you feeling?
9. What emotions do you think the other party is feeling?
10. Describe the alternatives you see or actions you could consider to resolve the conflict or solve the problem: (Describe the alternatives and the pros and cons of each)

- Start with the facts as you see them.
- Describe the gap between your desired outcome and the current reality.
- Share your story and ask for theirs.
- Ask clarifying questions, using reflective listening.
- Listen with an open mind and open heart.
- Listen for what is felt as well as said.
- Make conflict resolution the priority rather than winning or "being right".
- Focus on the present, not on the past.

Concluding the difficult conversation:

- Brainstorm options.
- Agree on a plan of resolution.
- Ask if there are missing details or unresolved issues.
- Stay flexible. If other issues come up, consciously decide whether to and when to address them.
- Agree to check back in.

Other thoughts:

- Pick your battles.
- Be willing to forgive.
- Know when to let something go.

Adapting Communication for Conflict Avoidants and High-Conflict Personalities

Conflict avoidants' fear can sometimes be allayed by speaking to it directly, such as by saying "I know this is hard/uncomfortable for you, but I care about our relationship/this practice/your success, and I hope you will hear me out." Another method is to frontload the approach with a positive sentiment to minimize the other party's defenses. For example, "Dr. Jones, I am really impressed with how much positive energy you are bringing to the practice, and I want you to know that it is helping the whole team. This makes me happy every morning when I see everyone in a good mood." Then talk about the issue. "I was surprised and hurt when you told Mrs. Smith that my proposed treatment for Fluffy was "old school" and you could offer something more effective. I wish you had talked to me about your concerns instead." Without this thoughtfulness, one might be inclined to say "How dare you call me "old school" and insult me to a client! Who do you think you are! You've got a lot of nerve for someone just a few years out of school!"[8]

The first example is respectful and allows Dr. Jones to have an opportunity to explain or own her behavior, make things right, and salvage the work relationship. It offers an off ramp to de-escalate the issue and prevent it from happening again in the future. The second example is a more aggressive confrontation that seems to label Dr. Jones as a bad person and suggests her position at the practice could be in jeopardy. With the heightening of the threat level that she feels, Dr. Jones is more likely to be hurt, defensive, and shut down without reflecting on her own behavior. This may lead to her withdrawing and beginning to search for a new position before her worst fears come true. By providing the space for the person who is being confronted to explain their perspective, clarify a miscommunication, or own a misstep, the experience can be the first step toward a conflict avoidant learning that they can emerge from a disagreement with relief rather than disaster.

With those people who possess high-conflict personalities, the challenge is greater. At their worst, these individuals are narcissists or have borderline personality and may utilize emotional blackmail regularly to get their way. Narcissistic personality disorder is a mental condition in which people have an inflated sense of their own importance, a deep need for excessive attention and admiration, troubled relationships, and a lack of empathy for others. Behind the façade of extreme confidence lies a fragile self-esteem that's vulnerable to the slightest criticism.[9] Borderline personality disorder is a mental illness that severely impacts a person's ability to regulate their emotions. This loss of emotional control can increase impulsivity, affect how a person feels about themselves, and negatively impact their relationships with others.[10]

Table 2. Common Triggers of an Emotional Response

	Common Triggers Are:
1.	Afraid of disappointing others
2.	Afraid of angering others
3.	Afraid others won't like/love me or will leave me
4.	I owe it to them
5.	They've done so much for me I can't say no
6.	It's my duty
7.	I'll feel guilty if I don't give in
8.	I'll feel selfish/unloving/greedy/mean
9.	I won't be a good person

Emotional blackmail is defined as a dysfunctional form of manipulation by a person to place demands and/or make threats to get what they want. Typically, this means the blackmailer sets up a comparison, induces guilt or obligation, and follows with a threat. It is important to understand that emotional blackmail is an attempt to meet unmet needs, manage fear, and maintain control.[11] Fear, obligation, and guilt (FOG) are what emotional blackmailers rely on for successful manipulation. Receivers feel fear of consequences, obligated to act, and guilty for not doing what they've been asked. The blackmailer quickly learns which parts of the FOG triad are most effective in manipulating an individual; they learn which emotional triggers work best. Emotional blackmailers are often very good at spotting the people who are likely to respond to these tactics the best.[12] Unfortunately, compliance guarantees repetition, so one must resist, despite feeling urgent need for relief from the blame and emotionally reactive storm. The receiver experiences relief when they comply: feelings of fear, obligation, and guilt recede, so they are rewarded for complying. But this then means the blackmailer will double down on this behavior.

To disrupt emotional blackmail, one must be curious about the unmet needs of the blackmailer, must find empathy for them, and must want to change the dynamic. This requires remarkable emotional control, but if one is prepared in advance and understands the manipulation, overcoming the storm is possible.[11] Part of the preparation involves determining where one's weaknesses will allow the high-conflict individual to gain traction. Understanding one's "hot buttons" will provide the self-awareness to divert the emotional response (Table 2). Unfortunately, people with a high-conflict personality may leave one unable to manage a confrontation effectively, despite one's best effort and preparation. They may appear enraged or shocked and create an endless drama with no productive resolution. In this case, it may be appropriate to end the employment relationship. A person who is incapable of resolving conflict productively may have deeper issues that are intractable and often lead to a spiral of distrust and animosity.

3. Conclusion

When careful thought is given to the desired outcome, responsibility is taken for one's part in the situation, and both empathy and curiosity are the foundation of the communication, better outcomes are often assured. By recognizing the legitimacy of conflicting needs and perceptions, an increase in trust and respect is realized. In the event one is experiencing repetitive difficult conversations with a high-conflict individual without satisfactory resolution, severing the relationship may be the most productive path.

Acknowledgments

Declaration of Ethics

The Author has adhered to the Principles of Veterinary Medical Ethics of the AVMA.

Conflict of Interest

The Author has no conflicts of interest.

References

1. Hirsch A. Working with People Who Avoid Conflict Available from: https://www.shrm.org/resourcesandtools/hr-topics/employee-relations/pages/working-with-people-who-avoid-conflict.aspx. Accessed March 11, 2022.
2. McLeod S. Maslow's Hierarchy of Needs. Available from: https://www.simplypsychology.org/maslow.html#:~:text=How%20many%20levels%20are%20there,esteem%2C%20and%20self%2Dactualization. Accessed May 10, 2022.
3. Hearn S. Addressing Conflict Avoidance in the Workplace. Available from: https://www.clearreview.com/conflict-avoidance-destroys-work-culture/. Accessed March 10, 2022.
4. Eddy B. High Conflict People. Available from: https://www.highconflictinstitute.com/hci-articles/who-are-high-conflict-people. Accessed March 08, 2022.
5. Eddy B. How to Quickly Spot High Conflict People. Available from: https://www.psychologytoday.com/us/blog/5-types-people-who-can-ruin-your-life/201711/how-quickly-spot-high-conflict-people. Accessed March 08, 2022.
6. Mandal E, Lip M. Mindfulness, relationship quality, and conflict resolution strategies used by partners in close relationships. Current Issues in Personality Psychology 2021. https://www.termedia.pl/Mindfulness-relationship-quality-and-conflict-r-nresolution-strategies-used-by-partners-r-nin-close-relationships,75,45933,0,1.html
7. Scott S. *Fierce Conversations*. New American Library. New York, NY 2017 pp 41-42.
8. Leonard E. Help for the Conflict Avoidant. Available from: https://www.psychologytoday.com/us/blog/peaceful-parenting/202002/help-the-conflict-avoidant. Accessed March 11, 2022.
9. Mayo Clinic. Narcissistic Personality Disorder. Available from: https://www.mayoclinic.org/diseases-conditions/narcissistic-personality-disorder/symptoms-causes/syc-20366662#:~:text=Narcissistic%20personality%20disorder%20%E2%80%94%20one%20of,lack%20of%20empathy%20for%20others. Accessed May 10, 2022.
10. Borderline Personality Disorder. Overview. Available from: https://www.nimh.nih.gov/health/topics/borderline-personality-disorder. Accessed May 10, 2022.
11. Brandt J. Emotional Blackmail: How to End the Cycle. AVMA Axon Online course. Available from: https://axon.avma.org/local/catalog/view/product.php?productid=109. Accessed March 02, 2022.
12. Forward S, Frazier D. Emotional Blackmail: When the People in Your Life Use Fear, *Obligation, and Guilt to*

Manipulate You. Harpers Collins. New York, NY 2001, pp 39-42.

Additional Reading

"Bargaining for Advantage", G. Richard Shell
"Crucial Conversations", Kerry Patterson, Joseph Grenny, Ron McMillan, Al Switzler
"Crucial Confrontations", Kerry Patterson, Joseph Grenny, Ron McMillan, Al Switzler
"Difficult Conversations", Douglas Stone, Bruce Patton, Sheila Heen
"Getting to Yes", Roger Fisher, William Ury, Bruce Patton
"Never Split the Difference", Chris Voss
"Fierce Conversations", Susan Scott

Mindfulness: A Powerful Tool for Sustainable Equine Practice

Tovah Caldwell, BSc.H, DVM, MA*; and Elizabeth Kurucz, BA(Hons), MIR, PhD

Equine veterinarians who practice mindfulness describe substantial improvements in subjective well-being, resiliency, and career longevity by cultivating the tools required for a sustainable career. These tools include developing a professional identity, broadening one's perspective, drawing and honoring boundaries, and successfully managing the transition between work and home life. Authors' address: McKee Pownall Equine Services, 12240 Second Line, Campbellville, ON L0P 1B0, Canada; e-mail: tovahcaldwelldvm@gmail.com. *Corresponding and presenting author. © 2022 AAEP.

1. Introduction

Most veterinarians are by now familiar with the 2016 AVMA-AAEP Survey of Equine Practitioners[1] that revealed troubling statistics about the current state of the equine industry. Many young practitioners are choosing not to renew their equine association memberships within the first 5 years of practice, and fewer graduating veterinarians are choosing to enter equine practice (5.7% in 2003 vs 1.5% in 2018). Endeavoring to understand this trend, Dr. Amy Grice's 2020 survey on Leaving Equine Practice[2] revealed that veterinarians who choose to leave practice do so because of the lifestyle and required work hours (58%), obligation to cover emergency calls (53%), low compensation compared to small animal counterparts (52%), mental health concerns (46%), and the culture of the equine veterinary industry (37%).

As an industry, equine medicine requires substantial change to address rates of compensation and the economics of practice, safety, and the accepted cultural norm of how the industry operates. While individual veterinarians are not able to address these industry problems on their own, it is possible for individuals to reframe their involvement in the industry and have more control over how the stressors of equine practice affect them on a personal and professional level.

Mindfulness

Originating in Eastern philosophy, mindfulness has been defined in various ways, the core of which describes a phenomenon where participants cultivate focus and awareness on both internal and external stimuli. Jon Kabat-Zinn,[3] perhaps one of the Western world's most famous mindfulness researchers, describes mindfulness as "the awareness that emerges through paying attention, on purpose, in the present moment, and nonjudgmentally to the unfolding of experience moment by moment." The opposite scenario, not being in the present moment and functioning in a state of mindlessness, leads to feelings of discontent, increased stress, and an inability to recognize the subconscious behaviors that create this state.[3]

NOTES

Over the last decade, mindfulness has received significant attention, both in mainstream popular culture and the scientific literature, particularly due to the well-documented evidence that mindfulness contributes to psychological well-being, mental health, physical health, and overall understanding of self. Unfortunately, a gap remains in the understanding of what mindfulness is, as it is narrowly associated with the image of a meditating Buddha, perfectly posed while in deep concentration. Although meditation is the most common tool to develop a mindfulness practice, activities such as yoga, body scan techniques, breathing exercises, and tai chi can accomplish the same goals by teaching nonjudgmental, present-moment awareness. While it may be difficult for some, it is important to remember that mindfulness is a skill that is learned over time with repeated practice.

The impact of mindfulness in practicing veterinarians has been scarcely evaluated. Quantifiable data have been gathered to investigate the relationship between mindfulness and resilience in veterinary students,[4] the impact of mindfulness-based interventions on veterinary students,[5,6] and the impact of mindfulness on attention and rumination in veterinary students.[7] However, there has been little investigation into how practicing veterinarians are actively using mindfulness to impact their daily work lives. As such, this research seeks to understand how equine veterinarians describe the impact of mindfulness as it relates to their ability to adapt to the unique challenges of equine veterinary medicine in the long term.

2. Methods

Social scientists study the nuance of human experience through rigorous qualitative research methods. As such, a qualitative study design was chosen to understand the experiences of equine veterinarians who use mindfulness, as numerical data do not always capture participants' perceptions of their own experience. Social media platforms and email listservs were used to solicit participants. Inclusion criteria were limited to practicing equine veterinarians who actively use mindfulness to support their daily work life. Fourteen veterinarians were interviewed using a semistructured technique with open-ended questions. Most resided in the United States (13/14), with one participant from New Zealand. There were two male and 12 female veterinarians. Most participants had greater than 10 years of clinical experience (13/14) with one intern veterinarian who had two years of experience. The 13 experienced veterinarians found mindfulness practice later in their careers, whereas the intern veterinarian had developed these skills prior to entering vet school. In addition, most experienced veterinarians had not received mental health, well-being, or mindfulness training in veterinary school, whereas the intern veterinarian had reported some degree of training in veterinary school on these topics.

Interview responses were transcribed and coded using NVIVO software. First-order codes were grouped to identify second-order themes, which included reasons for pursuing mindfulness, cultivating an awareness of self, developing a broader perspective, drawing and honoring boundaries, building life and career resiliency, and improving subjective well-being. The study design was approved by the Research Ethics Board at the University of Guelph for protection of human participants.

3. Results

Several key findings were identified across the interpretive analysis. Veterinarians reported that their mindfulness practice:

- Supported professional growth and the development of a professional identity by practicing nonjudgmental awareness and self-compassion.
- Enabled the development of a broader perspective that has both clinical and professional benefits.
- Facilitated setting and maintaining boundaries that support a sustainable practice.
- Was undertaken to improve subjective well-being and develop life and career resilience, leading to the desire and capacity for veterinarians to stay in practice.

4. Discussion: Building a Toolbox for Sustainable Equine Medicine

When asked why they pursued mindfulness training, many veterinarians felt a sense of desperation in practice, reporting an inability to cope with life and career stressors, symptoms of burnout, and a desire to take better care of themselves and their families. Participants felt they did not have the mental and emotional tools necessary to cope with equine practice, leading many to consider alternative career choices. In adopting mindfulness, participants strongly believed that it was wholly or in part responsible for developing key skills that supported their professional toolbox for sustainable equine practice.

5. Tool Number 1: Developing a Professional Identity

The concept of a professional identity, or professional self-awareness, is rarely discussed in veterinary medicine. Although most veterinary programs now include a focus on developing soft skills such as emotional intelligence and communication, there appears to be a gap in professional self-development and transformational self-awareness training. The consequence is that new practitioners struggle to understand the importance of these soft skills and fail to implement them into practice life. Furthermore, seasoned equine practitioners have received little training in this regard, and this has partly contributed to the current climate in equine practice.

A professional identity is an inherent sense of self that includes an understanding of personal and professional motivations, boundaries, values, goals, strengths, and weaknesses.[8] Symptoms of a poorly defined professional identity include seeking validation and self-worth through professional interactions,[9] self-blame when cases don't turn out as expected, struggling with imposter syndrome, having unrealistic expectations of one's knowledge and abilities, feeling a need to work all the time, worrying about what clients and coworkers think of one's personal character, and fighting a constant need to please people by always being available and responding to unreasonable requests. These symptoms were reported by nearly all participants at one point in their career, the result of which was excessive stress and career dissastifaction.[8]

A professional identity can be developed through transformational learning processes with the end goal being a heightened sense of self-awareness. For participants, the key factor that facilitated this growth was learning to not seek validation and self-worth through career success, a skill learned by practicing nonjudgment and developing self-compassion.

Practicing Nonjudgment

Learning to be nonjudgmental of self was a transformative process that helped participants define their professional identity by knowing, understanding, and accepting a realistic picture of the scope of their involvement in any situation. Nonjudgment is cultivated through mindfulness as one learns the process of being aware of present-moment thoughts, behaviors, and feelings, and accepting them for what they are without trying to change them.[10] Without the practice of nonjudgment, the tendency to scrutinize, ruminate, and judge one's role in a situation can lead to maladaptive coping mechanisms, heightened anxiety, and excessive stress.[11] Being able to clearly define expectations of self based on current circumstances allowed veterinarians to accept themselves as they were, thereby learning to seek internal validation unrelated to career success.

Developing Self-Compassion

The second element that veterinarians felt contributed to their professional growth was self-compassion. Self-compassion has been correlated with the trait of nonjudgment,[4] and the two constructs run parallel in importance. Developing self-compassion allows one to respond to personal shortcomings, failures, and judgments with kindness, similar to how one would support a close friend.[12] Mindfulness is an important mediator of self-compassion because, in order to respond with kindness, one must first acknowledge personal suffering through a mindful lens.

Participants frequently noted that learning self-compassion played a significant role in learning not to seek external validation through their career. This was particularly important when a mistake was made or things didn't turn out as expected, as participants reported a tendency to blame themselves in these situations. Practicing self-compassion was imperative to accepting mistakes, learning, and moving forward rather than spiraling into a cycle of shame and self-blame. Perhaps most importantly, developing self-compassion helped participants set realistic expectations for themselves in tough situations, accept their personal limits based on current levels of knowledge, and training, and reduce levels of imposter syndrome.

Nearly all participants reported that the transformative self-knowledge gained from their mindfulness practice enhanced their professional sense of self. Learning to seek internal validation was imperative for reducing feelings of stress, anxiety, and burnout, and significantly contributed to remaining in equine practice.

6. Tool Number 2: Perspective Taking

Perspective taking is defined as the ability to see a situation through another person's point of view and is an important component of developing empathy and building relationships.[13] Particularly in physicians, perspective taking has been linked with improved patient care, improved physical well-being, and has a positive protective factor against burnout.[14] This can easily extend to veterinary medicine, as there is often significant dissonance between how a veterinarian would like to treat an animal and what the owner may want or can realistically afford. This can create a stressful situation, particularly for young practitioners, making the skills of nonjudgment and perspective taking important. Reframing clinical expectations away from "getting the right answer" to "making a difference for this pet and this person" can significantly change how veterinarians find success in their days. This not only expands the range of possible outcomes available to the veterinarian and client but helps to reduce the stress associated with owner constraints.

A key benefit of perspective taking is improved clinical decision making; learning to "think outside the box" was a skill that most practitioners were able to develop with mindfulness. Participants reported they were able to make more informed, pragmatic, and ethical decisions leading to more positive outcomes with satisfied clients. Mindfulness appears to impact decision making by regulating attention on the present moment, allowing for fair assessments of the perspective of all parties involved, and engaging in enhanced cognitive ability to make unbiased and ethical decisions.[15] In equine medicine, this can lead to improved clinical outcomes for patients, less judgment of owner decisions, and improved compassion for individual circumstances. Veterinarians reported being more at peace with their decisions and carrying less resentment, anxiety, and fear of decision making, particularly when limited by owner financial constraints. Interestingly, some participants noted that this appeared to mitigate the effects of compassion fatigue, highlighting an important area of future research regarding the impacts of mindfulness.

Curbing Ruminative Thoughts

Rumination is a coping mechanism that involves excessive focus on unwanted thoughts. This may include recurrent analysis of situations with negative outcomes, stress-induced thinking associated with recent interactions, searching for meaning in negative situations, or overanalyzing thoughts, decisions, and actions.[16] This is particularly important for veterinarians as the tendency to replay clinical cases, outcomes, and interactions with owners is common. As the professional expectations of veterinary school often set veterinarians up to seek perfection and carry unrealistic expectations of themselves and their abilities, rumination becomes a key coping mechanism that many veterinarians use to deal with the disconnect between expectations and reality.

Rumination is perhaps one of the biggest hindrances to mindfulness and present-moment awareness, as by definition ruminative thoughts are replaying past or future events. The combined ability to see a broader perspective while practicing nonjudgment of self was found to be a powerful tool for interrupting distressing thought patterns. Mindfulness appeared to influence this by allowing people to recognize their thought patterns when they occurred, learn to nonjudgmentally assess such thoughts and differentiate facts from fiction (i.e., "the story I'm telling myself vs the truth"), practice self-compassion, and be able to see how their thoughts fit into the bigger picture. Veterinarians described a newfound ability to let go of situations by shifting the internal dialogue toward less reactive and more compassionate thoughts. This reduced stress levels, allowed for greater professional satisfaction, and allowed veterinarians to enjoy their personal time without being distracted by distressing, repetitive thoughts of work.

7. Tool Number 3: Drawing and Honoring Boundaries

Learning to form and honor structural, emotional, and social boundaries, was an important theme that emerged across nearly all interviews. Boundaries are particularly important for equine veterinarians as their work life has a much higher tendency to merge with their personal life, and learning to integrate work and life in a sustainable way is important for well-being, resilience, and career longevity. Many individual differences exist on the continuum of acceptable boundaries, but mindfulness consistently facilitated the development and understanding of what works for an individual in practice.

Separating Work from Life by Managing the Transition Between Them

In Dr. Grice's 2020 survey,[2] 58% of vets leaving practice cited excessive work hours and lifestyle as the main reason. Interestingly, despite being satisfied with their career choices, most participants still felt they didn't have an acceptable work–life integration. That said, mindfulness taught them to reframe their perspective on their work–life integration, draw boundaries around what was acceptable and unacceptable, and most importantly, be present when engaged in both personal and professional time.

For this group of veterinarians, their professional and personal lives appear to exist in separate spheres that don't necessarily compete with each other as expected in the traditional definition of work–life balance. Integrating work and life successfully required respecting the boundaries of both spheres, being present and in the moment when engaged in either aspect, and quickly transitioning between spheres with awareness when necessary. This resulted in higher personal and professional satisfaction from both aspects of life, even if not fully balanced. Participants reported that mindfulness was important in facilitating their ability to accomplish this by learning present-moment awareness, and being able to do so was a major step toward finding peace and longevity in equine practice.

Creating a Practice That Works

The art of saying no is an important skill that many veterinarians struggle to learn. Many participants discussed the difficulty of saying no to clients, particularly early in their career, and how this often led them to overextending their physical and emotional boundaries. Interviewees reported that mindfulness helped them to acknowledge and prioritize their own needs, and this facilitated drawing boundaries and saying no when necessary. This led to more control over how they spent their time, limited interactions with bad clients who were emotionally and financially draining, decreased tolerance for clients who were verbally abusive or unreasonable, and provided less guilt or fear of potential consequences when saying no. Most importantly, saying no allowed veterinarians to align themselves with great clients who shared their values and respected their professional relationship. This had a direct impact on lasting professional fulfillment and a desire to stay in practice.

8. Tool Number 4: Life and Career Resilience

Mindfulness has been shown to predict resilience through the development of self-compassion,[4,17] positive affect,[18] and nonjudgmental awareness,[4] and participants emphatically agreed that mindfulness was a significant contributor to personal measures of resiliency. Although there are numerous definitions of resiliency in the literature, to this population, resilience was defined by learning to believe in a future that is good.

Believing in the Future to Be Good

Allowing oneself to believe in a future that is good, despite difficult personal circumstances in the moment, appears to be an important predictor of resiliency. Although only a small number of participants reported suicidal thoughts at some point in their career (4/14), nearly all could recall very difficult times when they were not sure how to move forward. Many believed that

mindfulness allowed them to find a renewed passion for life by learning to believe in the future. This is particularly important for veterinary professionals given the increased tendency for suicidal ideation. Mindfulness has been shown in the general population to be a protective tool for curbing suicidal ideation through the development of a "zest for life,"[19] indicating that mindfulness-based interventions and resilience training may play a role in helping to combat veterinary suicide.

Career Longevity

Linked with resilience is the concept of career longevity. Given the unprecedented rate of attrition from equine veterinary medicine, career longevity was the initial focus of this research. Participants unanimously agreed that mindfulness has in part extended their career to date, and in many cases, mindfulness completely redefined participants' view of equine practice such that they never want to stop. This seemed to be facilitated by finding joy in practice, reigniting a passion for practice, being able to maintain perspective on work–life balance, and perhaps most importantly, gaining perspective on what individuals need on a personal level to be successful.

9. Tool Number 5: Improving Personal and Professional Well-Being

Previous studies have suggested that the main factors that contribute to veterinary well-being include work environment, degree of autonomy, and levels of work. However, in this research, well-being was described as being influenced by factors that focused less on career and more on participants' approach to life in general. These included developing a new focus in life, reduced negative affect, and improved physical health.

A New Focus in Life

When asked what mindfulness has done for them, participants frequently referred to a newfound focus in life. This focus was abstract and difficult to define but appeared to be developed by learning to take care of oneself and "finding a better way to do life." Vets commented that mindfulness "changed my brain and my approach to life," "let me be in control of my own thoughts, actions, words, and behaviors," "helped me learn to prioritize me," "helped me learn to accept where I am in life," "helps me understand what is truly important," and "makes me a better person and a better doctor." There was an overwhelming sentiment that mindfulness was inextricably tied to participants' overall well-being, and this greatly contributed to their desire to stay in equine practice.

Reduced Negative Affect

Negative affect refers to one's subjective degree of distress and can include states of anger, sadness, anxiety, guilt, and fear.[20] This group of veterinarians was prone to negative affect at points in their career, with many reporting pervasive feelings of sadness, anger, guilt, and shame prior to adopting a mindfulness practice. Although these feelings did not necessarily go away, mindfulness provided a tool to appropriately deal with these feelings so that they were less taxing to their mental health and well-being. Interestingly, negative affect has been shown to positively correlate with increased work hours and poor work–life integration (workaholism),[21] an important point for equine veterinarians to consider. Mindfulness has been shown to combat negative affect,[21] and a similar trend was seen among participants, as many reported feeling less angry, less resentful, and less emotionally reactive. Particularly in regards to work–life balance, reduced levels of negative affect helped veterinarians accept their work–life balance rather than resent the profession for what it demands. This positively influenced participants desire to stay in practice long term despite long hours and difficult working conditions.

Improved Physical Health

Health care workers with high levels of stress are prone to fatigue, poor sleep habits, heart and blood pressure problems, premature aging, cancer, mental health issues, and other health concerns.[22] Mindfulness has been shown to be an effective treatment for a range of similar health conditions,[10] and a number of participants reported improved physical health as a result of their mindfulness practice. The reported physical benefits included reduced blood pressure, improved sleep patterns, improved physicality at work, improved ability to ward off or heal from work-related injuries, reduced back pain, and reduced body tension. Most participants felt that mindfulness allowed them to find an appropriate balance in life such that they could preserve their physical health for the long haul. Especially given equine veterinarians' propensity to work despite physical challenges,[23] the perceived physical health benefits facilitated through mindfulness training positively impacted both subjective well-being and career longevity.

10. Conclusion and Practical Implications for Equine Practice

It is well known that equine veterinarians struggle with mental and physical health challenges that increase their risk for burnout and leaving equine practice. This is the combined result of personal, professional, and industry stressors that need to be addressed to support veterinarians over the long term. Although achieving substantial change in the industry is beyond the scope of this paper, this research clearly supports the use of mindfulness in changing how personal, professional, and industry stressors affect an individual veterinarian. This group of veterinarians described substantial improvements in subjective well-being, resiliency, and career longevity by cultivating the tools required to create a sustainable career. Major benefits included developing a professional identity through mindful self-compassion and nonjudgment; broadening one's perspective, leading to improved clinical decision making and a

healthier perspective on both career and personal life; creating a sustainable practice with boundary setting; reframing work–life integration to be in the present moment and allow for maximum fulfillment from both aspects of life; and cultivating a profound inner strength and personal measure of resiliency.

In conclusion, this research reflects the views of a group of passionate, mindful equine veterinarians who are not only personally and professionally satisfied, but who have no desire to leave equine practice. Given the issues facing equine practice, there is no greater benefit for veterinarians, highlighting the potential impact of mindfulness training early in one's career to support long-term health, wellness, and career success.

Limitations of this research include a gender bias toward female veterinarians predominantly in the United States, where work attitudes and perceived work stressors are similar. Although younger generations of equine vets are largely female, there is a large proportion of practicing male vets in other parts of the world that this research does not aptly represent. Furthermore, given the qualitative nature of this research, there is a principal researcher bias in data interpretation and the possibility that participant responses were affected by the researcher's presence. As there is no statistical representation, all conclusions represent the principal researcher's interpretation of the data, and no statements can be made about causality.

11. Resources

Undertaking a mindfulness practice can be initially overwhelming, but it is important to remember that mindfulness is a skill that needs to be learned and practiced regularly. There are numerous books and apps available that provide meditation training and prerecorded meditations to practice, in addition to scientifically backed courses for mindful stress reduction. Dr. Jon Kabat-Zinn, creator of the Center for Mindfulness in Medicine, Health Care and Society, has published many books on the topic and created the Mindfulness Based Stress Reduction program. This 8-week program, initially developed for the University of Massachusetts Medical Center, has been widely researched for its numerous benefits on stress reduction, physical health, and mental health, and is a great resource for people looking to get started. It is widely accepted as standard training in medical education for doctors, nurses, and psychologists.

For those that find meditation intimidating, yoga is an excellent place to learn about mindful movement and slowly ease into meditation concepts. There are many ways to practice mindfulness that don't necessarily involve meditation, so trying different techniques (meditation, yoga, tai chi, breathing exercises, body scan techniques, etc.) that promote focused, present-moment awareness is important in understanding what works for an individual.

Acknowledgments

The principal author thanks Dr. Elizabeth Kurucz (Associate Professor of Leadership and Sustainability, Lang School of Business, University of Guelph) for her guidance and oversight of the research process. An eternal thank you to the research participants for their time, expertise, and inspirational stories of success in equine practice.

Declaration of Ethics

The Authors have adhered to the policies and procedures outlined by the Research Ethics Board (University of Guelph) for the protection of human participants in addition to the Principles of Veterinary Medical Ethics of the AVMA.

Conflict of Interest

The Authors have no conflicts of interest.

References

1. American Association of Equine Practitioners. Economic report. 2019. https://aaep.org/sites/default/files/Documents/2019%20FINAL_AMVA_AAEP_Equine_Report.pdf. Accessed Nov. 21, 2020.
2. Grice A. Leaving equine veterinary practice. Unpublished data. 2020. https://equimanagement.com/articles/leaving-equine-veterinary-practice. Accessed Nov. 21, 2020.
3. Kabat-Zinn J. Mindfulness based interventions in context: past, present and future. *Clin Psych* 2003;10:144–156.
4. McArthur M, Mansfield C, Matthew S, et al. Resilience in veterinary students and the predictive role of mindfulness and self-compassion. *J Vet Med Educ* 2017;44:106–115.
5. Correia HM, Smith AD, Murray S, et al. The impact of a brief embedded mindfulness-based program for veterinary students. *J Vet Med Educ* 2017;44:125–133.
6. Pontin EE, Hanna J, Senior A. Piloting a mindfulness-based intervention to veterinary students: Learning and recommendations. *J Vet Med Educ* 2020;47:327–332.
7. Dowling P. Mindfulness training improves attention and reduces rumination in veterinary medicine students. Presented at: International Veterinary Social Work Summit; April 13, 2013; Le Conte, TN.
8. Bell MA, Cake AM, Mansfield CF. Beyond competence: Why we should talk about employability in veterinary education. *J Vet Med Educ* 2018;45:27–37.
9. Gibson DM, Dollarhide CT, Moss JM. Professional identity development: A grounded theory of transformational tasks of new counselors. *Couns Educ Superv* 2010;50:21–37.
10. Kabat-Zinn J. *Wherever You Go, There You Are: Mind-fulness Meditation in Everyday Life*. New York, NY: Hyperion; 1994.
11. Keng SL, Smoski MJ, Robins CJ. Effects of mindfulness on psychological health: A review of empirical studies. *Clin Psychol Rev* 2011;31:1041–1056.
12. Neff KD, Dahm KA. Self-compassion: What it is, what it does, and how it relates to mindfulness. In: Ostafin B, Robinson M, Meier B, eds. *Handbook of Mindfulness and Self-Regulation*. New York, NY: Springer; 2015:121–137.
13. Healey ML, Grossman M. Cognitive and affective perspective-taking: Evidence for shared and dissociable anatomical substrates. *Front Neurol* 2018;9:491.
14. Lamothe M, Boujut E, Zenasni F, et al. To be or not to be empathic: The combined role of empathic concern and perspective taking in understanding burnout in general practice. *BMC Fam Pract* 2014;15:15.
15. Liu S, Liu Y, Ni Y. A review of mindfulness improves decision making and future prospects. *Psych* 2018;09:229–248.
16. Deyo M, Wilson KA, Ong J, et al. Mindfulness and rumination: Does mindfulness training lead to reductions in the

ruminative thinking associated with depression? *Explore (NY)* 2009;5:265–271.
17. Sünbül ZA, Güneri OY. The relationship between mindfulness and resilience: The mediating role of self compassion and emotion regulation in a sample of underprivi leged Turkish adolescents. *Perso Individ Dif* 2019;139: 337–342.
18. Montero-Marin J, Tops M, Manzanera R, et al. Mindfulness, resilience, and burnout subtypes in primary care physicians: the possible mediating role of positive and negative affect. *Front Psychol* 2015;6:1895.
19. Collin KR, Stritzke WG, Page AC, et al. Mind full of life: Does mindfulness confer resilience to suicide by increasing zest for life? *J Affect Disord* 2018;226:100–107.
20. Watson D, Clark LA, Carey G. Positive and negative affectivity and their relation to anxiety and depressive disorders. *J Abnorm Psychol* 1988;97:346–353.
21. Aziz S, Bellows G, Wuensch K. The relationship between workaholism and negative affect: Mindfulness matters!. *Int J Ment Health Addiction* 2021;19:1605–1614.
22. Irving JA, Dobkin PL, Park J. Cultivating mindfulness in health care professionals: A review of empirical studies of mindfulness-based stress reduction. *Complement Ther Clin Pract* 2009;15:61–66.
23. Loomans J, Weeren-Bitterling M, Weeren P, et al. Occupational disability and job satisfaction in the equine veterinary profession: How sustainable is this “tough job” in a changing world? *Equine Vet Educ* 2008;20:597–607.

Boundaries: Telephone Time and Wellness in Equine Practice

Mary Beth Whitcomb, DVM, MBA, ECVDI (LA-Associate)

Time spent on the phone with horse owners is often excessive in equine practice. Prolonged discussions can be exhausting and are infrequently billed, reducing the perceived value of our expertise. Strategies to reduce phone time will be presented, including the use of communication policies to establish and enforce boundaries while improving financial viability and wellness within a practice.
Author's address: PO Box 904, Woodland, CA 95776; e-mail: mbwhitcomb@ucdavis.edu. © 2022 AAEP.

1. Introduction

It goes without saying that some degree of communication with horse owners is a necessary part of doing business in equine practice, but one would be hard-pressed to find an equine veterinarian who wished to spend *more* time on the phone with current or potential clients. This is especially true for demanding or high-maintenance clients that call multiple times per day, expect every question to be answered without charge, or those where we might hope the call-back goes straight to voicemail. Some of us may even employ an app for just that purpose.

For most equine veterinarians, time spent on the telephone is not billed, yet we often spend significant portions of our day providing advice at no cost to clients. Time spent on excessive or prolonged calls is not only financially taxing but also emotionally and even physically burdensome. One does not need to read many social media posts within private veterinary groups to appreciate that such conversations contribute to burnout, lack of overall well-being, and even attrition from equine practice. Compared to our small animal counterparts, equine veterinarians spend the least amount of time on billable tasks, the opportunity cost of which is not insignificant. Time spent texting or answering emails can be equally laborious, even more so if after-hour boundaries have not been established or enforced. While the focus of this presentation relates to telephone time, much of what will be discussed can be extrapolated to other forms of communication.

As part of a large academic practice for over 2 decades, issues related to telephone time and wellness became an increasingly significant concern over the years. The large number of residency programs within academia naturally yields a high turnover of doctors and exposure to many communication styles. Most house officers are early in their career and highly focused on developing specialty expertise. This is not to suggest that all young practitioners lack communication skills, as some are naturally gifted. The issue does, however, seem to be more prevalent among young veterinarians, even more so with those well indoctrinated into equine practice culture where the

NOTES

client comes first 24/7/365. As we address the problem of attrition from equine practice, it is important for practice owners and senior associates to be aware of issues related to excessive communications and to mentor accordingly. In multidoctor practices, new associates or those early in their career rarely share these concerns with senior clinicians, often due to their perception that communication at all costs is expected for client retention.

The purpose of this presentation is to increase awareness of this issue, why it is important, and to present ways to reduce telephone time/nonbilled hours in equine practice. Although based on experiences within a large academic hospital, excessive telephone time can be equally problematic in large, small, and even solo doctor practices, and strategies presented can be employed across practice types. This discussion is not to devalue the need for quality client communications within equine practice but to address the problem of excessive or prolonged conversations that reduce our ability to take care of our practice as well as our own professional and personal needs.

2. How Did This Evolve?

Excessive telephone time is rarely an issue in small animal practice. With appointments stacked every 15 to 30 minutes, there is simply no time for prolonged phone calls, even more so when one considers the sheer number of cases seen in one day. Technician phone calls (or resident/student phone calls in academia) are a much more accepted means of communication within small animal practice. In contrast, horse owners have been conditioned to expect to speak *only* with a veterinarian and frequently only with *their* specific veterinarian. While spending even 15 minutes on the phone with a small animal client is almost unheard of, it is not uncommon for some equine veterinarians to engage in 30- to 60-minute phone calls with horse owners. As a result, we have trained our clients that it is acceptable to remain on the phone until every major or minor question is answered, often in the belief that such a show of dedication will result in client loyalty and make them less likely to switch to a competitor. Perhaps we think we "have the time" because we are driving between calls. Regardless of the rationale, we are effectively devaluing our time and expertise. And the next time they call, they will likely expect the same level of attention whether we are driving or not. Admittedly, this issue is not new; it has been part of equine veterinary culture for decades.

The difference between practice types was well illustrated at last year's AAEP convention during the panel presentation of equine veterinarians who had left equine practice.[1] One of the panelists had recently transitioned from equine to a small animal practice in the same geographic area. She noted that clients who previously had no qualms contacting her via phone/text at any hour regarding their horse no longer did so when they had concerns about their dog/cat as clients of her new, small animal practice. It is noteworthy that these clients exhibited significantly different behavior *without* the panelist establishing any "new" boundaries as a small animal veterinarian; strong evidence that it is possible and feasible to retrain our clients, but we must also retrain ourselves as equine veterinarians.

3. Why We Must Address the Problem

What is the opportunity cost of our time? The concept of opportunity cost is one of the first to be taught in any business curriculum, yet it is often overlooked by many professionals. Opportunity costs are what is given up when we instead choose to perform a different task. For example, if we spend an hour on the phone during work hours, we are giving up billable tasks, such as lameness exams, taking radiographs, injecting joints, and so on. The value of that opportunity cost is what we could have earned during the same time period, and that amount defines what we *should* be charging for our telephone time. Even without a paying client, we should not be giving away this time unnecessarily. Opportunity costs could be any number of important tasks necessary for our practice or our personal well-being, including downtime with family or friends or just relaxing for a few minutes. It is not unusual to hear stories of equine veterinarians pulled away from dinner to talk to the same client with whom they already had multiple conversations during the day. There is little doubt on a repeated basis that such instances contribute significantly to burnout within equine practice.

It is equally important to acknowledge that when we give away our time, we are effectively eroding our expertise and reducing our value proposition, not only in the eyes of clients but also to each other as colleagues. It could easily be argued that clients who keep us on the phone for extended calls have already shown that they do not respect our time, even if we perceive them as "nice." If we consider our physician counterparts, most of us would be hard-pressed to recall any telephone conversations with our own doctor. And if such phone calls occurred regularly or were prolonged, we might wonder why they were not busier and may even question their expertise. While COVID-19 may have normalized telemedicine within human medicine, and to some degree within veterinary medicine, most veterinarians have not kept up in our ability to capture these costs. We must move away from the thought that "if I charge for telephone consults and my competitor does not, I'm going to lose that client." Instead, we must frame that conversation differently; if we don't charge, we are further jeopardizing the health of our industry.

As mentioned previously, this issue extends beyond telephone time. When combined with texting, e-mail, and social media, unbilled time is a significant, and often overlooked, contributor to poor salaries in equine practice compared with other sectors.[2] When we routinely give away significant portions of our time, we

also model that behavior to new equine veterinarians. Not only do we perpetuate the problem, but we limit our ability to pay them a competitive or even livable wage. Proposed solutions to salary issues routinely focus on raising prices, with the counterargument that clients will leave for a less expensive competitor, assuming there is one. If instead we begin to truly value our expertise and charge appropriately for all services performed, including bill capture at the time of service, we will reduce our subsidization of horse ownership and may be able to offer more competitive salaries to our new entrants.

4. How to Address the Problem

Recognize the Emotional Driver

If this discussion resonates for you or others in your practice, the first step is to recognize which emotion is triggered that contributes to the behavior. Perhaps it is a strong desire to feel liked, where the offender might think, "If I push the client off the phone, they won't like me. If I don't answer ALL their questions, they'll go to someone else who will." Perhaps it is expected within a practice to do anything to keep a client happy (i.e., "If I answer all their questions, they will respect my knowledge and remain loyal to the practice"). Getting to the root of the problem for an individual veterinarian is important. Is it truly inexperience, a desire to prove their dedication to clients, or a need to impress others with their dedication to equine practice in general or all of the above? This is an especially important consideration for practice owners or other associates who may already be efficient/effective in their communications. Merely telling an associate to reduce their time on each phone call is unlikely to be effective without understanding the emotional driver behind the behavior.

Set Goals

What is the appropriate phone call duration? That will depend on each practice, but a goal should be set. For anyone highly effective in their conversations, this might be less than 5 minutes. For others, setting a goal of no more than 15 minutes when a long phone call is anticipated may be a good place to start. Look at a clock when the phone call begins and watch the minutes. It will help.

Listen and Practice to Develop Your Skill Set

Perhaps you lack the skill set to appropriately end or shorten phone calls. Every group practice likely has someone who is an excellent and efficient communicator. Listen to those colleagues during their phone calls or in-person communications. Recognize and emulate what they do to be so effective. Do they prep a client at the beginning of their call for a limited discussion; that they only have a few minutes to provide an update or to discuss next steps? Do they transition the phone call into an appointment, especially with an exceptionally needy client? Ask for communication tips within relevant social media groups. These groups can be a treasure trove of advice and experience. Practice any key phrases out loud by yourself so that it becomes second nature. Practice again before making that callback.

Learn to Transition Calls to Appointments

It is important to recognize that every client question or thought does not need to be addressed in one phone call (or e-mail or text). This does not make anyone a "bad" veterinarian. If a client routinely has excessive questions, inform them you only have a specific timeframe before you have to see your next patient (even if you do not) and that they should prioritize their most important questions. If you feel an appointment is necessary, then book that appointment where you can bill for that consult time and answer questions appropriately: "Hi Ms. Smith, I have just a few minutes before my next appointment, but I wanted to give you a quick update that Sassy's bloodwork was slightly abnormal, so we'll need to perform that ultrasound exam we discussed. I'll have my receptionist contact you to schedule an appointment. That way you'll have my full attention to answer all your questions."

Alternatively, if a virtual consult is appropriate, then ask if they would like to make a telehealth appointment and share the fees with them. For those of us resistant to this idea, it may help to consider that equine veterinarians have been performing virtual consultations for decades; we just haven't been charging for this service.

Communications Policy

Every equine practice would benefit from developing a basic communications policy, even solo practitioners. Such a policy can be posted on the practice webpage and/or social media pages where it can easily be referred to if and when a client abuses your time. This policy should set clear expectations of what you are able to provide and is an excellent tool to fall back upon when a boundary-pushing client complains that they are not getting what they need.

First and foremost, the communications policy should set expectations for appropriate client behavior with *all* members of your *team* (use such terminology even if you are a one-person practice). At a minimum, it should state that all communications must be collegial and respectful; that abusive or disruptive behavior will not be tolerated and can result in client termination. Offenses could include abusive language, social media attacks, excessive after-hours texting, or inappropriate use of a personal cell phone (if that is not the accepted means of professional communication).

The policy should clearly state the type(s) of communication allowed by the practice (office phone, text, etc.) for regular appointments, emergencies, and information calls. For example: "Requests for appointments can only be made by calling (XXX)867-5309. Please note that requests made via Facebook messenger or other means of social media cannot be answered." Clients may still try to do so, but if you

miss any requests and that client gets upset, the communications policy is an easy tool to fall back upon, while also depersonalizing the issue at hand.

In hospital settings, communications policies should also state the expected number of daily updates for inpatient cases. For example: "Updates will be provided once daily for stable, noncritical inpatients; 1–2 times per day as appropriate for ICU patients." The policy should also address how you will respond to nonemergent communications or information calls. Underpromise and overdeliver is key. Consider that information-only calls might be answered on a time-permitted basis, especially if you are an established busy practice. For nonemergent inquiries, calls returned within 24 to 48 hours is a reasonable expectation. Goals should be achievable, and all doctors and staff should understand and abide by all aspects of the policy. Relatedly, it is critical that all staff be involved in creating communication policies, including receptionists who are often the first point of client contact and can be pressured by, or even side with, a difficult client. Lastly, when sharing these boundaries with clients, it is not necessary to elucidate the rationale behind them; a defense mechanism seldom engenders empathy from an offending client.

While there are many types of problem clients, those expecting excessive communications throughout the day are particularly challenging and often become demanding and even unreasonable. This may be a longstanding client, a trainer with a large barn or one perceived as highly valuable to the practice in some capacity. For this type of client, it is even more important to be able to refer to your communications policy. It may be helpful to remember that this type of client often prevents you and your team from providing care to all patients and that no one client should inhibit your ability to do so. This situation can occur in any type of practice, from solo to large multidoctor practices.

5. Conclusion

It is hoped that this discussion will help to improve an issue that is all too common but infrequently addressed within equine veterinary medicine. As equine practice continues to grapple with attrition, it is important to become aware of *all* issues that contribute to burnout, job dissatisfaction, reduced financial viability, and low salaries. Telephone time is one of many problems within the equine segment of veterinary medicine, and strategies to reduce this time are critical for financial, emotional, and mental well-being.

Acknowledgments

Declaration of Ethics

The Author has adhered to the Principles of Veterinary Medical Ethics of the AVMA.

Conflict of Interest

The Author has no conflicts of interest.

References

1. Breidenbach B, Buchert M, Norman TE, et al. What happens: Panel discussion with equine practitioners not in equine practice. *Am Assoc Equine Pract* 2021 Annual Convention (Audio Recording).
2. Bain B. Employment, starting salaries, and educational indebtedness analyzed by gender for year-2020 graduates of US veterinary medical colleges. *J Am Vet Med Assoc* 2021;258:865–869.

The Role of Magnetic Resonance Imaging

Michael Schramme, DVM, CertEO, PhD, HDR, MRCVS, DECVS, DACVS, DECVSMR, AECVDI*; and Marieke Zimmerman, MVM, DECVDI

Authors' address: Ecole Nationale Vétérinaire de Lyon VetAgro Sup – Campus Vétérinaire, University of Lyon, France; e-mail: michael.schramme@vetagro-sup.fr. *Corresponding and presenting author. © 2022 AAEP.

1. Introduction

Lameness is one of the most common problems facing equine veterinarians. Properly and effectively diagnosing and treating these musculoskeletal ailments can be a real challenge, even to the most experienced clinicians. However, a proper and correct diagnosis is an absolute requirement for an appropriate choice of treatment(s) and an accurate prognosis. This goal can only be achieved by following a meticulous and systematic approach to lameness diagnosis that encompasses each of the necessary logical and chronological steps to complete the full picture of information that is necessary to resolve this clinical puzzle with the help of the concrete observations of diagnostic imaging that form the basis of the diagnostic process.

The last 20 years have seen tremendous growth and advancement in equine diagnostic imaging, especially with the advent of technical improvements in radiography and ultrasonography, the wider accessibility of cross-sectional imaging modalities (magnetic resonance imaging [MRI] and computed tomography [CT]) and the arrival of positron emission tomography (PET). With this vast and frankly overwhelming array of diagnostic imaging tools at the practitioner's disposal comes the need to better understand each of the available imaging modalities. Specifically, the equine practitioner must be able to clearly identify which imaging modality will provide the best information for an accurate diagnosis in each specific lameness case. This paper deals specifically with the factors involved in the choice of the correct imaging modality/modalities appropriate for the patient, in particular the choice of MRI.

2. Clinical Examination and Diagnostic Analgesia

MRI is indicated when a lameness problem has been localized to an anatomical area (e.g., the foot) and other imaging modalities have failed to provide an unequivocal diagnosis. Lameness should first be localized to an anatomical area because unlike nuclear scintigraphy, MRI is not a screening technique. Accurate knowledge of the localization of the cause of lameness as well as the pitfalls encountered with the technique and interpretation of diagnostic anesthesia is indispensable when interpreting MR images.[1] These rules apply even in the face of newer, more powerful 3T magnets with faster scanning times now allowing routine screening of the foot, pastern, and fetlock regions in horses with distal limb lameness with only short general anesthesia times. The systematic process leading up to the choice of imaging modality is illustrated in Fig. 1. The steps involved in this process are listed in Table 1.

Many steps of this process rely heavily on subjective clinical impressions that may lead to inaccurate conclusions. The development of lameness measurement techniques with inertial sensors[2] has allowed much progress in this area. Pitfalls of interpretation of the

NOTES

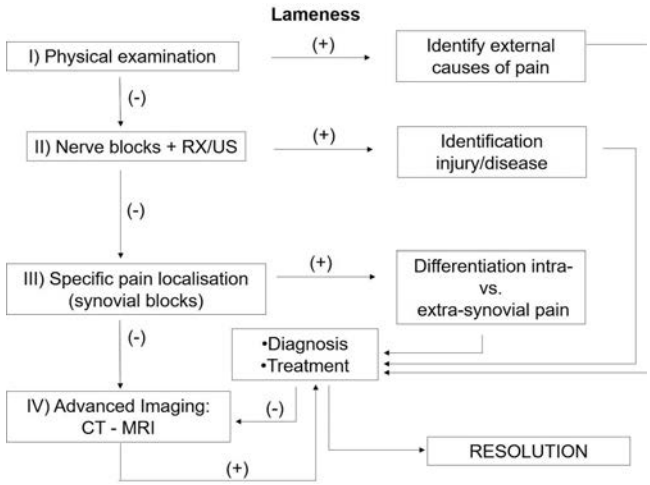

Fig. 1. Flow diagram showing the systematic step-by-step process of a lameness examination, including the choice of imaging modality. RX, radiography; US, ultrasonography; CT, computed tomography; MRI, magnetic resonance imaging.

results of diagnostic anesthesia are numerous and must be well-known by the lameness clinician[3] because localization of lameness is paramount in determining which imaging modality is most appropriate (Fig. 1).

3. Imaging Modalities

MRI is not a substitute for in-depth clinical investigation and conventional imaging techniques, and many causes of lameness can continue to be diagnosed without MRI. Nonetheless, the use of MRI has highlighted the limitations of both radiography for imaging bone and ultrasonography for imaging soft tissue lesions. A brief review of the currently available imaging modalities in equine sports medicine and lameness practice is presented in Table 2.

4. Magnetic Resonance Imaging

General Principles

The generation of an MR image is based on the movement of hydrogen atoms generating a measurable electrical current in the body. MRI produces a gray-scale image of tissue hydrogen protons by placing them in a strong magnetic field, exposing them to a radiofrequency pulse and measuring the MR caused in the tissues in response to this pulse. The imaging information obtained is based on the structure and biochemical environment of those hydrogen atoms in the tissues.

Table 1. The 7 Required Steps for an Accurate Diagnosis of Orthopedic Injury

1. A detailed history regarding the perceived circumstances and context of the lameness problem
2. Correct identification and accurate grading of the lameness
3. A thorough physical examination
4. Accurate interpretation of the improvement (or lack thereof) following the use of diagnostic anesthesia
5. A rational choice of the available imaging modalities most likely to reveal the structural abnormalities of the injury causing the lameness
6. Accurate interpretation of imaging findings and their clinical significance
7. An ability to integrate/synthesize all of the above information into a plausible diagnosis

High-Field vs. Low-Field MRI

Both high-field and low-field magnets are used in equine practice, and it is important to know the differences between both systems. High-field magnets are superconducting, closed, cylindrical bore magnets with magnetic field strength in excess of 1 T (currently 1.5 T or 3 T), while low-field magnets are open, permanent magnets with a field strength below 0.5 T. Image quality and resolution increase with increasing magnetic field strength and increasing field homogeneity. Consequently, low-field systems generate less tissue signal, require longer acquisition times, and produce lower-resolution images with less uniform signal, less image detail, and more motion artefact than high-field systems. Even so, several studies have shown that low-field magnets are capable of producing adequate diagnostic quality images of the distal limb up to the carpus/tarsus,[4–6] and even of the stifle.[7] A similarly high lesion yield was reported in direct comparisons between high- and low-field magnets.[8,9]

Strengths and Weaknesses of MRI

Because of its unique mode of image acquisition and construction, it is essential to understand the factors that influence the MR signal characteristics that produce the diagnostic images and to learn the strengths and weaknesses of the technique. The advantages and disadvantages of MRI are summarized in Table 2.

Comparison of MRI and Other Imaging Modalities

In comparison with MRI, radiography is incapable of detecting cartilage abnormalities in horses with distal limb joint lameness. Radiographic abnormalities are also absent in many forms of subchondral or trabecular bone injury (e.g., bone contusions, bone edema, subtle or focal subchondral bone resorption; Fig. 2). Radiography, however, has better bone versus soft tissue contrast when compared to MRI and is therefore more sensitive for soft tissue mineralization (Fig. 3) and subtle bone contour changes like osteophytes, enthesophytes, and small osteochondral fragments. As bone has the same low-intensity signal as tendon, ligament, and fibrous joint capsule, osteophytes and entheseophytes or areas of dystrophic mineralization are frequently invisible on MR images if they occur in or near a tendon, ligament, or enthesis. Small osseous fragments or osteophytes may also remain invisible on MR images due to partial volume averaging across the width of the imaging slice if it is thicker than the fragment or bony

Table 2. Available Imaging Modalities for Equine Lameness Diagnosis with Their Mode of Action, Indications, Common Usages, Advantages, and Disadvantages

	Digital Radiography	Ultrasonography	Scintigraphy	Computed Tomography	Magnetic Resonance Imaging
Imaging Mechanism	X-ray attenuation with tissue penetration Visible on screen	Sound waves reflected from tissue interfaces form image No penetration of bone surfaces	Photo multiplier tubes detect radioactivity emitted by the skeleton after injection of radioisotope-labelled tracer	X-ray attenuation Rotating x-ray source Multiple cross-sectional thin slice images Multiplanar reconstruction 3D reconstruction	Gray-scale image of tissue hydrogen protons in a strong magnetic field Multiplanar cross-sectional imaging High-detail, high-contrast anatomic images No ionizing radiation
Image Detection	Bone density changes visible from 30% mineral change Fine detail of bone contour (osteophytes, enthesophytes, fragments) Little soft tissue information, except contrast tenography and arthrography	Soft tissue imaging Bony surface detail	3-phase imaging: blood flow, soft tissue injury, and alterations in bone metabolism Poor spatial resolution	Sensitive to subtle bone density changes Superior bone contrast and detail: fractures, joint surfaces, focal bone resorption, and proliferation Limited soft tissue information, except contrast enhancement	Best combination soft tissue/bone detail Superior soft tissue contrast and detail Good anatomic separation between tissues Fluid imaging: bone edema, tissue necrosis, and fibrosis
Common Use	First line imaging for bone and joint injury Prepurchase examination Radiographic screening: osteochondrosis and distal limb	Assessment tendon and ligament injury Wounds Monitor soft tissue healing	Screening tool in multilimb or subtle lameness to help determine source(s) of pain	Evaluation fine bone detail Blood flow in soft tissue injury Complex anatomy (skull, sinuses, and teeth) preoperative planning fractures Screening: short exam time whole limb up to elbow	Low- vs. high-field selection Mostly accessible to distal limb including carpus, tarsus Not a screening tool Staging of soft tissue healing Bone trabecular detail, density, and fluid Cartilage (with limitations)
Availability	Widely Portable	Widely Portable	Widely	Few hospitals	High field few Low field more
Patient Positioning	Standing Sedation	Standing Sedation	Standing Sedation	Standing Recumbent general anesthesia	Standing low field Recumbent high general anesthesia
Disadvantages	Late-stage disease recognition Lack of correlation with lameness Ionizing radiation	Difficult Operator and equipment dependent Subjective False positives and false negatives	Expensive Radiation safety Huge variation Poor sensitivity Poor lameness correlation	Expensive No bone fluid Poor soft tissue detail Ionizing radiation Need for specialist training	Expensive Time consuming Signal loss and motion artefact for standing Variable image quality Numerous imaging parameters Unfamiliar artifacts Need for specialist training

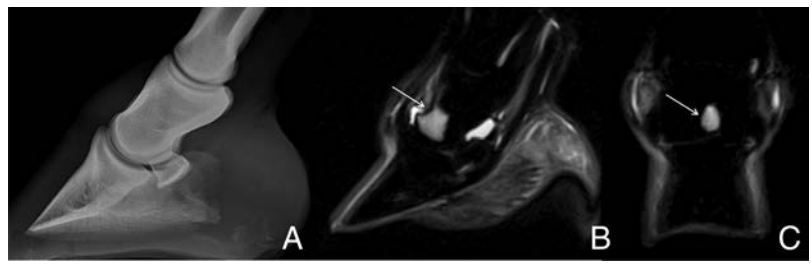

Fig. 2. Lateromedial radiograph (A) and sagittal (B) and frontal plane (C) short tau inversion recovery fast spin echo images (0.27 T) of the right foot of an upper-level showjumping pony with right fore foot lameness. Arrows indicate a markedly hyperintense bone marrow lesion in the dorsodistal aspect of the trabecular bone of the middle phalanx.

spur or if the fragment partially overlaps two adjacent slices.

Ultrasonography is limited by the hoof capsule in lameness of the foot. Ultrasonographic findings may be equivocal in lameness associated with the palmar/plantar soft tissues of the distal limb. Ultrasonography, however, gives a better representation of fiber pattern in tendons and ligaments and is not plagued by magic angle and flow artifacts. The ratio between T1 and T2/short tau inversion recovery (STIR) signal in MR images of tendons, on the other hand, can be used to determine whether an indolent ultrasonographic abnormality of the superficial digital flexor tendon (SDFT) is still "active" and poses a high reinjury risk.[10,11] One study found that horses whose hyperintense tendon or ligament lesions had resolved on STIR images were significantly more likely to be sound than horses whose lesions persisted on STIR images.[12] A combined ultrasonographic/standing low-field MRI protocol of transverse T1 and T2* gradient echo (GRE) and T2 and STIR fast spin echo (FSE) sequences has been proposed as the most accurate method of monitoring tendon healing with a view to a safer return to fast exercise in eventers.[11] Even though high-field MRI has been shown to be more sensitive than ultrasonography for diagnosis of subtle injuries of the suspensory branches and the distal sesamoidean ligaments,[13] ultrasonography can still be a useful adjunct modality alongside MRI. A concurrent ultrasonographic examination is always indicated in such cases to determine whether true fiber pattern abnormalities can be detected that correspond to the area of signal increase on low-field MR images and to try and establish a baseline T_0 image of the lesion that can be used to aid ultrasound-guided intralesional therapies but also to provide follow-up information without needing to repeat expensive MRI examinations. In spite of recent reports suggesting a reasonable correlation between ultrasonographic and MRI examinations,[14–16] results of ultrasonographic examinations frequently remain inconclusive. Both false positive and false negative ultrasonographic findings were common in comparison with high-field MRI for the collateral ligaments of the coffin joint (ultrasound sensitivity 27%),[17,18] the deep digital flexor tendon (ultrasound sensitivity 13%),[19] and the origin of the suspensory ligament in hind limbs (ultrasound sensitivity 66% and specificity 31%).[14,20] Ultrasonographic examination is therefore not considered a necessary first-line imaging modality if a low-field or high-field MRI examination is being considered in those areas where there is a poor correlation between both imaging modalities (e.g., the foot and the proximal suspensory region). However, in other areas where the results of ultrasonography can be equally or more reliable than those of a low-field MRI examination (e.g., the digital flexor tendon sheath, the distal sesamoidean ligaments, and the suspensory branches), it is advisable to perform ultrasonography prior to considering a low-field MRI examination. If a high-field MRI examination is planned, a first-line ultrasonographic examination is less necessary.

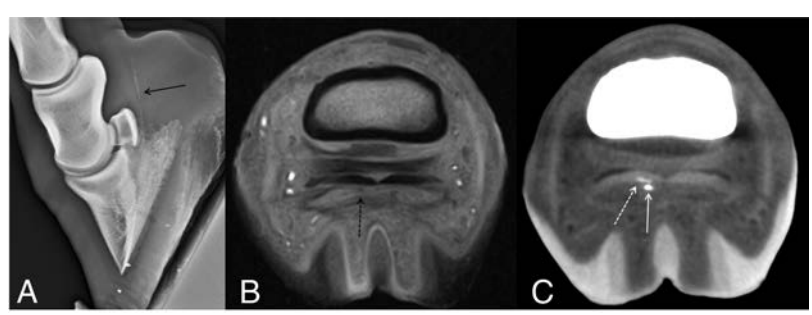

Fig. 3. Corresponding lateromedial radiograph (A), transverse 3D T1 gradient echo low-field MR (0.27 T; B), and contrast CT images (C) of the right foot of a horse with chronic foot lameness. Radiographic evidence of dystrophic mineralization is visible palmar to the deep digital flexor (black arrow), represented by a focally increased attenuation in the deep digital flexor tendon (dotted white arrow) and the distal digital annular ligament (white arrow) on the CT image. A corresponding area of low signal intensity on the MR image (black arrow) is much less conspicuous.

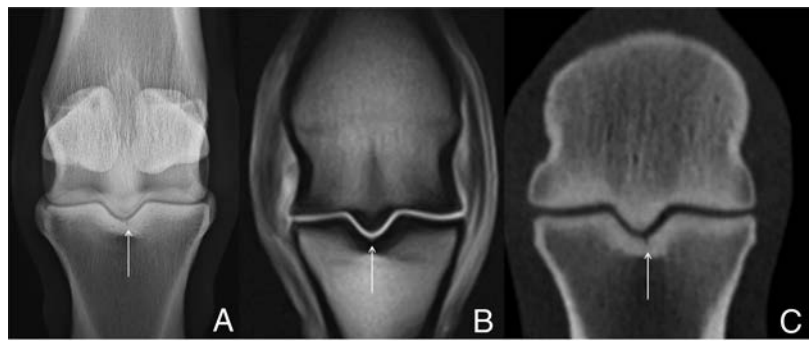

Fig. 4. Corresponding dorsopalmar radiograph (A), frontal 3D T1 gradient echo (0.27 T; B), and CT (C) images of the right fore fetlock of 3 different horses with a subtle linear area of subchondral bone resorption in the central part of the sagittal groove of the distal phalanx (white arrows) surrounded by mild sclerosis. The lesion is most conspicuous on the CT image.

Comparative studies between MRI and scintigraphy have been performed for 264 horses with foot lameness.[21] Scintigraphy had low sensitivity for deep digital flexor tendinopathy (19%), collateral desmopathy (15%), and navicular disease (24%) diagnosed with high-field MRI. The specificity of scintigraphy for these conditions was better with values above 90% for all three conditions. However, only 50% of horses with grade 3 navicular bone edema lesions showed increased radiopharmaceutical uptake on scintigraphic images.[21] It may be concluded that there is little added value of scintigraphy over MRI in horses with foot lameness.

In comparison with MRI, CT is unable to detect the presence of fluid or hemorrhage in bone. However, because of its superior bone detail and contrast and dependent on field strength and sequence selection of MRI, CT is generally better at evaluating fine bone detail than MRI. Moreover, the thin slices offer a high resolution making subtle trabecular thickening, subtle periosteal new bone formation, and subtle subchondral bone surface changes conspicuous on CT images well before they become visible on low-field MR images. For example, CT is more sensitive for early subchondral bone resorption and fissure formation in the sagittal groove of the proximal phalanx (Fig. 4).[22] Contrast enhanced CT may be useful in the identification of subtle but active soft tissue injuries that may not yet be visible on low-field MR images (Fig. 5). One study suggested that the sensitivity of contrast enhanced CT for deep digital flexor tendon injuries in the foot (85%) was better than that of low-field standing MRI (51%).[23] A lag period of several weeks to months may exist between the onset of lameness and the appearance of signal abnormalities indicative of tissue damage on low-field MR images, especially in the deep digital flexor tendon.[24] Such early developing tendon lesions may be more conspicuous on contrast enhanced CT images as they appear to enhance readily following injection of intravenous or intraarterial contrast when no abnormal MRI signal is visible yet. Reports have been contradictory on the value of MRI for evaluation of articular cartilage,[25,26] and recent studies have suggested that CT arthrography is superior to MRI for assessment of cartilage morphology and pathology.[27,28]

A few recent comparisons are available between PET imaging and low-field MRI of the foot and fetlock of horses.[29–32] It seems certain from the early observations that the functional properties and high sensitivity of both fluoride (F-NaF for bone remodeling) and glucose (F-FDG for metabolic activity) PET scanning have the potential to reveal subtle lesions earlier than other imaging modalities because functional changes in injured tissue precede the structural changes that are visible on CT and MRI. So far, such subtle lesions have included abnormalities of the navicular bone and of the entheses of the collateral ligaments, the

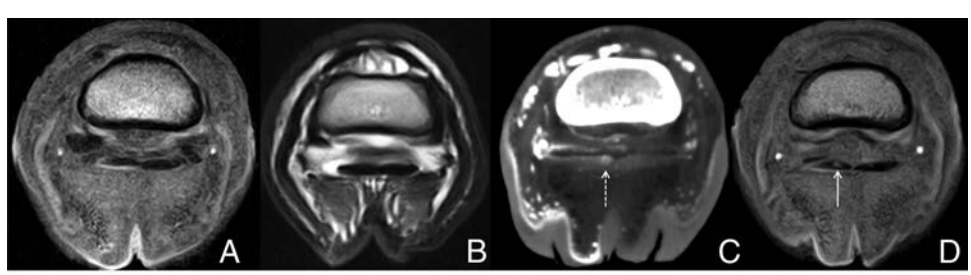

Fig. 5. Corresponding transverse 3D T1 gradient echo high resolution (A), 2D T2 fast spin echo (B), and contrast CT images (C) of the right hind foot of a 12-year-old dressage horse with a 1-week-old acute foot lameness. Contrast enhancement is visible on the dorsal aspect of the lateral lobe of the deep digital flexor tendon (dotted white arrow) without any concurrent signal increase on MR images. A core lesion was visible in the same location on the corresponding 3D T1 gradient echo high resolution image during a follow-up MRI examination 1 month later (D). All MR images were obtained with a 0.27 T low-field magnet.

chondrosesamoidean ligaments, and the deep digital flexor tendon in the foot, as well as the injuries of the palmar condyles and the proximal sesamoid bones in the fetlock. Moreover, F-FDG PET agreed more closely with modalities used to detect active tendon lesions (arterial contrast CT and T2/STIR low-field MRI) than with CT and T1 low-field MRI.[32]

In conclusion, MRI is the only imaging modality that can assess all tissues in a single examination, yet the availability of MRI should not replace but rather complement radiographic and ultrasonographic findings. Information obtained from radiographic, ultrasonographic, and scintigraphic examinations helps with the interpretation of MRI findings.

5. Rationale for Selection of Imaging Modalities

The equine practitioner has numerous diagnostic imaging options when working up a lame horse. When selecting an imaging modality, several factors must be considered, not least the anatomical region under scrutiny. Therefore, the consecutive steps of the decision-making process need to be considered separately for different anatomical regions.

The Foot

- It has become clear that proximal diffusion and migration of local anesthetic from a palmar digital nerve block can desensitize even the pastern and fetlock regions and that this nerve block should no longer be considered specific for foot lameness.[33] An abaxial sesamoid nerve block is far too indiscriminate to localize pain to the foot as proximal diffusion of local anesthetic solution results in desensitization of the fetlock region (including the branches of the suspensory ligament) in most horses. Abaxial sesamoid nerve blocks should therefore not be used as a first-line diagnostic nerve block in a lameness examination to help decide which area requires MRI.
- Radiography is the first-line imaging modality of choice for the foot provided good-quality radiographs are obtained. If good-quality radiographs of the foot fail to reveal any significant abnormalities, intra-articular anesthesia of the distal interphalangeal joint and intrabursal anesthesia are useful to confirm that lameness is caused by pain in the foot. Ultrasonography is frequently omitted during first-line imaging examination of the foot as it rarely produces a conclusive or complete diagnosis.
- In many parts of the world, low-field standing MRI has become the gold standard second-line imaging modality for horses with foot lameness without an obvious radiographic diagnosis because of its high sensitivity and specificity for the diagnosis of both bone and soft tissue injuries in the foot and because it can be performed without the need for general anesthesia. Radiographs and MR images are complementary and always need to be evaluated alongside one another (Figs. 3 and 4). If the low-field MRI examination of the foot does not reveal any significant abnormalities that are compatible with the presenting clinical signs, then the MRI examination should be extended to include the pastern and fetlock regions, especially if no further attempts have been performed to localize lameness more precisely with intrasynovial anesthesia after a positive palmar digital nerve block.
- If low-field MRI fails to reveal any significant abnormalities in either the foot/pastern or the fetlock region, the possible ways forward are as follows: 1) The localization of the cause of lameness was inaccurate and the diagnostic blocking process must be repeated, preferably with the use of inertial sensors,[2] to measure the lameness improvement objectively after each nerve block. 2) Alternatively, the horse can be rested for 1 to 2 months and represented for a follow-up MRI examination, in view of the fact that there may be a lag time between the onset of lameness and the development of signal abnormalities on MR images (Fig. 5).[24] 3) Third-line imaging can be pursued with either high-field MRI or contrast enhanced CT (or PET) as these modalities are more sensitive for subtle injuries than low-field MRI (Fig. 5). Low-field MRI has poor sensitivity for abnormalities of the lamellar tissues as well as the avascular layers of the hoof wall and sole (bruising, hoof abscess, seedy toe gravel, some keratomas, and other hoof wall masses). It also struggles to identify surface abnormalities of hyaline cartilage and fibrocartilage and of some deep digital flexor tendon injuries. Moreover, many horses with solar pain responsive to application of hoof testers or horses with poor dorsopalmar foot balance resulting in palmar heel pain have unremarkable low-field MR images.

The Fetlock

- Radiography is the first-line imaging modality for the fetlock region. Osteoarthritis is a common cause of fetlock lameness, and osteophytes, enthesophytes, and fragmentation of the articular margin are most easily identified on good-quality radiographs. Ultrasonography should also be part of the first-line imaging protocol because of the high prevalence of soft tissue injuries on the palmar aspect of the pastern and fetlock regions. However, several studies have reported a poor ability of ultrasonography to accurately predict the presence of marginal

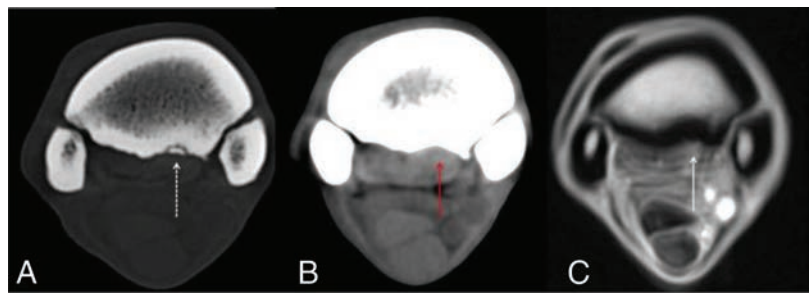

Fig. 6. Transverse bone window (A) and soft tissue window (B) CT images and a T1 gradient echo MR image (0.27 T; C) of the proximal part of the third metacarpal bone of a 3-year-old warmblood showjumper with acute onset lameness that was abolished by subcarpal anesthesia. A small cortical avulsion fragment was visible on the CT image only (dotted white arrow). A focal area of signal increase without an obvious fragment is visible in the dorsal margin of the medial lobe of the suspensory ligament on the MR image (white arrow). The soft tissue window CT image shows a corresponding area of subtle hypoattenuation (red arrow).

tearing of the deep digital flexor tendon or the manica flexoria.[34,35] Radiographic contrast tenography of the digital flexor tendon sheath, however, had a 92% sensitivity and 56% specificity for the diagnosis of manica flexoria tears and a 54% sensitivity and 73% specificity for longitudinal tears of the deep digital flexor tendon.[36,37] For horses presented with lameness localized to the digital flexor tendon sheath, contrast tenography should thus be performed as part of the first-line imaging protocol alongside ultrasonography.

- In many parts of the world, standing low-field MRI is the second-line imaging modality of choice for horses with fetlock region pain because of the high prevalence of subchondral bone injury characterized by the presence of bone edema in the fetlock of sports horses and racehorses.[13,38] Motion artifacts may interfere with accurate evaluation of the soft tissues, but marginal tears of the dorsal margin of the deep digital flexor tendon in the pastern region have been described using standing low-field MRI.[39]
- Because soft tissue contrast and resolution are superior to that of low-field, high-field MRI is the most suitable third-line imaging modality. One high-field MRI study reported distal sesamoidean ligament injuries as the most common finding in 94 of 232 horses with fetlock lameness without obvious first-line imaging abnormalities.[40] CT can also be used as a third-line modality as it offers increased sensitivity for subtle subchondral resorption (Fig. 4), sclerosis, and new bone production that may be missed on low-field MR images and adds the ability to assess contrast enhancement in subtle but active soft tissue injuries in the fetlock region.

The Metacarpal/Metatarsal Regions

- The obvious first-line imaging modality for soft tissue swellings of the palmar/plantar metacarpal/metatarsal regions is ultrasonography, including the use of Doppler ultrasound to detect new or persistent abnormal vascularization of the suspensory ligament or flexor tendons.[41–43]
- Radiographic contrast tenography may also be useful for soft tissue swelling extending distally into the region of the digital flexor tendon sheath (see above).
- Both MRI and contrast enhanced CT may be helpful second-line imaging modalities to answer specific questions that may remain following an ultrasonographic examination. High-field MRI and contrast CT may be able to identify fiber abnormalities that cause lameness but are not detected with ultrasonography (e.g., proximal part of the superficial digital flexor tendon). An abbreviated low-field MRI protocol combined with serial ultrasonographic examinations has been helpful in deciding when sports horses can safely resume fast exercise.[11]

The Proximal Metacarpal/Metatarsal and Distal Carpal/Tarsal Regions

- A clinical diagnosis of proximal suspensory region pain relies heavily on localization of the cause of pain with diagnostic anesthesia as external signs of injury are frequently absent. However, all diagnostic anesthesia techniques suffer from a lack of specificity, and none are able to single out the suspensory ligament as the definitive site of pain causing lameness.[20,44,45] In one study, only 66% of horses with hindlimb lameness that was eliminated or substantially improved by a nerve block of the deep branch of the lateral plantar nerve had lesions of the suspensory ligament or the plantar cortex of the third metatarsal bone identified on high-field MR images.[20] Observations in a study of 103 horses with pain in the distal tarsal or proximal metatarsal region showed that

the primary MRI abnormality frequently did not correlate with the diagnostic anesthetic technique that improved the lameness most.[45]

- A combination of radiography and ultrasonography is the first-line imaging protocol for horses with proximal metacarpal/metatarsal pain in order to rule out the presence of obvious bone or joint abnormalities (osteoarthritis and fractures) or severe proximal suspensory desmitis. Most frequently, however, the results of these examinations are inconclusive. Especially ultrasonography of the proximal part of the hind suspensory ligament has been reported to result in 66% false positive and 34% false negative findings when compared with high-field MRI.[20] A follow-up study that compared ultrasonography with histology was unable to support the reliability of ultrasonography for the diagnosis of proximal suspensory desmitis.[14,15] Of 36 limbs with ultrasonographic evidence of moderate to severe fiber damage to the proximal part of the suspensory ligament, 53% had no histological abnormalities of the collagen fiber pattern and organization, while 33% had mild and 14% had moderate fiber abnormalities. Ultrasonography therefore resulted in a false positive diagnosis of moderate to severe fiber damage in at least 54% of the suspensory ligaments in this study. The authors described cellular microscopic abnormalities of fibroblasts, myocytes, and adipocytes in 97% of the suspensory ligaments, but ultrasonography is unable to detect microscopic abnormalities at a cellular level. A significant association was observed between microscopic findings in myocytes and ultrasonography, yet the ultrasonographic abnormalities described at the outset related to the collagen fiber pattern.[14]
- Given the limitations of ultrasonography in the diagnosis of proximal suspensory desmitis (especially in hindlimbs), it is tempting to propose low-field MRI as an alternative first-line or at least second-line imaging modality for the proximal metatarsal/distal tarsal region. Both the proximal metacarpal/metatarsal and distal carpal/tarsal regions are commonly looked at concurrently during MRI examinations because it is difficult to localize pain definitively in either one or the other region with diagnostic anesthesia.[20,45] However, the interference of motion artefact with image quality, especially in T2 spin echo and STIR images of this region, imposes significant limitations on accurate assessment of the soft tissue structures in this region with standing MRI. Unsurprisingly, many clinicians have considered the technique more reliable for the diagnosis of osseous abnormalities than of proximal suspensory desmitis,[46] while results have been more encouraging in forelimbs (Fig. 6).[47,48] MR images of the suspensory origin need to be assessed with caution as motion artifacts (with standing low-field MRI) and the variable appearance of the muscle and fat tissue bundles should not be confused with signal changes caused by injury. Low-field MRI may be helpful to identify osseous abnormalities of the tarsal and carpal bones including sclerosis, slab fractures, and osseous cyst-like lesions, but motion artifact may interfere with accurate assessment of osteophytes, chip fractures, and joint space narrowing.
- In view of the problems of motion in low-field MRI of the proximal metatarsal region, high-field MRI might be regarded as a more suitable second-line imaging modality in hindlimbs.[46] It is also a suitable third-line imaging modality if the results of low-field MRI are inconclusive in forelimbs.[47]
- CT and contrast CT may have certain advantages as a third-line imaging modality. It is more sensitive than even high-field MRI for subtle new bone formation, bone resorption, and avulsion fragments (Fig. 6) associated with the proximal attachment of the suspensory ligament[49] because of the lack of contrast between bone and soft tissue at the ligament-cortical bone interface on MR images. Moreover, contrast enhancement may be observed in active proximal suspensory desmitis lesions but not in chronic fibrosis on CT images.[50]

The Stifle

- Radiography and ultrasonography are a useful first-line imaging protocol as they provide a reliable imaging diagnosis for many conditions causing stifle lameness and have offered the traditional basis for further arthroscopic exploration of the joint.
- Both low- and high-field MRI[7,51] as well as CT examinations[52,53] of the stifle can now be used as second-line diagnostic modalities for improved diagnosis of injuries of this complex joint as many of the soft tissue structures of the joint cannot be evaluated comprehensively with first-line conventional imaging modalities. However, general anesthesia is required for these cross-sectional imaging techniques, and current high-field magnets impose a size limitation on the horse due to the diameter of the bore. In one low-field MRI study of 76 sports horses with stifle lameness, the prevalence of meniscal lesions was 95%, cruciate ligament injuries 43%, and bone marrow lesions 14%.[51] Although these observations suggest that

many of these lesions were not only very common but also present concurrently, the clinical significance of some low-field MRI abnormalities in the stifle has been questioned previously.[54] CT is sensitive for subtle bone change [53] but cannot demonstrate bone marrow lesions and structural detail of most soft tissue lesions in the stifle. Contrast CT and CT arthrography have been useful to define cartilage lesions and ligament injuries in a series of 16 horses with stifle lameness.[52]

6. Conclusion

While lameness is one of the most common reasons for a consult in clinical practice, it remains a challenging aspect of equine veterinary medicine. The most effective way to diagnose musculoskeletal abnormalities is to integrate a thorough physical examination, gait analysis, and diagnostic anesthesia with the proper imaging modalities. Precise image acquisition and careful interpretation if necessary by a specialist[55,56] is the only road to an accurate diagnosis and prognosis.

Acknowledgments

Declaration of Ethics

The Authors have adhered to the Principles of Veterinary Medical Ethics of the AVMA.

Conflict of Interest

The Authors have no conflicts of interest.

References

1. Schumacher J, Schramme MC, Schumacher J, et al. Diagnostic analgesia of the equine digit. *Equine Vet Educ* 2013;25:408–421.
2. Keegan KG, Kramer J, Yonezawa Y, et al. Assessment of repeatability of a wireless, inertial sensor-based lameness evaluation system for horses. *Am J Vet Res* 2011;72:1156–1163.
3. Schumacher J, Schumacher J, Schramme M, et al. Review of mistakes that can be made when interpreting the results of diagnostic analgesia during a lameness examination, in *Proceedings*. Am Assoc Equine Pract 2014;60:83–93.
4. Murray RM, Mair TS, Sherlock CE, et al. Comparison of high-field and low-field magnetic resonance images of cadaver limbs of horses. *Vet Rec* 2009;165:281–288.
5. Smith M, Dyson S, Murray R. The appearance of the equine metacarpophalangeal region on high-field vs. standing low-field magnetic resonance imaging. *Vet Radiol Ultrasound* 2011;52:61–70.
6. Nagy A, Dyson S. Magnetic resonance imaging findings in the carpus and proximal metacarpal region of 50 lame horses. *Equine Vet J* 2012;44:163–168.
7. Waselau M, McKnight A, Kasparek A. Magnetic resonance imaging of equine stifles: Technique and observations in 76 clinical cases. *Equine Vet Educ* 2020;32:85–91.
8. Werpy NM. Magnetic resonance imaging of the equine patient: A comparison of high- and low-field systems. *Clin Tech Equine Pract* 2007;6:37–45.
9. Smith MA, Dyson SJ, Murray RC. Reliability of high- and low-field magnetic resonance imaging systems for detection of cartilage and bone lesions in the equine cadaver fetlock. *Equine Vet J* 2012;44:684–691.
10. Schramme M, Kerekes Z, Hunter S, et al. MR imaging features of surgically induced core lesions in the equine superficial digital flexor tendon. *Vet Radiol Ultrasound* 2010;51:280–287.
11. Bathe A. Monitoring SDFT injuries: Experiences with sMRI, in *Proceedings*. 12th Hallmarq User Meeting 2012;12:1–45.
12. Holowinski M, Judy C, Saveraid T, et al. Resolution of lesions on STIR images is associated with improved lameness status in horses. *Vet Radiol Ultrasound* 2010;51:479–484.
13. Gonzalez L, Schramme M, Redding WR, et al. MRI features of metacarpo(tarso)phalangeal region lameness in 40 horses. *Vet Radiol Ultrasound* 2010;51:404–414.
14. Dyson S, Murray R, Pinilla MJ. Proximal suspensory desmopathy in hindlimbs: A correlative clinical, ultrasonographic, gross post mortem and histological study. *Equine Vet J* 2017;49:65–72.
15. Dyson S, Pinilla MJ, Bolas N, et al. Proximal suspensory desmopathy in hindlimbs: Magnetic resonance imaging, gross post-mortem and histological study. *Equine Vet J* 2018;50:159–165.
16. Evrard L, Joostens Z, Vandersmissen M, et al. Comparison between ultrasonographic and standing magnetic resonance imaging findings in the podotrochlear apparatus of horses with foot pain. *Front Vet Sci* 2021;8:675180.
17. Dyson S, Murray R. Collateral desmitis of the distal interphalangeal joint in 62 horses (January 2001-December 2003), in *Proceedings*. Am Assoc Equine Pract 2004;50:248–256.
18. Dyson SJ, Murray RC, Schramme M, et al. Collateral desmitis of the distal interphalangeal joint in 18 horses (2001-2002). *Equine Vet J* 2004;36:160–166.
19. Dyson S, Murray R, Schramme M, et al. Lameness in 46 horses associated with deep digital flexor tendonitis in the digit: Diagnosis confirmed with magnetic resonance imaging. *Equine Vet J* 2003;35:681–690.
20. Labens R, Schramme MC, Robertson ID, et al. Clinical, magnetic resonance, and sonographic imaging findings in horses with proximal plantar metatarsal pain. *Vet Radiol Ultrasound* 2010;51:11–18.
21. Dyson S, Murray R. Use of concurrent scintigraphic and magnetic resonance imaging evaluation to improve understanding of the pathogenesis of injury of the podotrochlear apparatus. *Equine Vet J* 2007;39:365–369.
22. Brünisholz HP, Hagen R, Fürst AE, et al. Radiographic and computed tomographic configuration of incomplete proximal fractures of the proximal phalanx in horses not used for racing. *Vet Surg* 2015;44:809–815.
23. Vallance SA, Bell RJ, Spriet M, et al. Comparisons of computed tomography, contrast-enhanced computed tomography and standing low-field magnetic resonance imaging in horses with lameness localised to the foot. Part 2: Lesion identification. *Equine Vet J* 2012;44:149–156.
24. Wulster KA. Diagnosis of skeletal injury in the sport horse. *Vet Clin North Am Equine Pract* 2018;34:193–213.
25. Rovel T, Audigié F, Coudry V, et al. Evaluation of standing low-field magnetic resonance imaging for diagnosis of advanced distal interphalangeal primary degenerative joint disease in horses: 12 cases (2010–2014). *J Am Vet Med Assoc* 2019;254:257–265.
26. van Zadelhoff C, Schwarz T, Smith S, et al. Identification of naturally occurring cartilage damage in the equine distal interphalangeal joint using low-field magnetic resonance imaging and magnetic resonance arthrography. *Frontiers in Vet Sci* 2020;6:508.
27. Hontoir F, Clegg P, Nisolle JF, et al. A comparison of 3-T magnetic resonance imaging and computed tomography arthrography to identify structural cartilage defects of the fetlock joint in the horse. *Vet J* 2015;205:11–20.
28. Suarez Sanchez-Andrade J, Richter H, Kuhn K, et al. Comparison between magnetic resonance imaging, computed tomography, and arthrography to identify artificially induced cartilage defects of the equine carpal joints. *Vet Radiol Ultrasound* 2018;59:312–325.
29. Spriet M, Espinosa P, Kyme AZ, et al. 18 F-sodium fluoride positron emission tomography of the equine distal limb: Exploratory study in three horses. *Equine Vet J* 2018;50:125–132.

30. Spriet M, Espinosa-Mur P, Cissell DD, et al. 18 F-sodium fluoride positron emission tomography of the racing Thoroughbred fetlock: Validation and comparison with other imaging modalities in nine horses. *Equine Vet J* 2019;51:375–383.
31. Norvall A, Spriet M, Espinosa P, et al. Chondrosesamoidean ligament enthesopathy: Prevalence and findings in a population of lame horses imaged with positron emission tomography. *Equine Vet J* 2021;53:451–459.
32. Wilson S, Spriet M, Mur PE, et al. 18 Fluorine-fluorodeoxyglucose positron emission tomography for assessment of deep digital flexor tendinopathy: An exploratory study in eight horses with comparison to CT and MRI. *Vet Radiol Ultrasound* 2021;62:610–620.
33. Contino E, Werpy N, Morton A, et al. Metacarpophalangeal joint lesions identified on magnetic resonance imaging with lameness that resolves using palmar digital nerve and intra-articular analgesia, in *Proceedings*. Am Assoc Equine Pract 2012;58:534.
34. Smith MR, Wright IM. Noninfected tenosynovitis of the digital flexor tendon sheath: A retrospective analysis of 76 cases. *Equine Vet J* 2006;38:134–141.
35. Arensburg L, Wilderjans H, Simon O, et al. Nonseptic tenosynovitis of the digital flexor tendon sheath caused by longitudinal tears in the digital flexor tendons: a retrospective study of 135 tenoscopic procedures. *Equine Vet J* 2011;43:660–668.
36. Fiske-Jackson AR, Barker WH, Eliashar E, et al. The use of intrathecal analgesia and contrast radiography as preoperative diagnostic methods for digital flexor tendon sheath pathology. *Equine Vet J* 2013;45:36–40.
37. Kent AV, Chesworth MJ, Wells G, et al. Improved diagnostic criteria for digital flexor tendon sheath pathology using contrast tenography. *Equine Vet J* 2020;52:205–212.
38. Gold SJ, Werpy NM, Gutierrez-Nibeyro SD. Injuries of the sagittal groove of the proximal phalanx in Warmblood Horses detected with low-field magnetic resonance imaging: 19 cases (2007–2016). *Vet Radiol Ultrasound* 2017;58:344–353.
39. van Veggel ECS, Selberg KT, van der Velde H, et al. Deep digital flexor tendon injury at the level of the proximal phalanx in frontlimbs with tendon sheath distension characterized by standing low-field magnetic resonance imaging in horses: 13 cases. *Front Vet Sci* 2021;8:18734729.
40. King JN, Zubrod CJ, Schneider RK, et al. MRI findings in 232 horses with lameness localized to the metacarpo (tarso) phalangeal region and without a radiographic diagnosis. *Vet Radiol Ultrasound* 2013;54:36–47.
41. Rabba S, Grulke S, Verwilghen D, et al. B-mode and power Doppler ultrasonography of the equine suspensory ligament branches: A descriptive study on 13 horses. *Vet Radiol Ultrasound* 2018;59:453–460.
42. O'Brien EJO, Smith RKW. Mineralization can be an incidental ultrasonographic finding in equine tendons and ligaments. *Vet Radiol Ultrasound* 2018;59:613–623.
43. Lacitignola L, Rossella S, Pasquale L, et al. Power Doppler to investigate superficial digital flexor tendinopathy in the horse. *Open Vet J* 2020;9:317–321.
44. Pezzanite L, Contino E, Kawcak C. Lameness originating from the proximal metacarpus/tarsus: A review of local analgesic techniques and clinical diagnostic findings. *Equine Vet Educ* 2020;32:204–217.
45. Labens R, Schramme MC, Murray RC, et al. Standing low-field MRI of the equine proximal metacarpal/metatarsal region is considered useful for diagnosing primary bone pathology and makes a positive contribution to case management: A prospective survey study. *Vet Radiol Ultrasound* 2020;61:197–205.
46. Barrett MF, Selberg KT, Johnson SA, et al. High field magnetic resonance imaging contributes to diagnosis of equine distal tarsus and proximal metatarsus lesions: 103 horses. *Vet Radiol Ultrasound* 2018;59:587–596.
47. Barrett MF, Manchon PT, Hersman J, et al. Magnetic resonance imaging findings of the proximal metacarpus in Quarter Horses used for cutting: Retrospective analysis of 32 horses 2009-2012. *Equine Vet J* 2018;50:172–178.
48. van Veggel E, Selberg K, van der Velde-Hoogelander B, et al. Magnetic resonance imaging findings of the proximal metacarpal region in warmblood horses: 36 lame and 26 control limbs (2015-2021). *Front Vet Sci* 2021;8:714423.
49. Launois MT, Vandeweerd JM, Perrin RA, et al. Use of computed tomography to diagnose new bone formation associated with desmitis of the proximal aspect of the suspensory ligament in third metacarpal or third metatarsal bones of three horses. *J Am Vet Med Assoc* 2009;234:514–518.
50. Werpy NM, Denoix JM. Imaging of the equine proximal suspensory ligament. *Vet Clin North Am Equine Pract* 2012;28:507–525.
51. Judy C. The stifle. In: Murray RC, ed. *Equine MRI*. Oxford: Wiley Blackwell, 2011;451–467.
52. Bergman EH, Puchalski SM, Van der Veen H, et al. Computed tomography and computed tomography arthrography of the equine stifle: Technique and preliminary results in 16 clinical cases, in *Proceedings*. Am Assoc Equine Pract 2007;53:46–55.
53. De Lasalle J, Alexander K, Olive J, et al. Comparisons among radiography, ultrasonography and computed tomography for ex vivo characterization of stifle osteoarthritis in the horse. *Vet Radiol Ultrasound* 2016;57:489–501.
54. Santos MP, Gutierrez-Nibeyro SD, McKnight AL, et al. Gross and histopathologic correlation of low-field magnetic resonance imaging findings in the stifle of asymptomatic horses. *Vet Radiol Ultrasound* 2015;56:407–416.
55. Werpy NM, Barrett MF. Advances in equine imaging. *Vet Clin North Am Equine Pract* 2012;28:xiii–xxiv.
56. Schramme MC, Segard E. Equine magnetic resonance imaging. In: Baxter GM, ed. *Adams' lameness in horses 7th ed*. Hoboken: Wiley-Blackwell, 2020;397.

Nuclear Scintigraphy Use in Musculoskeletal Injury and Lameness

Ryland B. Edwards, III, DVM, PhD, DACVS, DACVSMR

Author's address: Fairfield Equine Associates, 32 Barnabas Road, Newtown, CT 06470; e-mail: redwards@fairfieldequine.com. © 2022 AAEP.

1. Background

The use of scintigraphy in equine practice began in the 1970s and was led by Ueltschi in Europe and Twardock in the United States.[1,2] Drs. Ross, Dyson, Murray, Martinelli, Ehrlich, Seeherman and others have researched reported scintigraphy's use as an aid for diagnosing musculoskeletal injury in the horse.[3–10] Other uses of scintigraphy have included investigation of respiratory disease (exercise-induced pulmonary hemorrhage), gastric emptying studies, identification of thrombus formation (primarily terminal aorta), using labeled white cells to localize regions of infection, and as an aid to identify parathyroid tissue in horses with hyperparathyroidism.[11–25] The primary use of scintigraphy in the horse is to identify possible areas of musculoskeletal injury that are causing poor performance. In many instances, examinations are performed on horses for which a comprehensive clinical examination has not been completed; this is a poor approach to its use as a diagnostic tool. Other common presentations for an examination include horses with severe lameness that cannot be localized, multiple limb lameness, lameness that has been localized but cannot be identified, possible pelvic trauma or injury, and to assess horses that may have clinical problems associated with impinging dorsal spinous processes. As magnetic resonance imaging (MRI), computed tomography (CT), and positron emission tomography (PET) have become more accessible, horses with a lameness isolated to a specific region may be imaged with one of these modalities instead or combined with scintigraphy.[9,26–28]

2. Principles

The basic principle of scintigraphy is the detection of gamma rays that are emitted from the decaying nucleotide by a gamma camera. The clinical information obtained is based on the biochemistry of the pharmaceutical and its interactions with the target organ, in this instance bone, and scintigraphy provides a physiologic picture of the bone, primarily bone turnover and blood flow to the bone and not an anatomical picture of the bone.[29] The nucleotide most commonly used in equine scintigraphy (technetium-99m) is bound to a diphosphonate salt such as methyl diphosphonate (MDP) or disodium oxidronate (HDP) in equine musculoskeletal studies. Methyl diphosphonate binds to the hydroxyapatite portion of bone, and the intensity of the uptake or capture is related to osteoblast activity.

Timing of the procedure relative to the bone injury can be important and factor into false negative studies. There are times where a client may want to give the horse some time off and then pursue scintigraphy if the horse is still lame. In general, this is the wrong approach, and scintigraphy, if it is an option, should be pursued prior to a rest period. When acute lameness occurs, the cause of the lameness will direct when imaging should occur. Acute lameness secondary to stress-related bone injury in horses in training/work

NOTES

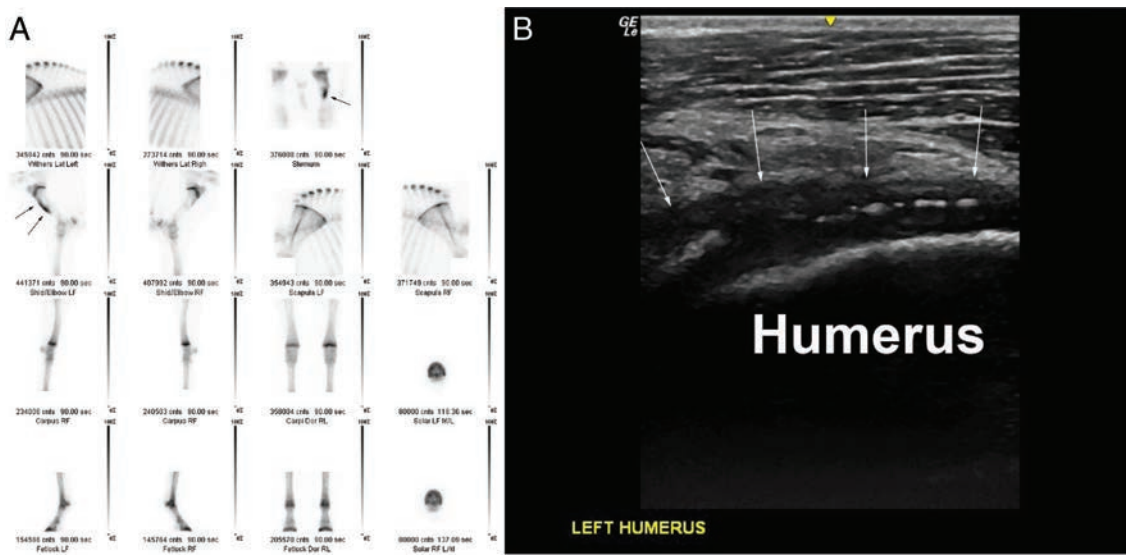

Fig. 1. Forelimb images of a 2-year-old Appaloosa filly that was 4/5 lame in the left forelimb after paddock turnout and initially was dragging her toe when the limb was advanced. A, Scintigraphic images of the left humerus demonstrated marked isotope capture along the cranial surface of the left humerus (arrows) that is not consistent with a stress fracture. B, Ultrasound image of the cranio-lateral aspect of the left humerus demonstrating a subperiosteal hematoma (white arrows).

will lead to ongoing bone modeling, and the area of interest will have increased isotope capture at the area of injury. Acute lameness secondary to acute trauma will take several days to develop increased osteoblast activity, and most clinicians recommend a 7- to 10-day delay before scintigraphy is performed.[3]

3. Imaging Procedure

Patient preparation is critical to image quality. Horses are admitted the day prior to being imaged to allow them to adapt to the surroundings and be prepared for imaging. In colder climates, the horse may be blanketed and standing wraps applied to the limbs that will be imaged to avoid what some describe as the "cold limb syndrome", which is a lack of isotope capture distal to the fetlock in most instances but can include the entire limb distal to the carpus and/or tarsus.[30] There is evidence that wrapping and blanketing alone does not prevent poor perfusion of the limb, and the best means to avoid this problem is to longe the horse at a trot and canter for 15 minutes prior to injecting the isotope.[30] Warmblood horses often have poor bone uptake compared to Thoroughbred racehorses secondary to reduced turnover of bone, less vigorous exercise, and thicker overlying soft tissue resulting in shielding.

There are reports that perineural and intra-articular anesthesia can impact pool and delayed (bone) phase imaging.[31,32] Tibial, peroneal, ulnar, and median blocks are most commonly reported to cause soft-tissue capture of isotope at the site the block was performed. This does not interfere with interpretation if two images (lateral and dorsopalmar or plantar dorsal) of the regions are completed as identification of the site of increased capture can be verified to be associated with the perineural anesthetic site. Intra-articular anesthesia may impact pool-phase images for 7 to 10 days.[3,30]

The shoes are removed, and the hooves are bandaged or boots applied to prevent urine contamination of the hooves. Standing wraps are applied to protect the lower limbs from urine contamination. An intravenous catheter is placed in the jugular vein, and 150 to 200 mCi (0.4–0.5 mCi/kg) is administered.

Image acquisition is divided into three phases: flow phase (vascular), pool phase (soft tissue), and delayed phase (bone). The flow phase lasts for the first 1 to 3 minutes and is generally combined with the pool phase during image acquisition. The flow phase is used specifically when imaging for aortoiliac thrombosis. During the pool phase, the radiopharmaceutical is located in the extracellular fluid space. The pool-phase images are generally obtained between 3 and 15 to 20 minutes after injection and are used in an attempt to examine soft tissues such as tendons, ligaments, digital sheaths, and bursae. Positive pool-phase images are reported to occur when soft-tissue injury has occurred within 6 weeks of imaging.[3] The pool phase is brief, so the region to be examined is limited. Negative pool phase images do not exclude the possibility of soft tissue injury and some individuals do not use pool phase imaging because they find limited benefits in this imaging phase. The delayed-phase images are obtained 2 to 4 hours after injection. The radiopharmaceutical is localized in the bone and has been cleared from the soft tissues by excretion in the kidneys. In areas of acute and severe bone injury, the bone uptake can be seen as rapidly as 20 minutes after isotope administration.

Obtained images are most commonly evaluated qualitatively, and the location and intensity of the

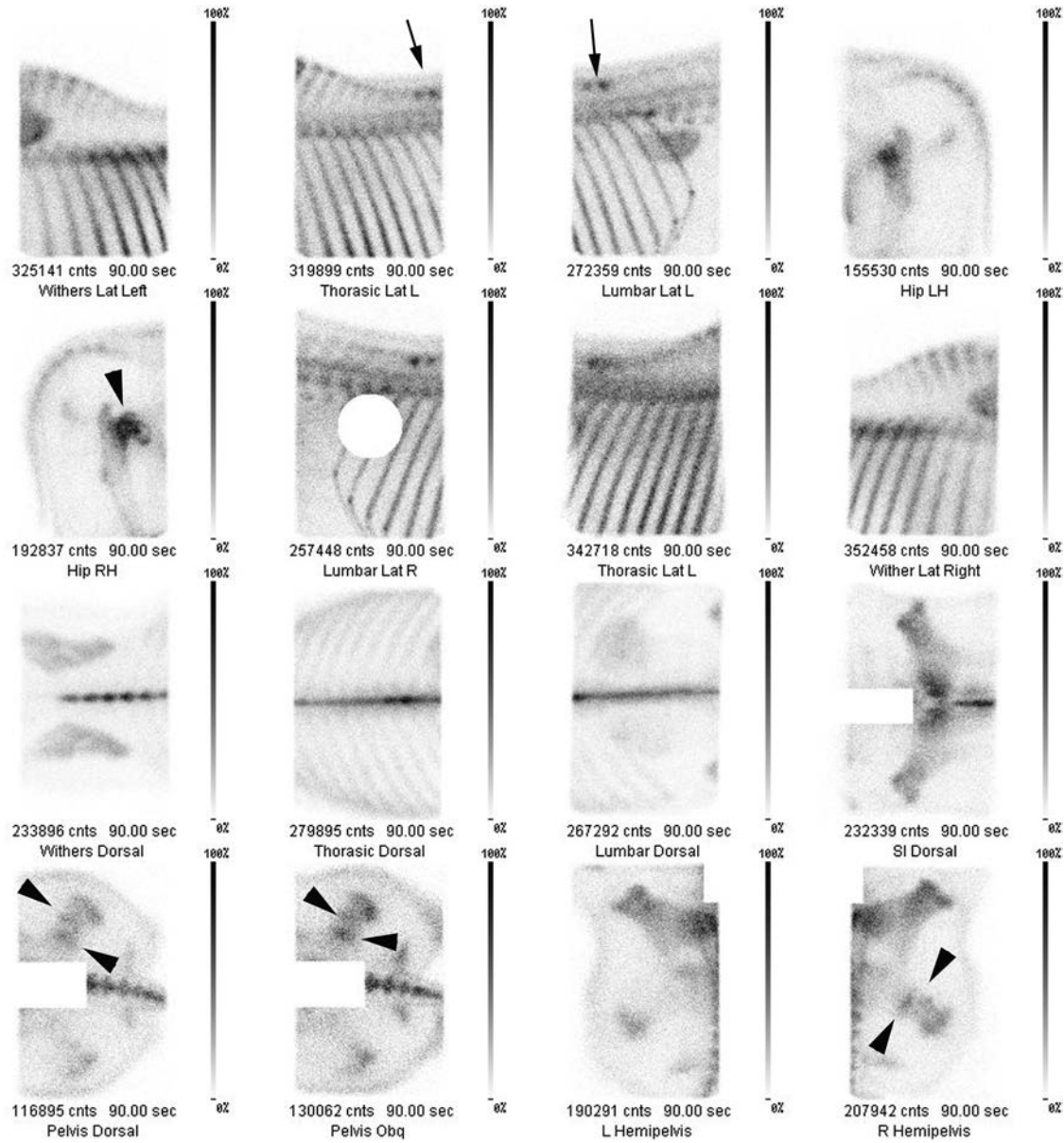

Fig. 2. 14-year-old Morgan gelding with an 8-month history of progressive right hind limb lameness. There are several areas of isotope capture: the caudal thoracic dorsal spinous processes (black arrows), right sacroiliac region (not labelled), and the right acetabular and femoral neck regions (black arrowheads).

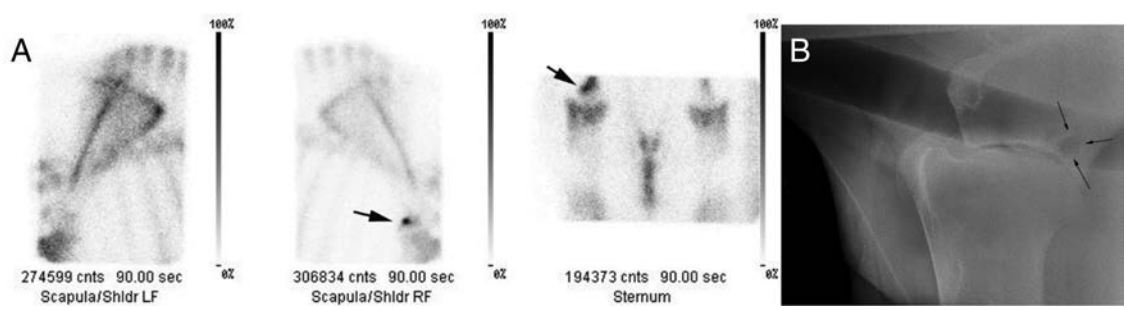

Fig. 3. A, Scintigraphy images of a 14-year-old Oldenberg gelding with right forelimb lameness that was partially improved with intra-articular anesthesia of the scapulohumeral joint. Black arrows highlight a focal area of bone activity in the caudal distal aspect of the right scapula. B, Medial to lateral radiograph of the right scapulohumeral joint demonstrating a subchondral cyst-like lesion in the caudal aspect of the glenoid.

capture or isotope uptake is described. Areas of increased capture or uptake are often described as hot spots.

Image acquisition by the gamma camera is dependent on the operator to position the camera the same distance from the horse on each side to facilitate accurate comparison of the same regions on opposites sides of the horse. Current software allows postprocessing of images such as masking areas of increased activity (i.e., the bladder, areas of capture in soft tissues after nerve blocks, or potentially areas of urine contamination). In general, two images are obtained of each region examined to localize areas of increased capture and avoid missing areas of capture that are shielded in one view. Dorsal imaging will provide little information of the palmar surface, and lateral imaging will provide little to no information of the medial surface of the limbs. Solar margin views of the digit allow uniform examination of the distal phalanx. Image quality is related to isotope dose administered, counts acquired per region examined, distance of camera from the horse, motion, shielding, and background radiation.[3] Shielding is an important concept to understand relative to false negative imaging and understanding limitations of scintigraphy. The soft tissue surrounding the pelvis will greatly reduce the intensity of isotope capture when the pelvis is examined. Soft-tissue shielding in the stifle region can also be partially responsible for limitations associated with scintigraphy and stifle lameness.[33] Shielding also occurs when the limb is imaged from the lateral aspect of the bone lesion on the medial aspect of the limb; normal bone prevents the emitted signal from reaching the camera. Positioning of the horse, sedation, and room comfort each play a role in the managing motion, which is most problematic when examining upper regions of the limbs and axial skeleton.

When the images are examined, areas of capture are described by the location, intensity, and character of uptake (focal versus diffuse). Areas of photopenia have been described and thought to be related to compression of vasculature by abscesses and joint effusion, septic osteitis, sequestrum formation, and vascular thrombosis.[3,34]

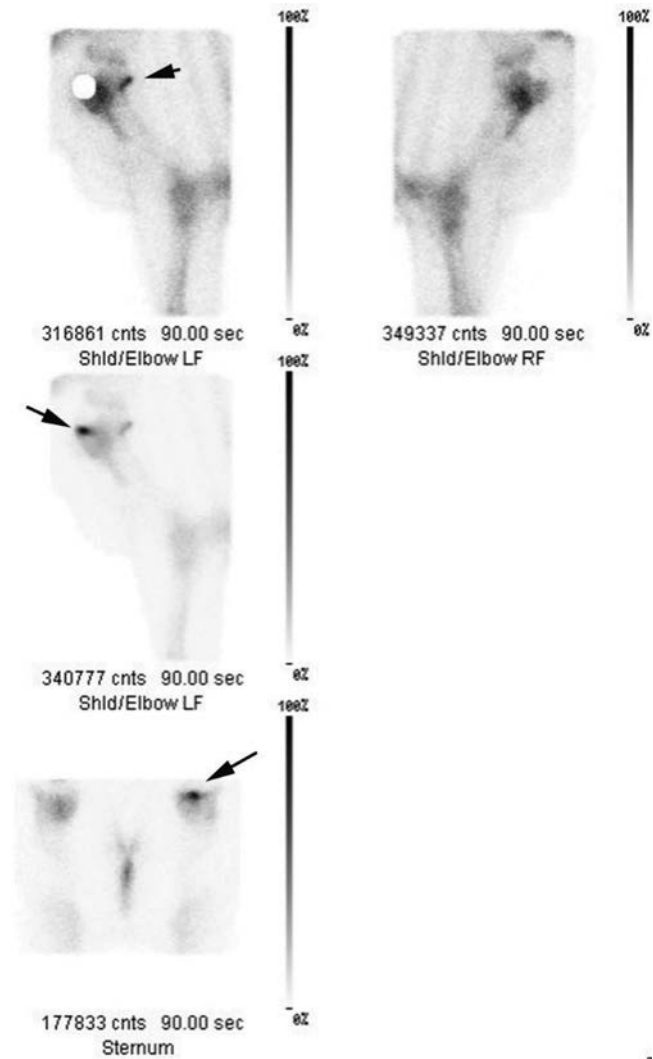

Fig. 4. 11-year-old Warmblood mare that ran in a paddock and had an acutely severely (4/5) lame left forelimb. The lameness improved rapidly and blocked to a low 4-point nerve block. Scintigraphy was pursued to determine if there was evidence of any other injury. There is focal isotope capture at the intermediate tubercle of the humerus. Masking of the tubercle activity demonstrates isotope capture in the proximal caudal humerus.

4. Applications

As previously discussed, scintigraphy examinations are commonly used to try to identify areas of bone injury in horses with poor performance but maybe no definitive lameness, in horses that are acutely lame but too lame to localize with local anesthesia (Fig. 1), and to provide confidence that subtle bone changes on radiographs are active physiologically, though this category may be more frequently examined with MRI, CT, and PET. There are areas such as the back, pelvis, and hip regions that cannot be examined by CT, MRI, or PET imaging in the standing sedated horse (Fig. 2). When examining horses for poor performance with scintigraphy, it is important to discuss with the client the possibility that no definitive source of poor performance may be identified. The positive is that a number of problems may have been eliminated, but this could be because the horse is being imaged too long after the bone injury occurred, the area of injury is shielded or below the resolution of the system/technique, or the injury is soft tissue related and not able to be detected via scintigraphy. Scintigraphy is generally most helpful when a lameness has been isolated but an imaging diagnosis has not been identified or, at minimum, a thorough examination has been completed and the clinician has a suspicion of where the lameness is originating (Fig. 3). Imaging horses that are not lame makes it difficult to determine the significance of isotope capture in some regions. Horses that are lame and in which certain regions such as the

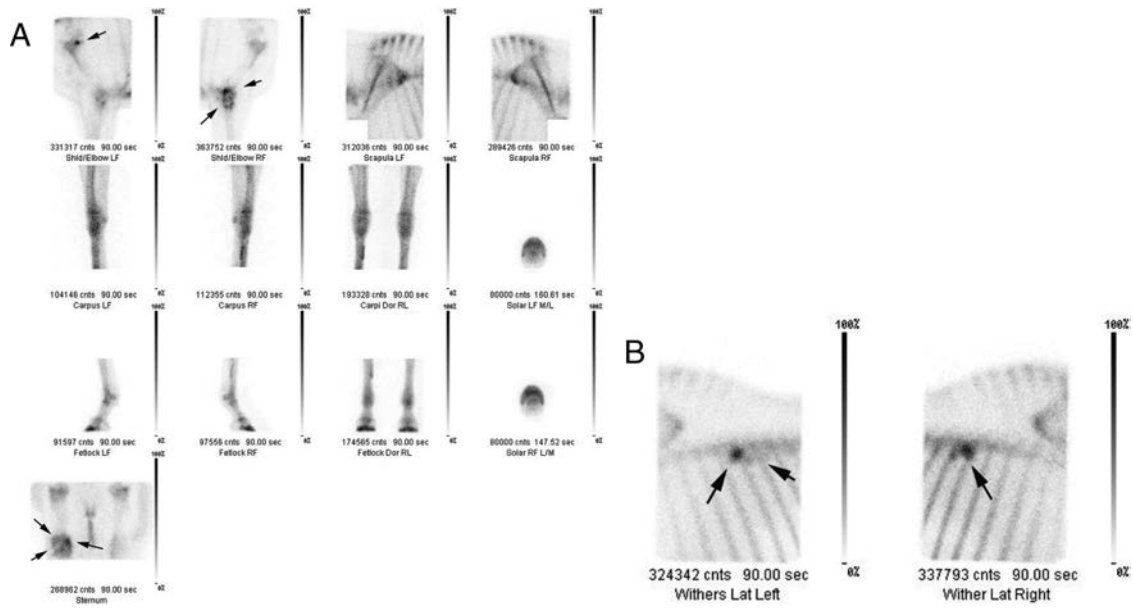

Fig. 5. 18-year-old Holsteiner mare that presented with a right forelimb lameness that was acute and thought to be associated with the carpus. A, Focal isotope capture in the caudal aspect of the left humeral head and diffuse isotope capture in the right elbow. B, Isotope capture in the thoracic spine consistent with spondylosis.

distal limb have been eliminated allow the clinician to concentrate on the upper limbs and axial skeleton as a cause of the lameness (Fig. 4). Scintigraphy in racehorses with nebulous lameness may allow the detection of stress fractures and compensatory injury. Sport horses with nebulous poor performance can be the least productive studies, but subtle changes can be significant if they can be linked to clinical disease and improved performance when the region is blocked or other imaging modalities support an injured soft-tissue or bony structure.

Some common problems that scintigraphy is beneficial in identifying include distal phalanx fractures, focal navicular bone remodeling and injury, increased activity in proximal sesamoid bones associated with sesamoid injury or suspensory branch injury, subchondral bone injury and osseous cyst-like defects, osteitis at the suspensory origin, stress fractures, osteoarthritis in the cervical and thoracolumbar facets, impinging dorsal spinous processes, pelvic trauma (stress fractures, fracture, sacroiliac injury, tuber ischii fracture), spondylosis, osteomyelitis, small carpal and tarsal bone injury and osteoarthritis, and elbow injury (Fig. 5.).[6,8,9,22,26–28,35–65]

5. Conclusions

Scintigraphy can be very useful as a diagnostic tool in horses with undiagnosed lameness and poor performance, but it does have limitations. Ideally these limitations will be discussed with the horse owner prior to imaging in an effort to guide expectations. Scintigraphy provides a physiologic picture of the musculoskeletal system and generally requires radiographic or ultrasonographic examination to fully describe the injury. Positive studies are most commonly obtained in horses with a lameness that has been isolated but not identified, though this may be a minority of the horses that are examined with scintigraphy. Recent injuries are more likely to be identified compared to horses with chronic lameness or horses rested and imaged after a period of rest. Vascular imaging can be helpful in identifying thrombus formation, though it is a rare cause of lameness. Increased isotope capture in soft tissues can be associated with soft-tissue injury or, in some instances, injury to adjacent bone. Similarly, increased isotope capture can be identified in osseous structures when the primary injury is in adjacent soft-tissue structures. Common locations for this phenomenon are increased activity in the navicular bone with deep digital flexor tendon (DDFT) injury, increased isotope capture in the carpus in horses with proximal superficial or DDFT injury, and isotope capture in the calcaneus in horses with gastrocnemius tendon or superficial digital flexor tendon injury. CT, MRI, and PET imaging are replacing scintigraphy in some instances, but scintigraphy continues to be a useful diagnostic tool and can be complementary to these advanced imaging modalities.

Acknowledgments

Declaration of Ethics

The Author has adhered to the Principles of Veterinary Medical Ethics of the AVMA.

Conflict of Interest

The Author has no conflicts of interest.

References

1. Ueltschi G. First results of scintigraphic skeletal examinations in horses using 99mTc phosphates as tracers. *Schweiz Arch Tierheilkd* 1975;117:383–392.
2. Twardock AR. A personal history of veterinary nuclear medicine. *Semin Vet Med Surg Small Anim* 1991;6:103–107.
3. Ross MW, Stacy VS. Nuclear medicine In: Ross MW, Dyson SJ, eds. *Diagnosis and management of lameness in the horse, 2nd ed*. Saint Louis: Elsevier Saunders, 2011;215–234.
4. Ehrlich PJ, Seeherman HJ, O'Callaghan MW, et al. Results of bone scintigraphy in horses used for show jumping, hunting, or eventing: 141 cases (1988-1994). *J Am Vet Med Assoc* 1998;213:1460–1467.
5. Dyson S. Nuclear scintigraphy: Uses and limitations. *Vet J* 2007;173:12–13.
6. Murray RC, Dyson SJ, Weekes JS, et al. Nuclear scintigraphic evaluation of the distal tarsal region in normal horses. *Vet Radiol Ultrasound* 2004;45:345–351.
7. Dyson S, Murray R. Verification of scintigraphic imaging for injury diagnosis in 264 horses with foot pain. *Equine Vet J* 2007;39:350–355.
8. Meehan L, Dyson S, Murray R. Radiographic and scintigraphic evaluation of spondylosis in the equine thoracolumbar spine: A retrospective study. *Equine Vet J* 2009;41:800–807.
9. Gillen A, Dyson S, Murray R. Nuclear scintigraphic assessment of the thoracolumbar synovial intervertebral articulations. *Equine Vet J* 2009;41:534–540.
10. Chambers MD, Martinelli MJ, Baker GJ, et al. Nuclear medicine for diagnosis of lameness in horses. *J Am Vet Med Assoc* 1995;206:792–796.
11. Lohmann KL, Roussel AJ, Cohen ND, et al. Comparison of nuclear scintigraphy and acetaminophen absorption as a means of studying gastric emptying in horses. *Am J Vet Res* 2000;61:310–315.
12. Metayer N, Lhote M, Bahr A, et al. Meal size and starch content affect gastric emptying in horses. *Equine Vet J* 2004;36:436–440.
13. O'Callaghan MW, Hornof WJ, Fisher PE, et al. Exercise-induced pulmonary haemorrhage in the horses: Results of a detailed clinical, post mortem and imaging study. VII. Ventilation/perfusion scintigraphy in horses with EIPH. *Equine Vet J* 1987;19:423–427.
14. O'Callaghan MW. Nuclear imaging techniques for equine respiratory disease. *Vet Clin North Am Equine Pract* 1991;7:417–433.
15. Votion DM, Roberts CA, Marlin DJ, et al. Feasibility of scintigraphy in exercise-induced pulmonary haemorrhage detection and quantification: Preliminary studies. *Equine Vet J* 2010;31:137–142.
16. Ross MW, Maxson AD, Stacy VS, et al. First-pass radionuclide angiography in the diagnosis of aortoiliac thromboembolism in a horse. *Vet Radiol Ultrasound* 1997;38:226–230.
17. Tomlinson JE, Johnson AL, Ross MW, et al. Successful detection and removal of a functional parathyroid adenoma in a pony using technetium Tc 99m sestamibi scintigraphy. *J Vet Intern Med* 2014;28:687–692.
18. Becerra P, Valdes Vazquez MA, Dudhia J, et al. Distribution of injected technetium(99m)-labeled mesenchymal stem cells in horses with naturally occurring tendinopathy. *J Orthop Res* 2013;31:1096–1102.
19. Trela JM, Spriet M, Padgett KA, et al. Scintigraphic comparison of intra-arterial injection and distal intravenous regional limb perfusion for administration of mesenchymal stem cells to the equine foot. *Equine Vet J* 2014;46:479–483.
20. Dudhia J, Becerra P, Valdes MA, et al. In vivo imaging and tracking of technetium-99m labeled bone marrow mesenchymal stem cells in equine tendinopathy. *J Vis Exp* 2015;106:e52748.
21. Spriet M, Buerchler S, Trela JM, et al. Scintigraphic tracking of mesenchymal stem cells after intravenous regional limb perfusion and subcutaneous administration in the standing horse. *Vet Surg* 2015;44:273–280.
22. Long CD, Galuppo LD, Waters NK, et al. Scintigraphic detection of equine orthopedic infection using Tc-HMPAO labeled leukocytes in 14 horses. *Vet Radiol Ultrasound* 2000;41:354–359.
23. Sonmezoglu K, Sonmezoglu M, Halac M, et al. Usefulness of 99mTc-ciprofloxacin (infecton) scan in diagnosis of chronic orthopedic infections: Comparative study with 99mTc-HMPAO leukocyte scintigraphy. *J Nucl Med* 2001;42:567–574.
24. Love C, Marwin SE, Palestro CJ. Nuclear medicine and the infected joint replacement. *Semin Nucl Med* 2009;39:66–78.
25. Hornof WJ, Koblik PD, O'Brien TR. Use of nuclear scintigraphy to characterize in intrathoracic mass in a foal. *J Am Vet Med Assoc* 1982;180:1319–1322.
26. Erichsen C, Eksell P, Holm KR, et al. Relationship between scintigraphic and radiographic evaluations of spinous processes in the thoracolumbar spine in riding horses without clinical signs of back problems. *Equine Vet J* 2004;36:458–465.
27. Zimmerman M, Dyson S, Murray R. Comparison of radiographic and scintigraphic findings of the spinous processes in the equine thoracolumbar region. *Vet Radiol Ultrasound* 2011;52:661–671.
28. Zimmerman M, Dyson S, Murray R. Close, impinging and overriding spinous processes in the thoracolumbar spine: The relationship between radiological and scintigraphic findings and clinical signs. *Equine Vet J* 2012;44:178–184.
29. Driver A. Basic principles of equine scintigraphy In: Dyson SJ, Pilsworth RC, Twardock AR, Martinelli MJ, eds. *Equine scintigraphy*. Suffolk: Equine Veterinary Journal, 2003;17–24.
30. Dyson S. Patient preparation In: Dyson S, Pilsworth RC, Twardock AR, Martinelli MJ, eds. *Equine scintigraphy*. Suffolk: Equine Veterinary Journal, 2003;69–72.
31. Griffin JFt, Young BD, Fosgate GT, et al. Focal skeletal muscle uptake of 99mTechnetium-hydroxymethylene diphosphonate following peroneal nerve blocks in horses. *Vet Radiol Ultrasound* 2010;51:338–343.
32. Trout DR, Hornof WJ, Liskey CC, et al. The effects of regional perineural anesthesia on soft tissue and bone phase scintigraphy in the horse. *Vet Radiol Ultrasound* 1991;32:140–144.
33. Graham S, Solano M, Sutherland-Smith J, et al. Diagnostic sensitivity of bone scintigraphy for equine stifle disorders. *Vet Radiol Ultrasound* 2015;56:96–102.
34. Levine DG, Ross BM, Ross MW, et al. Decreased radiopharmaceutical uptake (photopenia) in delayed phase scintigraphic images in three horses. *Vet Radiol Ultrasound* 2007;48:467–470.
35. Stover SM, Hornof WJ, Richardson GL, et al. Bone scintigraphy as an aid in the diagnosis of occult distal tarsal bone trauma in three horses. *J Am Vet Med Assoc* 1986;188:624–628.
36. Markel MD, Snyder JR, Hornof WJ, et al. Nuclear scintigraphic evaluation of third metacarpal and metatarsal bone fractures in three horses. *J Am Vet Med Assoc* 1987;191:75–77.
37. Boero MJ, Kneller SK, Baker GJ, et al. Clinical, radiographic, and scintigraphic findings associated with enthesitis of the lateral collateral ligaments of the tarsocrural joint in Standardbred racehorses. *Equine Vet J* 2010;20:53–59.
38. Lloyd KC, Koblik P, Ragle C, et al. Incomplete palmar fracture of the proximal extremity of the third metacarpal bone in horses: Ten cases (1981-1986). *J Am Vet Med Assoc* 1988;192:798–803.
39. Johnson PJ, Allhands RV, Baker GJ, et al. Incomplete linear tibial fractures in two horses. *J Am Vet Med Assoc* 1988;192:522–524.
40. Koblik PD, Hornof WJ, Seeherman HJ. Scintigraphic appearance of stress-induced trauma of the dorsal cortex of the third metacarpal bone in racing Thoroughbred horses: 121 cases (1978-1986). *J Am Vet Med Assoc* 1988;192:390–395.
41. Wisner ER, O'Brien TR, Pool RR, et al. Osteomyelitis of the axial border of the proximal sesamoid bones in seven horses. *Equine Vet J* 1991;23:383–389.
42. Trout DR, Hornof WJ, O'Brien TR. Soft tissue- and bone-phase scintigraphy for diagnosis of navicular disease in horses. *J Am Vet Med Assoc* 1991;198:73–77.

43. Keegan KG, Twardock AR, Losonsky JM, et al. Scintigraphic evaluation of fractures of the distal phalanx in horses: 27 cases (1979-1988). *J Am Vet Med Assoc* 1993;202:1993–1997.
44. Pilsworth RC, Shepherd MC, Herinckx BM, et al. Fracture of the wing of the ilium, adjacent to the sacroiliac joint, in Thoroughbred racehorses. *Equine Vet J* 1994;26:94–99.
45. Edwards RB III, Ducharme NG, Fubini SL, et al. Scintigraphy for diagnosis of avulsions of the origin of the suspensory ligament in horses: 51 cases (1980-1993). *J Am Vet Med Assoc* 1995;207:608–611.
46. Ruggles AJ, Moore RM, Bertone AL, et al. Tibial stress fractures in racing standardbreds: 13 cases (1989-1993). *J Am Vet Med Assoc* 1996;209:634–637.
47. Geissbuhler U, Busato A, Ueltschi G. Abnormal bone scan findings of the equine ischial tuberosity and third trochanter. *Vet Radiol Ultrasound* 1998;39:572–577.
48. Tucker RL, Schneider RK, Sondhof AH, et al. Bone scintigraphy in the diagnosis of sacroiliac injury in twelve horses. *Equine Vet J* 1998;30:390–395.
49. Ross MW. Scintigraphic and clinical findings in the Standardbred metatarsophalangeal joint: 114 cases (1993-1995). *Equine Vet J* 1998;30:131–138.
50. Bassage LH, Ross MW. Enostosis-like lesions in the long bones of 10 horses: Scintigraphic and radiographic features. *Equine Vet J* 1998;30:35–42.
51. Ehrlich PJ, Dohoo IR, O'Callaghan MW. Results of bone scintigraphy in racing Standardbred horses: 64 cases (1992-1994). *J Am Vet Med Assoc* 1999;215:982–991.
52. Weller R, Livesey L, Maierl J, et al. Comparison of radiography and scintigraphy in the diagnosis of dental disorders in the horse. *Equine Vet J* 2001;33:49–58.
53. Erichsen C, Eksell P, Widstrom C, et al. Scintigraphy of the sacroiliac joint region in asymptomatic riding horses: Scintigraphic appearance and evaluation of method. *Vet Radiol Ultrasound* 2003;44:699–706.
54. Dyson S, Murray R, Branch M, et al. The sacroiliac joints: Evaluation using nuclear scintigraphy. Part 2: Lame horses. *Equine Vet J* 2003;35:233–239.
55. Dyson S, Murray R, Branch M, et al. The sacroiliac joints: Evaluation using nuclear scintigraphy. Part 1: The normal horse. *Equine Vet J* 2003;35:226–232.
56. Davidson EJ, Martin BB Jr., Stress fracture of the scapula in two horses. *Vet Radiol Ultrasound* 2004;45:407–410.
57. Davenport-Goodall CL, Ross MW. Scintigraphic abnormalities of the pelvic region in horses examined because of lameness or poor performance: 128 cases (1993-2000). *J Am Vet Med Assoc* 2004;224:88–95.
58. Murray RC, Dyson SJ, Weekes JS, et al. Scintigraphic evaluation of the distal tarsal region in horses with distal tarsal pain. *Vet Radiol Ultrasound* 2005;46:171–178.
59. Smith RK, Dyson SJ, Schramme MC, et al. Osteoarthritis of the talocalcaneal joint in 18 horses. *Equine Vet J* 2005;37:166–171.
60. Ahern BJ, Boston RC, Ross MW. Enostosis-like lesions in equids: 79 cases (1997-2009). *J Am Vet Med Assoc* 2014; 245:1042–1047.
61. Sporn A, Berner D, Winter K, et al. Quantitative evaluation of bone scintigraphy of the spinous processes of the equine thoracic spine at different times after administering 99mTc-hydroxymethylene-diphosphonate. *Vet Rec* 2014;174:505.
62. Wulster KB. Diagnosis of skeletal injury in the sport horse. *Vet Clin North Am Equine Pract* 2018;34:193–213.
63. Swor TM, Schneider RK, Ross MW, et al. Injury to the origin of the gastrocnemius muscle as a possible cause of lameness in four horses. *J Am Vet Med Assoc* 2001;219:215–219.
64. Archer DC, Cotton JC, Boswell JC. Non-skeletal scintigraphy of the horse: Indications and validity. *Vet J* 2007;173:45–56.
65. Walmsley EA, Steel CM, Richardson JL, et al. Muscle strain injuries of the hindlimb in eight horses: Diagnostic imaging, management and outcomes. *Aust Vet J* 2010;88:313–321.

Positron Emission Tomography

Mathieu Spriet, DVM, MS, DACVR, DECVDI, DACVR-EDI

Author's address: School of Veterinary Medicine, University of California-Davis, Davis, CA 95616; e-mail: mspriet@ucdavis.edu. © 2022 AAEP.

1. Background

Positron emission tomography (PET) is the latest addition to the equine imaging arsenal. The first ever equine PET scan was performed at the University of California, Davis in 2015, using a compact high-resolution PET scanner designed to image the human brain.[a1] This scanner was used to perform over 150 equine studies in a 5-year period, but all these scans had to be performed under general anesthesia. In 2019, a PET scanner specifically designed to image the distal limb of standing horses[b] became available.[2] The ability to perform equine PET without general anesthesia has resulted in a steep increase in clinical use of this new imaging modality. As of January 2022, over 700 standing equine PET studies have been performed. With 3 imaging centers currently equipped, each performing 150 to 200 studies a year, and at least 4 other sites to be equipped during 2022, the number of equine PET studies will keep quickly increasing.

2. Principles

PET is a nuclear medicine imaging technique. Similar to scintigraphy, PET requires the intravenous injection of a radioactive tracer prior to imaging. The major difference between PET and scintigraphy is that PET is a cross-sectional imaging technique; instead of projecting a 2-dimensional image like scintigraphy, PET presents information in 3 dimensions. Similar to computed tomography (CT) or magnetic resonance imaging (MRI), the PET data can be displayed either as a stack of 2-dimensional images or using 3-dimensional rendering display techniques, such as multiplanar reformatting or maximal intensity projections.

As a nuclear medicine imaging technique, PET provides functional information about the tissues being imaged. This means instead of reporting the shape, size, or density of the body parts being imaged, like structural imaging techniques such as radiography and CT, PET provides information about activity happening at the molecular level, based on the biodistribution and specific accumulation of the radiotracer used.

Several radiotracers are available for PET imaging; two of them are routinely used for clinical applications in horses: 18F-fluorodeoxyglucose (18F-FDG)[1,3,4] and 18F-sodium fluoride (18F-NaF).[5–7] 18F-FDG is a marker of metabolic activity of glucose, commonly used for oncological imaging in human medicine. This tracer, however, is not specific for the metabolic activity of tumors and can be used in horses for assessment of inflammation in soft tissues. 18F-NaF is an excellent marker of bone turnover. Similar to the bisphosphonate radiotracers used in scintigraphy, 18F-NaF becomes integrated to exposed hydroxyapatite matrix, detecting areas with osteoblastic or osteoclastic activity.

3. Imaging Logistics

An intravenous jugular catheter is necessary for injection of the radiotracers. Typically, the radiotracers are injected 30 to 60 minutes prior to imaging to allow

NOTES



Fig. 1. A, The PET scanner,[b] specifically designed for imaging of the distal limb in standing horses, presented here with the ring in an open position. B, Imaging of a racehorse fetlock with the equine PET scanner.[b]

time for biodistribution and accumulation at sites of increased metabolic activity. Once the tracers have been injected, horses need to be housed and handled according to local radiation safety regulations, similar to scintigraphy patients. Based on the 2-hour half-life of the 18F radiotracers, patients can typically be released from radiation safety protocols within 5 to 8 hours after injection.

The scanner used for imaging of the distal limb in standing horses[b] was specifically designed for this application. It is composed of an openable ring of PET detectors, with a 25-cm internal diameter, that is positioned parallel to the ground and set up on a wheel frame (Fig. 1).[2] The scanner is pushed toward the sedated horse with the ring in an open position and centered on the limb to image. The ring is then manually closed but is able to freely open if the horse were to move. The height adjustment goes from ground level to 64 cm above the ground, allowing for imaging from the foot to the distal radius or tibia. The detector height is 8 cm, but because the ring can translate vertically during imaging over 14 cm, a maximal axial field of view of 22 cm can be obtained per scan.

Acquisition time for each scan ranges between 2 and 6 minutes depending on the site being imaged, the quality of uptake, and the selected axial field of view.[2] Including positioning time, imaging of both front fetlocks, for example, takes approximately 10 minutes. In 20 minutes, it is possible to image all 4 fetlocks or both front feet and front fetlocks. Although not available in the original standing equine PET validation study, a postprocessing motion correction tool is now available, rendering the acquisition fairly resistant to swaying motion during sedation, which is particularly beneficial for imaging the carpus or tarsus.

4. Applications

As equine PET is a recently introduced modality, the range of its applications is still evolving. The

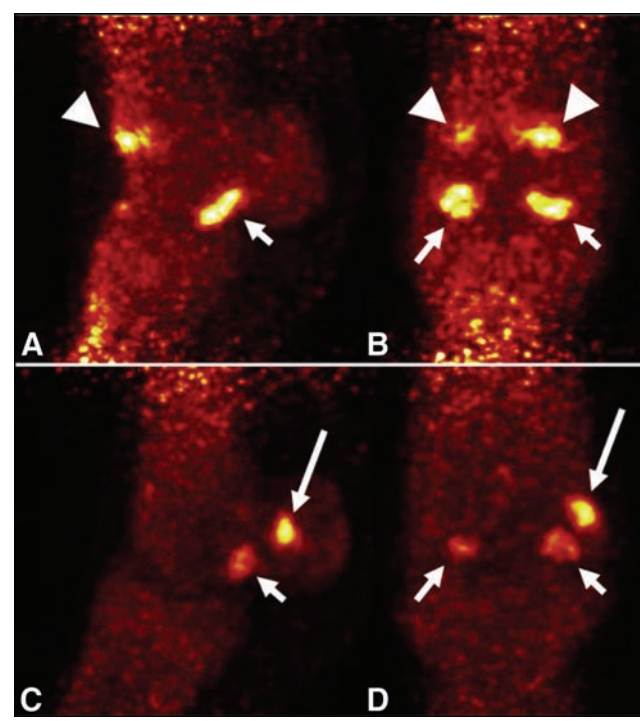

Fig. 2. Lateral (A, C) and dorsal (B, D) maximal intensity projections of 18F-NaF PET images of the fetlocks of two different racehorses. The horse on the top row (A, B) shows moderate to severe focal uptake in the palmar metacarpal condyles (short arrows) and at the dorsal aspect of the third metacarpal bone (arrowheads). The horse on the bottom row shows mild focal uptake in the palmar metacarpal condyles (short arrows) but marked focal uptake at the dorsal abaxial aspect of the medial proximal sesamoid bone, a site where subchondral injury is associated with sesamoid fracture.

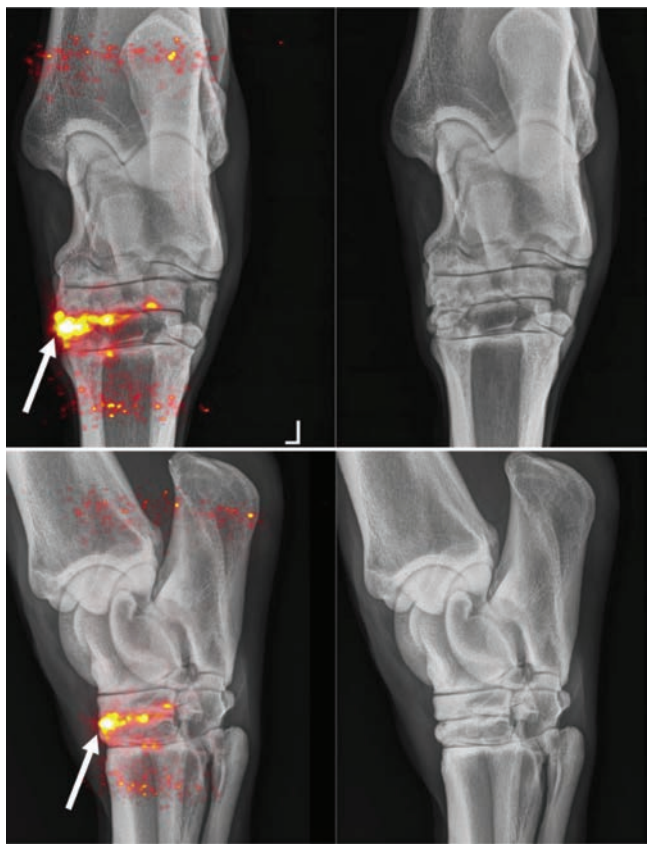

Fig. 3. 18F-NaF PET images of the tarsus of a horse with lameness localized to the distal tarsal/proximal metatarsal area overlaid on dorsoplantar (top row) and dorsolateral-plantaromedial oblique radiographs. Despite mild radiographic changes, the PET confirms marked remodeling activity at the dorsomedial aspect of the distal intertarsal joint (arrows). Note that the linear uptake across the distal tibia and proximal metacarpus is artifactual at the edge of the PET field of view.

majority of equine studies are performed with 18F-NaF, but 18F-FDG has specific applications for tendon or ligament imaging and for assessment of laminitis.

18F-NaF PET as 3D Bone Scan

Based on the similarities with scintigraphy, the first 18F-NaF PET application was imaging of the racehorse fetlock. An exploratory study confirmed the value of 18F-NaF PET to detect sites of increased radiopharmaceutical uptake not appreciated with scintigraphy,[7] in particular involving the proximal sesamoid bones (Fig. 2). The findings of the exploratory study were confirmed in the first standing equine PET clinical study, comparing 18F-NaF PET and scintigraphy in 33 racehorses (72 fetlocks).[8] In this study, the interobserver agreement for PET was higher than for scintigraphy, and PET detected more lesions than scintigraphy. The agreement between PET and scintigraphy for detection of increased uptake was highest for palmar/plantar metacarpal/metatarsal condylar sites, but PET detected abnormalities in 22.2% of the medial proximal sesamoid bones in this population compared with 6.9% for scintigraphy. Similarly, increased uptake in the proximal phalanx was identified much more commonly with PET than with scintigraphy (6.9% vs. 1.4%). In addition to the higher detection rate of abnormalities in the proximal sesamoid bones, PET allowed more detailed characterization of the site of uptake. The most common location for increased radiopharmaceutical uptake in the proximal sesamoid bones in a population of 130 racehorses was the dorsal subchondral bone of the medial sesamoid, a site where bone remodeling has been associated with complete midbody sesamoid fractures. For this reason, PET seems to have a major role to play in fracture risk assessment in racehorses.

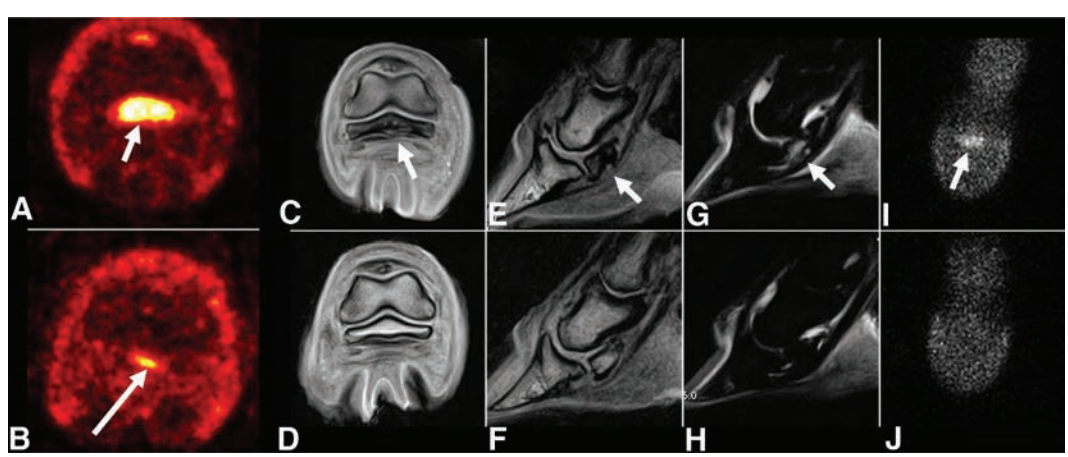

Fig. 4. 18F-NaF PET (A, B), low field standing MRI (C–H), and bone scintigraphy (I, J) images of the left (top row) and right (bottom row) fore feet of a Quarter Horse mare with left fore lameness. There is marked 18F-NaF uptake in the left fore navicular bone (short arrow). The bone is abnormal on MRI (T1 hypointensity, STIR hyperintensity, and lysis of the flexor cortex), and increased uptake is also recognized with scintigraphy (short arrows). Focal 18F-NaF uptake is recognized at the sagittal ridge of the flexor surface of the right fore navicular bone (long arrow). Other imaging modalities did not detect any abnormality at this site.[6]

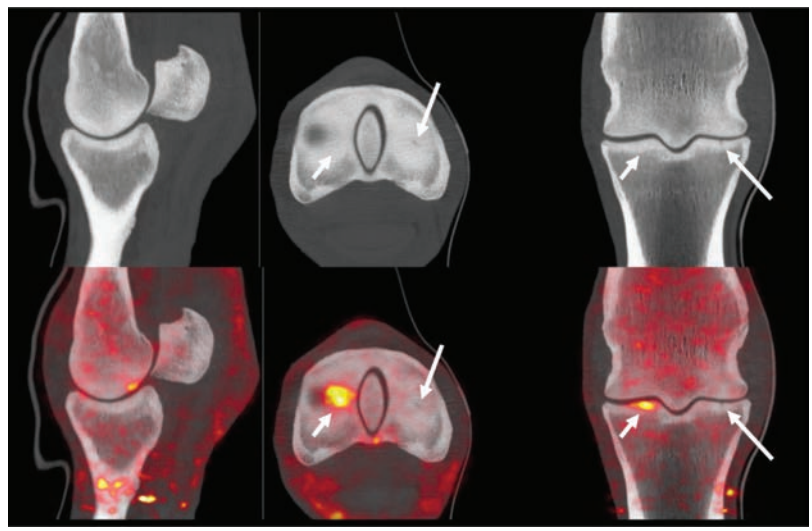

Fig. 5. Multiplanar reformatted CT images (top row) and fused 18F-NaF PET/CT images (bottom row) of the left hind fetlock of a 14-year-old off-the-track Thoroughbred used for eventing. There is marked focal increased 18F-NaF uptake in the medial compact subchondral bone of the proximal phalanx without associated CT abnormality (short arrow). (Note that the lucency adjacent to the uptake in the transverse plane is a slice thickness artifact.) There is a focal short linear defect in the lateral compact subchondral bone of the proximal phalanx (long arrow), without associated 18F-NaF uptake. This suggests that the lateral lesion is an inactive lesion, likely developmental, whereas there is early stress remodeling of the medial subchondral bone.

The carpus and tarsus are other imaging sites where PET demonstrates obvious advantages over scintigraphy to better define anatomical location of abnormalities. The carpus is the second anatomical site most commonly imaged with PET in racehorses. PET allows uptake from the dorsoproximal aspect of the third carpal bone to be distinguished from the dorsodistal aspect of the radial carpal bone, which typically cannot be resolved with scintigraphy. PET of the tarsus is particularly interesting in sport horses with lameness localized to the distal tarsus or proximal metatarsal area. PET is able to distinguish active from inactive distal tarsal osteoarthritis and also easily detects proximal enthesopathy of the origin of the suspensory ligament (Fig. 3).

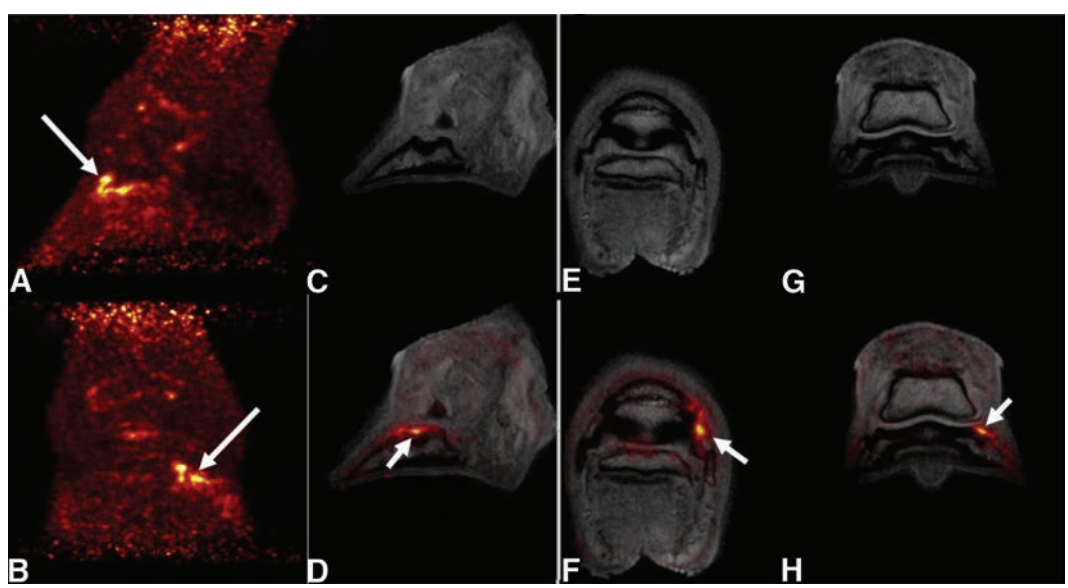

Fig. 6. Lateral (A) and dorsal (B) maximal intensity projections of 18F-NaF PET, multiplanar reformat standing low field 3D T1 isotropic MRI (C, E, G) and fused PET/MRI (D, H, F) of the left fore foot of a horse with lameness localized to this region. The 18F-NaF PET demonstrates focal increased uptake at the proximal lateral aspect of the distal phalanx (long arrows). The fused PET/MRI confirms that this uptake is associated with the attachment of the collateral ligament of the distal interphalangeal joint (short arrows). Changes were not appreciated on MRI in the soft tissue part of the ligament, and the lesion was considered an enthesopathy rather than a desmitis.

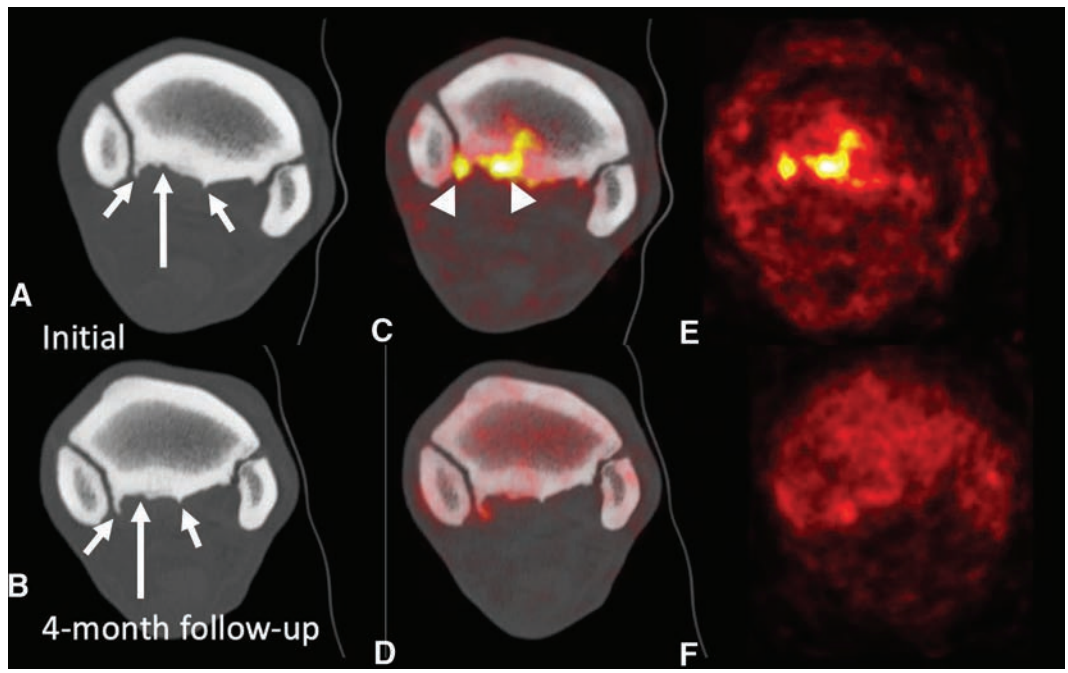

Fig. 7. Transverse CT (A, B), fused 18F-NaF PET/CT (C, D), and 18F-NaF PET (E, F) images of the proximal metacarpus of a 4-year-old Quarter Horse. The top row shows the initial scan when lameness was localized to this area, and the bottom row is a recheck 4 months later when lameness had resolved. There is irregularity of the palmar aspect of the third metacarpal bone at the site of attachment of the suspensory ligament with evidence of both resorption (long arrow) and enthesophyte formation (short arrows) on the initial CT images. This is associated with marked focal increased 18F-NaF uptake on the initial scan (arrowheads). On the recheck scan, the CT changes remain similar (arrows); however, the 18F-NaF uptake has resolved, confirming resolution of the active remodeling.

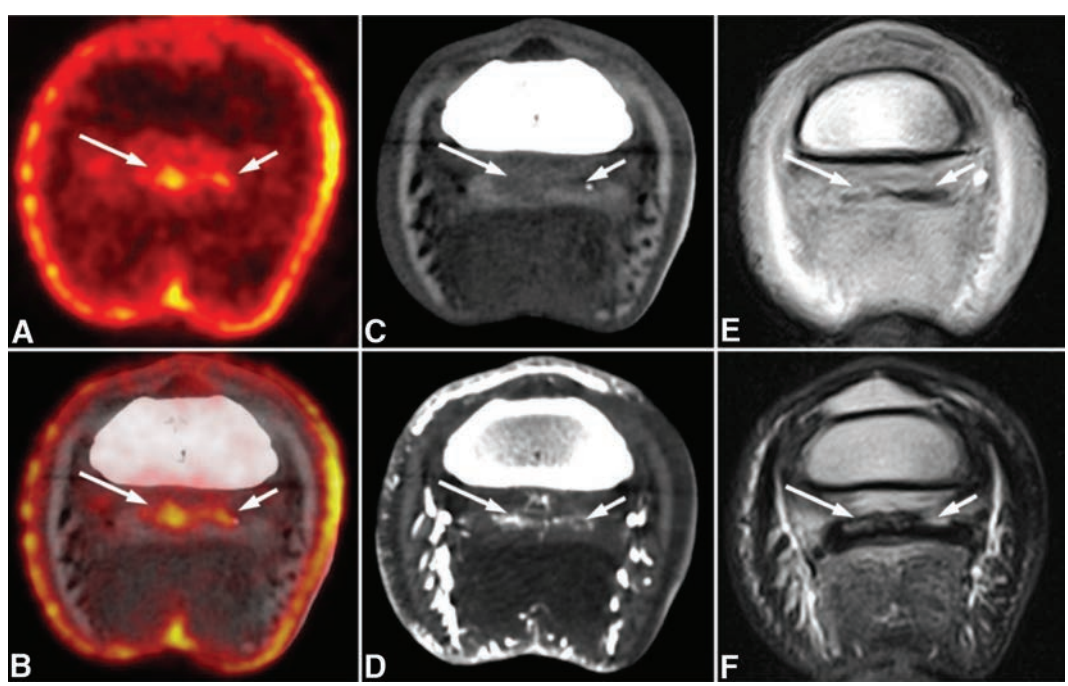

Fig. 8. Transverse 18F-FDG PET (A), fused PET/CT (B), noncontrast (C), and arterial contrast (D) CT, T1-w MRI (E), and T2-w MRI (F) images of the right fore foot of a 14-year-old Quarter Horse mare with lameness localized to this foot. Lateral is to the left. There are two focal areas of marked increased 18F-FDG uptake at the dorsal aspect of the DDFT, with the lateral area of uptake (long arrow) larger than the medial one (short arrow). These correspond to hypoattenuating areas on noncontrast CT with presence of arterial contrast enhancement and hyperintensity noticed both on T1-w and T2-w MRI. On all modalities, the changes are more severe at the dorsal aspect of the lateral lobe (long arrow) when compared with the medial lobe (short arrow). This demonstrates biaxial active supranavicular dorsal fibrillation of the DDFT.[3]

18F-NaF PET Combined with CT or MRI for Optimal Bone Imaging

Based on similar cross-sectional imaging properties, PET can be overlaid with CT or MRI to create "fused" images. A dedicated software[c] allows PET data to be aligned with CT or MRI images acquired with other scanners.[9] The combination of the functional information from PET with the structural information from CT or MRI provides optimal assessment of the imaged area. PET/CT or PET/MRI fusion is particularly helpful for assessment of subchondral bone and enthesis. These regions are common sites of lesions for which both CT and MRI have some limitations.

For subchondral bone assessment, the detection of abnormalities on CT relies mostly on changes in the bone density, but sclerosis is very common and not specific for lameness causing pathology, and resorption is typically only detected in the later stages of subchondral injury. MRI with the use of fluid-sensitive sequences can detect earlier changes in bone than CT. This is particularly true for the trabecular subchondral bone where fluid accumulation can easily be recognized. However, MRI is much more limited in the assessment of the dense compact subchondral bone as changes in the compact subchondral bone are only detected with CT and MRI when the lesion has progressed to significant resorption. Standing MRI image quality is also more greatly affected by patient motion compared to standing PET.

The value of 18F-NaF for assessment of early changes in the compact bone was established in the initial equine PET pilot study as focal increased 18F-NaF uptake was detected in the sagittal ridge of the flexor surface of the navicular bone of a horse where no abnormality had been detected with CT, MRI, and scintigraphy. This horse had a resorptive lesion at limb (Fig. 4).

The combination of PET with CT was proven particularly helpful for assessment of the fetlock in a population of sport horses.[10] The most common sites of increased uptake were the medial subchondral bone of the proximal phalanx and the dorsomedial aspect of the distal third metacarpal bone. These are common sites of lesions, and the presence of increased uptake was associated with lameness in this population, based on diagnostic analgesia. In addition to recognizing sites of subchondral bone activity, PET can help determine the clinical significance of other CT findings. For example, a focal subchondral defect apparent on CT without associated increased 18F-NaF uptake suggests that the lesion is not active (Fig. 5).

Diagnosing enthesopathies is also challenging because of a requirement to detect changes in dense bone. PET seems particularly capable of detecting abnormalities at the attachments of the collateral ligament of the distal interphalangeal joint (Fig. 6). Increased uptake can also be recognized with PET at the attachment of the distal sesamoidean impar ligament on the distal phalanx. PET also identified the attachment of the chondrosesamoidean ligament on the distal phalanx as a possible site of injury. This lesion has been recognized in a population of horses with foot lameness.[5] In the majority of cases, this finding was associated with other navicular apparatus lesions, but in a few cases, the chondrosesamoidean enthesopathy was considered the primary source of lameness. Another common issue in the diagnosis of

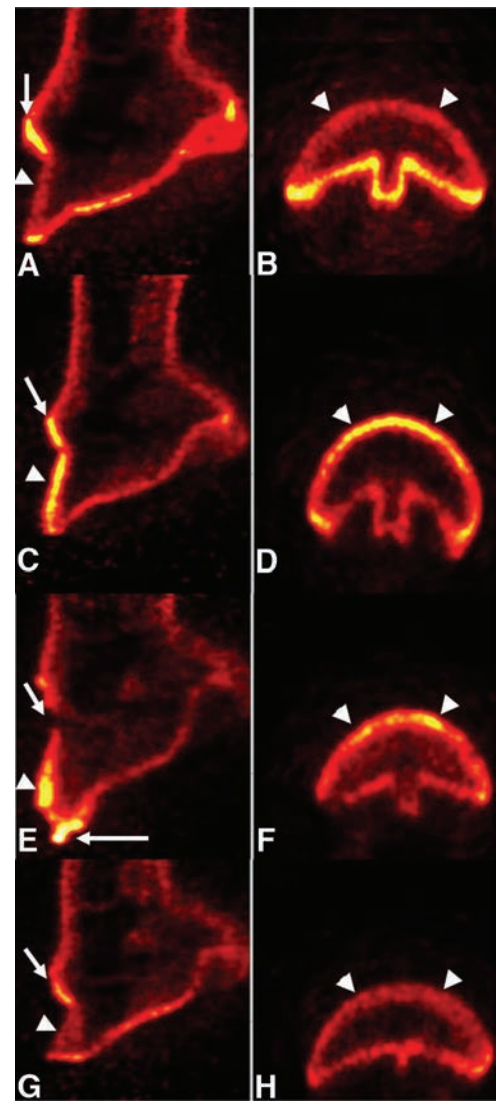

Fig. 9. Sagittal (left column) and transverse (right column) 18F-FDG images of the feet of 4 different horses. A, B, Normal horse, marked 18F-FDG uptake is present in the coronary band (arrow) with low uptake in the dorsal hoof wall (arrowheads). C, D, Horse with early acute laminitis; there is increased 18F-FDG uptake in the dorsal hoof wall (arrowheads). E, F, Horse with severe acute laminitis with protrusion of the distal phalanx through the sole. There is loss of 18F-FDG uptake at the coronary band (arrow). Marked increased 18F-FDG uptake is present in the distal dorsal hoof wall (arrowheads) and at the dorsal aspect of the sole at the site of protrusion of the distal phalanx (long arrow). G, H, Horse with quiescent chronic laminitis. There is decreased 18F-FDG uptake at the coronary band (arrow). The dorsal hoof wall appears distorted but presents a normal low 18F-FDG uptake (arrowheads).

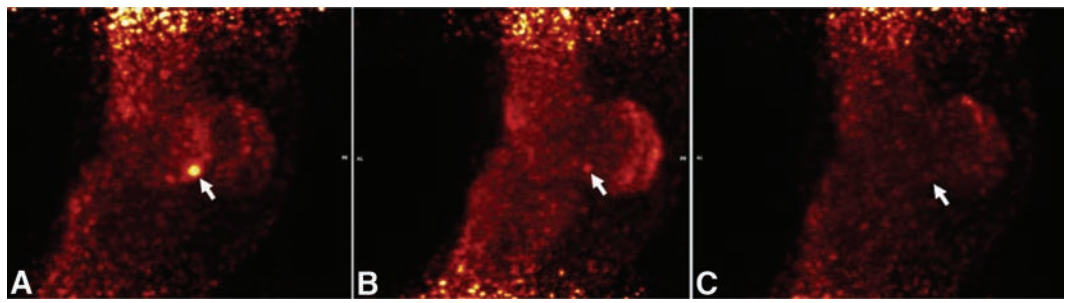

Fig. 10. Maximal intensity projection, lateral view, of 18F-NaF PET data of the left fore fetlock of a Thoroughbred racehorse with marked increased 18F-NaF uptake in the palmar metacarpal condyle (short arrow) on the initial scan (A), which is still apparent but improved at the 6-week follow-up scan (B) and resolved at the 12-week follow-up scan (C).

enthesopathies is the assessment of the significance of bone contour irregularities. For example, at the suspensory origin, it is fairly common to see the development of enthesophytes or focal areas of osseous resorption with other imaging modalities. This abnormal contour typically remains after resolution of the activity of lesions and can be appreciated in the inactive state (Fig. 7). PET has the ability to differentiate active enthesophyte formation or osseous resorption from chronic inactive changes.

18F-FDG PET Combined with CT or MRI for Staging of Soft Tissue Lesions

The ability of 18F-FDG PET to detect tendon lesions was identified in the original equine PET pilot study with an example of a deep digital flexor tendon (DDFT) lesion showing marked 18F-FDG increased uptake. A larger study in 8 horses with foot lameness compared PET findings with CT and MRI and confirmed the ability of PET to detect DDFT lesions (Fig. 8).[3] 18F-FDG PET detected fewer lesions than CT and MRI, but this can be explained by the functional aspect of the modality. Chronic inactive lesions tend to remain apparent on noncontrast enhanced CT and on certain MRI sequences, but only lesions with active changes will show increased uptake on PET. This is particularly helpful in staging lesions and determining the clinical significance. 18F-FDG PET/CT has also been used in a small group of horses with suspected proximal suspensory desmitis.[11]

18F-FDG PET for Assessment of Laminitis

The ability to assess glucose metabolic activity in the foot with 18-FDG is particularly interesting for assessment and monitoring of laminitis. A pilot study in cases with severe laminitis confirmed that horses with acute laminitis demonstrate increased 18F-FDG uptake in the dorsal hoof wall.[4] Another interesting finding was that the 18F-FDG uptake decreases in the coronary band of horses with laminitis, both acute and chronic (Fig. 9). An ongoing study with repeated 18F-FDG PET scans in horses with chronic laminitis seems to confirm the association between clinical signs and amount of 18F-FDG uptake. Further work is needed to fully establish the role of PET in laminitic cases, but the early data are encouraging for PET to become a pertinent monitoring tool in chronic cases and potentially a prognostic indicator in acute laminitis.

PET for Longitudinal Monitoring of Lesions

Based on the functional nature of PET assessment, PET is particularly suitable for following lesions, both for assessing healing and monitoring recurrence. The ability to quantify the uptake with using standardized uptake values (SUVs) adds to the convenience of comparison between different scans. The SUV is a measure of the amount of radioactivity per area, taking into consideration the administered dose, the time between injection and image acquisition for decay correction, and the weight of the patient. The maximal SUV (SUVmax) is the most convenient for assessment of lesions. Normal equine bone typically has an SUVmax between 3 and 5, whereas SUVmax of lesions can be as high as 60. In the soft tissue, the SUVs remain much lower as normal tendons have an SUVmax of 1 or lower and lesions typically are in the 3 to 5 SUVmax range. A longitudinal study assessing lesion healing in racehorse fetlocks during lay-up, 6 and 12 weeks after diagnosis, demonstrated that lesions with lower SUVmax were more likely to resolve faster.[12] The majority of the initially diagnosed lesions were resolved or improved 12 weeks after the initial diagnosis (Fig. 10). The exact lesion site had an effect on the likelihood of the uptake to resolve. Another study also in racehorses looked at monitoring possible fetlock lesion recurrence once horses were back in training. Horses were scanned when returning to training after lay-up and 1, 2, 4, and 6 months later. Most horses did not show significant abnormalities at 1 and 2 months, but abnormal uptake reoccurred in about half of the horses after 4 months. Abnormal uptake was more likely to develop at the site of the original lesion that had been responsible for the lay-up than in a different location.

Outside of these two racehorse longitudinal studies, follow-up scans have been performed in a clinical population of sport horses, in particular for assessment of subchondral lesions or enthesopathies with 18F-NaF, and for tendon lesions using 18F-FDG. As previously mentioned, a study is currently assessing the value of

repeated 18F-FDG PET scans for management of horses with chronic laminitis.

5. Conclusions

PET is a relatively new imaging modality for horses but has already found many applications. 18F-NaF PET can be described as an improved 3D bone scan. Its ability to fuse with CT and MRI to provide functional information is particularly pertinent to detect early lesions or determine the significance of structural changes. 18F-FDG PET is helpful for assessing the activity of soft tissue lesions, in particular in the DDFT or suspensory ligament. It also has pertinent applications in the assessment of laminitis.

Acknowledgments

Declaration of Ethics

The Author has adhered to the Principles of Veterinary Medical Ethics of the AVMA.

Conflict of Interest

Dr. Spriet has an affiliation with LONGMILE Veterinary PET Imaging as an unpaid volunteer scientific advisor.

References and Footnotes

1. Spriet M, Espinosa P, Kyme AZ, et al. Positron emission tomography of the equine distal limb: Exploratory study. *Vet Radiol Ultrasound* 2016;57:630–638.
2. Spriet M, Edwards L, Arndt S, et al. Validation of a dedicated positron emission tomography scanner for imaging of the distal limb of standing horses. *Vet Radiol Ultrasound*. Published online February 21, 2022.
3. Wilson S, Spriet M, Mur PE, et al. Fluorine-fluorodeoxyglucose positron emission tomography for assessment of deep digital flexor tendinopathy: An exploratory study in eight horses with comparison to CT and MRI. *Vet Radiol Ultrasound* 2021;62:610–620.
4. Spriet M, Cullen T, Espinosa P, et al. 18F-FDG PET for assessment of the hoof lamina in normal, laminitic and lame horses, in abstracts of the European Veterinary Diagnostic Imaging (EVDI) Congress, Basel Switzerland, August 21–24, 2019. *Vet Radiol Ultrasound* 2020;61:85–118. https://doi.org/10.1111/vru.12818.
5. Norvall A, Spriet M, Espinosa P, et al. Chondrosesamoidean ligament enthesopathy: Prevalence and findings in a population of lame horses imaged with positron emission tomography. *Equine Vet J* 2021;53:451–459.
6. Spriet M, Espinosa P, Kyme AZ, et al. (18) F-sodium fluoride positron emission tomography of the equine distal limb: Exploratory study in three horses. *Equine Vet J* 2018;50: 125–132.
7. Spriet M, Espinosa-Mur P, Cissell DD, et al. F-sodium fluoride positron emission tomography of the racing Thoroughbred fetlock: Validation and comparison with other imaging modalities in nine horses. *Equine Vet J* 2019; 51:375–383.
8. Spriet M, Arndt S, Pige C, et al. Comparison of bone scintigraphy and standing 18F-NaF positron emission tomography for imaging of the fetlock in Thoroughbred racehorses, in *Proceedings*. Am Assoc Equine Pract 2021;67:488–489.
9. Sannajust K, Spriet M, Anishchenko S, et al. Standardized uptake values and attenuation correction in 18F- sodium fluoride PET of the equine foot and fetlock, in *Vet Radiol Ultrasound*. 2022; *in press*. https://doi.org/10.1111/vru.13127.
10. Pige C, Spriet M, Katzman SA, et al. Comparison of 18F-sodium fluoride positron emission tomography and computed tomography for imaging of the fetlock in 25 sport horses. *Vet Radiol Ultrasound*. 2022; in press. https://doi.org/10.1111/vru.13127.
11. Arndt S, Spriet M, Pige C, et al. Assessment of dual-tracer positron emission tomography in a clinical population of horses with lameness localized to the distal tarsal/proximal metatarsal. Scientific Presentation Abstracts ACVS Surgery Summit 2021. *Vet Surg*, 2021;50:3. https://doi.org/10.1111/vsu.13706.
12. Pye J, Spriet M, O'Brion J, et al. Standing 18F-NaF positron emission tomography (PET) monitoring of fetlock injuries in Thoroughbred racehorses during layup, in *Proceedings*. Am Assoc Equine Pract 2021; 67:490–491.

[a]piPET Brain Biosciences, Inc., Rockville, MD 20852.
[b]MILE-PET, LONGMILE Veterinary Imaging, Division of Brain Biosciences, Inc., Rockville, MD 20852.
[c]Galatea, LONGMILE Veterinary Imaging, Rockville MD 20852.

Computed Tomography

Kyla Ortved, DVM, PhD, DACVS, DACVSMR

Computed tomography is a highly valuable cross-sectional imaging modality that can aid in diagnosis, surgical planning, and treatment of horses. Author's address: New Bolton Center, University of Pennsylvania, 382 West Street Road, Kennett Square, PA 19348; e-mail: kortved@vet.upenn.edu. © 2022 AAEP.

1. Introduction

Computed tomography (CT) was introduced into veterinary medicine in the early 1990s. Its use in equine medicine was gradual with only a few institutions using CT on a regular basis. However, recent advancements in technology and design have facilitated a rapid increase in its use. CT is a cross-sectional imaging modality that uses x-ray beams to generate tomographic slices of the animal. It has superior spatial resolution compared to radiographs, which allows for differentiation between bone and soft tissue. Conventional fan beam CT machines require the use of a fixed horizontal gantry requiring the horse to be placed under general anesthesia for image acquisition. Images are acquired by the x-ray generator and detector moving around the gantry in a helical fashion. Fixed CT machines require the use of a specialized CT table that move the point of interest through the gantry at a specified speed. Smaller, mobile gantries are also available and can be very useful for intraoperative imaging.

More recently, numerous CT systems have been made available in which several body parts can be scanned in the standing, sedated horse. Both standing fan beam and cone beam CT systems are currently available.[a-c] These systems require the horse to have the region of interest placed inside the enclosed gantry (Fig. 1). Cone beam CT uses diverging radiation emitted in a cone shape that is detected by a detector plate and is not limited by fixed annulus geometry. The open geometry of the cone beam CT creates a more flexible system that can be controlled by robotic arms (Fig. 2); however, the spatial resolution is lower than that of fan beam CT.

Computed tomography is considered a superior imaging modality for evaluating bone. Evaluation of soft tissues is limited especially compared to magnetic resonance imaging (MRI) which offers better spatial resolution. Contrast-enhanced CT (CE-CT) can be used to overcome some of the limitations in soft tissue imaging. Contrast agents can be administered intravascularly or intra-articularly to highlight soft tissue and joint pathology.[1] In equine medicine, CT is most useful, and at times critical, for early detection of bone pathology (e.g., subchondral bone injury); areas with complex anatomy where superimposition makes interpretation of plain radiographs challenging (e.g., head, cervical spine); surgical planning in complex fractures (e.g., comminuted P1 fractures); surgical planning for fractures that do not allow adequate fluoroscopic or radiographic projections (e.g., tarsal slab fractures); and surgical planning for bones with lack of direct exposure (e.g., P3). Image acquisition is rapid and multiplanar and three-

NOTES

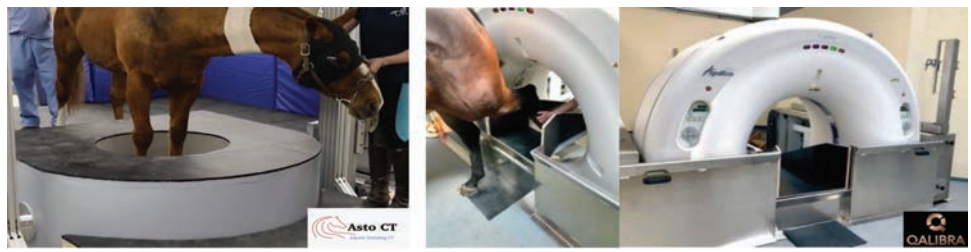

Fig. 1. Standing fan beam CT systems including Asto[a] CT (left) and Qalibra[b] (right).

Fig. 2. Standing cone beam CT systems including the Pegaso by Epica[d] (left) and Equimage[e] (right) that is a robotically controlled system.

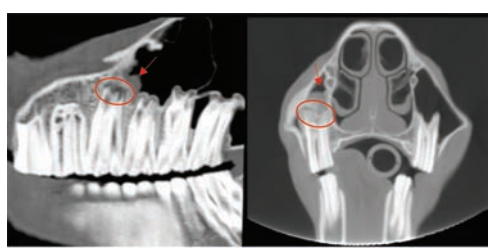

Fig. 3. Sagittal (left) and transverse (right) CT images of a horse with moderate to severe periodontal disease of distal 108 (circles) with adjacent sinus mucosal thickening (arrows) and early rostral maxillary sinus infection.

dimensional (3D) reconstructions can be generated to allow examination of the body part in multiple different planes (e.g., sagittal, transverse, dorsal or any oblique plane) or as a 3D image.

2. Diagnosis

Computed tomography has been used quite extensively to examine the head in horses presenting with signs of sinonasal disease and dental disease.[2] It is also very useful for evaluating the temporomandibular joints (TMJ), temporohyoid joints, and osseous bulla. The use of CT and CE-CT to diagnose intracranial disorders has been reported but MRI remains the superior imaging modality for these cases.[1] In terms of dental disease, CT can identify early pathologic changes in dentition such as widening of the pulp, gas accumulation, and periapical abscessation, all of which are impossible to diagnose on radiographs until the disease is advanced (Fig. 3). CT also provides detailed information about the paranasal sinuses and the infraorbital canal. The TMJs, hyoid apparatus, base of the skull, and osseous bulla are very challenging to adequately examine using plain radiography alone. CT greatly facilitates diagnosis of infectious (e.g., TMJ osteomyelitis, otitis), traumatic (e.g., petrous temporal bone fracture), and degenerative (e.g., temporohyoid osteoarthropathy (THO), TMJ osteoarthritis) disorders in this area.

Bony disorders of the equine foot including P3 fractures, navicular bone fractures, septic osteomyelitis of P3, and keratomas are easily diagnosed and characterized using CT. Soft tissue disorders, such as deep digital flexor tendinopathies and cartilage injury in the distal interphalangeal joint, can be investigated using intra-arterial (former) and intra-articular CE-CT (latter); however, MRI is likely the superior imaging modality.[3]

As predicted, CT has also become incredibly useful in the early diagnosis of stress-associated bone injury or subchondral bone injury in racehorses and sport horses.[4] Early changes in bone are difficult or even impossible to detect with plain radiography. The fetlock is the most common site of subchondral bone injury and CT is quickly becoming the gold standard for bone imaging of this joint. Due to the increased sensitivity and specificity of CT, there is potential to prevent more serious or even catastrophic injuries through early diagnosis (Fig. 4). CT can also be very helpful in diagnosing and characterizing traumatic, infectious, and degenerative disorders of the fetlock including condylar fractures, osteomyelitis, and osteoarthritis (OA). A study by Olive et al. found that CT consistently identified OA lesions including osteophytes, subchondral sclerosis, subchondral lysis,

Fig. 4. A, Flexed dorsopalmar (DP) and lateromedial (LM) radiograph of the right front fetlock of a horse with lameness localized to the fetlock. A definitive diagnosis could not be made based on the images obtained. B, Sagittal, transverse and dorsal plane CT images of the same fetlock clearly showing subchondral bone injury and a fissure in the medial condyle.

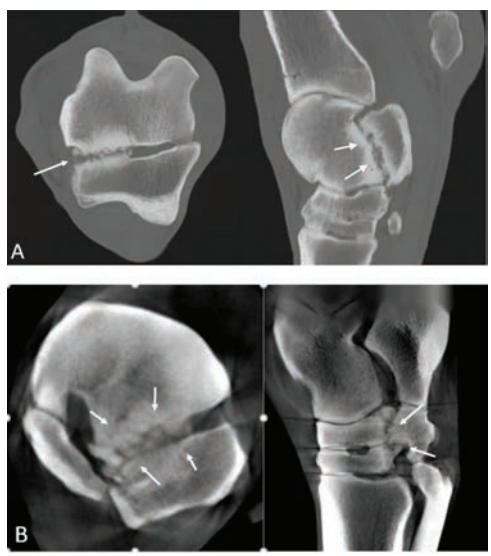

Fig. 5. A, Transverse and sagittal CT images of a horse with osteoarthritis of the talocalcaneal joint. In this horse, the medial facet (arrow) is more severely affected. B, Transverse and sagittal CT images of a horse with osteoarthritis of the plantar proximal intertarsal, distal intertarsal and tarsometatarsal joints. There is marked bone remodeling associated with the articulation of the 3rd tarsal bone and central tarsal bone with the 4th tarsal bone.

and subchondral bone cysts, better than plain radiography.[5]

The carpus and tarsus are both very amenable to CT imaging. Disorders such as occult osteoarthritis, subchondral bone injury, fractures, and proximal suspensory desmitis can all be diagnosed and characterized using CT. In the author's institution, CT has been particularly useful for evaluating horses with talocalcaneal and plantar distal tarsal osteoarthritis as these anatomic locations are difficult to adequately examine with plain radiographs due to superimposition (Fig. 5). Complex carpal fractures and tarsal slab fractures also lend themselves well to CT imaging. Although tarsal slab fractures are generally simple, they can be challenging to detect using radiography unless the perfect oblique projection is obtained. CT is also particularly useful for examining the enthesis of the proximal suspensory ligament, and CE-CT can be used to examine the proximal suspensory ligament itself (Fig. 6). CT can also be useful for evaluating horses with suspected caudal radial exostoses or osteochondromas.

The stifle can be a challenging area to image using CT because of the size and shape of the anatomic region. CT scanners with large gantries can be used to obtain images of the stifle, and CT arthrography has been shown to be useful in detecting joint pathology.[6] At this time, stifle CT can only be performed with the horse anesthetized.

Computed tomography imaging of the cervical spine, especially with standing systems that allow for easier image acquisition of the cervical spine up to the articulation of C7-T1, has been critical in expanding the understanding of cervical spine pathology and providing accurate diagnoses. Due to the complex anatomy, superimposition, and difficulty obtaining dorsoventral or ventrodorsal radiographs, the cervical spine can be challenging to evaluate using plain radiography. CT is incredibly useful for examining the paired articular process joints (APJ) for osteoarthritis, subchondral pathology, and osteochondritis dissecans (OCD) fragments. Intervertebral foraminal stenosis secondary to APJ osteoarthritis can be very difficult to identify on radiographs even when utilizing oblique projections to highlight the foramina; however, CT allows for examination of this area in multiple planes and easily facilitates a definitive diagnosis (Fig. 7). Traumatic and infectious disorders of the cervical spine can also be easily investigated with CT. Finally, CT myelograms can be used to determine spinal cord compression especially in horses with axial compression that can be difficult to detect during conventional myelography (Fig. 8).

Recently, some institutions have been investigating the use of positron emission tomography (PET) in the horse.[7] New Bolton Center, has been combining standing CT and standing PET to further examine areas of suspected bone injury. The co-registration of the images has been very useful for confirming clinically relevant bony lesions (Fig. 9).

3. Surgical Planning and Treatment

Preoperative CT can be invaluable for surgical planning. Surgeons preparing for surgeries involving anatomical locations with complex surgical anatomy, complex fractures, fractures that do not allow adequate fluoroscopic or radiographic projections, and bones with complete lack of direct exposure will always benefit from preoperative and, at times, intraoperative CT. Preoperative CT can be performed in the days leading up to surgery (an increasingly accessible option with the development of standing CT) or immediately prior to surgery once the patient is anesthetized (Fig. 10). Multiplanar reconstructions (MPR) allow for precise examination of bony anatomy, fracture configuration, and proposed drill and screw trajectories. Screw lengths can also be accurately measured using MPR images. This can be essential

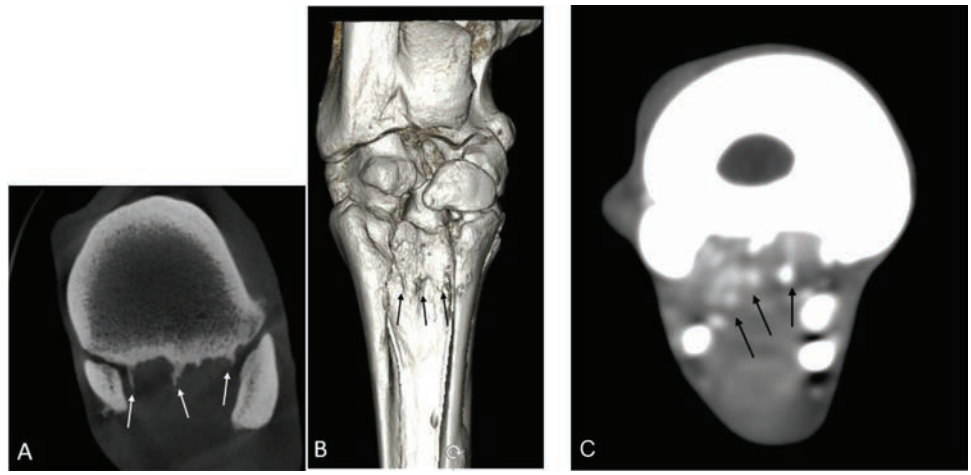

Fig. 6. A, Transverse CT image of the proximal metatarsus at the origin of the suspensory ligament. There is a marked enthesopathy with new bone formation (white arrows) and plantar cortical resorption at the origin of the suspensory ligament. B, 3D reconstruction showing enthesopathy with new bone formation and bony irregularity (black arrows). C, Proximal suspensory ligament desmopathy (arrows) noted on CE-CT of the metacarpus.

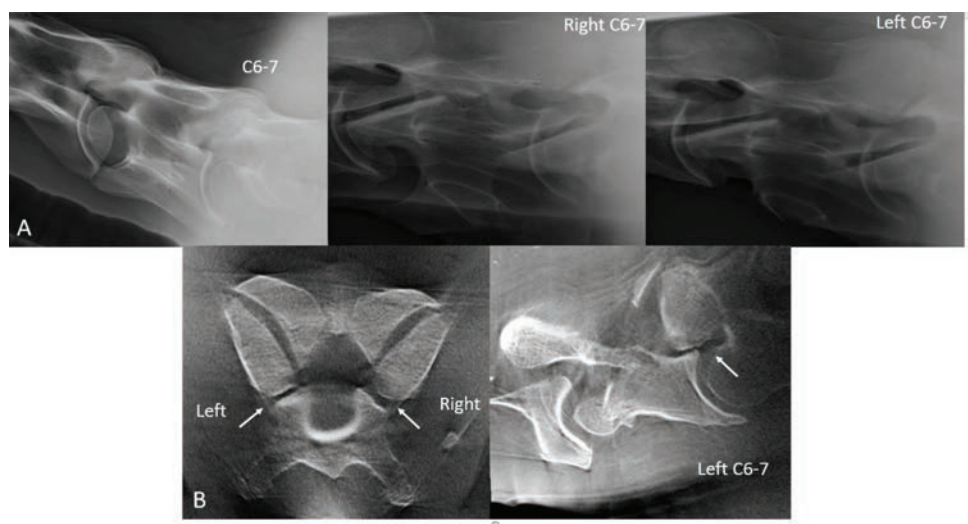

Fig. 7. A, Left to right lateral (left), right ventral-left dorsal (RV-LD) oblique (middle), and left ventral-right dorsal (LV-RD) oblique (right) radiographs of a horse suspected of having intervertebral foraminal stenosis due to periods of inability to raise his head and a hopping left front limb lameness that could not be blocked out. Osteoarthritis with enlargement of the articular process joint can be seen at C6-7. B, Transverse and sagittal CT images obtained from a standing CT scan show definitive evidence of foraminal stenosis at C6-7 (arrows). The left is more severely affected.

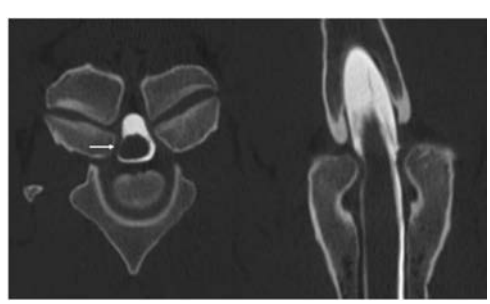

Fig. 8. Transverse (left) and dorsal (right) plane CT images of a horse with axial compression of the spinal cord at C2-3 (arrow) noted on standing myelogram CT.

when inserting screws through the hoof for the treatment of P3 or navicular bone fractures where the hoof prevents accurate measurement of the drilled hole. 3D reconstructions can be especially helpful when preparing for treatment of comminuted fractures; however, they should always be examined in conjunction with MPR images (Fig. 11).

As mentioned, complex and comminuted fractures lend themselves well to preoperative CT imaging. CT provides an in depth understanding of fracture planes and can be used to plan implant placement. This is particularly helpful in comminuted P1 and P2 fractures and complex carpal fractures. Preoperative CT is also very useful in horses with more simple

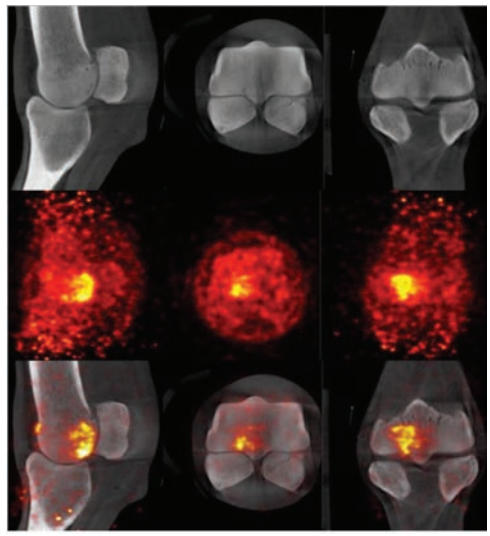

Fig. 9. Sagittal, transverse and dorsal plane images obtained using standing, robotic CT (top panel). The images show a small fissure in the lateral parasagittal groove. Sagittal, transverse and dorsal plane images obtained using standing PET (middle panel). Intense increased radioactivity is present in the lateral, plantar condyle. Sagittal, transverse and dorsal plane images produced following co-registration of CT and PET (bottom panel) which confirms that the lesion seen on CT is physiologically active.

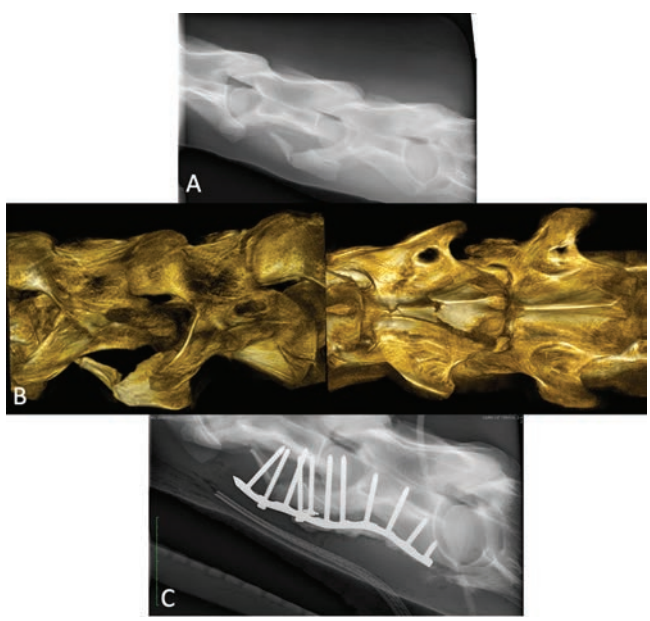

Fig. 10. A, Lateral radiograph of a horse that underwent a rotational fall. The radiograph shows a fracture of the ventral vertebral body of C4. B, 3D reconstructions of fracture viewed from the lateral (left) and ventral (right) aspect. The CT was performed standing the day before surgery to facilitate surgical planning. C, The fracture was repaired with a locking compression plate applied to the ventral surface of C4-5.

fractures that require careful and accurate screw placement in order to avoid complications. These include tarsal fractures in which radiographic or fluoroscopic projections can be misleading and

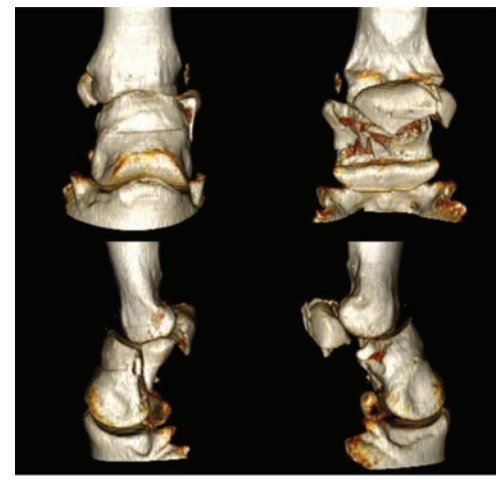

Fig. 11. A 3D reconstruction of a horse with a comminuted P2 fracture. A CT was performed immediately preoperatively to define the fracture configuration and guide the surgical approach.

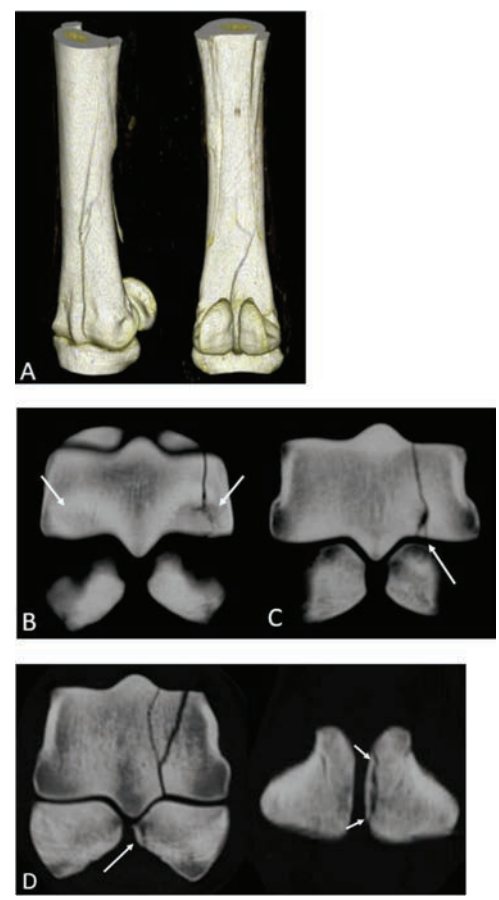

Fig. 12. A, 3D reconstructions of a horse with a propagating medial metatarsal fracture. The reconstruction shows the fracture configuration as it extends proximally from its origin at the parasagittal groove. B, Transverse CT image showing subchondral bone injury of the medial and lateral condyle (arrows) in a horse with a lateral condylar fracture. C, Transverse CT image showing palmar comminution (arrow) in a horse with a lateral condylar fracture. D, Transverse (left) and dorsal (right) CT images showing a concurrent axial sesamoid fracture (arrows) in a horse with a lateral condylar fracture.

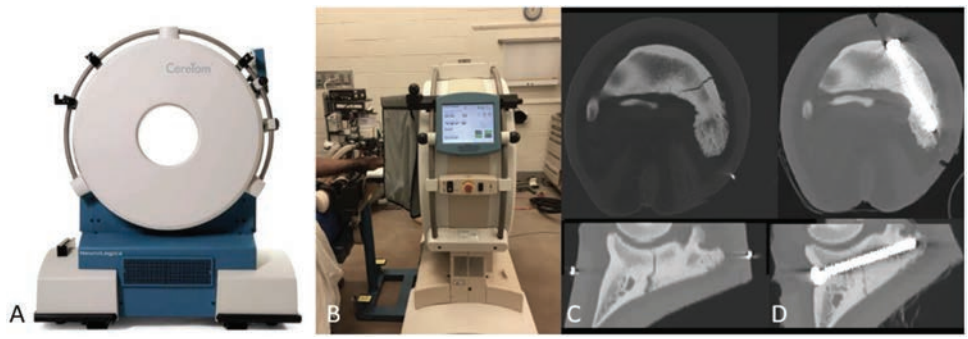

Fig. 13. A, Neurologica CereTom CT[f] with a mobile gantry that can be used for easy intraoperative imaging. B, The foot of a horse with a P3 fracture is having a CT performed following placement of radiopaque markers on the hoof that will guide screw placement through the hoof wall across the fracture. C, Transverse and parasagittal plane CT images showing the fracture line in the lateral wing of P3 and the radiopaque markers that will be used to guide screw placement. D, Transverse and parasagittal plane CT images showing appropriate screw placement across the fracture line. Reduction of the fracture line can be seen.

propagating condylar fractures in which the exact configuration of the fracture can be determined which ensures accurate screw and plate placement. Additionally, CT can be useful in the preoperative evaluation of all horses with condylar fractures as it helps to identify concurrent bony lesions including articular fragmentation, subchondral bone injury and proximal sesamoid bone trauma, which can affect the surgical approach and prognosis (Fig. 12).[8]

Radiopaque markers can be applied to the hoof or skin prior to the CT scan to determine the surgical approach (Fig. 13). This is particularly useful when the margin of error is minimal (e.g., navicular bone fracture). Placement of markers should be exact with repeat CT scans performed as needed until this is achieved. Intraoperative CT scans should be performed as needed to confirm the trajectory of drill holes and placement of implants.

4. Conclusion

Computed tomography is an invaluable, increasingly accessible tool for evaluating the equine skeleton. It has proved essential in the diagnosis of certain disorders and surgical treatment of fractures involving the foot. CT also facilitates more accurate surgical planning and approaches that can ultimately lead to better patient outcomes.

Acknowledgments

Declaration of Ethics

The Author has adhered to the Principles of Veterinary Medical Ethics of the AVMA.

Conflict of Interest

The Author has no conflicts of interest.

References and Footnotes

1. Puchalski SM. Advances in equine computed tomography and use of contrast media. *Vet Clin North Am Equine Pract* 2012;28:563–581.
2. Morrow KL, Park RD, Spurgeon TL, et al. Computed tomographic imaging of the equine head. *Vet Radiol Ultrasound* 2000;41:491–497.
3. Vallance SA, Bell RJW, Spriet M, et al. Comparisons of computed tomography, contrast-enhanced computed tomography and standing low-field magnetic resonance imaging in horses with lameness localised to the foot. Part 2: Lesion identification. *Equine Vet J* 2012;44:149–156.
4. van Weeren PR, Firth EC. Future tools for early diagnosis and monitoring of musculoskeletal injury: Biomarkers and CT. *Vet Clin North Am Equine Pract* 2008;24:153–175.
5. Olive J, d'Anjou M-A, Alexander K, et al. Correlation of signal attenuation-based quantitative magnetic resonance imaging with quantitative computed tomographic measurements of subchondral bone mineral density in metacarpophalangeal joints of horses. *Am J Vet Res* 2010;71:412–420.
6. Nelson BB, Kawcak CE, Goodrich LR, et al. Comparison between computed tomographic arthrography, radiography, ultrasonography, and arthroscopy for the diagnosis of femorotibial joint disease in western performance horses. *Vet Radiol Ultrasound* 2016;57:387–402.
7. Spriet M, Espinosa-Mur P, Cissell DD, et al. 18 F-sodium fluoride positron emission tomography of the racing Thoroughbred fetlock: Validation and comparison with other imaging modalities in nine horses. *Equine Vet J* 2019;51:375–383.
8. Cianci JM, Wulster KB, Richardson DW, et al. Computed tomographic assessment of fracture characteristics and subchondral bone injury in Thoroughbred racehorses with lateral condylar fractures and their relationship to outcome. *Vet Surg* 2022

[a]Asto CT™, Asto CT Inc., Middleton, WI 53562.
[b]Qalibra CT, Qalibra, Berlin, Germany.
[c]NeuroLogica BodyTom®, NeuroLogica, Danvers, MA 01923.
[d]Pegaso, Epica International, Duncan SC 29334.
[e]Equimage, EDAMIS, Orimtech, Buffalo Grove, IL 60089.
[f]NeuroLogica CereTom®, NeuroLogica, Danvers, MA 01923.

Emergency Triage of the Equine Neonate

Tiffany L. Hall, DVM, DACVIM, DACVECC

Author's address: Equine Medical Center of Ocala, 7107 W Hwy 326 Ocala, FL 34482; e-mail: thall@emcocala.com. © 2022 AAEP.

1. Introduction

Emergency stabilization of the critical, weak, or recumbent neonate may focus on identification and treatment of common clinical conditions independent of the primary diagnosis. Recognition of the presence of these conditions and selection of appropriate interventions allows for a focused approach to emergency evaluation and stabilization in the field, as well as upon intake to a tertiary facility. The team may then regroup to identify and address the primary diagnosis following emergency stabilization.

The following is a summary of the collective wisdom of equine neonatologists; various personal mentors over the last 22 years; and the author's personal clinical experience as a field and hospital criticalist. The goal of this session is to arm the new practitioner with the confidence to stabilize and evaluate the critical equine neonate in the field. For further reading, please refer to the list of additional references at the end of this summary.

2. Hypoperfusion

Hypoperfusion is defined as inadequate blood flow through organs and tissues to supply the necessary oxygen and nutrients for normal function.[1] Hypoperfusion occurs in neonates due to decreased circulating blood/plasma volume, decreased myocardial contractility, vasodilation, and/or coagulopathy. Hypoperfusion is frequently observed in foals that have not nursed in 4 hours, have increased fluid loss (diarrhea), or are septicemic.

Foals suffering from hypoperfusion are commonly identified based on history and evaluation of perfusion parameters. Perfusion parameters in the neonatal foal include jugular fill, extremity temperature, pulse quality, mucous membrane color, capillary refill time, mentation, urine production, blood pressure, and lactate concentration. Heart rate is not as reliable an indicator in foals as it is in adults. Serial monitoring of the perfusion parameters is used to guide therapy. Foals that have appropriate perfusion should have warm extremities, have strong peripheral pulse quality, have pink mucous membranes with a capillary refill time (CRT) of less than 2 seconds, demonstrate responsive mentation, and produce frequent, hyposthenuric urine (considered clinical perfusion parameters). Peripheral lactate concentrations should decrease by approximately 50% within the first 4 hours of therapy. There will be exceptions to these rules based on underlying diagnosis, such as persistently altered mentation in neonatal maladjustment syndrome (NMS).

Correction of hypoperfusion is a 3-step process. Circulating blood volume should be restored prior to administration of inotropes or vasopressors. In the author's practice, hypovolemia is corrected through the administration of 10 to 20 mL/kg bolus of balanced crystalloid solutions (Lactated Ringer's solution, NormR, or PlasmaLyte A) up to a maximum total of 60 mL/kg. In practice, this equates to 1 L for a 50-kg foal administered over 15 to 20 minutes in a case of severe shock or 30 to 60 minutes in less critical situations. Perfusion parameters are monitored, and foals that need more than 2 boluses often require

NOTES

myocardial or vasomotor support as well. Limits are best monitored in the hospital via ultrasonographic assessment of cardiac output and indirect arterial and central venous blood pressure determination to avoid overhydration. If perfusion remains poor following restoration of circulating blood volume or maximal resuscitation, administration of dobutamine and/or norepinephrine is indicated.

3. Hypoglycemia

Neonatal foals are predisposed to rapid development of hypoglycemia when not nursing adequately. Foals are born with minimal glycogen stores in the liver, muscle, or brain, and glucose levels drop significantly during the initial 2 hours of extrauterine life. Normal glucose concentrations are 80 to 160 mg/dL with lethargy, weakness, and seizure activity observed with increasing severity of hypoglycemia. Any condition that results in decreased nutritional intake can lead to hypoglycemia in the equine neonate, including an inability to rise due to musculoskeletal disorders, colic, sepsis, and/or NMS. In addition, hereditary disorders of glucose metabolism and conditions such as septicemia or prematurity may result in increased energy demands.

Glucose concentrations may be readily evaluated in the field using a handheld glucometer. Human glucometers have been shown to be reliable, although glucose concentrations may be underestimated when performed on whole blood. Glucometers are especially beneficial for serial monitoring of trends in glucose concentrations during therapy and hospitalization. iSTAT[a] also sells cartridges for glucose determination, including the CHEM8.

Dextrose supplementation of the critical neonate in the field should be judicious in the absence of a method for determining glucose concentrations. Hyperglycemia has repeatedly been demonstrated to have detrimental effects in human critical care studies[1] with strict glucose control between a range of 80 to 110 mg/dL resulting in improved outcomes. Therefore, bolus administration of 5% dextrose containing fluids is no longer considered ideal among equine neonatologists. Full-term neonates have a glucose energy requirement equal to 4 mg/kg/minute dextrose. Therefore, initial fluids should consist of a 1% dextrose solution in balanced crystalloid fluid (20 mL 50% dextrose/1 L) are recommended when glucose concentration is unknown. A 1% solution supplies twice maintenance energy requirements (8mg/kg/min) for a 50kg foal when administered over a period of 30 minutes. This will allow for correction of mild hypoglycemia without significant risk of iatrogenic hyperglycemia. When determination of glucose concentrations is available stall-side and is <50mg/dL, administration of a 2% dextrose solution (40mL 50% dextrose/1L) may be considered to correct the deficit. Alternatively, if the foal's temperature is above 98°F, enteral feeding is preferred. In the author's experience, a single administration of 250–500mL of mare's milk via nasogastric intubation is reasonable; however, if the foal does not turn around quickly, additional nutritional planning will be necessary.

4. Hypothermia

Neonates are prone to hypothermia (body temperature < 98°F) due to increased thermal loss via evaporation, conduction, radiation, and convection. The critical ambient temperature for a normal healthy foal is 77°F with sufficient heat production in temperatures below 37°F.[2] Ill and premature neonates, however, are less capable of appropriate thermoregulation associated with lower metabolic rates per surface area and decreased heat production. Hypothermia can result in a shock-like state with progressive decline in cellular and organ function.

However, hypothermia can be beneficial, as has been demonstrated in human CPR and hypoxic-ischemic encephalopathy. Hypothermia is associated with reduced metabolism, decreased inflammation, and prevention of ischemic-reperfusion injury; therefore, permissive hypothermia is currently recommended over aggressive warming. Increasing body temperature by no more than 1°F per hour with a body temperature goal of 98°F to 99°F is currently recommended. Rapid warming should occur when bradycardia (<60 beats per minute), dysrhythmias, or temperature <96°F is present.

Methods of warming include moving a foal into a warmer environment, moving it away from drafts, and applying a fleece or down cover. Bair[b] huggers or heat lamps are also beneficial, but caution should be taken to not overheat the foal. Electric heating blankets or pads should not be used to avoid burns and excessive peripheral vasodilation.

5. Hypoxemia

Causes of hypoxemia include decreased inspired oxygen concentration, diffusion impairment, hypoventilation, V/Q mismatch, and right to left shunting of blood. The most common causes of hypoxemia in the equine neonate are associated with hypoventilation and V/Q mismatch due to prematurity, NMS, septicemia, pneumonia, atelectasis of recumbency, or acute respiratory distress syndrome (ARDS).

Assessment of respiratory function and oxygen status requires the use of a pulse oximeter and/or blood gas analyzer, such as an iSTAT CG4 cartridge. Normal oxygen values are lower in the first 24 hours compared to adults and greatly influenced by prematurity, age, and position.

Recumbency can reduce oxygen concentrations by up to 40 mmHg with normal lung function. Adequate oxygenation is indicated by SpO_2 95% and $PaO_2 > 70$ mmHg. Evaluation of arterial gases in conjunction with venous blood gas will provide improved assessment of global oxygen status, particularly in foals with neonatal isoerythrolysis.

Provision of oxygen supplementation via intranasal insufflation is often the first step in neonatal

stabilization in an equine neonatal intensive care unit and may be administered within seconds of arrival. Humidified oxygen is supplied via small bore flexible tubing at rates of 2 to 10 L/minute with most critical and recumbent foals requiring 3 to 5 L/minute. Caution should be taken to avoid oxygen toxicity by reducing flow rates if $PaO_2 > 120$ mmHg. Comparison of arterial blood gas on room air versus oxygen insufflation allows for assessment of maturity and degree of shunting. Foals that do not respond to nasal insufflation in the absence of congenital cardiac anomalies may require positive pressure ventilation on 100% oxygen. In addition to supplementation of oxygen, lung function is improved by maintaining sternal recumbency over parasternal or lateral recumbency through the use of pillows, wedges, sandbags, or bales of hay.

6. Hypoventilation

Hypoventilation is defined as $PaCO_2 > 55$ to 60 mmHg resulting in respiratory acidosis, associated metabolic responses, cerebral vasodilation, and increased intracranial pressure. The most common causes of hypoventilation in the neonate include NMS, prematurity, sepsis, and severe respiratory disease (e.g., NERDS/NARDS). Permissive hypercapnia is allowed as long as mentation is appropriate and blood pH > 7.25. Assessment of ventilatory status requires arterial blood gas analysis, although poor mentation in the face of normalized cardiovascular function with an altered respiratory pattern and history consistent with prematurity or NMS may be suggestive.

Therapeutic intervention depends upon the underlying cause of hypercapnia—whether neurogenic, obstructive, or pulmonary in origin. Foals with neurogenic causes of hypoventilation, such as NMS or sepsis, benefit from chemical ventilation via stimulation of the respiratory centers of the brain. Administration of doxapram or caffeine stimulates respiratory drive; however, doxapram has been shown to be more effective in foals in both experimentally induced and clinical hypercapnia. Obstructive disorders resulting in hypercapnia are best treated by addressing the primary problem, such as upper respiratory obstruction, pleural disease, and pneumothorax. Foals that develop hypercapnia associated with neuromuscular or respiratory muscle fatigue and those in respiratory failure, including foals with botulism, ARDS, or prematurity, require positive pressure ventilation.

7. Hypobase

Three types of acidosis may be observed in critical neonates, including respiratory acidosis and organic (lactic) acidosis, which have already been discussed. In addition, inorganic acidosis associated with hyponatremia and hyperchloremia may be present and is treated through gradual correction of electrolyte concentrations and management of the underlying cause.

8. Hypoimmunity

Foals are highly susceptible to infection and require passive transfer of immunity via absorption of maternal antibodies in colostrum shortly after birth. Premature lactation, incomplete vaccination, poor immune status of the mare, or any illness of the foal that prevents proper colostral ingestion may prevent successful passive transfer and increase the risk of sepsis. Therefore, any critically ill neonate should be assessed as to the need for intravenous plasma and/or antimicrobial administration.

9. Conclusion

The status of critical neonates changes rapidly, and successful outcomes often require frequent fine-tuning of multimodal therapies under the observation of a team of skilled professionals. Awareness of the 7 hypos and knowledge of how to address each can provide guidance for emergency stabilization in the field, as well as upon admission to tertiary care facilities. Basic therapies recommended by the author and easily administered in the field prior to referral that may improve overall outcomes include 1. restoration of circulating fluid volume not to exceed 40 mL/kg IV fluid total, 2. provision of maintenance nutritional needs via 1% dextrose solutions or enterally administered mare's milk, 3. supporting body temperature via application of a lightweight blanket, 4. improved ventilatory status through single administration of caffeine at 10 mg/kg enterally, and 5. a single administration of broad-spectrum antimicrobials.

Acknowledgments

Declaration of Ethics

The Author has adhered to the Principles of Veterinary Medical Ethics of the AVMA.

Conflict of Interest

The Author has no conflicts of interest.

References and Footnotes

1. Corley KT, Axon JE. Resuscitation and emergency management for neonatal foals. *Vet Clin N Amer* 2005;21:431–455.
2. Madigan JE. *Manual of equine neonatal medicine, 4th ed*. Live Oak Publishing, 2013.
3. Fielding CL, Magdesian KG. Equine Fluid Therapy. 1st edition. Wiley Blackwell, 2015.
4. Southwood LL, Wilkins PA. Equine Emergency and Critical Care Medicine. 1st edition. CRC Press, 2015.
5. Stoneham SJ, Morresey P, Ousey J. Nutritional management and practical feeding of the orphan foal. *Equine Vet Educ* 2016;29(3):165–173.

[a]iSTAT, Abbott Point of Care Inc., Princeton, NJ 08540.
[b]Bair, 3M, Maplewood, MN 55144.

Dentistry Examination in the Adult Horse

Nicola Pusterla, DVM, PhD, DACVIM, DAVDC-Equine

Author's address: Department of Medicine and Epidemiology, School of Veterinary Medicine, University of California-Davis, Davis, CA 95616; email: npusterla@ucdavis.edu. © 2022 AAEP.

1. Introduction

Because many advances have been made in equine health, horses today live well into their 20s and 30s, making it even more important to provide their teeth with regular preventive care. Small problems that are recognized and corrected at an early age seldom become the large problems seen in many of today's adult horses. Current research is showing that equine teeth that function normally and have a normal grinding pattern actually wear more slowly and therefore last longer. This means that the better a horse's teeth are maintained, the longer its teeth will remain effective at grinding long-stemmed forage, the staple of the equine diet.

Because not all dental problems in horses are obvious to the untrained eye or are revealed through clinical signs, it is important to have regular, comprehensive dental examinations conducted by a veterinarian.[1,2] Due to the stoic nature of horses, obvious outward signs of dental disease are often not present until the condition is very advanced. Modern equine dentistry requires a physical exam of the entire patient, sedation, and specialized instrumentation to perform the oral examination. Advances in dentistry have brought forth new ways to approach pathological conditions in the horse's mouth. Veterinarians well trained in equine dentistry have the skills to prevent most major dental problems that previously have been accepted as an inevitable part of aging.

2. History and Physical Assessment

Horses with dental disorders can show no clinical signs or a variety of often unspecific clinical signs such as partial to complete anorexia, salivation, quidding, weight loss, large undigested feed particles in feces, head tilting or tossing on the bridle, refusing to take a lead, foul odor from mouth, nasal discharge, or swelling of face, jaw, or mouth tissues. Before undertaking an oral evaluation, one needs to first assess what the horse is fed and how the horse is eating (offer long-stem roughage and processed feed). It is also important to determine when an oral examination was last done and what the noticed pathologies were. A complete physical examination is indispensable in order to assess the overall health status of the horse and determine if the patient is suitable to be sedated.

3. Sedation

Proper and judicious sedation is a key element in the comprehensive oral examination and also in the delivery of any dental treatment. Always perform a physical evaluation before sedating a horse. Do not sedate any horse with systemic signs such as fever, tachycardia, arrhythmia, or tachypnea without first determining the cause of such signs. Several sedation protocols are used for dentistry; however, only a few have been clinically evaluated on a large scale. In general, horses are sedated with an alpha-2 agonist alone or in combination with a synthetic opioid.[3,4] Sedation should be based on temperament, breed, age, and weight. Refractory horses should be first sedated intramuscularly 30 to 40 minutes prior to the examination to improve patient's compliance.

NOTES

The use of reversals is generally not recommended but can be done in case the horse becomes hypotensive, recumbent, or distressed. The use of tolazoline (4 mg/kg IV slowly) or yohimbine (0.075 mg/kg) is not without serious risk of idiosyncratic (anxiety, respiratory distress, cardiovascular compromise due to vasodilation and airway constriction) and potentially fatal consequences as evidenced by clinical reports of drug reactions and possible death following their administration.[5] Because of the reported fatalities, it is recommended to use tolazoline intramuscularly only and to give it in increments of 1/3 of the calculated full dose.

4. Equipment

In order to perform a comprehensive oral examination, appropriate equipment is needed. A variety of dental equipment is available to facilitate the oral examination:

- Full mouth speculum
- Head stand or head support
- Illumination
- Diagnostic equipment (mirror, explorer, periodontal probe, forceps, scaler)
- Dose syringe, bucket, brush, and chlorhexidine gluconate
- Camera

5. The Oral Examination

The oral examination encompasses a comprehensive assessment of the equine dentition and the supporting structures associated with the teeth. There are five components to the oral examination: external oral examination, oral soft tissue exam, occlusion, and endodontic and periodontal status. It is very important to record all findings of the oral examination using a charting system.

The external oral examination of the head focuses on any bony swellings (Fig. 1), draining tract (Fig. 2), mandibular lymph node, muscular uniformity (asymmetry, atrophy, hypertrophy), anatomical and developmental changes, ocular or nasal discharge (Fig. 3), smell, and airflow through nasal passages. Visual assessment and palpation are essential in order to determine any possible asymmetry. Any mandibular callus, crepitus, draining tract, or pain on palpation may require mandibular radiographs to be obtained prior to placing a full mouth speculum so as not to exacerbate a possible underlying pathological process (fracture).

The oral soft tissues include gingiva, mucosa, tongue, and hard/soft palate. The gingiva should be tight in approximation of the tooth and light pink in color. Loss or recession of the gingiva and an increased redness indicate gingivitis. The mucosa of the lips, cheeks, and lingual surface, as well as the tongue and hard/soft palate, should be light pink in color and devoid of abrasions/ulcerations. Abrasions that are commonly noted are due mostly to sharp enamel points formed during chewing as well as following bit injuries (Figs. 4 and 5). Examination of these tissues will allow early detection of periodontal disease and oral neoplasia (Fig. 6).

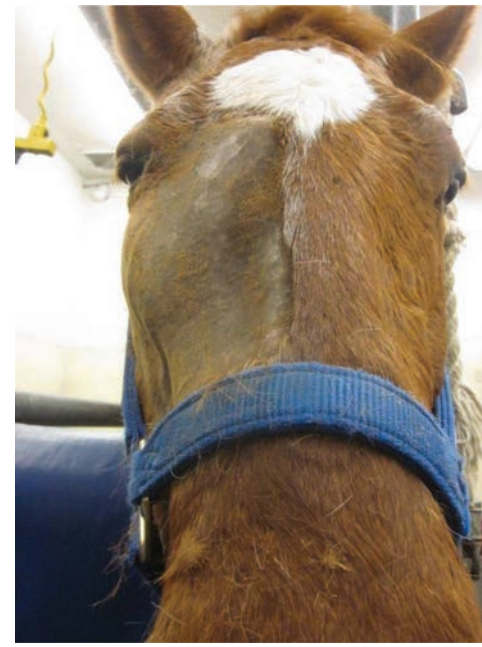

Fig. 1. Adult horse with bony swelling over the right maxillary sinus.

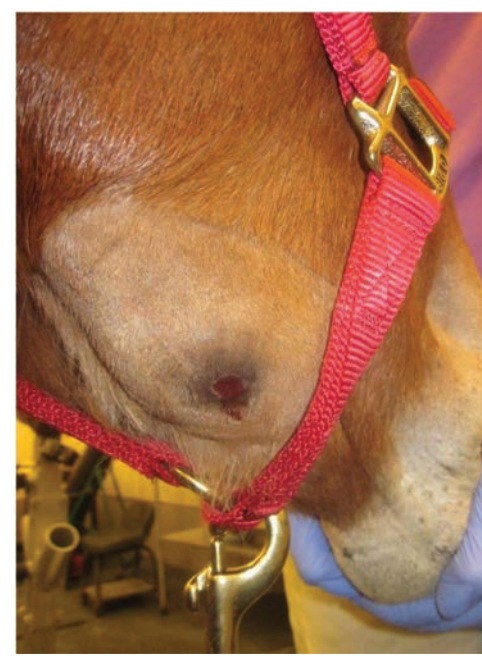

Fig. 2. Draining tract associated with the right mandible.

Occlusion refers to the grinding function of the teeth when the jaws are brought together. This is best observed during the external oral examination and reevaluated during the internal examination. This would include the identification of incisor (Fig. 7) and cheek teeth malocclusion (Fig. 8) and evaluation of

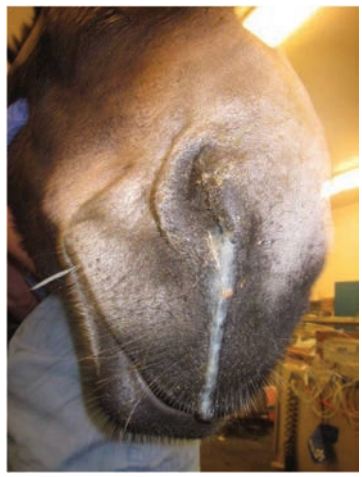

Fig. 3. Mucopurulent right-sided nasal discharge.

Fig. 5. Abrasions along the tongue secondary to sharp enamel points.

Fig. 4. Abrasions along the right buccal maxillary mucosa secondary to sharp enamel points.

Fig. 6. Soft tissue mass along the cranial lingual aspect of the right mandible (fibrosarcoma).

movement and range of motion. Missing teeth or the presence of supernumerary teeth should be noted as well as any associated overgrowth that might affect the occlusion. The table angle of the cheek teeth and the level of staining should also be noted. An increase in color staining indicates lack of occlusion, attrition, or chewing resulting in the buildup of tannic acid staining from food material. An increased table angle on one side of the mouth indicates a lack of attrition or a functional inability to use these quadrants.

The endodontic status evaluates the integrity of clinical crown (Fig. 9), occlusal dentin of the pulp horns/pulp chambers, and any decay (cemental or infundibular). Cheek teeth comprise 5 to 7 pulp horns that have live pulp extending from the apical aspect of the common pulp chamber toward the occlusal surface. The function of the pulp is to produce primary, secondary, and tertiary dentin. Primary dentin is present in the pulp horns when the teeth enter the mouth. Secondary and tertiary dentin are produced while the teeth are being worn away. Without the ability to efficiently produce dentin, the pulp would become exposed over time and result in pulpitis. The chewing surface of every tooth should be closely examined to identify any decay of the dentin in the pulp horns (often presence of feed material packed on the surface of the subocclusal secondary dentin, Fig. 10).

The periodontal status is examined by noting anywhere in the mouth where food is caught and stagnating. Periodontal disease in the horse often begins with food packing in the interproximal space, leading to rotting feed, acid production, and bacterial overgrowth, which contribute to inflammation of the periodontal structures (Fig. 11). Initially, the gingiva becomes inflamed (red and

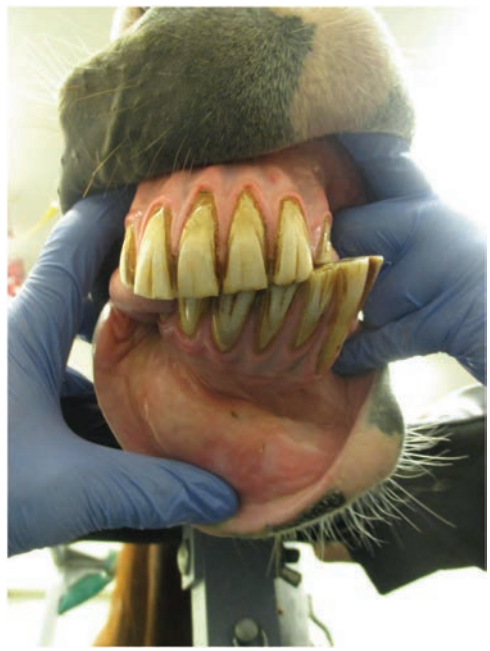

Fig. 7. Incisor malocclusion (slant).

Fig. 8. Malocclusion with rostral (106/206) and caudal hooks (311/411).

swollen). If the condition is not remediated, deeper structures such as bone and periodontal ligament become affected. This process leads to irreversible resorption of the interproximal bone and periodontal ligament. This process is painful for the horse and often causes quidding. The severity of a periodontal disease is best determined using probing depth and dental radiographs.

6. Conclusion

In summary, the equine oral examination is a comprehensive specialty exam that should be carried out in a systematic fashion. The findings of the oral examination should be recorded on a dental chart and kept with the patient's record. Dental records are important medical information that may help establish a dental care plan for the individual horse. Further, it will document past dental findings and procedures in case a different veterinarian becomes the primary

Fig. 9. Cheek tooth with loss of integrity (complicated crown root fracture of the 107).

Fig. 10. Open pulp horn number 2 on the 209 with feed packing (see tip of the explorer instrument). Feed is also present in the mesial and distal infundibulum.

Fig. 11. Periodontal disease with feed packing between 309 and 310 leading to gingivitis.

care provider. When any type of disease is noted, imaging of the reserve crown and roots should be done to evaluate the extent and severity of the condition.

Acknowledgments

Declaration of Ethics

The Author has adhered to the Principles of Veterinary Medical Ethics of the AVMA.

Conflict of Interest

The Author has no conflicts of interest.

References

1. Easley J. Dental care and instrumentation. *Vet Clin North Am Equine Pract* 1998;14:309–332.
2. Menzies R. Oral examination and charting: setting the basis for evidence-based medicine in the oral examination of equids. *Vet Clin North Am Equine Pract* 2013;29:325–343.
3. Kamerling SG, Cravens WM, Bagwell CA. Objective assessment of detomidine-induced analgesia and sedation in the horse. *Eur J Pharmacol* 1988;151:1–8.
4. Taylor PM, Browning AP, Harris CP. Detomidine-butorphanol sedation in equine clinical practice. *Vet Rec* 1988; 123:388–390.
5. Scofield DB, Alexander DL, Franklin RP, et al. Review of fatalities and adverse reactions after administration of α-2 adrenergic agonist reversal agents in the horse, in *Proceedings*. Am Assoc Equine Pract 2010;56:44–49.

Ophthalmic Examination in the Horse

Stephanie C. Bell, DVM, DACVO

Author's address: Hagyard Equine Medical Institute, 4250 Iron Works Pike, Lexington, KY 40511; e-mail: sbell@hagyard.com. © 2022 AAEP.

1. Introduction

A thorough ophthalmic examination should be performed if a horse is exhibiting signs of an ocular complaint (blepharospasm, ocular discharge, blepharedema, redness, vision changes, cloudy eye, etc.). An ophthalmic exam is also a key component of the prepurchase examination.[1] As many systemic diseases have ocular manifestations of systemic disease, it is recommended to perform an ophthalmic exam in any sick horse. Performing routine ophthalmic exams in a consistent manner will allow the practitioner to become confident and capable in diagnosing and treating ocular disorders. This talk and associated paper will focus on performing and interpreting ophthalmic examination in the horse.

2. Ophthalmic Examination

The ophthalmic examination should be performed in a systematic manner.[2] It is helpful to perform the exam in the same order each time to avoid missing an essential part. Ideally, a medical history of the horse should be available to the examining veterinarian to correlate any clinical findings with medical events or accidents (e.g., corneal scar responding to history or corneal ulcer and treatment).[1] Reason for the exam should be documented, along with a description of clinical signs, duration, previous/current treatment, and response to therapy. Prior and existing medical therapy is important to know. For example, topical atropine may result in mydriasis for up to 14 days in horses.[2,3]

The veterinarian should have the following equipment and supplies[2]:

- Focal bright light source, such as a penlight or Finoff transilluminator
- Magnification is often helpful, such as an Optivisor
- Indirect fundoscopic lens (e.g., 20-D or 2.2 Panretinal lens) or PanOptic ophthalmoscope
- Direct ophthalmoscope (especially useful for slit-beam setting)
- Schirmer Tear Test strips
- Topical corneal anesthetic (proparacaine or tetracaine)
- Sterile fluorescein dye strips
- Local nerve block agents (e.g., lidocaine, bupivacaine)
- Sedatives
- Short-acting dilating agent (tropicamide HCl 1%)
- Sterile culture swabs (cytology and culture)
- Glass slides (cytology)
- Cytology brushes, or #10 and #15 blades (cytology)
- ± Tonometer
- 1- and 3-mL syringes; 18- and 25-gauge needles
- Equipment for nasolacrimal duct flush (tomcat or other small animal urinary catheter, saline, betadine solution)
- Eyewash/saline for ocular flushing

The initial part of the ophthalmic exam should include observation of the horse in its surroundings in

NOTES

a well-lit area. The horse should be observed for response to movement and people or other animals approaching.[4] A step-by-step approach as outlined below will ensure all components of the exam are complete.[5] There are a variety of ophthalmic examination sheets that may be helpful to guide the examination and enable drawing of pictures to document lesions and evaluate progress over time (Fig. 1).[6]

Initial evaluation of symmetry, globe position, eyelash orientation, and cranial nerve evaluation (CN II, III, IV, V, VI, VII) should be performed prior to administering sedation as long as this is safe for the handler, examiner, and horse.[2,7] Safety of all involved is of utmost importance and overrides the need for any examination component. Thus, sedation should be administered initially if needed.

Environment

The initial components of the exam, including vision testing, evaluation of symmetry, nerve blocks, and adnexal examination, should be performed in a well-lit area with minimal noise and distractions if possible.[2] To adequately examine the cornea, anterior segment, and deeper structures of the eye, an area that can be darkened is ideal to maximize lesion identification.[2,6]

Symmetry

The examiner should assess the horse for facial, orbital, and globe symmetry. This may be best evaluated with the veterinarian standing in front of the horse at a distance to assess globe position, size, and ocular discomfort. In particular, the relative angulation of the upper eyelashes should be assessed. Lowering of the angle of the upper eyelashes is a subtle indicator of ocular discomfort in the absence of overt blepharospasm or epiphora.[7] Observe the face closely for signs of present or past tearing or other ocular discharge.

Palpation of both orbits should be performed. Retropulsion of both globes is performed by pushing the globe back into the orbit through closed eyelids.[5,6]

**Note: retropulsion should never be performed in a fragile globe with a corneal defect. It should be bilaterally symmetrical and nonpainful. Retropulsion is also used to extrude the third eyelid and allow for close examination of this structure[2,5,6] (see Adnexal section).

Vision and Ocular Reflexes

The veterinarian should note how the horse reacts to its surroundings.[1] With vision loss, especially chronic, horses may adapt and continue to perform. Thus, it is important to test ocular reflexes, including menace response, dazzle reflex, and pupillary light reflexes. In some cases, a maze test may be performed by covering one eye and having the horse navigate through obstacles.

The menace response tests cranial nerves II (optic) and VII (facial) and requires an intact visual and motor cortex. This is a learned cortical response in which a "menacing gesture" is performed with the observer's hand and the horse sees this and reacts by blinking or with an avoidance movement of the head.[2,8] Care should be taken to avoid stimulation of aural and tactile senses (air movement or inadvertently touching vibrissae). The menace response should be evaluated throughout the horse's visual field in all quadrants (i.e., hand motions from cranial, perpendicular, and caudal to the eye). The horse's total visual field extends almost 360° (146° of uniocular vision with 65° of binocular vision anteriorly), with a small blind spot posteriorly.[1]

The dazzle reflex also tests cranial nerves II (optic) and VII (facial) and the retina. This is a subcortical reflex and does not require cortical processing. The horse should blink when a focal bright light source is shone into the eye.[2]

It is important to ensure the palpebral reflex is intact and the horse is able to blink completely in order to adequately evaluate the menace response and dazzle reflex. The palpebral reflex tests cranial nerves V (trigeminal) and VII (facial).[2,6] The periocular area is touched, which stimulates the sensory portion of the trigeminal nerve and results in blinking via the facial nerve.

Pupillary Light Reflexes (PLRs)

Pupil size and symmetry should be evaluated using the focal light source.[2] The light should then be used to assess the pupillary light reflex in each eye. Light shone into one eye should cause both pupils to constrict (direct and consensual PLRs). The PLR tests cranial nerves II (optic) and III (oculomotor).[2,6]

**Following the initial assessment as outlined above, the veterinarian may now administer sedation and regional nerve blocks as indicated.

Regional Nerve Blocks

The most common nerve block used in the equine ocular examination is the auriculopalpebral nerve block, which targets the palpebral branch of the facial nerve (CN VII).[2,6] The examiner injects 1 to 2 mL of lidocaine (or other local anesthetic) subcutaneously over the zygomatic arch using a 25-gauge 5/8-inch needle. This blocks motor function to the orbicularis oculi muscle for ~1 to 2 hours and facilitates ocular examination. This is especially important in a fragile globe with a deep corneal ulcer or laceration as it reduces the pressure necessary to open the eyelids.[2,6]

Another common nerve block is the frontal nerve block, which targets the supraorbital branch of the trigeminal nerve (CN V).[2] This branch provides sensory innervation to most of the central upper eyelid. It is most easily blocked as it emerges from the supraorbital foramen within the frontal bone.

Topical corneal anesthetic such as proparacaine or tetracaine (~0.2 mL) may be instilled to provide corneal analgesia and facilitate ophthalmic examination and corneal sampling when indicated.[4] Short-term tissue desensitization (up to ~20 minutes) is achieved by applying the anesthetic ophthalmic solution onto the target surface. This may be accomplished using the broken-off hub of a 25-gauge needle attached to a small (1 or 3 mL) syringe as a spray device.[4] It is

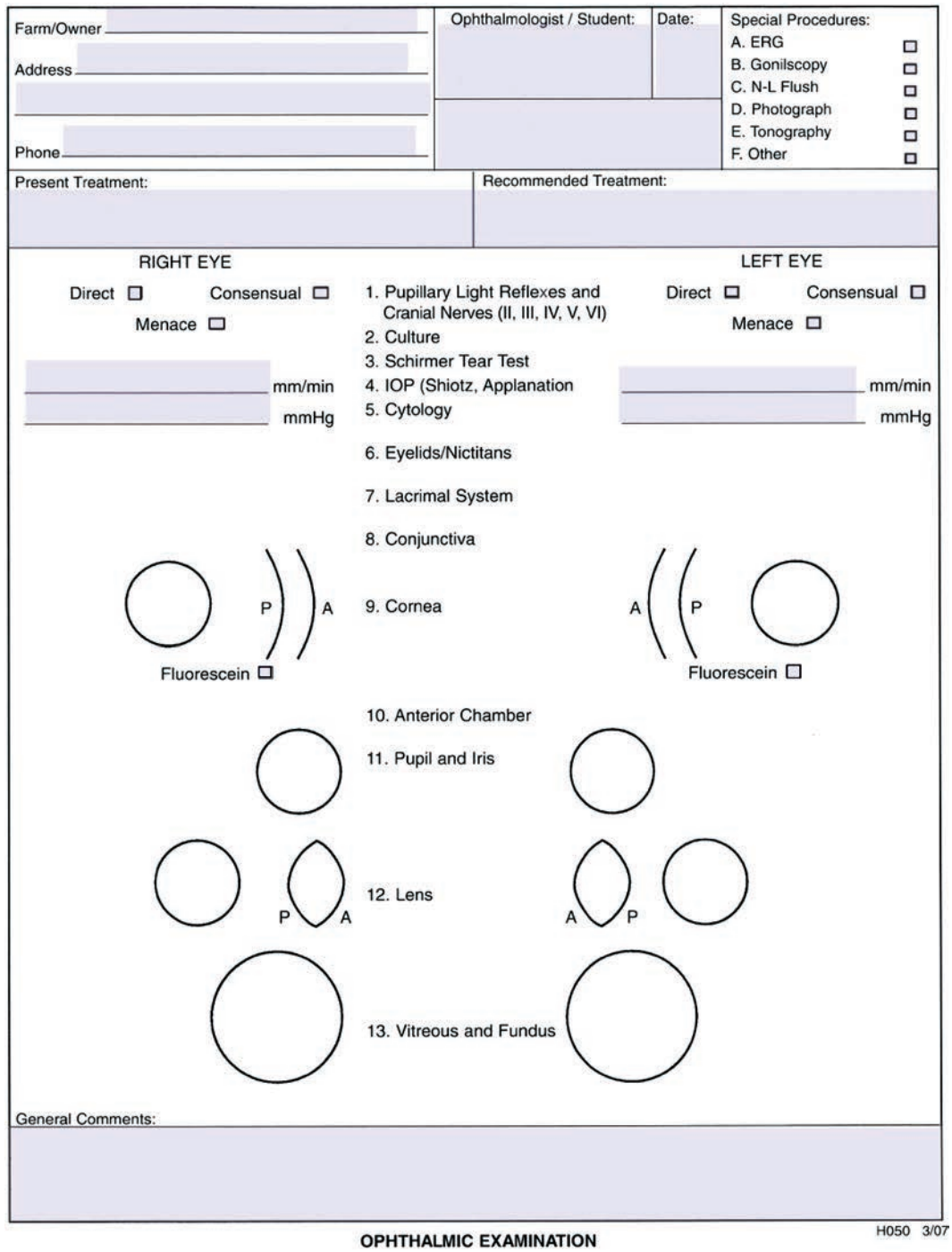
Farm/Owner
Address
Phone
Ophthalmologist / Student:
Date:
Special Procedures:
A. ERG
B. Gonilscopy
C. N-L Flush
D. Photograph
E. Tonography
F. Other
Present Treatment:
Recommended Treatment:
RIGHT EYE
Direct
Consensual
Menace
mm/min
mmHg
1. Pupillary Light Reflexes and Cranial Nerves (II, III, IV, V, VI)
2. Culture
3. Schirmer Tear Test
4. IOP (Shiotz, Applanation
5. Cytology
6. Eyelids/Nictitans
7. Lacrimal System
8. Conjunctiva
9. Cornea
10. Anterior Chamber
11. Pupil and Iris
12. Lens
13. Vitreous and Fundus
LEFT EYE
Direct
Consensual
Menace
mm/min
mmHg
P
A
Fluorescein
General Comments:
OPHTHALMIC EXAMINATION
H050 3/07

Fig. 1. Ophthalmic examination sheet, example (Hagyard Equine Medical Institute).

important to gently spray the solution, especially in fragile or compromised corneas, to decrease the risk of corneal perforation.

Refer to appropriate texts for diagrams and additional periocular nerve blocks for ophthalmic procedures or surgery.[2]

Examination Components

The ophthalmic exam should include evaluation of the following structures: periocular area, eyelids, third eyelid, conjunctiva, sclera, cornea, anterior chamber, iris, lens, vitreous, and fundus.[2,6] It is important to examine each structure in both eyes and avoid focusing directly on the lesion, as contributing factors may be missed. The examination sheet shown in Fig 1 may be helpful as a checklist. The veterinarian should perform the ophthalmic examination in an orderly repeatable manner each time. A preferred method is to begin at the front and progress to the back of the eye (anterior → posterior) while simultaneously moving from

peripheral to axial.[9] Retroillumination is used to visualize the tapetal reflection through the pupil; a focal light source is held close to the observer's eye and directed toward the horse's eye at arm's length.[6,9] This allows assessment of pupil size and symmetry and highlights any opacities impeding the reflection, including corneal scar, corneal blood vessels, cataract, pigment, and so on. Transillumination (focal illumination) is used to sequentially examine all structures in the anterior segment.[9] A focal light source should be directed at the eye from many angles while the examiner also varies the viewing angle, permitting assessment of the eye from all 3 dimensions.[6,9] Deeper structures are then examined using focal illumination, the slit-beam setting on the direct ophthalmoscope, and fundic examination with indirect ophthalmoscopy.

Adnexa, Eyelids, and Conjunctiva

The examiner may use a bright light source to provide direct illumination to inspect the adnexa, eyelids, and conjunctiva. Magnification loupes[a] are inexpensive and very helpful in identifying lesions on intricate structures. Varying degrees of magnification and focal distance are available. Any ocular discharge should be noted. The eyelid borders should be smooth and free of scars or regions of ulceration. Eyelid closure should be complete.[1] The globe should be retropulsed to extrude the third eyelid for examination. The conjunctiva should be smooth and pink with no irregularities. Common defects to look for include tumors (squamous cell carcinoma, sarcoid, melanoma, etc.), eyelid irregularities from prior trauma, entropion, and conjunctival hyperemia ± follicles consistent with conjunctivitis.

***The remainder of the ophthalmic examination is best performed in a dark or dimly lit area.* Magnification *is helpful in examining the cornea, anterior chamber, iris, and lens.*[2]

Cornea

The cornea should be smooth and clear with a lustrous tear film. Start with diffuse focal direct illumination and identify any abnormalities. Then change to the slit beam on a direct ophthalmoscope head to further evaluate corneal topography, thickness, depth of any previously identified lesions, and any areas of stromal loss. As with adnexa, magnification is very beneficial. Light directed perpendicular or diagonal to the cornea should help reveal opacities against the dark background of the iris/pupil interface.[2]

Anterior Chamber

The anterior chamber should be optically clear.[1] Again start with diffuse focal direct illumination to look for any abnormalities or opacities within the anterior chamber. Then change to the slit beam on a direct ophthalmoscope head to further evaluate clarity of the aqueous humor and the iris/lens interface. It is very important to look for aqueous flare, which represents protein ± cells in the anterior chamber and is an important indicator of anterior uveitis.[2,5,6] Aqueous flare can be detected by shining the focal light source directly on the cornea so it is a focused beam; the examiner looks perpendicular to the beam of light as it crosses through the anterior chamber. The anterior chamber should be clear and not cloudy or murky. Use the slit beam or the smallest focal circular beam of light to focus the light directly on the cornea.[6] Typically, the light source is held close to the cornea (~5–10 mm) in order to focus the light. The examiner should view the light from the side (45–90°) as the light courses from the cornea through the anterior chamber. Normal eyes will show the light beam hitting the corneal surface → a clear void in the anterior chamber → light hitting the anterior lens capsule and iris/lens interface → light coursing through the lens to the end at the posterior lens capsule.[6] A light beam visible in the anterior chamber between the cornea and iris/lens interface (like a car head light beam in the fog) indicates the presence of aqueous flare and thus uveitis.[6] Dark exam settings and magnification are helpful.

Iris Including Corpora Nigra

The iris should be examined for tissue architecture, smooth topography, variations in pigmentation, or mass effect. The iris may vary in color; combinations of brown and blue irides (heterochromia iridis) are a variation of normal. These should be differentiated from regions of hyper- or hypopigmentation of the iris from past uveitis.

The corpora nigra or granula iridica are normal round structures that arise from the posterior pigmented epithelium of the iris and are found at the dorsal and ventral pupillary margins.[7] Corpora nigra may have a wide variation of normal in terms of shape and size. It is important to compare the corpora nigra between both eyes to look for symmetry. Atrophy, shrinkage, or coalescence of corpora nigra may be indicative of past uveitis. Corpora nigra may also become cystic and enlarged, which can result in visual impairment from partial blockage of the pupil or impingement on the corneal endothelium causing corneal lesions.[7] Iridal cysts may be present separate from the corpora nigra along the margin of the pupil or rarely free-floating in the anterior chamber.[10] Iris cysts arise from the posterior pigmented epithelium of the iris and may peek over the pupillary margin into the anterior chamber. It is impossible to predict which cysts are likely to enlarge.

The examiner should ensure the pupil is mobile and look for any synechia (adhesions). Adhesions of the iris to the cornea are known as "anterior synechia."[7] Synechia are usually indicative of past corneal ulceration/rupture or uveitis. Anterior synechia should be differentiated from persistent pupillary membranes (iris to cornea), which are congenital. Persistent pupillary membranes (PPMs) typically originate at the iris collarette, and anterior synechia typically originate from the pupillary margin.[11] Adhesions of the iris to the lens are known as "posterior synechia" and generally indicate previous uveitis.[1] Differentiating a single episode of uveitis vs equine recurrent uveitis is generally not possible with a single examination.

Lens

Whether or not to dilate the pupil is dependent on the nature of the exam. In order to view the lens in its entirety, pharmacologic dilation is required.[5] It should be noted in the report whether or not the pupils were dilated for the exam. Pupillary dilation may also reveal subtle posterior synechia, which as described above indicates past uveitis. The most commonly used short-acting mydriatic is tropicamide 1%.

The lens is best examined initially with both direct illumination and retroillumination to identify lenticular opacities (cataracts). Using direct illumination, the observer should look for cloudiness or white opacities within the lens.[5,7] Retroillumination uses the reflection of light from the back of the eye (tapetum or red reflex in a nontapetal horse) to highlight lenticular opacities. Retroillumination causes opacities to appear dark against a light background.[5] The lens should then be examined with a slit beam, similar to other anterior segment structures listed above. The examiner should identify any opacities within the lens and then use the slit beam to further elucidate their location within the lens.

Lens position should also be evaluated. Lens luxation or subluxation is usually a consequence of trauma or uveitis.[7] This can be identified with a slit beam examining the iris–lens axis, which should be continuous. A "dip" or "step" in this slit beam at the iris–lens interface can be indicative of a lens subluxation or luxation.

Posterior Segment—Vitreous and Fundus

Examination of the posterior segment should begin with direct focal illumination (transillumination).[2] The vitreous is a hydrogel that should be optically clear. The central vitreous is variably liquified in horses of all ages, with liquefaction and mobility of the vitreous increasing with age.[1,7] With age and/or inflammation, condensations or occlusions (similar to "floaters" in humans) may become visible. If the vitreous is highly liquefied, these inclusions may be quite mobile as they move with the vitreous during eye movements.

Vitritis is inflammation of the vitreous and a part of posterior uveitis or panuveitis.[6,12] Inflammatory cells and debris may become suspended within the vitreous hydrogel, along with fibrin, hemorrhage, and vitreal membranes. These can result in vitreoretinal detachment. Although vitreal abnormalities can occur in the absence of anterior segment abnormalities, other evidence of previous uveitis (posterior synechia, cataract, corpora nigra atrophy, etc.) in conjunction may raise the suspension for equine recurrent uveitis.[5,12] Murkiness or yellow-green discoloration of the vitreous may obscure detail of the fundus and is observed in uveitis.[12]

The horse's fundus can be examined using both indirect and direct ophthalmoscopy. Ideally, both methods should be used as outlined below to examine the fundus through a dilated pupil. Indirect ophthalmoscopy requires a focal light source and a handheld lens (20 diopter or panretinal 2.2). This method gives the best overall widefield view of the fundus and is helpful in identifying lesions that may require closer examination with the direct ophthalmoscope.[1,5,12] Remember that the image obtained with indirect ophthalmoscopy is upside-down and backward. Indirect ophthalmoscopy gives the greatest field of view to assess the entire fundus.[2,6] The direct ophthalmoscope provides a very magnified view of a small field and should be used for detailed examination of the optic nerve, retinal blood vessels, and peripapillary region.[2,12] The author recommends indirect ophthalmoscopy always be performed to provide a broad screening view, as lesions can be missed if only direct ophthalmoscopy is used due to the narrow field of view at high magnification. An intermediate option for fundus examination is the PanOptic ophthalmoscope by Welch Allyn, which is also a direct ophthalmoscope that provides a field of view 5 times larger than standard direct ophthalmoscopy with less magnification.[6,12]

Many variations of normal exist for the equine fundus and can vary with coat and iris color. It is important to differentiate these variations of normal from pathologic changes. The major retinal abnormalities to look for include retinal detachment/separation, chorioretinitis or chorioretinal scarring, and changes to the optic nerve such as atrophy or inflammation.[5,12] Fundic pathology may be recognized by looking for ophthalmoscopic indicators of fundic disease,[7,12] which include the following:

- Loss or attenuation of peripapillary retinal blood vessels
- Raised hyporeflective, sometimes "fluffy" lesions (chorioretinitis)
- Regions of pigment clumping or pigment loss (chorioretinal scarring), including
  - Butterfly lesions (peripapillary)
  - Multifocal bullet-hole lesions
- Retinal detachment, which may be partial or complete with tear (rhegmatogenous); with a tear, a "veil" of retina is seen over the optic nerve head
- Pale or small optic nerve head (optic nerve atrophy)
- Reddened/hyperemic or enlarged optic nerve head (inflamed optic nerve)
- Attenuation of choroidal blood vessels ± white scleral show
- Mass or neoplasia

Interpretation of fundic lesions can be quite challenging regarding their clinical significance. Refer to textbooks and equine ophthalmology resources, including manuscripts that have pertinent information and color images to aid the examining veterinarian.[2,6,10,13]

Fluorescein Stain

Fluorescein stain should be performed on every eye with an ocular issue.[2,6] Stain may be applied by touching a

moist stain strip to the conjunctival surface; care should be taken to avoid touching the strip to the corneal surface as this can result in a false positive. Alternatively, the strip tip may be placed in a syringe with eyewash and gently irrigated on the corneal surface through a needle hub.[2,6] Corneal epithelium is hydrophobic and thus does not retain stain. Corneal stroma is hydrophilic and does retain stain.[6] Descemet's membrane does not retain stain; thus, very deep stromal ulcers may have a clear, dark, nonstaining center indicative of a descemetocele.[6]

The nares should be examined following fluorescein stain application to help evaluate patency.[2,6] Passage of the stain to the nares should occur within 5 minutes but may take up to 20 minutes.[2] Successful passage is definitive for a patent nasolacrimal duct. If fluorescein dye does not pass the nares and this is consistent with the clinical problem, irrigation of the nasolacrimal duct may be performed as a diagnostic test and/or treatment.[2,6] A negative test may also be a variation of normal due to the large-volume capacity of the equine nasolacrimal duct if no clinical signs associated with nasolacrimal duct obstruction are present.[2]

Summary

The equine ophthalmic examination should be performed in a routine, systematic, and repeatable manner. The eye is a very important and complex structure. A thorough ophthalmic exam should be performed for any primary ocular complaint, as well as during prepurchase examinations. Ophthalmic exams should be performed in systemically ill horses due to ocular manifestations of systemic disease. With practice, knowledge, resources, and appropriate equipment, the veterinarian will become competent and confident in ophthalmic examinations and interpretation of findings.

Acknowledgments

Declaration of Ethics

The Author has adhered to the Principles of Veterinary Medical Ethics of the AVMA.

Conflict of Interest

The Author has no conflicts of interest.

References and Footnote

1. Karpinski L. The prepurchase examination. *Vet Clin North Am Equine Pract* 2004;20:459–466.
2. Stoppini R, Gilger B. Equine ocular examination basic techniques. In: Gilger B, ed. *Equine Ophthalmology*. 3rd ed. Wiley Blackwell, Ames, IA; 2017:1–34.
3. Davis JL, Stewart T, Brazik E, et al. The effect of topical administration of atropine sulfate on the normal equine pupil: Influence of age, breed, and gender. *Vet Ophthalmol* 2003;6: 329–332.
4. Dwyer A. Practical Field Ophthalmology. In: Gilger B, ed. *Equine Ophthalmology*. 3rd ed. Wiley Blackwell, Ames, IA; 2017:72–101.
5. Scherrer N, Utter M, Monk C. How to perform the ocular portion of the pre-purchase examination, in *Proceedings*. Am Assoc Equine Pract 2013;59:191–194.
6. Allbaugh R. How to perform a thorough equine eye exam in the field, in *Proceedings*. Am Assoc Equine Pract 2013;59: 145–148.
7. Matthews AG. Eye examination as part of the equine prepurchase examination. *Equine Vet Educ* 2016;28:566–591.
8. Featherston HJ, Heinrich C. Ophthalmic examination and diagnostic. Part 1: The eye examination and diagnostic procedures. In: Gelatt KN, Gilger BC, Kern TJ, eds. *Veterinary Ophthalmology*. 5th ed. Ames, IA: Wiley Blackwell; 2013: 533–613.
9. Maggs DJ, Miller P, Ofri R. et al. *Slatter's Fundamentals of Veterinary Ophthalmology*. 5th ed. St Louis, MO: Saunders; 2016.
10. Barnett K, Crispen S, Lavach J, et al. *Color Atlas and Text of Equine Ophthalmology*. 2nd ed. London, UK: Mosby-Wolfe; 2004.
11. Leiva M, Pena T. Ophthalmic diseases of foals. In: Gilger B, ed. *Equine Ophthalmology*. 3rd ed. Wiley Blackwell, Ames, IA; 2017:369–415.
12. Allbaugh RA, Townsend WM, Wilkie DA. Diseases of the equine vitreous and retina. In: Gilger, B, ed. *Equine Ophthalmology*. 3rd ed. Wiley Blackwell, Ames, IA; 2017: 469–507.
13. Brooks D. *Ophthalmology for the Equine Practitioner*. 2nd ed. Jackson, WY: Teton New Media; 2008.

[a]Optivisor headband magnifier, Donegan Optical Company, Inc., Lenexa, KS 66219.

Upper and Lower Respiratory Exams in the Adult Horse

Emily Sundman, DVM, DABVP (Equine Practice)

Author's address: Texas Tech University, School of Veterinary Medicine, 7671 Evans Drive, Amarillo, TX 79106; e-mail: esundman@ttu.edu. © 2022 AAEP.

1. Introduction

Respiratory examinations in adult horses are necessary assessments that can be conducted in the field or in-clinic. Respiratory disease is nebulous in the adult horse; it can be a comorbidity of other diseases, or it can be a primary disease that is masked by other ailments (e.g., gastrointestinal system), and a thorough examination is invaluable to the practitioner. Often, respiratory abnormalities are identified by the observant veterinarian during an examination for a different purpose. This review details the key components of a thorough respiratory examination as well as specific diagnostic procedures that can be conducted in an ambulatory setting to further evaluate the respiratory system. Broadly, the practitioner should aim to localize the disease or abnormality (upper versus lower respiratory) and identify the type of disease (infectious versus noninfectious) to inform further diagnostics and treatment plans.

2. Signalment and History

Signalment and patient history are used to direct and focus the subsequent physical examination. Certain signalments or histories may prioritize specific diagnoses or drive specific physical examination measures to evaluate the information provided. Many diseases have an increased incidence based on age (severe neutrophilic asthma with older horses, viral pneumonia with younger animals). Breed and use of the horse also have strong disease associations. Travel history and vaccination status are relevant for identifying risk of infectious diseases. Other causes of stress or immunosuppression are also critical (e.g., recent surgery or general anesthesia, medication history). Evaluation of the environment will also inform the examination, including housing (e.g., pasture, stable), air quality (e.g., dust, ammonia, smoke exposure), feed quality (e.g., dusty or moldy hay), and housing density. Questions to the owner of a potential respiratory case should at minimum include information detailed in Table 1.

3. Physical Exam

The physical examination of the horse with either upper or lower respiratory disease is critical to directing additional diagnostic tests and prioritizing differential diagnoses. This review focuses on the specifics of the respiratory system; however, an excellent general physical examination must be performed to compile a thorough and accurate differential list. Many diseases of respiratory origin have systemic effects, while diseases of nonrespiratory origin may generate respiratory clinical signs (Table 2). The respiratory system in the horse is robust, allowing for disease to progress substantially before causing clinical signs observed by the owner.[1]

A thorough respiratory examination begins with observation of the standing horse. Evaluate the carriage

NOTES

Table 1. Question for Owners to Support Evaluation of the Respiratory System

Questions for Owners	
• History of nasal discharge?	• What is the horse fed?
• History of cough?	• How is the horse housed?
• History of exercise intolerance or poor performance?	• Deworming and vaccination history?
• History of abnormal respiration?	• Travel history?
• History of abnormal or increased noise from respiratory tract? At rest or exercise?	• Medical history (chronic and recent acute; fever, appetite)?
• History of odor from nares or mouth?	• Medication use history?
• Duration of clinical signs?	• Type of exercise or use?
• Is there a seasonal component to the clinical signs?	• Does the horse have allergies?
	• Other cases of respiratory disease on farm?

of the neck (at the level of the shoulder, below, or above) and head (in extension in cases of increased respiratory effort) of the horse. Observe the horse's posture and elbow position as abducted elbows may indicate pleural pain. Evaluate the horse's head for asymmetry and swelling (particularly of the frontal and maxillary sinuses and retropharyngeal lymph nodes). Percussion of the maxillary and frontal sinuses may elicit pain or a change in resonance. Evaluate both nares for flaring, equal and adequate airflow, odor, and evidence of nasal discharge. If nasal discharge is observed, define the quality (serous versus mucoid versus purulent) and quantity of discharge. Palpate the larynx for atrophy and surgical scars and note if a painful response or cough occur. Observe the respiratory rate and effort at rest and evaluate for evidence of a "heave" line. If the horse coughs voluntarily during the examination, evaluate the cough for frequency, noise, and whether the horse swallows following a cough (indicating it may be productive).

Auscultation in a thorough respiratory examination should cover the following locations at a minimum: trachea (proximal, middle, and distal thirds), lungs (dorsal, ventral, cranial, and caudal fields), and heart bilaterally. Auscultation of the trachea should evaluate for turbulent airflow and sounds of increased mucus. The lung fields should be evaluated for altered bronchovesicular sounds, crackles, wheezes, pleural friction rubs, and the absence of lung sounds (nonaerated lung). The heart should be auscultated both for primary cardiac disease and for decreased sound or muffling from pulmonary disease. Due to the robust capacity of the equine pulmonary system, subtle disease can be difficult to auscult. A rebreathing bag can be useful for mimicking the effect of a deep breath in human patients and can elicit a cough in predisposed horses. The bag must be large enough to allow the horse to breathe deeply as the exam progresses but small enough to not spook the animal or require a prolonged exam. Horses that are highly resistant to rebreathing bags may have chest pain or may be prone to hypoxia, and horses with airway irritation may cough. Once the bag is removed, the lungs and trachea should be auscultated rapidly.

Horses with a history of clinical signs while in work may require evaluation at speed in order to detect abnormalities, particularly if minimal abnormalities are observed in the standing examination. Some horses may make abnormal respiratory sounds or demonstrate a poor respiratory recovery (e.g., prolonged elevated respiratory rate, flared nostrils, productive cough) following lunging or jogging without tack. Other horses may need to be ridden under tack to elicit the clinical signs, particularly for disciplines where significant neck flexion is a component of the activity.

The results of the physical examination should provide sufficient evidence for the practitioner to begin to localize the abnormalities (upper versus lower respiratory tract) and prioritize any additional diagnostic tests. Importantly, suspected cases of

Table 2. Common Differentials in Respiratory Examinations

Disease	Characteristic Clinical Signs on Physical Examination
Bacterial pneumonia	Purulent nasal discharge, cough, fever, inappetence
Pleuropneumonia	Pleural pain (elbows abducted, reluctant to move), fever, inappetence, decreased lung sounds ventrally
Asthma	Tachypnea, cough, heave line
Viral pneumonia	Serous nasal discharge, dry cough, fever, limb edema
Strangles (*S. equi* subsp. *equi*)	Enlarged retropharyngeal lymph nodes, purulent nasal discharge, fever
Ethmoid hematoma	Epistaxis, cough
Exercise-induced pulmonary hemorrhage	Epistaxis
Recurrent laryngeal hemiplegia	Noise during exercise
Guttural pouch mycosis	Epistaxis, Horner's syndrome, dysphagia, fever
Sinusitis	Purulent nasal discharge, odor, fever, facial swelling
Dental disease	Purulent nasal discharge, odor, fever

infectious disease require consideration of the order of diagnostic sample collection to prevent contamination of samples and other patients, and may warrant implementation of biosecurity practices. Baseline bloodwork (complete blood count, serum chemistry, serum amyloid A) is often warranted, and in some cases, infectious disease assessment via nasal swab subjected to polymerase chain reaction testing may be indicated. Several clinical signs warrant additional diagnostics routinely, while others may be justified with an initial treatment and reassessment in the event of treatment failure.

4. Endoscopy

Excellent reviews of respiratory endoscopy technique and equipment are available.[2] Briefly, an approximately 1.0- to 1.5-m endoscope with either direct or video-based visualization capabilities is required for standing evaluation. The use of sedation is guided by the differential diagnoses generated from the history and physical examination. Whenever possible, suspected cases of laryngeal disorders should be evaluated without sedation, or with minimal sedation, in order to avoid sedation-induced relaxation of laryngeal and pharyngeal muscles.[3] The use of butorphanol is recommended for cases undergoing evaluation of the complete trachea to minimize coughing during the evaluation. A twitch can be useful for ensuring restraint of the horse and preventing damage to equipment or personnel.

When performing endoscopy of the respiratory tract, thorough examination is vital as an abbreviated evaluation can miss critical abnormalities. Furthermore, systematic and thorough examination can build the practitioner's experience in the range of normal anatomy. Both nasomaxillary apertures can be easily visualized at the caudal end of the middle nasal meatus between the ventral and dorsal nasal conchae and can be inspected for discharge arising from the paranasal sinuses. The contralateral nasal passage, conchae, and aperture should be evaluated via a brief reentrance of the endoscope in the opposing nostril at the end of the exam. Upper airway evaluations should include the ethmoid turbinates (conchae), pharynx, larynx, and proximal trachea. When observing the larynx, it can be useful to first observe the function through several breaths, then stimulate the horse to swallow, and again observe that the larynx returns to a normal resting posture. Dynamic endoscopy in the field or treadmill-based endoscopy are specialized procedures that are typically conducted, if warranted, following static evaluations.[4]

The openings to the guttural pouches via the pharynx should be observed in all horses for evidence of discharge. Entrance into the guttural pouches can be facilitated through the use of a guidewire, and any horse with purulent guttural pouch discharge should be investigated further due to the high index of suspicion for strangles (*S. equi* subsp. *equi*) infection. Hemorrhagic discharge should be investigated due to the potential for guttural pouch mycosis.

Lower airway endoscopy allows for visualization of the distal trachea and entrance to the intrathoracic airways. The trachea should be evaluated for the presence of blood or exudate. Localized discharge may indicate the location of a pulmonary abscess. Direct aspiration of pooled tracheal fluid is possible via the endoscope; however, sample collection for bacterial culture is better attempted via a percutaneous approach or via use of a guarded sterile catheter to avoid contamination from pharyngeal organisms.[5]

5. Thoracic Ultrasound

Thoracic ultrasound requires practitioner experience to obtain and interpret images but can be a quick and direct method to identify significant lesions in the equine pulmonary system. Thoracic ultrasound has largely replaced thoracic percussion in practice with the rise of high-quality portable units. Copious isopropyl alcohol application to the areas of the horse that will be ultrasounded is necessary for transducer (probe) contact and acceptable image quality. Alternatively, horses can be clipped, and ultrasound gel can be used if needed. The entire lung field should be scanned in a systematic (dorsal to ventral and caudal to cranial or cranial to caudal) manner bilaterally. At minimum, the evaluation should span from intercostal space 3 through 16 using the epaxial muscles as the dorsal border and the costochondral junctions as the ventral border. Excellent reviews are available of techniques for thoracic ultrasound in the horse.[6]

Thoracic ultrasound can often confirm the differentials generated during physical examination. Suspected pneumonia or pleuropneumonia can be supported by increased ventral pleural fluid, flocculant areas within free fluid, significant pleural roughening or "comet tails," consolidation, atelectasis, or abscessation. Suspected equine asthma and exercise-induced pulmonary hemorrhage can be supported by pleural roughening in the caudodorsal lung field, and nonspecific masses can support neoplasia or equine multinodular pulmonary fibrosis.

6. Bronchoalveolar Lavage and Transtracheal Wash

Sample collection from the lower respiratory tract can be broadly divided between bronchoalveolar lavage (BAL) and transtracheal wash (TTW). Bronchoalveolar lavage is most appropriate for cytologic diagnosis of noninfectious lower respiratory disease (e.g., exercise-induced pulmonary hemorrhage, asthma). Transtracheal wash is useful for characterization of infectious lower respiratory disease, particularly of bacterial or fungal cause, by collection of fluid for culture and sensitivity. Both techniques can be performed with or without endoscopic guidance. The use of an endoscope is highly dependent on the preference of the

veterinarian, the availability of equipment, and the number of respiratory procedures to be completed during the visit. Percutaneous TTW procedures and BAL procedures using BAL catheters should be performed prior to endoscopic evaluations to avoid contamination by upper airway commensal organisms. Sedation is often useful for these procedures (alpha 2 agonist of choice with butorphanol) for compliance of the horse and cough suppression.

Transtracheal wash collection must be a sterile procedure, either by a guarded sterile catheter through the endoscope biopsy channel or by percutaneous transtracheal approach with a commercially available TTW kit. A local anesthetic block is needed for the percutaneous approach, and 100 mL of warmed sterile 0.9% saline divided into 2 aliquots is recommended for the infusion. Recovery attempt should be made between each aliquot, and sufficient recovery may be obtained following the first attempt. Previous history of antimicrobials should be used to inform the usefulness of TTW collection in a particular horse. Finally, the trachea is not a sterile environment, and culture results should be interpreted accordingly.

Bronchoalveolar lavage is aided by the administration of 20 to 60 mL of sterile 2% lidocaine solution to the distal trachea to diminish the cough reflex. Bronchoalveolar lavage collection via a 3-m BAL tube (without endoscopic guidance) will most often collect samples from the right dorsal lung field. Passage of the BAL catheter is aided by positioning the horse's head in extension. Similar to the TTW, endoscopic BAL collection requires use of a guarded catheter. Cases where the BAL sample will not be cultured, the endoscope has been disinfected and rinsed, and the sample collection is in a clean environment may not require the use of the guarded catheter for sample collection. Endoscopic guidance can direct sample collection to a specific lung lobe if there are concerns of a localized lesion. Firm lodging of the BAL catheter into the bronchus aids in the collection of wash fluid. The recommended instilled fluid is 200 to 250 mL of warmed 0.9% saline instilled in 2 divided aliquots of 100 to 125 mL each. Recovery attempt should be made between each aliquot. Effort should be directed to maximizing the collection of instilled saline to at least greater than 50% to 75%.

Samples collected for culture should be immediately placed preferentially in an appropriate culture transport system or a sterile nonadditive vial. Samples collected for cytology should be placed in ethylenediaminetetraacetic acid (EDTA) vacutainers for cell preservation. In cases where specific molecular diagnostic tests are required (e.g., equine gamma herpesvirus 5), the reference laboratory should be contacted for the preferred collection plan.

7. Conclusion

Field-based diagnostic tools are available to support the results of a thorough physical examination in evaluating the respiratory system and can help differentiate between upper and lower respiratory tract disease. If etiology remains elusive, referral for thoracic or upper airway radiographs may be considered. Respiratory diseases in the horse can have complex pathogeneses, and respiratory-based clinical signs may be present in diseases of other systems. For example, nasal discharge may be present in cases of tooth-root abscessation, and a horse with pleural pain may present with "colic." Primary respiratory diseases may have underlying initiating factors that complicate the initial diagnosis, such as pneumonia in a horse with severe asthma or following viral infection. Thought and preplanning of respiratory diagnostic procedures is critical to obtaining useful evaluations and samples. This review is not an exhaustive description of respiratory diseases in the adult horse; however, less common abnormalities are identified with the same thorough systematic examination and use of diagnostic testing.

Acknowledgments

Declaration of Ethics

The Author has adhered to the Principles of Veterinary Medical Ethics of the AVMA.

Conflict of Interest

The Author is a consultant for Boehringer-Ingelheim Animal Health.

References

1. Poole D. Current concepts of oxygen transport during exercise. *Equine Comp Exerc Physiol* 2004;1:5–22.
2. Parente EJ. Upper airway conditions affecting the equine athlete. *Vet Clin North Am Equine Pract* 2018;34:427–441.
3. Lindegaard C, Husted L, Ullum H, et al. Sedation with detomidine and acepromazine influences the endoscopic evaluation of laryngeal function in horses. *Equine Vet J* 2007;39:553–556.
4. Elliott S, Cheetham J. Meta-analysis evaluating resting laryngeal endoscopy as a diagnostic tool for recurrent laryngeal neuropathy in the equine athlete. *Equine Vet J* 2019;51:167–172.
5. Christley R, Hodgson D, Rose R, et al. Comparison of bacteriology and cytology of tracheal fluid samples collected by percutaneous transtracheal aspiration or via an endoscope using a plugged, guarded catheter. *Equine Vet J* 1999;31:197–202.
6. Johns I. Use of thoracic ultrasound to investigate respiratory disease. *UK-Vet Equine* 2020;4:106–111.

Emergency Colic and Gastrointestinal Examination in the Horse

Andrew T. Willis, DVM, DACVIM (LAIM)

Author's address: Weatherford Equine Medical Center, PC, 1877 Mineral Wells Highway, Weatherford, TX 76088; e-mail: atwillis@weatherfordequine.com. © 2022 AAEP.

1. Introduction

Colic is the most common emergency condition of the horse.[1] As clinical signs associated with nondescript abdominal pain may vary widely from mild intermittent pawing or flank watching to marked uncontrollable thrashing, the condition can be distressing for owners and sometimes veterinarians alike. Having the clinical acumen to tease through the information to elucidate an underlying etiology, or at least category thereof, can improve patient outcomes and client satisfaction, as well as provide reassurance or increased linearity in the medical management versus surgical intervention decision-making algorithm. A thorough, yet concise, investigation of the patient's history and clinical examination to supplement diagnostic modalities may also facilitate diagnoses of nongastrointestinal diseases. Some nongastrointestinal diseases may mimic signs of colic; therefore, rendering an accurate diagnosis may subsequently lead to appropriate case management.

2. History

Assessment of the colicking horse begins with the signalment of the patient and a thorough but concise history. Often the history may be either condensed or performed concurrently with the physical examination and/or diagnostics as time is of the essence. Main areas on which to focus include what clinical signs the owner is noticing, the duration of those observed clinical signs, previously and/or recently administered medications and supplements, diet, deworming protocols, and dental history.

Signalment and Presenting Complaint

Signalment can be a helpful place to start to facilitate a definitive diagnosis. Examples of key signalment and etiology associations include young horses (weanlings in particular) and ascarid impactions, older horses and strangulating lipomas, American miniature horses and fecaliths, and postpartum mares and large colon torsions. It is important to understand what the owner has been observing at home and how long those clinical signs have been noted. Sometimes owners can perceive certain clinical signs as colic while an entirely different body system may be affected; examples of this would include exertional rhabdomyolysis (e.g., walking stiffly), pleuropneumonia (e.g., walking with the elbows abducted), and genitourinary issues (e.g., stretching out to urinate). Additionally, the specific clinical signs the owner has noted can be particularly useful for the practitioner's "severity barometer" as simply mild intermittent inappetence might be managed with supportive care, whereas patients exhibiting uncontrollable thrashing may require immediate surgical intervention. Similarly, it is imperative to question the owner as to what medications and/or supplements they have administered, by what route they have done so, and how these medications have affected the patient. This

NOTES

will assist the practitioner in gauging the severity of the patient's colic and facilitate documentation of potential treatment complications (e.g., clostridial myositis from intramuscular flunixin meglumine administration). Administration of a nonsteroidal anti-inflammatory drug (NSAID) is often inadvisable if the owner has already done so, particularly in the face of dehydration, which is common in horses exhibiting signs of colic.

Diet

A brief investigation of the patient's diet may also suggest certain etiologies. Feedstuffs or feeding practices that have been associated with a specific disease-causing colic include coastal Bermuda grass (especially free-choice access to round bales) leading to ileal impactions, alfalfa hay with resultant cantharidin toxicosis or enterolithiasis, and high-grain/concentrate diets that can predispose to equine gastric ulcer syndrome.

Dentistry and Deworming

An additional part of the abbreviated history should include inquiries into the client's dental and deworming history. It is well established that poor dentition can lead to impactions at various locations within the gastrointestinal tract. Endoparasitism, especially ascarid impactions and emergence of encysted strongyles, can be associated with clinical signs of colic. History is a key component of diagnosis of these disorders; without history, these diseases may not be diagnosed, leading to treatment failure and poor client-patient outcomes.

Additional Information

Two final points of consideration include whether the patient is a surgical candidate and if the patient has insurance coverage. Important questions to ask regarding insurance include type (e.g., colic surgery, major medical) and amount of insurance coverage. Additionally, the practitioner should inquire as to other noninsurance coverage that patient may have for colic as it is becoming more commonplace for feed and supplement companies to offer some form of coverage. This information is often required for insurance claim reports as many insurance companies will inquire as to any additional coverage the patient may have beyond that which the insurance company provides.

3. Physical Examination

The baseline colic examination should include a distance examination to gauge the patient's pain level, assessment of heart rate, temperature, respiratory rate, auscultation of gastrointestinal borborygmi, and mucus membrane color and consistency. As the practitioner is driving up on the farm, walking up to the patient, or the patient is being brought into the clinic, the examiner should perform an assessment of the patient's overall pain level exemplified by attempts to lay down, sweating, and abrasions/wounds that indicate that the patient has been aggressively rolling. First and foremost, the heart rate should be obtained; if the patient is tachycardic, all other history taking, assessment, and diagnostics should be postponed, and nasogastric intubation should be performed to facilitate gastric decompression and to help prevent gastric rupture. With respect to gastrointestinal auscultation, at minimum, four quadrants (namely paired right and left dorsal and ventral quadrants) should be auscultated; however, the author prefers a fifth location to be auscultated for a minimum of 30 seconds on the cranioventral abdomen to assess for sand (which has been likened to the sound of "waves crashing on a seashore"). Assessment of the mucus membrane tackiness can also be an indicator of the level of hemoconcentration, whereas assessment of the color can suggest other pathological conditions (e.g., toxicity associated with colitis, strangulating lesions, etc. and petechiation associated with thrombocytopenia or anaplasmosis, etc.). Other relevant parts of the clinical examination, especially to rule out clinical syndromes that mimic colic associated with gastrointestinal disease, may include palpation of the muscles for evidence of rhabdomyolysis, assessment of pleural pain for pleuropneumonia, and visualization of jugular fill following venous occlusion for volume status evaluation.

4. Diagnostics

While determining a definitive diagnosis is ideal, it may not always be feasible. Furthermore, an exhaustive list of etiologies for colic in horses is not only beyond the scope of this review but also less clinically useful in an emergency situation. As such, the author prefers to attempt to categorize lesions identified during a clinical workup of the acute abdomen into (1) small intestinal, (2) large intestinal, and (3) other. Regardless of the underlying etiology or categorization, the diagnostic modalities employed will be similar, yet it is the interpretation of these diagnostics that can facilitate achieving a definitive diagnosis. The secondary goal beyond classifying the lesion as small versus large intestinal should be to elucidate whether the lesion is surgical in nature. This should be performed as early in the clinical presentation as possible and as prospectively as feasible. The previously mentioned nasogastric intubation, which may have already been performed by this time due to the clinical presentation of the patient (e.g., tachycardia), is both diagnostic and therapeutic. The presence of gastric reflux may indicate either a primary or secondary small intestinal lesion. As mentioned previously, gastric decompression is also important to avoid stomach rupture.

Clinical Pathology

Clinicopathological data can determine the severity of the colic episode, classify medical versus surgical lesions, and assist in monitoring the response of the

patient to various therapies. A minimum database on a blood sample from the acute abdomen case should include a manual packed cell volume and total solids, as well as an L-lactate concentration. The value in these parameters is to assess the patient's overall hydration status (packed cell volume/total solids) and the patient's ability to perfuse their tissues (L-lactate), as well as to assist in the medical versus surgical decision-making process (discussed later). Additional lab work that may be useful in assessing the colicking horse include blood gas analysis (either venous or arterial—typically venous in an emergency triage situation), measurement of serum/plasma electrolytes (most preferably to include ionized calcium), a serum biochemical profile (or components thereof—renal parameters, liver enzymes, muscle enzymes, and protein differential), complete blood count, and peritoneal fluid analysis (discussed later).

Blood Gas Analysis

Most blood gas analyzers will include measurement of serum electrolytes, including ionized calcium. Some etiologies of colic can produce acid-base changes (e.g., hypochloremic metabolic alkalosis due to large volume gastric reflux, metabolic acidosis due to colitis), which can be prognostic in nature or simply diagnostic of a change; correction of metabolic perturbations can reduce case fatality rate and/or make the patient a better anesthetic and surgical candidate. However, a complete review of acid-base interpretation and correction of abnormalities is beyond the scope of this review. Measurement of ionized calcium can be exceptionally useful for the management of the colicking horse. Since calcium is required as part of the mechanism for smooth muscle contraction and ionized calcium is considered the biologically available or active fraction of total calcium, correction of hypocalcemia should be aggressive; a rule of thumb for calcium supplementation is 25 to 50 mL of 23% calcium gluconate or calcium borogluconate per liter of isotonic crystalloids since oversupplementation of calcium is unlikely due to efficient renal excretion of excessive calcium in an equine patient with otherwise appropriately functioning parathyroid and thyroid glands. Additionally, portable blood gas analyzers are widely available and can be used in the clinic, stall-side, and in an ambulatory setting.

Biochemical Profile

The author reserves the biochemical profile (or the components therein as aforementioned) for when azotemia may be suspected, helping to elucidate a medical versus surgical lesion (discussed later) and helping to rule in or out forms of colic or other etiologies that may mimic gastrointestinal disease. As will be discussed in the treatment section of these proceedings, NSAIDs are one of the mainstays of analgesia for colic cases; however, it is widely recognized that NSAIDs are potentially nephrotoxic, especially in the face of dehydration. Therefore, if the practitioner feels as though it is clinically indicated, assessment of renal values is recommended. Muscle enzyme assessment can help determine if the patient is experiencing rhabdomyolysis, which may be the primary problem or secondary to the colic episode. The reader will recall that elevations in muscle enzymes can occur simply secondarily to some of the signs that horses exhibit as a result of abdominal pain, such as rolling; however, the presence of firm musculature upon musculoskeletal palpation in conjunction with a stiff gait and elevated muscle enzymes in the absence of additional classic colic signs may be indicative of rhabdomyolysis as the primary medical issue. That said, the author recommends (especially for liability purposes) for the workup and management to be exhaustive, particularly if the presenting complaint is colic. Muscle enzymes can also be helpful to elucidate a medical versus surgical lesion, which will be discussed more in later sections. Evaluation of liver enzymes can also be useful for horses experiencing signs of colic. Horses with primary liver disease (e.g., hepatobiliary disease, cholelithiasis) may present as a colic; however, certain types of gastrointestinal lesions may also cause elevations in liver enzymes, such as proximal enteritis[2] and large colon displacements, especially right dorsal displacements.[3]

Complete Blood Count

Indications for a complete blood count would primarily include elevated rectal temperature (i.e., fever or hyperthermia) on presentation, the presence of diarrhea, and/or the visualization of thickened or edematous intestinal walls on transabdominal ultrasound. In addition to rendering a proper diagnosis, the assessment of the patient's leukogram is important for biosecurity, regardless of whether the patient is being assessed in the field or the hospital. Changes in the patient's white blood cell count when evaluated in conjunction with these clinical signs can be indicative of a potentially infectious and/or contagious pathogen. Primary differentials for the aforementioned abnormalities would be enteritis, colitis, and enterocolitis, in which case the leukogram will most likely reveal leukopenia characterized by a neutropenia and/or a lymphopenia with or without immature neutrophils, depending on the underlying etiology and the stage at which the patient presents, and may be an indication for isolation.

Abdominocentesis

The final clinicopathological data set that may be useful is peritoneal fluid analysis. Abdominocentesis can be performed in both the hospital and field settings. Indications for abdominocentesis in horses with colic include a high degree of pain, ultrasonographic visualization of colonic vasculature in the right hemiabdomen consistent with a right dorsal colon displacement or large colon volvulus, the presence of dilated loops of small intestine on transabdominal ultrasound, thickened or edematous intestinal walls on transabdominal ultrasound, an increased quantity or abnormal echogenicity of peritoneal fluid on

transabdominal ultrasound, presence of intra-abdominal masses on transabdominal ultrasound, suspicion of gastrointestinal tract rupture, and/or if the patient is insured. Preferably, the peritoneal fluid analysis would include a gross analysis, total nucleated cell count and cytologic evaluation, L-lactate concentration, total solids, and glucose concentration. It is preferable to perform peritoneal fluid analysis concurrent with analysis of peripheral blood as a comparison between analytes measured in the peritoneal fluid and peripheral blood can improve accuracy of assessment. Additionally, the author recommends collecting peritoneal fluid when possible for additional testing if indicated, such as a red top tube for culture and sensitivity testing. The normal appearance of peritoneal fluid should be clear and straw-colored such that the practitioner can "read a newspaper through it." The more common abnormalities that can be observed on gross examination would be serosanguinous color change consistent with a strangulating or surgical lesion (the common saying is "red is dead") and the presence of fecal or feed material suggestive of a gastrointestinal tract rupture. The clinicopathological parameters of normal peritoneal fluid values reported in the literature are widely variable; thus, the author uses $< 5{,}000$ cells/μL for total nucleated cell count, < 2 mmol/L for L-lactate, and < 2.0 g/dL for total solids, which is relatively commonplace amongst the equine veterinary community. A final analyte to consider for peritoneal fluid would be creatine kinase. A peritoneal fluid creatine kinase level of greater than or equal to 16 IU/L, particularly in those cases where the peritoneal fluid L-lactate concentration is additionally elevated as previously described, is quite sensitive and specific for a strangulating lesion.[4]

Peritoneal fluid:blood ratio of lactate and glucose can provide valuable information. For L-lactate, the relative value should be less than twice the peripheral L-lactate, or the ratio of peritoneal fluid L-lactate to peripheral blood L-lactate should not be greater than 1:1, as elevations in L-lactate greater than twice the peripheral L-lactate or elevated ratios have been associated with strangulating and/or surgical lesions in multiple research studies. Peritoneal fluid glucose concentrations should roughly approximate those in the systemic circulation, whereby decreased peritoneal fluid glucose concentrations, especially if less than half of peripheral blood concentrations, could be indicative of peritonitis.

Additional Diagnostics

Beyond clinicopathological data, other common diagnostic modalities for use in the equine acute abdomen would include transabdominal ultrasound, rectal palpation, and abdominal radiography.

Ultrasound

Transabdominal ultrasound is remarkably beneficial for use in the equine acute abdomen. A comprehensive overview of transabdominal ultrasonography is beyond the scope of this review; however, some key points will be outlined here. Ideally, if the patient is otherwise stable, the transabdominal ultrasound will be performed in the same manner, starting in the same place, on the same side of body, in the absence of sedation (as alpha-2 agonists alter gastrointestinal motility) with each case. Ideally, a large curvilinear 2- to 5-MHz probe would be used. However, a 5- to 10-MHz rectal probe may be used if it is the only available transducer. In the right hemiabdomen, the cecum and right ventral and dorsal colons should be examined for mural thickening and edema. The duodenum should be observed between the liver and the right dorsal colon for mural thickening and edema, as well as luminal distension and evidence of peristalsis. Colonic vasculature should not be visible in the right hemiabdomen on the lateral aspect of the right dorsal colon; this finding would be consistent with a right dorsal displacement of the large colon or a large colon volvulus. In the left hemiabdomen, the spleen should be observed adjacent to the left kidney, whereas the presence of gas-filled bowel (in which sacculations are often visible) adjacent to the spleen that precludes visualization of the left kidney is consistent with a nephrosplenic entrapment (or left dorsal displacement). Normal segments of the small colon in the left paralumbar fossa should be observed. The greater curvature of the stomach should be observed adjacent to the spleen and corresponding splenic vein within normal anatomical limits with a normal radius of curvature. The left dorsal and ventral colons should also be visualized similar to that of the right dorsal and ventral colons. The jejunum should be observed in the left inguinal region. The ventral abdomen should be scanned for the presence and characterization of peritoneal fluid. Aforementioned anatomic structures that would be visible with a rectal transducer include small intestinal inguinally, stomach size and shape, and colonic wall thickness and luminal content.

Rectal Palpation

Rectal palpation is also useful to assist in diagnosing various types of colic. Rectal tears are an uncommon and unfortunate complication associated with rectal palpation and have the potential to lead to malpractice claims. As such, every effort should be made to prevent rectal tears when performing diagnostic rectal palpation. The author recommends that the patient be haltered, twitched, restrained in stocks, sedated with a combination of an alpha-2 agonist and an opioid (discussed later), administered a butylscopolamine bromide, and have rectal mucosa locally anesthetized with a minimum of 60 mL of either 2% lidocaine or mepivacaine instilled through a red rubber catheter, while using an abundance of methylcellulose-based lubrication atop the practitioner's rectal sleeve. Additionally, fecal material should be carefully removed and lubricant reapplied following each evacuation prior to any attempt to perform a diagnostic evaluation. The author also suggests saving the evacuated fecal material for fecal analysis if clinically indicated, which may include fecal flotation for parasites, fecal egg count, floating the feces in water in a rectal

sleeve for sand, and/or fecal polymerase chain reaction test for infectious pathogens and their respective toxins. There are many methods for rectal palpation, but the author prefers a method whereby a clockwise approach is taken with the abdomen divided into a four-quadrant palpation window; outlined here is an overview of this method. When the abdomen is viewed in a caudocranial fashion, the examiner will fall off the pelvic brim and in the left ventral palpation window, the small colon should be appreciated whereby the fecal balls should be easily distinguishable and somewhat indentable with the gently cupped palpation hand. Extending cranially from this position, the pelvic flexure may be appreciated, but is not always felt depending on the length of the practitioner's arm, the size of the horse, as well as the fecal content within the pelvic flexure. Rotating in a clockwise direction to the left dorsal palpation window, the caudal extent of the spleen should be palpated abaxial to the caudal pole of the left kidney. To reorient the examiner, the palpation hand is cupped dorsally to find a true median line that divides the palpation window in the left and right (the pulse within the terminal aorta can be a useful landmark for this purpose). Along the right side of the patient, the cecum should be appreciated with a consistent quantity of gas; when the medial band of the cecum is palpated, the cecum should not seem heavy and on ballottement should not appear to be excessively gas distended. Additionally, it is important to note that small intestinal loops, tight bands, and gas distension are all abnormal findings on rectal palpation and should be noted and addressed appropriately. An additional finding that could be appreciated is the urinary bladder along ventral midline; depending on the quantity of urine within the bladder lumen, it may be appreciated and should not be confused for an abnormal finding associated with the gastrointestinal tract.

Abdominal Radiography

Abdominal radiography is not currently widely available to most private practitioners, particularly to those in ambulatory practice; referral to either a university or specialty imaging center is often required. Notably, abdominal radiographs obtained with portable units are of limited diagnostic value when evaluating light-breed (or larger) adult horses and have been known to confound diagnoses; thus, it is inadvisable to attempt diagnosis with these units. The two primary indications for abdominal radiographs include evaluation for the presence of sand (e.g., sand impactions) and enterolithiasis.

Further Comments on Diagnostics

At this point in the diagnostic workup, the practitioner should feel relatively comfortable delineating if the patient has a small or large intestinal lesion and if surgical intervention is warranted. However, in cases for which the cause remains idiopathic, the primary etiologies to consider include endoparasitism, equine gastric ulcer syndrome, and spasmodic colic (along with less common etiologies that will not be discussed in this review); the only definitive diagnostic procedure for equine gastric ulcer syndrome is a full gastroscopic examination after an appropriate fasting period to allow visualization of the entire stomach with a flexible endoscope. Additionally, it is important to realize that spasmodic colic is a diagnosis of exclusion; there is no definitive diagnostic test for spasmodic colic. However, an empirical clinical response to spasmolytic agents (more specifically butylscopolamine bromide) may be supportive of a diagnosis of spasmodic colic. Finally, the clinical assessments and diagnostics mentioned herein possess significantly higher diagnostic sensitivity and specificity when performed in serial fashion, as opposed to interpretation of the values at a single time point or in parallel. Therefore, the practitioner should be encouraged to repeat all or part of the examination and diagnostics as the clinical picture evolves.

5. Case Management

If a surgical lesion is identified and the patient is determined to be a surgical candidate, the colic team should initiate preparing for exploratory laparotomy, and the patient should be triaged accordingly to make them the best anesthetic candidate possible considering the clinical circumstances. The single most important indication for surgical intervention is unrelenting pain that is unresponsive to appropriate sedation and analgesia (even in the absence of other suggestive findings on the colic examination). Nevertheless, only a small percentage (approximately 1.4%–17.5%, and in the author's experience it is toward the lower end of these values) of horses with colic require surgical intervention.[5] Regardless of the underlying cause of the patient's abdominal pain, it is indicated to withhold feed until the patient is comfortable and passing feces for an extended duration of time, which will vary depending on the setting, the patient, and the underlying medical issue. Nonsurgical (or postsurgical) management of the acute abdomen case typically includes sedation, analgesia, and fluid therapy.

Sedation and Analgesia

The mainstays of sedation are alpha-2 agonists, of which xylazine hydrochloride administered intravascularly is often the preference. Many practitioners elect to avoid the routine use of detomidine hydrochloride due to its longer duration of action and a higher propensity to mask more severe pain that may require surgical intervention. The author routinely administers 150 mg of xylazine hydrochloride to a standard 454- to 500-kg adult horse (approximately a 0.3 mg/kg dose). Additionally, it is commonplace to coadminister butorphanol tartrate intravascularly with xylazine hydrochloride. The author normally administers 5 mg to a standard 454- to 500-kg adult horse (approximately a 0.01 mg/kg dose); however, many practitioners argue to avoid using opioids for

those same reasons mentioned for avoiding the use of detomidine. Another class of medication commonly administered to patients with abdominal discomfort are parasympatholytic medications, namely N-butylscopolammonium bromide administered intravascularly. Some practitioners avoid its use due to the concern that abolition of smooth muscle contraction might be counterproductive to the overall clinical picture; however, the author commonly administers 100 mg to a standard 454- to 500-kg adult horse (approximately a 0.2 mg/kg dose) to not only facilitate the rectal examination but also assess the likelihood of spasmodic colic and as a temporary source of pain relief and is pleased with the results. An additional class of medications that can assist in the management of the equine acute abdomen is NSAIDs, of which the primary drugs include flunixin meglumine, phenylbutazone, and dipyrone. There is an adage amongst equine practitioners that flunixin is preferable to phenylbutazone for soft tissue or visceral pain, whereas phenylbutazone is preferable for orthopedic pain. Thus, it is more commonplace to administer flunixin for management of the acute abdomen, which is generally administered at a 1.1 mg/kg dose intravascularly. It is ill-advised to "stack" NSAIDs (meaning using two different NSAIDs concurrently, such as coadministration of flunixin meglumine and phenylbutazone) as doing so (especially in the face of dehydration) will increase the risks of negative side effects such as renal toxicity, right dorsal colitis, and gastric ulceration. An additional medication within this drug class is dipyrone.[a] Dipyrone is currently marketed in the United States and carries a label for control of fever. Dipyrone was previously available in the United States prior to its more recent release and was commonly administered for analgesia. Historically, the drug was employed in human medicine for fever and visceral pain but was removed from the market due to agranulocytosis; however, it is still routinely used in human medicine for visceral pain in other countries. There is a paucity of data, particularly in the recent literature, describing dipyrone use in horses for visceral pain. Furthermore, to the author's knowledge, the complete mechanism of action of dipyrone's antinociceptive pathways in the horse has yet to be fully elucidated. The company under which dipyrone is currently marketed also states that it too should not be stacked with other NSAIDs and/or corticosteroids. Anecdotally, however, many practitioners are utilizing dipyrone for equine patients experiencing signs of colic at a dose of 20 to 30 mg/kg intravascularly up to every 12 hours as needed for control of pain. Until adequate evidenced-based data exist to support this use, the author cannot recommend its use for horses with colic. A final drug frequently used for analgesia in the equine acute abdomen is 2% lidocaine hydrochloride. The efficacy of lidocaine as a promotility agent in horses has variably been called into question; also, the use of a loading dose prior to constant rate infusion (CRI) remains controversial. It is important to note that lidocaine has been used not only for analgesia but also as a general anti-inflammatory and as a prokinetic. A full review of prokinetics for use in horses is beyond the scope of this review, yet the author feels it to be pertinent to provide background on the use of a 2% lidocaine CRI for analgesia as his experience has provided positive results. If a loading dose is administered, a dose of 1.3 mg/kg administered intravascularly over 15 minutes should be used, followed by a CRI rate of 0.05 mg/kg/minute. Due to the risk of neurotoxicity, lidocaine should be administered as a CRI with other fluids, and the rate should be administered carefully.

Fluid Therapy

A complete review of fluid therapy is beyond the scope of this review; however, outlined herein are some general guidelines the author follows for the acute abdomen. Fluid therapy is indicated in the presence of hemoconcentration or a palpable impaction on rectal examination and/or for those patients being prepared for exploratory laparotomy. The two primary means by which to provide fluid therapy are enteral fluids and intravenous fluids; however, a third option of rectal administration of fluids has recently been validated for use in horses and provides an intriguing and cost-effective means of fluid administration.[6]

Enteral Fluid Therapy

For horses with palpable colonic impactions on rectal examination, enteral fluids are the preferred fluid administration route as these have been shown to be superior to intravenous fluids for hydrating colonic contents.[7] Contraindications for enteral fluid therapy include a strangulating small intestinal lesion, the presence of net gastric reflux on nasogastric intubation, intolerance of enteral fluids (discomfort upon administration of enteral fluids), and recumbency. Enteral fluid administration rates of 6 L every 2 to 4 hours in the 454- to 500-kg adult horse are generally safe and well tolerated. As important as the rate of fluid administration is the composition of the administered fluid. Mineral oil has been previously recommended for enteral administration in equine patients with colic. However, to the author's knowledge, there is a paucity of scientific literature supporting its use; moreover, the ability of mineral oil to hydrate impacted ingesta within the colonic lumen is far less than that of other enterally administered medications. Additionally, mineral oil, if aspirated, induces severe and often fatal pneumonia. Last, mineral oil is considered by some practitioners to be contraindicated for surgical candidates and in some toxicities.[8] Other medications administered per nasogastric tube as part of an enteral fluid therapy plan are electrolytes and magnesium sulfate. Magnesium sulfate at 1 g/kg of bodyweight may be administered and is quite efficacious;[9] however, the author recommends limiting this to a maximum of twice daily due to the propensity to induce diarrhea and potential magnesium toxicosis.[10] A variety of commercial electrolyte products are widely available for use in horses. If a product is used that contains a separate package for dextrose, as

many do, it is inadvisable to administer this portion of the product as it is not necessary, and the addition of excess glucose can be detrimental due to potential iatrogenic hyperglycemia and a subsequent hyperinsulinemia. The electrolyte portion of these products should be administered according to the manufacturer's recommendations. Furthermore, there are a few different means by which to improvise CRI of enteral fluids using either a nasogastric tube or enteral feeding tube with a Christmas-tree connector, carboy, and standard coil set.

Intravenous Fluid Therapy

Indications for intravenous fluid therapy include hemoconcentration, preparation for exploratory laparotomy, intolerance of enteral fluids, and correction of electrolyte and acid-base imbalances, amongst others. For patients requiring intravenous fluid therapy due to moderate or marked hemoconcentration, 7.2% hypertonic saline is a very effective means by which to expand the intravascular volume and quickly improve cardiac output;[11] however, it is important to note that hypertonic saline must always be followed with polyionic isotonic crystalloids. A full review of fluid types and fluid therapy is beyond the scope of this review. However, general guidelines the author employs for standard use of polyionic isotonic crystalloids for the dehydrated acute abdomen are to follow the "3 Ps" of resuscitation—namely pink, perky, and pee. Shock boluses of 30 mL/kg are administered until either (a) the patient's mucus membranes are pink and moist; their mentation is bright, alert, and responsive in the absence of signs of colic; and they are urinating normally or (b) a total of 90 mL/kg have been administered. Following emergency resuscitation, it is commonplace to administer polyionic isotonic crystalloids at approximately twice maintenance rate (4 mL/kg/h) for the first 6 to 24 hours. Subsequent fluid therapy depends upon response to initial treatment. Moreover, it should be stated that intravenous and enteral fluid therapy can be used concurrently; this combination is a very rapid and effective means by which to achieve both systemic and local enteral rehydration.

Cecal Trocarization

A final intervention for medical management of the acute abdomen of which the practitioner should be aware is cecal trocarization. Cecal trocarization should be reserved for those patients who do not have a surgical option and whose owners have been adequately counseled regarding the potential complications, which include focal abscessation, peritonitis, and hemorrhage. The main indication for cecal trocarization includes abdominal gas distension that is otherwise unable to be relieved in a nonsurgical candidate; this technique can be especially useful for right dorsal displacements of the large colon and small colon impactions. The full methodology for performing the procedure is described elsewhere,[12] but briefly: The horse is restrained, sedated, and clipped and the skin aseptically prepared in the right paralumbar fossa, and an ultrasound is performed on the area to ensure the safety of the procedure (i.e., no other segments of gastrointestinal viscera trapped between the base of the cecum and the body wall) and to triangulate the gas cap on the cecal base. Following subcutaneous instillation of a local anesthetic (either 2% lidocaine or mepivacaine), the cecum is then trocarized at its base at an approximately 45° angle to the skin with a standard 14-gauge 5.25-in over-the-needle intravenous catheter attached to a 30-in extension set of which the opposing end is submerged in water. Once the release of gas has ceased (as evidenced by gas bubbles no longer being visible in the cup of water), the trocar is removed; the author also prefers to infuse a 3.3 mg/kg dose of gentamicin while the trocar is being removed to reduce risks of peritonitis and abscessation.

6. Conclusion

While colic is a common condition presented to the equine practitioner, few patients undergo surgical intervention. Additionally, it can be distressing for owners and veterinarians, but being prepared and knowledgeable regarding both the workup and the management of the equine acute abdomen can facilitate positive patient and client outcomes. Performing and interpreting diagnostics both quickly and competently will facilitate rendering a proper diagnosis and subsequently appropriate management in a timely fashion.

Acknowledgments

The Author wishes to thank his friend and mentor, Dr. Laszlo Hunyadi, the moderator for the session, for his cordial invitation to speak on the topic, as well as the American Association of Equine Practitioners for the opportunity to speak at this session. The author also wishes to provide the utmost gratitude to all his mentors throughout his career thus far for providing the knowledge base and skill set required to present on this topic. Last, the sincerest appreciation is extended to all those involved in the peer review of these proceedings to ensure its accuracy and usefulness.

Declaration of Ethics

The Author has adhered to the Principles of Veterinary Medical Ethics of the AVMA.

Conflict of Interest

The Author has no conflicts of interest.

References and Footnote

1. Bowden A, Burford JH, Brennan ML, et al. Horse owners' knowledge, and opinions on recognising colic in the horse. *Equine Vet J* 2020;52:262–267.

2. Davis JL, Blikslager AT, Catto K, et al. A retrospective analysis of hepatic injury in horses with proximal enteritis (1984–2002). *J Vet Intern Med* 2003;17:896–901.
3. Gardner RB, Nydam DV, Mohammed HO, et al. Serum gamma glutamyl transferase activity in horses with right or left dorsal displacement of the large colon. *J Vet Intern Med* 2005;19:761–764.
4. Kilcoyne I, Nieto JE, Dechant JE. Predictive value of plasma and peritoneal creatine kinase in horses with strangulating intestinal lesions. *Vet Surg* 2019;48:152–158.
5. Freeman DE. Fifty years of colic surgery. *Equine Vet J* 2018;50:423–435.
6. Khan A, Hallowell GD, Underwood C, et al. Continuous fluid infusion per rectum compared with intravenous and nasogastric fluid administration in horses. *Equine Vet J* 2019;51:767–773.
7. Lopes MAF, Walker BL, White NA II, et al. Treatments to promote colonic hydration: Enteral fluid therapy versus intravenous fluid therapy and magnesium sulphate. *Equine Vet J* 2002;34:505–509.
8. Qualls HJ, Holbrook TC, Gilliam LL, et al. Evaluation of efficacy of mineral oil, charcoal, and smectite in a rat model of equine cantharidin toxicosis. *J Vet Intern Med* 2013;27:1179–1184.
9. Lopes MA, White NA, Donaldson L, et al. Effects of enteral and intravenous fluid therapy, magnesium sulfate, and sodium sulfate on colonic contents and feces in horses. *Am J Vet Res* 2004;65:695–704.
10. Henninger RW, Horst J. Magnesium toxicosis in two horses. *J Am Vet Med Assoc* 1997;211:82–85.
11. Tavanaeimanesh H, Dezfouli MR, Vajhi A, et al. The effect of 7.2% hypertonic saline solution on echocardiographic parameters of healthy horses. *Equine Vet J* 2015;47:741–744.
12. Schroeder EL, Gardner AK, Mudge MC. How to perform a percutaneous cecal or colonic trocarization in horses with severe abdominal tympany. *J Vet Emerg Crit Care* 2022;32:57–62.

[a]Zimeta®, Dechra, Overland Park, KS 66211.

The Equine Neurologic Exam

Sally DeNotta, DVM, PhD, DACVIM*; and Rob MacKay, BVSc, PhD, DACVIM

With a bit of practice and a systematic approach, equine practitioners can become proficient in performing complete neurologic exams in both the field and hospital settings. Neurologic exam findings are essential for neuroanatomic localization and serve as the basis for formulation of a differential list and diagnostic plan in horses presenting with neurologic abnormalities. Authors' address: University of Florida College of Veterinary Medicine, Gainesville, FL 32608; e-mail: s.denotta@ufl.edu. *Corresponding and presenting author. © 2022 AAEP.

1. Introduction

A complete neurologic examination can be compared to lameness evaluation—a systematic approach involving an initial stationary examination followed by gait assessment (a sample examination form can be found in the Appendix). The only equipment needed is a transilluminator (or smartphone flashlight) and hemostat. The neuro exam is used to localize a lesion or lesions and serves as the basis for formulation of a differential list and diagnostic plan. Information regarding cranial nerve assessment, anatomic neurolocalization and ataxia grading has been provided in Tables 1–3, and an example Neuro Exam Checklist has been provided in Appendix I. In this discussion, all potential abnormal findings are interpreted in the context of a neurologic examination. However, in a clinical setting, complete general physical and lameness examinations should also be performed to assess possible involvement of other body systems.

2. Mentation and Behavior

Assess level of consciousness or alertness on a continuous scale from normal (i.e., bright and alert) to comatose. Progressive levels of obtundation are termed lethargy, stupor, semicoma, and coma. Abnormalities of behavior are termed *dementia*. Behavior is assessed from history and general observation in the course of the examination. Typical abnormal behaviors resulting from central nervous system disease include self-mutilation, head pressing, compulsive walking (often in a circle), yawning, aggression (including unprovoked biting or kicking), timidity, loss of affinity of a foal for its dam, and loss of learned behaviors and skills.

3. Examination of the Head

Head Orientation

Evaluate the orientation of the head from directly in front. Asymmetric disease of the vestibular system (cranial nerve [CN] VIII, brainstem) causes the head to tilt, whereas asymmetric cerebral disease may cause the head and neck to turn *without* tilting. Carefully blindfold the horse and observe the effect on head position. Blindfolding removes visual input to head position and exacerbates abnormalities caused by either vestibular or cerebral disease. Because of

NOTES

Table 1. Cranial Nerves

		Function	Signs of Dysfunction
I	Olfactory	Smell	Difficult to assess in horses
II	Optic	Vision	Blindness, loss of menace and pupillary light reflex
III	Oculomotor	Extraocular muscles, pupillary light reflex	Abnormal pupillary light reflex, strabismus
IV	Trochlear	Extraocular muscles	Dorsomedial strabismus
V	Trigeminal	Muscles of mastication, sensory to face	Muscle atrophy; jaw weakness; loss of sensation over ears, face, nares
VI	Abducent	Extraocular muscles	Strabismus
VII	Facial	Muscles of facial expression, parasympathetic input to salivary and lacrimal glands	Asymmetric expression/ears, deviated muscle, weak eyelid tone, dry eye
VIII	Vestibulocochlear	Hearing, posture, and balance	Deafness, head tilt, loss of coordination and balance, nystagmus
IX	Glossopharyngeal	Motor and sensory to pharynx	Dysphagia, inability to swallow, displaced soft palate
X	Vagus	Motor and sensory to pharynx/larynx	Dysphagia, inability to swallow, displaced soft palate
XI	Accessory	Cervical muscles	Cervical muscle atrophy
XII	Hypoglossal	Tongue muscle	Tongue weakness and atrophy

Table 2. Basic Neurolocalization

Lesion Location	Clinical Signs
Forebrain	Abnormal mentation, changes in behavior, seizures
Brainstem	Abnormal mentation, cranial nerve deficits, ataxia
Cerebellum	Spastic, uncoordinated movement; head (intension) tremors; loss of menace response.
Vestibular System	Loss of balance; circling, leaning, falling; head tilt, nystagmus
Spinal Cord: C1–C5/6	Normal mentation, ataxia in all 4 limbs (often more severe in hind limbs)
Spinal Cord: C6–T2	Normal mentation, weakness in forelimbs, ataxia in hind limbs
Spinal Cord: T3–L3	Normal mentation, normal forelimbs, ataxia in hind limbs
Spinal Cord: L4–S2	Normal mentation, normal forelimbs, weakness in hind limbs
Spinal Cord: S2–caudal	Cauda equina syndrome: muscle atrophy, decreased tail and anal tone/sensation, urinary incontinence, fecal retention

Table 3. Mayhew's Grading Scale for Ataxia

GRADE 0:	Normal strength and coordination
GRADE 1:	Subtle neurological deficits noted under certain conditions; e.g., while circling
GRADE 2:	Mild neurological deficits apparent at all times/gaits
GRADE 3:	Obvious neurological deficits apparent at all times/gaits
GRADE 4:	Severe deficits with tendency to buckle, stumble spontaneously, and/or fall
GRADE 5:	Recumbent, unable to stand

the close proximity of cranial nerves VII and VIII, facial paralysis is often seen in horses with vestibular disease. Offer feed or a treat to the horse and observe the way in which the horse moves its head in response. Coarse or fine head bobbing, especially intentional, indicates diffuse cerebellar dysfunction.

Facial Expression, Sensation, and Muscle Symmetry

Examine the head carefully for symmetry of facial expression, particularly with respect to the ears, eyes, and muzzle. With unilateral facial paralysis (CN VII), there is drooping of the ear and lower lip and immobility, narrowing, and lengthening of the affected external nare. The muzzle is deviated away from the affected side, and saliva may drool from the mouth. In some horses, there also is mild ptosis.

Evaluate sensory branches of the trigeminal nerve (CN V) and facial nerve motor function by testing "flick" reflexes on each side of the face. Each of these reflexes requires intact trigeminal sensory branches, central connections in the hindbrain, as well as functioning facial nerves. To test these reflexes, touch in turn the commissure of the lips, the medial and lateral canthi of the eye, the supraorbital fossa, and the ear. Appropriate responses are retraction of the commissure of the lip, blinking of the eye (medial and lateral canthi and supraorbital fossa), and flick of the ear, respectively. It is helpful to have the handler cover the ipsilateral eye during testing of the lip and ear. Further assess the sensory branches of the trigeminal nerve (CN V) by firmly poking the nasal septum. The normal response to this noxious stimulus is vigorous movement of the head away from the side of the stimulus. Compare the intensity of responses on each side. Trigeminal nerve dysfunction results in ipsilateral deficits in both motor and/or sensation, while horses with unilateral forebrain disease may lose sensation to the contralateral side of the face.

Menace Response

Stand in front of the horse, hold the halter noseband with one hand, and use the palm of the other hand to make a threatening gesture toward the eye. Test from both temporal and nasal directions on each side. Stimulate the horse just before each menace gesture by tapping the skin below the eye. A normal menace response is blinking of the eye.

The menace response can be interrupted anywhere in its pathway from the eye via the optic nerve (CN II) to the contralateral optic tract, diencephalon, internal capsule, and visual cortex. From the visual cortex, the menace response pathway continues to the facial nucleus and nerve (CN VII) on the side being tested probably after passage through the ipsilateral cerebellum. Normal neonates and horses with cerebellar cortical disease may lack menace responses despite having normal vision. In these settings, vigorous threatening gestures toward the eye may cause evasive movements of the head without blinking of the eye.

Pupil Size and Pupillary Light Reflex

First, examine the eyes in neutral light conditions and determine whether or not the pupils are of equal size and if the diameter of each pupil is appropriate for the conditions. Unequal pupillary size is termed *anisocoria*, a constricted pupil is *miotic*, and a dilated pupil is *mydriatic*. Next, examine the eyes in subdued or dim light so that the pupils are large enough to easily allow appreciation of reflex constriction. Aim the light at the skin below one eye. Redirect the beam directly into the eye. This strong light should elicit both a *dazzle* reflex in the ipsilateral eye and pupillary light reflexes in both eyes. The dazzle response is an avoidance reaction to bright light. There is blinking, retraction of the eyeball, and movement of the head away from the light. A normal pupillary light reflex is immediate equal constriction of the pupils of both eyes in response to light directed into one eye. If the direct (i.e., ipsilateral) pupillary light reflexes are normal on both sides, no further testing is necessary. If one is abnormal, then consensual (indirect) reflexes should be tested. To perform the consensual reflex, watch the pupil in one eye while an assistant shines the light into the opposite eye.

Position and Movement of the Eyeballs

While continuing to stand in front of the horse, observe the position and size of the pupils while the head is held level (i.e., a line through the center of each eyeball is parallel to the ground). While keeping the head level, lift the chin slowly. The eyeballs should remain stationary while the chin moves upward; thus, the eyes rotate ventrally *relative* to the long axis of the head. In horses with vestibular disease (CN VIII), abnormal eye positions are exaggerated by this maneuver.

In horses with strabismus, the eyeball may be rotated medially or laterally, clockwise or counterclockwise. If the pupils are in abnormal positions, try to position the head in such a way (usually by rotation) that the pupils are normally oriented relative to the transverse axis of the head. For example, a horse with vestibular disease usually has ventral deviation of the eyeball on the side of the lesion and dorsal deviation on the opposite side. In horses with *vestibular strabismus*, eye position can be normalized relative to the axis of the head simply by rotating the head in the direction of the ventrally deviated eye. True strabismus is eye deviation that cannot be corrected by repositioning the head and usually reflects dysfunction of nerves to the extraocular muscles (i.e., oculomotor, trochlear, or abducens nerves [CNs III, IV, VI]).

Move the horse's head in a horizontal arc from side to side and observe the movements of the eyeballs. Signs of *physiologic nystagmus* should normally be elicited—namely, a series of horizontal movements of the eyeballs consisting of a rapid phase in the direction of head movement followed by a slow phase in the opposite direction. Each fast phase is accompanied by an eyelid blink. Physiologic nystagmus is normal and should be distinguished from eye movements characteristic of vestibular disease: *spontaneous* nystagmus, which occurs when the head is stationary and in a neutral position, and *positional* nystagmus, which only occurs when the head is moved to certain positions. In horses with asymmetric vestibular disease, physiologic nystagmus often is abnormal or absent when the head is moved toward the side of the lesion. With peripheral vestibular disease, there often is spontaneous horizontal or arc-shaped nystagmus with the fast phase directed away from the side of the lesion. In horses with involvement of the central components of the vestibular system, there may be horizontal *or* vertical nystagmus.

Assess abducens nerve (CN VI) function by performing a *modified corneal* reflex. Hold the eyelids closed and, through the eyelid, push the eyeball medially. The normal response to this maneuver is retraction of the eyeball. This reflex requires intact sensory branches of the trigeminal nerve (CN V), central connections in the hindbrain, and motor fibers of the abducens nerve (CN VI).

Swallowing

It is difficult to assess competence for swallowing during a physical examination. On the basis of history and observation, note whether feed, water, or saliva return through the nose, especially when the horse eats or drinks. Dysphagic horses often cough when eating or drinking and may be initially misdiagnosed as chokes. Pass a nasogastric tube into the pharynx and assess effectiveness of swallowing movements as the horse attempts to move the tube into the esophagus. Involvement of the nucleus ambiguus in the hindbrain or peripheral parts of the glossopharyngeal (CN IX) and/or vagus (CN X) nerves can cause dysphagia. These nerves are particularly vulnerable to damage as they pass in folds of the guttural pouches.

Tongue

Pull the jaws slightly apart and observe the movements of the unrestrained tongue. With acute

unilateral weakness, the tongue curls toward the unaffected side. Grasp the tongue from one side after inserting the hand through the interdental space. Note resistance of the tongue to being stretched and look for atrophy and muscular fasciculations (CN XII). Gently pinch the side of the tongue with a hemostat and look for reflex retraction (CN V). Pull the tongue out one side of the mouth, release it, and look for retraction of the tongue back into the mouth. In normal horses, one or two chewing movements occur as the tongue is quickly retracted. Delayed or absent retraction of the tongue back into the mouth can occur with hypoglossal nerve (CN XII) dysfunction, neuromuscular weakness (especially botulism), or obtundation from cerebral disease.

4. General Examination of the Neck, Trunk, and Limbs

Examination

With the horse standing squarely, assess muscle mass, paying particular attention to asymmetries. Note any circumscribed or asymmetric areas of sweating. Firmly press the cranial edge of each of the cervical transverse processes from C3 to C6 on each side to test for a pain response. Put pressure on the C6 and C7 intervertebral joints by pushing medial to the deep pectoral muscle in front of the shoulder on each side. Test lateral neck flexion by enticing the horse to move its head toward feed held at the point of the elbow, and then the point of the hip. Neck pain revealed by palpation or reluctance to turn laterally may follow any neck trauma but usually reflects arthritis of intervertebral joints. Press down firmly on each section of the thoracic and lumbar epaxial muscles to evaluate for back pain.

Severe or rapidly developing muscle atrophy indicates denervation and is a localizing sign. Neurogenic muscle atrophy is caused by damage to the lower motor neuron in the ventral column of the gray matter, nerve roots, or peripheral nerves supplying that muscle. Neurogenic atrophy of thoracic limb musculature results from lesions of the C6 to T2 spinal cord segments or roots, brachial plexus, or peripheral nerves, while atrophy of pelvic limb muscles reflects involvement of L3 to S2. Anesthesia of a strip of skin is caused by loss of the segmental sensory nerve, dorsal nerve root, or connections in the spinal cord. Because sympathetic fibers are distributed with spinal nerves, spontaneous sweating may occur over denervated skin.

Cervicofacial Reflex

Place the left index and middle fingers at the commissure of the left lip, and then strike the skin over the brachiocephalicus muscle with the closed tip of the hemostat. Begin at the cranial end of the neck and continue back to the shoulder. The expected response is facial contraction, detected as retraction of the commissure of the lip, and contraction of the brachiocephalicus and cutaneous colli, observed as shrugging of the shoulder, lateral jerking of the head, and twitching of the skin of the neck. This reflex typically is reduced at the level of a cervical spinal cord lesion but is normal cranial and caudal to the lesion.

Slap (Thoracolaryngeal) Test

While standing on the left side, reach under the horse's neck and hook the index and middle fingers of the left hand over the highest palpable point of the larynx—the muscular process of the arytenoid. Have the handler move the head slightly to the left of midline, and then gently strike the horse behind the withers several times with the palm of the right hand. The expected response is slight palpable movement (adduction) of the arytenoid in response to each slap. Repeat the procedure from the right side.

Sensory input to this reflex is the sensory nerves and roots under the area that is slapped (approximately T7–T11). Central pathways are thought to cross to the other side at this level and pass rostrally to the nucleus ambiguus in the white matter of the spinal cord, and then efferent fibers pass out in the vagus nerve via the recurrent laryngeal nerve to innervate the contralateral laryngeal adductor muscles. Severe cervical spinal cord disease often affects this test bilaterally, and the vagus and recurrent laryngeal nerves may be affected at the guttural pouch or within the jugular groove.

Cutaneous Trunci Reflex (Panniculus)

To elicit the panniculus reflex, use the thumb to firmly prod the lateral thoracic wall, beginning cranially just behind the shoulder and extending caudally to the last intercostal space. Check every intercostal space both ventrally and dorsally. For safety, firmly grasp the back of the mane with the left hand and face backward when testing the reflex because horses that resent this test will try to kick the examiner. Repeat on both sides of the horse. A normal response is twitching of the skin, with or without indication of conscious perception of the stimulus.

The reflex pathway is input from sensory thoracic nerves to the ipsilateral spinal cord, where it courses rostrally via interneurons to end in the C8 and T1 segments, and thence via the brachial plexus to the lateral thoracic nerve and the cutaneous trunci muscle. Interruption of this pathway in the spinal cord white matter results in loss of the reflex from approximately the point of the lesion caudally. A lesion of the sensory nerve will only affect the reflex within the same dermatome (skin strip), while loss of lateral thoracic nerve function ablates the entire ipsilateral reflex. Horses with botulism may display a generalized loss of panniculus reflex bilaterally.

Back Reflexes

Make sure that the pelvic limbs are positioned equally and squarely, and then stroke the closed tip of the hemostat caudally along the skin over the longissimus dorsi muscle, from mid-thorax caudally to the level of the tuber coxae. For safety, hold the back part of the mane with the other hand. The expected response is

brisk extension of the back and pelvis without disengagement of the stay apparatus of the pelvic limb, followed quickly by return to normal posture. Next, stroke the hemostat caudally along the skin over the gluteal muscles. This should elicit spinal flexion, followed by relaxation of the lumbar spine and pelvis, again without release of the patella from the medial femoral trochlear ridge. Common abnormal reactions to these tests include (1) partial collapse in the pelvic limbs, (2) wobbling of the pelvis from side to side, and (3) no response, all of which may be observed in horses with truncal and pelvic limb weakness and/or ataxia caused by spinal cord disease.

Tail and Anus

Assess tail strength by lifting (extending) the tail. Prod or pinch the skin adjacent to the anus and observe the anal contraction and tail-clamp reflexes. If these reflexes are abnormal or if the history suggests possible cauda equina syndrome, perform a rectal examination to assess rectal tone and bladder size and tone. Assess muscular symmetry of the tail and test cutaneous sensation over the tail and caudal structures.

Anesthesia and areflexia of the tail, penis, and perineum and paralysis of the anus, rectum, bladder, and penis are signs of cauda equina syndrome. Lesions of the spinal cord or nerve roots caudal to the S2 spinal cord segment cause some or all of the signs of cauda equina syndrome.

5. Gait Evaluation

Examination

Have the handler walk the horse in straight lines while keeping the horse's head and neck as straight as possible during walking. Follow directly behind the horse. From this vantage point, evaluate leg position and stride symmetry. Also, watch for excessive (1) side-to-side (wobbling) movement of the pelvis, (2) up-and-down movement of the tuber coxae (pelvic roll), and (3) side-to-side rotation of an imaginary line from the tailhead to the tuber sacrale (pelvic yaw). Next, watch the gait from the side while walking in stride with the pelvic and then thoracic limbs. Note any toe dragging, knuckling, stride-length asymmetries, and abnormal protractive movements such as hyperflexion, stiffness (hypometria), or excessive range of movement (hypermetria). Often, these signs are most obvious as the horse transitions from standing still to walking. Repeat this part of the examination with the horse's chin lifted and with the horse walking up and down a modest slope. These maneuvers exacerbate most gait abnormalities, especially stiffness of the thoracic limbs. Take extreme caution when walking ataxic horses up and down slopes as they are more likely to stumble or fall on uneven ground.

Back the horse briskly, observing for limb coordination and willingness to move backward. Normal horses should readily back in a straight line in two-beat fashion, with diagonal limb pairs moving in synchrony (e.g., left thoracic and right pelvic limbs). A horse with spinal cord disease may sag backward before moving and slide its hooves along the ground rather than picking them up and placing them.

Take the horse in hand for the next part of the examination. Hold the lead rope with the left hand and, by walking backward, lead the horse in counterclockwise circles. It is very important that the horse is always walking *forward* in these circles. Vary the diameter, making the circles alternately small and large. Carefully observe the motion of the right (outside) pelvic limb by looking under the horse's torso. This limb will often arc out widely on the outside of the circle (i.e., circumduction) in horses with spinal cord disease. In mirror-image fashion, lead the horse from the right side in clockwise circles.

Next, pull the horse sideways in *tight* circles in either direction. To do this, position yourself slightly behind the shoulder and walk backward while pulling the lead rope caudally and downward. The goal is to have the horse pivot around its center of gravity, with the forelimbs coming toward the examiner and the hind limbs moving away. If done correctly in normal horses, the opposite thoracic limb should cross in front of the supporting limb and the pelvic limbs should move reciprocally, causing the horse to pivot around a point midway between the thoracic and pelvic limbs. Horses that are weak and ataxic tend to sag backward in the hindquarters before they start to move and then pivot the front part of the body around one or both pelvic limbs. There is often also interference between or otherwise inappropriate placement of thoracic limbs. Horses with caudal neck pain will often display reluctance or refusal to cross one forelimb over the other.

Signs of limb weakness and ataxia suggest spinal cord (or, rarely, peripheral nerve) damage at or cranial to the affected limb. If there is obvious ataxia and weakness in thoracic *and* pelvic limbs, there likely is at least one lesion in the spinal cord somewhere between the front of the C1 and back of the T2 spinal cord segments. In cases where the signs are caused by external compression of the cervical spinal cord (e.g., cervical vertebral stenotic myelopathy), signs in the pelvic limbs are usually worse than those in the thoracic limbs. When, in such cases, the pelvic limb signs are mild, thoracic limbs may appear normal. In contrast, when thoracic limbs are normal but there is moderate or severe ataxia and weakness in the pelvic limbs, there likely is at least one lesion caudal to T2 and cranial to S3. If one or both thoracic limbs are abnormal in a horse that has normal pelvic-limb gait, the gray matter of the C6 to T2 spinal cord segments (without white matter involvement), the roots or nerves of the brachial plexus, or the peripheral nerves to the limbs are likely affected. Asymmetric lesions in the spinal cord cause signs that are more severe on the side of the lesion. Occasionally, there are signs of weakness without

ataxia (e.g., botulism, equine motor neuron disease) or ataxia without weakness (e.g., cerebellar abiotrophy, peripheral vestibular disease, equine degenerative myelopathy). Additional signs such as defective reflexes (cervicofacial, slap, or cutaneous trunci), neurogenic muscle atrophy, or cutaneous anesthesia often help to localize the spinal cord lesion.

Tail Pull

The tail-pull test is done both at rest and while the horse is walking in a straight line. With the horse standing squarely, take the tail and pull sideways with gradually increasing force. After initial slight movement in the direction of pull, normal horses usually cannot be moved sideways, even with strong pressure. Next, pull sideways on the tail while the horse is walking in a straight line. Normal horses of 450-kg bodyweight can only be moved slightly to the side. Perform the test in mirror-image fashion from the right side (i.e., with the horse being led from the right side).

If a full-sized adult horse can easily be pulled sideways at rest, there is likely a lesion located either in the ventral gray matter or roots (L3–L5) that form the femoral nerve or in the femoral nerve itself. The much more common finding is lack of resistance to tail pull only during walking and is often observed with ipsilateral spinal cord lesions affecting descending upper motor neurons anywhere from C1 to S2.

Hopping

The hopping test evaluates both proprioceptive function (spinocerebellar tracts, cerebellum) and limb-strength. From the left side, hold the halter with the left hand. Pick up the left leg, and then push the head toward the right side while leaning against the left shoulder. Normal horses use the right limb to hop briskly around a circle centered on the pelvic limbs. With limb weakness, the response may be delayed so that the horse leans markedly before hopping or the limb may buckle after landing.

Acknowledgments

Declaration of Ethics

The Authors have adhered to the Principles of Veterinary Medical Ethics of the AVMA.

Conflict of Interest

The Authors have no conflicts of interest.

Further Reading

- Furr M, Reed S. *Equine Neurology*, 2nd ed. John Wiley & Sons, 2015.
- Johnson A. How to perform a complete neurologic examination in the field and identify abnormalities, in *Proceedings*. Am Assoc Equine Pract 2010;56:331–337.

(continued on next page)

Appendix I. Neurologic Examination Checklist

Date: _____ Patient: _____

Clinician: _____

ATAXIA GRADE: _____

NEUROANATOMIC LOCALIZATION: _____

EVALUATION	STRUCTURES TESTED	NOTES
☐ Mentation		
○ Behavior	Forebrain	
○ Level of consciousness	RAS (brainstem) > forebrain	
☐ Posture	Forebrain, BS, SC, neuromuscular, PNS	
☐ Symmetry		
○ Head tilt?	VIII	
○ Facial expression	VIIm	
○ Chewing muscles ○ Jaw alignment	Vm	
☐ Eyes		
○ Menace response	II, contralateral forebrain	
○ PLR, dazzle	II, midbrain, III	
○ Eye position and drop	III, IV, VI, VIII	
○ Physiologic nystagmus	III, IV, VI, VIII	
○ Eye retraction0	Vs, III/VI	
☐ "Flick" reflexes	Vs, VII	
☐ Perception of touch		
○ Nares, Face, Ear	Vs, contralateral forebrain	
☐ Tongue tone and muscling Sensation	XII Vs	
☐ Swallowing/dysphagia?	IV, X, BS, neuromuscular	
☐ Muscle symmetry		
○ From back, sides, front	Muscles, spinal cord, PNS	
☐ Neck		
○ Lateral flexibility	Articular process joints, disks	
○ Sensation	Cervical SC and spinal nn	
☐ Long spinal reflexes		
○ Cervicofacial	Cervical nn, SC, VII	
○ Slap test	Thoracic nn, SC, X,RLN	
○ Cutaneous trunci	Thoracic nn, SC, lateral thoracic n	
○ Back reflexes • Lumbar • Sacral	Thoracolumbar SC, anti-gravity reflexes (LSI & nn, L4-S2)	

EVALUATION	STRUCTURES TESTED	NOTES
☐Tail tone and anal reflex	SC (S2-caudal)	
☐Straight-line gait		
○ From side and behind	SC, LSI BI & PNS	
○ Head elevated	SC, LSI, BI & PNS	
○ Tail pull: At rest At walk	LSI & PNS SC, LSI & PNS	
☐Circles		
○ Walking circles	SC, BS, BI & PNS	
○ Tight circles (pivots)	SC, BS, BI & PNS	
☐Backing	SC, BS, BI & PNS	
☐Hopping	SC, BS, BI & PNS	
☐Hills	SC, BS, BI & PNS	

RAS = reticular activating system; m = motor; s = sensory; RLN = recurrent laryngeal nerve; LSI = lumbosacral intumescence; BS = brainstem; SC = spinal cord; BI = brachial intumescence; nn = nerves; PNS = peripheral nervous system

Mechanical Objectives: Simplifying the Approach to Equine Podiatry

Britt Conklin, DVM

Identifying opportunities for the application of five mechanical potentials within a prescriptive therapeutic shoeing plan represents a simplified approach to equine podiatry. Therapeutic shoeing can take on many forms, from traditional styles and modifications to a whole host of pedal appliances aimed at therapy. It is essential to understand that therapeutic shoeing and its pedal modifications alter the mechanical forces of leverage, tension, pressure, protection, and stabilization. Author's address: Texas Tech University School of Veterinary Medicine, 7671 Evans Drive, Amarillo, TX 79106; e-mail: britt.conklin@ttu.edu. © 2022 AAEP.

1. Introduction

Farriery in the horse is routinely executed for three broad reasons: protection, modification of traction, and therapy. The first two categories can be irrespective of a veterinarian's skillset but the third requires a diagnosis. The activity by which a veterinarian elucidates a musculoskeletal or pedal pathology, combined with prescriptive therapeutic shoeing, can be represented as equine podiatry. When dealing with the structural enigma of the foot, a regional anatomical diagnosis, and various farrier skillsets, pedal treatments often become empirical and based on the previous experience of the clinician or farrier.[1] Additionally, with the advent of many "therapeutic" shoe designs, styles, composites, and shapes, a preoccupation on the appliance rather than the reason for its application can be an inherent impediment to successful therapy. Veterinarians, who are not farriers, may be more comfortable with the diagnostic component of the process and can simplify the prescriptive component by focusing on five available mechanical modifications. Understanding there are only a limited number of mechanical adjustments that can be made to the equine foot, one can develop a mechanical shoeing prescription that can be matched to an array of effective pedal appliances.[2] Much has been said regarding structure and function in the digit as it relates to force, load, and motion.[3,4,5] Additionally, much has been said regarding shoeing management as therapy for different diseases of the equine digit.[6,7,8] The purpose of this article is to simplify one's approach to equine podiatry by focusing on the desired mechanical objectives and not the appliance. This approach can simplify prescriptive communications on podiatry with the farrier.

Spatial Geometry/Physics

It is important to realize that the foot can be modified in three directions: proximal/distal, medial/lateral, dorsal/palmar (or up and down, side to side, and front to back). Spatially, these and in varying

NOTES

vector combinations are the only directions the position of the digit can be altered.

The foot in the horse is static, kinematic, and dynamic. It is static in the stance phase and moves secondary to forces applied from within. It is also subject to outside external forces dictated by its structure and the physical laws of nature. To function properly, the foot of the horse must be in anatomic balance with itself, these external forces, and in equilibrium with its own physiology. An example of a disruption of this homeostasis is laminitis; whereby, internal physiological equilibrium is compromised causing architectural structural failure resulting in disproportionate vector movements of anatomy. This is an important concept to realize when dealing with high scale cases. If the normal constructs of the hoof wall/sole (epidermis) are dissociated with the internal structures (bone/dermal), then a mechanical modification to the external structure will have limited ability to recover the internal physiological equilibrium.

Anatomy of the Digit

The foot can be evaluated in near perfect symmetry in the median plane. In the transverse plane, the foot can be divided into dorsal and palmar/plantar components. The dorsal component consists of the more rigid tubular capsule, dorsally and laterally, while the palmar/plantar component is made up of softer more elastic structures. This palmar/plantar makeup is helpful to dissipate concussive energy through expansion while the dorsal component is essential in shear load bearing and force transduction.[5] Within the hoof capsule, the foot is composed of dermal tissue which contains the vascular and nerve supply, 11 ligaments, 2 tendons, the digital cushion, a synovial joint, a bursa and 2 bones. In addition, the collateral cartilages attach within the foot but have wing-like extensions above the coronary groove.[9]

The hoof capsule is the epidermal extension of the skin separated by a junction called the coronet and is made up of three main parts: wall, sole, and frog each having different viscoelastic properties. Topographically, the wall can be divided into toe, quarters, and heels. At the heel, the hoof wall is reflected dorsally like a hook at an acute angle to form the bars. The sole forms most of the ventral surface of the foot and the junction in which the wall laminae and the sole epidermis meet is called the "white line". The frog is wedge shaped and is located in between the bars and completes the sole of the foot. It is the epidermal covering of the digital cushion.

Moving from external to internal past the tubular horn, the epidermal lamellae of the hoof meet with the dermal lamellae of PIII in an inter-digitating fashion to form a complex lamellar interface. This interface is continually remodeling to allow the horny wall to grow towards the ground surface past the stationary distal phalanx. It also suspends the distal phalanx within the hoof capsule. There are many soft tissue structures associated with the palmar/plantar portion of the foot, but this discussion will be limited to the anatomy of those areas most affected with pathology. Principally they are the deep digital flexor tendon (DDFT), collateral sesamoidean ligaments (CSL), distal sesamoidean impar ligament (DSIL), collateral ligaments (CL) of the distal interphalangeal joint (DIPJ), fibrocartilage of the navicular bone, navicular bone (NB), synovial membrane of the DIPJ, and synovial membrane of the navicular bursa.[10] A critical understanding of the form and function of these structures and how they are affected by external manipulation is essential when developing a mechanical shoeing prescription.



Fig. 1. A moving foot with reduced leverage at the toe depicting leverage attenuation in the placement and the modification of the shoe. Note the shoe is set back off the toe and rockered at the ground surface.

2. Manipulation of the Digit

With a general understanding of the functional anatomy of the foot and given that mechanical changes can be made in three spatial planes, there are five therapeutic alterations that we can either increase or decrease. They are leverage, tension, pressure, protection, and stabilization.

Leverage

Leverage is most often identified in horizontal spatial planes and evaluated from dorsal to palmar and medial to lateral. In practice, one can either increase or decrease leverage. It has a direct relationship with tension, but leverage is generally appreciated as the foot begins to move. An example would be break-over. The static foot can't appreciate the reduction in leverage at its toe until it moves over it (Fig. 1). The therapeutic application of leverage can be modified: 1) in the trim, 2) in placement of the shoe on the foot, or 3) in modification of the shoe itself. Examples of shoes that modify leverage include toe extensions, lateral extensions, rolled toes, rocker toes, square toes, half round, rail shoes, roller motion shoes, heel extensions, bar shoes, bumped stock, commercialized shoes like: Natural Balance and PLR[a] shoes or any appliance that increases or decreases leverage (Fig. 2).

Fig. 2. Various pedal appliances that have modifications to reduce leverage at the toe.

Fig. 3. Various shoes that elevate the heels and reduce tension.

Tension

Tension is understood in relation to tensile anatomic structures. In practice the heels of the foot are often manipulated to alter tension. The deep digital flex or tendon is the anatomical structure to which most of the focus is given. Tension is generally manipulated by heel height and one study indicates that each 1 degree decrease in heel height can change the tension in the DDFT by 4%. Conversely, elevating the heels decreases the tension in the DDFT.[11] It should be noted that overzealous use of the foot as a mechanical tool can sometimes be harmful. As an example, wedging the foot can potentially be harmful to the hoof capsule at the heels.[12] Wedging loads the heel structure and focuses pressure to them by reducing the load sharing of the frog, bars and sole, and may be deleterious in weak or underrun heels. Examples of shoes that modify tension include wedged shoes, wedge pads, Patten shoes, Ultimate cuffs,[b] modified stock or material, and any device that raises or lowers the heels or alters toe depth (Fig. 3).

Pressure

Pressure is often synonymous with load or support and works by manipulating solar contact with the ground or the shoe. Pressure can be modified through trimming, shoeing, or artificial materials placed on the foot. In cases of artificial material, the density needs to be considered when adding pressure. The greater the density in an object, the more directly the ground force is transferred. Think of standing on a marble versus standing on a sponge. The marble transfers pressure in a direct line while the sponge dissipates force, based on its structure. Most of the composite materials today have differing shore densities. A shore 40 material is softer than a shore 60 material which is less dense than aluminum or steel.

Fig. 4. The shoes on the left increase pressure dependent on their material makeup. The shoes on the right reduce pressure by eliminating contact.

Examples of appliances that alter pressure are heartbars, pour pads, impression materials, heel plate/impression material combinations, lily pads, synthetic padded boots, frog plates, frog pads, beveled solar stock, or any other device that increases or decreases load (Fig. 4).

Protection

Protection is often considered in relationship to the sole of the foot, using devices that reduce the ground reaction force by inhibiting direct contact. Protection is used to limit damage to sensitive, diseased, or compromised tissues and is directed toward epidermal, dermal, bony, or soft tissue structures in the foot. The mitigation of pressure provides protection, but devices used specifically for protection can vary from those used for attenuating pressure. A simple form of protection might be the use of a pad to treat sole bruising. More complex forms of protection might include appliances that address pedal disease, or varying pathologies of the palmar foot.

The application of devices like plastic pads, leather pads, pour pads, hospital plates, heel plates, onion heels, z-bars, bandages, therapeutic boots, topical solutions, or casts are focused at providing some type of protection to specific areas in the equine foot (Fig. 5).

Fig. 5. Various shoes that provide protection to the foot.

Stabilization

The final force that can be attenuated in the foot is stabilization. Stabilization is simply adding some form of external coaptation to limit movement during loading and unloading of the digit. Various disease pathologies will require stabilization as a form of therapy and can include quarter cracks, wall defects, shear lesions, coffin bone or other fractures and some cases of laminitis. Foals will often fracture their coffin bone and the utilization of various cuffs, clips, or casts are forms of stabilization. Stabilization of cracks may be accomplished using wire apposition and materials such as fiberglass, kevlar, or acrylics.[c,d] Shoe modifications such as toe, side, or quarter clips are forms of stabilization, and the use of a foot cast provides rigid stabilization (Fig. 6).

Fig. 6. Various implementations of mechanical stabilization. The tongue depressor (in the lower left) is simply used as a spacer between the shoe and wall and is removed once the adhering material has set.

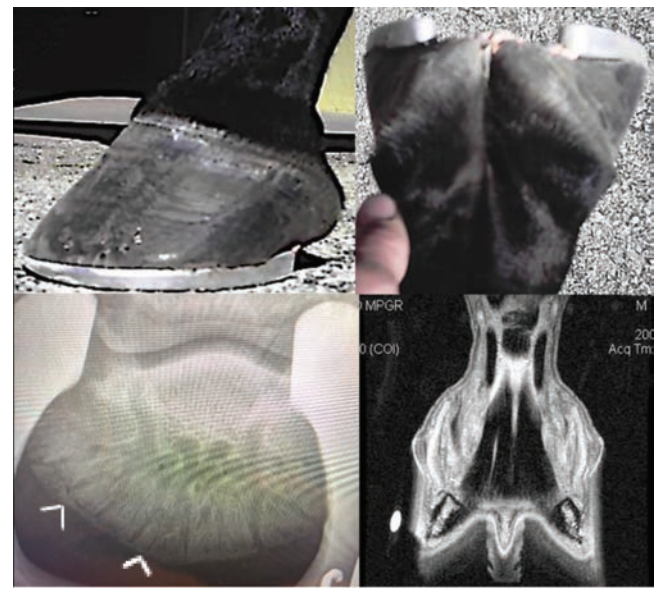

Fig. 7. A horse presenting with an underrun heel, minimal digital cushion, coffin bone rim fractures (arrows) and a linear tear in the lateral lobe of the deep digital flexor tendon (note the hyperintensity).

3. Clinical Application

Palmar Foot Pain

As mentioned earlier, a combination of alterations in leverage, tension, pressure, protection, and stabilization may be necessary to provide a therapeutic benefit. The example below reflects the thought combination applied in a case to all the mechanical potentials.

A nine-year-old Quarter Horse gelding presents with a chronic history of palmar foot pain. The horse has crushed heels and under-run pedal conformation with minimal digital cushion, blocks to a palmar digital nerve block, and is positive to testers across the heels. Radiographically the navicular bone is unremarkable, but there is noted pathology to the rim of the coffin bone likely secondary to compensated toe first landing. Additionally, magnetic resonance reveals significant navicular bone edema (hyperintensity), and a linear DDFT core lesion (Fig. 7).

Knowing there are capabilities to reduce tension in the DDFT with heel elevation, one might elect a wedge shoe. However, consequences of this action to the horse's heel structure will have to be considered. One may, therefore, elect to unload the heels, while maintaining elevation and transfer pressure to the sole/frog, to limit compromising heel integrity. This transfer of pressure may elicit a negative consequence due to the underlying palmar pathologies in the

Fig. 8. An example of a heel plate with underlying impression material, floated and elevated heels, protected palmar foot, a wide protected toe and reduced leverage as therapy for palmar foot pain. This shoe addresses leverage, tension, pressure, and protection.

navicular bone and deep flexor tendon. Patients with similar pathology are often positive to hoof testers across the frog and heel and are reluctant to material pressure on the frog. Because of this, one may elect to provide a more rigid and broad form of heel protection to the palmar foot. To address the rim of the coffin bone, one may elect to relieve the inner web of the shoe and isolate any impression material to the back half of the sole to reduce pressure at the toe. Leverage can be reduced by rolling the toe, or setting the shoe back off the toe, which will additionally protect the rim of the coffin bone, if a wide-web shoe is used. A consideration for stabilization with a rim cast could be made. An example of a therapeutic shoe that could meet these criteria is given in Figure 8.

The basic mechanical prescriptive plan that could be communicated to a farrier for application would be: 1) reduce tension in the DDFT, 2) redistribute pressure from the heels, 3) protect the rim of the coffin bone, 4) protect the palmar foot, and 5) reduce leverage at the toe. Several different appliances might work to achieve the same objectives. The goal is to communicate the mechanics, allow farrier's choice in material, and discuss any potential consequences. Recognition of the importance of the trim to achieve some of the mechanical objectives should be considered, and further medical treatments and rehabilitation would obviously be important for this case, as well.

It is worth noting that without an accurate, quantitative, anatomical diagnosis the above case is difficult to build a complete mechanical shoeing prescription but is understandably what practitioners deal with day-to-day.

4. Discussion

The approach to equine podiatry can be simplified by working to obtain an accurate diagnosis, determining what mechanical objective would help the pathology and then conveying those principles into a prescriptive plan. This will avoid conversations and empirical discussions over various shoes, techniques, or pedal appliances. By focusing on leverage, tension, pressure, protection, and stabilization, within the prescriptive plan, communication with farriers will invariably improve and allow them to use the shoe or methodology they are comfortable with to achieve the mechanical objective.

Acknowledgments

Declaration of Ethics

The Author has adhered to the Principles of Veterinary Medical Ethics of the AVMA.

Conflict of Interest

The Author has no conflicts of interest.

References and Footnotes

1. O'Grady SE. Strategies for shoeing the horse with palmar foot pain, in *Proceedings*. Am Assoc Equine Pract 2006; 52:209-217.
2. Conklin B. Therapeutic shoeing: A veterinary perspective, in *Proceedings*. Am Assoc Equine Pract 2009;55:155–167.
3. Parks AH. Form and function of the equine digit. *Vet Clin North Am [Equine Practice]* 2003;19:285–296.
4. Chateau H, Degueurce C, Denoix J-M. Evaluation of three-dimensional kinematics of the distal portion of the forelimb in horses walking in a straight line. *Am J Vet Res* 2004;65: 447–455.
5. Dyhre-Poulsen P, Smedegaard HH, Roed J, et al. Equine hoof function investigated by pressure transducers inside the hoof and accelerometers mounted on the first phalanx. *Equine Vet J* 1994;26:362–366.
6. Scheffer CJ, Back W. Effect of 'navicular' shoeing on equine distal forelimb kinematics on different track surfaces. *Vet Q* 2001;23:191–195.
7. Dabareiner RM, Carter GK. Diagnosis, treatment, and farriery for horses with chronic heel pain. *Vet Clin North Am [Equine Pract]* 2003;19:443–449.
8. Willemen MA, Savelberg HHCM, Barneveld A, et al. The effect of orthopedic shoeing on the force exerted by the deep digital flexor tendon on the navicular bone. *Equine Vet J* 1999;31:25–30.
9. Stump JE. Anatomy of the normal equine foot including microscopic features of the laminar region. *J Am Vet Med Assoc* 1967;151:1588–1598.
10. Schramme MC, Murray RC, Blunden AS, et al. A comparison between magnetic resonance imaging, pathology, and radiology in 34 limbs with navicular syndrome and 25 control limbs, in *Proceedings*. Assoc Equine Pract 2005;51:348–358
11. Lochner FK, Milne DW, Mills EJ, et al. In vivo and in vitro measurement of tendon strain in the horse. *Am J Vet Res* 1980;41:1929–1937.
12. Rogers CW, Back W. Wedge and eggbar shoes change the pressure distribution under the hoof of the forelimb in the square standing horse. *J Equine Vet Sci* 2003;23:306–309.

[a]EDSS, Inc., Penrose CO 81240.
[b]Ultimate Cuffs, Nanric Inc., Lawrenceburg, KY 40342.
[c]Equilox, Equilox International, Pine Island, MN 55963.
[d]Adhere, Vettec, Inc., Oxnard CA 93033.

Radiographing the Lame Horse: How to Acquire and Interpret Diagnostic Radiographs

David M. Dutton, DVM, DACVS

Lameness examinations are a significant component of an equine practice and diagnostic tools are invaluable in assessing and determining the cause of lameness. A thorough history and complete lameness examination, as well as anesthetic blocks, are the cornerstones to successful lameness examination. Further diagnostic tools such as radiography and ultrasonography are the most common initial diagnostic tools used to help establish a specific diagnosis and guide the practitioner in developing a therapeutic plan. Successful radiographic diagnosis is reliant on good radiographic equipment, proper technique, proper positioning, and complete radiographic studies. Knowledge of normal and abnormal radiographic anatomy is imperative for proper diagnosis. With the development of digital radiography, the quality of radiographs has significantly improved, but proper technique and proper positioning are necessary for diagnostic quality radiographs. Author's address: Texas Tech University, 7671 Evans Drive, Amarillo, TX 79106; e-mail: david.dutton@ttu.edu. © 2022 AAEP.

1. Radiographic Technique

Regarding proper technique, there are some general rules of thumb to remember for equine radiography. One is to have the kilovoltage setting high enough to supply enough energy to penetrate equine bone. As the bone and soft tissue thickness increases, subsequently density, so will the supplied kilovoltage. For example, 65 kV will be adequate to evaluate solar margin of P3 vs 80 kV for the stifle. For most equine limb radiographs, the kilovoltage will range from 65 to 90 kV. The second general rule of thumb is to have the shortest exposure time as possible, which will limit motion artifact. The third factor for consistent radiographic techniques is maintaining the established focal distance. A typical focal distance used in equine radiology is 36 inches. Collimation on the area of interest will also increase radiographic quality as well as ensure better radiation safety by decreasing scatter radiation. Placement of the radiographic plate close to the patient will limit magnification artifact. Proper film labeling is important for patient identification for medical and legal purposes. Film labeling should include the owner's name, patient's name (or hip/identification number in the case of sales films), veterinarian's or clinic's name taking the radiographs, radiographic acquisition date, and the limb being radiographed. Placement of radiographic markers is also crucial for correct anatomical lesion localization, especially for surgical intervention. Radiographic markers are placed on the radiographic plate on the dorsal or lateral aspect of the

NOTES

limb when the radiograph is taken. This ensures the radiographic reviewer knows which aspect of the limb is lateral vs medial and is especially beneficial on the oblique views. In the case of radiographic oblique views, the marker is placed on the lateral aspect of the limb.

2. Radiographic Positioning

Regarding proper radiographic positioning, first ensure the patient is standing square on a flat and level surface. This is especially important in evaluating feet for balance. When evaluating feet for balance, both feet should be on equal height blocks with the horse standing and positioned squarely. The height of the blocks should be high enough that the center of the radiographic beam, where the laser pointer is centered, is at the solar margin of the third phalanx. For a dorsopalmar view of the foot, the radiographic plate is positioned parallel to the heel bulbs and perpendicular to the ground surface. For the lateral view, the heel bulbs can also serve as a guide with the plate and generator being perpendicular to the heel bulbs. For the rest of the joints radiographed in the horse, the general concept is the radiographic plate is held and maintained perpendicular to the radiographic generator. The center of the radiographic beam is aimed directly at the center of the bone or joint of interest and at an angle where the radiographic beam is parallel to the joint surface. In general, a minimum of 2 radiographic views at right angles to each other (lateromedial and dorsopalmar/plantar views) may be taken for survey films in the distal limb of the horse. This is the minimal views needed to assess a 3-dimensional structure in a 2-dimensional image. However, in the lame horse, a complete radiographic study should be performed of the area of interest. In the lower limb, this includes the oblique views but could also entail special projections unique to that bone or joint involved.

3. Radiographic Views

Beyond the basics of patient positioning and projecting the radiographic beam, there are the specific views and angles of radiographs for each area of interest. Several equine textbooks[1,2] along with journal articles on specific anatomical locations can serve as useful guides for consultation of radiographic positions. The common views taken for a radiographic study can vary by the breed, age, discipline of use, and preference of the veterinary practitioner. Common basic radiographic views of each anatomical area of the horse in relation to lameness localization and clinical scenarios will be discussed.

Distal Phalanx/Navicular Bone Region

The most common area evaluated for lameness is the foot. Here are some scenarios and what radiographic views that would be warranted.

Scenario 1: A horse is presented with a unilateral non-weightbearing limb lameness, with heat at the coronary band, increased digital pulses, and is positive to hoof testers across the toe. The most likely diagnosis is a foot abscess, but no definitive tracts are seen. Rather than randomly paring on the foot for an abscess, radiographic evaluation would be warranted, especially to rule out a P3 fracture. The basic radiographic views for a foot/distal phalanx study in this scenario would include a lateromedial view, horizontal dorsopalmar view, and a 65-degree dorsoproximal-palmarodistal view of the solar margin. These views allow for evaluation of the foot for potential gas tracts seen with some abscesses, coffin bone fractures, keratomas, osteitis, as well as coffin joint osteoarthritis, subchondral bone cysts, and osteochondral fragments. Even when the cause of lameness is an obvious abscess, it is good practice to obtain these radiographic views to rule out other underlying causes for the abscess and to have a baseline set of radiographs if the problem progresses. These 3 main basic views are also obtained in cases of laminitis. The lateral view allows for evaluation of potential rotation, sinking, and dorsal laminar thickening. Some horses can sink medially as well, thus the reasoning for a dorsopalmar (DP) view. The solar margin view allows for evaluation of solar margin fragmentation and osteitis of P3. Further radiographic evaluation in a laminitic case would include a venogram.

Scenario 2: A horse is presented with a forelimb lameness, negative to hoof testers and blocks out to a palmar digital nerve block. A palmar digital nerve (PDN) block is not specific to just blocking out the heels but regionalizes the lameness to the foot/pastern region. The lateromedial (LM) and DP views discussed above along with radiographs of the navicular bone, including a collimated 60-degree dorsoproximal-palmarodistal oblique view and palmaroproximal-palmarodistal oblique skyline view, would be the basic radiographs obtained in this case. Lateral and medial oblique views from a horizontal plane or from the 65-degree dorsoproximal-palmarodistal oblique view are taken to further examine areas of interest in the region of the phalanges, navicular bone, solar margin, and wings of the third phalanx. When radiographs of the navicular bone are taken, it is imperative to ensure the foot/sulci of the frog are clean and any exfoliating false sole or detached frog is pared away to avoid radiographic artifact. The addition of packing material to fill in the voids of the sulci of the frog decreases artifact, improves radiographic detail, and avoids inadvertently suspecting a frog/solar artifact as a fracture. The addition of navicular radiographs allows for evaluation of navicular cysts, flexor cortical lysis, loss of corticomedullary junction, distal marginal fragmentation, enthesiophytes, and synovial invaginations. Other causes of lameness that can block out to the foot involve the soft tissues of the foot such as the deep digital flexor tendon, impar ligament, suspensory ligament of the navicular bone, and collateral ligaments. Also, bone bruising/bone edema and navicular bursitis can be causes of foot lameness. Further diagnostics such as ultrasound of the soft tissues that can be accessed can be performed, but complete evaluation is limited. Magnetic resonance imaging

(MRI) or computed tomography (CT) evaluation of the foot region is needed in more complex cases and for complete evaluation to obtain a final definitive diagnosis.

Pastern/Fetlock/Metacarpus

Horses in which the lameness blocks to an abaxial block would warrant radiographic evaluation of the pastern. Radiographic positions for the pastern include a lateromedial view, dorsoproximal-palmarodistal view (20–35 degrees proximal to distal with the plate parallel to the pastern and the beam perpendicular to the pastern), dorsolateral-palmaromedial view, and dorsomedial-palmarolateral view. The obliquity of the dorsolateral-palmaromedial oblique (DLPMO) and dorsomedial-palmarolateral oblique (DMPLO) views can vary depending on the specific area of interest. In general, 35- to 45-degree oblique views are standard for the pastern joint. Common radiographic abnormalities of the pastern region are high ringbone (articular osteoarthritis, nonarticular), subchondral bone cysts, and fractures. Areas of exostosis, such as seen along the palmar aspect of P1, can be indicative of soft tissue involvement. Nonarticular bony changes and avulsion fragments can be indicative of soft tissue injuries, and further assessment of the associated tendon or ligament should be performed via ultrasonography or, in some cases, MRI or CT.

Radiographs of the fetlock are taken in cases where the lameness is localized to the fetlock via clinical evaluation, intra-articular anesthesia, and/or a low 4-point block. Radiographs of the fetlock include lateromedial view, flexed lateromedial view, 30-degree dorsoproximal-palmarodistal view, dorsolateral-palmaromedial view, and dorsomedial-palmarolateral view. Standard angulations of the fetlock joint are 45 degrees. Proximal to distal oblique views are taken in cases of further evaluation of the proximal sesamoid bones and palmar eminences. Common radiographic abnormalities of the fetlock include osteoarthritis, osteochondral fragments, osteochondrosis, osteochondrosis dissecans, subchondral bone cysts, proximal sesamoid fractures, and proximal sesamoiditis. As with other anatomical areas, signs of bone remodeling, periostitis, and exostosis can be indicative of soft tissue injuries and should be evaluated further via ultrasonography. In lameness localized to the fetlock region, the suspensory branches, in particular, should be evaluated for potential involvement as well.

Radiographs of the metacarpal bones include a lateromedial view, dorsopalmar view, dorsolateral-palmaromedial view, and dorsomedial-palmarolateral view. Common radiographic abnormalities include dorsal metacarpal disease/bucked shins, dorsal cortical fractures, splints, and splint fractures. The dorsopalmar view also allows for evaluation of bony changes at the origin of the suspensory.

Carpus/Radius

Lameness localized to the carpus is usually diagnosed via examination, palpation of carpal effusion, and positive response to flexions. Intra-articular anesthesia of the midcarpal and/or radiocarpal joint confirms the origin of the lameness. Many lameness cases associated with the carpi will be more subtle in lameness severity. Radiographs of the carpus include a flexed lateromedial view, dorsopalmar view, dorsolateral-palmaromedial view, and dorsomedial-palmarolateral view. Especially in speed event horses, skyline views of the carpal bones are taken for evaluation for slab fractures, third carpal bone remodeling, and osteochondral fragments. The distal radius, proximal row of carpal bones, and distal row of carpal bones are evaluated via dorsoproximal-dorsodistal radiographic views. The row of carpal bones evaluated is done by changing the radiographic angle. The distal radius is evaluated via 90-degree view, the proximal row of carpal bones via 60-degree view, and the distal row of carpal bones via a 30-degree view. Most radiographs of the carpi are taken to evaluate carpal conformation, angular limb deformities, flexural limb deformities, physitis, osteochondral fragmentation, carpal slab fractures, and osteoarthritis. The radius can be evaluated via craniocaudal, lateral, craniolateral-caudomedial oblique, and craniomedial-caudolateral oblique views. Most radiographs of the radius are taken for stress fractures and fractures of the radius.

Elbow/Humerus/Shoulder

Lameness and radiographic evaluation of the elbow to shoulder are less common. Usually, the lameness associated in this region is more pronounced and typically presents with a shortened cranial phase of stride. In young horses, these areas are radiographed in conjunction with traumatic injuries or due to osteochondrosis. Lameness localization can be accomplished with intra-articular blocks. Caution should be taken when blocking the elbow joint in that the radial nerve can be inadvertently anesthetized, leading to several hours of radial nerve paresis. Common radiographic views of the elbow include a flexed mediolateral view and a craniocaudal view. A "lateral" view of the elbow is best taken in a 90-degree flexed position with the limb pulled cranially and the radiograph taken from a medial to lateral direction. The radius is parallel to the ground surface to achieve a 90-degree flexion position of the elbow. For the craniocaudal view, the plate needs to be slightly angled and pushed into the ribcage with the radiographic beam slightly angled medial to lateral from a true cranial to caudal position. Radiographic evaluation of the elbow is common for olecranon fractures, trauma, and osteoarthritis. Radiographs of the humerus are usually taken to evaluate traumatic injuries and evaluate for humeral fractures and fractures of the deltoid tuberosity. Radiographic views of the humerus include a mediolateral/lateromedial view and a proximocaudal-distocranial view. The "lateral" view of the humerus can be accomplished either via a slightly cranial medial to lateral projection or a slightly caudal lateral to medial projection. The lateral vs a medial projection is usually based on the case circumstance, size of patient, and standing vs recumbent

position. The caudocranial is best accomplished with a proximal to distal beam projection attempting to align the plate parallel to the humerus and requires a slight lateral to medial angulation of the x-ray generator. Shoulder radiographs are more challenging but can be accomplished with proper radiographic positioning. Shoulder radiographs are an extended mediolateral view and a caudolateral-craniomedial view. For the "lateral" view, the radiograph is taken from a medial to lateral projection. The affected limb is pulled forward and elevated with the goal of overlapping the shoulder joint and the trachea. Shoulder radiographs are typically taken for traumatic injuries, osteoarthritis, and osteochondrosis.

Hocks/Stifles

Lameness associated with the hocks is common in performance horses across all disciplines. Hock lameness is determined via examination and flexions and confirmed via intra-articular anesthesia. Radiographic evaluation of the hock includes a lateromedial view, dorsopalmar view, dorsolateral-palmaromedial view, and palmarolateral-dorsomedial view. The lateromedial, dorsopalmar, and dorsolateral-palmaromedial views will have a slight proximal to distal projection to be parallel to the distal hock joints. The palmarolateral-dorsomedial view will have a distal to proximal projection to improve evaluation of the distal hock joints. Another view occasionally taken is the flexed plantaroproximal-plantarodistal view, which allows for evaluation of the tuber calcaneus and sustentaculum tali. Common radiographic evaluations of the hocks are taken for evaluation of incomplete ossification of the tarsal bones, angular limb deformities, osteoarthritis, osteochondrosis, and tarsal slab fractures. Osteoarthritis is primarily associated with the tarsometatarsal and distal intertarsal joints (bone spavin). Osteochondritis dessicans lesions are primarily in the tibiotarsal joint with the distal intermediate ridge of the tibia being the most common site but can occur on the lateral trochlear ridge, medial trochlear ridge, and the medial and lateral malleolus. Osteochondral fragments are seen distal to the medial trochlear ridge (dew drop) and, in general, are an incidental finding. The tarsal skyline views are mostly taken for evaluation of the sustentaculum tali for fracture fragments, osteitis, and osteomyelitis usually associated with sepsis of the medial tarsal sheath.

The stifle is composed of 3 joints and lameness can originate from any of the joints. The lateral femorotibial joint is the least commonly affected. Confirmation of the stifle and which specific joint involved in the lameness is determined via intra-articular anesthesia. Stifle radiographs primarily consist of a lateromedial view, caudolateral-craniomedial oblique view, and caudocranial view. There are clinician preferred and specialized views of the stifle as well, such a flexed lateromedial view and flexed cranioproximal-craniodistal view. Common abnormal stifle radiographic findings are osteoarthritis, osteochondritis dissecans of trochlear ridges, and subchondral bone cysts of the medial femoral condyle. Skyline views (cranioproximal-craniodistal) of the patella are needed for evaluation of patellar fractures and evaluation of the trochlear groove, especially in miniature horses. The flexed lateromedial view allows for better assessment of the patella, proximal aspects of the trochlear ridges, and insertion of the cruciate ligaments. The flexed view is an option in horses not tolerating radiographic plate placement medially and not being able to position further proximally in the weight-bearing position.

4. Normal Radiographic Anatomy

Knowledge of normal radiographic anatomy is imperative in making a proper radiographic diagnosis and thus in being able to identify abnormal findings. General radiographic evaluation will consist of assessing the surrounding soft tissue for radiographic signs of swelling, defects, opacities such as mineralization, or lucencies such as gas tracts. The soft tissue swelling can correlate with general soft tissue swelling such as seen with edema or cellulitis, enlargement and thickening of tendons or ligaments, or swelling around joints consistent with joint effusion. The cortex of the bone is evaluated for thickening, sclerosis, lysis, periosteal reaction, or endosteal reaction. The medullary cavity is assessed for trabecular pattern as well as sclerosis or lysis. The joint margins are evaluated for a smooth surface. Abnormalities at the joint margins can be periarticular periosteal reactions, bone lysis, enthesiophyte formation, osteophyte formation, and osteochondral fragmentation. The joint space is evaluated for joint alignment, symmetry of the joint space, and thickness. A narrowed joint space is consistent with articular cartilage thinning and loss. A widened joint space is consistent with joint effusion. The subchondral bone is evaluated for sclerosis, lysis, fragmentation, cyst formation, and osteochondrosis. A 3-dimensional perspective of the anatomy of the area radiographed is beneficial when evaluating a 2-dimensional radiograph to account for anatomical areas of bone overlap. In summary, a solid foundation of the skeletal anatomy of the bones and location of soft tissue attachments is crucial for successful radiographic interpretation of normal. There are available textbooks for reference that are useful for equine anatomy.[3,4]

In closing, it should be noted that radiographs are just one component of a complete thorough lameness examination. In some cases, the radiographs will provide a definitive diagnosis of the inciting cause of the lameness, such as in advanced osteoarthritis, fractures, osteochondral fragments, etc. In other cases, the radiographic findings will lead the practitioner to suspect soft tissue

involvement as an inciting factor of the cause of lameness and ultrasonography of the soft tissue structures are warranted. Typical radiographic changes seen with soft tissue involvement can include exostosis, sclerosis, lysis, mineralization, or avulsion fragments of the bone at ligamentous or tendonous insertions. This highlights the importance of knowing the anatomical locations of origin or insertion of the soft tissues. Thermography is also a diagnostic tool being used to help gather more clinical evidence to determine the inciting cause. Other times the radiographs are normal or inconclusive and other advanced modalities of diagnostic imagining are warranted, such as the use of nuclear scintigraphy, MRI, and CT. In other cases, radiographic changes are seen but do not necessarily fit with the clinical picture and further diagnostics are necessary to see the complete picture.

Acknowledgments

Declaration of Ethics

The Author has adhered to the Principles of Veterinary Medical Ethics of the AVMA.

Conflict of Interest

The Author has no conflicts of interest.

References

1. Butler J, Colles C, Dyson S. *Clinical Radiology of the Horse*. 4th ed. Chichester, UK: John Wiley and Sons; 2017.
2. Stashak T. *Adams Lameness in Horses*. 5th ed. Baltimore, MD: Lippincott Williams and Wilkins; 2002.
3. Denoix J. *The Equine Distal Limb*. London: Manson Publishing; 2002.
4. Budras K, Sack W, Rock S. *Anatomy of the Horse*. 4th ed. Hannover, Germany: Schlutersche; 2003.

Use of Ultrasound for Diagnosis of Common Soft Tissue Injuries

Tyler E. Tipton, DVM, DACVS-LA

Author's address: 113 Equine, 6700 S. FM 113 Millsap, TX 76066; e-mail: ttipton@113equine.com. © 2022 AAEP.

1. Introduction

Lameness is a common and difficult ailment facing most equine veterinarians. A large portion of equine patients are required to perform athletic maneuvers, which put extraordinary stress on the musculoskeletal system, resulting in many potential injuries. Equine veterinarians are expected to accurately diagnose these conditions and develop treatment plans allowing the horse to return to activity with the shortest convalescent period possible. An accurate diagnosis can be particularly difficult in the case of soft tissue injury. Intimate knowledge of regional anatomy, ability to perform diagnostic anesthesia, and use of multiple imaging techniques (radiography and ultrasonography) are essential for lameness diagnosis. It is the intention of this article to familiarize the general equine practitioner with ultrasonography and its use in the diagnosis of commonly encountered soft tissue injuries in equine patients.

Ultrasonography has been used in the equine patient for close to 40 years, and the technology has become reliably used in the practice of equine medicine. Ultrasonography has become important due to relatively low cost, accessibility, and ease of use in ambulatory situations.[1] However, obtaining diagnostic images and accurately interpreting ultrasonographic images requires an understanding of the interaction between the ultrasonographic waves and the tissue being examined, knowledge of the anatomy being examined, and knowledge of the normal ultrasonographic appearance of the tissue being examined. The quality of the equipment, preparation of the patient, and operator practice and proficiency all determine the diagnostic quality of the images.[2,3]

Equipment

Ultrasound technology has developed rapidly over the last few years, and the advent of more portable and affordable ultrasound machines has made this modality more available to practitioners than ever before. Diagnostic images can be obtained with most any ultrasound machine currently on the market; therefore, there is no longer a need for a large console unit to produce high-quality diagnostic images. This has enabled the ambulatory veterinarian to diagnose and treat soft tissue injury in the field.

Patient Preparation

Proper preparation of the patient cannot be overlooked when performing ultrasonography. The hair should be clipped with a #40 clipper blade and all dirt and debris carefully removed from the skin surface. The area should be thoroughly cleaned with soap and warm water and acoustic coupling gel applied to the skin. The presence of any debris such as hair, dirt, or skin wounds can adversely affect image quality and produce artifacts rendering image interpretation more difficult.[3] There are instances where the patient is unable to be clipped for one reason or another; in these instances, isopropyl alcohol can be placed on the

NOTES

Fig. 1. The peripheral nature of the typical SDFT lesion in cutting horses as opposed to the classic centrally located core lesion seen in racing horses.

cleaned limb to facilitate contact between the probe and the patient.

The ultrasonographer should get in a comfortable position to image the desired structure. If the patient or clinician is in an uncomfortable position, the exam will be rushed and image quality will suffer. Proper restraint and sedation are necessary for the patient to stand long enough for the exam to be performed. Some patients resent the cleaning or placement of alcohol on the limb, so care should be taken. Also, some patients resent the pressure of the probe being placed on the skin to obtain the image.

Imaging Technique

Although developing proficiency with ultrasound requires practice, the technique can be easily developed over time to obtain diagnostic quality images. Becoming familiar with adjusting the settings for optimal image quality is important and comes with repeated use of the equipment. Knowing when and how to adjust frequency, use a standoff, adjust gain, and adjust focal depth is important for obtaining the image.

Placement of the probe on the skin and using the proper amount of force are also essential to image quality. In most instances, the probe should be oriented at a 90-degree angle from the structure being imaged; this is referred to as an on-incidence image. There are certain instances when structures can be imaged with an off-incidence image (suspensory ligament). Also, obtaining weight-bearing and non-weight-bearing images is part of a complete ultrasonographic examination.

Common Soft Tissue Injuries

1. Superficial Digital Flexor Tendon (SDFT)

Superficial digital flexor tendonitis is common among horses competing in speed events such as racing of all types. The SDFT is most commonly injured in the mid-metacarpal/tarsal region and the classic lesion is a hypoechoic area within the center of the tendon (i.e., a core lesion). In a study of cutting horses, it was found that SDFT lesions commonly occurred in the mid-metacarpal region, but at the lateral margin of the tendon.[4] The ultrasonographic technique for diagnosis of SDFT lesions includes weight-bearing, on-incidence images. The use of a standoff pad is important in imaging of the SDFT due to the very superficial location of the tendon. When the tendon is imaged in a non-weight-bearing position, there can be some relaxation artifact noted on the images (Fig. 1).

2. Proximal Suspensory Ligament (PSL)

The suspensory ligament is a very important cause of lameness in many different disciplines of horses. The suspensory apparatus is responsible for suspension of the metacarpo/metatarsophalangeal joint during locomotion and is commonly injured. The suspensory ligament presents a unique challenge for the ultrasonographer due to the location of the origin of the ligament between the second and fourth metacarpal/metatarsal bones, as well as the presence of fat and muscle bundles within the proximal portion of the ligament. A complete exam of the PSL includes weight-bearing, non-weight-bearing, on-incidence, and off-incidence images.

Evaluation of the PSL includes determining the shape, size, and echogenicity of the ligament as well as the bone ligament interface at the origin. The normal PSL has a rounded appearance with a medial and lateral bundle. Within each bundle, there is a fat and muscle bundle centrally located; these are easily confused with a lesion and so should be interpreted carefully. The fat and muscle deposits within the PSL necessitate the use of off-incidence images, and there is a predictable echogenic pattern of the fat and muscle deposits that is different from the echogenic pattern of damaged or scar tissue within the ligament. The ability to differentiate scar or damaged tissue from normal tissue is paramount to an accurate diagnosis. Using a combination of findings (increased size, change in echogenic pattern, change in shape) assists with making the diagnosis. Using both weight-bearing and non-weight-bearing exam of PSL is important. Non-weight-bearing exam allows displacement of the overlying tendons, allowing the PSL to be more easily imaged, and imaged with a higher frequency, providing better resolution of Fig. 2.

3. Suspensory Branch (SB) Injury

The suspensory branches are a continuation of the distal aspect of the suspensory ligament. The ligament splits into medial and lateral branches in the distal one-third of the metacarpus/metatarsus. SB injury is very common in many disciplines of horses and relatively easily diagnosed. The SB is easily palpated, and injury can be suspected based on palpation of pain or increase in size on clinical exam as well as exacerbation of lameness with distal limb flexion tests. Ultrasound is used to confirm diagnosis. SB

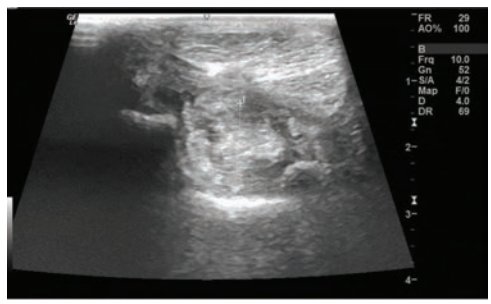

Fig. 2. PSL lesion, generalized enlargement, and hypoechogenicity of the suspensory in the non-weight-bearing patient.

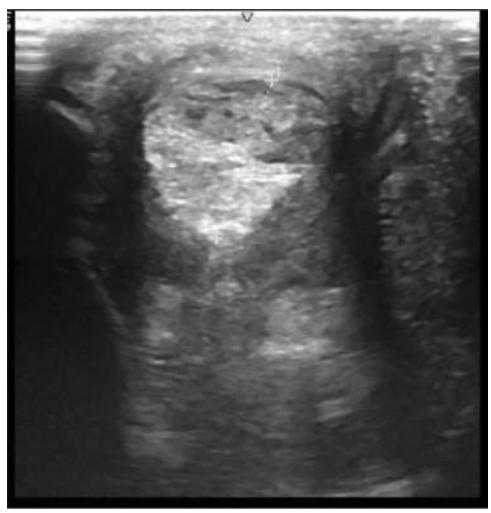

Fig. 3. Peripheral fiber damage of the suspensory branch with enlargement of the SB.

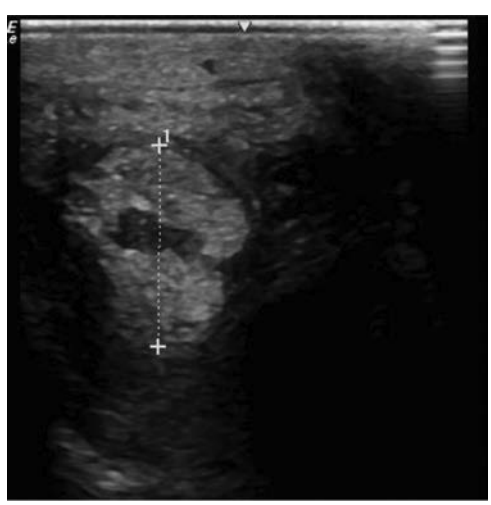

Fig. 4. Large core lesion in the suspensory branch with peri-ligamentous fibrosis.

injuries are common in both fore- and hindlimbs and appearance is similar in fore- and hindlimbs.

An injured SB is generally increased in size and can have significant distortion of the normal shape. Centrally located hypoechogenic areas are common, as are hypoechogenic margins. Another common

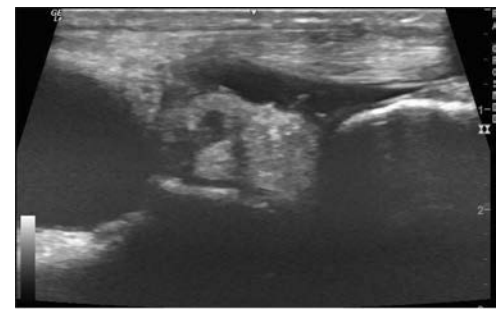

Fig. 5. Large lesion of the medial meniscus with marked joint effusion of the medial femorotibial joint and displacement of the joint capsule over meniscus.

finding in chronic SB desmitis is peri-ligamentous fibrosis, noted as thickening of the tissue between the skin and SB. Evaluation of the bone–ligament interface at the insertion on the proximal sesamoid bones is important as avulsion fractures and irregular bone margins are very common with SB injuries and potentially negatively affect prognosis (Figs. 3 and 4).

4. Soft Tissue Injury of the Stifle

The stifle joint is a common place to find multiple soft tissue injuries that are many times able to be diagnosed with ultrasound. Ultrasound exam of the stifle is important; the anatomy of the stifle does not lend itself to imaging with magnetic resonance imaging in most cases. Many times, ultrasound is the only noninvasive soft tissue diagnostic imaging that can be performed. The commonly injured soft tissues include the medial meniscus, medial collateral ligament, cranial ligament of medial meniscus, cranial and caudal cruciate ligaments, and less commonly the patellar ligaments, most of which can be imaged with good ultrasonographic technique. Again, an exam in the non-weight-bearing position is required to image some of the soft tissues of the stifle.

Medial meniscal injuries are one of the more common stifle injuries diagnosed with the ultrasound. Only the cranial portion of the medial meniscus is visible with the ultrasound exam; however, this is valuable information and should be performed in cases with medial femorotibial joint effusion and nonspecific radiographic findings. When injured, common changes in the meniscus include loss of the normal triangular shape, prolapse of the ligament from its normal position between the distal medial femoral condyle and proximal medial tibia, and hypoechoic lesions within the body of the meniscus. Evaluation of hypoechogenicity of the medial meniscus should be interpreted carefully because the normal meniscus has hypoechoic linear bands or streaks. Massive joint effusion, synovial proliferation, and inflammatory infiltrate within synovial fluid often accompany abnormal findings of the meniscus (Fig. 5).

Imaging of the medial collateral ligament (MCL) is performed in the weight-bearing or non-weight-bearing patient with the ultrasound probe on the medial aspect of the stifle. The MCL can be imaged in its

entirety, originating on the distal medial femur and inserting on the proximal medial tibia. Increased sized, hypoechogenicity, or inability to image from origin to insertion are all indications of injury. Joint effusion may or may not be present as a portion of the MCL is extracapsular and not within the medial femorotibial joint.

Cranial ligament of the medial meniscus is more difficult to image and requires the patient to be non-weight-bearing. The ligament is imaged at the cranial medial aspect of the medial meniscus, and injuries are normally noted as loss of normal fiber alignment, which can extend into the cranial pole of the medial meniscus. A portion of the cranial cruciate ligament can be imaged with ultrasonography, but diagnosis of injury with ultrasound is technically demanding and not discussed further. Injury of the patellar ligaments is much less common. Each of the patellar ligaments is easily imaged from the distal patella to the insertion on the tibial tuberosity.

2. Discussion

The ability of the equine clinician to accurately diagnose soft tissue injury is a requirement to perform lameness evaluation of the horse. The availability of ultrasound as a diagnostic tool has enabled practitioners to reliably assess the soft tissues and develop diagnosis and treatment plans. Although there is a learning curve with ultrasound technique, proficiency can be achieved with practice. Many times, inability to obtain diagnostic images is due to improper patient preparation or improper settings on the ultrasound. Becoming familiar with manipulation of frequency, depth, focal zone, and gain allows the ultrasonographer to optimize the image during examination. A careful and thorough examination is required of the structure being imaged, and development of a systematic approach to imaging will prevent missing potential lesions.

As the technology of ultrasound advances, becomes more affordable, and is portable, this imaging will become increasingly important to the general equine practitioner. Point-of-care ultrasound is now available and increasingly used. Veterinarians are now required to become more comfortable with the technology and techniques associated with ultrasound imaging.

Becoming comfortable with some of the techniques discussed previously (on- and off-incidence imaging, weight-bearing and non-weight-bearing examination) will increase the diagnostic ability of equine practitioners. The ability to accurately diagnose and treat patients on the farm at the time of exam not only provides a higher quality of medicine for equine patients but also increases the profitability of a veterinary practice.

Acknowledgments

Declaration of Ethics

The Author has adhered to the Principles of Veterinary Medical Ethics of the AVMA.

Conflict of Interest

The Author has no conflicts of interest.

References

1. Werpy NM, Axiak L. Review of ultrasound techniques for the diagnosis of musculoskeletal injury, in *Proceedings*. Am Assoc Equine Pract 2013;59:209–219.
2. Walmsley JP. Diagnosis and treatment of ligamentous and meniscal injuries in the equine stifle. *Vet Clin North Am Equine Pract* 2005;21:651–672.
3. Rantanen NW, Jorgensen JS, Genovese RL. Ultrasonographic evaluation of the equine limb: technique. In: Ross MW, ed. *Diagnosis and Management of Lameness in the Horse. 2nd ed. Philadelphia, PA*: Elsevier; 2011:182–206.
4. Tipton TE, Ray CS, Hand DR. Superficial digital flexor tendonitis in cutting horses: 19 cases (2007–2011). *J Am Vet Med Assoc* 2013;243:1162–1165.

Congenital and Juvenile Cataracts in Horses

Kelly E. Knickelbein, VMD, DACVO*; Kathryn L. Good, DVM, DACVO; and Rebecca R. Bellone, PhD

The American Quarter Horse, Andalusian, and Standardbred breeds are overrepresented for congenital and juvenile cataracts, and a genetic basis is suspected. Authors' address: College of Veterinary Medicine, Cornell University, 930 Campus Road, Box 31, Ithaca, NY 14853; e-mail: kek248@cornell.edu. *Corresponding and presenting author. © 2022 AAEP.

1. Introduction

Cataracts represent an important cause of blindness in horses. While feasible, equine cataract surgery outcomes are variable, and normal vision is an infrequent postoperative result. Identification of breeds predisposed to congenital and juvenile cataract development may allow for future genetic investigations to identify genetic variation contributing to cataract development.

2. Materials and Methods

Retrospective case identification of horses diagnosed with congenital or juvenile cataracts presented to an academic referral hospital. Signalment, ophthalmic examination findings, and treatment measures were assessed.

3. Results

Seventy horses with congenital or juvenile cataracts were identified. Fifty-six horses were affected bilaterally and 14 unilaterally, for a total of 126 affected eyes. American Quarter Horses, Andalusians, and Standardbreds were significantly overrepresented compared to the ophthalmology and hospital reference populations ($P = 0.011 - 1.0 \times 10^{-5}$). Fifty-five eyes (43.7%) received no treatment, 21 eyes (16.7%) received medical therapy, and 34 eyes (27.0%) were treated with phacoemulsification without intraocular lens implantation. Eight horses were euthanized. No eyes were restored with normal vision as all operated eyes were left aphakic. Postoperative vision was present in 25/30 eyes for which follow-up was available.

4. Discussion

The overrepresentation of certain breeds and frequent bilateral nature of congenital and juvenile cataracts is suggestive of an underlying genetic basis. Future genetic studies are warranted, and the identification of genetic variants associated with or causal for congenital and juvenile cataracts should enable a better understanding of this disease.

Research Abstract—for more information, contact the corresponding author

NOTES

Acknowledgments

Declaration of Ethics

The Authors have adhered to the Principles of Veterinary Medical Ethics of the AVMA.

Conflict of Interest

The Authors have no conflicts of interest.

Effects of Phenylbutazone, Firocoxib, and Dipyrone on the Diuretic Effect of Furosemide in Horses

Julianne M. White, DVM, MBA*; Aimee C. Colbath, DVM, MS, PhD, DACVS; and Harold C. Schott II, DVM, PhD, DACVIM

COX-2 selective NSAIDs do not appear to be "renosparing", warranting monitoring of renal function when using all NSAIDs. Authors' address: Michigan State University College of Veterinary Medicine, 736 Wilson Road, East Lansing, MI 48824; e-mail: juliewhitedvm@gmail.com. *Corresponding and presenting author. © 2022 AAEP.

1. Introduction

Administration of NSAIDs to horses to control inflammation by inhibition of cyclooxygenase enzyme (COX) activity can have adverse renal effects. Both COX-1 and COX-2 regulate renal blood flow, glomerular filtration, tubular function, and urinary concentrating ability. Pretreatment with phenylbutazone (a non-selective COX inhibitor) decreases the diuretic and natriuretic effects of furosemide by nearly 30%. Effects of COX-2 selective (firocoxib) and atypical NSAIDs (dipyrone) on the renal responses to furosemide in horses are unknown.

2. Materials and Methods

Eight mares received four treatments in a replicated 4×4 Latin Square design: furosemide alone (F), furosemide and firocoxib (FX), furosemide and dipyrone (DP), and furosemide and phenylbutazone (PB). After 24 h of pretreatment with NSAIDs at recommended dosages, ureteral catheters were placed for urine collection. After a baseline collection period, furosemide (1.0 mg/kg, IV) was administered, and urine and blood samples were collected for 4 h. Data were assessed by repeated measures ANOVA.

3. Results

Urine volume during the 4 h after furosemide administration decreased ($P < 0.001$) 20-25% after pretreatment with all NSAIDs, as compared to F, and there were no differences between FX, DP, or PB. Considerable interindividual variability in responses to furosemide administration after pretreatment with different NSAIDs was observed.

4. Discussion

No difference in inhibition of furosemide-induced diuresis was found between NSAIDs in this study, suggesting that COX-2 selective NSAIDs might not be "renosparing."

Research Abstract – for more information, contact the corresponding author

NOTES

Acknowledgments

Declaration of Ethics

The Authors have adhered to the Principles of Veterinary Medical Ethics of the AVMA.

Conflict of Interest

The Authors have no conflicts of interest.

Comparison of Whole Blood and Plasma Equine Insulin Concentrations Using a Novel Stall-Side Insulin Assay and Reference Radioimmunoassay

Emily Berryhill, DVM, DACVIM*; Naomi Urbina, DVM, PhD; and Flavio Alonso, DVM, PhD, DACVCP

The Wellness Ready Equine Insulin Test (WRT) has good agreement with a radioimmunoassay (RIA) across a range of insulin concentrations. Concentrations averaged 10.39% higher using the WRT. The WRT has utility as a screening assay for insulin dysregulation (ID). Authors' addresses: Department of Medicine and Epidemiology (Berryhill) and Department of Pathology, Microbiology, and Immunology (Alonso), School of Veterinary Medicine, University of California-Davis, Davis, CA, 95616; Fortis Life Sciences, 4878 Ronson Court, Ste. J, San Diego, CA 92111 (Urbina); Department of Biomedical Sciences, Ross University School of Veterinary Medicine, Saint Kitts, West Indies (Alonso); e-mail: ehberryhill@ucdavis.edu. *Corresponding and presenting author. © 2022 AAEP.

1. Introduction

Monitoring insulin concentrations is critical for managing insulation dysregulation (ID) in horses. The WRT, a stall-side assay utilizing whole blood, has recently become available. Method comparison between the WRT and a reference RIA is required to validate the WRT and assist veterinarians in interpreting results.

2. Materials and Methods

Ninety-nine whole blood and plasma samples were analyzed in duplicate using the WRT and RIA, respectively. Insulin concentrations ranged from <20 to >100 μIU/mL. Assay sensitivity and specificity were determined for insulin cut-offs used for diagnosing ID, with bias between the assays were evaluated.

3. Results

Linear regression showed a slope of 1.005 and y-intercept of 3.502. The Spearman correlation coefficient (r_s) was 0.90 (95% CI 0.85-0.94). The WRT concentrations averaged 10.39% higher than the RIA, with mean bias of 3.74-3.84 μIU/mL for cut-offs of 45, 50, and 65 μIU/mL. The WRT had sensitivities of 87% and specificities of 93% at cut-offs of 45 and 50 μIU/mL and a sensitivity and specificity of 95% at 65 μIU/mL.

Research Abstract—for more information, contact the corresponding author

NOTES

4. Discussion

Linear regression and Spearman correlation showed good assay agreement. Diagnostic accuracy for determining ID was best at the 65 μIU/mL cut-off. The mean 10.39% higher WRT concentrations may have clinical significance when insulin concentrations fall on the cusp of a decision changing cut-off point.

Acknowledgments

Declaration of Ethics

The Authors have adhered to the Principles of Veterinary Medical Ethics of the AVMA.

Conflict of Interest

This study was funded by Wellness Ready Labs, 107 Church Street, Suite 201, Lexington, KY 40507. Dr. Naomi Urbina is employed by Fortis Labs, contracted to Wellness Ready Labs for product development.

How to Interpret the Phosphorylated Neurofilament Heavy Biomarker Test

Carrie J. Finno, DVM, PhD, DACVIM (LAIM)*; Lisa A. Edwards, DVM, DACVIM (LAIM); Callum G. Donnelly, BVSc, DACT, DACVIM (LAIM); Stephen M. Reed, DVM, DACVIM (LAIM); Stephanie J. Valberg, DVM, PhD, DACVSMR, DACVIM (LAIM); Munashe Chigerwe, BVSc, MPH, DACVIM (LAIM), PhD; and Amy L. Johnson, DVM, DACVIM (LAIM and Neurology)

Authors' addresses: Department of Medicine and Epidemiology, School of Veterinary Medicine, University of California-Davis, One Shields Avenue, Davis, CA 95616 (Finno, Edwards, Donnelly, Chigerwe); Rood and Riddle Equine Hospital, PO Box 12070 Lexington, KY 40580-2070 (Reed); Department of Large Animal Clinical Sciences, Mary Anne McPhail Equine Performance Center, Michigan State University, East Lansing, MI 48824 (Valberg); Department of Clinical Studies, New Bolton Center, School of Veterinary Medicine, University of Pennsylvania, Kennett Square, PA 19348 (Johnson); e-mail: cjfinno@ucdavis.edu. *Corresponding and presenting author. © 2022 AAEP.

1. Introduction

Definitive diagnosis of neurological disease in the equine patient is challenging, typically involving multiple diagnostic tests, in addition to a thorough clinical examination. Equine spinal neurodegeneration has several underlying causes, including cervical vertebral compressive myelopathy (CVCM; Wobbler syndrome), equine neuroaxonal dystrophy/equine degenerative myeloencephalopathy (eNAD/EDM), equine motor neuron disease, equine grass sickness, and Shivers. While clinical signs of equine motor neuron disease, equine grass sickness, and Shivers are distinct, the proprioceptive ataxia observed with CVCM and eNAD/EDM are nearly identical, and it is challenging to arrive at a definitive antemortem diagnosis. While CVCM has classically been defined as a multifactorial or idiopathic disorder,[1] the spinal cord compression leads to a degenerative cervical myelopathy,[2] thus classifying CVCM as a form of neurodegeneration, similar to degenerative cervical myelopathy in humans.[3] Infectious etiologies, including equine protozoal myeloencephalitis (EPM), West Nile Virus, and equine herpes myeloencephalopathy, can also present as spinal ataxias; however, accurate antemortem diagnostics tests are readily available for these diseases.

The physical size of the horse precludes sensitive imaging techniques such as magnetic resonance imaging, with the mainstay of diagnosis relying on radiography, myelography, and computed tomography. These imaging techniques are primarily to exclude CVCM; however, the poor sensitivity and presence of nonsignificant background lesions limit their utility.[4] Additionally, there is no definitive diagnostic test for the second most common etiology of spinal ataxia, eNAD/EDM.[5–7] In Quarter Horses (QHs) and in Warmbloods (WBs), the clinical presentation of eNAD/EDM differs, with QHs displaying an abnormally dull mentation and ataxia at a young age, while WBs often present with acute behavioral changes (aggression, spooking, etc.) and ataxia between 5 and

NOTES

15 years of age.[8] Vitamin E deficiency has been definitively associated with eNAD/EDM in the QHs[9] but not yet in the WBs. Thoroughbreds can fall into either category, manifesting clinical signs as youngsters or later in life. Thus, there may be subcategories of eNAD/EDM that remain to be defined. Currently, a presumptive diagnosis of eNAD/EDM is based on clinical signs and exclusion of other causes of neurological disease.[5] In human medicine, biomarker research has aided in the diagnosis of neurologic diseases. In particular, neurofilaments are structural scaffolding proteins specific to the neuron that are essential for axonal growth. With axonal damage, neurofilaments are accumulated into the cerebrospinal fluid (CSF) and, to a lesser extent, into the blood. Phosphorylated neurofilament heavy protein (pNfH) is one type of neurofilament that has specificity to the nervous system and is particularly resistant to proteases, making it an ideal biomarker.[10] The goal for this "how to" session is to provide guidelines for how to interpret pNfH results in cases of equine neurologic disease.

2. Materials and Methods

The goal of this study was to determine pNfH concentrations, using a pNfH enzyme-linked immunosorbent assay, in serum and CSF from neurologically normal control horses and horses with eNAD/EDM, CVCM, and Shivers. All samples evaluated in the study were from postmortem-confirmed cases of eNAD/EDM ($n = 64$) and CVCM ($n = 26$). Five of the 9 Shivers cases were diagnosed at postmortem and the remaining 4 clinically phenotyped. Control samples ($n = 51$) were collected prospectively from healthy research horses with normal neurologic evaluations at the University of California, Davis Center for Equine Health.[11]

Serum and CSF pNfH concentrations were compared among groups with a Kruskal-Wallis test followed by Dunn's multiple comparisons test with adjustment of the p value for multiple testing. A nonlinear univariate analysis using chi-square contingency tables was performed using data from eNAD/EDM, CVCM, and neurologically normal control horses to determine the association between disease status (eNAD/EDM yes/no) and the following binary variables: age (≤ 5 and > 5 years based on age distribution), sex (male or female), breed (QH or non-QH), CSF total protein (< 80 mg/dL or ≥ 80 mg/dL), and CSF total nucleated cell count ($< 6/\mu$L or $\geq 6/\mu$L). Variables with $p < 0.2$ in the univariate analysis were included in the multivariate logistic regression model. The same univariate analyses were then performed for CVCM (yes/no) for each binary variable. Subsequent multivariate logistic regressions were conducted with eNAD/EDM (yes/no) and CVCM (yes/no) as the outcome variables, whereas serum and CSF pNfH concentrations were considered predictor variables. Due to the small sample size, Shivers affected horses were excluded from the univariate and multivariate analyses.

Subsequently, interval likelihood ratios determination was performed to choose the optimal serum and CSF cutoff point that maximized diagnosis of eNAD/EDM and CVCM. Strength of association between the chosen cutoff point and diagnosis of eNAD/EDM and CVCM was determined by calculating odd ratios using a 2×2 frequency table. Odds ratios < 1 or > 1 and 95% confidence interval excluding 1 and a corresponding $p < 0.05$ were considered significant. Sensitivity and specificity at the chosen cutoff point were also determined from the 2×2 frequency table.

3. Results

Median and 95% confidence interval serum pNfH concentrations in control, CVCM, eNAD/EDM, and Shivers horses can be found in Table 1. CSF pNfH concentrations were significantly higher in CVCM ($p = .001$) and eNAD/EDM ($p = .01$) affected horses compared to control horses. Serum pNfH concentrations >1 ng/mL were significantly associated with eNAD/EDM ($p = .01$), with only 12% sensitivity but 99% specificity. CSF pNfH concentrations > 3 ng/mL were significantly associated with CVCM ($p = .0002$), with 50% sensitivity and 86% specificity.

4. Discussion

Until recently, the only way to definitively diagnose eNAD/EDM was through postmortem histologic evaluation of the brainstem and spinal cord. A biomarker test for pNfH represents the first diagnostic antemortem testing available for eNAD/EDM. Serum and CSF pNfH testing for eNAD/EDM has higher sensitivity in horses < 5 years of age as compared to older horses. This test may still be useful in older horses,

Table 1. Median and 95% CI Serum and CSF pNfH Concentrations for Healthy Control Horses and Horses with CVCM, eNAD/EDM, and Shivers

	Serum (ng/mL)		CSF (ng/mL)	
Group	Median	95% CI	Median	95% CI
Control ($n = 51$)	0.08	0.07–0.15	1.26	1.06–1.5
CVCM ($n = 26$)	0.07	0.07–0.15	3.07	1.15–29.9
eNAD/EDM ($n = 64$)	0.07	0.07–1.13	1.78	1.5–2.28
Shivers ($n = 9$)	<0.07	NA	1.39	0.74–3.89

Abbreviations: CSF, cerebrospinal fluid; CI, confidence interval; CVCM, cervical vertebral compressive myelopathy; eNAD, equine neuroaxonal dystrophy; EDM, equine degenerative myeloencephalopathy.

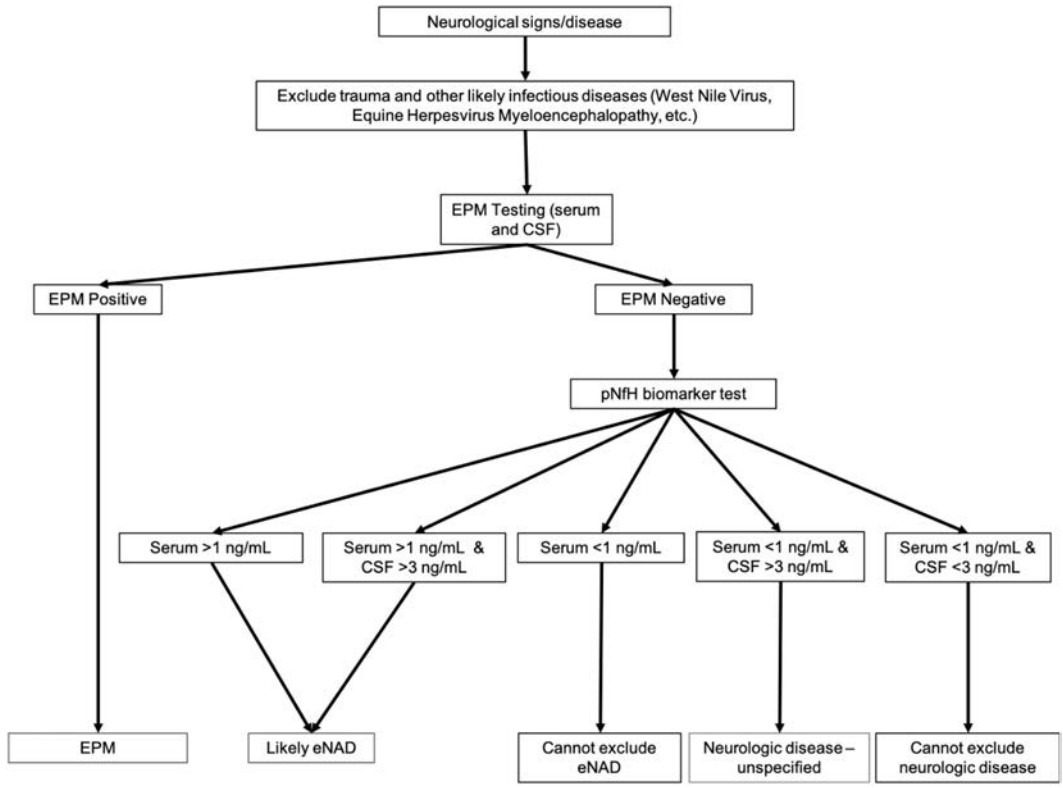

Fig. 1. Diagnostic flow chart for the recommended use of the pNfH test.

but this is an important caveat. Additionally, these increased pNfH values only occurred in non-WB eNAD/EDM cases. Values are only informative if elevated as a normal value (i.e., serum <1 ng/mL and/or CSF <3 ng/mL) does not exclude disease. Of note, there were no samples of horses with EPM assessed in this study. Thus, serum and CSF pNfH results should only be assessed once a horse is negative for infectious disease testing (i.e., EPM, West Nile Virus, etc.).

In conclusion, eNAD/EDM is very likely if serum pNF-H > 1 ng/mL (specificity 99%) in non-WB horses over 1 year of age, for which other causes of neurologic disease have been excluded. Neurologic disease due to either eNAD/EDM or CVCM is very likely if CSF pNF-H > 3 ng/mL (specificity 98% for eNAD/EDM or CVCM). Future studies are required to determine how serum and CSF pNfH concentrations change over time with neurologic disease to identify the potential value in retesting horses with neurologic disease that have levels of pNfH below the limit of detection in serum and CSF. A recommended diagnostic flowchart is included in Fig 1.

Acknowledgments

Funding Sources

This study was supported by the University of California, Davis Center for Equine Health with funds provided by the State of California pari-mutuel fund and contributions by private donors. Additional postdoctoral fellowship support was provided by the American College of Veterinary Internal Medicine, Finno Laboratory, and University of California, Davis Veterinary Medical Teaching Hospital. Support for Carrie J. Finno was provided by the National Institutes of Health (K05OD015134 and L40TR001136).

Declaration of Ethics

The Authors have adhered to the Principles of Veterinary Medical Ethics of the AVMA.

Conflict of Interest

The Authors have no conflicts of interest.

References

1. Mayhew IG. Multifactorial and idiopathic disorders. In: Mayhew IG, ed. *Large animal neurology*. Ames: Wiley-Blackwell, 2009;392–420.
2. Finno CJ, Valberg SJ, Shivers J, et al. Evidence of the primary afferent tracts undergoing neurodegeneration in horses with equine degenerative myeloencephalopathy based on calretinin immunohistochemical localization. *Vet Pathol* 2016;53:77–86.
3. Akter F, Yu X, Qin X, et al. The pathophysiology of degenerative cervical myelopathy and the physiology of recovery following decompression. *Front Neurosci* 2020;14:138.
4. van Biervliet J, Scrivani PV, Divers TJ, et al. Evaluation of decision criteria for detection of spinal cord compression

based on cervical myelography in horses: 38 cases (1981-2001). *Equine Vet J* 2010;36:14–20.
5. Hales EN, Aleman M, Marquardt SA, et al. Postmortem diagnoses of spinal ataxia in 316 horses in California. *J Am Vet Med Assoc* 2021;258:1386–1393.
6. Mayhew IG, deLahunta A, Whitlock RH, et al. Spinal cord disease in the horse. *Cornell Vet* 1978;68:1–207.
7. Nappert G, Vrins A, Breton L, et al. A retrospective study of nineteen ataxic horses. *Can Vet J* 1989;30:802–806.
8. Johnson AL. Equine degenerative myeloencephalopathy: An updated clinical perspective. In *Proceedings*. Am Coll Vet Int Med. Phoenix, AZ 2019 197–198.
9. Aleman M, Finno CJ, Higgins RJ, et al. Evaluation of epidemiological, clinical, and pathological features of neuroaxonal dystrophy in Quarter Horses. *J Am Vet Med Assoc* 2011;239:823–833.
10. Shaw G. The use of pNF-H as a general blood biomarker for axonal loss: An immediate application for CNS injury. In: Kobeissy FH, ed. *Brain neurotrauma: Molecular, neuropsychological and rehabilitation aspects*. Boca Raton: CRC Press/Taylor & Francis, Chapter 21, 2015.
11. Edwards LA, Donnelly CG, Reed SM, et al. Serum and cerebrospinal fluid phosphorylated neurofilament heavy protein concentrations in equine neurodegenerative diseases. *Equine Vet J* 2022;54:290–298.

Long-Term Response of Equids with Pituitary Pars Intermedia Dysfunction to Treatment with Pergolide

Harold C. Schott II, DVM, PhD, DACVIM*; Julie R. Strachota, DVM, MS; Judith V. Marteniuk, DVM, MS; and Kent R. Refsal, DVM, MS, PhD

Long-term treatment of pituitary pars intermedia dysfunction-affected equids with pergolide produces clinical improvement in nearly all affected animals, normalization of endocrine test results in some cases, and high owner satisfaction. Further, this case series provides evidence that some horses may respond favorably long term to a low pergolide dose, rather than needing a progressive increase in dose over time in all pituitary pars intermedia dysfunction-affected equids. Authors' address: Michigan State University, 736 Wilson Road, East Lansing, MI 48824-1314; e-mail: schott@msu.edu. *Corresponding and presenting author. © 2022 AAEP.

1. Background

Limited data exist documenting long-term responses of equids with pituitary pars intermedia dysfunction (PPID) to pergolide treatment.

2. Objectives

The objectives were to report clinical response, medical problems, outcome, and owner satisfaction with pergolide treatment of PPID-affected equids over 0.6 to 11 years.

3. Materials and Methods

There were 30 client-owned equids with PPID in this study. After completion of the field clinical efficacy study for pergolide mesylate[a], 28 horses and 2 ponies were enrolled in an extended pergolide treatment study (15 receiving 2 μg/kg, PO, q 24 h and 15 receiving 4 μg/kg, PO, q 24 h). Equid owners were interviewed every 3 months, and equids were reevaluated after 2.5, 3, 3.5, 4.5, 5.5, 6.5, 9.5, and 12.5 years of treatment.

4. Results

Twenty-nine equids died or were euthanized (5 for chronic laminitis) during the study period (median survival time 3.3 years, range 0.6–12.5 years). Seven out of 15 equids had a dosage increase to 4 μg/kg, PO, q 24 h (maximum study dose) from 1.7 to 4.7 years of the study. After 5.5 years, owners of 13 surviving equids reported continued clinical improvement, and 75% had normal endocrine test results. After 9.5 years of treatment, only 2 out of 6 of surviving equids had normal endocrine test results.

Research Abstract—for more information, contact the corresponding author

NOTES

Acknowledgments

Funding Sources

This study was funded by Boehringer-Ingelheim Health, USA, Inc., and Michigan State University Endowed Research Funds.

Declaration of Ethics

The Authors have adhered to the Principles of Veterinary Medical Ethics of the AVMA.

Conflict of Interest

The Authors declare no conflicts of interest.

Footnote

[a]Prascend®, 1 mg tablets, Boehringer-Ingelheim Animal Health USA, Inc., St. Joseph, MO 64506.

Review of Factors to Consider When Using the Oral Sugar Test to Diagnose Insulin Dysregulation

Amanda Adams, PhD*; and Amy Polkes, DVM, DACVIM

Several factors including "fed vs. fasted" state, dose and type of corn syrup, season, and combination endocrine testing should be considered when performing the oral sugar test in diagnosing insulin dysregulation. Authors' address: University of Kentucky, 108 Gluck Equine Research Center, Lexington, KY 40546; e-mail: amanda.adams@uky.edu. *Corresponding and presenting author. © 2022 AAEP.

1. Introduction

Insulin dysregulation (ID) is the key feature of equine metabolic syndrome and can coexist with pituitary pars intermedia dysfunction (PPID). ID appears to be the driving factor and strongest predictor of the development and reoccurring episodes of endocrinopathic laminitis, or now called hyperinsulinemia-associated laminitis.[1] Prevention of hyperinsulinemia-associated laminitis depends on the ability to diagnose and control ID. ID is defined as any combination of the following: basal (resting) hyperinsulinemia, postprandial hyperinsulinemia (to the oral sugar test [OST] or consumed feeds), or tissue insulin resistance.[1] The most accepted and practical in-field diagnostic tests for ID are measuring resting (basal) insulin and/or performing dynamic testing using the OST.[1] Normal basal insulin values are < 20 μU/mL (radioimmunoassay [RIA] and chemiluminescent assay [Immulite] 1000) and < 31 μU/mL (Immulite 2000 xpi).[1] ID suspect basal insulin values are 20 to 50 μU/mL better assess (RIA and Immulite 1000) and 30 to 75 μU/mL (Immulite 2000 xpi), but for suscept cases, it is best to perform the OST.[1] Abnormal basal insulin values are > 50 μU/mL (RIA and Immulite 1000) and > 75 μU/mL (Immulite 2000 xpi).[1] Abnormal OST insulin values are > 45 μU/mL (RIA) positive for 0.15 mL/kg test.[1] Factors affecting these diagnostic tests such as fed vs. fasted state of the animal, dose of corn syrup, etc. are often debated due to the knowledge base evolving as more research is conducted around these subjects. Thus, the objectives of this review are to provide updates from recent research on factors (fed vs. fasted state, dose and type of corn syrup, seasonal changes, and effects of combination testing) affecting the OST when diagnosing ID.

2. OST – Fed vs. Fasted State

Practicality and accurate diagnosis of ID are both important considerations when developing diagnostic protocols. The state of fed vs. fasted of the equid is an important factor when diagnosing ID with the OST. To

NOTES

clarify here, when referring to fed vs. fasted states, the definition of "fed" describes an animal that has access to some kind of forage, whether it be pasture or hay, but typically no grain, or at the minimum grain is withheld 4 hours prior to testing. The "fasted" state refers to the animal being fasted at the minimum of 3 to 6 hours but oftentimes overnight with no access to grain or forage of either pasture or hay. While fasting is no longer recommended when assessing resting (basal) insulin concentrations, fasting (3–6 hours) has been recommended when performing the OST, even though few studies have been conducted to support this fasting recommendation in ID horses. A study conducted in metabolically normal ponies has shown that fed vs. fasted state does impact the insulin responses to the OST. This study evaluated ponies tested with the OST right off of pasture or after an overnight fast ~10 hours and showed that the fasted ponies had significantly higher insulin responses to the OST when compared to the fed state ponies.[2] However, these researchers conducted another study to investigate the fed vs. fasted state of the OST in distinguishing between previously laminitic vs. nonlaminitic ponies and found there was no difference in insulin responses to the OST in different fasting conditions of the ponies.[3] A very recent study has been conducted in ID horses that evaluated similar conditions of fed vs. fasted states in response to the OST with similar outcomes.[4] Results from this study showed that while ID horses sampled in a fasted state of 3 hours had significantly lower resting insulin concentrations, no differences were found between fed vs. fasted states for insulin responses to the OST.[4] In this study, investigators also evaluated these same responses in non-ID horses and found no difference in insulin responses to the OST in fed vs. fasted non-ID horses.[4] These results are supported from two earlier studies that examined the effects of fed vs. fasted on OST responses in non-ID horses and found no differences in insulin responses.[5–6] Overall, these studies indicate that while there can be differences in the fed vs. fasted state insulin responses to the OST in ponies, this does not seem to be the case for horses. Regardless, fed vs. fasted state results should not be used interchangeably, and when monitoring ID status over time in the same animal, one should use the same method of fed vs. fasted state. If the fed state is used for the OST, it is important to take into consideration the type of forage, and ideally the equid is maintained on a low-nonstructural-carbohydrate forage at the time of sampling. It may also be worthwhile to consider evaluating the insulin responses to feedstuffs as recent research has shown significant differences in postprandial insulin responses of ID horses compared to non-ID horses; this testing could also help with management decisions.[7]

3. OST – Dose and Type of Corn Syrup

The OST is used to try and mimic or reflect the natural, postprandial responses to various feedstuffs in horses, which is useful to study and identify horses with excessive responses of the entero-insular axis to oral sugar. Thus, Karo light corn syrup is used as the sugar challenge in the OST, and this brand formulation is composed of maltose and glucose. However, Karo is not available in all countries, and thus the type of corn syrup and differences in composition can potentially impact insulin results. A recent study evaluated the insulin responses of horses receiving either Karo light corn syrup or Crown Lily white, a corn syrup available in Canada, and found no significant differences between insulin responses to the OST when using Karo or Crown corn syrups in horses.[6] The dose of corn syrup to use in the OST is oftentimes questionable as to whether to use the low dose (0.15 mL/kg) or the high dose (0.45 mL/kg) of corn syrup. Research in ponies has shown that when using the higher dose, stimulated insulin responses to the OST were better able to distinguish between previously laminitic ponies or nonlaminitic ponies, while they found no difference in responses to the low dose of corn syrup.[3] A recent study conducted in both non-ID and ID horses comparing the low- vs. high-dose OST found no difference in 60-minute insulin responses between the two doses in either non-ID or ID horses.[4] Thus, these results indicate that a low-dose OST at this time is appropriate for diagnosing ID in horses, but a high-dose OST may be useful when equivocal cases are detected and being monitored.

4. OST – Season

It is known that season impacts the hypothalamic-pituitary-adrenal axis; thus, there is a need for seasonal hormone reference ranges, for example, for adrenocorticotropic hormone when diagnosing PPID; however, very little is known about the effects of season on insulin responses to the OST. A recent study performed OSTs across seasons on a group of horses from Finland and found no differences or seasonal patterns in insulin responses to the OST; however, they found insulin dysregulation status varied throughout the year.[8] The authors indicated several limitations of this study that could have influenced the study results.[8] Even more recently, a study conducted in Kentucky evaluated the effects of season on insulin responses to the OST in ID and non-ID horses over a 2-year period and found significant effects of season on insulin responses to the OST.[9] This study found that for non-ID horses, season had no effect on basal or resting insulin concentrations, but it also found that OST insulin values were higher in the spring vs. summer. Further results from this study showed that season affected both basal insulin and insulin responses to the OST in ID horses, with both being higher in spring than fall and summer, and winter OST responses were higher than fall.[9] In this study, horses changed their ID categorization across season, and relying only on basal insulin, ID status across seasons was confirmed only 21.1% to 63.6% of the time, while OST insulin responses across season confirmed ID 84.2% to 100% of the

time.[9] Therefore, regardless of seasonal changes, if the OST was used, ID diagnosis would be consistent. Season should be considered when monitoring horses across season when using the OST.

5. OST – Combination Testing

Oftentimes, for practicality, concurrent testing for PPID and ID are of interest and valuable given both endocrine disorders can coexist. Thus, a protocol that combines using the thyrotropin-releasing hormone (TRH) stimulation test and the OST test is a practical means; however, until recently, it was not known if one test would impact results of the other or vice versa. A recent study was conducted to investigate these questions in a prospective randomized placebo-controlled, crossover design comparing 3 OST protocols: OST alone, TRH followed by OST (TRH + OST), and placebo followed by OST (placebo + OST) in horses.[10] The results of this study found no difference in insulin responses to the OST when performing the TRH stimulation test prior to the OST.[10] Thus, a practical protocol for diagnosing PPID and ID can utilize the TRH stimulation test prior to the OST on the same day of testing and not have an impact on the OST results.

6. Discussion

In fed vs. fasted states, insulin responses to the OST can differ, but more so in ponies than horses; thus, results should not be used interchangeably. In monitoring ID status over time in the same animal, one should use the same method of fed vs. fasted state. If the fed state is used for the OST, it is important to take into consideration the type of forage, and ideally the equid is maintained on a low-nonstructural-carbohydrate forage at the time of sampling. Recent research in horses indicates that a low-dose OST is appropriate for diagnosing ID, but a high-dose OST may be useful when equivocal cases are detected or in question. No differences in insulin responses to the OST have been found when using Karo light corn syrup compared to Crown Lily white corn syrup. Season appears to impact insulin responses; however, if the OST is used across seasons, the ID diagnosis is consistent. Regardless, one should be aware and consider season when monitoring and diagnosing ID. Concurrent testing using the TRH stimulation prior to the OST does not seem to impact insulin responses and thus is a practical protocol to consider when endocrine screening for concurrent endocrine disorders of PPID and ID.

Acknowledgments

Declaration of Ethics

The Authors have adhered to the Principles of Veterinary Medical Ethics of the AVMA.

Conflict of Interest

The Authors have no conflicts of interest.

References

1. Frank N, Bailey S, Bertin F, et al. Recommendations for the diagnosis and treatment of equine metabolic syndrome (EMS). Equine Endocrinology Group. Available from: https://sites.tufts.edu/equineendogroup/files/2020/09/200592_EMS_Recommendations_Bro-FINAL.pdf.
2. Knowles EJ, Harris PA, Elliott J, et al. Use of the oral sugar test in ponies when performed with or without prior fasting. *Equine Vet J* 2017;49:519–524.
3. Jocelyn NA, Harris PA, Menzies-Gow NJ. Effect of varying the dose of corn syrup on the insulin and glucose response to the oral sugar test. *Equine Vet J* 2018;50:836–841.
4. Macon EL, Harris P, Partridge E, et al. Effect of dose and fasting on oral sugar test responses in insulin dysregulated horses. *J Equine Vet Sci* 2021;107:103770.
5. Banse HE, McFarlane D. Comparison of three methods for evaluation of equine insulin regulation in horses of varied body condition score. *J Equine Vet Sci* 2014;34:742–748.
6. Moser K, Banse H. Comparison of the glucose and insulin responses of horses to 2 formulations of corn syrup. *Can Vet J* 2019;60:637–643.
7. Macon EL, Harris P, Bailey S, et al. Postprandial insulin responses to various feedstuffs differ in insulin dysregulated horses compared with non-insulin dysregulated controls. *Equine Vet J* 2022;54:574–583.
8. Karikoski NP, Box JR, Mykkänen AK, et al. Variation in insulin response to oral sugar test in a cohort of horses throughout the year and evaluation of risk factors for insulin dysregulation. *Equine Vet J*. Published online October 28, 2021.
9. Macon EL, Harris PA, Barker VD, et al. Seasonal insulin responses to the oral sugar test in healthy and insulin dysregulated horses. *J Equine Vet Sci* 2022;113:103945.
10. Hodge E, Kowalski A, Torcivia C, et al. Effect of thyrotropin-releasing hormone stimulation testing on the oral sugar test in horses when performed as a combined protocol. *J Vet Intern Med* 2019;33:2272–2279.

Review of Considerations When Feeding the Equid with Insulin Dysregulation

P.A. Harris, MA, VetMB, PhD, DipECVCN, MRCVS, RCVS Specialist Clinical Nutrition (equine)

Whilst animals with insulin dysregulation are often obese, they can be lean and therefore the dietary goal may be weight maintenance, gain, or loss. As the dietary insulin response is variable, and all the nutritional triggers are unknown, it is advisable to monitor the individual's response to their specific diet if it is considered essential to induce only a low insulin response. For some individuals, very low starch and sugar intakes per meal (<0.1 g/kg body weight/meal) may be required to elicit such a low response. Repeat monitoring is key. Author's address: Waltham Petcare Science Institute, Freeby Lane, Waltham on the Wolds, Nr Melton Mowbray, Leicestershire LE14 4RT, United Kingdom; e-mail: pat.harris@effem.com. © 2022 AAEP.

1. Introduction

Insulin dysregulation (ID) reflects the presence of 1 or more of the following: basal or fasting hyperinsulinemia, tissue insulin resistance, exaggerated insulin response to ingested nonstructural carbohydrates (i.e., starch, simple sugars, and fructans), and/or exaggerated insulin response to intravenously provided simple sugars.[1] ID is recognized as the main consistent feature of the equine metabolic syndrome (EMS) with an associated increased risk of laminitis.[2,3] In addition, as equids age, there is a tendency for them to show exaggerated postprandial insulin responses, especially to high-starch-providing diets.[4,5] Not all EMS animals or aged ID animals, however, are obese and therefore nutritional management of an ID animal needs to take into account various factors including body condition score (BCS), age, and pituitary pars intermedia dysfunction (PPID) status as discussed by Galinelli et al.[6] ID status is not necessarily consistent and therefore monitoring and repeat testing is essential, especially in animals at increased risk. Recent research has highlighted the fact that dietary recommendations for ID animals cannot be based on those for non-ID,[7] and this review addresses this factor as well as other considerations when feeding the ID animal. This review also addresses the request from equine practitioners for more information regarding the feeding of animals with insulin dysregulation.[8]

2. General Principles

The primary goal in the feeding management of horses and ponies with ID (obese or nonobese) is avoidance of feeds rich in nonstructural carbohydrates (NSC: = starch + WSC [water-soluble carbohydrates: simple sugars and fructans]) that may increase risk of laminitis, either by exacerbation of hyperinsulinaemia[9] or possibly via disturbances to the hindgut microbial community that may trigger events that

NOTES

lead to laminitis. For lean animals, the objective may be weight maintenance or even weight gain using feeds and forages that do not promote an exaggerated insulin response. An essential goal in the obese insulin dysregulated animal is to promote weight loss primarily through restricting energy intake supported by increased energy expenditure.[10] Further work, however, is needed with respect to insulin sensitizing agents/dietary supplements in the horse.[11] The general guidelines for feeding management of insulin resistant horses are included below.

1. ***The removal of cereal grains and high/moderate NSC sweet/complementary feeds*** (i.e., feedstuffs rich in starch and/or sugars) from the diet. The starch contents of oats, barley, and corn are approximately 45% to 55%, 60% to 65%, and 65% to 75% of the dry matter (DM), respectively, and some sweet feeds can be up to 50% NSC on a DM basis.
2. ***Feeding multiple small low NSC meals.*** Today, many complementary feeds are available with a low or restricted NSC content (e.g., <15%-20% NSC) on a DM basis and are fed with the aim of producing a low or low-moderate postprandial insulin response. For some ID animals, such feeds fed in several small meals may be suitable especially for animals considered at a lower laminitis risk. However, recent work has suggested that severely ID animals can have exaggerated insulinemic responses even to small intakes of complementary feeds with a threshold between 0.08 and 0.15 g NSC/kg body weight (BW)/meal.[7] Unlike for non-ID animals, this means that feeding relatively small amounts of even restricted (15%–20% NSC on a DM basis) may provoke an augmented insulin response in such ID animals. Based on this work at the moment, severely ID animals should be restricted to 0.1 g NSC/kg BW/meal if a very low postprandial insulin response is required in animals at high risk for laminitis. In older animals with age-associated increases in insulin responses that are not considered at high risk of laminitis, then based on Jacob et al,[5] the levels could be increased to ~0.5 g NSC/kg BW/meal in most individuals.

Practically, this means feeding even the forage balancer type of complementary feeds in multiple small meals a day to some severely ID animals.

3. ***Restricted or zero access to pasture.*** Pasture access may have to be restricted to help with weight management and to prevent increases in plasma insulin concentrations. It is well appreciated that pasture turnout, particularly at certain times of the year, can increase the risk of laminitis.[12,13] Pasture DM intake can reach up to 40% of daily DM intake and around 1% BW in DM within 3 hours and up to 5% BW DM/d in some individuals.[14] Especially with cool season grasses, pasture NSC content can be 30+% on a DM basis in some places at certain times of day. Pasture plants other than grasses can also have high NSC contents.[15] Even with moderate NSC content, if there is a plentiful supply of plant material, the overall NSC intake, even within a relatively short period of time, can be quite high in some individuals. Certain individuals as mentioned above may be particularly sensitive to even relatively low NSC intakes.

Practically, it means for some individual animals, access to pasture has to be prevented or highly restricted, especially at certain times of the year. Strategies such as the use of track systems, strip grazing, grazing muzzles, and rotational grazing may need to be considered depending on individual circumstances, but monitoring is essential.[16–18] *It is important to note that compensatory intake can occur in animals left grazing/foraging once any grazing muzzle has been removed, which may increase the risk of laminitis.*[16,19]

4. ***A diet based on grass hay (or hay substitute) with low (<10%–12% DM) NSC content.*** It has been recommended that the minimum forage DM intake for horses should be 1.5% BW on a DM basis and that where possible the energy content of the forage being fed should be chosen to ensure such an intake can be provided.[14,20] However, for the obese ID animal, even low energy forage (<8 MJ/KG DM) may need to be restricted (short term) even lower to 1.25 or even 1% BW DM.[10] For the ID animal, it is recommended for the forage to have a low (<10%–12% on a DM basis) NSC content.

It is not possible to determine the NSC content of forage by eye, although warm season hays, for example, may "naturally" have a lower NSC content than cool season grasses, but other factors may need to be considered when choosing such hays.[21] For example, teff hay has been found to be a source of the prohibited substance synephrine in some instances. If it is essential that the individual is fed a low NSC forage, then analysis is essential (wet chemistry recommended) and/or monitoring the insulin response to feeding the specific batch of forage (and repeating with new batches, which should be introduced gradually). The author recommends that hay rather than haylage is fed to ID animals, not least because haylage may promote a greater insulin response for a given level of consumed NSC in ID animals.[14,22]

Practically, hay soaking can result in around 40% loss of WSC content and therefore is a useful adjunct to managing both overweight animals and those prone to laminitis. However, especially with cool season grasses, WSC loss is highly variable and not predictable.[23] *In addition, it is important to remember that DM is also lost with soaking, as well as some soluble protein and*

a proportion of certain vitamins, minerals, and trace elements. Therefore, it is necessary to allow for 20% loss of DM with soaking when calculating hay intakes and importantly provide an appropriate forage balancer, especially when feeding soaked forage but also if feeding a forage-based diet or less than recommended intakes of the core complementary feed.[14] *As the postprandial insulin response is very variable, and all the nutritional triggers are unknown, it is advisable to monitor repeatedly the individual animal's response to both complementary feed and forage if it is considered essential to induce only a low insulin response to their diet.*

5. ***Feeding for maintenance of bodyweight and BCS.*** Although many ID animals may be obese, some lean animals can be ID, especially older animals. However, weight gain will typically exacerbate insulin resistance, so it is important to avoid overfeeding, and if the equid is obese, then it is important to initiate a program of weight management with, whenever possible, increased exercise as this may help improve insulin sensitivity.[10,24] Regular evaluation of bodyweight and/or BCS is the best way to assess the adequacy or otherwise of energy provision. If additional energy is required, then it is important that the feedstuffs provided support a low postprandial insulin response. Feeds to consider (depending on clinical situation) include supplemental vegetable oil and/or feeding highly digestible fiber sources (e.g., soaked unmolassed sugar beet; soya hulls) and/or a low-starch and sugar commercial fortified complementary feed, which ideally has been shown to produce in target animals a low postprandial glucose/insulin response.

If vegetable oil is to be added to the existing low NSC fortified ration (corn and soy oils are typically used), it needs to be fresh, nonrancid, and introduced gradually (starting around 30–50 mL/500 kg horse once daily and increasing over 7–21 days). Fecal quality should be monitored and reassessment made if there is evidence of, for example, steatorrhea or issues with palatability. One standard cup (about 225 mL or 210 g) of vegetable oil provides ~7 MJ of digestible energy, and depending on energy requirements, ½ to 1 cup of oil can be fed once or twice daily (up to a maximum of ~1 mL oil/1 kg bodyweight without specialist nutritional consideration). Supplemental antioxidant (1–2 IU vitamin E per 1 mL of added oil) should be provided. Calcium-supplemented stabilized rice bran (~20% fat) or commercial fortified high vegetable fat/oil low NSC diets are alternatives.

6. **Exercise.** Increasing free and/or structured exercise, based on veterinary advice, may help limit muscle loss associated with calorie-restricted diets, and can have an anti-inflammatory effect, and even at relatively low intensities and duration (e.g., working trot for 15 minutes) can promote improved insulin sensitivity.[24,25]

Consideration should be given to increasing the number, length, or intensity of exercise occasions, or changing the type of structured activity (riding/lunging, etc.), as well prolonging free activity in the paddock. Track systems or similar may be a solution for some but consideration of land suitability and so forth is required.

3. Conclusion

It is important when managing an ID animal to develop a targeted nutrition (and exercise) plan for that individual animal and its clinical needs that considers the available complementary feeds/forages as well as facility/time, constraints of the owner/carer, and so on. Monitoring is essential, as is good communication between the veterinarian and the owner/carer.

Acknowledgments

Declaration of Ethics

The Author has adhered to the Principles of Veterinary Medical Ethics of the AVMA.

Conflict of Interest

The Author is employed by Mars Petcare UK.

References

1. Bertin FR, De Laat MA. The diagnosis of equine insulin dysregulation. *Equine Vet J* 2017;49:570–576.
2. Durham AE, Frank N, McGowan CM, et al. ECEIM consensus statement on equine metabolic syndrome. *J Vet Intern Med* 2019;33:335–349.
3. Harris PA, Bamford NJ, Bailey SR. Equine metabolic syndrome: Evolution of understanding over two decades: A personal perspective. *Anim Prod Sci* 2020;60:2103–2110.
4. Rapson JL, Schott IIH, Nielsen BD, et al. Effects of age and diet on glucose and insulin dynamics in the horse. *Equine Vet J* 2018;50:690–696.
5. Jacob SI, Geor RJ, Weber PSD, et al. Effect of age and dietary carbohydrate profiles on glucose and insulin dynamics in horses. *Equine Vet J* 2018;50:249–254.
6. Galinelli N, Bailey S, Bamford N, et al. Nutritional considerations for the management of equine pituitary pars intermedia dysfunction. *Equine Vet Educ* 2022, in press.
7. Macon EL, Harris P, Bailey S, et al. Postprandial insulin responses to various feedstuffs differ in insulin dysregulated horses compared with non-insulin dysregulated controls. *Equine Vet J* 2022 May;54(3):574–583. doi: http://dx.doi.org/10.111/evj.13474. Epub 2021 Jul 8. 34053111.
8. Nichols JL, Robinson JS, Hiney KM, et al. An investigation into equine nutrition knowledge and educational needs of equine veterinarians. *J Vet Med Educ* 2022. e20210121.
9. Meier AD, De Laat MA, Reiche DB, et al. The oral glucose test predicts laminitis risk in ponies fed a diet high in non-structural carbohydrates. *Domest Anim Endocrinol* 2018;63:1–9.
10. Shepherd M, Harris P, Martinson KL. Nutritional considerations when dealing with an obese adult equine. *Vet Clin North Am Equine Pract* 2021;37:111–137.
11. Vervuert I, Stratton PM. The safety and efficacy in horses of certain nutracuticals that claim to have health benefits. *Vet Clin North Am Equine Pract* 2021;37:206.

12. Geor RJ, Harris P. Laminitis. In Geor RJ, Harris P, Coenen M, eds. *Equine Clinical and Applied Nutrition*. London, UK: Elsevier; 2013:469–486.
13. Harris PA. Nutritional management for avoidance of pasture-associated laminitis. In: Belknap J, ed. *Equine Laminitis*. West Sussex, UK: John Wiley; 2017:436–441.
14. Harris P, Shepherd M. What would be good for all veterinarians to know about equine nutrition. *Vet Clin North Am Equine Pract* 2021;37:1–20.
15. Longland AC. Pastures and pasture management. In Geor RJ, Harris P, Coenen M, eds. *Equine Clinical and Applied Nutrition*. London, UK: Elsevier; 2013:332–350.
16. Longland A, Barfoot C, Harris P. Efficacy of wearing grazing muzzles for 10 hours per day on controlling bodyweight in pastured ponies. *J Equine Vet Sci* 2016;45:22–27.
17. Longland AC, Barfoot C, Harris PA. Strip-grazing: Reduces pony dry matter intakes and changes in bodyweight and morphometrics. *Equine Vet J* 2022;54:159–166.
18. Cameron A, Longland A, Pfau T, et al. The effect of strip grazing on physical activity and behaviour in ponies. *J Equine Vet Sci* 2022;110:103745.
19. Pollard D, Wylie CE, Verheyen KLP, et al. Identification of modifiable factors associated with owner-reported equine laminitis in Britain using a web-based cohort study approach. *BMC Vet Res* 2019;15:59.
20. Harris PA, Ellis AD, Fradinho MJ, et al. Review of feeding conserved forage to horses: Recent advances and recommendations. *Animal* 2017;11:958–967.
21. Richards N, Nielsen BD, Finno CJ. Nutritional and nonnutritional aspects of forage. *Vet Clin North Am Equine Pract* 2021;37:43–61.
22. Carslake HB, Argo CM, Pinchbeck GL, et al. Insulinaemic and glycaemic responses to three forages in ponies. *Vet J* 2018;235:83–89.
23. Longland AC, Barfoot C, Harris PA. Effects of soaking on the water-soluble carbohydrate and crude protein content of hay. *Vet Rec* 2011;168:618.
24. Bamford NJ, Potter SJ, Baskerville CL, et al. Influence of dietary restriction and low-intensity exercise on weight loss and insulin sensitivity in obese equids. *J Vet Intern Med* 2019;33:280–286.
25. Menzies-Gow NJ, Wray H, Bailey SR, et al. The effect of exercise on plasma concentrations of inflammatory markers in normal and previously laminitic ponies. *Equine Vet J* 2014;46:317–321.

Ertugliflozin in the Management of Hyperinsulinemia and Laminitis

Tania Sundra, BSc.(Hons), BVMS, MANZCVS (Equine Medicine); Erin Kelty, BSc, PhD; and David Rendle, BVSc, MVM, CertEM (IntMed), DipECEIM*

In horses with endocrinopathic laminitis, ertugliflozin administration was associated with significant reductions in insulin concentrations and lameness within 30 days. Authors' address: Avon Ridge Equine Veterinary Services, Brigadoon, Western Australia, Australia; e-mail: info@avonridgeequine.com.au. *Corresponding and presenting author. © 2022 AAEP.

1. Background

Endocrinopathic laminitis associated with persistent hyperinsulinemia is encountered commonly in equine practice. There are currently no registered medications that specifically target hyperinsulinemia in horses and ponies. Sodium glucose cotransporter 2 inhibitors (SGLT2i) have been demonstrated to limit postprandial insulin responses and prevent the development of experimental diet-induced laminitis. This study reports clinical experiences of ertugliflozin in the treatment of naturally occurring hyperinsulinemia and laminitis.

2. Materials and Methods

Data was collected from a clinical case series. Records were reviewed to identify horses with hyperinsulinemia and laminitis that had been treated with ertugliflozin (in the absence of other insulin-sensitizing drugs or diet change) at 0.05 mg/kg once daily for a minimum of 30 days. Treatment responses were assessed using a Wilcoxon matched-pairs signed-rank test.

3. Results

Thirty-six horses met the inclusion criteria. After 30 days of treatment, mean (SD) insulin concentration reduced from 224 (100) to 59 (58) μu/mL ($P < .001$). Modified Obel laminitis scores reduced from 7.9/12 to 1.3/12 ($P < .001$). Mean (SD) serum triglyceride concentrations rose from 0.67 (0.48) mmol/L to 3.14 (3.62) mmol/L after treatment ($P < .001$). Mean (SD) body weight reduced from 307 (163) kg to 285 (160) kg ($P < .001$). In a subsection of 25 horses examined after 1 day of treatment, insulin concentration had decreased to a mean (SD) of 77 (68) μu/mL ($P < .001$) and triglycerides increased to a mean (SD) of 1.66 (1.57, $P < .001$). No adverse clinical effects were identified in horses treated for up to 6 months. Hyperlipidemia was not associated with clinical signs of hyperlipemia. Urine glucose concentrations ranged from 2.8 to 55.5 mmol/L.

Research Abstract—for more information, contact the corresponding author

NOTES

4. Discussion

Ertugliflozin may be effective in reducing insulin concentrations and aiding recovery from laminitis. The use of ertugliflozin for the prevention and management of laminitis associated with hyperinsulinemia merits further investigation. This study was limited by small case numbers and retrospective data collection.

Acknowledgments

Funding Source

BOVA AUS subsidized some of the laboratory fees.

Declaration of Ethics

The Authors have adhered to the Principles of Veterinary Medical Ethics of the AVMA.

Conflict of Interest

Dr. David Rendle provides consultancy services to BOVA AUS and BOVA UK, who produce an extemporaneous ertugliflozin paste. Drs. Sundra and Kelty have no conflicts of interest.

Right Dorsal Colitis: Is This Similar to Cystic Fibrosis in People?

Anje G. Bauck, DVM, PhD, DACVS*; and David E. Freeman, MVB, PhD, DACVS

Different mechanisms of bicarbonate (HCO_3^-) secretion between right dorsal colon (RDC) and right ventral colon (RVC) could explain right dorsal colitis. Authors' address: Department of Large Animal Clinical Sciences, College of Veterinary Medicine, University of Florida, 2015 SW 16th Avenue, Gainesville, FL 32608; e-mail: baucka@ufl.edu. *Corresponding and presenting author. © 2022 AAEP.

Introduction

Right dorsal colitis is a disease with high morbidity and variable response to treatment. Horses treated with phenylbutazone (PBZ) are at greatest risk. Objectives of this study were to characterize bicarbonate (HCO_3^-) secretion in equine colon ex vivo and to determine the effect of PBZ on this secretion.

Materials and Methods

Mucosa was collected from anesthetized horses (n = 10) to measure HCO_3^- secretion ex vivo (pH Stat Method). The effect of PBZ on HCO_3^- secretion was studied in 4 horses.

Results

Secretion of HCO_3^- was considerably greater in the RDC ($P < .05$) than the RVC and involved different transport mechanisms. The primary transporter of HCO_3^- in the RDC was consistent with cystic fibrosis transmembrane conductance regulator (CFTR), the failed transporter in human cystic fibrosis. In the RDC, HCO_3^- secretion was decreased by PBZ ($P < .05$), probably through inhibition of CFTR.

Discussion

As in other species, secretion of HCO_3^- in the RDC could protect mucosa from injury caused by intense microbial production of short-chain fatty acids. Inhibition of CFTR by PBZ could inhibit mucosal buffering with HCO_3^- and thereby cause right dorsal colitis. Consequently, PBZ-induced right dorsal colitis could be similar to cystic fibrosis in human and rodent models. These findings reveal a potential treatment for right dorsal colitis through dietary or other methods of delivering buffer to the RDC.

Acknowledgments

Declaration of Ethics

The Authors have adhered to the Principles of Veterinary Medical Ethics of the AVMA.

Research Abstract—for more information, contact the corresponding author

NOTES

Conflict of Interest

The Authors have no conflicts of interest.

Disclaimer

Powdered phenylbutazone[a] at a concentration of 3.24×10^{-6} M (1 μg/mL) was used in the in vitro Ussing chambers studies. A compounded product was used because this is an in vitro study and did not involve administering the product to an animal. Various additives are added to the injectable and oral forms of phenylbutazone used commercially. It was important to have pure phenylbutazone diluted to an appropriate concentration in this study.

Footnote

[a]Sigma-Aldrich, Inc., St Louis, MO 63103.

Red Cell Distribution Width Values and Red Cell Distribution Width to Platelet Ratio in Thoroughbred Foals in the First 24 Hours of Life

Rebeca Scalco, DVM*; Monica Aleman, MVZ Cert., PhD, DACVIM (LAIM, Neurology); Carlos Eduardo Wayne Nogueira, DVM, MSc, PhD; Natalia Freitas, DVM; and Bruna da Rosa Curcio, DVM, MS, PhD

Red blood cell distribution width (RDW) and RDW to platelet (RPR) ratio have been reported to be an indicator of systemic inflammation in humans. RPR was higher in neonatal foals at-risk of disease, suggesting that it could be useful to aid the field triage of foals. RDW values did not differ between healthy full-term foals and at-risk foals. Authors' address: University of California-Davis, One Shields Avenue, Tupper Hall - Room 3118, Davis, CA 95616; e-mail: rscalco@ucdavis.edu *Corresponding and presenting author. © 2022 AAEP.

1. Introduction

Sepsis remains the leading cause of death among foals up to 7 days of age. Red blood cell distribution (RDW) and RDW platelet (RPR) have been used in human medicine as markers of inflammation in many diseases.

2. Objectives

To report the values of RDW and RPR and to investigate its possible application in neonatal foals classified as healthy or at-risk based on clinical information from a population of foals up to 24 hours of life.

3. Materials and Methods

This was a retrospective study of 309 full-term Thoroughbred foals $\leq$ 24 h of age. Foals were evaluated within 15 minutes after birth, and blood sample collected within 24 h of life. Risk-score was calculated based on clinical and obstetric data and foals were divided in Healthy and At-risk.

4. Results

Based on risk-score, 88 of 309 foals (28.4%) were considered at risk of perinatal disease. RDW values did not differ between groups. RPR index was higher for at-risk (0.073 $\pm$ 0.018) than for healthy foals (0.068 $\pm$ 0.014, $P = 0.01$).

5. Conclusion and Clinical Importance

RPR might be a promising early indicator of disease for the field triage of neonatal foals, and rapidly estimate possible systemic disorders.

Research Abstract—for more information, contact the corresponding author

NOTES

Acknowledgments

Declaration of Ethics

The Authors have adhered to the Principles of Veterinary Medical Ethics of the AVMA.

Conflict of Interest

The Authors have no conflicts of interest.

Climbing Mt. Debt: Navigating Student Loans and Repayment Strategies

Tony Bartels, DVM, MBA*; and Paul Pion, DVM, DACVIM

Like any challenging medical case, evaluating and treating your student loans clinically can help to reduce both the financial and emotional stress. Federal student loans are the most flexible loans veterinarians will encounter in their lifetime. Using knowledge of the repayment options and metrics like student debt to income ratio, a veterinarian can craft a flexible repayment strategy to manage any amount of student debt or income situation they encounter. Authors' addresses: (Cardiology) Veterinary Information Network (VIN) (Bartels); VIN Foundation (Pion), Davis, 777 West Covell Blvd., Davis, CA 95616; e-mail: tonyb@vin.com. *Corresponding and presenting author. © 2022 AAEP.

1. Introduction

For those graduating from a U.S. veterinary school in 2020, the mean reported debt for those with student loans was about $189,000. Forty-eight percent of those report debt above $200,000, with a growing number of graduates in the $300,000 and $400,000 ranges.[1] Student debt continues to grow at a rate faster than starting incomes. Disparities between student debt and starting income are particularly problematic for equine practitioners who report the lowest starting salaries, about $59,000 for 2020 graduates,[1] where choosing an appropriate repayment strategy is imperative.

This article will discuss how to analyze student loans and the assorted options available, including income-driven repayment (IDR) plans[2] and the associated side effects of any student loan repayment strategy.

The objectives are listed below:

- Know your student debt and repayment options
- Know the challenges and side effects of various repayment strategies
- Craft a student loan strategy to match your student debt to income ratio
- Think beyond student loans to financial wellness

2. Solution

For the individual borrower, the most important factor for determining a student loan repayment strategy is their student debt to income ratio. The quickest way to calculate student debt to income ratio is to take annual taxable income and divide it by the total student debt balance.

Student debt to income ratios less than one favor more traditional repayment methods and strategies. Student debt to income ratios greater than one favor IDR strategies. Most veterinarians fall into the latter scenario, particularly in the early years after school. Knowing how to navigate the options available can

NOTES

Loan Repayment Summary

SAVE/SHARE	STD 10 YR	STD 25 YR	IBR 2009	IBR 2014	PAYE	REPAYE
Starting Repayment Balance:	$200,000	$200,000	$200,000	$200,000	$200,000	$200,000
Interest rate (Wtd Avg):	5.75%	5.75%	5.75%	5.75%	5.75%	5.75%
Year 1 Monthly Payment:	$0 to $2,195	$0 to $1,258	$0 to $495	$0 to $330	$0 to $330	$0 to $330
Next 2 years (24 months) total payments:	$48,298	$27,680	$14,576	$9,717	$9,717	$9,717
Next 5 years (60 months) total payments:	$127,332	$72,976	$51,146	$34,097	$34,097	$34,097
Years to Repay:	10.25 years	25.25 years	25 years	20 years	20 years	25 years
Total Minimum Monthly Payments [a]:	$263,446	$377,463	$407,054	$197,449	$197,449	$271,369
Total Additional Monthly Contribution [b]:	$0	$0	$0	$0	$0	$0
Principal Forgiven:	$0	$0	$15,890	$200,000	$200,000	$195,947
Unpaid Interest Forgiven:	$0	$0	$0	$30,634	$30,634	$0
Amount Forgiven:	$0	$0	$15,890	$230,634	$230,634	$195,947
Taxes on Forgiveness (30%) [c]:	$0	$0	$4,767	$69,190	$69,190	$58,784
Total Cost of Loan [a-b-c]:	$263,446	$377,463	$411,821	$266,639	$266,639	$330,153
Effective Interest Rate:	3.12%	3.53%	4.24%	1.67%	1.67%	2.60%

Fig. 1. Loan repayment summary table.

significantly reduce the financial and mental distress of student loans.

3. Results

Consider the case of a 2022 graduate veterinarian pursuing equine practice in Texas. The equine practitioner graduates with $200,000 of federal student debt with an average interest rate of 5.75%. She is single with a starting income of $60,000/year, increasing to $85,000 in year two, and $100,000 in year three.[4] After year three, an increase of 3% per year will be applied.

Her starting student debt to income ratio is 3.3, decreasing to about 2.3 in year two, and about 2 in year three. With a student debt to income ratio consistently above one for the first three years after graduation, a federal IDR plan like Pay-As-You-Earn (PAYE) can help to minimize financial risk, maximize cash flow, and often lower the total repayment cost. As the name implies, the payment is a function of income, taxable income specifically. As income goes up, the payment increases. If income goes down, the payment decreases. IDR requires proof of taxable income and family size at least annually.

A variable payment structure can make interpreting IDR plans difficult. Using a tool like the VIN Foundation Student Debt Center and Student Loan Repayment Simulator can help to compare projected IDR costs vs. traditional time-driven plans. Figure 1 illustrates a comparison of repayment projections for this case.[5]

The advantage of IDR in the early years of repayment are the significantly reduced minimum monthly payments as compared to a time-driven plan. A lower monthly payment increases cash flow to help the veterinarian build a financial wellness plan, including an emergency fund, retirement plan, home down payment, practice start-up/buy- in, etc.

Student loan repayment flexibility is more important than reducing the total repayment cost. Sacrificing critical areas of financial wellness in favor of higher student loan payments can put the recent graduate veterinarian further behind. Reviewing the Loan Repayment Summary results in Fig 1, the minimum monthly payment due using an IDR plan like PAYE is $330/month as compared to a minimum payment of $2,195/month using a standard 10-year repayment plan. Over the first two years of repayment, PAYE will free up more than $40,000 in cash flow, and nearly $100,000 the first five years of repayment.

Working down the Loan Repayment Summary table in Figure 1, there is a forgiven balance projected with

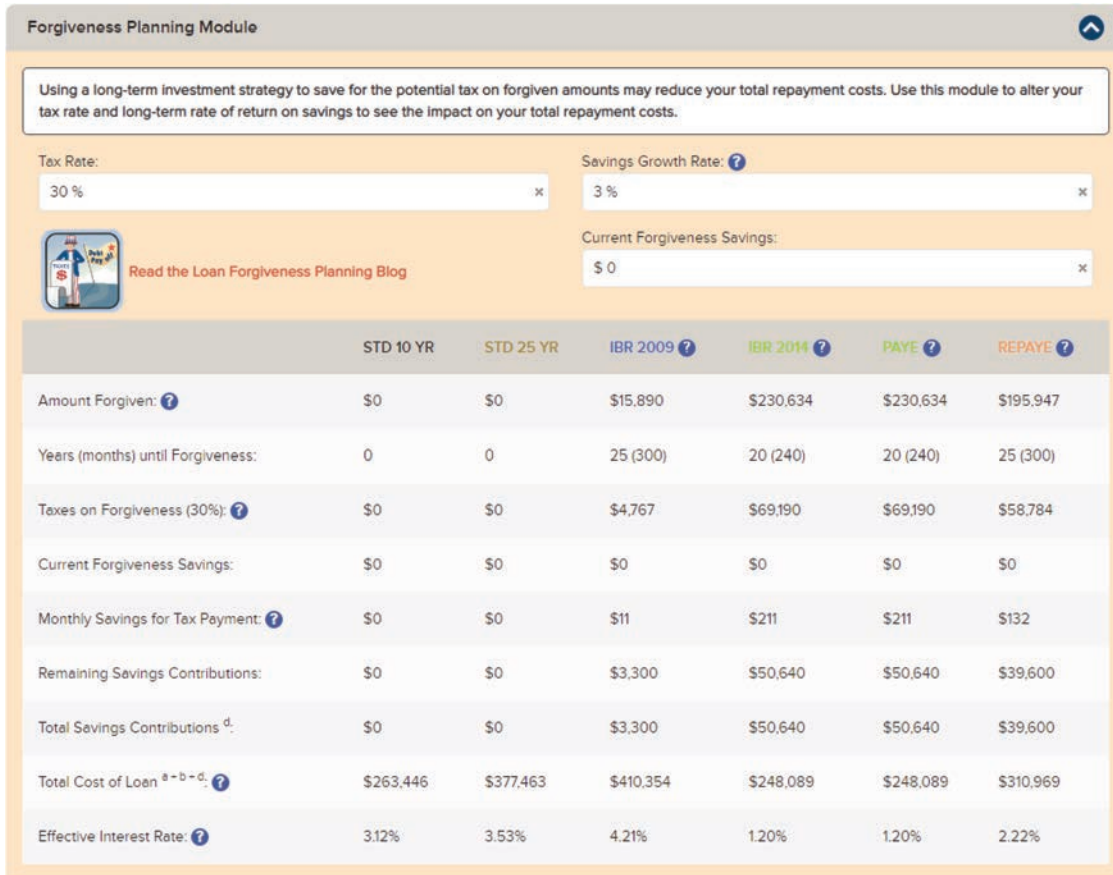

Forgiveness Planning Module

Using a long-term investment strategy to save for the potential tax on forgiven amounts may reduce your total repayment costs. Use this module to alter your tax rate and long-term rate of return on savings to see the impact on your total repayment costs.

Tax Rate: 30 %

Savings Growth Rate: 3 %

Read the Loan Forgiveness Planning Blog

Current Forgiveness Savings: $ 0

	STD 10 YR	STD 25 YR	IBR 2009	IBR 2014	PAYE	REPAYE
Amount Forgiven:	$0	$0	$15,890	$230,634	$230,634	$195,947
Years (months) until Forgiveness:	0	0	25 (300)	20 (240)	20 (240)	25 (300)
Taxes on Forgiveness (30%):	$0	$0	$4,767	$69,190	$69,190	$58,784
Current Forgiveness Savings:	$0	$0	$0	$0	$0	$0
Monthly Savings for Tax Payment:	$0	$0	$11	$211	$211	$132
Remaining Savings Contributions:	$0	$0	$3,300	$50,640	$50,640	$39,600
Total Savings Contributions [d]:	$0	$0	$3,300	$50,640	$50,640	$39,600
Total Cost of Loan [a+b+d]:	$263,446	$377,463	$410,354	$248,089	$248,089	$310,969
Effective Interest Rate:	3.12%	3.53%	4.21%	1.20%	1.20%	2.22%

Fig. 2. Forgiveness planning module.

PAYE and a slightly higher total cost as compared to the Standard 10-year repayment plan. Forgiveness is both a feature and a side effect with IDR. Borrowers can make payments based on their taxable income for a maximum number of years. If they reach the maximum repayment period (20 years for PAYE) and still have a balance remaining, then the rest of the balance is forgiven. Forgiven debt can be treated as taxable income. If a borrower is projected to reach forgiveness, then a forgiveness savings plan is necessary to cover any anticipated tax due on forgiven debt.

The VIN Foundation Student Loan Repayment Simulator has a Forgiveness Planning Module to help veterinarians calculate the potential costs of the tax and how to save for the expense. Figure 2 illustrates the forgiveness plan for the 2022 graduate veterinarian.

With a projected tax rate of 30% on the forgiven student debt balance, this new graduate veterinarian may owe $67,500 to the Internal Revenue Service when she reaches forgiveness 20 years after starting repayment in PAYE. In order to prepare for that expense, she can save $206/month in some combination of accounts/investments that will return an average of 3% per year. Doing so will provide enough to cover the tax and will also reduce her total projected repayment costs by about $18,000. Now her projected PAYE repayment strategy is less than a standard 10-year plan.

Figure 2 also shows an "Effective Interest Rate" of 1.36% per year. Although the stated interest rate for this simulation is 5.75%, with a total PAYE repayment cost of $254,272 over 20 years on $200,000 borrowed, she would pay $54,272 of interest over 20 years of repayment, or an 1.36% effective interest per year for the duration of PAYE repayment. Also consider that a large portion will be paid in the future when her income will likely be higher, and the value of the dollars used to pay the loan will be lower due to the time-value of money. The effective interest rate can be particularly helpful for evaluating private loan refinance offers and time-driven repayment plans.

4. Discussion

Veterinarians with student loans can choose from a variety of student loan repayment strategies. Choosing a strategy that minimizes risk, maximizes cash flow, and reduces total loan repayment costs is the goal. For most recent graduate veterinarians or any veterinarian with federal student loans and a student debt to income ratio greater than one, IDR can obtain that goal.

However, IDR is not for everyone. The lower monthly payments and potential forgiveness tax liability can result in a growing loan balance and future

stress that some borrowers avoid by choosing time-driven repayment strategies.

Any repayment pathway can work. Knowing all the options available can help veterinarians navigate periods of uncertainty or reach financial goals regardless of their student loan balance.

There are pros and cons associated with any repayment strategy. Time-driven strategies are simpler but require more cash flow and increase repayment risk. IDR strategies are more complex but can increase cash flow and decrease repayment risk.

The best strategies weigh the pros and cons, ideally applying numerical values and financial principals to the decisions. Factors beyond student loan monthly payments, interest rates, and total repayment costs also come into play. Short and long-term tax and financial planning can also play significant roles in a student loan repayment strategy. For example, aggressive student loan repayment strategies may eliminate student loans faster, but they can also result in higher taxes paid and postponement of short and long-term savings. IDR strategies can promote long-term savings and near-term wealth building that can decrease taxes as well as student loan repayment costs. However, the duration of repayment and potential tax planning for student loan forgiveness are also part of IDR strategies. IDR can also become more complicated for married couples, particularly married couples living in community property states. Oftentimes, it can make financial sense for married couples to file their taxes separately when using an IDR plan because the student loan repayment savings are significantly greater than the tax savings realized by filing jointly. The tax code financially incentivizes getting married, having children, and filing your tax returns jointly. Sometimes, the student loan repayment incentives can discourage marriage or encourage filing separately from a spouse, while still having children. The task is to see which combination of tax filing status and income-driven repayment option will help the equine practitioner keep more of their income.

A sound knowledge of student loan repayment options, tax incentives, and available resources can help to improve loan repayment success.

Acknowledgments

Declaration of Ethics

The Authors have adhered to the Principles of Veterinary Medical Ethics of the AVMA.

Conflict of Interest

The Authors have no conflicts of interest.

VIN and VIN Foundation provide financial and material support for the research and development of the student loan repayment resources available for free on the VIN Foundation Student Debt Center. VIN Foundation is a non- profit organization supported primarily by donations from the veterinary community.

References

1. American Veterinary Medical Association. *AVMA Report on Economic State of the Veterinary Profession;* 2021
2. Federal Student Aid. *Income-Driven Repayment Plans.* Retrieved March 11, 2022, from https://studentaid.ed.gov/sa/repay-loans/understand/plans/income-driven
3. Prezi. AAEP Annual Convention (continually updated until date of presentation), https://prezi.com/view/acatonnWxpdPwrjwyVX7/ [AQ2]
4. AVMA. My Veterinary Life. Retrieved March 11, 2022, from https://myvetlife.avma.org/rising-professional/your-financial-health/veterinary-salary-estimator
5. VIN Foundation. Student Loan Repayment Simulator. Retrieved March 11, 2022, from https://www.vin.com/studentdebtcenter/default.aspx?pid=14352&id=7578014#jj4+YY8xuqUlHr9cvyPRQw==

Paying off Student Debt Utilizing the Dave Ramsey Method

Caitlin Daly, DVM

High student debt can affect many facets of one's life from purchasing a business, home, or new car to saving for a child's education. With numerous debt repayment strategies, there is no single method that fits the needs and lifestyle of every individual. However, for those that are motivated to pay off debt aggressively and quickly, the Dave Ramsey method may be just what is needed. Author's address: PO Box 1446, Waldoboro, ME 04572; e-mail: midcoastequine@gmail.com. © 2022 AAEP.

1. Introduction

Student loan debt for veterinary graduates is a problem that isn't going away anytime soon. In fact, those veterinarians graduating in 2020 with educational debt had on average $188,853 in student debt.[1] This is over a 3-fold increase from those graduating 20 years ago who had an average debt load of about $61,000.[2] Unfortunately, starting salaries have not increased at a comparable rate. This has resulted in a debt-to-income ratio of 2.6 that far exceeds the 1.6 considered reasonable for professionals.[1]

Dave Ramsey is a name that has been around in the financial advisory world since 1992. After recovering from his own series of catastrophic financial mistakes, Dave Ramsey developed his money management plan, The 7 Baby Steps, to help people save for emergencies, pay off debt, and build wealth. The goal of his plan is to prevent others from experiencing the same financial loss he had by giving them the necessary tools to work toward financial freedom.[3] This plan involves asking participants to make drastic cuts to their spending, find ways to increase their income, and strictly adhere to a budget for as long as it takes to pay off their debt. For a veterinarian with a high student debt load, this may take many years.

Is his plan for everyone in every situation? No, not necessarily. Could it be for you? Yes, if you want it to be. The Dave Ramsey plan works best for motivated and willing participants. It's hard to stay the course when you feel like you're being forced to participate. You don't have to be a recent graduate to start this program, although the sooner you start, the less interest you'll have to pay in the long run. This program can also be completed by those that are single or in a partnership, and those with or without children. Only you can decide if it's right for you.

This paper will focus on how to utilize Baby Steps 1 and 2 to pay off student debt. Baby Steps 3 to 7 focus on how to save and build wealth once you've become debt free. Information regarding all 7 Baby Steps can be found at https://www.ramseysolutions.com/dave-ramsey-7-baby-steps.

The first baby step of Dave Ramsey's plan is to create an emergency fund of $1000. Not a penny more and not a penny less. The purpose of this fund is to

NOTES

cover unexpected life events, not to cover an overdrawn checking account or to fund a vacation. If your current savings account contains more than $1000, all surplus funds will be applied to your debt in Baby Step 2. If you do not have $1000 in savings, you will contribute all additional income to the emergency fund until it reaches a total of $1000.[4]

The second baby step of the Dave Ramsey plan is to pay off all debt (except a mortgage on your home) using the debt snowball method. Using the snowball method means that you will focus any extra income on the smallest debt first while paying the minimum payments on everything else. Once the smallest debt is paid off, you will take that payment and apply it to the next smallest debt and so on until all debt is paid off.[4] The reason for using the snowball method versus starting with the high interest rate debt first (also known as the avalanche method) is simple. The intent of the snowball method is to knock out numerous small debts upfront, activating our reward system and releasing dopamine—one of our feel-good neurotransmitter. Feeling good about what we've done increases the likelihood of repeating this behavior, keeping us motivated to play the long game.[2]

In the author's experience (a 2011 graduate), all student loans were assigned the same interest rate. This may not be the case for all individuals. In the last 15 years, fixed interest rates for Federal Stafford Unsubsidized Loans have varied from as high as 6.8% (2006–2013) to as low as 2.75% (2020–2021).[5] If you have student loans with variable interest rates, paying them off utilizing the avalanche method may result in less interest paid over time. However, you may not receive the same motivating psychological benefits discussed above.

Baby Step 2 begins by making a list of all debt, including car loans, credit cards, student loans, and any other consumer debt from smallest to largest, regardless of interest rate.[4] Sitting down and listing all of your debt can seem like a daunting task. The total can add up very quickly, reaching a sum for which a payoff seems unattainable. But don't be discouraged. The only way to fix the problem is to have a clear understanding of what the issue looks like and develop actionable steps to rectify it.

Once a list of debts has been made, take a look at how money is being spent. That means developing a monthly budget.[4] A budget allows you to organize, track, and be accountable for your income and spending habits. If you're in partnership, working on a budget together enables you to decide if you're able to live off one person's income and apply the other's income toward debt. Having a visual representation of your money through your budget highlights where you're overspending and where you can afford to cut back on your expenses. Spending $25 to $50 each time you go to the grocery store may not seem like a lot until you see the sum of $500 spent for one person's needs. A helpful tip for staying on budget is using the "envelope method." This means that for different categories, such as groceries and entertainment, the allotted monthly budget is held in an envelope in the form of cash. Only having cash on hand to spend, without the backup of a credit card, makes you more mindful of your spending. When it's gone, you cannot spend more. Also, budgeting apps (such as GoodBudget, YNAB, and EveryDollar) can help you stay organized and on-track by enabling transactions to be entered at the time of purchase or downloaded from your bank, alerting you to the remaining funds available, and comparing your spending habits from month to month.

Paying off a large sum of debt often requires that you make some drastic changes to increase the overall amount of money available to pay toward the balance. There are two ways to find additional money. First, take a look at your budget. Decreasing your overall monthly expenditures will enable you to make the most of your current paycheck. Second, increase your overall income by finding additional income sources. Below are suggestions for accomplishing both.

Suggestions for ways to decrease overall monthly expenses are listed below:

- Ditch personal credit cards and go cash only.
- Utilize cash back from business credit cards to pay for personal items.
- Cut out cable services and utilize less expensive streaming options.
- Reduce the cost of internet services (most providers allow a yearly price reduction).
- Price shop for cell phone service. If you have permission to utilize your business phone for personal use, consider canceling your personal phone.
- Buy used and if buying new, only do so if you can find a sale or a coupon.
- Rent books, audiobooks, and movies for free at the library.
- Find other cheap or free entertainment options in your local community.
- Pause or discontinue subscriptions and memberships.
- Trade babysitting with another family.
- Make coffee and meals at home (no takeout or eating out).
- Make a grocery list or buy groceries online to reduce the likelihood of impulse buying.
- Contact credit card companies about waiving and/or lowering interest rates.
- Eliminate or reduce car payments by purchasing a less expensive vehicle.
- Pause retirement and savings investments.
- Downsize your home or rental unit.

Options for increasing your overall income:

- Sell anything and everything you have no attachment to. If you haven't used or worn it in the last year, sell it.

- Sell your home or other real estate assets.
- Become a practice owner.
- Increase overall pricing and collect all accounts receivable.
- For associates—Secure compensation for 100% of the emergency fee and then offer to take additional emergency coverage or find other ways to increase your overall production.
- Utilize employer tax-exempt student loan repayment contributions up to $5250/year through 2025.
- Explore state-sponsored relief programs for rural/large animal veterinarians—may offer up to $25,000/year.
- Work vaccine clinics or small animal emergency shifts.
- Teach at a local college or technical school.
- Accept and seek out industry speaking or writing opportunities.
- Take paid online surveys (both industry sponsored and not).
- Pet sit or babysit.
- Turn your creative outlet into money by selling on Etsy or the Facebook group Vetsy.

2. Summary

Whether utilizing the method highlighted here or another option, making accelerated payments toward student debt is a commitment that requires unwavering dedication and sacrifice. It invites you to look at things differently and consider where you place value. Connection with family, friends, animals, and nature may become more important than the things that can be bought. You may develop a greater ability to decipher what is truly needed versus what is simply wanted in the fleeting moment. And most importantly, you will likely develop a firm understanding of "your why." What does paying off educational debt mean for you? What life could you have if you were no longer in debt? Where are the places you could go, the things you could see, and the people you could meet if you weren't tied down by your debt? Who could you help if you had more time and money to spare? The answers to these questions will help you stay on the course to financial freedom.

Acknowledgments

Declaration of Ethics

The Author has adhered to the Principles of Veterinary Medical Ethics of the AVMA.

Conflict of Interest

The Author has no conflicts of interest.

References

1. Bain B, Hansen C, Ouedraogo F, et al. *Economic State of the Veterinary Profession*. Schaumburg, IL: American Veterinary Medical Association; 2021.
2. Smith R, Fuller A. Some professional degrees leave students with high debt but without high salaries. *Wall Street Journal*. Available from: https://www.wsj.com/articles/some-professional-degrees-leave-students-with-high-debt-but-without-high-salaries-11638354602. Accessed January 30, 2022.
3. Ramsey Solutions. Dave's story. Available from: https://www.ramseysolutions.com/company/history/daves-story. Accessed January 30, 2022.
4. Ramsey D. *The Total Money Makeover*. Nelson Current; 2010.
5. Kantrowitz M. Historical federal student loan interest rates and fees. Available from: https://www.savingforcollege.com/article/historical-federal-student-interest-rates-and-fees. Accessed May 12, 2020.

Practice Ownership - The Key to Financial Health

Amy L. Grice, VMD, MBA

Practice ownership can significantly increase a veterinarian's financial success through the augmentation of compensation for effort as a veterinarian with an owner return on investment. Profits from a veterinary business can allow marked differences in the lifetime earnings of owners versus associates.
Author's address: PO Box 192, Virginia City, MT 59755; e-mail: amyvmdmba@gmail.com. © 2022 AAEP.

1. Introduction

Over the past 2 decades, fewer new graduates are entering equine private practice and nearly half have let their American Association of Equine Practitioners (AAEP) membership lapse by the fifth year after graduation, suggesting a departure from the sector.[1] According to the 2021 American Veterinary Medical Association (AVMA) Report on the Economic State of the Veterinary Profession, educational debt averaged $188,853 for the 83% of 2020 graduates with debt, which may be a factor in the lack of retention in the field.[2] Due to many AAEP members nearing retirement, with 46% currently over the age of 50, there may be a shortfall in veterinarians to care for our nation's horses in the near future if more practitioners cannot be attracted and retained. Finding ways to increase equine practitioners' total income may help with this goal.

Practice ownership is one of the most reliable of ways to increase pay. Practice ownership generally significantly increases a veterinarian's total income because on top of payment for work as a horse doctor, there is a payment for being a business owner—his or her share of the profits. Most veterinary practices are quite profitable if reasonable business management practices are in place. Although most veterinarians have little business education, there are a number of avenues to increase acumen, including networking groups, business seminars, traditional business school classes, and AAEP educational sessions.

2. Discussion

Many years ago, most veterinary practices were small and owned by the practitioners working in the firm. They typically saw all species of animals, with farm animals taking priority, though a few practitioners concentrated on pet animals or equines. When new associates were hired, they were assessed for compatibility and then, within a few years, offered partnership in the practice. There was a collegiality between practices that was professional and expected. The majority of veterinarians, especially those in large-animal and equine practice, were male. In the present time, the majority of equine practices continue to be small. According to the AVMA AAEP Equine Economic Survey, 53% of equine practices in the

NOTES

Year	# Equine Private Practice DVM	% of Total Private Practice DVM	% Males	% Females
2020	4184	5.6%	43.5%	56.5%
2019	4151	5.6%	44.5%	55.5%
2018	4125	5.6%	45.8%	54.2%
2017	4043	5.7%	47.0%	53.0%
2016	3920	5.7%	50.6%	49.4%
2015	3874	5.8%	49.9%	50.1%
2014	3816	5.9%	51.2%	48.8%
2013	3827	5.9%	51.8%	48.2%

Fig. 1. AVMA gender demographics of equine private practice 2013 to 2020.

United States have 2 full-time equivalent veterinarians or fewer.[1]

Beginning in the late 1990s, the pendulum began to swing to veterinary school classes having a majority of female students. In 2019, the size of the nation's active veterinary workforce was approximately 116,000 members, of whom 63% were female, marking a 12% increase in women veterinarians over the previous decade.[3] Some of these women were interested in equine practice and joined the profession as associates. In about 2017, females became the majority in equine private practice (Fig. 1). They were and still are typically offered salaries lower than those offered to males. In the 2016 AVMA AAEP Equine Economic Impact Study, starting salaries in the equine veterinary field lagged behind those offered in other types of private practice. AVMA respondents (almost exclusively working in companion animal practices) reported higher postinternship salaries than equine respondents on average, except for male equine respondents who graduated in the period 2012 to 2016; these graduates reported an average starting salary of $61,867 compared to AVMA males, who reported $61,810. In contrast, female equine respondents who graduated from 2012 to 2016 reported an average starting salary of $51,109 compared to AVMA females, who reported $70,452. When considering these first-year salaries offered to equine practitioners after a 1-year internship, there was a $10,000 difference between the males and females, with males earning $61,867 and women earning $51,109.[1] This gender wage gap has not improved but instead appears to have worsened, according to the 2020 AVMA Senior Survey, which reported that the four male veterinary school graduates entering equine practice without an internship were offered an average salary of $75,000, while the 26 females entering were offered a mean of $56,000.[4]

As the demographic changes to primarily female graduates occurred, equine practice owners increasingly declined to add associates as partners, sometimes citing their belief that interest in ownership was no longer present among associates.[5] Several studies refute that perception. Results from a survey reported at the 2016 AAEP Annual Convention stated that 76% of associates working at group practices of 7 or more veterinarians were interested in ownership, and 84% of those working in group practices with 2 to 6 veterinarians felt likewise.[5] The 2016 AVMA AAEP Equine Economic Impact Study reported that about half (50.4%) of respondents identifying as equine relief veterinarians and associates (58.7% of males and 48.0% of females) were interested in practice ownership, a number almost twice as high as the general veterinary (21.7%) (primarily companion animal) respondent population (34.0% of males and 18.7% of females). In addition to those that definitely desired ownership, 18.7% of female and 12.7% of male AAEP respondents were unsure if they wanted to buy shares or obtain ownership. Additively, this represents 71.4% of male and 66.7% of female respondents potentially seeking to be future equine practice owners. Among the AAEP sample, only 28.6% of male respondents and 33.3% of female respondents stated they were not interested in buying shares or ownership of a practice.[1]

In 2020, a study reported that nearly 25% of respondents at larger practices (>4 doctors) had left the equine space, the largest percentage among the different practice sizes. In contrast, only about 10% of those in solo practices left the industry.[6] Solo practice allows veterinarians to unilaterally set their own boundaries, create a practice culture in alignment with their values, and make decisions about how the practice will evolve. Possibly a solo practice owner feels more obligated to stay in practice due to the feeling of obligation to their clients. One might also wonder if the larger practices that are experiencing more departures have more traditional work models that fail to accommodate the needs of women veterinarians. Because they often have different priorities than previous generations of veterinarians, millennials may be choosing workplaces that fit the lives they want, or opening their own practices, rather than trying to conform to old models. In order to retain equine practitioners in equine practice, maybe practice ownership is one of the answers.

While many of the largest equine practices in the United States are selling to corporate consolidators or national groups, it is good to remember that when including all types of veterinary practices, which means predominantly companion animal practices, large corporate groups currently represent less than 25% of all practices in the United States. Data from the 2016 AVMA AAEP Equine Economic Impact Study reported that 53% of equine practices have 2 full-time equivalent veterinarians or fewer, so the majority are quite small.[1] More than 3000 new veterinary practices opened between 2005 and 2017, according to US Census Bureau data, and the total number of practices was estimated to be around 32,000 in 2019,[3] so clearly veterinarians continue to possess an entrepreneurial spirit.

According to Frederic Ouedraogo, PhD, AVMA assistant director of economics, the percentage of private practitioners who are owners declined from 43% in

ABC Equine Practice			
Income Statement - Profit and Loss Statement 12/31/2022			
Revenue			
Professional Service Revenue	$	800,000.00	96.97%
Retail Drug and Supplies Revenue	$	25,000.00	3.03%
Total Revenues	**$**	**825,000.00**	**100.00%**
Expenses			
Cost of Professional Services			
Cost of Retail Drugs and Supplies	$	15,000.00	1.82%
Cost of Drugs and Professional Supplies	$	160,000.00	19.39%
Laboratory Costs	$	25,000.00	3.03%
Other Costs (medical waste, etc.)	$	750.00	0.09%
TOTAL COPS	**$**	**200,750.00**	**24.33%**
GROSS PROFIT	**$**	**624,250.00**	**75.67%**
Payroll and Employee Costs			
Veterinarians (25% of service revenue)	$	200,000.00	24.24%
Veterinary Technicians/Assistants	$	60,000.00	7.27%
Office Staff	$	30,000.00	3.64%
Benefits	$	28,000.00	3.39%
Payroll Taxes (All salaries)	$	11,700.00	1.42%
Other	$	1,500.00	0.18%
TOTAL Payroll and Employee Costs	**$**	**331,200.00**	**40.15%**
Administrative Costs			
Licenses & Memberships	$	2,300.00	0.28%
Office Supplies	$	2,400.00	0.29%
Advertising	$	2,400.00	0.29%
Accounting & Legal Services	$	3,000.00	0.36%
Postage & Shipping	$	500.00	0.06%
Other	$	12,000.00	1.45%
TOTAL Administrative Costs	**$**	**22,600.00**	**2.74%**
Fee Income Collection Costs			
TOTAL Fee Income Collection Costs		**12,375**	**1.50%**
Facility and Equipment Costs			
Rent	$	-	0.00%
Equipment Repairs & Maintenance	$	2,500.00	0.30%
Practice Vehicle Expense	$	24,000.00	2.91%
Utilities	$	-	0.00%
Insurance (Business, PLIT)	$	7,400.00	0.90%
Telephone	$	5,000.00	0.61%
Computer Software	$	3,600.00	0.44%
Website	$	500.00	0.06%
Other	$	10,000.00	1.21%
TOTAL Facility and Equipment Costs	**$**	**53,000.00**	**6.42%**
Total Expenses	**$**	**619,925.00**	**75.14%**
Net Ordinary Income (EBITDA)	**$**	**205,075.00**	**24.86%**
Truck purchase loan x 60 mo 60K 4%	**$**	**13,250.00**	**1.61%**
Equipment Loan Payments - 120 mo 100K 4%	**$**	**12,732.00**	**1.54%**
Net Income	**$**	**179,093.00**	**21.71%**
Compensation Pool for Two Owners			Each Owner
Effort Pool as Veterinarians	$	200,000.00	$ 100,000.00
Return on Ownership Pool (Profit)	$	179,093.00	$ 89,546.50
TOTAL	**$**	**379,093.00**	**$ 189,546.50**

Fig. 2. ABC equine profit & loss statement.

2007 to 33% in 2019. Practice ownership or co-ownership is associated with several benefits, including higher lifetime earnings and improved work-life balance, he noted. "It's important that we start as a profession to think about ways to promote and encourage ownership," Dr. Ouedraogo said. "One way to do

that is to include business management or startup finance classes in our curriculum. Another way is to advocate for government support to new DVM graduates who want to start a new business. It can be similar to the loan repayment program or any other incentives." Men currently make up the majority of private practice owners, but the percentage of women owners is increasing, shifting from 29% of the total in 2007 to 41% in 2019. By 2028, the majority of US practice owners will be women, he said.[3]

In equine practice, in the 2016 AVMA AAEP Equine Economic Impact Study, practice owners, numbering 334, accounted for 54.3% of the AAEP respondents, with 60% of owners male and 40% female. Of the respondents who were practice owners, 49.7% were sole proprietors, 36.5% were a partner/shareholder in an S-Corp or C-Corp, and 13.8% were a partner in a Limited Liability Corporation (LLC) or other type of practice ownership structure.[1]

Encouraging practice ownership in equine practice could help retain equine veterinarians. Average ambulatory net income from operations before depreciation and amortization was reported in 2020 as 13.5%.[7] The author commonly sees small ambulatory practices with EBITDA (Earnings Before Interest, Taxes, Depreciation and Amortization) of 20% or more. While this ordinary profit may be reduced after payment of principal and interest on loan obligations, it can still amount to a generous amount of additional compensation.

Utilizing computed benchmarks for expenses for a small (2 doctors or fewer) equine ambulatory practice (author calculation from compilation of 1-2 DVM client financial records), one can visualize the potential financial benefit of ownership (Fig. 2). With 2 doctors contributing to total practice revenue of $825,000, and Cost of Professional Services (COPS) totaling 24.33% of revenue, a gross profit of $624,250 remains. When all expenses including COPS ($619,925) are subtracted from income, this leaves $205,075 in EBITDA. After accounting for loan payments for a $60,000 truck financed over 60 months at 4% and a $100,000 equipment loan financed over 120 months at 4%, there still remains $179,093 to be distributed to the owners in accordance with their share of ownership in addition to their salary for effort as veterinarians ($100,000 each, based on 25% of their service revenue production). This totals $189,547 in compensation for each of 2 partners in this practice if they each own 50%. If this practice had just 1 owner and an associate, rather than 2 partners, and each earned service revenue of $400,000 for the practice, the associate would have total compensation of $100,000. The sole owner would have compensation of $100,000 + $179,093, or $279,093. If the sole owner of the practice had no associate but instead utilized the 2 technicians to increase his or her efficiency and produced $800,000 single-handedly, the veterinarian would have total compensation of more than $379,093 ($200,000 + $179,093), because expenses would be reduced due to less costs for licenses, memberships, continuing education, vehicle costs, professional liability insurance, and benefits.

Business owners earn so much more than employees because the owners are taking risks in owning a business. While associates can go home at night without worrying whether the cash flow will be sufficient to meet payroll and other monthly obligations, or whether the horse owner whose horse fell down while sedated will sue the business, or whether the receptionist is going to give her notice tomorrow, the practice owner may lose sleep over these concerns. A practice owner could risk bankruptcy if the economy sinks into recession and he or she cannot then make loan payments. Business owners are willing to assume these burdens of risk because they have the opportunity to make profit, which can be substantial. One of the reasons corporate consolidators are so interested in investing in veterinary practices is that they generally produce strong, consistent profits.

However, practice ownership is not only about monetary gains. Owners can also grow their practices in the direction of their vision for their careers and lives, make the decisions on services offered and the boundaries set, and create a culture that is an expression of their values. They can limit their services to an area of interest, limit their growth to a select group of compatible clients, or limit their work hours to fit their other priorities. Their practice is shaped by their choices, and they have control over how life as an equine veterinarian looks.

Because the current paradigms of the equine veterinary profession are not compatible with attracting and retaining equine veterinarians, it is sensible that some are seeking to shape their futures through practice ownership. Because of the differing priorities of the next generation of horse doctors, ownership shares in existing practices may not be attractive unless these individuals have agency to make changes, have choices, and exert control over their professional lives. Consequently, if existing practice owners seeking a sale at retirement wish to engage associates as partners, it is the author's opinion that this effort should occur early in the associate's tenure, after 2 to 5 years of service that ensures compatible values, with the offer of a meaningful percentage of ownership and control. Minor profit sharing will likely not be satisfactory to meet the more pressing needs of younger practitioners, who seek to shift the traditional mores of equine practice. Embracing the change desired by new partners is important in attracting them to stay in existing practices.

3. Conclusion

Whereas there are inherent risks and management tasks to attend to as a business owner, the advantages over employment as an associate are significant and far beyond the monetary. Practice ownership provides freedom to pursue a professional as well as personal vision for one's life, along with providing marked financial benefits. Lifetime earnings of owners far

exceed those of associates, with concomitant benefits to career satisfaction and well-being.

Acknowledgments

Declaration of Ethics

The Author has adhered to the Principles of Veterinary Medical Ethics of the AVMA.

Conflict of Interest

The Author has no conflicts of interest.

References

1. American Association of Equine Practitioners (AAEP). 2016 AVMA AAEP Equine Economic Survey. https://aaep.org/sites/default/files/Documents/2019%20FINAL_AMVA_AAEP_Equine_Report.pdf. Accessed January 19, 2022.
2. American Veterinary Medical Association (AVMA). 2021 AVMA report on economic state of the veterinary profession. https://ebusiness.avma.org/ProductCatalog/product.aspx?ID=2000. Accessed January 19, 2022.
3. Nolen RS. Women practice owners projected to overtake men within a decade. https://www.avma.org/javma-news/2020-12-15/women-practice-owners-projected-overtake-men-within-decade#:~:text=The%20size%20of%20the%20nation's,veterinarians%20over%20the%20past%20decade. Accessed January 28, 2022.
4. Bain B. Employment, starting salaries, and educational indebtedness analyzed by gender for year-2020 graduates of US veterinary medical colleges. *J Am Vet Med Assoc* 2021;258:867.
5. Grice A. Conflicting perceptions of practice ownership: Survey results from AAEP listserv members in 2014, *in Proceedings*. Am Assoc Equine Pract 2016;62:392–396.
6. Grice A. Why veterinarians are leaving equine practice, *in Proceedings*. Am Assoc Equine Pract 2020;66:170–180.
7. Heinke ML. Healthy practice measures (benchmarking) for solo and multi-doctor practices, *in Proceedings*. Am Assoc Equine Pract 2020;66:345–354.

Seeding the Field to Grow Future Owners

Ciera Guardia, DVM*; and Amy L. Grice, VMD, MBA

One unique path to incentivize equine practitioners to remain in equine practice involves the financial support and mentorship of an established practice owner. Such an investor can realize both a financial and personal return on their investment. Authors' addresses: Guardia Equine Sports Medicine, 12645 Memorial Drive, #F1176, Houston, TX 77024 (Guardia); PO Box 192, Virginia City, MT 59755 (Grice); e-mail: cg@guardiaequine.com. *Corresponding and presenting author. © 2022 AAEP.

1. Introduction

For the past decade, declining numbers of veterinary graduates have accepted positions in equine private practice directly after graduation,[1] and about half no longer belong to the AAEP within 5 years of their graduation.[1] Because companion animal exclusive positions offer substantially higher salaries than equine positions,[2] these decisions could be related to graduates' obligations to pay high educational debt, which averaged $188,853 for the 83% of 2020 graduates with debt, according to the 2021 AVMA Report on the Economic State of the Veterinary Profession.[2]

In the 2016 AVMA AAEP Equine Economic Study, it was reported that about half of AAEP member equine associate and relief veterinarian respondents (58.7% of males and 48.0% of females) were interested in practice ownership, which was a higher percentage than the number of AVMA respondents who reported desire for ownership in the AVMA 2016 Census Study of the mostly companion animal membership, where 34.0% of males and 18.7% of females indicated they were in the market to become a practice owner.[1] When examining practice size, the 2016 AVMA AAEP Equine Economic Study reported that 52.8% of practices had 2 full-time equivalent veterinarians or less.[1] In 2020, a study reported that nearly 25% of respondents at larger practices (>4 doctors) had left or definitely had decided to leave equine practice compared to only about 10% of those respondents in solo practices who said the same.[3] Because desire for practice ownership appears to be higher among equine veterinarians than those in the companion animal sector, and those in small practices appear less likely to have left or to have definitely decided to leave equine practice, to keep more equine practitioners in equine practice, maybe solo or small practice ownership is one of the answers.

There are distinct financial advantages to practice ownership, as the owner has compensation that includes profits as well as salary for their efforts as a veterinarian. In addition, the ability to be the decision maker allows a veterinarian to build a career that matches their values, aspirations, and skillset. Being the owner of a practice may allow the opportunity to achieve increased personal career satisfaction and financial benefits that make equine practice a more sustainable

NOTES

	Year 1	Year 2	Year 3	Year 4	Year 5	Year 6	TOTAL
Total Revenue	**$ 200,000.00**	**$ 275,000.00**	**$ 350,000.00**	**$ 425,000.00**	**$ 500,000.00**	**$ 550,000.00**	
Expenses							
COPS (Cost of Professional Services) @ 29% of total revenue	$ 58,000.00	$ 79,750.00	$ 101,500.00	$ 123,250.00	$ 145,000.00	$ 159,500.00	
Gross Profit	**$ 142,000.00**	**$ 195,250.00**	**$ 248,500.00**	**$ 301,750.00**	**$ 355,000.00**	**$ 390,500.00**	
Base Salary	$ 60,000.00	$ 60,000.00	$ 60,000.00	$ 60,000.00	$ 60,000.00	$ 60,000.00	
OR 25% of Gross Profit	$ 35,500.00	$ 48,812.50	$ 62,125.00	$ 75,437.50	$ 88,750.00	$ 97,625.00	
Compensation	$ 60,000.00	$ 60,000.00	$ 62,125.00	$ 75,437.50	$ 88,750.00	$ 97,625.00	
Employee Costs @10%	$ 20,000.00	$ 27,500.00	$ 35,000.00	$ 42,500.00	$ 50,000.00	$ 55,000.00	
Administrative Costs @ 4.5%	$ 9,000.00	$ 12,375.00	$ 15,750.00	$ 19,125.00	$ 22,500.00	$ 24,750.00	
Credit Card Fees @ 1.5%	$ 3,000.00	$ 4,125.00	$ 5,250.00	$ 6,375.00	$ 7,500.00	$ 8,250.00	
Facility & Equipment Costs @ 7%	$ 14,000.00	$ 19,250.00	$ 24,500.00	$ 29,750.00	$ 35,000.00	$ 38,500.00	
TOTAL Expenses	**$ 164,000.00**	**$ 203,000.00**	**$ 244,125.00**	**$ 296,437.50**	**$ 348,750.00**	**$ 383,625.00**	
EBITDA (Earnings Before Interest, Taxes, Depreciation, and Amortization)	$ 36,000.00	$ 72,000.00	$ 105,875.00	$ 128,562.50	$ 151,250.00	$ 166,375.00	
$50,000 Equipment 60 mo @5%	$ 11,323.00	$ 11,323.00	$ 11,323.00	$ 11,323.00	$ 11,323.00	$ -	
Net Income	**$ 24,677.00**	**$ 60,677.00**	**$ 94,552.00**	**$ 117,239.50**	**$ 139,927.00**	**$ 166,375.00**	
Mentee Vesting %	0%	10%	20%	30%	40%	50%	
Mentee Veterinarian Share	$ -	$ 6,067.70	$ 18,910.40	$ 35,171.85	$ 55,970.80	$ 83,187.50	**$ 199,308.25**
Mentor Veterinarian Share	$ 24,677.00	$ 54,609.30	$ 75,641.60	$ 82,067.65	$ 83,956.20	$ 83,187.50	**$ 404,139.25**

Profit %	
Year 1	12.34%
Year 2	22.06%
Year 3	27.01%
Year 4	27.59%
Year 5	27.99%
Year 6	30.25%

Fig. 1. Financial results of mentor mentee vested purchase of practice over 5 years.

choice for the individual. Although there are certainly increased responsibilities with small business ownership, it is the authors' opinion that the rewards far exceed the challenges.

2. Discussion

While starting an ambulatory equine practice may not be as substantial an undertaking as launching a brick-and-mortar practice, lack of business knowledge may prevent a veterinarian from proceeding with confidence. Seeking participation in a business education networking group can assist veterinarians in understanding practice finances, marketing strategies, and other business management aspects.[4] Alternatively, an experienced practice owner could provide business mentorship to a less-experienced veterinarian to give back to the profession and assist a new generation of equine doctors.

An established equine practice owner might identify a talented young veterinarian that is poised to leave equine practice and help them establish a path to stay in the profession. That path could lead to practice ownership. Such a path, taken by one of the authors (Guardia), is herein described.

The mentor veterinarian would begin the process by helping the mentee to form a professional and personal vision, understand their core values, and articulate a practice mission. Next, the established practice owner would provide a list of necessary tasks to open the practice, such as researching the demographics in the chosen practice area, establishing a permanent address, naming the practice, and planning the service offerings. The established practice owner then would add the "Doing Business As," or DBA, to his or her pre-existing veterinary business. This new practice satellite might be many miles away from the parent practice.

Additional items the mentor might assist the mentee with include setting up accounts at distributors, laboratories, banks, and service providers such as Global Vet Link for federal and state health documents. Also, advice might be given for practice credit card applications, forming accounts with shipping firms, obtaining a DEA license, registering radiology equipment with the State Department of Health and Safety, obtaining dosimeter badges, and acquiring necessary equipment. To populate the new practice website and social media, the established practice owner might recommend a professional photography session.

The mentor might provide diagnostic equipment such as a digital radiography unit, an x-ray generator, and an ultrasound, as well as other necessary equipment, and create a payment plan for the new practice to pay off these purchases over several years. A written agreement might be formalized to have the new practice transferred to the mentee as a vested purchase over a certain number of years. The established practice owner might pay the mentee a base salary, or a percentage of gross profit, whichever was greater. After the initial 12-month period, the vesting process could allow a certain percentage per year ownership share with resultant profit sharing. For example, in a 5-year vested purchase of 50% of the ownership of the practice, in months 13 to 24, the mentee could receive a 10% net profit share and hold 10% equity, followed

by a 20% profit share and 20% equity the following year, with a 50% ownership share being obtained by the end of the fifth year.

With this type of vested purchase agreement, at the end of the fifth year, the mentee would own 50% of the practice and would be given the opportunity to purchase the remaining 50% from the mentor. An independent practice evaluation would then be performed to determine the current value of the practice at the time of the transition. Based on that evaluation, a buy-out payment plan could be agreed upon. An amortized loan at a fixed interest rate to be paid off over 10 years might be held by the mentor for the purchase of the remaining 50% of the practice. If the practice location was chosen carefully where there was a strong demand for the services that the new practice was providing and the need for an additional provider, and the mentee veterinarian was a motivated individual, practice gross revenue might increase robustly each year. If the mentor invested $50,000 in used equipment to provide to the mentee, and the mentee provided a practice vehicle, both would be materially invested. If benchmark averages for practice expenses were achieved,[6] the mentee was paid a base salary of $60,000 or 25% of gross profit, whichever was higher, and the mentee did not utilize employees initially, a small net profit could be realized in year 1 (Fig. 1). In this example, the mentor might have an investment in providing cash flow to pay the base salary initially until the revenue stream became stronger, but even in the first year of this sample case, revenue would cover this by year end. During the first several years of the practice, seasonality or irregularity of revenue production might create the need for cash flow supplementation, but a positive net income could be realized each year in this illustration.

3. Conclusion

Whereas the financial investment of a mentor might be important in providing equipment and cash flow to the new practice, the business guidance and the confidence that involvement of an established practitioner provides could be invaluable to the mentee. Established practice owners who have the generosity and inclination to assist younger equine veterinarians in establishing practices and reaping the benefits of ownership can provide an incentive for these practitioners to remain in equine practice and shape satisfying careers. These investors can realize a strong return on their investment—this return can be inspirational as well as financial. For some, helping give a hand to those coming up behind them may be more rewarding than the profits they earn in the arrangement.

Acknowledgments

Declaration of Ethics

The Authors have adhered to the Principles of Veterinary Medical Ethics of the AVMA.

Conflict of Interest

The Authors have no conflicts of interest.

References

1. 2016 AVMA AAEP Equine Economic Survey. https://aaep.org/sites/default/files/Documents/2019%20FINAL_AMVA_AAEP_Equine_Report.pdf. Accessed January 19, 2022.
2. 2021 AVMA report on economic state of the veterinary profession. https://ebusiness.avma.org/ProductCatalog/product.aspx?ID=2000. Accessed January 19, 2022.
3. Grice A. Why veterinarians are leaving equine practice, *in Proceedings*. Am Assoc Equine Pract 2020; 66:170–180.
4. Decade One. http://www.decadeonevet.com/. Accessed January 19, 2022.
5. Heinke M. Healthy practice measures (benchmarking) for solo and multi-doctor practices, *in Proceedings*. Am Assoc Equine Pract 2020;66:351.

Building Wealth – Outside of Your Practice

John A. Chalk, Jr., JD, CPA, CFP®

Author's address: 121 Countryside Court, Suite 140, Southlake, TX 76092; e-mail: john@trinityportfolio.com. © 2022 AAEP.

1. Introduction

Practice ownership is one of the best ways for veterinarians to build wealth. Alongside practice ownership, there are other approaches and techniques available to build wealth outside of one's vocation. The diversification of one's assets is a worthwhile pursuit. Periods of economic turbulence are inevitable and, as one's net worth grows, this pursuit of diversification becomes more and more fruitful. Many practice owners find that virtually all of their wealth is locked up in their practice and, in turn, expose themselves to an avoidable amount of risk.

This presentation aims to provide simple steps one can take in the pursuit of a well-diversified net worth. Wealth accumulation does not require the expertise of a financial services professional. While professional advice can certainly help, the objective is to highlight several practical methods that allow one to accumulate and diversify collectively.

Basics begin with spending less than you make, managing debt, and investing excess cashflow in a diverse manner.

2. Discussion

Building wealth does not have to be a complicated process. There are actually some very simple rules to building wealth. First, spend less than you make. This is easiest when score is kept around how much one spends, saves, and gives away. Virtually all money that leaves one's possession can be put into one of these three categories. Second, debt management. Executed correctly, debt can help increase wealth; executed incorrectly, debt can become a major constrictor of cash flow. Third, diversification. Diversifying investments among various asset classes will help assure continued accumulation regardless of economic conditions.

Keeping score is essential. Keeping score is simply the regular measurement of anything. In a game, it is the score. If there is no score kept in a game, then no one knows whether they are winning or losing. The same is true in wealth accumulation. Scores should be kept in several areas so one can determine whether wealth is accumulating or not. Lewis Carroll, the author of *Alice in Wonderland* is credited with saying, "If you don't know where you are going, any road will get you there." Keeping score will ensure one is on the right road and not just any road. The periodic recording of specific amounts at the same time, year after year, will begin to tell a story. In time, this process will help identify a significant aspect of one's financial DNA. Unlike the human genome, altering one's financial DNA does not require a mutation. Rather, the altering of one's financial DNA is a gradual, consistent process of addressing one's weaknesses and building on one's strengths.

3. Spend/Save/Give

- **Spend**: Spending is one of the most common financial controversies within a family. Inevitably, in a typical couple, there is a "spender" and there is a "saver." Unaddressed, these differing outlooks

NOTES

can lead to conflicts regarding how much should be spent and how much should be saved. Most individuals that feel as though they are spending too much do not adhere to a set saving or giving goal. The reprioritization and implementation of a habitual, systematic approach to both saving and giving tempers many of the controversies that arise from the act of spending. The author has found it is best to focus on saving and giving as the priority. Having a set goal for these two items and making them the priority ensures that spending no longer comes first.

- **Save**: Saving is the cornerstone of building wealth outside of a practice. Simply put, saving is the act of allocating excess cash flow into wealth building resources.

Typically, the first place one should allocate earnings is into their qualified plan(s). Qualified plans are investment accounts with certain tax benefits and are designed to provide investment vehicles for individuals to save for retirement. The most common examples of these accounts are Traditional IRA's/401(k)'s and Roth IRA's/401(k)'s. The difference between Traditional plans and Roth plans is the taxation at the time of contribution and distribution. For Traditional plans, contributions are tax deductible but all distributions, including the tax deferred growth in the account, are fully taxable as ordinary income. Roth plans are the opposite of Traditional plans. For Roth retirement plans, contributions are not tax deductible and all distributions, including the growth in the account, are tax exempt. For both Traditional and Roth plans, there are maximum amounts that can be contributed and those amounts typically change each year. As one's earnings increase, one's contributions to their qualified plan(s) should increase until the maximum annual amount is reached.

Once retirement accounts are sufficiently funded, net savings can and should be put to work in numerous ways. One way could be to acquire the real estate where the practice is located. Most practice owners end up owning the real estate where their practice is based. Over time, this asset can substantially increase their net worth and provide an additional source of income. Another method would be making contributions to a non-qualified investment account. Either of these investments can help both diversify wealth while adding to overall net worth.

- **Give**: giving is the third action one can take with their money. What causes one to give and in what amounts are aspects of one's personal philosophy surrounding their wealth? Whether one chooses to give or not, that decision should be rooted in the purpose one has for their money. Keeping score in this area is also very important. Over time, a pattern of what percentage of cash inflows were given will emerge. This percentage can be adjusted over time, either up or down, depending on the giving philosophy. Giving decisions can also involve the entire family and provide benefits far beyond charitable contributions.

Debt Management

Managing debt can increase wealth. Using newly received cash to repay the principal of debt increases net worth. As debt goes down, net worth (meaning fair market value of assets less total debt) goes up. This happens even if the fair market value of assets remains constant. Generally, debt with the highest interest rate should be repaid first.

Not all debt negatively impacts wealth accumulation. There are times when debt is a valuable way to increase wealth. Over the last few years, interest rates have been historically low. If debt is used to acquire assets that appreciate at a rate higher than the interest being charged, net worth increases. For instance, the acquisition of your practice's real estate through the use of a loan is a common and typically profitable way to use debt. However, debt combined with economic uncertainty can create financial pressure as the payments become due.

Like giving, everyone should have a philosophy around debt. When, why, and on what terms will one borrow money are the important aspects of a debt philosophy. Remaining true to one's philosophy will help ensure that debt is incurred for opportunities that are both affordable and profitable. Random, uncalculated additions of debt to one's personal balance sheet is one of the most frequent bottle necks of growing one's net worth.

The elimination of debt places the focus on the repayment of the principal and interest associated with debt. This increases available cash flow and, therefore, increases the amount available to save. It is important to be intentional with freed up cash flow as money without a job evaporates.

Adjusting to Economic Uncertainty

Monitoring wealth is even more important during times of economic uncertainty. Having a well-diversified net worth shields oneself from the volatility of capital markets, the swings of business cycles and other external variables outside of one's control. A common saying that rings true in asset management is that with uncertainty comes opportunity. Depending on the source of uncertainty, and using history as a guide, one can make adjustments to increase exposure to historically profitable asset classes. As a relevant example, during times of inflation, interest sensitive investments such as bonds typically underperform. Inflation reduces the value of a bond holder's coupon interest payment. The longer the maturity of the bond, the more pronounced the inflation effect. This is because there are many more coupon interest payments to come at further dates, which reduces the present value of those future payments even more. Conversely, equities and real estate have maintained

notable performance through inflationary periods of record. Veterinary practices are also historically resilient during times of economic hardship. Costs associated with construction and other products can come down during times of recession and therefore, while it may seem counterintuitive, recessions can be a good time to expand one's practice.

Summary/Action Items

Building wealth outside of a veterinary practice requires a diligent, systematic, and organized approach. Having a clear plan requires the knowledge of both where one's wealth stands today and where it is to go. Once a clear plan is created, consistently keeping score will confirm whether progress is being made or expose areas that need to be adjusted. Wealth growth and stewardship is a life-long process and, done well, will create a legacy that will provide benefits for generations to come.

Acknowledgments

Declaration of Ethics

The Author has adhered to the Principles of Veterinary Medical Ethics of the AVMA.

Conflict of Interest

John Chalk, Jr., JD, CPA, CFP® owns the registered investment advisory firm Trinity Portfolio Advisors, LLC. Based in Southlake, Texas, Trinity Portfolio Advisors, LLC is a paid consultant to owners of veterinary practices. The Author has no conflicts of interest in this presentation.

Harvesting the Value of Smaller Practices: Mergers, Partnerships, or Sale to Individuals

Amy L. Grice, VMD, MBA

Small primarily ambulatory firms make up the majority of equine practices. While larger practices are increasingly sold to corporate aggregators for high multiples, smaller practices mostly do not have this opportunity. Other options for harvesting the value of these businesses include mergers, partnerships, or sales to individuals. Author's address: PO Box 192, Virginia City, MT 59755; e-mail: amyvmdmba@gmail.com. © 2022 AAEP.

1. Introduction

Data from the 2016 AVMA AAEP Economic Impact Study show that over half (53%) of equine practices in the United States have two or less full-time equivalent veterinarians. Nearly two thirds have three or less. Ambulatory practices and ambulatory practices with a haul-in facility account for 36.5% and 35.4% of equine veterinary businesses, respectively.[1]

The pace of sales of equine practices to corporate aggregators has seemed to quicken over the last several years. These buyers are primarily interested in practices that have gross revenue of at least $2 million, a dedicated facility, and at least three full-time veterinarians. Only about a third of equine practices meet these parameters. As a result, there are a large number of practitioners with more limited exit strategies.

Equine practitioners are often independent and entrepreneurial, leading them to want to be practice owners in higher numbers than those in companion animal practice. In the 2016 study noted above, 58.7% of male associates and 48.0% of female associates in equine practice reported they were interested in practice ownership compared to just 34.0% of men and 18.7% of women in companion animal practice.[1] This has undoubtedly contributed to the growth of multiple smaller practices, as some associates have left employment to start their own ventures.

Retirement and retainment of equine practitioners from equine practice, combined with the decline in the numbers of new graduates entering the equine field, has made traditional exit strategies more difficult. In the past, retiring doctors often sold their practices to their associates or brought them on as partners after a few years of collegial work together. This model began to shift in the last decade, with owners declining to bring on partners, possibly preferring instead to reap higher profits from the work of a stable of associates, as has been recommended by some business management groups. Other owners offered small numbers of shares for purchase by associates, with no decision-making capacity, which many found

NOTES

unappealing. When the time to retire arrived, some of these owners found their associates were not interested in buying their practice. Some associates had reached an age where buying in was less financially attractive due to the shortened timeframe for returns after purchase debt was satisfied. Others had started families and were unwilling to take on additional responsibilities. In other cases, few to no associates were left at the owners' retirement time, as they had either accepted new positions in companion animal practices offering shorter work hours, significantly higher pay, and no emergency duty or branched out on their own. Increasingly, some very small or solo practices have been unable to harvest their practice asset and have simply closed their businesses.

Planning ahead for a transition of ownership is important for all practices but especially vital for small practices.

2. Discussion

Whether the owner is interested in selling his or her shares in a group practice, selling an entire practice outright, or merging with a colleague, the path begins with finding a buyer/partner that is the "right fit". Other steps include determining the fair value of the practice(s), exploring tax implications of the sale, and making a smooth transition. There are also important considerations with regard to the elements of partners' operating agreements if adding partners.

Right Fit

An organization's values identify what the practice cares about most deeply and are the basis of the business' brand identity. It is important that a prospective partner's or new practice owner's personal values align with these. This is achieved by carefully getting to know the buyer. When values alignment occurs, it is easier to understand one another's motivations, everyone will tend to do the right things for the right reasons, and this common purpose and understanding will help the partners build a strong relationship. Conversely, when values are out of alignment, partners may find that they are working towards different goals, with different intentions, and with different outcomes. This can damage work relationships, productivity, job satisfaction, profitability, and practice brand identity. Only individuals whose values are in alignment with practice values will be successful partners.

To uncover values, one should ask focused questions that tease out the behaviors expected from the potential partner in the future. These will generally mirror their values. For instance, as a seller, imagine that honesty and integrity are two of the practice's core values. One could ask: "Describe a time when you felt ethically challenged. How did you go about identifying and understanding the opposing points of view? How did you deal effectively with the challenge? What was the outcome?" Or one might ask: "Has there ever been a time when your beliefs clashed with someone else's at work? If so, how did you overcome these differences?"

The practice culture provides a background of expectations for how team members will behave and what will be given highest importance. It is defined as the values and behaviors that contribute to the unique social and psychological environment. Finding a buyer that is in alignment with practice values is one of the best ways to ensure continued success of the practice after the sale, because clients are expecting the practice culture and values to remain consistent. This is particularly important if the seller is providing the financing. Listen carefully for what is not said in addition to what is said.

Value

Planning for a transition of ownership ideally requires a 3–5 year timeline. If a sudden life-changing event forces a quick sale, commonly the transaction yields a lower value than if there was time for preparation. During that preparation phase, the financial management of the practice needs to be modified to minimize personal expenses, create consistency, and maximize profit. Because value is based on profits, adjustments to the financials during the valuation process are necessary to make sure they reflect the true performance of the practice. Tax strategies and practice management can also have a large effect on financial statements. Because of this, they rarely show true economic reality. Owner doctors' compensation for their effort as veterinarians often must be adjusted to industry standards, as must rent/lease for an office or facility. If rent is excessive or inadequate, it is revised to be 4–6% of gross revenue.[a] Any personal expenses need to be removed in order to show true profit. These changes insure fairness to both buyer and seller.

Tax Considerations

Because there are tax implications in any sale that may vary depending on how the sale is structured, an accountant should always be consulted by both buyer and seller. Seeking fairness and equal tax liability for both parties is a good objective.

Smooth Transition

When a practice is sold, often the selling veterinarian stays for 3–6 months to transfer the goodwill that he or she has just been paid for, helping with the introduction of the new veterinarian to existing clients and fostering the future success of the practice. During retirement of a partner, this same transition may occur with a newly added associate, if one has been hired. When practices merge, having a client event where all the veterinarians are introduced, and their clinical interests are highlighted, can help with making the change exciting for the clients rather than something to dread. Keeping a positive, enthusiastic tone during change can make it easier to accept by all parties, including those working inside the practices.

Operating Agreements[2]

There are a number of events that could trigger a partner's departure. Sometimes the agreement for purchase of the shares of the outgoing owner will differ based on what event is causing the exit. For example, the formula for computing the price to be paid could be different for a partner leaving the practice due to a disability compared to one selling due to dismissal, with a discount on value placed on shares owned by the individual whose conduct forced the sale. Triggering events may include the following:

- Death
- Disability (must be well-defined)
- Departure (before buy-in completed)
- Departure (early retirement)
- Departure (retirement)
- Departure (aged out, if agreement forces sale at a particular age)
- Divorce (forced sale of shares prevents possibility of non-veterinarian spouse being awarded the asset)
- Dismissed (violation of standards of conduct or practice)
- Disqualification (loss of license, etc.)
- Disaffection (no longer contributes to the business)
- Deadlock/disagreement (fundamental impasse with no possible progress forward)
- Default (failure to meet payments for purchase of shares)

Death of a partner is one of the most important reasons to have an operating agreement in place. If you were to die unexpectedly, what would happen to your equity in your practice? Would your family or heirs receive a fair price or be paid at all for your investment in the practice? How would the practice value be determined? Would your family receive that value as a lump sum or over time with a promissory note? If paid over a period of time, would the note be secured? What would happen if the practice subsequently failed to produce sufficient profit to pay the note? These same questions could apply for the loss of one of your partners. Could you and your practice afford to pay the value of their shares to their surviving family members? How quickly could you do this? Many practices choose to carry a life insurance policy on each partner payable to the practice in order to meet these obligations. The same concerns can surround a disability following injury or illness.

When bringing on a partner, there are many questions to be answered to document expectations. A well-written operating agreement allows for smooth ownership operations and transitions. Don't leave this to chance!

Selling Shares in a Group Practice

When selling one's shares in an existing practice, the valuation methodology and process is generally spelled out in the operating agreement. A well-written operating agreement prevents each departure from being a separate negotiated transaction. Practices that do not have an operating agreement that memorializes "how things work" can find themselves struggling when transitions of ownership occur.

Shares can be sold back to the company ("inside" sale) or directly to an individual ("outside" sale). Often, operating agreements require that any buyer into the company must be approved by all the existing partners and may include other conditions of sale.

Selling a Sole Owner Practice to Associates

There are distinct advantages to associate buyers if they purchase an existing practice, but only if it has an excellent reputation, has strong practice brand identity, appropriate financial policies that insure good cash flow, and a well-trained engaged staff. There is no advantage to buyers if they are gaining clients trained to pay sporadically, expecting non-urgent access to veterinarians at all times, and stubbornly bonded to the retiring seller. These practices often also have high accounts receivable, staff loyal only to the seller, and minimal policies and compliance. However, there can be opportunities in purchasing a practice such as this, if the purchase price reflects the difficulty the purchaser will have in pivoting the practice to new management.

Many equine veterinarians working as associates long to be owners in order to put their ideas into the practice, increase their financial prospects, and be able to have more control over their careers. Because they want to be able to affect change, small percentages of ownership (2–5%) are often not very effective in retaining associates in small practices. They understand these offers as a way to lock them into a practice without providing the aspects of ownership they really desire. Some business management experts recommend locking in associates in this way as minority partners and having operating agreements that compel them to later buy out the retiring owner(s) at the prevailing value at retirement. While this is a great strategy for the practice owners, it is does not have the same effect for the minority shareholder.

It is much better to offer meaningful partnership to associates once they have shown they can produce robust revenue and have compatible values. In past times, these offers were made to associates after 2–5 years of service. As the profession became feminized, this way of passing on ownership of practices changed. Although studies have shown that 58.7% of male associates and 48.0% of female associates in equine practice are interested in practice ownership, and an additional 1 in 7 are unsure, equine practice owners persist in believing that their associates don't want to be owners. Perhaps what is really happening is that the conditions necessary for a sale are not present – the right price, the right % of shares, and the right degree of possibility for meaningful change brought about by a new partner.

If a sale to an associate or even two associates is desired, consider offering them partnership share percentages equal to the other owners five years before retirement. Be ready to lean into change and support it. Champion your new partners' ideas and help them succeed. Understand that if the sale price is appropriate, it should be able to be financed over a ten-year period at a prevailing rate of interest with the new partners' share of profit being sufficient to pay the principal, interest, and taxes on the profits they receive. Generously teach them what you know about successful management of a business while allowing them to be excited about growing the firm. Your reward will be the successful sale of your small practice and your legacy living on.

Selling a Solo Practice

For at least the last decade, solo practitioners have made up nearly 40% of AAEP members. These veterinarians have made their careers as sole proprietors for a variety of reasons, but most have prized the independence that working alone provides. One of the biggest challenges that solo equine practitioners face is determining an exit strategy when they are ready for retirement or an alternative career.

Some options when retiring from solo practice include simply informing clients of the retirement and referring them to other local colleagues through a letter; identifying a local practice interested in acquiring the retiring veterinarian's practice; selling the client list to a trusted colleague and actively supporting the transition of clients; or selling the practice to a new solo owner.

In the current environment, most veterinarians will not be interested in purchase of a solo practice because it does not offer an advantage to opening a practice of their own. Occasionally, a solo practice that can demonstrate that their clients will remain loyal to the new owner; has a well-rounded arsenal of diagnostic equipment; has strong policies and procedures; will retain existing staff members; and has shown a reliable and robust stream of profit each year can be sold. However, because the solo practitioner is the brand identity, unless they can step back and bring in the buyer as an associate to whom they can bond the clients for six months or so prior to the sale, the sale of a solo practice is generally very difficult or impossible. Alternatively, these practices can often sell their client list as well as their used equipment.

Client list sales are typically structured such that the purchaser pays a percentage of the revenue that is earned from the seller's clients over a three-year period. The first year the buyer typically pays 15–20% of the revenue earned that year from the seller's clients, with the second year dropping the percentage paid on earned revenue by about a third (10–13%), and the third year an additional third (5–7%). This approach requires some trust and detailed recordkeeping. The buyer is expected to print an accounting of monies earned from the seller's previous clients at the end of each year, which usually means logging them into practice management software in a way that allows these reports to be generated. The payments can be made quarterly or annually. Sometimes there are clients that used both the seller and the buyer before the sale, so defining what revenue will be counted is essential.

With a client list sale, the seller sends a letter to clients stating that their records will be transferred to the buyer's practice unless they request otherwise. As it is to the seller's benefit that their clients transfer to the new service provider, the seller typically also expresses confidence in the new veterinarian and tries to help the doctor succeed by being available to them for questions about clients or patients for a time after the sale.

It is important to consider that exit strategies for solo practitioners do not always need to rely on a practice sale. Well-managed solo practices can produce robust profits that, if invested wisely on an ongoing basis, can yield excellent long-term gains. Some veterinarians simply harvest as much money from their work as they can over the course of their career and then simply sell their equipment when they are ready to retire. As they age, some of these doctors begin to limit their practice to certain areas in which they have special competencies, and they reduce their client list to slow their growth and minimize the number of hours they work. In these practices, the legacy of the veterinarian is kept in the memories of the clients they served.

Merging Practices

Sometimes neighboring practices decide to merge to increase economies of scale, share resources, and minimize on call duties. When one of the practices has an owner or owners approaching retirement age, this can provide an excellent way to transfer clients, ease into a slower work pace, and receive value for a practice in the future. Sometimes practices merge in order to be large enough to attract a corporate buyer. Other times, mergers provide a way for a group practice of younger veterinarians to consolidate nearby small practices as their owners near retirement, in order to have an orderly transfer of client loyalty. This often also appeals to retiring veterinarians who are concerned about good care for their clients. When merging, owners must have compatible values, embrace flexibility, and believe that the pain of change will be exceeded by the positive gains. Stepping away from calling all the shots and having complete control can be difficult for some people who have not been in a partnership in the past. Keeping the focus on the reasons for the merger can help.

Mergers also require careful attention to details such as which practice's software and price list will be used, whether the practice will have a new name, and how the shares of the new company will be allocated. These details can sometimes be surprisingly hard to come to agreement on. Again, returning to the original objectives of the merger can help increase flexibility. It is often best to have money exchange hands to

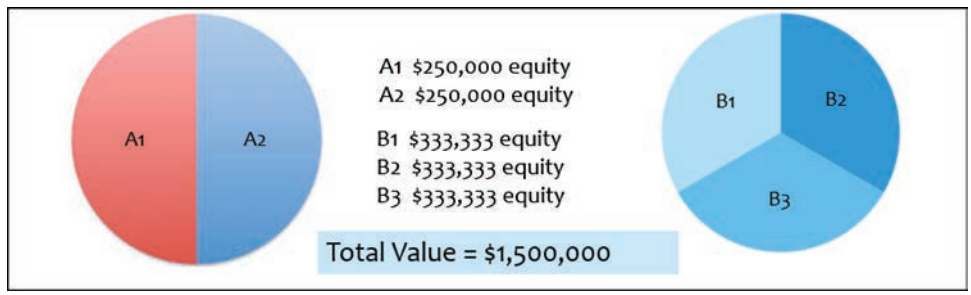

Fig. 1. Merger of Practice A and Practice B.

"even up" ownership amounts, so partners have equal shares.

In determining ownership percentages in the new merged company, generally both practices are valued by the same professional, using identical assumptions to make adjustments to the financial statements, and then the shares in the new company are apportioned to the new owners accordingly. For instance, if Practice A with two equal owners is valued at $500,000 and Practice B with three equal owners is valued at $1,000,000, the merged practice value of $1,500,000 will be apportioned as follows: Owner A1 16.66% ($250,000/$1.5M), Owner A2 16.66%, Owner B1 22.22% ($333,333/$1.5M), Owner B2 22.22%, and Owner B3 22.22%. (See Fig. 1)

Mergers can be hard to manage, as veterinarians have lived with certain policies and procedures for years and can resist change. Creating continuity and consistency in merged practices is important but difficult. All parties must be flexible and driven to succeed in the merger. Redundancy may cause the need for staff shrinkage, which can be a source of friction. Differing preferences for equipment or pharmaceuticals can also arise. The details are often where the disagreements pile up. Having compatible values and good communication skills is essential in mergers.

3. Conclusion

Although small practices make up the majority of equine firms in the United States, transfers of ownership in these businesses can pose challenges that require flexibility to overcome. Planning an exit strategy well in advance of retirement is often the best way to harvest the highest value from one's practice asset. Partnership with an associate early in their career with a meaningful or equal portion of the practice has the highest probability of success. Solo practice owners need to put profit away for retirement through the years as they practice and work to sell their client list to a local colleague at the time of their retirement if they are unable to attract an associate eager to be the buyer. Mergers may provide a good solution to gleaning value from a small practice but require high levels of cooperation and collaboration. Most importantly, owners of small practices should be proactive in planning for the future of their business.

Acknowledgments

Declaration of Ethics

The Author has adhered to the Principles of Veterinary Medical Ethics of the AVMA.

Conflict of Interest

The Author has no conflicts of interest.

References and Footnote

1. VMA AAEP Equine Economic Impact Study. https://aaep.org/sites/default/files/Documents/AAEP_Webinar_05-27-20_%202019_FINAL_AMVA_AAEP_Equine_Report.pdf. Accessed January 15, 2022.
2. Grice, A. Operating Agreements among Veterinary Partners. 2020, Jul 14. https://equimanagement.com/articles/operating-agreements-among-veterinary-partners. Accessed March 31, 2022.

[a]John Chalk, CPA, JD, CFP®, ChSNC (personal communication), 2021.

Selling to a Corporate Entity

Andrew R. Clark, DVM, MBA

Author's address: Avanti Equine Veterinary Partners, PO Box 547, Columbus, NC 28722; email: aclark@advantiequine.com. © 2022 AAEP.

Selling an equine practice at full value is a relatively new opportunity for equine practice owners. Historically, equine practices have transacted at a discounted rate because these practices were not a liquid asset, as there was virtually no marketplace in which to sell those practices other than internal sales to associates. The discount factor has been referred to as a marketability discount. The marketability discount arose because equine practices were an illiquid asset with no ready pool of buyers for the practices. Practice owners had to "grow their own" buyers from the associate pool. The full value of a practice was calculated using business valuation formulas commonly used in all types of businesses, then a marketability discount was applied to the true value to arrive at the price at which there was a willing "home grown" buyer and a willing practice owner seller. The discount rate was a subjective number, varying from practice-to-practice to arrive at the maximum price the associate would pay and the minimum price the practice owner would accept. Practice owners sold the practice or parts of the practice to associate(s) at the discounted value, usually financing the sale themselves and holding the practice as collateral. The buyer was generally a long-term associate veterinarian in the practice. Because for many years there was no non-associate marketplace for equine practices, associate veterinarians' belief that "an equine practice just isn't worth that much" has eroded even the discounted value of an equine practice. Associate veterinarian disbelief in the economic value of an equine practice has many origins and is a topic for another day. This resulted in many equine practitioners simply continuing to work into their 70s and 80s and ultimately walking away from their practices. Recently, a new equine practice marketplace has developed in which corporate investors believe that a practice is worth more, not less, than historic valuations, and those corporate investors have begun acquiring equine veterinary practice businesses at those high valuations. Selling any asset requires a willing seller and a willing buyer. Tension in the marketplace for equine practice sales results from having two groups of buyers: associate veterinarians and corporate buyers. These buyers have a significant difference of opinion regarding the value of an equine practice. This dynamic creates a difficult decision for some sellers of an equine practice. The seller may have a willing corporate buyer at market value and another willing associate veterinarian buyer at a discounted value, often deeply discounted. The seller is faced with a decision having at least two components, financial and nonfinancial, to become a willing seller.

- The financial component is whether to accept a higher price or lower price for the practice.
- The non-financial component is much more complex and varies from seller to seller, often including legacy in the community and generous "familial" feelings for the associate(s).

To become a willing seller to one or the other of those buyers, the seller must fully understand the variables on which they are making one of the most critical decisions in their life.

NOTES

1. What Is the Buyer of an Equine Practice Acquiring?

A corporate buyer, as well as an associate buyer, is buying a stream of cash that the business will deliver to the buyer into the future. The unit of measure commonly used to value that stream of cash is earnings before interest, taxes, depreciation, and amortization (EBITDA). The practice's EBITDA is the basis of what is being sold to the buyer. The strategic goals of most corporate buyers are threefold:

1. To be the veterinary service provider of choice.
2. To be the employer of choice.
3. To be the investment of choice.

The strategic goals of most associate buyers are also threefold and very similar:

1. To be the veterinary service provider of choice.
2. To have a higher income, i.e., investment of choice.
3. To have control over their career and create their own practice culture that suits their specific needs and values, i.e., employer of choice.

The value of a practice is usually calculated as a multiple of the businesses' EBITDA. The "multiple" in the equation is dependent upon the level of uncertainty that the stream of cash delivered by the business will grow over time. A seller can maximize the valuation of their equine practice by decreasing the uncertainty of future delivery of that stream of cash to the buyer. The level of risk of future returns can substantially impact value. There are many factors which increase or decrease the level of uncertainty. A few of the common risk factors are listed below:

1. Client's personal brand loyalty to the practice owner(s) rather than to the practice.
2. No successor lead veterinarian identified and trained.
3. Random pricing strategy that is not based on cost of providing a service.
4. Low collection at time of service.
5. Casual inventory management without routine inventory counts and location tracking.
6. Non-compliant controlled substance program.
7. Reliance on billing records rather than board of examiners compliant medical records.

Whether or not an equine practice can be sold to a corporate entity and, if so, the valuation of the practice depend on whether the business has been developed and managed to minimize business uncertainty in the future. The three primary objectives of the practice ownership team contemplating sale to a corporate aggregator should be to maximize EBITDA, client loyalty, and establish a veterinary successor as the leader of the veterinary team. Lowering those should probably be the three primary objectives in managing a veterinary business whether or not it is for sale. Another way to look at management to maximize return to the owner and value of the practice is to identify and mitigate risks that impact cash flow, profitability, and regulatory compliance consequences.

2. Maximizing EBITDA

Think of an equine practice as a black box into which money and effort are the inputs and cash is the output. The cash output is EBITDA. The largest two expenses of an equine practice are drugs and medical supplies, and payroll. Managing these components toward efficiency while not sacrificing excellence, should be the primary goal in managing the business. The revenue and cash flow generated by the caseload of a practice is influenced by pricing, discounting, and collection policy. The higher the price, the lower the discounts, and the sooner money is collected, the more EBITDA the practice can sell. A major obstacle to healthy EBITDA is the tendency of veterinarians to assume responsibility for subsidizing an expensive hobby of their clients.

Client Loyalty

Client loyalty must be to the practice, not to the individual veterinarian. Personal brand loyalty adds virtually no value to a buyer, while practice brand loyalty has tremendous value. Clearly, a solo equine practice's client loyalty is loyalty to the veterinarian, minimizing value. However, several very valuable group equine practices have been formed by merging solo practices, creating brand loyalty, and building leadership. Opportunities for subsequent sale to corporate entities have followed.

Successor Veterinary Leadership

Historically, equine practice lead veterinarians have been the owners of the practice. Following the sale of an equine practice to a corporate buyer, the veterinarians of the practice will probably prefer to be led by another veterinarian rather than a lay person. Having successor lead veterinarian(s), a compensated position, in place prior to the sale minimizes uncertainty and increases the value of the practice.

Summary

There is no set formula for what the selling veterinarian(s) role will be post sale. Some sellers want to retire immediately. This can significantly reduce the value of the practice unless client loyalty to the practice and a strong successor lead veterinarian are in place. The usual path is for the selling veterinarian(s) to remain employed as associate veterinarians with a leadership role for a few years. Some sellers expect to stay on as an associate with a leadership role for many years. The multiple used in the valuation of a veterinary practice will be proportionally higher in relation to the success in establishing client loyalty and a successor lead veterinarian(s). Whether or not an owner or owners sell to a corporate group, equine practices with clients loyal to the practice and strong practice lead veterinarians are usually more profitable businesses, so fetch a higher price. Think of an

equine veterinary business as a circular cycle with systems and strategies in place to attract and retain veterinarians, technicians, assistants, staff, clients, patients, and ultimately to attract new owners. Corporate buyers are looking for EBIDTA, a culture of client loyalty, and veterinary leadership into the future.

Acknowledgments

Declaration of Ethics

The Author has adhered to the Principles of Veterinary Medical Ethics of the AVMA.

Conflict of Interest

The Author has no conflicts of interest.

How to Milk Mares and Maintain Milk Production

Scott Austin, DVM, MS, DACVIM

Author's address: University of Illinois, 1102 West Hazelwood Drive, Urbana, IL 61802; e-mail: smaustin@illinois.edu. © 2022 AAEP.

1. Introduction

When treating sick foals, it is not unusual that supplemental nutrition is required. Mare's milk is the best and most natural source of nutrition, but it may be a challenge to maintain milk production in mares that are not being suckled and are being milked by hand. Mares must be milked frequently due to the small size of the cisternal compartment. Mares may be difficult to milk by hand due to discomfort and failure to stimulate milk letdown. There are thoughts that mares let down milk in response to normal mothering behavior rather than tactile stimulation of the teat. Milk letdown may be impaired when attempting to feed a recumbent foal. Hand milking can make the mare sore, and it may be difficult to milk the mare out completely. Incomplete emptying of the udder at each milking may contribute to the decrease in milk production seen in mares that are hand milked. The continued friction of the thumb and forefinger against the mare's skin can result in tenderness and decreased compliance of the mare. Cleanliness is essential as bacteria from the milker's skin can lead to mastitis.

2. Materials and Methods

Milking Options

Commercial milkers[a] are available that have a trigger operated vacuum pump and are designed to fit the unique shape of the teat and udder. The pumps are not inexpensive and will wear out over time. They also do not withstand a few kicks by agitated mares. Small studies have suggested that milk yield is higher and milking time is shorter in mares that are milked by machine compared to hand milking.[1]

If a commercial milker is not available, a 60-mL syringe can easily be converted for use. The plunger should be backed up an inch, and the needle end of the syringe can be cut off with a saw. A vice can facilitate this procedure. Tin snips are an easily available alternative to a saw. After removal of the needle end of the syringe, the plunger should be removed and placed in the barrel from the other direction. This leaves the smooth flange end that can be placed over the teat and against the udder (Fig. 1). Gentle pressure can then be applied, and the syringe will fill with milk. Avoid overzealous pressure and be careful to not pull the plunger out of the syringe and lose the milk. With this method, a mare can quickly and easily be milked out. Volumes of 500 mL to 1 L should be obtained every 2 hours.

Improve Milk Letdown

Regardless of the method used, it is imperative to prepare the mare. Someone offering feed or allowing the mare to nuzzle the foal can be helpful to achieve milk letdown. A warm compress should be applied to the udder to both stimulate milk letdown and to remove smegma, dirt, and debris. After gently

NOTES

Fig. 1. A 60-mL syringe converted into a milking syringe by removal of the needle end of the syringe and reversing the plunger.

cleaning, the mare can be milked. Metal bowls may frighten the mare due to the noise of the milk hitting the bowl. It is imperative that if milking into a bowl, the operator be able to maintain a firm hold on the container and be able to move with the mare. The commercial milker and syringe method allow the operator to not lose the milk obtained if the mare moves during the procedure. If particulate matter from the udder is found in the milk, straining the milk through a 4 × 4 gauze is all that is necessary to remove debris.

Feeding the Foal

It is important that all equipment used to collect and store milk is cleaned thoroughly between uses. Foals can be fed through an indwelling stomach tube. Foals that suffer from neonatal maladjustment must be fed carefully as they may not be tolerant of enteral nutrition. The tube should always be checked for reflux before giving milk. Commercial feeding bags[b] can be used, but 1-L fluid bags with an attached primary administration set can be adapted if alternatives are not available. A slit can be made in the top of the bag to allow milk to be poured in, and the bag can be hung to administer milk to recumbent foals or can easily be carried if feeding ambulatory foals. It is best to start by giving about 5% to 7% of body weight as milk the first day divided into hourly feedings. The foal must be standing or in sternal recumbency during and for at least 10 minutes after feeding. All milk must be administered by gravity flow. If the foal tolerates enteral nutrition, then the amount of milk may be gradually increased. Ten percent of body weight as milk may be given on days 2 and 3 and then increased to 15% to 20% of body weight per day over the subsequent days. Most foals that require nutritional support show a positive response in 1 to 2 days and resume suckling.

Improving Milk Production

Despite the best intentions, mares that are being milked for several days often experience decreased milk production. Care should be taken to make sure that adequate nutrition and water are provided to support lactation. Inexperience of personnel, stressful environment, overaggressive milking, inadequate emptying of the udder, reduced frequency of milking, and failure to mimic natural udder stimulation may all contribute to the decline in milk production. Acepromazine maleate[c] (0.02–0.06 mg/kg, IV or IM) may be administered as a tranquilizer to anxious mares and to take advantage of its prolactin promoting effects.[2] If milk production is falling, dopamine D2 receptor antagonists such as domperidone[d] (1.1 mg/kg, orally, q 24 h for 4 days) or sulpiride[e] (1 mg/kg, IM, q 12 h) may be administered for their prolactin promoting effects. When available, sulpiride is felt to be the preferred drug for induction of lactation in mares.[3] Occasionally, foal rejection may be encountered when a previously weak or recumbent foal is strong enough to resume nursing. Keeping the mare and foal in close proximity aids in maintaining the maternal bond. Prior to returning the foal to nursing, all milk feeding should be stopped 4 hours prior so that the foal is hungry. The administration of prostaglandins can be a strong stimulant of maternal behavior. Dinoprost tromethamine[f] (0.05 mg/kg, IM) may be used, and the foal is carefully introduced to the mare in 20 minutes, usually during the period of mild sweating, restlessness, and softening of the manure seen in the mare at peak prostaglandin activity. If maternal behavior such as licking, sniffing, and nickering to the foal is not seen within 10 to 15 minutes of introduction of the foal, cloprostenol sodium[g] (0.001 mg/kg, IM) may be administered. Butorphanol tartrate[h] (0.02 mg/kg, IM) may be administered to mares that become overly uncomfortable after prostaglandin treatment.[3]

3. Results

Using the methods described here have been successful in the author's hospital for providing short-term nutritional support to recumbent or weak foals that tolerate enteral feeding. These methods facilitate nutritional support of the foal while maintaining lactation in the mare so the foal may be returned to its dam once it has recovered.

4. Discussion

It is not uncommon for a veterinarian to need to milk a mare to provide valuable nutrition to the foal. Milking may be necessary to provide valuable colostrum to a weak or slow foal that has not suckled before gut closure occurs or during the treatment of sick neonates that are too weak to suckle on their own. While milk replacers can provide the necessary nutritional requirements, the author believes mare's milk is superior for intestinal development and function. Feeding mare's milk appears to be tolerated better by foals and results in less digestive upset than milk replacer. Careful attention to milking

practices can maintain milk production with the goal of reuniting the mare and foal after resolution of the foal's illness.

Acknowledgments

Declaration of Ethics

The Author has adhered to the Principles of Veterinary Medical Ethics of the AVMA.

Conflict of Interest

The Author has no conflicts of interest.

References and Footnotes

1. Caroprese M, Albenzio M, Marino R, et al. Behavior, milk yield, and milk composition of machine- and hand-milked Murgese mares. *J Dairy Sci* 2007;90:2773–2777.
2. Bryant CD, Connan RM, Greenwood FC. Changes in plasma prolactin induced by acepromazine in sheep. *J Endocrinol* 1968;41:613–614.
3. Podico G, Migliorisi AC, Wilkins PA, et al. Successful induction of lactation, foal grafting and maintenance of pregnancy in a nonparturient Thoroughbred mare. *Equine Vet Educ* 2022;34:e1–e10.

[a]Udderly EZ, EZ Animal Products, Lexington, KY 40504.
[b]Kangaroo Bag, Medtronic, Minneapolis, MN 55432.
[c]Acepromazine®, Boehringer Ingelheim Vetmedica, Inc., Boise, ID 83705.
[d]Equidone®, Dechra Veterinary Products, Overland Park, KS 66211.
[e]Lutalyse®, Zoetis Inc., Kalamazoo, MI 49007.
[f]Estrumate®, Merck Animal Health, Madison, NJ 07940.
[g]Sulpiride, Hagyard Pharmacy, Lexington, KY 60511.
[h]Torbugesic®, Zoetis Inc., Kalamazoo, MI 49007.

Behavior and Perinatal Parameters of Mule Foals

Yatta Linhares Boakari, DVM, MsC, PhD; Maria Augusta Alonso, DVM, MSc, PhD; Polyanna Nunes da Silva, DVM; and Claudia Barbosa Fernandes, DVM, MSc, PhD*

Mules have perinatal characteristics that are different from domesticated horse foals, such as shorter time to onset of suckling, resulting in faster adaptation to the extrauterine environment. Authors' addresses: Department of Large Animal Clinical Sciences, College of Veterinary Medicine and Biomedical Sciences, Texas A&M University, College Station, TX, 77843–4466 (Boakari); Department of Animal Reproduction, School of Veterinary Medicine and Animal Science, University of São Paulo, São Paulo, Brazil (Alonso, da Silva, Fernandes); e-mails: fernandescb@yahoo.com.br, fernandescb@usp.br. *Corresponding and presenting author. © 2022 AAEP.

1. Introduction

Reference ranges of behavior and perinatal characteristics of mules are paramount for early diagnosis and intervention of compromised animals. The objective was to evaluate and compare neonatal behaviors and parameters of mules and domesticated horse foals.

2. Materials and Methods

A total of 47 healthy foals from eutocic births were evaluated (n = 30 mule and 17 domesticated horses). Modified Apgar score (MAS) at birth, 5, 10, 30, and 60 minutes postpartum, and times to sit in sternal recumbency, start suckling reflex, stand, onset of suckling, and meconium elimination after birth were evaluated. Time to placental expulsion was recorded. A model using MAS with group, time, and interaction using time as repeated measures was performed, followed by a Tukey test. Significance level was set at $p \leq 0.05$.

3. Results

There was a group effect for MAS during the first 60 minutes postpartum, with mule foals having a higher score compared to domesticated horse foals (7.93 ± 0.02 and 7.60 ± 0.07, respectively; $p < 0.0001$). Onset of suckling was faster in mule foals (49.3 ± 2.71 minutes) than domesticated horse foals (81.86 ± 8.41 minutes; $p < 0.001$); however, meconium elimination was slower in mule foals when compared to domesticated horse foals (255.83 ± 18.14 and 76.66 ± 7.79 minutes, respectively; $p < 0.001$). Mares pregnant with mule foals eliminated their placenta faster when compared with those pregnant with domesticated horse foals (35.00 ± 4.06 and 113.38 ± 24.70 minutes, respectively; $p = 0.0004$).

4. Discussion

Mule foals might have a faster neurological and hormonal adaptation to extrauterine life, nursing earlier

Research Abstract—for more information, contact the corresponding author

NOTES

than domesticated horse foals, thus stimulating maternal oxytocin release and faster placental elimination. Nevertheless, meconium elimination took longer in mule foals, which can be an interspecies characteristic resulting in a different gastrointestinal motility pattern. This study describes perinatal development parameters of healthy mule foals enabling prompt identification of abnormal neonatal behavior and peripartum events.

Acknowledgments

Declaration of Ethics

The Authors have adhered to the Principles of Veterinary Medical Ethics of the AVMA.

Conflict of Interest

The Authors have no conflicts of interest.

Abnormal Mare Behavior Is Not Often Associated with Changes in Hormonal Markers of Granulosa Cell Tumors: A Retrospective Study

Lauren Huggins, VMD, MS†; Alan Conley, BVSc, PhD, DACT (hon); and Pouya Dini, DVM, PhD, PhD, DECAR, DACT*

Only stallion-like behavior was associated significantly with abnormally elevated reproductive hormone concentrations among mares with abnormal or undesirable behaviors as assessed and reported by owners submitting samples for endocrine analysis. Authors' address: University of California-Davis, One Garrod Drive, Davis, CA 95616; e-mails: pdini@ucdavis.edu; lmhuggins@ucdavis.edu. *Corresponding author; †presenting author. © 2022 AAEP.

1. Introduction

Owners commonly suspect that abnormal or undesired mare behaviors are associated with elevated reproductive hormones. This study aimed to determine the incidence of abnormal behaviors and their association with concentrations of one or more reproductive hormones.

2. Materials and Methods

A total of 2,914 hormonal profile samples submitted to UC Davis Clinical Endocrinology Laboratory with the words behave, behavior, or behaving in the history were analyzed. Association between reported abnormal behaviors and concentrations of testosterone, anti-Müllerian hormone, inhibins, and inhibin-B were assessed. Statistical analysis was performed using a Chi-squared test of association.

3. Results

Abnormal behaviors were associated significantly with elevated hormone concentrations in less than 10% of samples. Stallion-like behavior was significantly associated with elevated concentrations of all four hormones, while aggression, estrous, and other abnormal behaviors were significantly less likely to be reported with submissions.

4. Discussion

Owner-assessed abnormal behaviors among mares, variously described and in general, were not associated with increased ovarian hormones. Of behaviors commonly attributed to reproductive hormones, only stallion-like behavior was associated significantly with elevated concentrations. These results highlight the common

Research Abstract—for more information, contact the corresponding author

NOTES

assumption among owners about the involvement of ovarian hormones in "abnormal behaviors" of mares.

Acknowledgments

Declaration of Ethics

The Authors have adhered to the Principles of Veterinary Medical Ethics of the AVMA.

Conflict of Interest

The Authors have no conflicts of interest.

Evaluation of IgG Content of Mare Colostrum in the Postpartum Period

Emily M. May, DVM*; Patrick M. McCue, DVM, PhD, DACT; Brittany T. Middlebrooks, DVM, MS; and Mason Schumaker, BS

A Brix refractometer can be used to evaluate quality of colostrum immediately following foaling and monitor the depletion of immunoglobulin G (IgG) as the foal nurses during the early postpartum period. Authors' address: Equine Reproduction Laboratory, Colorado State University, 3101 Rampart Road, Fort Collins, CO 80521; e-mail: matty.may@colostate.edu. *Corresponding and presenting author. © 2022 AAEP.

1. Introduction

There is no transplacental transfer of maternal antibodies from the mare to the fetus *in utero*. Newborn foals acquire immunoglobulin G (IgG) following ingestion of colostrum in the first 24 hours of life. Repeated bouts of nursing by the newborn foal decrease the IgG concentration of antibodies in the mammary fluid over time. The goals of this project were to 1) describe the quality of mare colostrum in the immediate postpartum period relative to mare parity and age, 2) evaluate the relationship between colostrum quality at foaling and foal plasma IgG concentration at 12 hours of age, and 3) describe the depletion of IgG concentration in mammary fluid over a 48-hour period postpartum.

2. Materials and Methods

Colostrum samples (< 0.5 mL) were collected from 229 mares immediately after foaling and applied to a Brix refractometer to evaluate quality (Brix score, %). Quality assessment was compared between multiparous mares and maiden mares, as well as compared by age groups (< 10, 10–14, 15–19, and ≥ 20 years of age). The initial Brix score of the colostrum was subsequently compared with the plasma IgG concentration of foals at 12 hours of age as determined by a validated immunoturbidometric assay. Finally, the depletion of IgG antibodies was determined in mammary fluid collected from a subset of 10 mares at defined times over the first 48 hours postpartum by both single radial immunodiffusion (SRID) assay and Brix refractometry. The subset of mares was randomly selected from a population of 70 mares foaling in 2022. Data are presented as the mean ± standard deviation. The intra-assay coefficient of variation was 2.1% for the SRID assay. The interassay coefficient of variation for the Brix refractometry assessment was 0.2%.

3. Results

The average Brix score for the 229 colostrum samples collected immediately after foaling was 27.1 ± 4.8%. Samples from 91 mares were ≥ 30% (very good quality), 123 mares were 20% to 29% (good quality), 10 mares

Research Abstract—for more information, contact the corresponding author

NOTES

were 15% to 19% (fair quality), and 5 mares were ≤ 14% (poor quality). There was no statistical difference ($p > 0.05$) in colostrum quality between multiparous mares (27.3 ± 4.5%; $n = 139$) and primiparous mares (26.0 ± 5.5%; $n = 51$). There was also no difference in colostrum quality between mare age groups (27.9 ± 4.6, < 10 years; 26.6 ± 4.9, 10–14 years; 27.1 ± 4.6, 15–19 years; 26.0 ± 5.6, ≥ 20 years). The average plasma IgG concentration of foals born to mares with a colostrum Brix score of < 20% (1456.7 ± 572.4 mg/dL; $n = 15$) was significantly less ($p < 0.05$) than the IgG concentration of foals born to mares with a colostrum Brix score of 20% to 29% (1775.9 ± 377.5 mg/dL; $n = 123$) or ≥ 30% (1775 ± 483.6 mg/dL; $n = 91$). There was a strong correlation, $r(98) = 0.97$, $p < .05$, between the SRID IgG values and Brix refractometer scores for colostrum samples collected from the subset of mares during the first 12 hours postpartum. Colostrum IgG concentration and Brix score immediately after foaling were 20694.0 ± 6284.3 mg/dL and 28.2 ± 4.0%, respectively, and declined to 1720.4 ± 1910.8 mg/dL and 11.1 ± 1.8%, respectively, at 12 hours postpartum, and 626.1 ± 232.0 mg/dL and 10.5 ± 0.5%, respectively, at 24 hours postpartum.

4. Discussion

Evaluation of colostrum using a Brix refractometer is a rapid and inexpensive technique to estimate quality, and results are correlated with IgG content as determined by SRID assay. Foals born to mares with fair or poor-quality colostrum have lower plasma IgG concentration than foals born to mares with good- or very good-quality colostrum. Mares with fair- or poor-quality colostrum can be identified early and their foals supplemented with frozen-thawed colostrum and/or a colostrum substitute orally within the first few hours after birth. Knowledge of colostrum quality is also important when selecting mares from which to harvest colostrum for banking. Colostrum should be harvested as soon as possible in the postpartum period to optimize colostrum quality as nursing by the foal results in rapid depletion in IgG. In addition, understanding when colostrum IgG concentrations decline to baseline levels can be helpful in determining when to allow a foal considered to be at risk of neonatal isoerythrolysis to nurse from their dam.

Acknowledgments

Declaration of Ethics

The Authors have adhered to the Principles of Veterinary Medical Ethics of the AVMA.

Conflict of Interest

The Authors have no conflicts of interest.

Ovum Pick up in a Clinical Program Can Induce Mild Transient Discomfort in Mares

Soledad Martin-Pelaez, DVM†; T.A.E. Stout, MA, VetMB, PhD, DECAR; Bart Leemans, DVM, PhD; Pouya Dini, DVM, PhD, PhD, DECAR, DACT; and Anthony N. Claes, DVM, PhD, DACT*

Equine ovum pick up is generally a safe procedure, but mares can display signs of pain and discomfort for up to 3 days after follicle aspiration. Authors' addresses: Department of Clinical Sciences, Faculty of Veterinary Medicine, Utrecht University, Yalelaan 112, Utrecht, the Netherlands (Stout, Leemans, Claes); Department of Population Health and Reproduction, School of Veterinary Medicine, University of California-Davis, Davis, CA 95616 (Martin, Dini); e-mail: pdini@ucdavis.edu; smartinpelaez@ucdavis.edu. *Corresponding author; †presenting author. © 2022 AAEP.

1. Introduction

Aspiration of follicles to harvest oocytes for in vitro embryo production is a reproductive technique that is growing in popularity in clinical practice. To date, there is little data regarding the well-being of mares following aspiration. The objective of this study was to investigate the frequency and severity of complications associated with ovum pick up (OPU) and to identify factors influencing the well-being of mares after OPU in a clinical program. The authors hypothesized that different degrees of pain and discomfort occur after OPU, and they could be associated with mare factors.

2. Materials and Methods

Data were collected between 2019 and 2021 from 913 OPU procedures using a client survey to record body temperature, appetite, attitude, scraping, and lying down in the 3 days after OPU. Only Warmblood and Arabian mares were included in the study.

3. Results

No fatal complications were observed. Some form of discomfort (fever, loss of appetite, lethargy, lying down, or scraping) was observed in 24% of mares the day after OPU, decreasing to 10% and 3% on days 2 and 3, respectively. Furthermore, young ($p = 0.02$) and competing ($p < 0.001$) mares were more likely to show signs of discomfort than older mares and broodmares.

4. Discussion

These results indicate that, in experienced hands, OPU is a safe procedure associated with minor post-procedure discomfort, but they also highlight the importance of adequate post-OPU pain management protocols, especially in young, competing mares.

Research Abstract—for more information, contact the corresponding author

NOTES

Acknowledgments

Declaration of Ethics

The Authors have adhered to the Principles of Veterinary Medical Ethics of the AVMA.

Conflict of Interest

The Authors have no conflicts of interest.

Ovarian Removal Before or After Euthanasia for Postmortem Gamete Retrieval: An Assessment of Pentobarbital Concentration in the Follicular Fluid

Soledad Martin-Pelaez, DVM†; Peyton Draheim, DVM; Zachary Rabow; Alan Loynachan, DVM, PhD, DACVP; Stuart Meyers, DVM, MS, PhD, DACT; Candace Lyman, DVM, DACT; and Pouya Dini, DVM, PhD, PhD, DECAR, DACT*

Pentobarbital was found in the post euthanasia follicular fluid at a concentration threefold lower than in the serum samples from the same mares. A similar concentration of pentobarbitol[a] as detected in the follicles that were collected immediately (5 min) and 24 hrs after euthanasia. Authors' addresses: Department of Population Health and Reproduction (Martin, Dini), Department of Anatomy, Physiology, and Cell Biology (Meyers), School of Veterinary Medicine, University of California-Davis, Davis, CA 95616; College of Veterinary Medicine, Auburn University, Auburn, AL, 36849 (Draheim, Lyman); National Institute of Health West Coast Metabolomics Center, University of California-Davis, Davis, CA 95616 (Rabow); Veterinary Diagnostic Laboratory, Department of Veterinary Science, University of Kentucky, Lexington, KY, 40511 (Loynachan); e-mails: pdini@ucdavis.edu; smartinpelaez@ucdavis.edu. *Corresponding author; †presenting author. © 2022 AAEP.

1. Introduction

With the current advances in assisted reproductive techniques (ART) such as postmortem gamete retrieval and in vitro embryo production (IVP), a new possibility arises for obtaining postmortem progeny. However, the effect of euthanasia agents on the outcome of IVP is unknown. In this study, the presence of pentobarbital[a] as the most common euthanasia solution, in the follicular fluid (FF) of mares after euthanasia was assessed.

2. Materials and Methods

Follicular fluid (n = 20) from mares after euthanasia, FF (n =10) from mares after ovariectomy (negative control), and serum from mares after euthanasia (positive control; n = 5) were collected immediately or ~24 hrs after euthanasia. The follicles were aspirated and stored at −20°C. Samples were extracted and the concentration of pentobarbital was measured by gas-chromatography/mass-spectrometry.

3. Results

Pentobarbital concentration averaged 147 mg/L in serum samples, while it was not detected in the negative controls. In all FF samples pentobarbital was detected with an average concentration of 56.5 mg/L.

Research Abstract—for more information, contact the corresponding author

NOTES

4. Discussion

Based on the results, ovariectomy under general non-barbiturate anesthesia before euthanasia is the recommended practice to avoid the potential effects of pentobarbital on oocytes. A future study to evaluate the effect of the detected concentration of pentobarbital on oocyte developmental competence is warranted.

Acknowledgments

Declaration of Ethics

The Authors have adhered to the Principles of Veterinary Medical Ethics of the AVMA.

Conflict of Interest

The Authors have no conflicts of interest.

Footnote

[a]Euthasol®, Dechra Veterinary Products, Overland Park, KS 66211.

Deslorelin Acetate is Effective to Induce Ovulation During Early and Late Fall Despite Lower Endometrial Edema in the Latter

Kianna M. Spencer, DVM*; Giorgia Podico, DVM, MS; Ameer A. Megahed, MS, PhD; Kristi Jones, PhD; João H.J. Bittar, MS; and Igor Canisso, DVM, MSc, PhD, DACT, DECAR

Mares respond to deslorelin in the fall similarly to that previously reported for spring and summer. Despite lower endometrial edema scores in late fall, the lack of difference for other parameters, such as interval to ovulation and percent of successful inductions between early and late suggest response to GnRH-agonist this time of year. Authors' address: University of Illinois, Urbana-Champaign, 1008 West Hazelwood Drive, Urbana, IL 61802; e-mail: kiannas2@illinois.edu. *Corresponding and presenting author. © 2022 AAEP.

1. Introduction

Deslorelin is a popular GnRH-agonist to induce ovulation due to its efficacy of ~90% over spring and summer in older and young mares;[1] however, its fall efficacy is debated. Scoring endometrial edema can indicate a follicle's readiness to ovulate ≤48 h post GnRH;[2] however, anecdotally it is suggested that edema score decreases in the fall, rendering a poor GnRH-response. This study aimed to assess ovulatory response to deslorelin in the fall.

2. Material and Methods

Mares (n = 22) having a pre-ovulatory follicle received deslorelin[a] (1.8 mg/mare, IM). Ovulation was confirmed by ultrasonography performed 24, 36 h post induction and repeated at 2 h-intervals. Progesterone concentrations were determined with chemiluminescence.[b] Dinoprost[c] (7.5 mg/mare, IM) was administered 8 d post-ovulation. Cycles were repeated ≤5 times and grouped as early (n = 55) and late fall (n = 45). Parametric data was analyzed with mixed models, ANOVA, Tukey's test, and Pearson's correlation and non-parametric data with Kruskal-Wallis, Fisher's, and Dunn's tests.[d]

3. Results and Discussion

Deslorelin effectively induced ovulation in 90% of cycles, with similar intervals from induction to ovulation in early (40.6 ± 0.4 h) and late (41.2 ± 0.5 h) fall (P = 0.55)

Research Abstract—for more information, contact the corresponding author

NOTES

and to those reported for spring.[1] Spontaneous (<24 h-post deslorelin), failure (>48 h-post deslorelin), and multiple ovulations were similar between early and late fall ($P > 0.05$). The percentage of ovulations occurring during typical intervals used for timed-breeding (36-48 h: 91 *vs* 95%; 38-44 h: 60 *vs* 61%) were similar between early and late fall, respectively ($P > 0.05$). Follicle size at induction tended to be smaller in early (36.4 ± 0.4 mm) than late (37.4 ± 0.4 mm) fall ($P = 0.07$). Edema scores varied with time relative to ovulation ($P < 0.001$) and were lower in late fall ($P = 0.01$). Progesterone concentrations varied with time from induction ($P < 0.001$) but not between early and late fall when comparing specific time points from induction ($P = 0.73$).

Acknowledgments

Funding Sources

This study was supported by the Department of Veterinary Clinical Medicine, University of Illinois, Urbana-Champaign.

Declaration of Ethics

The Authors have adhered to the Principles of Veterinary Medical Ethics of the AVMA.

Conflict of Interest

The Authors have no conflicts of interest.

References and Footnotes

1. Ferris RA, Hatzel JN, Lindholm ARG, et al. Efficacy of deslorelin acetate (SucroMate) on induction of ovulation in American Quarter Horse mares. *J Equine Vet Sci* 2012;32: 285–288.
2. Samper JC. Ultrasonographic appearance and the pattern of uterine edema to time ovulation in mares. *Reproduction* 1997;43:189–191.

[a]SucroMate™, Thorn BioScience, LLC, Louisville, KY 40204.
[b]Chemiluminescence Immulite 2000 XPi Platform, Siemens Medical Solutions, Inc, Malvern, PA 19355.
[c]Lutalyse®, Zoetis Inc., Parsipanny, NJ 07054.
[d]R Version 1.4.1717, R Studio, PBC, Boston, MA 02210.

Follicular and Systemic Metabolic Alterations in Obese Mares Can Be Mitigated by Dietary Supplementation

Giovana D. Catandi, DVM*; Kyle Fresa; Ming-Hao Cheng, MS; Tom Chen, PhD; Adam J. Chicco, PhD; and Elaine M. Carnevale, MS, PhD, DVM

Dietary supplements can mitigate detrimental effects of obesity on systemic insulin dysregulation and ovarian cell function. Authors' addresses: Equine Reproduction Laboratory, College of Veterinary Medicine and Biomedical Sciences, Colorado State University, Fort Collins, CO 80521 (Catandi, Fresa, Chicco, Carnevale); Department of Electrical and Computer Engineering, Colorado State University, Fort Collins, CO 80523 (Cheng, Chen); e-mail: giovana.catandi@gmail.com. *Corresponding and presenting author. © 2022 AAEP.

1. Introduction

Obesity increases propensity for metabolic pathologies and reproductive failure. This study hypothesized that mare obesity causes mitochondrial dysfunction of ovarian follicle cells and optimal dietary nutrient intake can mitigate these effects and improve insulin regulation.

2. Materials and Methods

Light-horse mares were grouped: Normal Weight (NW, n = 6, 17.8 ± 1.8 yr, BCS [body condition score] 5.7 ± 0.3), Obese (OB, n = 7, 18.6 ± 1.5 yr, BCS 7.7 ± 0.2), and Obese Diet Supplemented (OBD, n = 7, 18.1 ± 1.3 yr, BCS 7.7 ± 0.2). Daily and for ≥6 wk before follicular sampling, NW were fed hay (grass/alfalfa) at ~2% body weight; OB and OBD were free-fed hay and 3 kg corn/oats, with OBD also receiving diet supplements (vitamins, trace minerals, amino acids, antioxidants, n-3 PUFA, probiotics[a], and metabolic support proprietary blend[b]). Cellular metabolism was assessed with microsensor (oocytes) or high-resolution respirometer (granulosa cells). Insulin dysregulation was determined by fasting insulin and an oral sugar test at 12 wk.

3. Results and Discussion

Oocyte oxygen consumption (aerobic metabolism) was higher ($p < 0.05$) for OB than NW, with OBD in between both. Measurements of impaired mitochondrial function in granulosa cells (reactive oxygen species production and outer membrane damage) were higher in OB than NW, but OBD was either not different than other groups or similar to NW. Basal fasting insulin was higher in OB than NW and OBD. More OB demonstrated insulin dysregulation after the oral sugar test than NW ($p < 0.05$) or OBD ($p < 0.1$). Dietary supplementation attenuated effects of obesity on cellular mitochondrial function and improved insulin regulation.

Research Abstract—for more information, contact the corresponding author

NOTES

Acknowledgments

Funding Sources

This study was funded in part by The Cecil and Irene Hylton Foundation and the Foundation for the Horse research grant. Advanced nutritional supplement formulas were provided by Platinum Performance, Inc., Buellton, CA.

Declaration of Ethics

The Authors have adhered to the Principles of Veterinary Medical Ethics of the AVMA.

Conflict of Interest

Some financial support was received by Platinum Performance for general research in our laboratory. However, they had no control over any research in our laboratory, no control over the study design or implementation of this research, and no input as to publication content.

Disclaimer

An aqueous solution of deslorelin acetate[c] was used for induction of follicular maturation to maintain consistency with previous research. Compounded products can vary significantly with respect to potency of the active ingredient(s).

Footnotes

[a]Equine GI (147g Daily), Platinum Performance®, Inc., Buellton, CA 93427.

[b]Metabolic support blend, Platinum Performance®, Inc., Buellton, CA 93427.

[c]Precision Pharmacy, Bakersfield, CA 93311.

Influence of Chronic Lameness on Thoracolumbar Musculus Multifidus Structure in the Horse

Hayley M. Sullivan, DVM, MS*; Elizabeth V. Acutt, BVSc; Myra F. Barrett, DVM, MS, DACVR, DACVR-EDI; Mo D. Salman, BVMS, MPVM, PhD, DACVPM; Katherine L. Ellis, DVM, MS, DACVSMR; and Melissa R. King, DVM, PhD, DACVSMR

Atrophy of the thoracolumbar musculus multifidus occurs bilaterally in chronic unilaterally forelimb lame horses, supporting that axial skeleton adaptation should be considered in these cases. Authors' address: Colorado State University, 300 West Drake Road, Fort Collins, CO 80523; e-mail: thegallopingvet@gmail.com. *Corresponding and presenting author. © 2022 AAEP.

1. Introduction

The musculus multifidus (m. multifidus) provides spinal intersegmental stabilization, and a functional relationship between equine postural stability and m. multifidus hypertrophy has been established. The relationship between equine m. multifidus cross-sectional area (CSA) and limb lameness, however, is unknown. The objective of this study was to evaluate ultrasonographic thoracolumbar m. multifidus CSA in horses with chronic single limb lameness, compared with sound horses.

2. Materials and Methods

Twelve horses were used in each group: sound, chronic single forelimb lameness, and chronic single hindlimb lameness. M. multifidus CSA was measured ultrasonographically at multiple spinal levels (T12, T14, T16, T18, L2, L5) bilaterally. Data were analyzed using mixed-model analysis of variance and covariate analysis with horse, level, horse size, and lameness side, grade, and duration as variables.

3. Results

M. multifidus CSA at T18 was significantly larger than other levels, regardless of group. CSA was significantly larger bilaterally in sound horses than forelimb lame horses across all levels. There was no difference in CSA symmetry between lame and non-lame sides, regardless of group.

4. Discussion

This study demonstrated a significant decrease in m. multifidus CSA in horses with a single forelimb lameness. These results impart an understanding of the

Research Abstract—for more information, contact the corresponding author

NOTES

long-term adaptation processes of the axial skeleton that can occur with chronic naturally occurring lameness and further justifies consideration of changes in spinal characteristics when rehabilitating limb injuries.

Acknowledgments

Funding Sources

The Authors thank the College Research Council of Colorado State University – College of Veterinary Medicine and Biomedical Sciences for funding this project.

Declaration of Ethics

The Authors have adhered to the Principles of Veterinary Medical Ethics of the AVMA.

Conflict of Interest

The Authors have no conflicts of interest.

Clinical Field Study to Evaluate Injectable Pentosan Polysulfate for the Control of Clinical Signs Associated with Osteoarthritis in Horses

Scott McClure, DVM, PhD, DACVS, DACVSMR*; and Kayla N. Peck, DVM

Pentosan polysulfate sodium administered at 3.0 mg/kg intramuscularly once a week for 4 weeks significantly decreased lameness in horses with naturally occurring osteoarthritis. There were no significant adverse events associated with the osteoarthritis treatment. Authors' address: Midwest Equine Surgery and Sports Medicine, 2615 Eastgate Drive, Boone, IA 50036; e-mail: srmeqdr@gmail.com. *Corresponding and presenting author. © 2022 AAEP.

1. Introduction

Pentosan polysulfate sodium (PPS) is a semisynthetic polysulfated xylan used for the relief of various medical conditions including osteoarthritis (OA) in horses.[1,2] In the osteochondral fragment model, intramuscular administration of PPS for the treatment of experimentally induced OA in horses indicated that 4 weekly injections at a dose of 3.0 mg/kg may be a therapeutic option for OA in horses.[2] A pilot study that was a preliminary investigation for this study was done.[a] In 39 horses with OA of metacarpophalangeal/metatarsophalangeal joints, PPS reduced the clinical signs of lameness and increased range of motion and stride length. In a survey on the use of PPS in Australia, the respondents reported they used PPS for prophylaxis and treatment of OA despite the limited evidence available.[3]

PPS may provide a disease-modifying effect in the management of OA. In vitro PPS resulted in a concentration-related stimulated proteoglycan synthesis in chondrocyte monolayers.[4] In vitro evaluation of PPS shows there is a dose-related inhibition of stromelysin.[5] While there is direct inhibition of degradation effects, there are also direct anabolic effects.[6,7] Chondrocyte uptake of PPS can stimulate production of matrix proteins and also has anti-inflammatory and fibrinolytic effects.[7] In a rat model, PPS may preserve proteoglycan within cartilage matrix.[8] Studies have confirmed that intramuscular dosing of PPS in the horse can achieve concentrations of PPS in the synovial fluid that can result in an effect on synoviocyte metabolism, stimulate proteoglycan synthesis, and reduce metalloproteinase activity.[9] In the osteochondral fragment model, PPS was shown to reduce cartilage fibrillation and increase chondroitin sulfate (CS 846) epitope concentrations in the synovial fluid of treated horses compared with saline-treated controls.[2]

NOTES

PPS is approved for use in Australia[b] and is currently being provided by compounding pharmacies in the United States for veterinary use. The objective of this study was to generate pivotal data to evaluate the field safety and effectiveness of PPS[c] when injected intramuscularly once weekly for 4 weeks in horses with naturally occurring osteoarthritis as part of a Food and Drug Administration approval process.

2. Methods

The study was a multicentered study conducted at 12 veterinary practices in the United States. Each evaluable site contributed at least 2 evaluable cases per treatment group. This study was approved by the required Institutional Animal Care and Use Committee committees. Within 5 days prior to study day (SD) 0, the investigator reviewed the study requirements and inclusion/exclusion criteria (Table 1) with the owner and obtained informed consent. Horses were maintained by their owners on their current diets and housing. Owners were given a daily diary to maintain during the study period and comment on whether appetite and drinking habits were considered normal or abnormal.

Radiographs of the affected joint were obtained pretreatment for the purpose of inclusion and on SD 28 to verify there were no unexpected changes. The horse's weight was measured at enrollment by weight tape using the heart girth circumference and body length to calculate the weight.[10] The investigational product (IVP) was PPS formulated as a 25% (250 mg/mL) injectable sterile solution.[c] Once-weekly injections of 3.0 mg/kg PPS on SD 0, 7 (± 2 days), 14 (± 2 days), and 21 (± 2 days) were administered. A 0.9% saline solution was used as a control product (CP), with a volume calculated to be equal to the IVP volume. The IVP/CP was administered by intramuscular

Table 1. Enrollment Inclusion and Exclusion Criteria and Postenrollment Exclusion Criteria

Animal Inclusion
Minimum age: 2 years.
Owner/agent had signed the informed consent form.
Corresponding radiographed index limb exhibited lameness score between 2 and 4 (≥ 2 and ≤ 4) according to the AAEP Lameness Scale.
Presnce of OA in one limb, as confirmed by radiographs performed prior to enrollment (Day −5 to Day 0).
Good general health with the exception of OA.
Owner/caretaker demonstrated a clear understanding of his/her requirements for study participation and agreed to comply with study instructions, restrictions, and visits.
Animal Exclusion
Less than 2 years of age.
Total lameness score of less than 2 or greater than 4.
Presence of lameness in more than one limb.
Conditions in the index limb other than OA that could have contributed to the lameness.
Treatment with NSAIDs in the 14 days prior to Day 0.
Treatment (IA) with corticosteroids within previous 90 days prior to Day 0.
Treatment with systemically administered corticosteroids within previous 14 days prior to Day 0.
Treatment (IM, IV, or IA) with other pain or lameness-modulating treatments such as hyaluronic acid, polysulfated glycosaminoglycans, etc. within previous 30 days prior to Day 0.
Treatments such as bisphosphonates, regenerative medicine (IRAP, PRP, stem cells), and shockwave within previous 6 months prior to Day 0.
Use of nonmedicinal treatments such as acupuncture, chiropractic, shockwave, laser therapy, etc., were not allowed during the study period.
Joint supplements were acceptable if they were administered for at least 30 days (prior to Day 0) and provided there was no dosage change.
Horses were not placed on additional supplements once the study was initiated.
Pregnant or lactating mares.
Underwent major surgery within the previous 30 days prior to Day 0.
Autoimmune diseases.
Prior bleeding issues (including exercise induced pulmonary hemorrhage).
Horses where expected trauma or possible bleeding could occur.
Horses with neurological abnormalities, e.g., EPM, NAD, or EDM.
Horses that were on or that were enrolled in another clinical field study within the previous month prior to Day 0.
Horses belonging to employees of the study site.
Horses with any clinically relevant systemic health problems and/or clinically relevant abnormalities found in the clinical pathology testing.
Postinclusion Removals
Horses with adverse events that required treatment with NSAIDs, corticosteroids, or other lameness-modulating compounds.
Horses with serious adverse events may have been removed from the study.
Owner withdrew consent.
Horses with clinically relevant abnormalities on bloodwork determined after enrollment.

Abbreviations: OA, osteoarthritis; NSAID, nonsteroidal anti-inflammatory drug; IA, intra-articular; IM, intramuscular; IV, intravenous.

injection in the neck with the gauge of needle of the clinician's preference. The subsequent injections were given on the opposite side of the neck from the previous injection site and at least 3 inches from the previous injection when on the same side. This protocol was used to enable the assessment of injection sites. The treatment dispenser had access to previous visits to determine location. Any concomitant treatment during the study period was documented in the study records.

Physical Examinations

The investigator performed a physical examination and then a lameness score based on the AAEP Lameness Scale[11] pretreatment on SD 0, SD 7 (± 2 days), SD 14 (± 2 days), SD 21 (± 2 days), SD 28 (± 2 days), and any unplanned visits. Injection site observations were performed by the investigator pretreatment on SD 0, SD 7 (± 2 days), SD 14 (± 2 days), and SD 21 (± 2 days) to confirm the site was normal prior to injection (full neck assessed). Approximately 3 hours postinjection (± 15 minutes), the investigator observed the injection sites. Following treatment, the owner was asked to record an injection site observation in the days between visits. On SD 28, the investigator made a full assessment of the neck to confirm that all injection site observations had resolved. Injection site observations were obtained at unplanned visits if deemed appropriate by the investigator. In addition to injection site observations, owners were asked to maintain a daily diary record on the general, appetite, and drinking habits and if the horse was considered normal/abnormal for the period of time between each visit. Owners were instructed to report any potential adverse events (AEs) to the investigator. A follow-up phone call to the owner took place on SD 38 (± 2 days).

Clinicopathology

Blood and serum samples were collected for clinical pathology (complete blood count and serum chemistry with fibrinogen) on SD 0 (pretreatment), SD 14 (pretreatment), SD 28, and any unplanned visits if indicated in response to an AE. Blood and serum samples were collected for prothrombin time (PT) and activated partial thromboplastin time (aPTT) analyses pretreatment and then 3 hours post-treatment (± 15 minutes) on SD 0, SD 14 (± 2 days), and SD 21 (± 2 days). All clinicopathologic analyses were performed at a single reference laboratory.[d]

Outcome Assessment

At enrollment, the investigator identified a single limb with lameness due to OA with radiographic evidence to support the diagnosis. This limb was then followed in each subsequent lameness evaluations and used in the assessment of treatment effect. The endpoint for efficacy was the improvement in lameness score at SD 28. SD 28 lameness scores were compared to SD 0 lameness scores. Animals with an improvement of at least 1 category in the SD 28 lameness score as compared to the SD 0 lameness score were considered a treatment "success"; otherwise, the animal would be classified as a "failure." Should an animal have been withdrawn from the study for perceived inefficacy or failure to improve, or at any time for treatment-related reasons, they would have been classified as a failure. The success rate of the IVP treated group was then compared to the negative control group to determine overall treatment effect. Any horses removed from the study for treatment-related reasons were considered treatment failures. Horses that did not complete all study visits due to treatment-related reasons are included in the effectiveness analysis as treatment failures. In addition, horses that completed all or any of the interim visits but did not complete the follow-up (Day 38 ± 2) phone call visits were included in the effectiveness analysis and deemed as a success or failure based on the last evaluation.

Adverse Events

For this study, an AE was defined as any unfavorable and unintended observation in a horse that occurred any time following administration of the IVP or CP, whether or not it was considered product related. Any AE that occurred during the study was reported to the investigator, who recorded the AE and any associated concomitant medication administered.

Data Analysis

The study was a negatively controlled, randomized, blinded field efficacy study. The investigator doing the physical examinations and lameness examinations and the owner/agent were blinded. The treatment administrator could not be blinded because of differences in color and packaging of the control and treatment materials. Treatment administration data and materials were securely maintained by the treatment dministrator. Each animal was randomized in presentation order using randomization generated by the SAS statistical package also used for analysis.[e] Each study site utilized a separate randomization. Animals were blocked in groups of 4 in a 2:2 IVP to CP ratio. Masking was achieved by separation of function and access to treatment records. The individual horse was evaluated as the experimental unit. Descriptive statistics (number of observations, mean, standard deviation, minimum, and maximum (or number of observations, median, and frequency counts for binomial data) were generated for all variables at all visits. All hypotheses were tested at a two-sided 0.05 level of significance. Effectiveness was determined by the results obtained on Day 28. Animals having major protocol deviations were not included in the effectiveness evaluation. The lameness scores from Day 28 were compared to the lameness scores at Day 0, and an animal was classified as a success if there was an improvement of at least one category in the Day 28 lameness scores; otherwise, the animal was classified as a failure. Animals withdrawn from the study for perceived inefficacy or failure to improve, or at any time for treatment-related reasons, were classified as

a failure. The results from all evaluable cases were analyzed using SAS PROC GLIMMIX with "treatment" and "site" as classification variables and included the interaction "treatment by site." Treatment was included in the model as a fixed effect, and site and treatment by site were included as random effects. A logit link function was employed in the model since the variable was binary in nature. Hematology and serum chemistry variables were statistically evaluated using a repeated-measures analysis of covariance using SAS PROC MIXED with the pretreatment (Day 0) value used as a covariate. The model included terms for the effects "treatment," "day," and "treatment by day" interaction as fixed effects, as well as "animal within treatment and site," "site," and "treatment by site" interaction as random effects. Statistical analysis was performed on a per-protocol (PP) population set (comparison of treatment groups that includes only those cases that completed the treatment originally allocated without major deviation). This population takes into consideration all protocol deviations that would be considered to impact the results and conclusions drawn from this case data. Statistical analysis was also performed on an intent-to-treat (ITT) population set. This population reports the efficacy for all cases on the study regardless of any protocol deviations. This population set is included as it gives an indication of the true field situation and how the product would perform once it comes to market. The ITT population will be used for safety summary and analyses. Body systems were evaluated using categorical observations (normal/abnormal). Injection site and physical examination data were evaluated with descriptive statistics. No hypothesis testing was conducted on these variables.

3. Results

Enrollment included 237 horses of multiple breeds including Appaloosa, Arabian, Belgian, Crossbred, Dutch Warmblood, Friesian, Grade, Hanoverian, Miniature Horse, Morgan, Oldenburg, Other, Paint Horse, Percheron, Quarter Horse, Saddlebred, Standardbred, Tennessee Walking Horse, and Thoroughbred from 3 to 32 years of age. There were 82 females, 151 castrated males, and 4 intact males ranging from 153 to 904 kg.

Outcome Assessment

A total of 237 horses were randomized to either the CP ($n = 117$) or IVP ($n = 120$), the ITT population. Of these, 113 CP and 106 IVP horses were included in the PP population. Horses excluded from the PP population included cases with major protocol deviations (16) and sites that enrolled less than 2 cases in one of the treatment groups (2). No horses were eliminated for severe adverse events. Table 2 provides a summary of the assessment of treatment success based on the primary outcome variable. Treatment success rate in the PP population was significantly higher in the IVP group (58.92%) as compared to the CP group (36.29%) on Day 28. Similarly, for the ITT population, treatment success rate was significantly higher in the IVP group (59.19%) as compared to the CP group (36.98%) on Day 28. The distribution of joints treated for the IVP and CP are presented in Table 3.

The treatment by day interaction was statistically significant for conjugated bilirubin, unconjugated bilirubin, total bilirubin, globulin, total protein, neutrophils, and white blood cells (WBC) (Table 4). No within-day treatment effects were detected for conjugated bilirubin, unconjugated bilirubin, or total bilirubin. Globulin, protein, neutrophil, and WBC values on SD 28 were significantly lower in the PPS treated group as compared to the saline control ($p < 0.05$). In addition to the significant interactions between treatment and day described above, the main effect of treatment was significant for blood urea nitrogen (BUN) and mean corpuscular hemoglobin (MCH; $p = 0.0220$ and $p = 0.0229$, respectively). Descriptive statistics were performed on the PT and aPTT. It was noted that the predosing PTT means were marginally and consistently lower than the reference range before treatment was given for both treatment groups and at all time points. Post-treatment mean values in the saline control group were comparable to baseline mean values, but the PPS had increased; however, they were still within the acceptable reference range.

Descriptive statistics of categorical observations of body systems, heart rate, respiration rate, and temperature resulted in no difference noted between the treatment groups. A small percentage of PPS treated horses exhibited an injection site reaction approximately 3 hours post-treatment (maximum number on any given study day: edema/swelling 11 [9.17%], heat 1 [0.87%], pain 4 [3.33%], and redness 1 [0.87%]). As with the investigator's assessment of injection sites, the animals' owners reported that a small percentage of individual horses exhibited an abnormal injection site reaction; the PPS-treated group had 13.33% of cases compared to the saline treated group, which was 2.56%. The minimum duration (days) of observation was that a reaction was observed the same day but had resolved by the next day (i.e., reaction lasting only a matter of hours), and the maximum duration was 5 days, reported for PPS-treated horses.

Adverse Events

No serious adverse events were reported during the study period. The majority of nonserious AEs reported were considered to be transient and did not require treatment, with the vast majority of AEs being typical of the population under treatment.

4. Discussion

The objective of this study was to generate pivotal data to evaluate the field safety and effectiveness of PPS when injected intramuscularly once weekly for 4 weeks. The study demonstrated a significantly higher success rate in the PPS-treated group (58.92%) compared to the saline group (36.29%) on SD 28 ($p = 0.0419$). The administration of PPS was well

Table 2. The Percent Success and the 95% Confidence Interval Represent Back-Transformed Values from the Logit Transformation

Population	Treatment	*N*	Percent Success[a]	95% Confidence Interval	*P* Value
Per Protocol	CP	113	36.29	23.34–51.59	0.0419
	IVP	106	58.92	43.52–72.74	
Intent to Treat	CP	115	36.98	24.24–51.84	0.0396
	IVP	110	59.19	44.31–72.56	

Abbreviations: CP, control product; IVP, investigational product. The intent to treat population includes all horse treated and completing the study through Day 28.

Table 3. The Intent to Treat Horses Grouped by the Joints Identified with Osteoarthritis Included in the Study

	IVP				CP			
Joint	Lameness Score	Success	Failure	Total	Lameness Score	Success	Failure	Total
Distal Interphalangeal	2.28	5 (71%)	2 (29%)	7	2.56	2 (22%)	7 (78%)	9
Proximal Interphalangeal	2.44	3 (33%)	6 (67%)	9	2.65	2 (22%)	7 (78%)	9
Metacarpal or Metatarsal Phalangeal	2.44	10 (50%)	10 (50%)	20	2.42	5 (26%)	14 (74%)	19
Carpus	2.95	14 (61%)	9 (39%)	23	2.46	10 (50%)	10 (50%)	20
Tarsus	2.38	30 (64%)	17 (36%)	47	2.27	19 (39%)	30 (61%)	49
Stifle	2.67	3 (100%)	0	3	3	2 (25%)	6 (75%)	8
Joint Not Included in Protocol			1	1		1		1
Total	2.53	65 (59%)	45 (41%)	110	2.56	41 (36%)	74 (64%)	115

Abbreviations: CP, control product; IVP, investigational product. The mean lameness score on Day 0 is in the first column for the IVP and CP groups. The number (percentage) for the IVP and CP is shown as success or failure per trial protocol.

tolerated with no serious AEs reported. Injection site reactions were observed in relatively few animals, and the maximum duration was 5 days. The treatment by day interaction was statistically significant, but no within-day treatment differences were detected for unconjugated bilirubin, conjugated bilirubin, and total bilirubin. Comparison between the treatment groups within day showed no statistically significant difference for each analyte for each study day; therefore, these findings were considered spurious changes in the horses over time. The treatment by day interaction was statistically significant for globulin, total protein, neutrophils, and WBC. The means were significantly lower in the PPS-treated group compared to the saline group. It should be noted that there were 4 cases that reported an AE of systemic infection including increases in these variables (3 PPS, 1 saline case). There is not a singular explanation why PPS-treated horses would have less systemic inflammation. A potential effect of decreased joint inflammation leading to lower systemic indicators of inflammation is possible. The treatment by day effect was significant for BUN and MCH. The means for both the BUN and MCH values were significantly higher in the PPS-treated group compared to the saline group. One AE was recorded for elevated BUN for a PPS-treated case; otherwise, there were no consistent abnormalities of BUN noted.

PPS has thrombolytic properties via mechanisms similar to heparin, acting on the intrinsic coagulation pathway.[12] Heparin utilizes antithrombin III to catalyze thrombin-heparin cofactor II, and PPS independently catalyzes this cofactor without the use of antithrombin III. Lipids and thrombi have been reported to be present in the microvasculature of subchondral bone in joints with osteoarthritis, causing osteonecrosis and pain.[13] Even though the anticoagulant effects of PPS are significantly lower than heparin and it is cleared from plasma concentrations relatively quickly, it has been reported to improve blood flow in subchondral bone and reduce joint inflammation in animal model studies.[12,13] In this study, at a dose of 3.0 mg/kg given systemically, PPS did not cause any adverse events such as hemorrhage or pain at injection site, thrombocytopenia, etc.

PT/aPTT and fibrinogen levels are used to evaluate potential complications associated with anticoagulant products such as PPS. Pre- and postdosing mean values for PT levels were within reference range. Predosing mean values for aPTT were marginally and consistently lower than the reference ranges in both the PPS and saline groups. Different reagents and assay configurations influence sensitivity, and this may explain why all predosing values were lower than the reference range. Post-treatment mean values were increased for the PPS-treated group but were still within the reference range. There were 5 AEs reported for an increase of aPTT (all PPS-treated horses) and 1 AE reported to document prolonged aPTT (PPS-treated horse). These were considered AEs based on the clinicopathologic data, not clinical symptoms.

There were no reported serious AEs in the study, and most AEs were considered transient and did not require treatment. The AEs reported by owners during the

Table 4. The Variables Identified That May Have a Treatment or Treatment by Day Interaction are Included

Variable	Treatment p value	Group, LS Mean, SEM	Treatment × Day Interaction p value	Day 28 Group, LS Mean, SEM
MCH (pg)	0.0229*	CP, 16.92, 0.02 IVP, 17.02, 0.02*	0.9746	
BUN (mg/dL)	0.0220*	CP, 17.28, 0 IVP, 17.93, 0.23*	0.6776	
Neutrophil (/uL)	0.0486*		0.0160*	CP, 4939.87, 126.48 IVP, 4379.55, 128.12*
WBC k/uL	0.0129*		0.0112*	CP, 8.33, 0.16 IVP, 7.58, 0.17*
Bilirubin Conjugated	0.8084		0.0336*	CP, 0.29, 0.01 IVP, 0.28, 0.01 NS
Bilirubin Unconjugated	0.9623		0.0020*	CP, 0.86, 0.03 IVP, 0.81, 0.03 NS
Total Bilirubin	0.9917		0.0015*	CP, 1.15, 0.04 IVP, 1.09, 0.04 NS
Total Protein	0.1283		0.0068*	CP 6.34, 0.05 IVP 6.21, 0.05*
Globulin	0.2349		0.0043*	CP, 3.17, 0.03 IVP, 3.07, 0.03*

Abbreviations: NS, not significantly different ($p > 0.05$); MCH, mean corpuscular hemoglobin; BUN, blood urea nitrogen; WBC, white blood cells. *Significantly different at $p < 0.05$. Data are presented by group (investigational product [IVP] or control product [CP]) with the least squares (LS) mean and standard error of the mean (SEM). Where the treatment by day interaction was significant, within-day treatment effects were assessed. Otherwise, the treatment p value was assessed and differences between groups evaluated without regard to day.

study were typical of the study population and client-reported events (changes in appetite, activity, lameness, and behavior, among others). However, there were marginally more AEs per subject noted in the PPS-treated group compared to the saline-treated group. However, many AEs recorded in the PPS group had the relationship to treatment recorded as "unlikely."

In this study, 58.92% of the horses treated with PPS improved at least one grade of lameness. When PPS was evaluated in the osteochondral fragment model, there was not a significant difference in lameness between control horses and horses treated with PPS.[2] There were, however, indications of disease-modifying effects including decreased cartilage fibrillation. While the methodology of these two studies is quite different, the findings of both studies are very relevant. In this study, enrollment criteria required radiographic evidence of OA. While this helps create a more homogenous study group, it does select for more advanced cases where subtle disease-modifying effects may not be evident. The improvement of almost 60% of the cases enrolled in this study is notable because of the more advanced nature of cases being enrolled. Ultimate clinical use may be more effective earlier in the disease process. Where PPS is approved for use, a survey of veterinarians indicated PPS had a higher efficacy as a prophylactic drug than for treatment OA.[3] Similarly, respondents perceived PPS had moderate treatment efficacy. This would suggest that the methodology of this study found a significant outcome in a challenging model of treating advanced OA with radiographic evidence of degeneration.

5. Conclusion

Pentosan polysulfate sodium administered at 3.0 mg/kg intramuscularly once a week for 4 weeks is a safe and effective therapy for osteoarthritis in horses.

Acknowledgments

Funding Source

Anzac Animal Health LLC, 218 Millwell Drive, Suite B, Maryland Heights, MO 63043.

Declaration of Ethics

All applicable Institutional Animal Care and Use Protocols were obtained. The horse owners gave informed consent for inclusion of their horses in the study. The Authors have adhered to the Principles of Veterinary Medical Ethics of the AVMA.

Conflict of Interest

The primary Author was paid for inclusion of cases, as were all investigators contributing cases to the study. There are no conflicts of interest.

References and Footnotes

1. Goodrich LR, Nixon AJ. Medical treatment of osteoarthritis in the horse – A review. *Vet J* 2006;171:51–69.
2. McIlwraith CW, Frisbie DD, Kawcak CE. Evaluation of intramuscularly administered sodium pentosan polysulfate for treatment of experimentally induced osteoarthritis in horses. *Am J Vet Res* 2012;73:628–633.
3. Kramer CM, Tsang AS, Koenig T, et al. Survey of the therapeutic approach and efficacy of pentosan polysulfate for the

prevention and treatment of equine osteoarthritis in veterinary practice in Australia. *Aust Vet J* 2014;92:482–487.
4. Frean SP, Cambridge H, Lees P. Effects of anti-arthritic drugs on proteoglycan synthesis by equine cartilage. *J Vet Pharmacol Ther* 2002;25:289–298.
5. Nethery A, Giles I, Jenkins K, et al. The chondroprotective drugs, Arteparon and sodium pentosan polysulphate, increase collagenase activity and inhibit stromelysin activity in vitro. *Biochem Pharmacol* 1992;44:1549–1553.
6. Ghosh P, Hutadilok N. Interactions of pentosan polysulfate with cartilage matrix proteins and synovial fibroblasts derived from patients with osteoarthritis. *Osteoarth Cartil* 1996;4:43–53.
7. Ghosh P. The pathology of osteoarthritis and the rationale for the use of pentosan polysulfate for its treatment. *Semin Arthritis Rheum* 1999;28:211–265.
8. Francis DJ, Forrest MJ, Brooks PM, et al. Retardation of articular cartilage degradation by glycosaminoglycan polysulfate, pentosan polysulfate, and DH-40J in the rat air pouch model. *Arthritis Rheum* 1989;32:608–616.
9. Fuller CJ, Ghosh P, Barr AR. Plasma and synovial fluid concentrations of calcium pentosan polysulphate achieved in the horse following intramuscular injection. *Equine Vet J* 2002;34:61–64.
10. Carroll CL, Huntington PJ. Body condition scoring and weight estimation of horses. *Equine Vet J* 1988;20:41–45.
11. Ross MW. Movement. In: Ross MW, Dyson SJ, eds. *Diagnosis and management of lameness in the horse 4th ed*. Philadelphia: Saunders, 2011;64–80.
12. Dart AJ, Perkins N, Dowling BA, et al. The effect of three different doses of sodium pentosane polysulphate on haematological and haemostatic variables in adult horses. *Australian Vet J* 2001;79:624–627.
13. Ghosh P, Edelman J, March L, et al. Effects of pentosan polysulfate in osteoarthritis of the knee: A randomized, double-blind, placebo-controlled pilot study. *Curr Ther Res* 2005;66:552–571.

[a]Anzac Animal Health, unpublished data.
[b]Cartrophen® Equine Forte, Biopharm, Australia.
[c]Zycosan® Anzac Animal Health, Maryland Heights, MO 63403.
[d]IDEXX BioResearch, Sacramento, CA 95605.
[e]SAS/STAT® Software, SAS Institute Inc., Cary, NC; Version 9.4.

Managing Proximal Suspensory Desmopathy in Horses: A Review

Erin Contino, MS, DVM, DACVSMR

Although managing proximal suspensory desmopathy in horses can be challenging, there are a wide variety of treatment options available. Author's address: Colorado State University, 300 West Drake Road, Fort Collins, CO 80523; e-mail: erin.contino@colostate.edu. © 2022 AAEP.

1. Introduction

Proximal suspensory desmopathy (PSD) is one of the most common causes of lameness and decreased performance in athletic horses. The disease is commonly referred to as proximal suspensory desmitis or desmopathy, both of which indicate injury to the ligament. However, the disease process is much more complex and typically involves pathologic change to not only the ligament but also the bony origin, connective palmar/plantar fascia, and/or the nerve that innervates the region, the deep branch of the lateral plantar nerve. For the purposes of this discussion, PSD will refer to the pathologic changes that involve the ligament as well as the surrounding tissues. This paper aims to discuss various options available to treat PSD and will review the scientific literature for these treatment options when available.

Treating PSD can be broken down in a variety of ways. One is to categorize treatments by purpose, such as treatments aimed to mitigate pain versus treatments designed to aid in tissue healing. Another way would be to group treatments by the tissue type it is targeting, such as treatments targeting the ligament versus the bone versus the nerve. Ultimately, it is most important to identify which tissues are involved and design an individualized treatment plan accordingly.

2. Methods to Manage PSD

Pain Management

There has been a somewhat recent movement to change the terminology from proximal suspensory *desmitis* to *desmopathy* in order to remove inflammation from the description of the disease. While it is true that the disease process is degenerative and often not primarily inflammatory in nature (at least not in the chronic phase when most horses present), it should not be misconstrued as not being a painful condition. Despite the lack of pronounced inflammatory cells present in histopathology, anti-inflammatories are an important part of treating PSD clinically as they can decrease lameness. In acute cases, the author tends to treat with phenylbutazone (2.2 mg/kg for 3 to 5 days) prior to switching to firocoxib for longer-term administration (57 mg q 24 PO), often until significant improvement or resolution of clinical signs. Additionally, topical nonsteroidal anti-inflammatory

NOTES

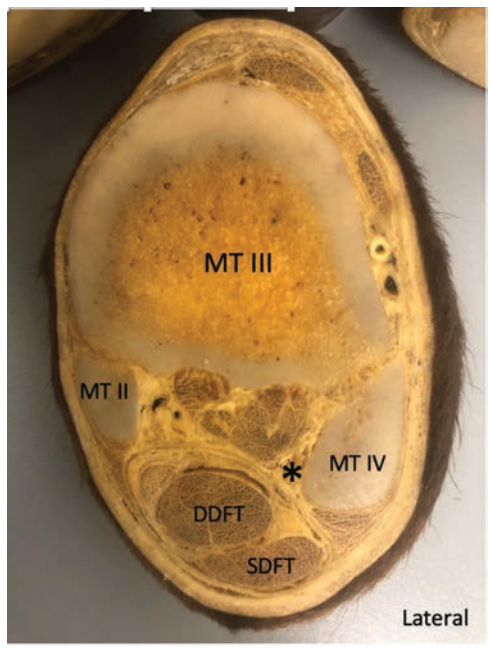

Fig. 1. A cross-section of the proximal metatarsal region; lateral is to the right. Note the plantar extension of the fourth metatarsal bone (MT IV); this anatomic construction precludes access to the suspensory ligament with ultrasound or shockwave from a lateral approach. The asterisk marks the location of the deep branch of the lateral plantar nerve. SDFT, superficial digital flexor tendon; DDFT, deep digital flexor tendon.

drugs (NSAIDs; 1% diclofenac cream) can be applied over the affected area, although it is questionable if the product can penetrate far enough to reach the suspensory ligament that lies several centimeters deep to the palmar/plantar skin surface. Although it has not been studied for PSD, 1% diclofenac cream,[a] applied twice daily over the affected joint, was shown to decrease lameness in horses with experimentally induced carpal joint osteoarthritis.[1]

Cryotherapy is a useful pain management tool but is logistically difficult unless one has access to a soaking boot as the majority of muck tubs and/or 5-gallon utility buckets are not tall enough to reach the proximal aspect of the suspensory ligament, especially in a hindlimb. Submerging the limb in ice water is an effective way to cool deeper tissues,[2] and there are commercially available soaking boots that are useful for this purpose. Commercially available pressurized cold therapy boots[b] have also been shown to effectively cool deeper tissues and are a good choice for "icing" the proximal suspensory region. In the acute phase, icing for 20 to 25 minutes twice daily is helpful in reducing pain. This should be implemented for at least the first 48 to 72 hours, and if the client is able, it can be continued for 10 to 14 days. Additionally, in the chronic phase and/or during rehabilitation, cryotherapy can help mitigate pain following exercise, in which case cryotherapy can be reduced to a single 20- to 25-minute session following exercise or following more rigorous exercise.

Extracorporeal Shockwave Therapy

In the author's practice, extracorporeal shockwave therapy (ESWT) is a cornerstone of treating PSD. Treatment (performed with an electrohydraulic-focused ESWT unit) typically consists of 800 to 1000 pulses with a 20-mm or 35-mm trode on energy E6 (0.15 mJ/mm^2) performed every 7 to 14 days for a total of 3 treatments. Forelimb pulses are applied from a palmaromedial, palmar, and palmarolateral direction, but in the hindlimb, it is recommended to administer the pulses from a plantar and plantaromedial direction. This is due to the fact that the size and placement of the fourth metatarsal bone precludes shockwaves from reaching the proximal suspensory ligament from a lateral approach (Fig. 1). Considering shockwave exerts the most effect at tissue interfaces, cases where there is pathologic change at the bone-ligament interface may be particularly good candidates for this treatment.

The first report of ESWT was in 2000 in a study of 30 horses with chronic (> 3 months) PSD. Horses were treated with 2000 pneumatic generated radial shockwaves at 0.16 mJ/mm^2 energy every 2 to 4 weeks for 3 treatments.[3] Immediately following the first treatment, 11 of the 30 horses were sound, and immediately following the third treatment, 24 (80%) were sound. However, at the 6-month follow-up, only 16 horses remained sound, and 18 (60%) had resumed full work. Crowe et al. also investigated the use of radial shockwave (2000 impulses; 3 treatments spaced 2 weeks apart) in sport horses with chronic PSD and reported that 53% of 20 forelimb cases and 41% of 43 hindlimb cases were in full work at the 6-month follow-up.[4] Lischer et al. provided longer follow-up in horses that were treated with a series of 3 focused ESWT treatments at 3-week intervals (2000 electrohydraulic shockwave pulses, 35-mm probe, energy 0.15 mJ/mm^2).[5] Of 34 forelimb cases, 21 (62%) had returned to full work at 6 months, but only 56% were in full work at 1 year. In hindlimb cases, 41% of 22 horses were in full work at 6 months compared to only 18% that were in full work at 1 year. Collectively, these studies demonstrate that ESWT appears to have better short-term versus long-term success.

Unfortunately, none of the studies cited above were case controlled, which highlights the importance of the Löffeld et al. study that compared horses that underwent radial pressure wave therapy to horses that were treated conservatively with rest and local infiltration of corticosteroids.[6] Of 31 horses that underwent ESWT, 22 (71%) resumed full work at 6 months compared to only 50% of 30 horses that were managed conservatively.

Finally, a recent study in Western Performance horses ($n = 96$) compared treatment with ESWT to treatment with platelet-rich plasma (PRP). [7] Horses were treated with either 800 ESWT pulses (focused electrohydraulic unit, 20-mm probe, E6: 0.15 mJ/mm^2) or with injection of 3 to 6 mL of leukocyte-poor PRP into and around the suspensory ligament origin.

At initial follow-up on day 4, horses in the ESWT group showed a mean improvement in lameness of 47% compared to a mean improvement of 33% in the PRP group. At 6 months, there were no differences in work level between the two groups, and at 1 year, 75% (18 of 24) of PRP-treated horses and 82% of (28 of 34) ESWT-treated horses were in full work. In this study, there was a trend for horses with more mild ultrasound changes to respond better to ESWT and horses with more severe ultrasound changes to respond better to PRP. In both treatment groups, the results at 1 year are superior to the majority of other studies and may indicate that Western Performance horses have a better prognosis compared to other disciplines, such as English sport horses.

Biologics

There are multiple formulations and types of biologic products available for use in soft tissue injuries, including PSD. Biologic products provide a varying array of growth factors and therefore may improve the quality of tissue repair. At the author's institution, the most common biologic products used to treat PSD are PRP or bone-marrow-derived mesenchymal stem cells (MSCs). Finances often dictate the selection as PRP is approximately one tenth the cost of MSCs. The primary indication for biologics is cases that have damage to the ligament, particularly if there is a defined area of fiber loss or disruption that allows for direct injection of a biologic product. In many cases, a series of ESWT will be started, and if the results are unsatisfactory by the third treatment, an ultrasound-guided injection of PRP can be performed. It may be useful to apply the third shockwave immediately following the PRP injection as ESWT can increase the release of growth factors from platelets.[8]

Stem cells have a distinct advantage over other biologics in the diversity of administration. In cases where there is enough ligament fiber disruption to allow for direct injection, this would be the obvious choice. But in many cases of PSD, there is no distinct core lesion in which to inject biologics; in such cases, regional IV perfusion or intra-arterial injection with MSCs is an excellent choice. In many cases MSCs are delivered via multiple routes and/or repeated (typically once monthly) as required. When used for intralesional injection, the author prefers to use ~20 million MSCs qs to 3 to 4 mL in Lactated Ringer's solution as appropriate for the size of the lesion. For intra-arterial and regional intravenous administration, 30 million MSCs qs to 20 to 30 mL in Lactated Ringer's solution are used.

Considering how frequently biologics are used to treat PSD, there is surprisingly little scientific research to go along with it. The use of autologous bone marrow to treat chronic PSD was first reported in 2001; of 100 sport horses, 84% were sound and 92% were in full work 6 months after treatment.[9] Autologous bone marrow has also been used to treat acute forelimb suspensory body and branch lesions in racehorses.[10] Average time to return to racing was 12 to 14 months, and 9 of 13 (69%) Standardbreds and 12 of 17 (71%) Thoroughbreds had 5 or more starts following treatment. Although this study provides longer-term outcomes than most of the other studies that only followed horses to 6 months, the results may not be directly applicable as treatment was directed at the suspensory body and branches, rather than the proximal aspect, which carries a worse prognosis.

A recent study examined the use of a combined allogenic PRP (100–150 million platelets) and peripheral bone MSC (2–3 million MSCs) injectate to treat proximal suspensory or suspensory branch desmopathy.[11] Of the 68 English sport horses in the study, 57 (84%) were competing at their previous level at 1 year, and 56 (82%) were still in full work and competition at 2 years. The majority of these cases, however, were suspensory branch injuries rather than PSD. A meta-analysis from the same study found that stem-cell-treated groups had a significantly lower reinjury rate (18%) compared to other more conventional treatments (44%).

When used by itself, the results of intralesional PRP are similar to the reports of bone marrow aspirate and/or MSCs, at least in the short term.[12] Twenty sport horses with acute forelimb PSD were treated with intralesional PRP q 2 weeks, as required for near resolution of the lesion on ultrasound. Of these, 16 (80%) were able to return to full work 12 to 24 weeks after their last treatment. Finally, there has been one study of 271 horses treated with a single injection of autologous conditioned serum (5 mL diffused to the palmar/plantar cortex of the proximal metacarpal/tarsal bone at the suspensory ligament origin).[13] Of 127 forelimb cases, 85% of unilateral cases and 82% of bilateral cases were sound 1 month after resuming full training. Of 144 hindlimb cases, 78% of unilateral and 71% of bilateral cases had maintained soundness for at least 30 days of full training. Longer-term follow-up was not presented. Unfortunately, the majority of studies discussed lack a control group and lack follow-up longer than 6 months. There appears to be a pattern of better short-term and poorer long-term outcome regardless of treatment. Of the many biologic choices available, MSCs may provide the best opportunity for improved long-term prognosis; however, more controlled studies over longer periods of time are needed.

Surgery

For hindlimb PSD, surgery is a common treatment. Surgery can involve a neurectomy (of the deep branch of the lateral plantar nerve), fasciotomy (of the plantar fascia), desmoplasty, and/or osteostixis. In the author's experience, surgery is often not required for successful long-term management of PSD as the majority of horses can be managed medically. However, for many practitioners, surgery is one of the primary and first treatment options.

The largest report of surgical outcome comes from Dyson et al. reported on 155 horses that underwent

Fig. 2. Picture demonstrating a horse with excessively straight hindlimb conformation. Horses with this conformation are not good candidates for neurectomy fasciotomy surgery.

hindlimb neurectomy and fasciotomy.[14] The horses were grouped into 3 groups, with Group 1 having only PSD, Group 2 having PSD but also very straight hock conformation (hock angle ≥ 150°) and/or hyperextension of the fetlocks (dorsal fetlock angle ≤ 130°), and Group 3 having PSD and another concurrent issue (e.g., sacroiliac pain). Using return to the previous level of function for greater than 1 year as the outcome measurement, 70% (64/92) of the Group 1 horses were successful compared to none of Group 2 horses (0/5) and only 44% (23/52) of the Group 3 horses. The rehabilitation protocol entailed 2 weeks of stall rest followed by 6 weeks of ridden walk exercise prior to gradual return to full exercise if soundness allowed. An important take home from this study is that not only did the 5 Group 2 horses fail to improve, but they also worsened based on ultrasound evaluation. The authors concluded that horses with excessively straight hindlimb and/or dropped fetlock conformation (Fig. 2) are not good candidates for neurectomy and fasciotomy surgery.

Some surgeons prefer to spare the nerve and only perform a fasciotomy, with the theory that decompression alone will yield a satisfactory outcome. In a study of 27 horses with chronic (1–12 months) PSD that underwent desmoplasty (fenestration of the ligament lesion to the depth of the underlying plantar cortex of MTIII) and fasciotomy surgery, 23 (85%) were able to return to full work 5 to 18 months following surgery.[15] Osteostixis, in which 3 to 6 small holes (2 mm) are drilled into the palmar/plantar cortex of MCIII/MTIII, does not seem to improve outcome as only 17 of 29 sport horses returned to competition at 6 months post-surgery.[16] In an experimental study, horses treated with microfracture (and ligament splitting) did not show a significant difference in lameness through the 210-day study.[17]

Conversely, there are surgeries that only involve neurectomy. A tibial neurectomy was performed in 8 horses, of which 6 (75%) were able to return to full athletic function for at least 2 years following surgery.[18] In the forelimb, limited but promising studies exist on excision of the deep branch of the lateral palmar nerve (DBLPaN). In an experimental study, 8 horses with collagenase-induced PSL in forelimbs were sound 2 weeks after neurectomy of the DBLPaN.[19] In a case series of 4 horses with chronic forelimb PSD that failed medical management (consisting of 3 radial shockwave treatments at 2-week intervals, local injection of 10 mg triamcinolone, and increasing exercise over 12 weeks), all were sound at 6 weeks and at 1 year following neurectomy of the DBLPaN.[20] Last, Bathe reported on the outcome of 26 horses that underwent neurectomy of the DBLPaN.[21] Thirteen of 16 (81%) were in full work at 1 year and 8 of 12 (67%) were in full work at 2 years following surgery.

Bisphosphonates

Although there is no literature reporting on the efficacy of bisphosphonate therapy in treating PSD specifically, the mechanism of action for this class of drugs lends promise for cases with involvement of the bony origin. Bisphosphonates are widely used in humans to combat osteoclast-mediated osseous resorption and more recently have been recognized as having anti-inflammatory effects as well.[22,23] In horses, there are only a few studies that investigated the efficacy of bisphosphonates for treating navicular disease, distal hock joint osteoarthritis, and thoracolumbar back osteoarthritis.[24–26] The author routinely uses bisphosphonates in cases of PSD that involve the osseous origin of the suspensory ligament. Examples include sclerosis, osseous resorption, enthesophyte formation, and/or "bone marrow edema" of the proximal palmar/plantar aspect of the third metacarpal/tarsal bone (Fig. 3). Two FDA-approved bisphosphonates are available for use in horses (tiludronate[c] and clodronate[d]). In adult horses, the author typically treats with a single dose of clodronate[d] (1.8 mg/kg, not to exceed 900 mg IM, split into 3 injections sites). Safety data for both bisphosphonates demonstrate that an increase in serum kidney values can occur; therefore, assessing blood urea nitrogen and creatinine prior to administration is advisable. Additionally, these medications should not be given in conjunction with NSAIDs as there may be an additive load on the renal system.

Corticosteroid Injection

Neuropathy of the deep branch of the lateral plantar nerve (DBLPN) is a common component of the PSD disease "complex." This is likely due to fact that PSD, particularly in hindlimbs, is a compartment-like syndrome that could lead to compressive damage of the

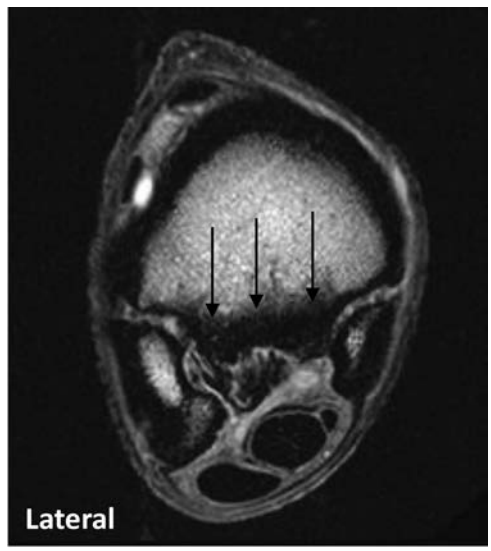

Fig. 3. A transverse proton density magnetic resonance image of the proximal metacarpal region; lateral is the left. Note the marked changes of the cortical bone at the interface of the proximal suspensory ligament (black arrows).

Fig. 4. A horse with hyperextension of the fetlock shod in a "fishtail" shoe to support the fetlock from dropping further.

DBLPN. In fact, in a study of 16 horses that underwent unilateral or bilateral DBPLN neurectomy, all DBLPN nerves excised from lame limbs showed histopathologic changes consistent with nerve compression.[27] Therefore, cases of chronic PSD likely involve some degree of neuritis, and for this reason, direct injection of an anti-inflammatory may be indicated. Dyson opines that local injection of corticosteroids (with 4 to 6 weeks of onset) may decrease the compartment-like syndrome.[28] However, in the acute stage, there may also be more acute soft tissue injury, in which case local injection of corticosteroids may be contraindicate due to the potential for corticosteroids to retard soft tissue healing. The author has had very good outcomes treating with focal infiltration of corticosteroids (3–6 mg triamcinolone qs to ~4–5 mL in sterile saline) in cases where there is little to no ligamentous change and/or in more chronic cases.

Shoeing

By design, the suspensory apparatus "suspends" the fetlock, which, if left to gravity, would hyperflex and sink to the ground. While not to that extreme, injury of the proximal aspect of the suspensory ligament leaves the normal biomechanics of the suspensory compromised. It is well established that increasing the height of the heel will unload the deep digital flexor tendon and increase load on the superficial digital flexor tendon and the suspensory ligament. By the same theory, some practitioners chose to preferentially load the deep digital flexor tendon by lowering the heel of the shoe, theoretically lessening the load on the suspensory apparatus, as is the case with the Denoix suspensory shoe.[e] This author aims for good hoof pastern alignment and adequate palmar/plantar solar margin angles but does not intentionally lower the heels. Fetlock "support" is provided with a shoe that extends more palmar/plantar than normal with use of an extended heel egg bar shoe, extended branch shoe, or even a fishtail shoe (Fig. 4) in extreme cases.

Rehabilitation

One of the most central components in managing PSD involves a period of rest and controlled exercise, though the specifics of such programs vary widely among practitioners. Gillis[29] provided one of the more detailed protocols for rehabilitation of soft tissue injuries many years ago that generally outlined 30 minutes of hand walking a day for the first 2 months and then increasing to 40 to 60 minutes of walk. For all but severe injuries, in the fourth and fifth months, horses are walked under saddle for 30 and then 45 to 60 minutes daily, respectively. At 6 months, trot is typically introduced in increments of 5 minutes every other week for 4 weeks, followed by an addition of 5 minutes of canter every other week. The majority of horses would return to full flat work at 8 months and competition in 10 months.[29] In the PSD literature, the majority of authors initially restrict horses to box rest plus walking for 20[3,11,13] to 60 minutes[4,30] daily. Trot is added as soon as 4 weeks by some[11,13] and 6, 8, and 12 weeks by others,[3,4,30] with return to full exercise occurring anywhere from 3[12,21] to 6 to 9 months.[9,10,31] Postsurgery rehabilitation typically consists of a period of strict stall rest for 2 to 4 weeks before resuming trot work 4 to 8 weeks after surgery.[14,17,20,21]

Ultimately, there are no studies comparing the rest and rehabilitation protocols. This author typically employs hand walking (20 minutes daily) throughout the initial treatment period (~4 weeks), followed by increasing amounts of walking under saddle, increasing by 5 minutes of walk per week. Once the horse has achieved at least 30 minutes of walking under saddle, trot is introduced in 2.5- to 5-minute intervals per week, depending on the severity, with canter being added only once the horse has reached 20 minutes of trot work. Clients are generally advised that the horse will not return to full work for at least 6 months and, in some cases, up to a year. Other considerations for the controlled exercise program include working on level, flat, consistent surfaces, with the amount of exercise decreased by ~25% if the footing conditions are different than what the horse is accustomed to. For example, for horses that are walking for 30 minutes on firm footing but are then abruptly required to walk in deeper sand footing, it may be advisable to decrease walking to 22 to 25 minutes until the horse reconditions to the different footing over several weeks.

There are many other techniques that are often incorporated into a PSD rehabilitation plan. Unfortunately, many therapeutic modalities are marketed directly to the owner, often with unsubstantiated claims. However, two recent studies have shown significant improvement in horses with suspensory branch lesions that were treated with high-power laser (once daily for 2 to 4 weeks).[32,33] If a laser unit is available to the owner, the author prescribes its use daily in acute cases or, in chronic cases, once daily for 3 days and then 3 times per week for 6 weeks. Simple, inexpensive techniques should also not be overlooked. Walking over ground poles, for example, can be employed later in the under-saddle walking portion of the program to increase proprioception and begin to expose the suspensory ligament to varied range of motion and forces. Proprioceptive balance pads (which may be more appropriate after resolution of acute injury) and core strengthening exercises are incorporated into many rehabilitation programs though are not necessarily specific to PSD.

3. Conclusion

Proximal suspensory disease is a complicated and complex disease that involves the proximal aspect of the suspensory ligament, its osseous origin, the DBLPaN/DBLPN, and/or the connective fascia. The wide range of tissue types and pathology involved in PSD is likely to explain the wide variety of treatments that are employed to manage the disease. As studies demonstrate, hindlimb PSD is harder to manage and carries a poorer long-term prognosis than forelimb PSD. However, with the combination of shockwave, biologic therapies, systemic and topical NSAIDs, bisphosphonates, shoeing, and rehabilitation considerations, most cases can be successfully managed without surgical intervention. However, surgery carries a good prognosis that is at least equivalent to management with shockwave and/or biologics and is also a valid treatment option. The author has managed hundreds of cases of PSD, mostly in English performance horses, with a success rate similar to those reported in the literature, which underscores the variety of ways that PSD can be managed in performance horses.

Acknowledgments

Declaration of Ethics

The Author has adhered to the Principles of Veterinary Medical Ethics of the AVMA.

Conflict of Interest

The Author has indirect financial interest in a commercial stem cell company.

References and Footnotes

1. Frisbie DD, McIlwraith CW, Kawcak CE, et al. Evaluation of topically administered diclofenac liposomal cream for treatment of horses with experimentally induced osteoarthritis. *Am J Vet Res* 2009;70:210–215.
2. Van Eps AW, Orsini JA. A comparison of seven methods for continuous therapeutic cooling of the equine digit. *Equine Vet J* 2016;48:120–124.
3. Boening KJ, Loffeld S, Weitkamp K, et al. Radial extracorporeal shock wave therapy for chronic insertion desmopathy of the proximal suspensory ligament, in *Proceedings*. Am Assoc Equine Pract 2000;46:203–207.
4. Crowe OM, Dyson SJ, Wright IM, et al. Treatment of chronic or recurrent proximal suspensory desmitis using radial pressure wave therapy in the horse. *Equine Vet J* 2004;36:313–316.
5. Lischer C, Ringer S, Schnewlin M, et al. Treatment of chronic proximal suspensory desmitis in horses using focused electrohydraulic shockwave therapy. *Schweiz Arch Tierheilkd* 2006;148:561–568.
6. Loffeld S, Boening KJ, Weitkamp K, et al. Radiale extrakorporale Stoßwellentherapie bei Pferden mit chronischer Insertionsdesmopathie am Fesselträgerursprung – Eine kontrollierte Studie. *Pferdeheilkunde* 2002;18:147–154.
7. Guinta K, Donnell JR, Donnell AD, et al. Prospective randomized comparison of platelet rich plasma to extracorporeal shockwave therapy for treatment of proximal suspensory pain in Western Performance horses. *Res Vet Sci* 2020;126:38–44.
8. Seabaugh KA, Thoresen M, Giguère S. Extracorporeal shockwave therapy increases growth factor release from equine platelet-rich plasma in vitro. *Front Vet Sci* 2017;4:205.
9. Herthel D. Enhanced suspensory ligament healing in 100 horses by stem cell and other bone marrow components, in *Proceedings*. Am Assoc Equine Pract 2001;47:319–321.
10. Hall MS, Vasey JR, Russell JW, et al. Use of ultrasound-guided autologous bone marrow transfer for treatment of suspensory ligament desmitis in 30 race horses (2003-2010). *Aust Vet J* 2013;91:102–107.
11. Beerts C, Suls M, Broeckx SY, et al. Tenogenically induced allogenic peripheral blood mesenchymal stem cells in allogenic platelet-rich plasma: 2-year follow-up after tendon or ligament treatment in horses. *Front Vet Sci* 2017;4:158.
12. Romagnoli N, Rinnovati R, Ricciardi J, et al. Clinical evaluation of intralesional injection of platelet-rich plasma for the treatment of proximal suspensory ligament desmitis in horses. *J Equine Vet Sci* 2015;35:141–146.

13. Easter JL, Watts AE. How to select cases and use autologous conditioned serum to treat proximal suspensory desmitis, in *Proceedings*. Am Assoc Equine Pract 2014;60: 516–522.
14. Dyson S, Murray R. Management of hindlimb proximal suspensory desmopathy by neurectomy of the deep branch of the lateral plantar nerve and plantar fasciotomy: 155 horses (2003-2008). *Equine Vet J* 2012;44:361–367.
15. Hewes C, White N. Outcome of desmoplasty and fasciotomy for desmitis of the origin of the suspensory ligament in horses: 27 cases (1995-2004). *J Am Vet Med Assoc* 2006; 229:407–412.
16. Launois T, Desbrosse F, Perrin R. Percutaneous osteostixis as treatment for avulsion fractures of the palmar/plantar third metacarpal/metatarsal bone cortex at the origin of the suspensory ligament in 29 cases. *Equine Vet Educ* 2010; 15:126–138.
17. Brokken MT, Schneider RK, Roberts GD, et al. Evaluation of a new surgical treatment for equine hind limb proximal suspensory desmitis. *Vet Surg* 2016;45:868–878.
18. Dyson S, Genovese R. The suspensory apparatus. In: Ross M, Dyson S, eds. *Diagnosis and management of lameness in the horse, 1st ed*. St. Louis: Elsevier Science, 2003;654–672.
19. Lopez-Navarro G, Trigo-Tavera FJ, Rodriguez-Monterde A, et al. Histological changes in the proximal suspensory ligament after neurectomy of the deep branch of the lateral palmar nerve of horses with induced proximal suspensory desmitis. *Vet J* 2017;227:46–48.
20. Guasco PG, Kelly G, Schumacher J, et al. Excision of the deep branch of the lateral palmar nerve of horses resolve lameness caused by proximal suspensory desmitis. *Vet Surg* 2013;42:296–301.
21. Bathe AP. Neurectomy of the deep branch of the lateral palmar nerve as a treatment for chronic equine forelimb proximal suspensory desmitis: 26 cases. *Equine Vet J Suppl* 2019;51:14.
22. Drake MT, Cremers S. Bisphosphonate therapeutics in bone disease: The hard and soft data on osteoclast inhibition. *Mol Interv* 2010;10:141–152.
23. Kamm L, McIlwraith W, Kawcak C. A review of the efficacy of tiludronate in the horse. *J Equine Vet Sci* 2008;28:209–214.
24. Denoix JM, Thibaud D, Riccio B. Tiludronate as a new therapeutic agent in the treatment of navicular disease: A double-blind placebo-controlled clinical trial. *Equine Vet J* 2003;35:407–413.
25. Gough MR, Thibaud D, Smith RKW. Tiludronate infusion in the treatment of bone spavin: A double blinded placebo-controlled trial. *Equine Vet J* 2010;42:381–387.
26. Coudry V, Thibaud D, Riccio B, et al. Efficacy of tiludronate in the treatment of horses with signs of pain associated with osteoarthritic lesions of the thoracolumbar vertebral column. *Am J Vet Res* 2007;68:329–337.
27. Toth F, Schumacher J, Schramme M, et al. Compressive damage to the deep branch of the lateral plantar nerve associated with lameness caused by proximal suspensory desmitis. *Vet Surg* 2008;37:328–335.
28. Dyson S. Diagnosis and management of common suspensory lesions in the forelimbs and hindlimbs of sport horses. *Clin Tech Equine Practice* 2007;6:179–188.
29. Gillis CL. Rehabilitation of tendon and ligament injuries, in *Proceedings*. Am Assoc Equine Pract 1997;43:306–309.
30. Dyson S. Proximal suspensory desmitis in the hindlimb: 42 cases. *British Vet J* 1994;150:279–291.
31. Gibson KT, Steel CM. Conditions of the suspensory ligament causing lameness in horses. *Equine Vet Educ* 2010;14: 39–50.
32. Pluim M, Martens A, Vanderperren K, et al. Short- and long term follow-up of 150 sport horses diagnosed with tendinopathy or desmopathy by ultrasonographic examination and treated with high power laser therapy. *Res Vet Sci* 2018; 119:232–238.
33. Pluim M, Martens A, Vanderperren K, et al. High-power laser therapy improves healing of the equine suspensory branch in a standardized lesion model. *Frontiers Vet Sci* 2020;7:600.

[a]Surpass, Boehringer Ingelheim, Duluth, GA 30096.
[b]Game Ready, Avanos Medical, Inc., Alpharetta, GA 30004.
[c]Tildren, Bimeda, Oakbrook Terrace, IL 60181.
[d]Osphos, Dechra, Overland Park, KS 66211.
[e]Denoix Suspensory Shoe, Grand Circuit Inc., Louisville, KY 40228.

Safety Validation of Equine Blood Flow Restriction Training: A Pilot Investigation

Sherry A. Johnson, DVM, MS, DACVSMR*; Melissa R. King, DVM, PhD, DACVSMR; Gregg Griffenhagen, DVM, DACVA; and David D. Frisbie, DVM, PhD, DACVS, DACVSMR

Blood flow restriction (BFR) training at 80% limb occlusion pressure (LOP) did not result in gait alterations over a 56-day study period, but significant differences in LOP values between horses and limbs were appreciated. Authors' address: Colorado State University, 300 West Drake Road, Fort Collins, CO 80523; e-mail: sherryjdvm@gmail.com. *Corresponding and presenting author. © 2022 AAEP.

1. Introduction

Blood flow restriction (BFR) has become a key rehabilitative tool for human orthopedic conditions, but safety validation for use in the horse is lacking. The objectives of this study were: 1) to determine if BFR exposure resulted in biomechanical gait deficiencies and 2) to investigate intra- and inter-horse limb occlusion pressure (LOP) differences.

2. Materials and Methods

Daily forelimb BFR exposure was performed in four horses over a 56-day study period with clinical examinations and objective gait analysis performed on study days 0, 28 and 56. Daily LOP values were determined by Doppler evaluation to deliver 80% vascular occlusion while at a walk.

3. Results

Significant differences in kinematic and kinetic gait parameters over time were not appreciated. Significant differences between mean LOP values between horses and forelimbs were observed. Mean LOP and standard deviation across all readings was 189.1 +/− 22.2 mm Hg.

4. Discussion

Results indicate that BFR exposure did not negatively impact the normal biomechanical gait parameters assessed in four horses and all BFR sessions were well tolerated. Clinically apparent complications related to BFR such as forelimb lameness, thrombosis, or dermatitis were not appreciated. This data suggests that occlusion pressures of 75-151 mm Hg would likely simulate a range of 50-80% vascular occlusion in horses, but inherent physiologic variation warrants incorporation of individual pressures for optimized BFR application.

Acknowledgments

Funding Sources

This project was funded by the Translational Acceleration Program (TAP) of the Translational Medicine Institute (TMI), College of Veterinary Medicine and Biomedical Sciences, Colorado State University.

Research Abstract—for more information, contact the corresponding author

NOTES

Declaration of Ethics

The Authors have adhered to the Principles of Veterinary Medical Ethics of the AVMA.

Conflict of Interest

Drs. Johnson, King, and Frisbie are co-founders and partners of Equine Core, Inc. (Fort Collins, CO), an entity that is involved in the development of equine-specific blood flow restriction devices.

Systematic Review of the Association Between Intra-Synovial Corticosteroid Use and Laminitis: What Is the Evidence?

Paula Keiko Anadão Tokawa, DVM*; Raquel Yvonne Arantes Baccarin, DVM, PhD; and Gustavo M. Zanotto, DVM, MSc, PhD, DACVSMR

Moderate scientific evidence suggests that intra-synovial corticosteroids are not associated with laminitis in horses without underlying metabolic or endocrine disease, obesity, and history of laminitis. Authors' addresses: Department of Internal Medicine, School of Veterinary Medicine and Animal Science, University of São Paulo, Brazil (Tokawa, Baccarin); Texas A&M University, College of Veterinary Medicine and Biomedical Sciences, Large Animal Clinical Sciences Department, College Station, TX (Zanotto); e-mail: p.tokawa@usp.br. *Corresponding and presenting author. © 2022 AAEP.

1. Introduction

Anecdotal information has linked intra-synovial corticosteroid administration with the development of laminitis in horses. This systematic review aims to compile and evaluate the level of current evidence that investigates the relationship between intra-synovial corticosteroid use and laminitis.

2. Materials and Methods

A systematic search in PubMed, CAB Direct, and Web of Science databases was conducted in February, 2022. Studies were included if designed as experimental in vivo in horses, case series, observational cohorts (retrospective or prospective – with/without control group) or randomized clinical trials.

3. Results

A total of 237 studies were generated from the systematic search and after applying inclusion criteria, 4 were selected: two were designed as retrospective cohort, one included a retrospective and a prospective investigation and the last one was a cases series. Studies had a moderate level of quality of evidence, and all presented some degree of weakness such as lack of controls or insufficient information (corticosteroid dose, treatment/follow-up period). Reported incidence of laminitis followed by corticosteroid intra-synovial administration was low and similar to controls (if included).

4. Discussion

Despite differing opinions found among veterinarians, the limited number of articles that met the inclusion

Research Abstract — for more information, contact the corresponding author

NOTES

criteria of this systematic review highlights the lack of studies with high-evidence level. Current scientific information at a moderate-evidence level suggests that there is no association between intra-synovial corticosteroid injection and laminitis in horses without risk factors.

Acknowledgments

The Authors would like to thank the AAEP Performance horse committee for its support and the Texas A&M University library services for their assistance during creation of searching term and data acquisition.

Declaration of Ethics

The Authors have adhered to the Principles of Veterinary Medical Ethics of the AVMA.

Conflict of Interest

The Authors have no conflicts of interest.

Residual Anti-Inflammatory Effects of Intra-Articular Triamcinolone Acetonide and Betamethasone in an Equine Acute Synovitis Model

Emma Partridge, BS; Emma Adam, DVM, PhD, DACVIM, DACVS; Courtney Wood, MS; Jordan Parker, BS; Mackenzie Johnson, BS; David W. Horohov, PhD; and Allen E. Page, DVM, PhD*

Intra-articular triamcinolone acetonide maintains a significant, localized anti-inflammatory effect 14 days after treatment while both intra-articular triamcinolone acetonide and betamethasone have profound post-treatment suppressive effects on serum cortisol concentration. Authors' addresses: University of Kentucky, 108 Gluck Equine Research Center, Lexington, KY 40546 (Partridge, Adam, Parker, Johnson, Horohov, Page); Lincoln Memorial University, Harrogate, TN 37752 (Wood); e-mail: a.page@uky.edu. *Corresponding and presenting author. © 2022 AAEP.

1. Introduction

Intra-articular (IA) corticosteroids are commonly used to combat the sequelae of joint disease in equine athletes resulting from the high-intensity nature of their disciplines. These therapeutic drugs have long been a popular choice to treat joints given they are highly potent and effective medications used to control pain and inflammation. There is concern, however, that the long-lasting effects of corticosteroids may mask clinical signs associated with underlying musculoskeletal injuries, leading to their exacerbation during exercise and competition. Importantly, in the context of Thoroughbred racing, underlying musculoskeletal injuries put the safety of the horse and rider at risk since most catastrophic injuries occur when underlying pathology is present. With recent work by multiple groups examining the messenger RNA (mRNA) response to exercise and injury in horses, it is necessary to better understand the residual effects that IA corticosteroids may have on mRNA expression, as well as other inflammatory parameters, in horses.

2. Materials and Methods

Five mixed-breed, 2-year-old horses were utilized for this study, and all IA injections were conducted 14 days apart. One radiocarpal joint was aseptically injected randomly with 9 mg of either betamethasone or triamcinolone acetonide (TA). Two weeks following treatment, horses were injected with 1 μg (1,000 ng) of lipopolysaccharide (LPS) diluted in 1 mL of sterile

Research Abstract—for more information, contact the corresponding author

NOTES

saline. Following treatment, horses were crossed-over and treated with the other drug followed by a subsequent LPS injection at the same 14 day intervals. Additional injections with saline-only or LPS-only were conducted as negative and positive controls, respectively. Blood samples were collected at multiple time points for RNA isolation and qPCR expression analysis, as well as cortisol determination, serum amyloid A (SAA) quantification, complete blood cell counts, and blood biochemistry analysis. Additionally, lameness was subjectively scored and recorded at the same time points. Two-way repeated measures analysis of variance was used to analyze all data with $p < 0.05$ considered significant.

3. Results

At 14 days post-treatment, horses treated with triamcinolone acetonide had evidence of a residual anti-inflammatory effect based on *IL-6* and *PTGS1* (cyclooxygenase-1) expression. Additionally, TA treated horses experienced less severe and significantly shorter periods of lameness, as well as lower peak SAA and serum cortisol concentrations, compared to times when the joints were not treated. Similar residual treatment effects with betamethasone were not noted, except for differences in *IL-6* expression. Intra-articular injection with either betamethasone or TA was noted to have a profound effect on serum cortisol concentrations, with cortisol exhibiting significant suppression until 48 hours (betamethasone) and 120 hours (TA) post-treatment.

4. Discussion

Despite utilizing a model for acute synovitis that is more severe than those previously reported by others, findings from this study suggest that the commonly used intra-articular corticosteroid, triamcinolone acetonide, retains significant anti-inflammatory effects at least 14 days after administration. Within the context of racing and competition requirements, these findings suggest that current guidelines may be insufficient if the regulatory concern is residual anti-inflammatory effects following treatment. Furthermore, findings from this project demonstrate that the administration of intra-articular corticosteroids are not without risk, as evidenced by the significant and prolonged suppression of serum cortisol concentration, and, as such, the benefits of their administration should be weighed against those risks.

Acknowledgments

Declaration of Ethics

The Authors have adhered to the Principles of Veterinary Medical Ethics of the AVMA.

Conflict of Interest

The Authors have no conflicts of interest.

How to Manage the Upright/Low-Grade Club Foot with a Rocker Shoe

Ramon Batalla, MV

Author's address: Rood and Riddle Equine Hospital, 2150 Georgetown Road, Lexington, KY 40511; e-mail: ramonbatallavet@gmail.com. © 2022 AAEP.

1. Introduction

The intricate balance and equilibrium that exists in the interconnectedness of the digital structures of the healthy foot can be thrown out of synchronicity by injury, disease, genetic factors, overload, environment, and/or human interference, resulting in a cascading series of events influenced by body weight and the action of the deep digital flexor tendon, causing altered growth patterns and hoof capsule distortion.[1–3] It has been described that approximately two-thirds of horses have mismatched feet where usually one is flat and the other one is upright.[4] Contrary to popular belief, the upright or club foot is not a foot problem; it is a muscle problem that manifests in the foot. It is the result of significantly increased tension on the deep digital flexor tendon (DDFT) due to hypercontraction of the deep digital flexor muscle fibers that results in hyperflexion of the coffin joint.[3,5,6] Unlike laminitis, the laminae antagonist is healthy. It is the tendon pull that is abnormally strong, creating an imbalance in the suspension system of the third phalanx. Though the cause is different from laminitis, many of the effects are similar: unrelenting contraction that increases palmar angle (PA), which causes vascular compromise in areas of the foot that receive abnormal compressive forces.[7] Sole corium compression inhibits papillae function, which compromises adequate sole growth underneath the apex of the third phalanx. This routinely leads to rapid remodeling of the palmar rim (load induced lesions) and remodeling along the face of the coffin bone.[3,8] The bending and compressive forces can also create a toe flare in the horn wall. The excess heel is the result of suspension of the posterior aspect of the bone, which allows for uninhibited heel growth. This lack of internal load results in narrow heels, recessed frog, and thick digital cushion.[2,9,10] This is grossly evidenced by observing the foot, where it is common to see high heels, growth rings wider at the heels than at the toe, and a toe flare.[3] The club foot syndrome is a condition that is managed rather than treated, and like laminitis, the optimum approach is dependent on multiple factors. It is important to remember that while a club foot can be healthy, it will still be a club and require a different management protocol. Therefore, attempting to eliminate it by making the exterior of the foot "look" normal does not change the fact that the condition is still present. Once the heel has been removed with trimming, instead of resting on the ground, the heel remains slightly off the ground with load being transferred to the toe.[3,7] Attempting to make a club foot look normal is highly counterproductive, as the forces that created it in the first place are often increased.[7]

2. Materials and Methods

There is scarce information in the veterinary literature regarding the management of a mature horse with a club foot. Farriery to maintain or improve the club foot is often empirical and based on past experience. To apply the appropriate farriery, understanding the proposed mechanism leading to this conformation is very valuable. Traditional farriery management for

NOTES

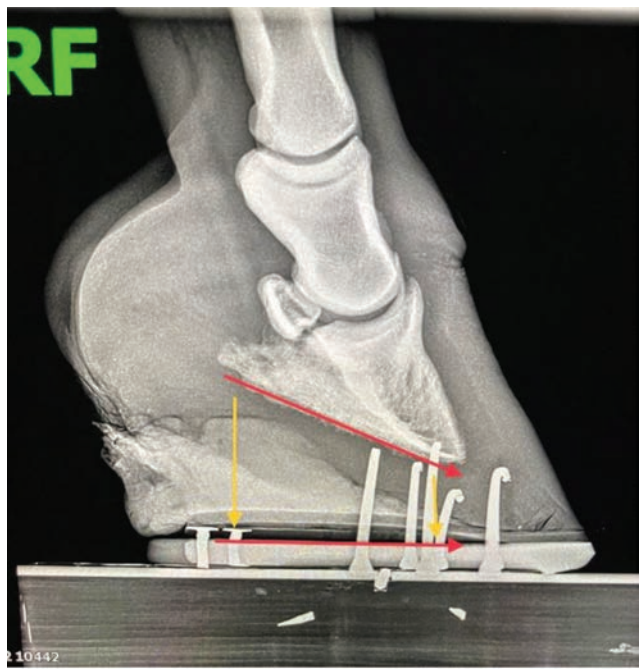

Fig. 1. A club foot shod flat. It is evident how the distance between the apex of the third phalanx and the shoe is less than the distance between the posterior area of the third phalanx and the shoe creating a positive capsular palmar angle which in this case promotes uneven load distribution over the sole.

Fig. 2. Guideline of the trim (white line of radiopaque paste), bringing the heels back from the widest part of the foot to the widest part of the frog attempting to match the palmar rim of the third phalanx (red line), but without compromising the mass of the foot.

upright or club feet has been directed at trimming the heels to shift the load caudally and at reducing breakover, but the amount of heel to remove can be difficult to determine.[3,10] Often, the addition of heel elevation following the trim is necessary to compensate for the shortening of the musculotendinous unit. It has been described that the degree of wedge that is applied often mimics the amount of heel removed, which can be a subjective approach, and clear information as to its effectiveness unloading the toe and promoting even hoof growth is not readily available.[10] When dealing with upright or low-grade club feet, the author has found that the mechanical advantages provided by the rocker or banana shoe are very valuable to counteract the abnormal forces acting upon these feet.[8,11] The market has several options of shoes that provide built-in mechanics (rocker or banana shape) on the ground surface, while the foot surface remains flat. This approach will provide a certain amount of relief of the tension of the DDFT by providing a reduced breakover, but it is still a flat shoe. Working as a veterinarian with an emphasis in equine podiatry, the author has the opportunity to radiograph the feet of patients on a regular basis, and it has been repeatedly observed that either with a flat shoe (even if it has mechanics on the ground surface) or with the traditional methods of dealing with upright/club feet, it is common to find that the distance between the apex of the coffin bone and the shoe is less than the distance between the wings of the coffin bone (posterior area) and the shoe, thus creating uneven load distribution over the sole (Fig. 1). Also it is common to find longer breakover distances (toe ahead of the apex of third phalanx), especially if the shoeing is fitted to the toe and if the shoe does not provide sufficient mechanics on the ground surface. The leverage caused by the longer breakover is one of the principal causes of hoof distortions.[7]

As a consequence, and aided by the increased pull of the DDFT that characterizes this condition, there will be a constant uneven blood perfusion to the solar corium, where less blood reaches the toe in comparison to the heels, giving the heels the elements to have increased growth, thus promoting the clubby characteristics of these feet.[7,8,10]

As explained before, if the management approach is based on lowering the heels, trying to make the foot look "normal" or to match the other foot as it has been suggested by some literature,[12] it will create an increased tension on the DDFT, which will increase the pulling forces over the coffin bone obliterating the blood perfusion over the toe area, creating a negative vicious cycle where the horse has less toe growth and more heel growth.[9,10] Many times, these horses will not put their heels down after trimming, because of the pain caused by the pull of the tendon (soft tissue strain, solar corium compression, lamellar stretching and pressure over the navicular bone). In order to remove the excess heels yet avoid the complications previously described, it is fundamental to compensate what was removed by using a wedge[5,10] or, in this case, an "air wedge" provided by the rocker or banana shoe (Figs. 2 and 3).[8,13]



Fig. 3. A, Placement of the rocker shoe to match the trim and create a 0 capsular PA which will provide an even load distribution over the sole. B, Mechanics of the rocker shoe are achieved by creating an even concave shape with the support close to the center of the shoe.

The goal is to achieve uniform blood perfusion throughout the entire sole of the foot by matching the branches of the shoe with the palmar rim of the coffin bone (0 capsule PA), while maintaining a positive ground PA with an ideal distal bony column alignment.[6] That is what, in the author's experience, best stimulates even hoof growth and development of hoof mass, thus maintaining a healthy foot. When dealing with upright feet, the mechanics in the foot should be achieved by trimming the heels, rolling them back from the widest part of the foot to the widest part of the frog instead doing it flat and all the way from the toe (how it is commonly taught). The use of radiographic guidance is very helpful, as it is possible to mark the trim by applying radiopaque paste on the medial heel and checking with a radiograph to confirm if it matches the palmar rim of the bone, like in Figure 2. Putting the mechanics (rocker shape) into the shoe in order to properly match the trim should be a methodical procedure. Rocker Jigs (metal plate with concave bend) seem to be the most appropriate tool to forge the rocker shape into the shoe, but there are other, more accessible ways like cams 1 3/8 in. apart or even the step of the anvil. The rocker is forged, starting at the heel of the shoe and working the hammer toward the toe one branch at a time.[14] It is ideal to obtain an evenly distributed concave bend that matches the trim and avoid a "V" shape in the shoe, which can make the foot sit flat in one of the sides, especially toward the end of the shoeing cycle (Fig. 3B).

The author has experienced that the rocker shoe, which has also been referred to as self-adjusting palmar angle shoe, if applied correctly, allows the horse to "rock" forward, thus relieving the tension of the DDFT, while achieving a desired distal bony column alignment.[8,11,13] The secret to success in this protocol is in the application. The trim needs to match the shoe, and the belly or support of the shoe has to be

Fig. 4. The center of rotation (blue line) of the foot is located and how this should coincide with the "belly" or support of the rocker shoe.

Fig. 5. Example of the upright foot of a hi-low horse after shoeing with a rocker shoe. This picture shows how the belly or support of the shoe is underneath the center of rotation and how the foot is breaking over under the apex of P3.

Fig. 6. The end result of the foot after the described shoeing procedure.

Fig. 7. A superimposed image that demonstrates the relationship between the internal bony structures and the external landmarks of the foot after the application of a modified rocker shoe.

underneath the center of rotation (COR) of the foot, for the horse to maximize the ability to utilize the mechanics while presenting even, robust hoof growth. The COR is the point of convergence of the loading forces of the horse's bodyweight upon the foot, and it is found by drawing a vertical line from the center of the lateral condyle of the distal middle phalanx to the ground. This can be explained by basic biomechanics and the fact that a concave uniform belly that sits underneath the center of rotation makes both the flexor and extensor moment arms achieve an equilibrium, and with the absence of resistance that the shape of the shoe provides, the "self-adjusting" benefits are made possible (Fig. 4).

Another crucial aspect of the banana shoe with this proposed application is that the breakover point will be located right underneath the apex of P3, guaranteeing no leverage over the hoof wall or the laminae, and providing a biomechanically efficient breakover process while avoiding the formation of a toe flare. If properly applied, the horse will stand comfortably managing the mechanics without any tendency to rock forward or backward (Fig. 5).

3. Results

In summary, it is the author's experience that the rocker shoe applied on an upright foot trimmed to match the mechanics of the shoe will provide a good possibility to obtain a uniformly distributed blood perfusion to the sole, which will promote even sole growth and protect the foot from negative biomechanical forces that can affect its health. The goals of this application are to obtain the desirable benefits of a 0 capsular PA while maintaining a positive ground PA and to place the belly or support of the shoe underneath the center of rotation with the breakover point underneath the apex of P3. Upon achieving these parameters, it has been noted that the horses can adjust their PA to one where they seem to be comfortable and decrease the pulling forces of the DDFT (Figs. 6 and 7). The author has yet to experience considerable problems related to instability of the foot and rocking back during the stance phase of the stride with this application, and the consensus among several clinicians consulted, who have vast experience with the use of this approach, is the same. It has also been described as advantageous for the performance of sport horses, but correct timing and application

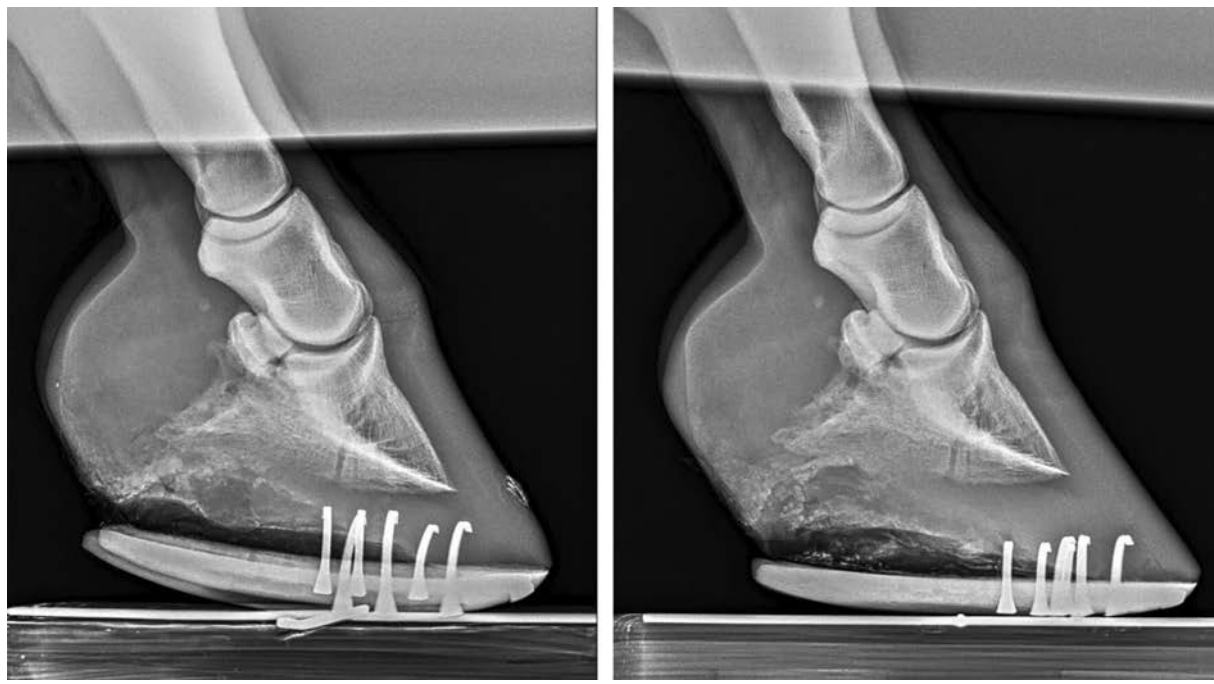

Fig. 8. Even when the shoe lost some of its mechanics (banana shape) due to the load received during the shoeing cycle and to the annealing of the aluminum (tendency of a metal to lose its hardness after being heated), a robust, even foot growth was obtained without prompting the distortion typical of a club foot.

seem to be vital. Monitoring the precision in which the desired parameters are achieved through radiological control with pre-, intra-, and postshoeing radiographs is of great value to set things up for the desired outcome, while being able to provide radiological follow up throughout several shoeing cycles is the best way of knowing if these efforts are proving to be successful or not, and to have the opportunity to make the necessary adjustments in a timely manner (Fig. 8).

4. Discussion

Although the use of the rocker or banana shoe is not a new therapeutic shoeing technique, in the latter years, it has been more regularly used by a greater number of clinicians who have found value in it. For those familiar with the procedure, it has proven to be a very valuable tool to manage upright or low-grade club feet, as it appears to give a greater biomechanical advantage when compared to other approaches that have been described. With the use of this technique, long-term maintenance and soundness has been provided to many horses and is believed to be something that should be more widely considered in regular practice. The cons to this approach are that it requires a certain degree of skill in its application and it is somewhat out of the ordinary, which may lead to some skepticism by those who do not fully understand the principles behind it and who have not experienced its benefits firsthand. Also, on many occasions, the use of radiographs as part of the process is important to check if the application is providing the parameters required to obtain the desired results. Nonetheless, once a certain level of skill and familiarity has been achieved, the use of this technique with low-grade mechanics is not radiographically dependent. In the majority of cases, this therapeutic approach may need to be utilized for the rest of the patient's life, as the club foot is not a condition that will normally resolve.

Acknowledgments

Declaration of Ethics

The Author has adhered to the Principles of Veterinary Medical Ethics of the AVMA.

Conflict of Interest

The Author has no conflicts of interest.

References

1. O'Grady SE, Parks AH, Redden RF. A glossary of therapeutic farriery terms. *Equine Vet Educ* 2007;19:263–271.
2. Redden RF. The interconnectedness of suspension and support. *Equine Podiatry Principles* 2021, pp 24–28.
3. O'Grady SE, Dryden VC. Farriery for the horse with the high heel or club foot. *Vet Clin North Am Equine Pract*. 2012;28(2):365–380.
4. Hobbs SJ, Nauwelaerts S, Sinclair J. Sagittal plane fore hoof unevenness is associated with fore and hindlimb asymmetrical force vectors in the sagittal and frontal planes. *PLoS One* 2018;13(8):e0203134.
5. Hunt RJ. Management of clubfoot in horses: Foal to adult, in *Proceedings*. Am Assoc Equine Pract 2012;58:157–163.
6. O'Grady. How to manage the club foot-birth to maturity, in *Proceedings*. Am Assoc Equine Pract 2014;60:62–72.

7. Redden RF. Hoof capsule distortion: Understanding the mechanisms as a basis for rational management. *Vet Clin of North Am*: W.B. Saunders, Philadelphia 2003;19:443–463.
8. Redden RF. How to identify, classify, and manage club feet: Understanding the mechanisms as a basis for rational management, classify and manage club feet. *Equine Podiatry Principles & Mechanical Concepts*. 2015;22–28.
9. Kentucky Equine Research. Equinews. *Club Foot Conformation in Horses*, in *Proceedings* 2015;18:127–132.
10. O'Grady Farriery for the club foot. *The Natural Angle*. 2022;15(3). https://www.equipodiatry.com/news/articles/farrieryfortheclubfoothtml.
11. Merriam JG. The role and importance of farriery in equine veterinary practice. *Vet Clin North Am*, WB Saunders, Philadelphia. 2003;19:443–463.
12. Floyd M. Equine podiatry. In: *Managing Common Problems: Mismatched and Club Feet*. Saunders Elsevier, St. Louis, MO 2007:398–399.
13. Penttila K. Recognizing and managing the club foot in horses. *Can Horse J* 2021. https://www.horsejournals.com/horse-care/hoof-care/recognizing-and-managing-club-foot-horses.
14. Redden RF. Rockering a rail shoe. *YouTube video, Case 13*. 2011. https://www.youtube.com/watch?v=N0PVP45z32Q.

The Ridden Horse Pain Ethogram and the Performance of Sports Horse: A Review

Sue Dyson, VetMB, PhD

There is a relationship between Ridden Horse Pain Ethogram (RHpE) scores and performance in event horses, from novice to elite levels, and in elite and sub-elite Grand Prix dressage horses. Use of the RHpE should facilitate earlier identification of horses that may benefit from diagnosis and treatment, potentially resulting in improvement in both performance and equine welfare. Author's address: The Cottage, Church Road, Market Weston, Diss, IP22 2NX, UK; e-mail: sue.dyson@aol.com. © 2022 AAEP.

1. Introduction

The welfare of horses engaged in equestrian sport is currently in the spotlight after the Tokyo Olympics and the subsequent dropping of riding from the Olympic modern pentathlon;[1] the debate about 3 or 4 in an Olympic team, in particular for showjumping and eventing;[2] the recent unsuccessful litigation by People for the Ethical Treatment of Animals (PETA) against a Dutch dressage rider for excessive use of rollkur (hyperflexion of the neck);[3] the Fédération Equestre Internationale's (FEI) suspension of a Brazilian dressage rider for abusing his daughter's pony;[4] the FEI's suspension of an American showjumper for the use of electric spurs;[5] the rapping allegations against a German showjumper;[6] and the suspension of a trainer, former world class event rider, by the British Horseracing Authority for beating a horse during a cross-country training session.[7] There has never been a greater need for the equine industry to act proactively to protect the future of equestrian sports.

The Ridden Horse Pain Ethogram (RHpE) was developed as a tool to facilitate the identification of musculoskeletal pain in ridden sports horses (dressage, showjumping, and eventing) when performing dressage-type movements.[8] It comprises 24 behaviors (Table 1), the majority of which are at least 10 times more likely to be seen in a horse with musculoskeletal pain than in a nonlame horse. The median RHpE score of nonlame horses was 2/24 (range = 0–6), whereas lame horses had a median RHpE score of 9/24 (range = 4–14).[8] An RHpE score of $\geq$ 8/24 indicates the presence of musculoskeletal pain, although some lame horses have an RHpE score $<$ 8/24.[8–11] The substantial reduction in RHpE scores observed after abolition of lameness using diagnostic anesthesia indicates a causal relationship between these behaviors and pain.[9,12] Other factors with a positive association with the RHpE score are tight tree points of the saddle compared with a correctly fitting saddle,[11] the rider sitting on the caudal one third of the saddle rather than in the middle of the saddle,[11] and rider weight as a proportion of the horse's body weight.[13] For accurate application and interpretation of the RHpE, horses should be evaluated working for 5 to 10 minutes after appropriate warm-up.[8,14] The horse

NOTES

Table 1. The Ridden Horse Pain Ethogram

Behavior	Tick if Present	Comments
1. Repeated changes of head position (up/down) not in rhythm with the trot		
2. Head tilted or tilting repeatedly		
3. Head in front of vertical (> 30°) for ≥ 10 s		
4. Head behind vertical for (> 10°) ≥ 10 s		
5. Head position changes regularly, tossed or twisted from side to side, corrected constantly		
6. Ears rotated back behind vertical or flat (both or one only) ≥ 5 s; repeatedly lay flat		
7. Eyelids closed or half closed for 2–5 s; repeated rapid blinking		
8. Sclera exposed repeatedly		
9. Intense stare (glazed expression, "zone out") for ≥ 5 s		
10. Mouth opening ± shutting repeatedly with separation of teeth for ≥ 10 s		
11. Tongue exposed, protruding or hanging out, and/or moving in and out > once		
12. Bit pulled through the mouth on one side (left or right) repeatedly		
13. Tail clamped tightly to middle or held to one side		
14. Tail swishing large movements: repeatedly up and down/side to side/circular; during transitions		
15. A rushed gait (frequency of trot steps > 40/15 s); irregular rhythm in trot or canter; repeated changes of speed in trot or canter		
16. Gait too slow (frequency of trot steps < 35/15 s); passage-like trot		
17. Hindlimbs do not follow tracks of forelimbs but deviated to left or right; on 3 tracks in trot or canter		
18. Canter repeated leg changes: repeated strike off wrong leg; change of leg in front and/or behind (disunited)		
19. Spontaneous changes of gait (e.g., breaks from canter to trot or trot to canter) > once		
20. Stumbles or trips repeatedly; repeated bilateral hindlimb toe drag		
21. Sudden change of direction, against rider direction; spooking		
22. Reluctant to move forward (has to be kicked ± verbal encouragement), stops spontaneously		
23. Rearing (both forelimbs off the ground)		
24. Bucking or kicking backwards (one or both hindlimbs)		

Horses are evaluated performing their full repertoire of movements over a period of 5 to 10 minutes, and the presence of any behavior fulfilling each of the definitions is recorded. It may also be useful to add comments such as tail swishing only occurred in synchrony with spur cues or increased head behind vertical in canter. In addition, comments about gaits provide further information, such as lame right fore 2/8 in right half-pass or canter lacks suspension.

should perform walk, trot, and canter around the periphery of the arena and in circles of 20 m and 10 m diameter to include repeated transitions and the horse's full repertoire of work (for example, canter pirouettes for a Grand Prix dressage horse).[14]

A trained observer demonstrated excellent repeatability of the application of the RHpE when assessing video recordings of 9 anonymized horses evaluated in random order on two occasions.[8] Excellent agreement was achieved when a different trained observer

applied the RHpE to 20 horses in real time or by assessment of video recordings.[15] Nontrained observers ($n = 10$) of different professional backgrounds were able to differentiate between nonlame and lame horses based on application of the RHpE to video recordings.[12] Equine veterinarians ($n = 10$) of variable experience were, after preliminary video-based training, able to differentiate between horses with low-grade lameness and nonlame horses assessed in real time using the RHpE.[15] When comparing the 10 equine veterinarians and an experienced observer, there was also excellent consistency in overall agreement for total RHpE scores among raters (intraclass correlation coefficient = 0.97, $p < 0.001$), and for exact agreement between individual observers, there was good to moderate agreement (intraclass correlation coefficient = 0.7, $p < 0.001$).

Rider skill cannot mask the behavioral signs of musculoskeletal pain.[16] Forty horses were ridden by the normal rider of each horse and a single skilled professional rider in random order, performing a standardized dressage-type test of 8.5 minutes' duration. Rider skill altered gait quality, with overall higher gait quality scores for the professional rider. The professional rider had a variable influence on the presence or absence of lameness and gait abnormalities in canter. However, there was no significant difference in the mean RHpE scores when ridden by the normal rider compared with the professional rider, although there were some differences in the behaviors exhibited by the horses.

Studies in Denmark, Sweden, Switzerland, and the United Kingdom have shown that at least 50% of the sports horse and leisure horse populations show lameness ± abnormalities of canter, especially when ridden.[17–20] The welfare of sports horses is under increasing scrutiny as the social license to compete with horses is debated widely.[21–25] Several studies have investigated the relationship between RHpE scores and the performance of sports horses.[26–30] The aim of this review is to summarize these studies and to comment on their clinical relevance to the sports horse veterinary practitioner, who is the ultimate guardian of sports horse welfare.

2. 5-Star 3-Day Events

Pilot data were acquired at the Burghley Concours Complet Internationale (CCI) 4-star (now 5-star) event in 2018.[26] A convenience sample of 35 horses, competing in consecutive order on the second day of dressage, were each assessed for a minimum of 10 minutes during trot and canter in the late stages of warm-up. The RHpE was applied by a trained observer. Cross-country performance was obtained from the competition website; horses were classified as completing, eliminated, or retired. The median RHpE score for 27 nonlame horses was 2/24 (interquartile range [IQR] = 0–3; range = 0–4). The median RHpE score for 8 horses with gait abnormalities (lameness or abnormalities of canter) was 7.5/24 (IQR = 4–8; range = 3–9). The RHpE score was ≥ 8/24 in only 4 horses. Thirty-four horses started cross-country, of which 35% were eliminated or retired. The proportion of horses failing to complete was significantly higher for those with RHpE scores ≥ 7/24 compared with scores < 7/24. Of 28 horses with an RHpE score < 7/24, 8 (29%) were eliminated or retired. Of 6 horses with an RHpE score ≥ 7/24, 4 (67%) were eliminated or retired.

The pilot study highlighted that in a cohort of highly trained event horses competing at 5-star level, it may be useful to use a slightly lower total RHpE score as an indicator of possible influence on performance, rather than the score of ≥ 8/24, previously identified as a reliable score for differentiating sports horses competing at a variety of levels, from unaffiliated to elite, with and without musculoskeletal pain.[8,9,11,12]

Additional data were acquired for all starters ($n = 137$) warming up for the dressage phase of two CCI 5-star events (Badminton May 2019, $n = 70$; Burghley September 2019, $n = 67$).[27] Episodic, mild (≤ grade 2/8)[31] forelimb or hindlimb lameness was observed in 13.1% of starters; 20.4% showed abnormalities of canter, and 6.6% exhibited poor hindlimb engagement and impulsion. RHpE scores ranged from 0 to 9/24. Only 10/137 (7.3%) horses had an RHpE score ≥ 8/24. The median score for horses with neither lameness nor abnormalities of canter was 3/24 (range = 0–9), compared with a median score of 5/24 (range = 1–9) for horses with gait abnormalities. Horses with lameness or abnormalities of canter had a significantly higher RHpE score compared with other horses.

There was a moderate correlation between the RHpE scores for individual horses that competed at both events. The overall frequency of occurrence of each of the behaviors comprising the RHpE is summarized in Table 2. There was a moderate positive correlation between dressage penalty scores (the mean value for the 3 judges [the Ground Jury]) and the RHpE score. The proportion of horses failing to complete the cross-country phase was higher for horses with an RHpE score ≥ 7 ($n = 10/17$; 59%) compared to horses with an RHpE score < 7 ($n = 39/117$; 33%). There was a strong trend toward a higher RHpE score for horses that did not complete (median = 4) compared with those that did complete (median = 3) the cross-country phase. There was a higher RHpE score for horses that retired during the cross-country phase compared with those that completed but no difference between eliminations and retirements. There was no relationship between the RHpE score and total showjumping penalties. There was a significant weak correlation between total RHpE score and final horse placings ($n = 70$).

In conclusion, horses with higher RHpE scores had higher dressage penalties and lower overall finish places. Combining the data from the pilot study and the main study ($n = 172$), 63% of horses with an RHpE score ≥ 7/24 failed to complete cross-country,

Table 2. The Frequency of Occurrence, Expressed as a Percentage of Competition Starts, of the 24 Behaviors of the Ridden Horse Pain Ethogram at 5-Star 3-Day Events (TDE; *n* = 137), British Eventing (BE) 90, 100, and Novice 1-Day Events (ODE; *n* = 1,010), World Cup (WC) Grand Prix Dressage (*n* = 147), and Sub-Elite Grand Prix Dressage (*n* = 64)

Behavior	TDE %	BE ODE %	WC Dressage %	Sub-Elite Dressage%
Head up and down repeatedly	5.0	17.2	1.4	2.6
Repeated head tilt	**56.0**	**39.8**	20.4	20.7
Front of head ≥ 30° in front of vertical for ≥ 10 s	0	5.2	0	0
Front of head ≥ 10° behind vertical for ≥ 10 s	**64.0**	**59.3**	**66.7**	**77.2**
Repeated side to side movement of head	10.0	9.6	2.0	4.6
Ears behind vertical ≥ 5 s	19.0	**35.8**	24.5	**46.7**
Eyes closed 2–5 s; rapid blinking	0	1.3	0	0
Sclera exposed repeatedly	22.5	6.1	6.8	9.7
Intense stare ≥ 5 s	**40.0**	**46.5**	29.9	**66.1**
Mouth opening with separation of the teeth ≥ 10 s	**44.5**	28.4	**68.0**	**81.1**
Tongue out repeatedly	8.0	7.8	4.8	18.8
Bit pulled through to one side, repeatedly	4.5	15.8	0	0
Tail clamped to midline or repeatedly crooked	26.0	12.4	0.7	18.2
Repeated tail swishing not in synchrony with spur cue	**37.5**	21.0	28.6	**66.7**
Rushed gait or irregular speed	1.5	6.6	0	0
Slow gait	0	0	0	0
Repeatedly crooked, on 3 tracks	4.5	28.4	0.7	3.8
Repeated incorrect strike off in canter or repeatedly disunited	2	3.7	0	0
Spontaneous change of gait	2.5	10.3	8.8	17.5
Repeated bilateral hindlimb toe drag and/or stumbling > once	0	**37.4**	6.8	**30.5**
Not following rider's cues; spooking	1.5	2.9	2.0	4.6
Reluctant to go forward (requiring verbal encouragement or repeated kicking) or stopping spontaneously	1.5	4.0	0.7	5.9
Rearing	0	0.6	0.7	2.6
Bucking	2.5	2.0	0.7	3.3

Behaviors observed in more than 30% of competition starts are in bold.

compared with 31% with a score < 7/24. This suggests that musculoskeletal pain may be a contributory factor for elimination (because of a horse or rider fall, 4 cumulative refusals, or 3 refusals at a single fence) or retirement in the cross-country phase.

3. British Eventing 90, 100, and Novice 1-Day Events

British Eventing (BE) 1-day events comprise dressage, showjumping, and cross-country phases, with the maximum height of cross-country fences being 0.90 m, 1.0 m, and 1.10 m for BE 90, 100, and Novice classes, respectively. The RHpE was applied by a single trained observer to 1010 competition starters (841 horses and 708 riders) during the dressage phase at a convenience sample of BE 90 ($n = 204$ starters), BE 100 ($n = 450$ starters), and Novice ($n = 356$ starters) 1-day events in 2021 and compared with performance.[28] BE 90 competitors were exclusively amateur riders, including a small proportion of children ≥ 12 years of age, whereas BE 100 and Novice participants were amateur or professional riders, including Olympic, World, and European Championships competitors.

Overall, there was a low frequency of occurrence of overt lameness (8.6%) of variable degree (≤ grade 4/8),[31] but poor hindlimb impulsion and engagement were observed in 38.1% of competition starts, and canter was abnormal in the majority (61.0%). The overall median RHpE score was 4/24 (IQR = 2–6; range = 0–12). The median RHpE score was higher (5/24; IQR = 3–7; range = 0–12) for BE 90 competitors, compared with BE 100 (median = 4/24; IQR = 2–5; range = 0–12) and Novice (median = 3.5/24; IQR = 2–5; range = 0–11). There were significant differences in the total RHpE scores between BE 90 and both BE 100 ($p < 0.001$) and Novice ($p < 0.001$) levels but not between BE 100 and Novice levels. This was associated with a higher frequency of forelimb lameness (16.7%), hindlimb lameness (15.7%), abnormal canter (75.0%), lack of hindlimb engagement and impulsion (48.0%), and stumbling (12.9%) in BE 90 starters compared with BE 100 and Novice. The frequency of occurrence of each behavior of the RHpE is summarized in Table 1.

There were moderate positive correlations between RHpE scores and dressage penalty scores. There were weak positive correlations between RHpE scores and final placings. In showjumping, 1.7% of starters were eliminated or retired, compared with 9.8% of cross-country starters. Horse or rider falls occurred in 2.6% of cross-country starts. Horses placed first, second, or third in each section had lower RHpE scores (median = 2/24, IQR = 1–4; range = 0–8) than other horses that finished (median = 4/24; IQR = 2–6; range =

0–12; $p < 0.001$). The RHpE score was ≥ 8/24 for 9.4% of competition starts; of horses that completed, horses with an RHpE score ≥ 8 had significantly higher total penalty scores (median = 47.8, IQR = 40.2–62.0; range = 31.8–116.8) than horses with an RHpE score < 8 (median = 41.1, IQR = 34.8–53.5; range = 20.5–170.5; $p < 0.001$).

There was a significant difference ($p = 0.01$) in the proportion of horses with an RHpE score ≥ 8/24 according to finish status. The proportion of horses placed first to third with an RHpE score ≥ 8 was lowest (2%), followed by those with lower finish placings (9.9%), and was highest for those that failed to complete (11.3%). It was concluded that RHpE scores were associated with dressage and cross-country performances and with final placings for horses that completed at each level of competition, despite variability in rider skill levels. RHpE scores were higher at BE 90 level compared with BE 100 and Novice in association with a higher frequency of occurrence of gait abnormalities.

4. Grand Prix Dressage Competitions

World Cup Grand Prix Dressage

The aim of the first study was to apply the RHpE to elite dressage horses competing at World Cup Grand Prix qualifying competitions ($n = 7$) or finals ($n = 2$) from 2018 to 2020.[29] It was hypothesized that this should be a group of horses with a low incidence of musculoskeletal pain and thus RHpE scores would be consistently < 8/24. Additional objectives were to compare RHpE scores with judges' percentage scores (the mean score for 5 judges at qualifying competitions and 7 judges at finals) and to compare these and other observations concerning gait with the guidelines for judging FEI dressage.[32] The RHpE was applied by a trained observer to video recordings of 150 competitors at 9 venues. Freehand notes described additional observations.

Three horses were eliminated because of forelimb lameness ($n = 1$) or blood in the mouth ($n = 2$). Of 147 competitors that completed the test, transient mild (≤ grade 2/8)[31] forelimb lameness was seen in 14 (9.5%) in extended trot, half-pass, or passage; 17 competitors (11.6%) showed unilateral or bilateral hindlimb toe drag in passage or extended trot. Nine competitors (6.1%) exhibited variable spatial and temporal separation of the hindlimbs in sequence flying changes. The median RHpE score for completed tests was 3 (IQR = 1–4; range = 0–7). There was a moderate negative correlation between the RHpE scores and the judges' percentage scores. The median RHpE score for the top ranked 5 competitors at each venue was 2 (range = 0–6), compared with the overall median score of 3 (range = 0–7). Mouth open with separation of the teeth for ≥ 10 seconds (68%), head behind vertical ≥ 10° for ≥ 10 seconds (67%), an intense stare for ≥ 5 seconds (30%), and repeated tail swishing (29%) were the most frequent RHpE behaviors (Table 2).

Deviations from FEI guidelines were most frequent in passage, piaffe, canter flying changes, canter pirouettes, and "halt-immobility-rein back 5 steps-collected trot." The majority of competitors (61.9%, $n = 91$) showed gait abnormalities in passage and/or piaffe. The most frequent modification of passage was the almost simultaneous placement of the hindlimbs to the ground. There were numerous variable modifications of piaffe as horses attempted to redistribute load. Canter flying changes (one time and/or two times) were incorrect, characterized by swinging excessively from side to side, missed changes, being croup high, or repeated close temporal and spatial placement of the hindlimbs in 30 competitors (20.4%). Canter pirouettes were abnormal in 18 competitors (12.2%), usually characterized by close temporal placement of the hindlimbs and often associated with the head being considerably behind a vertical position. The most frequent errors in "halt-immobility-rein back 5 steps-collected trot" were halt not at marker ($n = 25$; 17.1%), halt not square ($n = 52$; 35.6%), rein back mouth open with separation of the teeth ($n = 48$; 32.9%), rein back head behind vertical ≥ 10° ($n = 92$; 63.0%), and rein back incorrect number of steps ($n = 34$; 23.3%).

International and National Grand Prix Dressage

The aim of the second study was to apply the RHpE to a broader range of Grand Prix dressage horses than those elite horses qualified to compete at FEI World Cup competitions and to compare RHpE scores with performance.[30] It was hypothesized that the median RHpE scores and range would be higher than those documented for horses competing in FEI World Cup competitions. The RHpE was applied to video recordings of Grand Prix dressage tests at an international event for invited riders (Event A, $n = 38$) and the British Dressage Grand Prix National Championships (Event B, $n = 26$) in 2020. The frequency of gait abnormalities in trot and canter, each of the 24 behaviors of the RHpE, and the correctness of movements according to FEI Guidelines were compared between World Cup competitors and competitors at Events A and B.

The median RHpE scores were 4 (IQR = 3–6; range = 0–8) and 6 (IQR = 4–7; range = 1–9), for Events A and B, respectively, both higher ($p = 0.0011$ and $p = 0.0000$) than World Cup competitors' scores. Median RHpE scores were also higher in horses competing at Event B compared with Event A ($p = 0.0267$). Ears back ≥ 5 seconds ($p = 0.005$), intense stare ≥ 5 seconds ($p = 0.000$), repeated tail swishing ($p = 0.000$), repeated bilateral hindlimb toe drag ($p = 0.000$), repeated tongue out ($p = 0.003$), and crooked tail carriage ($p = 0.000$) occurred more frequently at Events A and B compared with World Cup competitions (Table 2). This was associated with a higher frequency of lameness (forelimb lameness 7.8%, hindlimb lameness 42.2%) and abnormalities of canter (26.6%) at Events A and B compared with World Cup competitors ($p < 0.001$). There were also more frequent errors in canter flying changes ($p = 0.002$), canter pirouettes ($p = 0.009$), and passage and piaffe ($p = 0.108$) at

Table 3. Summary of Ridden Horse Pain Ethogram (RHpE) Scores for Horses Competing at 5-Star 3-Day Events (TDE), British Eventing (BE) 90, 100, and Novice 1-Day Events, World Cup Grand Prix Dressage, International Grand Prix Dressage, and National Grand Prix Dressage

		RHpE Score, 0–24			
		Nonlame	Abnormal Trot and/or Canter		
Competition	Number of Starters	Median	Range	Median	Range
Pilot study TDE	35	2	0–4	7.5	3–9
Main study TDE	137	3	0–9	5	1–9
		Median	Range		
BE 90	204	5	0–12		
BE 100	450	4	0–12		
BE Novice	356	3.5	0–11		
World Cup dressage	147	3	0–7		
International dressage	38	4	0–8		
National dressage	26	6	1–9		

Events A and B compared with World Cup competitors. The median number of errors in rein back was similar for Events A and B and World Cup competitors; however, there was a significantly higher frequency of occurrence of 3 errors (lack of diagonal steps [$p = 0.028$], mouth open in rein back [$p = 0.004$], and crooked in rein back [$p = 0.027$]) at Events A and B compared with World Cup competitors.

There was no official judging at Event A. At Event B, there was a moderate negative correlation between the mean of the 5 dressage judges' percentage scores and the RHpE scores.

It was concluded that in elite and sub-elite Grand Prix dressage competitions, there is an association between RHpE scores and performance, with higher RHpE scores correlated with lower percentage marks. The RHpE scores were higher for the sub-elite horses compared with the elite horses associated with a higher frequency of occurrence of gait abnormalities.

5. Discussion

At upper-level international 3-day events and Grand Prix dressage and at lower levels of competition, there were significant associations between RHpE scores and performance.

The median RHpE scores were lowest, with a smaller score range at the highest level of competition, particularly for those horses that showed no evidence of musculoskeletal discomfort (Table 3). At lower levels of competition, there was a higher frequency of occurrence of lameness and/or abnormalities of canter compared with the elite dressage and event horses. At elite levels of both dressage and eventing, the lameness that was observed was low grade ($\leq$ 2/8)[31] and intermittent, often only being observed in more biomechanically demanding movements (e.g., half-pass). However, in lower-level eventing, particularly at BE 90 level, lameness was often more consistently apparent and more severe ($\leq$ 4/8).[31] Although judges at any level can advise that a horse is withdrawn or undergoes veterinary inspection at a 1-day or 3-day event before being allowed to start the cross-country phase, in practice, this infrequently occurs. Such inspections can be misleading because at such assessments, horses are only evaluated moving in hand, and a large proportion of horses that appear lame when ridden do not show lameness in hand.[11,17]

The rules and their interpretation vary somewhat between disciplines. For FEI dressage competitions, the judge at C (usually the President of the Ground Jury) can eliminate a horse showing "marked" lameness, and no appeal is allowed.[33] Under FEI rules for 3-day events, "The Ground Jury, in consultation with the Veterinary Delegate, has the right and the duty to eliminate any Horse which, in their opinion, is lame or is unfit to continue. … Riding a lame horse constitutes abuse."[34] Under BE rules, "If the judge considers the horse to be markedly lame he should stop the test and consult with the BE Steward and the Veterinary Officer. At the discretion of the BE Steward following such consultation, the combination may be eliminated or allowed to complete the test and any unevenness of pace penalised appropriately."[35]

The median RHpE scores across disciplines and levels of competition provide evidence that many horses are competing comfortably, and thus, in general, these studies support the social license for the use of sports horses in competition. This is of increasing importance, highlighted by recent litigation in which a high-profile European dressage rider was unsuccessfully accused of horse abuse by PETA[3] and by a call for equestrian sports to be removed from the Olympic Games.[36] However, the current studies do demonstrate that clearly a proportion of horses are competing despite musculoskeletal discomfort, and there are cogent arguments for appropriate clinical investigation to determine the source(s) of pain and to develop both treatment and management plans. Reduction in pain may result in improvement in both performance and equine welfare. There are many potential causal factors of discomfort including primary musculoskeletal pain, pain induced by the tack, the rider's weight distribution, and the way cues are applied by a rider. The reason(s) in any particular horse could only be determined by careful clinical assessment by a group of suitably qualified professionals. However, this requires that the presence of a potential problem is recognized by the team producing the horse and that appropriate advice is sought. Further education of

Fig. 1. A, A British Eventing Novice competitor in rising trot. The Ridden Horse Pain Ethogram score was 4/24. The head was behind the vertical ≥ 10° throughout the test. The lips are separated, but the mouth is not open with separation of the teeth. Note the extension of the lumbosacral region and the low height of arc of foot flight of the right hindlimb. The horse finished sixth. B, The same horse as in panel A in left canter. The head is behind the vertical ≥ 10° and is further behind the vertical than in trot. Note the degree of extension of the left metatarsophalangeal joint, the leading hindlimb, in the midstance phase. Breakover of the trailing right hindlimb is not yet complete, but the leading left forelimb is about to make ground contact. There was not a period of suspension. C, British Eventing 100 competitor (Olympic and World Championships rider) in rising trot. The Ridden Horse Pain Ethogram score was 1/24. The head was behind the vertical ≥ 10° throughout the test. The ears are rotated outward but are not behind a vertical position. Note the extension of the lumbosacral region and poor development of the lumbar epaxial muscles relative to the dorsal neck muscles. The horse finished in first place. D, The same horse as in panel C, in left canter. The head is considerably further behind a vertical position compared with trot. The horse is on the forehand and croup high.

riders, trainers, coaches, and owners is required to ensure that they are aware that so-called training or behavioral problems are frequently pain induced. Regular assessments of horses ridden through their full repertoire of movements, by veterinarians who understand the demands of the sports discipline in which the horse competes, are recommended as part of a routine health program. The evaluation of the quality of the gaits and transitions, combined with application of the RHpE, may facilitate earlier detection of problems. It is important to recognize that abnormalities of canter are often pain related, despite the absence of overt lameness.[37,38]

The overall performance of both event horses and dressage horses reflects their training, how they are presented by their riders, rider strength, the method of application of cues, fitness, neuromuscular coordination, misinterpretation of cues by the horse, external stressors, and freedom from discomfort. Given the high frequency of occurrence of the head being behind a vertical position ≥ 10° throughout a large proportion of the test in horses competing in both dressage and eventing (Table 2; Figs. 1A–D), irrespective of level, it seems likely that this to some extent reflects training, but it does not necessarily indicate the practice of rollkur.[39] The biomechanical effects of the head positioned 10° to 20° behind the vertical on the long-term function of the rest of the body and musculoskeletal health have not been investigated scientifically, but there are persuasive arguments against it based on repeated clinical observations.[40–42] This head and neck position is likely to compromise engagement of the muscles of the thoracic sling and the abdominal "core" muscles and to limit movement of the thoracolumbosacral region and hindlimb impulsion and engagement. These are all factors that may predispose to the development of musculoskeletal discomfort. Improved awareness among riders, trainers, and veterinarians about how training methods can influence movement patterns, muscle development, and risk of injury is required.

However, the higher frequency of occurrence of "head behind vertical" in sub-elite dressage horses, compared with elite dressage horses, that was associated with a higher frequency of pain-related gait abnormalities indicates a likely role of pain in some horses. This is also supported by the observation that "head behind vertical" increased in movements that required a greater degree of collection, compared with less demanding movements, and was often associated with other behaviors of the RHpE (Fig. 2).[27,29,30]

Fig. 2. A 5-star 3-day event competitor exhibiting head behind the vertical ≥ 10°, an intense stare, and mouth opening with separation of the teeth. Note the reduced rein tension. The Ridden Horse Pain Ethogram score was 6/24. The horse was withdrawn at the final horse inspection.

The FEI states that "the objective of dressage is the development of the horse into a happy athlete through harmonious education" (FEI rules).[33] Repeated tail swishing, mouth opening with separation of the teeth for ≥ 10 seconds, and the head behind a vertical position ≥ 10° for ≥ 10 seconds were frequent observations at all levels, with tail swishing and mouth opening occurring most frequently in Grand Prix dressage horses and 3-day event horses. Despite these behaviors being clear contraventions of the aims of dressage, horses displaying such behaviors were frequently awarded average marks of 6/10 (satisfactory) or 7/10 (fairly good).[33] Further education of dressage judges is required to raise awareness of these and other behaviors and their potential significance. Tail swishing that occurred only in synchrony with spur cues applied to Grand Prix dressage horses was not included as a positive RHpE behavior but was observed in 36% of competitors at elite level.[29]

There is considerable current debate about the types of nosebands used in competition and the way in which they are fitted, including tightness, their contribution to oral pain, and the ability or otherwise of nosebands to limit mouth opening, and this is discussed elsewhere.[28,29] The veterinary profession needs to be aware of these issues but more importantly needs to address the question of why there is such a high frequency of occurrence of mouth opening in sports horses, most particularly in Grand Prix dressage horses. Mouth opening may be related to oral lesions,[43,44] the size and type of the bit relative to the shape and size of the horse's oral cavity and tongue,[45,46] movement of the rider's hands,[47] or excessive rein tension[48,49] or may be a nonspecific response to musculoskeletal pain.[8,9]

There are many factors that may influence cross-country jumping performance, including the difficulty of the course, the terrain, the footing, the weather conditions, the skill, fitness, and strength of the rider, the athletic ability of the horse and its experience, fitness and freedom from pain, and also the horse's training to follow the rider's cues.[25] The eventing studies from all levels indicate that musculoskeletal pain may be influential in the performance of some horses given the association between RHpE scores and failure to complete the cross-country phase.[26–28] Veterinarians need to advise riders that suboptimal performance may reflect discomfort. Nonetheless, it is acknowledged that the influence of endorphins and adrenaline may allow a horse to jump satisfactorily despite musculoskeletal pain,[50,51] particularly if the size of the fences is well within the horse's athletic capabilities. It is also the role of a veterinarian to advise a client that the ability of a horse to jump well, despite performing poorly in dressage-type work, does not preclude the presence of musculoskeletal pain.

These studies provide evidence that there is a relationship between reduced performance and musculoskeletal pain. Therefore, if veterinarians are performing regular clinical assessments of clients' horses, it may also be worthwhile to review the recent performance record together with the rider and trainer and compare it with previous performances. A reduction in performance may be indicative of an underlying problem, the cause of which needs identifying. The importance of the quality of previous performances has also been highlighted by the introduction of the EquiRating's Horse Form Index, developed in conjunction with the FEI.[52] At CCI 3-star to 5-star levels of eventing, it has been shown that recent previous cross-country jumping performances can be used to predict the likelihood of a future cross-country performance without jumping penalties.

The reviewed studies had some limitations. The RHpE was applied by single observer who could not be blinded to horse and rider identity, and therefore there was the potential for bias. Moreover, the observer could not be blinded to the presence or absence of gait abnormalities. However, the performances of horses could not be predicted, and all statistical analyses were performed completely independently and involved large data sets, including all competitors at individual competitions, supporting the validity of the results. The circumstances under which horses were evaluated were variable. The 3-day event horses were assessed during warm-up for the dressage phase and were therefore not performing a set pattern of movements, at specific markers, within the confines of an arena. However, the majority of riders performed most of the movements included in the test. The event horse studies were performed in real time, whereas the Grand Prix dressage horses were assessed using video recordings. A good correlation between RHpE scores for the same horses assessed in real time and in video recordings acquired from the same perspective was previously observed.[15] When dressage tests were assessed in real time, the observer was restricted to a single position relative to the arena, within 1 to 3 m of the MC corner,[28] whereas ideally horses should also be assessed from a different perspective (e.g., the HC corner).[14] The video recordings of the dressage

horses were acquired in a standardized way for commercial release, and this also resulted in an inability to view horses from all perspectives. However, within each study, all horses were assessed similarly. The event horse studies were performed in variable weather conditions, and strong wind, if present, prevented accurate determination of tail position. The footing was variable for the 1-day event study, and long grass prevented evaluation of hindlimb toe drag at some venues. A behavior was only determined to have occurred if it was unequivocally present.

Excessive white "froth" around the lips prevented assessment of mouth opening with separation of the teeth in a small proportion of World Cup Grand Prix dressage horses. The FEI has since banned the use of "any type of white substance around the horse's mouth to imitate foaming (like 'marshmallow fluff,' shaving cream, etc.); this is considered cheating and against horse welfare as it can hide lip injuries."[33] The reason for the change of rule seems odd because small amounts of blood are highlighted by white froth; however, the rule should make it easier for a judge to assess "the acceptance of the bit, without any tension or resistance."[32,33]

There were additional lessons from some observations made in these studies that may be of benefit to riders and the performance of their horses. In the warm-up for the dressage phase at 3-day events, it was noted that some riders of horses that appeared uncomfortable in canter repeatedly performed flying changes that progressively deteriorated in quality, probably reflecting increasing musculoskeletal discomfort and in some instances the development of conflict behavior.[53] The warm-up at this level is not a place for training, and it seems preferable to avoid movements that are likely to cause or enhance discomfort. When developing treatment and management plans for horses with underlying musculoskeletal problems, veterinarians could become more involved in planning warm-up strategies in association with the rider and trainer. Rein back was performed poorly at all levels, which is likely to reflect either conflict behavior or poor or inadequate training, which could be improved, with resultant increase in marks. Inaccuracies in test riding (for example, a halt not at the prescribed marker) had the potential to lose marks unnecessarily.

The relationship between quality of competition performance and RHpE scores highlights the value of ridden exercise when assessing a horse's musculoskeletal health. This applies not only to routine veterinary assessments but also to prepurchase examinations. Application of the RHpE may highlight the likely presence of underlying problems that may become amplified by a change in management and training.

6. Conclusions

These studies indicate a relationship between RHpE scores and performance and illustrate how knowledge of the RHpE and its application are potentially valuable for a sports horse veterinarian. These studies can be used to raise awareness among riders and trainers about the influence of musculoskeletal pain on performance. Through regular monitoring of horses during ridden exercise, using the RHpE and critically evaluating gaits, early interventions may result in increased performance and potentially increase the competitive longevity of sports horses. These studies provide equine veterinarians with some objective evidence to counter the claims of those who suggest that horse sports are cruel and to proactively protect the social license to compete.

Acknowledgments

Thanks to Jeannine Berger, Anne Bondi, Andrea Ellis, Claire Martin, Jessica Mullard, Danica Pollard, Laura Quiney, Jenny Routh, Katy Thomson, and Jan Van Dijk who contributed to the Ridden Horse Pain Ethogram studies that are cited.

Funding Source

World Horse Welfare provided financial support for some of the Ridden Horse Pain Ethogram studies cited in this review.

Declaration of Ethics

The sports horse studies were approved by either the Clinical Ethical Review Committee of the Animal Health Trust or the Ethics Review Panel of the Royal College of Veterinary Surgeons and complied with the Principles of Veterinary Medical Ethics of the AVMA.

Conflict of Interest

The Author has no conflicts of interest.

References

1. Houston M. Removal of riding from modern pentathlon approved at UIPM Congress despite CAS appeal. Inside the Games. November 27, 2021. Available from: https://www.insidethegames.biz/articles/1116039/uipm-congress-2021. Accessed February 21, 2022.
2. https://www.kilcradinsolicitors.com/2021/10/equestrian-olympics-teams-of-three-to-be-retained-despite-objections/ANNEX_15.3_GA2021_PARIS2024OLYMPICQUALIFICATIONsystem. Accessed February 21, 2022.
3. Eurodressage. PETA loses lawsuit against Edward Gal for animal cruelty. December 31, 2021. Available from: https://www.eurodressage.com/2021/12/31/peta-loses-lawsuit-against-edward-gal-animal-cruelty. Accessed January 10, 2022.
4. https:/insideFEI.org/system/files/20210419FINALDECISIONCase2020HA01–FEIvLAparecidoDaSilvaC20-0059_. Accessed February 21, 2022.
5. Fédération Equestre Internationale. FEI Tribunal imposes 10-year suspension on US Jumping athlete. April 22, 2021. Available from: https://inside.fei.org/media-updates/fei-tribunal-imposes-10-year-suspension-us-jumping-athlete. Accessed February 21, 2022.
6. World of Showjumping. FEI states that training methods shown in RTL video footage are totally unacceptable from a horse welfare perspective. January 12, 2022. Available from: https://www.worldofshowjumping.com/en/News/FEI-states-that-training-methods-shown-in-RTL-video-footage-are-totally-unacceptable-from-a-horse-welfare-perspective.html. Accessed February 21, 2022.
7. British Horseracing Authority. BHA confirms interim suspension of Sir Mark Todd. February 16, 2022. Available from: https://

www.britishhorseracing.com/press_releases/bha-announces-interim-suspension-of-sir-mark-todd/. Accessed February 21, 2022.
8. Dyson S, Berger J, Ellis A, et al. Development of an ethogram for a pain scoring system in ridden horses and its application to determine the presence of musculoskeletal pain. *J Vet Behav: Clin Appl Res* 2018;23:47–57.
9. Dyson S, Berger J, Ellis A, et al. Behavioural observations and comparisons of non-lame horses and lame horses before and after resolution of lameness by diagnostic analgesia. *J Vet Behav: Clin Appl Res* 2018;26:64–70.
10. Dyson S, Pollard D. Application of a Ridden Horse Pain Ethogram and its relationship with gait in a convenience sample of 60 riding horses. *Animals* 2020;10:1044.
11. Dyson S, Bondi A, Routh J, et al. Gait abnormalities and ridden horse behaviour in a convenience sample of the United Kingdom ridden sports horse and leisure horse population. *Equine Vet Educ* 2022;34:84–95.
12. Dyson S, Van Dijk J. Application of a ridden horse ethogram to video recordings of 21 horses before and after diagnostic analgesia: Reduction in behaviour scores. *Equine Vet Educ* 2020;32:104–111.
13. Dyson S. How to assess the suitability of rider size - height, morphology, and weight - for optimal horse welfare and performance: A review, in *Proceedings*. Am Assoc Equine Pract 2021;67:223–230.
14. Dyson S. The Ridden Horse Pain Ethogram. *Equine Vet Educ*. Published online March 15, 2021.
15. Dyson S, Thomson K, Quiney L, et al. Can veterinarians reliably apply a whole horse ridden ethogram to differentiate non-lame and lame horses based on live horse assessment of behaviour? *Equine Vet Educ* 2020;32:112–120.
16. Dyson S, Martin C, Bondi A, et al. The influence of rider skill on ridden horse behaviour, assessed using the Ridden Horse Pain Ethogram, and gait quality. *Equine Vet Educ* Published online December 24, 2020.
17. Dyson S, Greve L. Subjective gait assessment of 57 sports horses in normal work: A comparison of the response to flexion tests, movement in hand, on the lunge and ridden. *J Equine Vet Sci* 2016;38:1–7.
18. Rhodin M, Roepstorff L, French A, et al. Head and pelvic movement asymmetry during lungeing in horses showing symmetrical movement on the straight. *Equine Vet J* 2016;48:315–320.
19. Dittmann M, Latif S, Hefti R, et al. Husbandry, use, and orthopedic health of horses owned by competitive and leisure riders in Switzerland. *J Equine Vet Sci* 2020;91:103107.
20. Greve L, Dyson S. The interrelationship of lameness, saddle slip and back shape in the general sports horse population. *Equine Vet J* 2014;46:687–694.
21. Campbell M. Freedoms and frameworks: How we think about the welfare of competition horses. *Equine Vet J* 2016;48:540–542.
22. Williams J, Marlin D. Foreword – Emerging issues in equestrian practice. *Comp Exerc Phys* 2020;16:1–4.
23. Campbell M. An ethical framework for the use of horses in competitive sport: Theory and function. *Animals* 2021;11:1725.
24. Furtado T, Preshaw L, Hockenhull J, et al. How happy are equine athletes? Stakeholder perceptions of equine welfare issues associated with equestrian sport. *Animals* 2021;11:3228.
25. Hogg RC, Hodgins GA. Symbiosis or sporting tool? Competition and the horse-rider relationship in elite equestrian sports. *Animals* 2021;11:1352.
26. Dyson S. Application of a ridden horse ethogram to horses competing at a 4-star three-day-event: Comparison with cross-country performance. *Equine Vet J* 2019;51:11.
27. Dyson S, Ellis A. Application of a Ridden Horse Pain Ethogram to horses competing at 5-star three-day-events: Comparison with performance. *Equine Vet Educ* 2020;34:306–315.
28. Dyson S, Pollard D. Application of the Ridden Horse Pain Ethogram to horses competing in British Eventing 90, 100 and Novice one-day events and comparison with performance. *Animals* 2022;12:590.
29. Dyson S, Pollard D. Application of the Ridden Horse Pain Ethogram to elite dressage horses competing in World Cup Grand Prix Competitions. *Animals* 2021;11:1187.
30. Dyson S, Pollard D. Application of the Ridden Horse Pain Ethogram to horses competing at the Hickstead-Rotterdam Grand Prix Challenge and the British Dressage Grand Prix National Championship 2020 and comparison with World Cup Grand Prix competitions. *Animals* 2021;11:1820.
31. Dyson S. Can lameness be reliably graded? *Equine Vet J* 2011;43:379–382.
32. Fédération Equestre Internationale. *FEI dressage handbook guidelines for judging, 9th ed*. Lausanne: FEI, 2021.
33. Fédération Equestre Internationale. *FEI dressage rules, 25th ed*. Lausanne: FEI, 2022. Available from: https://inside.fei.org/content/fei-dressage-rules-2022-0.
34. Fédération Equestre Internationale. *FEI eventing rules, 25th ed*. Lausanne: FEI, 2022. Available from: https://inside.fei.org/content/fei-eventing-rules-2022-0.
35. British Eventing. Rules and members handbook. Available from: https://issuu.com/thebrightmediaagency/docs/be-rulebook2021-digital?fr=sOWZkYTMyNTAyMTE. Accessed January 6, 2022.
36. Taylor J. *'I can't watch anymore': The case for dropping equestrian from the Olympic Games*. Copenhagen: Epona Media, 2022.
37. Barstow A, Dyson S. Clinical features and diagnosis of sacroiliac joint region pain in 296 horses: 2004 – 2014. *Equine Vet Educ* 2015;27:637–647.
38. Dyson S. Evaluation of poor performance in competition horses: A musculoskeletal perspective. Part 1 clinical assessment. *Equine Vet Educ* 2016;28:284–293.
39. van Weeren P. Rollkur, or low, deep and round: Why Winston Churchill and Albert Einstein were right. *Vet J* 2013;196:290–293.
40. Heuschmann G. *Tug of war – Classical versus 'modern' dressage*. London: J.A. Allen, 2009.
41. Heuschmann G. *Balancing act. The horse in sport – An irreconcilable conflict, 1st ed*. London: J.A. Allen, 2012.
42. Leibbrandt K. *Compassionate training for today's sport horse*. Zelhem: Het Boekenschap, 2018.
43. Tell A, Egenvall A, Lundström T, et al. The prevalence of oral ulceration in Swedish horses when ridden with bit and bridle and when unridden. *Vet J* 2008;178:405–410.
44. Mellor D. Mouth pain in horses: Physiological foundations, behavioural indices, welfare implications, and a suggested solution. *Animals* 2020;10:572.
45. Engelke E, Gasse H. An anatomical study of the rostral part of the equine oral cavity with respect to position and size of a snaffle bit. *Equine Vet Educ* 2010;15:158–163.
46. Björnsdóttir S, Frey R, Kristjansson T, et al. Bit-related lesions in Icelandic competition horses. *Acta Vet Scand* 2014;56:40.
47. Eisersiö M, Roepstorff L, Weishaupt M, et al. Movements of the horse's mouth in relation to horse–rider kinematic variables. *The Vet J* 2013;198:e33–e38.
48. Manfredi J, Rosenstein D, Lanovaz J, et al. Fluoroscopic study of oral behaviours in response to the presence to the presence of a bit and the effects of rein tension. *Comp Exerc Physiol* 2009;6:143–148.
49. Christensen J, Zharkikh T, Antoine A, et al. Rein tension acceptance in young horses in a voluntary test situation. *Equine Vet J* 2011;43:223–228.
50. Ferlazzo A, Medica P, Cravana C, et al. Circulating β-endorphin, adrenocorticotropin, and cortisol concentrations of horses before and after competitive show jumping with different fence heights. *J Equine Vet Sci* 2012;32:740–746.
51. Micalos P. Perspectives on biochemical and neurosensory mechanisms for exercise-induced pain inhibition. *Fatigue: Biomed Health Behav* 2014;2:219–230.
52. Fédération Equestre Internationale. Horse form index (HFI). Available from:https://inside.fei.org/fei/disc/eventing/risk-management/hfi. Accessed February 4, 2022.
53. Anonymous. Glossary. Advancing equine practice to improve quality of life, in *Proceedings. International Equitation Science Conference* 2021;17:104.

Rein-Lameness Associated with Inflammation of the Equine Temporomandibular Joint

Nathalie A. Reisbig, VetMed, MSc, PhD; Justin W. Pfiko, BSc; Joel L. Lanovaz, PhD; and James L. Carmalt, MA, VetMB, MVetSc, PhD, FRCVS, DABVP, DAVDC, DACVSMR, DACVS*

Inflammation of the temporomandibular joint (TMJ) may cause rein-lameness. A complete assessment of poor performance should therefore consider this joint. Authors' addresses: Department of Large Animal Clinical Sciences, Western College of Veterinary Medicine (Reisbig, Carmalt); College of Kinesiology (Pfiko, Lanovaz), University of Saskatchewan, Saskatoon SK, S7N 5B4 Canada; e-mail: james.carmalt@usask.ca. *Corresponding and presenting author. © 2022 AAEP.

1. Introduction

Rein- or bridle-lameness is a lameness which can be felt by a rider/handler, or one which is visible when the horse is being exercised under saddle or when wearing a bit and bridle. The role of TMJ inflammation on equine performance is unknown. The objectives were to determine the effect of TMJ inflammation on horse movement and rein-tension when horses long-reined on a treadmill.

2. Materials and Methods

Five horses were trained to walk and trot on a treadmill wearing long-reining equipment (with additional rein-tension devices) and 28 reflective optical tracking markers. Subjective assessment of horse movement was determined without rein-tension (free walk and trot) and when the horses were "worked into the bit" (long-reined walk and trot) and preferred side. Continuous rein-force data from both sides were collected over ~60s from each trial. Movement was recorded using a twelve-camera optical motion capture system. One randomly assigned TMJ was subsequently injected with lipopolysaccharide and the treadmill tests repeated by an investigator blinded to treatment side. A second, identical assessment was performed ten days later with the opposite TMJ being the target of intervention.

3. Results

All horses showing reduced rein-tension on the inflamed side post-injection but no effect on any kinematic variables was determined.

4. Discussion

TMJ inflammation resulted in subjective and objective changes in response to rein-input without horses being classically, visibly, lame.

Research Abstract—for more information, contact the corresponding author

NOTES

Acknowledgments

Declaration of Ethics

The Authors have adhered to the Principles of Veterinary Medical Ethics of the AVMA.

Conflict of Interest

The Authors have no conflicts of interest.

Profitability Implications of Revenue and Expenses

John A. Chalk, Jr., JD, CPA, CFP®; and Robert P. Magnus, DVM, MBA

During inflationary times, it is important to keep pace with increasing costs by adjusting fee structures while improving operational efficiency and maintaining a talented labor force. Focusing on three key expenses along with developing revenue growth is crucial to be able to monitor and proactively manage a business by keeping score. Authors' addresses: 121 Countryside Court, Suite 140, Southlake, TX 76092 (Chalk); 1025 N Morgan Road, Oconomowoc, WI 53066 (Magnus); e-mails: john@trinityportfolio.com, bmagnus@oculusinsights.net. © 2022 AAEP.

1. Introduction

There are many factors that influence practice profitability. This presentation explores the challenges of running a successful equine practice in an ever-changing market with labor shortages and inflationary times. Benchmark comparisons, market forces, cost (expense) management, pricing and fees, revenue growth, and keeping score are critical areas investigated to improve practice value and sustainability. The objective is to share real-life experiences and provide solutions using case examples illustrating the impact of market forces and the implications of practice expenses and revenue on the bottom line, profitability.

2. Discussion

Rising prices (inflation) and a tight labor market are key issues that are facing everyone. Private equity aggregation of equine practices and a changing workforce are impacting the marketplace. To be successful and sustainable, take a closer look at operational expenses, revenue streams, and how they influence the value of the business. This deep dive into the business provides solutions and tactics to improve financial health. The presentation details, case examples, and benchmark metrics in the slide deck will be provided after the presentation. The core discussion focuses on the three key items of revenue, expenses, and keeping score and how changes in one or more areas influence the practice overall financial health.

Practice Revenue

- Services: The old saying "focus on what you are good at and love doing" holds true in most successful businesses. In equine practice, examine market and competition. This means asking questions of customers and potential clients—what is needed and what is missing? Internally, a breakeven analysis is suggested to examine the financial impact of a new service and assess the pricing structure. This approach is also

NOTES

used for current services in an effort to evaluate profitability and where marketing dollars are best used.

- Fee Structure: Costs increase at variable rates over time. In times of high inflation, the dollar does not go as far. As operational costs increase, keep pace by adjusting fees to protect your margin (profitability). There are three key components to fees: price, volume, and market tolerance. Several approaches to adjusting fees and the impact of timing those fee changes will be presented in the program.
- Impact of Growth on Value: It is easy to assume that as a practice grows, it becomes more valuable, and while that is generally true, it is important that a practice is growing correctly. For instance, if profit margins are not maintained as a practice grows, the value of the practice could be hurt. Growth "at any cost" is not healthy growth. During periods of rapid growth like the industry has seen over the last few years, practice owners should closely watch practice profitability to make sure that percentage of revenue that translates into earnings stays consistent. By keeping score on a consistent basis, a practice owner will know what a typical profitability percentage is for the practice and individual services, and that profitability percentage should be maintained, even in times of rapid growth or in times of contraction.

Practice Expenses

Monitoring and controlling expenses are key to profitability in turbulent and prosperous times. In an equine practice, cost of professional services and people costs are the two biggest categories of expenses. The benchmarks presented later in this paper establish the general guidelines for what percentage of revenue these two primary expense categories should represent.

- Labor: There are generally three categories of the cost of labor: doctor compensation, lay staff compensation, and benefits. Overall total labor costs, including all three of these categories, are typically somewhere between 40% and 50% of total revenue. Doctor compensation (excluding benefits) is typically 20% to 25%, lay staff compensation (excluding benefits) is typically 15% to 20%, and the remaining total cost of labor is for employee benefits. Typically, employee benefits range from 5% to 10% of total revenue.
- Cost of Professional Services: Total cost of professional services typically is approximately 27% of total revenue. The biggest portion of cost of professional services is the cost of drugs and supplies, which is typically about 20% of total revenue. The remaining 7% of revenue that is cost of professional services comes from lab costs, field service costs, and other items associated with the provision of professional services.

Income Statement as a percentage of Gross Revenue	
Gross Revenue	100.00%
Cost of Professional Services	(27.12%)
Gross Profit	72.88%
Payroll	(44.49%)
Facilities & Equipment	(10.18%)
Administrative	(5.55%)
Net Ordinary Income	12.66%
Depreciation, Taxes & Interest	(1.40%)
Net Income	11.26%
EBITDA	12.66%

Cash Flow items as a percentage of EBITDA	
CapEX	12.51%
Debt Services	9.00%
Profit Distribution	70.16%

Fig. 1. Income statement and cashflow benchmarks. Developed by John A. Chalk and Trinity Portfolio Advisors.

Keeping Score

- Importance of Monitoring Progress: Keeping score is simply the regular measurement of anything. In a game, it is the score. If there is no score kept in a game, then no one knows whether they are winning or losing. The same is true in business; it is important to keep score in several areas to know whether the business is winning or losing. Each member of a practice team can help keep score in individual areas of responsibility. In order for the score to be meaningful, it should be measured regularly. When regularly comparing one result to another result (measured at a later time), trends will become apparent in the practice, and judging whether or not progress is being made in that particular area will be possible. A few examples are included below.
    - Number of new clients attained last month versus this month
    - Total revenue of the practice this month versus the same month last year
    - Total patients seen this month versus same month last year
    - Average invoice amount per doctor
    - Average days accounts receivable
    - Inventory turnover
    - Budget comparisons and performance
- Value of Benchmarks: Benchmarks are used to compare one practice to other practices or groups of practices. The use of benchmarks can help measure the financial health of the practice. Figure 1 shows some benchmarks that were developed by the authors of this paper.
- Dashboards and Key Performance Indicators: It is important to monitor practices on monthly, quarterly, and sometimes daily metrics. Examples of dashboards and the use of key performance indicators will be illustrated in the case situations during the program.

Acknowledgments

Declaration of Ethics

The Authors have adhered to the Principles of Veterinary Medical Ethics of the AVMA.

Conflict of Interest

John Chalk, Jr. owns the registered investment advisory firm Trinity Portfolio Advisors, LLC. Based in Southlake, Texas, Trinity Portfolio Advisors, LLC is a paid consultant to owners of veterinary practices. Mr. Chalk has no conflict of interest in this presentation. Dr. Magnus owns the business consulting firm Oculus Insights, LLP and is a paid consultant for numerous equine practices, private equity investors, and animal health industry companies. His company provides business tools, educational programs, and support for the global equine veterinary industry. Dr. Magnus has no conflicts of interest in this presentation.

Taking Control of Cost of Goods Sold with Focused Inventory Management

Danika Kent Dostal

Inventory management within an equine veterinary practice warrants more than a passing glance. This paper seeks to identify the many variables affecting cost of goods sold, how they directly affect profitability, and how they can be managed simply for significant results. Author's address: 20071 N US Hwy 281, Stephenville, TX 76401; e-mail: danika.dostal@vmitexas.com. © 2022 AAEP.

1. Laying the Groundwork

Inventory is among the highest expenses of a veterinary practice. Logically, it follows that the management or mismanagement of inventory greatly impacts the profitability of the business.

All practice owners aspire to maximize profits. Most would like to manage inventory more proactively, but few know where to start. The easiest way is to spend less on inventory purchased to stock the practice. Reining in spending is a small portion of the inventory management strategies that can free up cash flow, increase margins, and improve overall practice value.

Whatever inventory-related goals have been identified in a practice, benchmarks should be selected to measure progress toward those goals. These metrics should be constant because while the evolution of inventory policy over time is inevitable, consistent baseline benchmarks will help evaluate improvement no matter how many times the drawing board is revisited.

Cost of goods sold (COGS) is one of the most common metrics used to find the pulse of inventory. It is important to understand that while COGS is technically a dollar amount, it is applicable to a wider audience to discuss it as a percentage of either production or gross revenue. If calculated as a percentage of gross revenue, accounts receivable factors into the equation. Percentage of production can be a more consistent meter because some business models fluctuate in their accounts receivable throughout the year. Regardless, discussing COGS as a percentage of production or revenue allows a practice to compare apples to apples, whether it is a $5,000,000 practice or a $15,000,000 practice.

Therefore, for the purposes of this paper, a working definition that defines COGS as the percentage of gross revenue spent on drugs and supplies will be used. It is a simple equation, but the complex reality is that COGS is influenced by everything that happens with inventory— from as early as before the purchase, when pricing is negotiated, to after the point of sale, when payment is collected.

Factors affecting COGS can be sorted into two categories: purchasing and inventory management.

Purchasing is an inclusive term blanketing every element of the procurement process. Before a purchase is made, the cost is set. A window of opportunity for negotiation exists around the price set by most

NOTES

suppliers. Beyond the monetary cost of inventory are logistical variables, such as time spent on the ordering process and the method of placing orders.

Inventory management includes, but is not limited to, organization and storage, data entry and record keeping, systems of counting and tracking inventory, calculating turnover, setting minimum and maximum stock levels, determining appropriate sales plans and discounting, and billing and collecting.

To illustrate the COGS equation, consider this example of a practice with $500,000 revenue and $150,000 drug and supply cost:

$150,000 drug and supply cost/$500,000 revenue = 30% COGS

For every dollar of revenue generated, this practice spends $0.30 on inventory. Industry average is 20.33%, and so the journey begins for this practice to find ways to reduce the COGS.[a]

COGS will be one metric this practice can use over time to evaluate whether efforts at improving purchasing and inventory control are fruitful, but the practice might select two or three others to focus on at a more micro level. Some metrics that exist within the previously mentioned categories of COGS-influencing factors include:

- Purchasing: mark-ups, discounts, rebates, rebate exclusions, terms, volume commitments
- Stock levels: days to turnover, minimums, maximums, and reorder points
- Sales plans: percentage mark-up, fees, regional comparisons
- Shrink: dollar value of expired medications, percentage of inventory wasted, dollar value or percentage of missed billing
- Discounting: dollar value of discounts
- Accounts receivable: days to collection

For maximum improvement to COGS, each side of the equation must be scrutinized. Both cost and revenue components have ground-level starting points that will establish the foundation upon which to add additional savvy and cost-saving inventory management tactics.

2. Buying Better

Efforts to reduce COGS by "buying better" include understanding and negotiating for better purchasing agreements and discerning whether available purchasing tools align with the goals of the practice.

A simple lack of understanding of purchasing agreements can leave a lot of money on the table. Unfortunately, purchasing agreements are often complex and largely untransparent by design. For the scope of this conversation, further discussion about purchasing agreements will focus on those between a veterinary practice and a distributor; contracts with pharmaceutical manufacturers and other vendors have additional nuances. To better understand distributor agreements, it is necessary to first understand some important terms.

Cost-plus pricing is determined by adding a percentage mark-up to the seller's cost—in this case, the distributor's cost to stock and sell the product. Cost-plus pricing is the foundation of any distributor pricing agreement. The definition of cost is complex and ultimately a moving target as some vendors include labor, logistics, and other overhead costs, while others strictly define cost as their own purchase price. Still, it is an important benchmark to use when comparing pricing agreements across distributors.

The pricing of some products is set by the manufacturer, and from a practice owner's point of view, manufacturer-set pricing is unaffected by the cost-plus structure.

For pricing left to the discretion of the distributor rather than the manufacturer, cost-plus pricing comes into play. This variability can be observed in private label generic and consumable products, such as generic flunixin and brown gauze, and in the products that cross over from the human market, such as sulfamethoxazole tablets. While most animal health products see a price increase once a year, human drugs are extremely volatile in pricing, changing frequently throughout the year and sometimes from day to day.

Rebates are a percentage of sales paid back to the buyer, typically in exchange for purchasing a preagreed-upon volume of product. Rebates can represent significant net savings beyond the invoice price. One advantage of rebates paid after the initial purchase rather than as an up-front discount at the time of sale is that the savings can be reserved entirely for the practice, rather than passed on to the client when sales plans are calculated from the invoice price.

Be advised, however, that it is critical to ask which, if any, products are excluded from a rebate or rebated at a different level. It should never be assumed that all products are rebated equally or rebated at all.

Terms are also negotiable. Standard payment terms are 30 days from the end of a billing cycle. Extended payment terms are common for large orders, such as at the annual AAEP convention where they are often referred to as delayed billing. What is not commonly known is that extended payment terms can be negotiated for everyday orders as well. With appropriate stock levels and turnover, extended payment terms offer a larger window to buy what is needed and use, bill, and collect payment before paying the vendor, effectively using the vendor's money. While this does not directly impact COGS, the advantages to the cash flow of a business maximizing payment terms should not be overlooked.

Cost is not limited to the fiscal realm. Cost may come in the form of inefficiencies in management or other holes in the purchasing process. It is important to discern whether the shiny, well-marketed tech options truly optimize efficiency and savings or simply provide one at the cost of the other. All tools come

with a cost, some higher than others, and all should be carefully vetted.

For example, it is becoming more commonplace for inventory software to tout the convenience of integration with a distributor's website. This may sound attractive, but if purchasing decisions are based solely on this integration, it is possible that the increased convenience will pigeonhole the practice into purchasing from a source that is not necessarily in the best financial interest of the business.

An alternative innovation worth considering is Vetcove (vetcove.com). Developed by the sons of an equine veterinarian, this free service streamlines ordering efficiency by syncing with supplier websites through the clinics' vendor accounts, displaying real-time pricing and availability across all synced suppliers while highlighting pricing variability.

To revisit the previously illustrated equation, remember the practice that started with a 30% COGS. In focusing on the drug and supply cost side of the COGS equation, this practice became more proficient in the language of purchasing agreements and was able to negotiate for a better cost-plus mark-up and additional rebates with a black-and-white understanding of which purchases are rebate eligible and which are not. The practice was also able to gain extended payment terms on everyday orders, not just once a year at AAEP, thereby improving cash flow.

Through utilization of Vetcove, the practice realized they were leaving money on the table by ordering solely from the distributor that integrated with their inventory software and decided to find other ways to increase efficiency that were not at the expense of their carefully negotiated savings.

As a result of these changes, the practice was able to reduce their drug costs by over 5%, reducing the amount spent on drugs and supplies from $150,000 to $142,000. This savings translated to a 2.8% improvement in COGS, enabling this practice to retain $8,000 that was previously spent on procurement.

$142,000 drug and supply cost/$500,000 revenue = 28.4% COGS

Prudent review of pricing agreements and purchasing tools are simple blueprints that can be easily adapted by any veterinary business. Further efforts to improve purchasing practices include the implementation of protocols that utilize real practice data to balance efficiency, stock levels, and cash flow. There are rational purposes behind these methods. Collecting usage data, such as turnover, and then putting that data to use to align order frequency and volume with negotiated payment terms is the apex of purchasing efficiency. These strategies begin to bleed into the inventory management side of the COGS equation.

3. Controlling Inventory

The previous example illustrated how lowering inventory expenses can have a positive effect on COGS. Unfortunately, it is not uncommon for mismanagement of inventory and the resultant impact on revenue to negate any money saved in the procurement process. Shrink has arguably the largest impact on revenue, but many practices lack the inventory tracking standard operating procedures necessary to put a true value on wastage, expired medications, and missed billing. Without such concrete data, few practices are able to make a change for the better.

In order to answer questions about shrink with any certainty, a practice must first be able to track its inventory. Traceability requires a clearly defined system of moving inventory through the business. The goal is to illuminate the path inventory follows from purchase to sale, allowing the habits that impact COGS to be highlighted and tweaked as necessary to reach desired goals.

For all the tangible places inventory goes, transactions must be mirrored, ideally in an inventory software that supports multiple inventory locations. The goal is for 100% of the movement of tracked inventory to be recorded as purchases, transfers, sales, or adjustments. To identify missed billing, in particular, transfers are key.

Inventory locations are fundamental to inventory control. A system of primary and secondary locations is recommended, with the central pharmacy designated as the primary, and secondary locations to match all ancillary locations outside the pharmacy. Inventory moves into the pharmacy as purchases and out of the pharmacy as transfers. Inventory moves into secondary locations as transfers and out as sales.

As much as possible, locations are dedicated to people rather than trucks, areas, or rooms. To understand the rationale behind this logistical convention, consider one question: If inventory is transferred to a "hospital" location within a multidoctor practice, who is responsible for that inventory when multiple veterinarians have in-patients in their care? Where traceability is lost, so is accountability.

The pharmacy is the heart of inventory control within a practice, and it is from here that all changes must originate. If putting a true, reliable value on shrink is a practice priority, it may be necessary to close or limit pharmacy access. This can initially be one of the most disruptive changes to the inventory protocols within a practice, but the hard truth is that the more disruptive it is, the more it is probably needed.

An open pharmacy is more convenient because staff can take whatever is needed, whenever they need it. If, however, the entire staff is not religious about recording what is taken and where it goes, inventory becomes untraceable in its first move off the pharmacy shelf.

On the other hand, providing the extra measure of traceability paves the way for greater accountability, which consciously leads to greater billing awareness, boosted production, and increased revenue—and when these results are not initially materialized, there is a trail to follow inventory to its dead end and troubleshoot the habits and behaviors that lead to missed billing and drugs left to expire in obscure locations.

Other benefits of closing the pharmacy include greater awareness of stock levels for reordering purposes, better control and usage of short-dated products, and reduced incidence of expired medications.

Change is hard, and culture is the key to success. Communicate the purpose and goal behind any change before implementation. When the team understands the "why," it facilitates compliance and cooperation. Listen to the concerns that will inevitably be expressed because everyone that touches inventory views the issue through their own lens and may raise a valid concern that has not yet been considered. Get started on the best possible foot, but do not be afraid to go back to the drawing board if a change does not move the practice closer to its goals.

To further develop the previous COGS equation, after its previously described measures to improve purchasing costs, this practice made concentrated efforts to effect change on the revenue side of the COGS equation. It began by establishing a system of inventory locations identified within the physical infrastructure of the business and mirrored in the practice management software. This design facilitated a clean, traceable system of inventory movement, ensuring all inventory leaving the pharmacy would be accounted for and making staff more mindful, which resulted in a greater percentage of inventory purchased and transferred also being billed. Cumulatively, these efforts resulted in a revenue increase of 10%, or $50,000.

$142,000 drug and supply cost/$550,000 revenue = 25.8% COGS

When compared with the original equation, this represents a 4.2% improvement in COGS, which translates to $58,000 in the bank rather than left on the table, handed off as free product, or thrown in the trash.

4. Conclusion

These innovations are just the springboard from which to further improve inventory systems within a veterinary business. There is no one-size-fits-all approach, but there are a great number of fundamental methodologies that can be tailored to any practice.

For example, mapping inventory locations and closing the pharmacy provide the foundation on which to build a checks-and-balances system of counting high-volume drugs and supplies. That data can be paired with reliable records of inventory transactions to calculate turnover and set minimums and maximums customized to the practice or report revenue-related information on areas like discounting and missed billing.

Broad-stroke improvements like these create additional opportunities to finesse inventory at an increasingly micro level, but first steps must be simple, manageable, and, most importantly, part of a cooperative, forward-thinking culture.

Acknowledgments

Declaration of Ethics

The Author has adhered to the Principles of Veterinary Medical Ethics of the AVMA.

Conflict of Interest

The Author has no conflicts of interest.

Footnote

[a]Chalk J. Unpublished data, May 2022.

Use of Equinosis Q with Lameness Locator to Evaluate Lameness in Horses

Kevin G. Keegan, DVM, MS, DACVS

Author's address: University of Missouri Veterinary Health Center, Columbia, MO 65211; e-mail: keegank@missouri.edu. © 2022 AAEP.

1. Introduction

Lameness is a clinical sign.[1,2] There are many diseases or dysfunctions that cause horses to display lameness, but the base reason is pain during weight bearing. To accommodate pain, the horse, using various mechanisms, loads the limb with less vertical force. Amplitude of lameness is inversely proportional to vertical limb force. Measuring ground reaction force is easy for single strides. But lameness is notoriously variable from stride to stride[3,4] and must be measured over many strides. Acceleration is a proxy measurement for force, and it can be measured continuously with body-mounted inertial sensors (BMIS).[5–7]

Decreased downward vertical acceleration of the torso is the direct cause of smaller ground reaction forces during the first half of stance, and decreased upward acceleration of the torso is the direct result of smaller ground reaction forces during the second half of stance.[8,9] All of the information necessary to detect and localize the cause of lameness can be ascertained by close analysis of the vertical movement of the torso. Detection of lameness is a simple measurement problem. Determination of the importance of lameness and localization of the cause of lameness are more complex problems.

Why, then, if lameness detection and measurement is simple in concept, is it sometimes so difficult in practice? Consider weighing a flea. The concept is simple, but the task is difficult, unless you have a very sensitive and precise scale. In a similar vein, subjective evaluation of lameness by simple observation of the horse in motion at the trot is the most common method of lameness detection, but the spatial and temporal resolution of the human eye is limited. Small differences in vertical torso movement resulting from unequal loading of limbs are not reliably detected. Methods of objective measurement with higher spatial and temporal resolution than the naked human eye will therefore be more sensitive and reliable for detecting lameness. Line-of-site measurement techniques, like video capture or computer-assisted kinematic analysis of gait, can offer high temporal resolution, but unless the horse is contained within a limited field of view, like on a treadmill, both suffer from limited spatial resolution. BMIS, with both high sampling frequency and wireless transmission of measurement, so the horse can be evaluated anywhere at any time, is the most practical objective technique suitable for routine clinical use.

Objective measurement of lameness is unbiased. It removes doubt and difference of opinion. Objective measurement creates a quantitative record to be stored, archived, and studied. It makes comparisons between dates more accurate; it can help decipher the complex relationship between primary, compensatory, and secondary lameness; and most importantly, it creates an objective database that can be searched and analyzed for patterns that may be clinically useful.

2. Analysis of Forelimb Lameness by Measuring Vertical Head Movement

The head is attached to the torso on a long lever arm parallel to midline. Vertical head movement

NOTES

mimics vertical torso movement. The head's large mass makes it an effective counterweight that can be used to adjust vertical torso movement to unload painful limbs. It is such an effective counterweight that its vertical movement in lameness dominates all other movement adjustments by the horse to reduce weight-bearing forelimb pain.

There are 2 principle causes of vertical head movement in the trotting horse. The first is that the head simply follows the down and up motion of the torso as the horse is trotting. This is the natural, normal, and expected vertical head trajectory in a horse without lameness. The second is that the head moves more upward, or less downward, with pain during weight bearing. Total vertical movement trajectory of the head is a summation of both these causes. Closer inspection of this model of head movement suggests that the shape of the trajectory provides information on timing of forelimb lameness, that is, whether the pain is greatest in the first or second half of stance. Knowing this could provide useful clinical information.

If the pain of lameness peaks in the first half of stance, neck muscles reduce force of weight bearing by restricting the fall of the head. The head falls less during the stance phase of the lame limb so that the head height from the ground is higher than that during the stance phase of the sound limb, creating a difference in minimum head height. If the start of the stride is defined as the beginning of right forelimb stance, the first minimum as the minimum head height during right forelimb stance, and the second minimum during left forelimb stance, then a horse with a right forelimb impact-type lameness will have a positive difference in minimum head height (Diff Min [head] = +). With lameness in the first half of stance, the horse usually also thrusts its head upward right before impact of the lame limb. If, by definition, the first maximum head height occurs right before right forelimb impact and the second right before left forelimb impact, then horses with a right forelimb impact-type lameness will also have a positive difference in maximum head height (Diff Max [head] = +).

If, on the other hand, the pain of lameness peaks in the second half of stance, neck muscle activity reduces force on the limb by raising the head during push off. By defining the starting point of the stride to be impact of the right forelimb, a horse with a right forelimb push-off-type lameness will have a higher head height both during a positive Diff Min (head) and after a negative Diff Max (head) right forelimb stance. Similarly, a horse with a left forelimb push-off-type lameness will have a negative Diff Min (head) and a positive Diff Max (head).

Table 1 indicates the signs of Diff Min and Diff Max (head) for the various types of forelimb lameness.

The Q™ displays forelimb lameness in a plot (Fig. 1) with the *x*-axis as Diff Max (head) and the *y*-axis as Diff Min (head). Each blue line in the plot is a stride. The length of the line is the vector sum (VS) of the amplitude of Diff Min (head) and Diff Max (head), which represents the severity of lameness for that stride. $VS = \sqrt{DDiff\ Max\ (head)^2 + Diff\ Min\ (head)^2}$. Mean Diff Minx (head), Diff Max (head), and VS are calculated over all strides. The location of the line in the plot is indicative of the limb involved (left or right) and timing (beginning through end of stance) of forelimb lameness. Rays in quadrant (Q) 1 indicate right forelimb beginning of stance lameness; rays in Q2 indicate right forelimb end of stance lameness; in Q3, left forelimb beginning of stance lameness; and in Q4, left forelimb end of stance lameness. Thresholds for Diff Min (head) and Diff Max (head) between normal and lameness are estimated to be ± 6 mm. Threshold for VS between normal and lameness is estimated to be 8.5 mm.

Table 1. Signs of Diff Min and Diff Max (Head) for the Various Types of Forelimb Lameness

Side and type of lameness	Diff Min (Head)	Diff Max (Head)
Right forelimb impact	+	+
Right forelimb push off	+	−
Left forelimb impact	−	−
Left forelimb push off	−	+

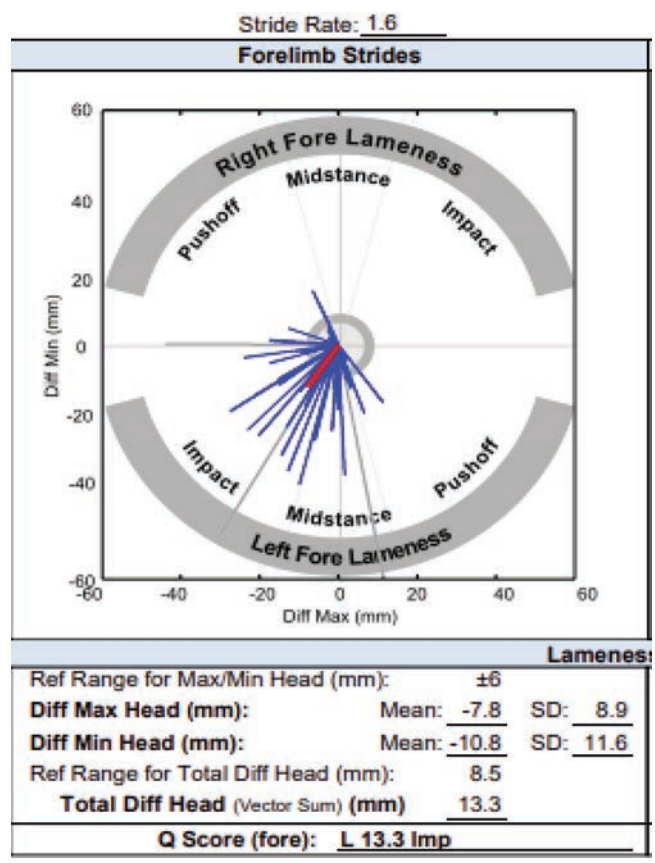

Fig. 1. Left forelimb beginning of stance lameness. Negative Diff Max (head) and negative Diff Min (head).

3. Analysis of Hindlimb Lameness by Measuring Vertical Movement of the Pelvis

Vertical pelvic movement due to hindlimb weight-bearing pain is simpler to explain than vertical movement of the head due to forelimb pain. The biomechanics of vertical pelvic movement are modeled as a bouncing ball. Reduction of force on the painful hindlimb is accomplished either by reducing the fall of the pelvis during hindlimb impact, by reducing the rise of the pelvis during hindlimb push off, or by both. If the first half of hindlimb stance is painful, the pelvis falls less so that its lowest height will be higher from the ground than if there was no hindlimb pain in the first half of stance. This results in a difference of minimum pelvic height between right and left hindlimb stance (Diff Min [pelvis]). Positive Diff Min (pelvis) indicates right hindlimb beginning of stance, or impact, lameness, and negative Diff Min (pelvis) indicates left hindlimb beginning of stance, or impact, lameness.

If pain is in the second half of stance, the horse will push off the affected hindlimb with less force, moving the pelvis up less. This results in a difference in maximum pelvic height between push off of the right hind and left hindlimbs, which is measured as Diff Max (pelvis). Positive Diff Max (pelvis) indicates right hindlimb end of stance, or push off, lameness, and negative Diff Max (pelvis) indicates left hindlimb push-off lameness. Because the causes of Diff Min (pelvis) and Diff Max (pelvis) are different, they are separate measures and are not simply combined to create a single overall hindlimb lameness measure. Although one aspect (impact, push off) may be greater than the other, many horses with hindlimb lameness, unless the lameness is very mild, display components of both types of hindlimb lameness.

The Q™ displays hindlimb lameness as "deficiencies" in left and right hindlimb impact and push off (Fig. 2). Each type of deficiency is color coded, with red lines directed up indicating deficiency of push off and green lines projecting down showing deficiency of impact. The amplitude of each red line above the horizontal is the Diff Max (pelvis) for that stride. The amplitude of each green line below the horizontal is the Diff Min (pelvis) for that stride. Mean Diff Max (pelvis) and Diff Min (pelvis) are calculated and displayed over all strides. Estimated thresholds of Diff Min (pelvis) and Diff Max (pelvis), determined by comparison to subjective evaluation of 3 experienced equine clinicians, between sound and lame states are ± 3 mm.[3,4]

4. Compensatory and Secondary Lameness Patterns in an Apparent Multilimb Lameness

An apparent multilimb lameness may originate from different causes. Compensatory movement in the other half of the body, in an attempt to shift force of weight bearing off the affected limb, is the most common. A compensatory lameness is, in a sense, a false lameness as a limb that appears lame has no focus of pain but appears lame only because of the compensatory shifting of weight to the other end of the body.

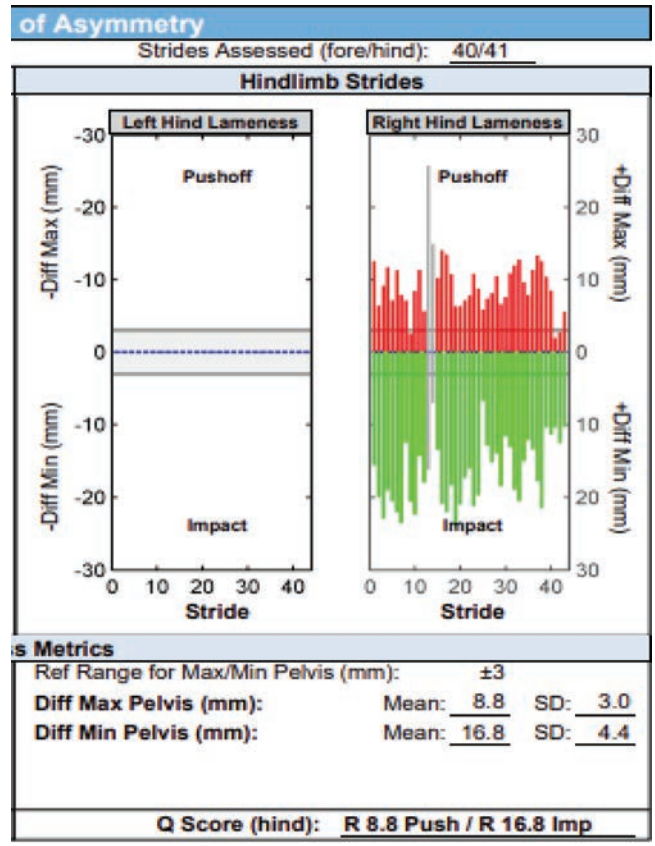

Fig. 2. Right hindlimb push-off and impact-type lameness. Positive Diff Max (pelvis) and positive Diff Min (pelvis).

Another cause of multilimb lameness is secondary lameness, or a truly painful cause in a previously normal limb, due to overloading of that limb over time. It is possible but unlikely for a horse to develop two different primary sources of lameness in separate limbs simultaneously. Extensive trauma, congenital conditions, old age, and long-term intensive exercise may be exceptions. Compensatory lameness should be reversed with the elimination of the primary lameness. Blocking out a secondary lameness, anticipating that whole and possible multiple structures in the limb would be overloaded, should be more difficult.

The pattern of compensatory vertical head and pelvic movement is well studied. Compensatory lameness patterns have been defined as the "law of sides," with 2 principles: 1) In an apparent simultaneous ipsilateral (for example, right forelimb and right hindlimb) lameness, the most likely limb with pain is the hindlimb, and 2) in an apparent simultaneous contralateral lameness, the most likely limb with pain is the forelimb. Recent evidence suggests that there should be a modern clarification of this old law of sides.

The ipsilateral principal of the old law of sides has been confirmed by experimental evidence. When a horse has pain in a hindlimb, it will shift weight forward. Increased force of weight bearing on the simultaneously landing contralateral forelimb results in increased downward movement of the head. When

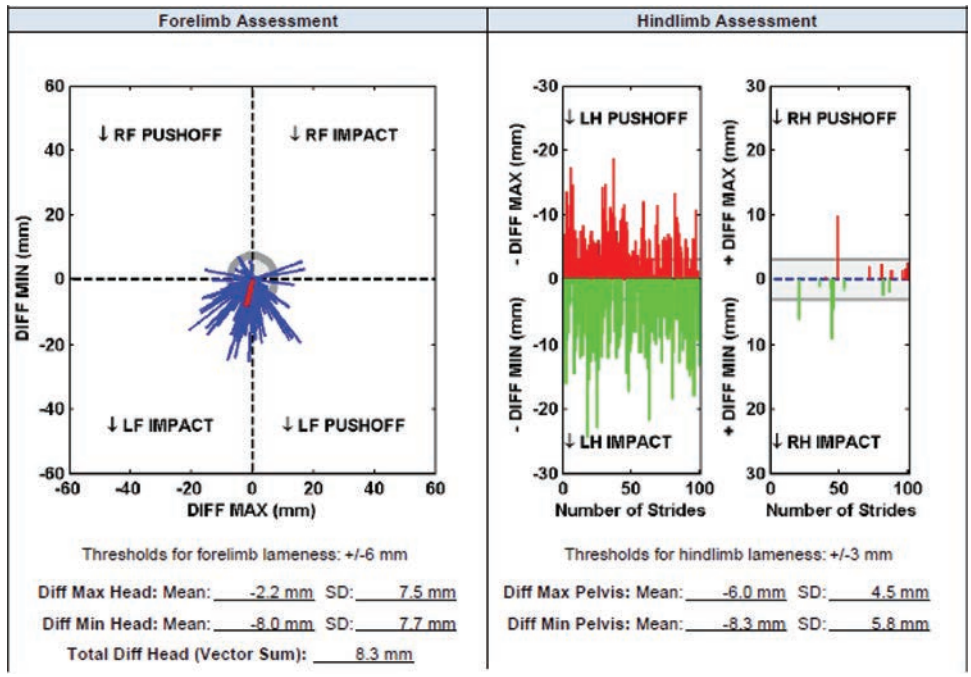

Fig. 3. Primary left hindlimb lameness with compensatory ipsilateral left forelimb lameness. RF, right fore; RH, right hind; LF, left fore; LH, left hind.

the horse lands on the opposite forelimb, ipsilateral to the painful hindlimb, the head will fall to a normal height. But this is higher than when the contralateral forelimb is in stance. Following the "low on sound" rule of head movement in forelimb lameness, this gives the appearance of an ipsilateral forelimb lameness (Fig. 3). Sometimes, the apparent asymmetric head movement is more easily seen than the asymmetric vertical pelvic movement caused by the primary hindlimb lameness. Some horses compensate greatly, and small-amplitude hindlimb lameness can be easily mistaken for forelimb lameness. However, further studies have found that this first principle of the law of sides is only true when the type of hindlimb lameness is only or primarily lack of push off. When the character of hindlimb lameness is only lack of impact, then there is an approximately equal chance that the source of primary lameness is in the forelimb as in the hindlimb. Ipsilateral combined forelimb and hindlimb lameness (CFHL) with hindlimb lameness character as decrease impact (an ipsi-impact pattern) is an exception to the first principle of the law of sides. A more modern and correct ipsilateral principle of the law of sides would state, "Horses with a CFHL in which there is an ipsilateral hindlimb lameness that is mostly lack of push off usually indicates primary hindlimb lameness."

The second part of the old law of sides has been only partially confirmed. When a horse has pain in a hindlimb, it will sometimes shift weight rearward. The horse will land with greater force on the simultaneously landing contralateral hindlimb, and the pelvis will fall more than normal. When the horse lands with normal force on the opposite diagonal, when the opposite normal forelimb and the ipsilateral hindlimb are weight bearing, the pelvis will fall a normal amount, which may be less than when the compensating hindlimb is weight bearing. This will give the appearance of an ipsilateral impact-type hindlimb lameness, with differences in the minimum heights of the pelvis between right and left. If this were the only, more common, or strongest effect, then horses with apparent ipsilateral lameness would be difficult to decipher, as in fact they are (see above). However, fortuitously, a second, more common, and usually more dramatic effect is also seen. A horse with a primary forelimb lameness will tend to push off the simultaneously weight-bearing contralateral hindlimb with less force than usual, causing the pelvis to rise less. This gives the appearance of a push-off-type lameness in the contralateral hindlimb (Fig. 4). So, the second part of the old law of sides is only partially true. Confusion of a hindlimb lameness for a true forelimb lameness, however, is not so likely since, in most horses, the primary forelimb lameness will need to be quite strong before the asymmetric vertical pelvic movement is seen. A more modern version of the second, or contralateral, principle of the law of sides would state, "Horses with a CFHL in which there is a contralateral hindlimb lameness that is mostly lack of push off usually indicates primary forelimb lameness. There may also be an ipsilateral hindlimb lack of impact."

The increased sensitivity of BMIS for measuring head and pelvic movement asymmetry protects against making the wrong determination of primary lameness in the compensatory lameness situation. Knowing the law of sides is helpful for clinical decision-making.

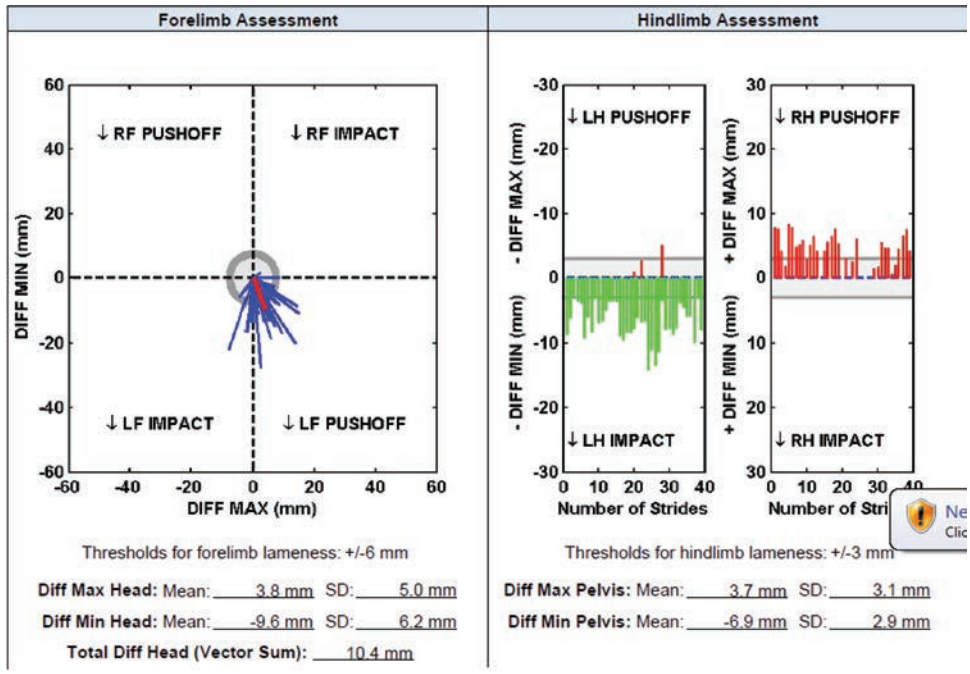

Fig. 4. Primary left forelimb lameness with compensatory contralateral right hindlimb push-off lameness and ipsilateral left hindlimb impact lameness. RF, right fore; RH, right hind; LF, left fore; LH, left hind.

Secondary lameness is much harder to study, and objective evidence for the most common patterns of secondary lameness is anecdotal. With decreased weight bearing on a painful forelimb, the most likely location of overload leading to secondary lameness will be up higher in the affected forelimb (if the primary lameness is distal), in the opposite forelimb, and last, in the opposite hindlimb. It is uncommon, perhaps with the exception of Standardbred pacers, for an ipsilateral hindlimb to be overloaded and to develop secondary hindlimb lameness. One the other hand, with decreased weight bearing on a painful hindlimb, a horse seems to be equally likely to overload and develop secondary lameness in either the contralateral forelimb or in the opposite hindlimb. It is uncommon, perhaps again with the exception of Standardbred pacers, for an ipsilateral forelimb to be overloaded and develop a secondary forelimb lameness. Secondary forelimb lameness is almost always contralateral.

Knowing the compensatory and secondary forelimb and hindlimb lameness patterns can be helpful in figuring out the most likely source of primary lameness in a CFHL case. Sometimes, for example, a hindlimb pattern of movement may be the exact opposite of that expected with a forelimb lameness measurement. This could be the first hint that one is actually dealing with a bilateral forelimb lameness.

5. Lunging

Veterinarians frequently lunge horses during prepurchase and lameness evaluations. It is thought that some lameness may not be seen when horses are trotting in a straight line. The relative forces on the right and left limbs, and the force distribution within each limb, are different when a horse is traveling in a circle. Higher compressive forces are experienced on the outer half of the limb on the inside of the circle and on the inside half of the limb on the outside of the circle, and vice versa with tensile forces.

The horse's body can be quite tilted to the inside of the lunging circle, depending both on the horse and on the size of the circle. This induces a normal asymmetric head and pelvic movement that can interfere with using vertical motion of the head and vertical motion of the pelvis to detect lameness. Thresholds for asymmetry of head and pelvic movement between suspect sound and lame states do not exist for the lunging horse. The horse-to-horse variation on amplitude of asymmetric vertical head and pelvic movement during the lunge is too large to enable establishment of thresholds between lame and not lame as in the straight-line evaluation.

It is common for normal horses to lunge in one direction differently than in the other direction. Last, and most importantly, the patterns of vertical torso movement asymmetry seen in normal horses are heavily dependent upon ground surface characteristics.[10]

However, in general, certain patterns of vertical head and pelvic motion can be expected on hard or soft ground, and deviations from these expected patterns can be used to increase the strength of evidence of lameness.[10] On soft ground, the horse will move its head up more when pushing off the outside forelimb, giving the appearance of an outside forelimb push-off-type lameness. The outside hindlimb will sink down into the surface when pushing off and the pelvis will raise less, and the pelvis will fall less when weight bearing on the inside hindlimb. These findings combine

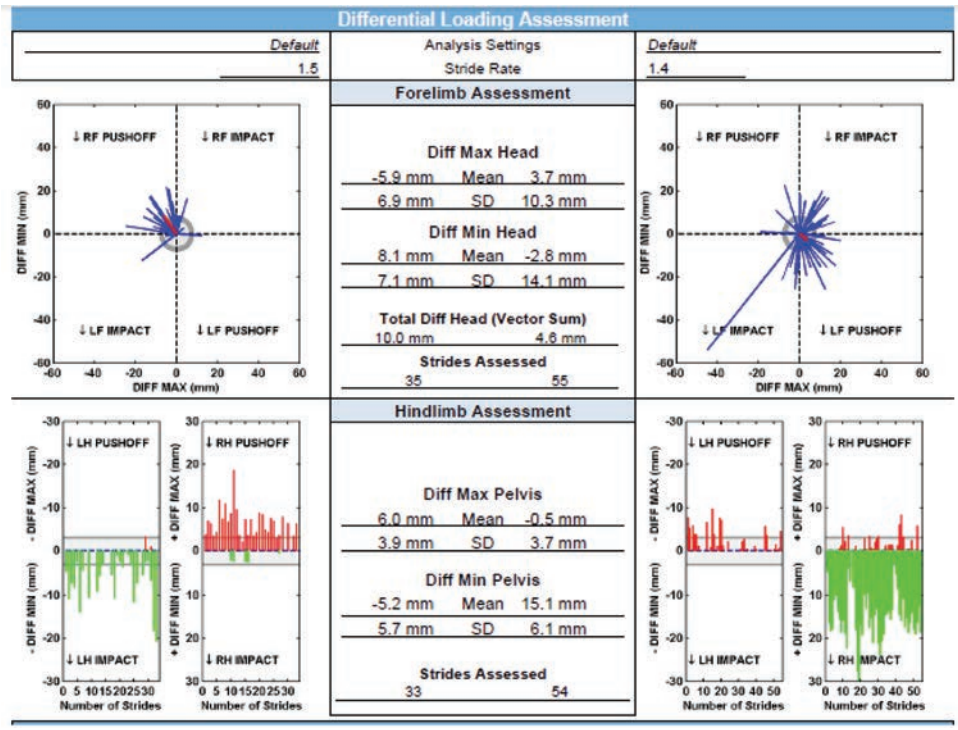

Fig. 5. Normal asymmetric head and pelvic vertical movement when lunging on soft surfaces. RF, right fore; RH, right hind; LF, left fore; LH, left hind.

to make it appear like the horse has an outside hindlimb push-off-type lameness and an inside hindlimb impact-type lameness. When this pattern is seen (Fig. 5), or any part of this pattern, caution should be used before proclaiming evidence of lameness.

By contrast, if the horse is lunging on very hard ground, the head will move down less on the inside forelimb, thus giving the appearance of an inside forelimb impact lameness. Also, the pelvis will fall less and rise less on the inside hindlimb, thus giving the horse the appearance of inside hindlimb impact-type and push-off-type lameness. When this pattern is seen (Fig. 6), or any part of this pattern, caution should be used before proclaiming evidence of lameness.

Adding lunging to the lameness evaluation protocol increases the complexity of the lameness evaluation, especially when different surfaces are used for straight-line and lunging evaluations. Unless a horse is trained to lunge, it is fruitless to try to gain information by lunging the horse. Highly variable observations and data distract from correct determination of lameness. Even with horses that are trained to lunge, they will commonly show handedness and lunge in one direction differently that the other. Horses may display lameness at the lunge that is not shown in the straight, but it is very uncommon for horses with a clearly seen lameness in the straight to not also show this lameness at the lunge. All these observations suggest that using lunging for workup of lameness may not be necessary, and may actually be distracting in some cases, when the lameness is easily seen (or measured) in the straight-line trot. Lunging should be reserved for horses that are trained to lunge and for presentations in which lameness is not seen or measured at the straight trot.

Despite these findings, it remains good procedure to lunge horses in lameness evaluations, if not only to have the data to study later. However, if the lameness is seen or measured easily in the straight line and it is decided to block the horse to try to locate the lameness within the limb, it is most prudent to restrict evaluations to only trotting the horse in a straight line to assess the block. Because of the more complex patterns of asymmetry seen when horses are lunging, it is more challenging to accurately measure changes in lameness amplitude before and after blocking while the horse is lunging. When the lameness is only seen or measured when the horse is lunging, then, of course, the effect of blocking is measured with the horse lunging in the direction that most displays the lameness.

6. Lameness Evaluation Under Saddle

Some believe that putting the horse under saddle with a rider will invariably make the lameness appear worse. Putting the horse under saddle with a rider increases weight on the limbs, causes increased back extension, and exacerbates discomfort with any poor saddle fit. However, there are also good reasons why putting a horse under saddle makes the appearance of lameness more difficult to detect. Horses that are well trained when ridden are more under the control of the rider. Good horses that are well trained and willing can easily mask even moderate-grade lameness. Also, some horses are more excited under

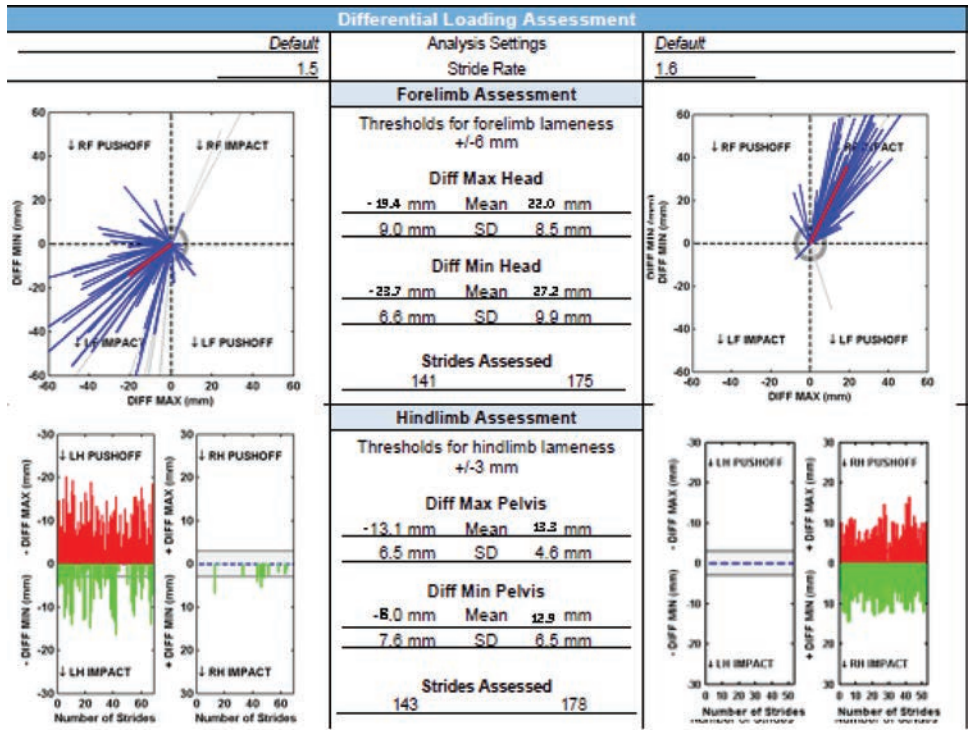

Fig. 6. Normal asymmetric head and pelvic vertical movement when lunging on hard surfaces. RF, right fore; RH, right hind; LF, left fore; LH, left hind.

saddle, with the increase in adrenaline masking pain and the exhibition of lameness.

The effect of the rider on measurement of lameness has been studied using BMIS attached to both the horse and the rider. Movement in sound horses was measured before and after induction of lameness and in horses with natural lameness conditions. Appearance of lameness was dependent on the rider's activity. Appearance of lameness also depends on whether the horse was being ridden in a circle, the size of the circle, and the surface characteristics on which the horse was being ridden. Circle size, surface characteristics, and rider activity combine to affect vertical head and pelvic movement, with the effects sometimes additive, making a false lameness appear (or an existing lameness appear more severe), and sometimes subtractive, masking a true lameness (or making an existing lameness appear less severe).

When the rider was sitting at the trot, the results were quite variable. About one third of the horses looked the same as trotting in a straight line without the rider, about one third seemed to be less lame with the rider, and about one third seemed to be more lame with the rider. However, with the rider posting on the outside limb, it was common for the horse to appear to be lamer on the opposite side, both in the forelimb and in the hindlimb, with the most dramatic effect as decreased push off of the opposite hindlimb. When the rider is posting on the outside limb, they are rising in the saddle and shifting weight forward when the inside forelimb is on the ground. If the horse had a true inside forelimb lameness, this could exacerbate the expression of lameness. Also, the rider is falling into the saddle when the inside hindlimb is pushing off. The downward motion of the rider and upward motion of the pelvis oppose each other, and the pelvis rises less than it normally would, giving the appearance of lack of inside hindlimb push off.

Although evaluation for lameness under saddle is more complicated because of rider activity, certainly when lameness is not being measured when not under saddle, then evaluation of lameness under saddle becomes necessary. Another indication is in cases in which the lameness being measured when not under saddle is different from what is described by the owner or trainer (or referring veterinarian). When owners preface their request for lameness evaluation with a historical description that the lameness is not seen or felt unless the horse is under saddle, it is usually a good idea to try to perform the evaluation under saddle.

7. Other Observations of Lameness as Measured with Inertial Sensors

Evaluating for Lameness at the Walk, Canter, and/or Gallop

Most practitioners would agree that lameness is easier to see in a trotting horse compared to other gaits. There are a few "lameness" conditions that are more easily seen at the walk, like fibrotic myopathy, ruptured peroneous tertius, upward fixation of the patella, and stringhalt. These are erroneously thought to be primarily swinging limb lamenesses but are indeed more easily seen at the walk. Some also claim that a weight-bearing

lameness may be more apparent when the horse is walking, but this is only because when the horse is walking, the asymmetric motion falls within the normal temporal resolution of the naked human eye. The lameness may be easier to see at the walk than the trot, but this does not mean that the lameness would be easier to measure at the walk than the trot. Also, almost always, the lameness, when compared to the canter and gallop gaits, is easier to see at the trot.[11] This has usually been explained as a consequence of the rather easy task of identifying asymmetry in an otherwise very symmetrical expected movement. This is definitely true, but this is not the only reason. When a horse transitions from trot to canter or gallop, within the range of speeds compatible for this transition, forces on the limbs decrease. Thus, it is logical to also assume that the lameness will be less perceived or felt by the horse when it breaks into the canter or gallop.[11] Also, options for redistributing load to spare the painful limb that are available to the horse at the trot are not so available to the horse at the canter or gallop. At transition speeds, horses with lameness will prefer to canter, especially on the nonlame limb lead. Preference for cantering or galloping on a particular lead may be informative for establishing the existence of lameness as a clinical sign, but specific motion parameters that are sensitive for detection of lameness (like asymmetric vertical head and pelvic motion for the trot) have yet to be objectively identified for the canter or gallop. After gradually inducing pain on the bottom of the foot in horses, lameness was measured at a slow trot in a straight line before it was measured at either the canter or gallop. Detection of lameness at the trot in a straight line was more sensitive at picking up lameness than at the canter or gallop.[11] This may not be applicable to pain in the limb that occurs only during the swing phase of the stride. However, attempts to create lameness isolated only to the swing phase of the stride have not been successful, and the existence of pure swinging limb lameness without pain during the weight-bearing phase of the stride has not been objectively determined to exist.

Stabilizing the Lameness

Before the availability of BMIS, it was not recognized that lameness was frequently not displayed by the horse clearly (above thresholds) and consistently (with low variability) when first examined. Clinical impression over the years has shown this to be quite common. Using horses with natural or induced lameness, and in following horses in the clinic with known lameness conditions as part of routine assessment of improvement, one may frequently have the opportunity to evaluate horses with lameness multiple times on multiple days. Horses with known lameness conditions, diagnosed by previous full lameness workups, often either do not show the strongest lameness in the previously identified limb, or the lameness is not of the previously identified amplitude. When using simple, subjective evaluation, there is a tendency to either not notice this or just shrug it off. It is not difficult to raise awareness to the mistakes that can be made in the evaluation of response to blocks if lameness changes spontaneously like this.

However, lameness can be "stabilized" by simply trotting the horse back and forth a few times or lunging (if the horse lunges) it in both directions for a few minutes. A standard method of lameness evaluation with BMIS starts off with trotting the horse in a straight line. Then, the horse is lunged and another straight-line trial is collected. If the straight-line lameness is not stable, that is, if the lameness is not in the same limb, at the approximate same amplitude, and at an acceptable consistency (standard deviations not too much higher than the average), one should keep collecting trials until they are consistent (time permitting), have an assistant or the owner exercise the horse more (freeing oneself up to evaluate another patient), or accept the fate that the source of lameness may have to be found some other way (limb palpation, imaging, etc.). Sometimes, the complete limb and torso evaluation stabilizes the lameness, possibly due to limb manipulation. It is not efficient to block the horse to try to discover the foci of lameness if the lameness is not stabilized. It is usually a waste of time.

Some would ask if this would not, in some cases, warm the horse out of the lameness, making it undiscoverable. This may occur, but if the horse warms out of the lameness in such a short time, with this limited amount of exercise, then it probably is not clinically important. Understanding and taking this into consideration will go a long way to ameliorate some of the headaches and mistakes of interpreting objective measurement to evaluate blocks in horses with lameness.

Figure 7 is an example of an unstable lameness. This first trial (left) was collected immediately before the second (right). The lame limbs are consistent, but their amplitudes are not. If the horse had been blocked immediately after Trial 1, either in the left forelimb or right hindlimb, it would have appeared that the horse improved because of the block. The real improvement occurred spontaneously.

Some horses measure with high variability of lameness, especially in the forelimbs, because they are not trotting consistently and their adrenaline level is high and pain is masked. A small amount of sedation[a] will usually help, and this has been shown to be inconsequential to the display of lameness. Lameness is often displayed stronger with mild sedation.

If one encounters a horse that does not stabilize its lameness, or one that displays lameness of different type (impact/push off), in different limbs, or of wide variation of amplitude in different limbs, neurologic dysfunction should be more strongly considered.

Using Body-Mounted Inertial Sensors to Assess Response to Blocking

Assessing response to block as a decrease in lameness from baseline is relatively straightforward using BMIS. A positive response to block is based upon finding a change in the measurement of lameness that is outside the 95% confidence interval for repeatability for the

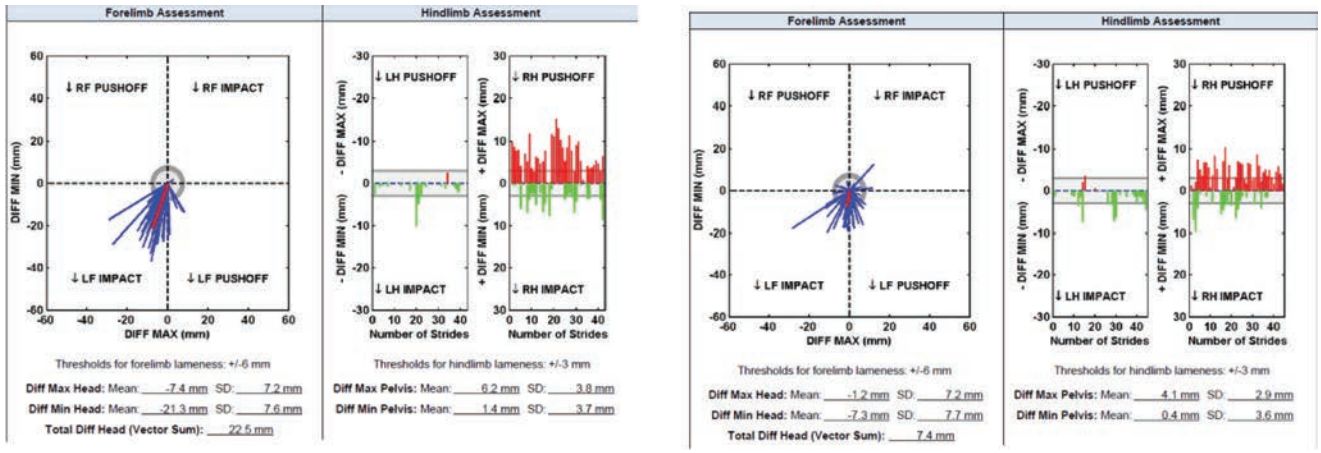

Fig. 7. An unstable lameness. RF, right fore; RH, right hind; LF, left fore; LH, left hind.

lameness measurement variables, ± 8.5 mm for VS and ± 3 mm for Diff Min (pelvis) and Diff Max (pelvis). An increase or decrease in these values within the 95% confidence intervals may be significant, but assessment should be repeated.

It is important to compare the trial after block to the trial collected immediately before that block when 1) the user switches from blocking one limb to another limb, 2) more than 1 limb was blocked at the same time, and 3) the lameness increased significantly after the previous blocks. It is not uncommon for a block to increase the amplitude of lameness in a limb, especially with the most distal limb blocks when the focus of lameness is more proximal in the limb being blocked. This is an indication that the limb being blocked is the primary source of pain. If blocking a limb, starting low and progressing proximally, and an apparent small decrease in lameness with each block is achieved is evidence for blocking a secondarily lame limb. There are a significant number of false positives (horse is better after block but the block should not have desensitized the site of lameness) and false negatives (horse seems no better but the block should have desensitized the site of lameness) blocks. The full effect of the block sometimes takes much longer than a few minutes, and somewhat paradoxically, sometimes blocks were off quicker than expected.

BMIS and Big Data

The Q with Lameness Locator has been available to veterinarians for 15 years, and there are now over 450 units in use around the world. Every year, there are new developments and improvements in hardware and software that make the veterinarian experience more seamless and easier to use. In the author's (the University of Missouri) use alone, data on thousands of clinical cases have been collected. Hundreds of thousands more cases have been evaluated by other equine clinics around the world. Practitioners have only recently begun to take advantage of these numbers, matching up lameness measurement parameters with blocking and imaging findings and with clinical data on final diagnosis. The author has introduced in this presentation only a few of the things that have been learned over the years of clinical importance: the variability of lunging, the effects of surface on lunging results, the effect of the rider and their activity on lameness measurement, the need to stabilize the lameness before blocking, the meaning of increasing lameness after blocking, etc. It has been recently learned that CFHL is measured frequently but that finding a primary cause of lameness in both a forelimb and a hindlimb is not common, that the law of sides is generally true but not perfect, that ipsi-impact patterns are just as likely to be primary forelimb or primary hindlimb lameness, and that ipsi-push-off patterns are most likely primary hindlimb lameness problems.[11] It has also been learned that hindlimb impact patterns more likely indicate cause of lameness in the foot, pastern, or distal tarsal joints; that hindlimb push-off patterns more likely indicate tendon, suspensory, or high-motion joint disease; and that navicular disease is a common cause of forelimb lameness in ipsi-impact patterns but rarely the cause of lameness in ipsi-push-off patterns with a primary forelimb cause of lameness. Critics of using BMIS to objectively measure lameness in horses, arguing that it is just too difficult and time-consuming, that it reduces the importance of a difficultly acquired skill of visually recognizing lameness, or that it is too deficient to provide clinically useful information, none of which is true in the author's opinion, are missing the most important point. Measuring and recording data is the first and most critical step in studying or investigating anything.

Acknowledgments

Declaration of Ethics

The Author has adhered to the Principles of Veterinary Medical Ethics of the AVMA.

Conflict of Interest

Dr. Keegan is a co-developer of the algorithms, code, and hardware used in Equinosis Q with Lameness Locator, is the original founder of Equinosis, and holds a minority share. All intellectual property associated with the

development of the Q with Lameness Locator is owned by the University of Missouri and licensed to Equinosis. Dr. Keegan is not a paid employee or consultant of Equinosis and receives no salary or consulting fees from Equinosis.

References and Footnote

1. Adair S, Baus M, Bell R, et al. A response to 'What is lameness and what (or who) is the gold standard to detect it?' *Equine Vet J* 2019;51:270–272.
2. Adair S, Baus M, Belknap J, et al. Response to Letter to the Editor: Do we have to redefine lameness in the era of quantitative gait analysis? *Equine Vet J* 2018;50:415–417.
3. McCracken MJ, Kramer J, Keegan KG, et al. Comparison of an inertial sensor system of lameness quantification with subjective lameness evaluation. *Equine Vet J* 2012;44:652–656.
4. Keegan KG, Wilson DA, Kramer J, et al. Comparison of a body-mounted inertial sensor system-based method with subjective evaluation for detection of lameness in horses. *Am J Vet Res* 2013;74:17–24.
5. Keegan KG, Yonezawa Y, Pai PF, et al. Accelerometer-based system for the detection of lameness in horses. *Biomedical Sci Instrumentation* 2002;38:107–112.
6. Keegan KG, Yonezawa Y, Pai PF, et al. Evaluation of a sensor-based system of motion analysis for detection and quantification of forelimb and hindlimb lameness in horses. *Am J Vet Res* 2004;65:665–670.
7. Keegan KG, Kramer J, Yonezawa Y, et al. Assessment of repeatability of a wireless, inertial sensor-based lameness evaluation system for horses. *Am J Vet Res* 2011;72:1156–1163.
8. Keegan KG, MacAllister CG, Wilson DA, et al. Comparison of an inertial sensor system with a stationary force plate for evaluation of horses with bilateral forelimb lameness. *Am J Vet Res* 2012;73:368–374.
9. Bell RP, Reed SK, Schoonover MJ, et al. Associations of force plate and body-mounted inertial sensor measurements for identification of hindlimb lameness in horses. *Am J Vet Res* 2016;77:337–345.
10. Rhodin M, Roepstorff L, French A, et al. Head and pelvic movement asymmetry during lungeing in horses with symmetrical movement on the straight. *Equine Vet J* 2016; 48:315–320.
11. Lopes MAF, Dearo ACO, Lee A, et al. An attempt to detect lameness in galloping horses by use of body-mounted inertial sensors. *Am J Vet Res* 2016;77:1121–1131.

[a]Dormosedan (0.1-0.15 cc), Zoetis, Inc., Kalamazoo, MI 49007.

Inertial Measurement Units: What Are They and How Can They Be Used?

Valerie J. Moorman, DVM, MS, DACVS-LA, PhD

Author's address: University of Georgia, College of Veterinary Medicine, 2200 College Station Road, Athens, GA 30602; e-mail: vj_moorman@yahoo.com. © 2022 AAEP.

1. What Is an IMU?

An inertial measurement unit (IMU) is a wearable device that is a type of inertial sensor. An IMU is composed of a triaxial accelerometer, a triaxial gyroscope, and a magnetometer, and the combination of these individual components can provide information on kinematics, or motion, of a horse or specific body segments of a horse. The accelerometer provides measurements of accelerations in three planes (cranial-caudal, medial-lateral, and proximal-distal); this is translatio-nal motion (Fig. 1). These accelerations can be integrated to determine velocity and positional data. The gyroscopes provide angular velocity in three planes (Fig. 1), which can be integrated to provide angular orientation or differentiated to provide angular acceleration. Thus, the output of the IMU can determine both linear and angular kinematics of the horse or a segment of the horse. Additionally, fusion of the accelerometer and gyroscope signals can provide information on heading, and adding in the magnetometer signal aligns the sensor with the reference plane of the Earth.

2. How Is an IMU Different from an Inertial Sensor?

An inertial measurement unit is a type of inertial sensor. Inertial sensors can be composed of the individual components of an IMU. For example, an accelerometer and a gyroscope are also types of inertial sensors. The most commonly used inertial sensor system, the Lameness Locator,[a] is composed of 3 inertial sensors: 2 uni-axial accelerometers and 1 uni-axial gyroscope. An IMU combines these sensors into a single unit (i.e., the accelerometer and gyroscope are within one sensor box; Fig. 2).

3. What IMU Systems Are Available for Use in Horses?

There are currently 3 IMU systems that are used in equine research: XSens MTW,[b] GaitSmart Pegasus,[c] and EquiMoves.[d] The XSens® MTW system has been intensely researched since the early 2000s.[1,2] These IMU sensor units contain a triaxial accelerometer ($\pm$ 18 g) and triaxial gyroscope ($\pm$ 1200 degrees/second). While data have been collected from IMUs attached to the distal limbs just above the level of the metacarpo/metatarsophalangeal joint using the XSens® system,[3] most of the published work has been from body-mounted sensors (poll, withers, thoracolumbar spine, and pelvis). The use of a second commercially available IMU system, Pegasus®, was reported in the mid-2010s.[4,5] The IMUs of this unit have a $\pm$ 5 g triaxial accelerometer and 3 uniaxial $\pm$ 1200 degrees/second gyroscopes. The IMU sensors in this system have been placed on the limbs of the horse at the level of the distal tibia and midmetatarsus or midmetacarpus and have been able to provide information on limb movement.[4] The third IMU system that is commercially available is the EquiMoves® system.[6] This system is composed of two triaxial accelerometers: a low-g range at $\pm$ 16 g and a high-g range at $\pm$ 400 g. The

NOTES



Fig. 1. Photograph demonstrating the planes of motion (translational and angular) determined by an IMU. A, Vertical axis. B, Cranial-caudal axis. C, Medial-lateral axis. Rotation around the vertical axis (white arrow) is internal-external rotation (yaw). Rotation around the cranial-caudal axis (red arrow) is abduction/adduction (roll). Rotation around the medial-lateral axis (yellow arrow) is flexion-extension (pitch).

Fig. 2. Photograph of two of the commercially available IMU devices: the XSens® MTW IMU sensor (orange) and the EquiMoves® sensor (black).

gyroscope within this system is ± 2000 degrees/second. This system has been used to collect kinematic data on both the body of the horse and the limbs. Another IMU system that has been evaluated to a limited extent in horses is the smartphone.[7–10] There are numerous apps on smartphones that allow collection of data from the accelerometers and gyroscopes contained within these devices. The ranges of acceleration and angular velocity vary somewhat with smartphones, but as an example, the iPhone® 6^{e} has a ± 16 *g* accelerometer and ± 2000 degrees/second gyroscope.

4. Limitations of IMUs

While IMUs have the ability to determine both translational and angular motions, they are also complex devices with a number of limitations. First, there are limitations with the measurement ranges of both accelerometers and gyroscopes when it comes to both the location of the IMU on the horse and the gait and speed at which the horse will be traveling. This is most important for limb-mounted sensors because of the high rate of change in motion at the distal aspect of the limb, that is, the foot. For the walk and regular trot, both the acceleration and the rate of angular motion are within the range that can be captured with currently available IMUs. However, at faster gaits (gallop or trotting at high speed), the acceleration ranges of the hoof during both flight and landing are higher than some of the accelerometers within commercially available IMUs. The high-range accelerometer within the EquiMoves® system (± 400 *g*) is high enough to capture those accelerations. The other component to consider is the gyroscope, which measures rate of angular orientation (angular velocity). The current range limit is ± 2000 degrees/second, which again is appropriate for walk and regular trot speeds but is likely not sufficient for higher-velocity gaits. A previously validated IMU system contained a ± 20000 degrees/second gyroscope, but that system is not currently marketed and had other flaws in its sensor design, including motion of the individual components within the device box.[11]

A second limitation of the IMU also involves the gyroscope. When the gyroscope is collecting data for a longer period of time (as short as a few minutes), it undergoes a process called drift (Fig. 3). There are a number of algorithms that can be utilized in post-processing that can address this problem. Calibrating the gyroscope and collecting short durations of data are also useful in preventing data alterations from drift.

A third limitation of the IMU is one that is encountered with wearable sensors. That is the attachment

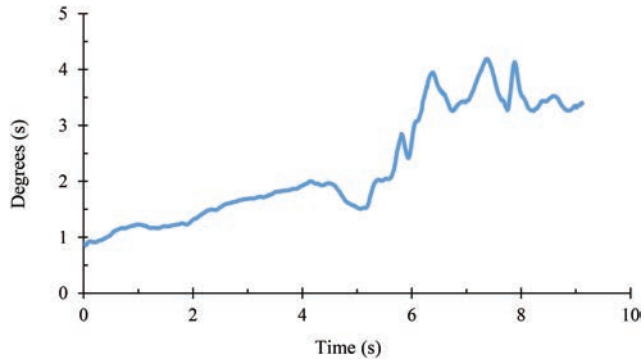

Fig. 3. Angular orientation around the vertical axis (yaw) from an IMU mounted on the surcingle of a standing horse, which demonstrates drift that occurs from the gyroscopic sensor.

method. If the IMU is not snuggly mounted to the horse, it will not provide true readings, that is, there will be background noise. This can be a problem no matter where the sensor is mounted on the horse (body, hoof, or limb).

5. How Have IMUs Been Used in Horses?

Currently, the use of IMUs has been mostly in the research field. However, the EquiMoves® system is marketed for clinical use in Europe. There is a huge amount of research data that have been collected from horses using IMUs, with IMUs mounted on both the body and limbs. IMUs have also been used to collect kinematic information at multiple gaits from the walk to the gallop. The ability of an IMU to collect useful kinematic data depends on its attachment method, the specifications of the components, and the gait at which the horse is moving, as previously discussed.

Body-Mounted IMUs

The earliest research with IMUs involved mounting them on the body of the horse as early units were wired and had lower acceleration and gyroscopic ranges.[1,2] They have been mounted on the poll, tuber sacrale, tuber coxae, and thoracolumbar spine. Because the Lameness Locator® system is a well-known and commonly used inertial sensor system, IMUs have been used in the same locations (poll and tuber sacrale) and to determine the same variables as the Lameness Locator®.[12] The tuber coxae have been another location for placement of IMUs as this is an anatomic region that is often used for subjective visual assessment of lameness.[13,14] Vertical displacement (calculated using the accelerometers) has been a commonly evaluated variable and has been used to assess symmetry in right- versus left-sided motion. Rotational data (calculated from gyroscopes) have also been evaluated with sensors placed on the axial skeleton at sites between cranial withers (T5) to the sacrum (tuber sacrale).[15–17] Thoracolumbar-mounted sensors have been attached to the skin at these sites, which has allowed for saddle placement over them. In one recent study, the rotational motion of the thoracolumbosacral region was investigated in a group of elite dressage horses both in hand and being ridden at a sitting trot.[17] These results were able to capture differences in back motion that occurred between these two conditions. The effect of saddle fit on thoracolumbar motion during ridden work has also been investigated using IMUs.[16] Both of these investigations were able to provide information on back motion underneath the saddle, which would not have been possible using other currently validated motion analysis techniques. Another study examined the effects of local anesthesia to eliminate lameness on thoracolumbar kinematics, which provided additional support to the interconnection of lameness and back pain in horses.[15]

Limb-Mounted IMUs

IMUs have also been mounted on the limbs of horses but to a lesser extent compared to the axial skeleton. There are likely several reasons why limb sensors have been investigated to a lesser extent. First, early IMU systems were wired and required the sensors to be directly to a main data-logging device. Second, the components of the IMUs were of lower ranges, limiting their use on the limbs. Last, as these devices have been investigated as objective lameness tools, it was logical to examine the regions of the horse that are commonly assessed subjectively (i.e., the head and pelvis). Currently, the angular motions of limb segments have been the primary area of investigation using IMUs. Because of the limitations of some of the components within the currently available IMUs, these devices have been primarily used at the level of the metacarpus/metatarsus or proximal limb. Placement of sensors at the metacarpus and distal tibia has allowed the range of motion of the tarsus to be evaluated.[18] The displacement and rotation of the foot has also been determined using a hoof-mounted IMU.[11,19] Limb protraction and retraction angles have also been measured at the trot using metacarpal- or metatarsal-mounted sensors.[5,18,20] Limb-mounted IMUs have also been used to determine hoof-on and hoof-off events, which can be used to determine stance and swing phases of stride.[3,21] The information obtained from the limb-mounted sensors may prove useful for investigation of lameness as well as to understand limb movements in the elite athlete.

6. IMUs Versus Other Kinematic Systems

Currently available IMUs, such as the Pegasus®, XSens®, and EquiMoves® systems, have been validated to the gold standard of kinematics, optical kinematics,[1,4,6] and both systems were found to have good accuracy. As the Lameness Locator® system has become widely utilized around the world, a study was performed to compare this system to the XSens® system in the calculation of commonly assessed variables used in the Lameness Locator® system.[12] Results from this work demonstrated that there were small differences in the variables calculated by each system; however, the authors felt that this should not affect the amount of lameness detected with each system. While not yet

investigated, it is likely that the Pegasus® and EquiMoves® systems would provide similar variable calculations as the XSens® system and the Lameness Locator®.

7. Clinical Use of IMUs

Until recently, IMUs have largely been utilized in a research setting. There have been several main reasons for their limited clinical use. First, the technology, both hardware and processing algorithms, had to be tested and validated. Second, an equine-specific system had to be developed as the first intensively investigated IMU system (XSens®) was designed for use in people and did not have equine-specific software. Now, equine-specific systems are being designed and are being used clinically mostly within the European Union (Pegasus®, EquiMoves®). These and other similar systems are likely to become more commercially available more globally in the next few years.

8. Conclusions

IMUs are sophisticated motion analysis devices that can provide both translational and rotational kinematics of both the axial skeleton and limbs in horses. These sensors have already been used intensively in research settings to better understand the motions of horses during both ridden and unridden exercise. As sensor technology improves as has already begun to occur, it is likely that these devices will be able to provide more kinematic information about distal limb motion, including the interaction of the hoof with the ground at high speeds. It is likely that these devices will provide a better understanding of equine motion, both for lameness and general gait analysis. Additionally, these systems are becoming more commercially available for clinical use, which will add another objective gait analysis tool for equine practitioners.

Acknowledgments

Declaration of Ethics

The Author has adhered to the AVMA Principles of Veterinary Medical Ethics.

Conflict of Interest

The Author has no conflicts of interest.

References and Footnotes

1. Pfau T, Witte TH, Wilson AM. A method for deriving displacement data during cyclical movement using an inertial sensor. *J Exp Biol* 2005;208:2503–2514.
2. Pfau T, Robilliard JJ, Weller R, et al. Assessment of mild hindlimb lameness during over ground locomotion using linear discriminant analysis of inertial sensor data. *Equine Vet J* 2007;39:407–413.
3. Olsen E, Andersen PH, Pfau T. Accuracy and precision of equine gait event detection during walking with limb and trunk mounted inertial sensors. *Sensors (Basel)* 2012;12:8145–8156.
4. Roepstorff L, Wiestner T, Weishaupt MA, et al. Comparison of microgyro-based measurements of equine metatarsal/metacarpal bone to a high speed video locomotion analysis system during treadmill locomotion. *The Vet J* 2013;198:e157–e160.
5. Cruz AM, Maninchedda UE, Burger D, et al. Repeatability of gait pattern variables measured by use of extremity-mounted inertial measurement units in nonlame horses during trotting. *Am J Vet Res* 2017;78:1011–1018.
6. Bosch S, Braganca FS, Marin-Perianu M, et al. EquiMoves: A wireless networked inertial measurement system for objective examination of horse gait. *Sensors* 2018;18:850.
7. Moorman VJ, Kawcak CE, King MR. Evaluation of a portable media device for use in determining postural stability in standing horses. *Am J Vet Res* 2017;78:1036–1042.
8. Moorman VJ, King MR. Angular orientations derived from a portable media device to assess postural stability during quiet standing in the horse. *Equine Vet Educ* 2021;34:e198–e202.
9. Pfau T, Weller R. Comparison of a standalone consumer grade smartphone with a specialist inertial measurement unit for quantification of movement symmetry in the trotting horse. *Equine Vet J* 2017;49:124–129.
10. Marunova E, Dod L, Witte S, et al. Smartphone-based pelvic movement asymmetry measures for clinical decision making in equine lameness assessment. *Animals* 2021;11:1665.
11. Moorman VJ, Reiser RF, McIlwraith CW, et al. Validation of an equine inertial measurement unit system in normal horses overground at the walk and trot. *Am J Vet Res* 2012;73:1160–1170.
12. Pfau T, Boultbee H, Davis H, et al. Agreement between two inertial sensor gait analysis systems for lameness examinations in horses. *Equine Vet Educ* 2016;28:203–208.
13. Church EE, Walker AM, Wilson AM, et al. Evaluation of discriminant analysis based on dorsoventral symmetry indices to quantify hindlimb lameness during over ground locomotion in the horse. *Equine Vet J* 2009;41:304–308.
14. Pfau T, Starke SD, Troster S, et al. Estimation of vertical tuber coxae movement in the horse from a single inertial measurement unit. *The Vet J* 2013;198:498–503.
15. Greve L, Dyson S, Pfau T. Alterations in thoracolumbosacral movement when pain causing lameness has been improved by diagnostic analgesia. *Vet J* 2017;224:55–63.
16. MacKechnie-Guire R, MacKechnie-Guire E, Fairfax V, et al. The effect of tree width on thoracolumbar and limb kinematics, saddle pressure distribution, and thoracolumbar dimensions in sport horses in trot and canter. *Animals* 2019;9:842.
17. MacKechnie R, Pfau T. Differential rotational movement and symmetry values of the thoracolumbosacral region in high-level dressage horses when trotting. *PLoS ONE* 2021;16:e0251144.
18. Schwarz J, Vidondo B, Maninchedda UE, et al. Inter-evaluator and intra-evaluator reliability of a software program used to extract kinematic variables obtained by an extremity-mounted inertial measurement unit system in sound horses at the trot under soft and hard ground conditions and treadmill exercise. *Front Vet Sci* 2021;8:595455.
19. Moorman VJ, Reiser RF, Mahaffey CA, et al. Use of an inertial measurement unit to assess the effect of equine forelimb lameness on three-dimensional hoof orientation at the walk and trot. *Am J Vet Res* 2014;75:800–808.
20. Sapone M, Martin P, Mansour KB, et al. The protraction and retraction angles of horse limbs: An estimation during trotting using inertial sensors. *Sensors* 2021;21:3792.
21. Serra Braganca FM, Bosch S, Voskamp JP, et al. Validation of distal limb mounted inertial measurement unit sensors for stride detection in Warmblood horses at walk and trot. *Equine Vet J* 2017;49:45–551.

[a]Lameness Locator, Equinosis, LLC, Columbia, MO 65203.
[b]XSens MTW, XSens North America Inc, El Segundo, CA 90245.
[c]Gaitsmart PeLgasus, European Technologies for Business Ltd., Codicote, UK.
[d]EquiMoves, Inertia Technologies, Enschede, Netherlands.
[e]iPhone, Apple Inc, Cupertino, CA 95014.

Big Data and Body-Mounted Inertial Sensors

Kevin G. Keegan, DVM, MS, DACVS

Author's address: University of Missouri Veterinary Health Center, Columbia, MO 65211; e-mail: keegank@missouri.edu. © 2022 AAEP.

1. Introduction

The Q with Lameness Locator has been available to veterinarians for 15 years, and there are now 450 units in use around the world. Every year, there are new developments and improvements in hardware and software that make the veterinarian's experience easier. At the University of Missouri alone, data on thousands of clinical cases have been collected. Hundreds of thousands more cases have been evaluated by other equine clinics around the world. Only recently have practitioners begun to take advantage of these numbers, matching up lameness measurement parameters with blocking and imaging findings and with clinical data on final diagnosis.

2. Comparison of Results for Body-Mounted Inertial Sensor Assessment with Final Lameness Determination in 1,224 Equids[1]

Body-mounted inertial sensors (BMIS) are now being used to objectively evaluate lameness in horses around the world. In quadrupeds, lameness, as a clinical sign (not a disease), can be found to originate with an abnormality in a single limb, it can be bilateral but confined to either end of the body (i.e., forelimbs or hindlimbs exclusively), or it can involve a combination of (one or more) forelimbs and hindlimbs. Simultaneous, combined lameness in a forelimb and hindlimb (CFHL) has been further subdivided into compensatory and secondary lameness. Compensatory lameness develops at the opposite end of the body from the primary lameness; it is nonpathological, presumably appears simultaneously with primary lameness, and is expected to disappear with the resolution of primary lameness. Conversely, secondary lameness is probably associated with pain. It may not be detected until after primary lameness is found and will continue following the resolution of primary lameness, and both forelimbs or both hindlimbs can be involved at the same time. Compensatory lameness in horses has been well studied with kinematics,[2,3] force-measuring treadmills,[4,5] and BMIS systems,[6,7] whereas secondary lameness is a logically suspected but less studied concept supported by clinical opinion.[8]

Compensatory lameness patterns generally follow what has been referred to as the sagittal and diagonal compensatory movement principles,[2] also described as the law of sides.[9] The sagittal compensatory movement principle states that ipsilateral CFHL usually indicates primary hindlimb lameness. The diagonal compensatory movement principle states that contralateral CFHL usually indicates primary forelimb lameness. In contrast, secondary lameness patterns attributable to overloading are generally considered to be contralateral only and to occur at the same end or opposite ends of the body.

It has been shown that prevalence of forelimb-only lameness, hind-limb-only lameness, and CFHL in equids as measured by a BMIS system when trotting

NOTES

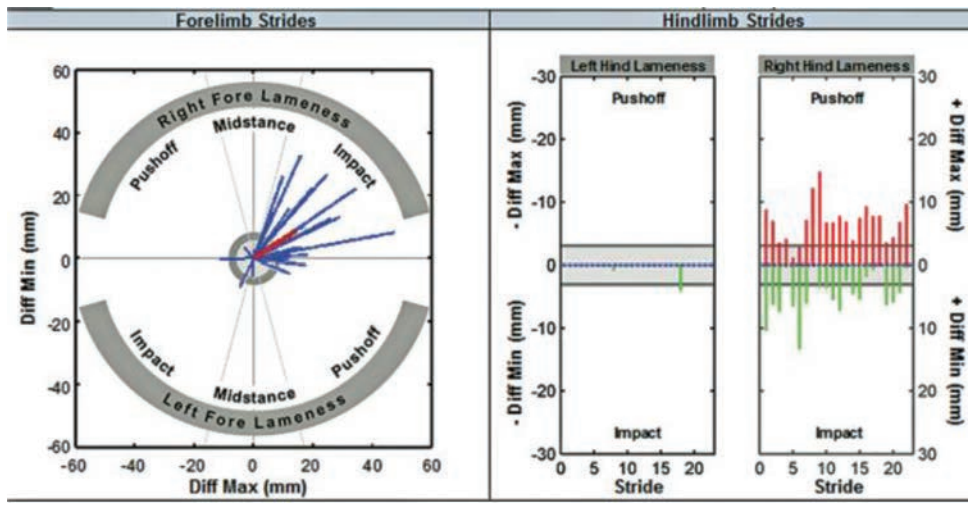

Fig. 1. Right forelimb with combined right hindlimb impact and pushoff CFHL.

in a straight line is associated with location of the cause of lameness. This information is helpful to veterinarians planning their lameness work ups.

1. A horse with CFHL where the forelimb and hindlimb lameness is ipsilateral and the hindlimb lameness is both lack of impact and lack of pushoff. This pattern had a high (86.6%) positive diagnostic rate. The primary problem is most likely in the hindlimb; 86.4% had the primary problem in the hindlimb (Fig 1).
2. A horse with CFHL where the forelimb and hindlimb lameness is ipsilateral and the hindlimb lameness is only lack of pushoff. This pattern had a moderate (62.0%) positive diagnostic rate. The primary problem is more likely to be in the hindlimb; 86.3% had the primary problem in the hindlimb (Fig 2).

It is preferable to see the prior 2 patterns (1 and 2). They have a high to moderately high positive diagnostic rate, and the good bet is that the primary problem is in the hindlimb.

3. A horse with CFHL where the forelimb and hindlimb lameness is ipsilateral but the hindlimb lameness is only lack of impact. This pattern had a high (77.9%) positive diagnostic rate, but the primary problem is almost as likely to be in the forelimb (45.2%) as in the hindlimb (33.9%) as in both (11.3%). This is considered a difficult pattern as more information is needed to decide which limb to look at or block first (Fig 3).
4. A horse with CFHL where the hindlimb lameness is ipsilateral lack of pushoff and contralateral lack of impact. This pattern did not (thankfully) occur very frequently (only 4% of all CFHL cases). Horses with this pattern were just as likely to have the primary cause of lameness in the forelimb (20%), in the hindlimb (35%), in both the forelimb and the

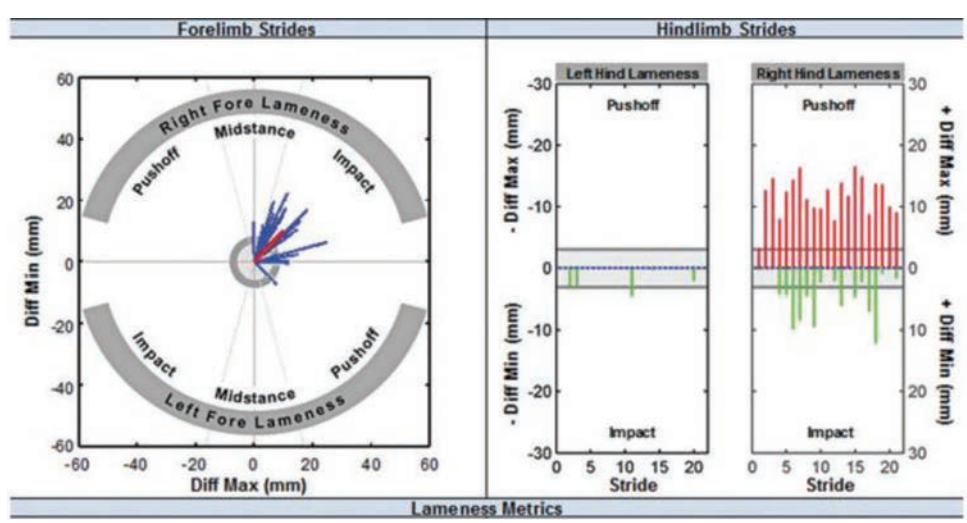

Fig. 2. Right forelimb with only right hindlimb pushoff CFHL.

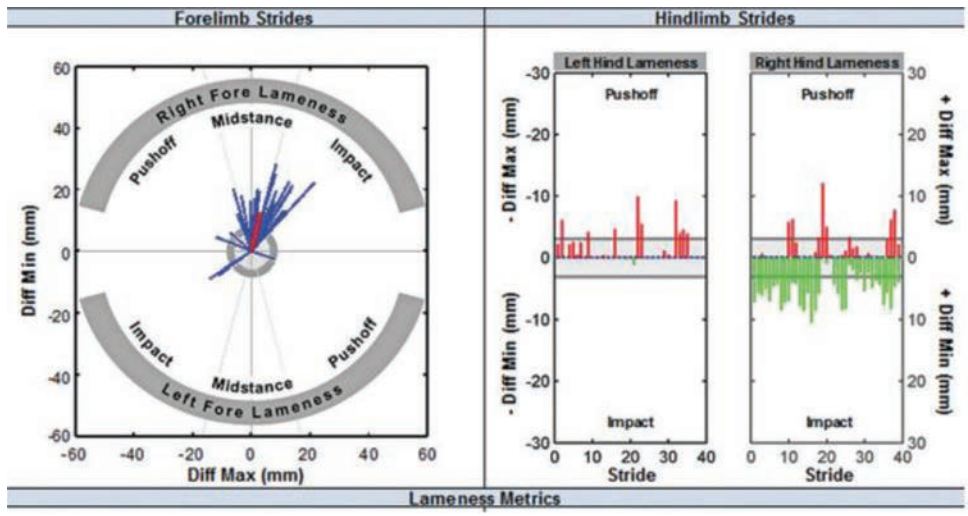

Fig. 3. Right forelimb with only right hindlimb impact CFHL.

hindlimb (25%), or not within the limbs (20%). This is considered a difficult pattern as the primary cause of lameness could just as likely be in the forelimb only, in the hindlimb only, in both the forelimb and hindlimb, or not in the limbs (Fig 4).

5. A horse with CFHL with forelimb lameness and contralateral hindlimb lameness that is both lack of pushoff and lack of impact. This pattern has a moderately high (70.6%) positive diagnostic rate. The primary problem is more likely to be in a forelimb; 78.6% of the cases had a primary cause of lameness in a forelimb (Fig 5).
6. A horse with CFHL with forelimb lameness and contralateral hindlimb lameness that is only lack of pushoff. This pattern has a moderately high (69.6%) positive diagnostic rate. The primary problem is most likely to be in a forelimb; 90.6% of the cases had a primary cause of lameness in a forelimb (Fig 6).

It is preferable to see the prior two patterns (5 and 6). They have a high to moderately high positive diagnostic rate, and the good bet is that the primary problem is in the forelimb.

7. A horse with CFHL with forelimb lameness and contralateral hindlimb lameness that is only lack of impact. Even though the majority of these cases had the primary cause of lameness in a forelimb (86.1%), this pattern had a low definitive diagnostic rate (54.5%). The only explanation for this is primary forelimb lameness with secondary hindlimb lameness, or vice versa. There is no known compensatory pattern that explains this CFHL (Fig 7).
8. Last, a horse with CFHL with forelimb lameness, contralateral hindlimb lameness that is

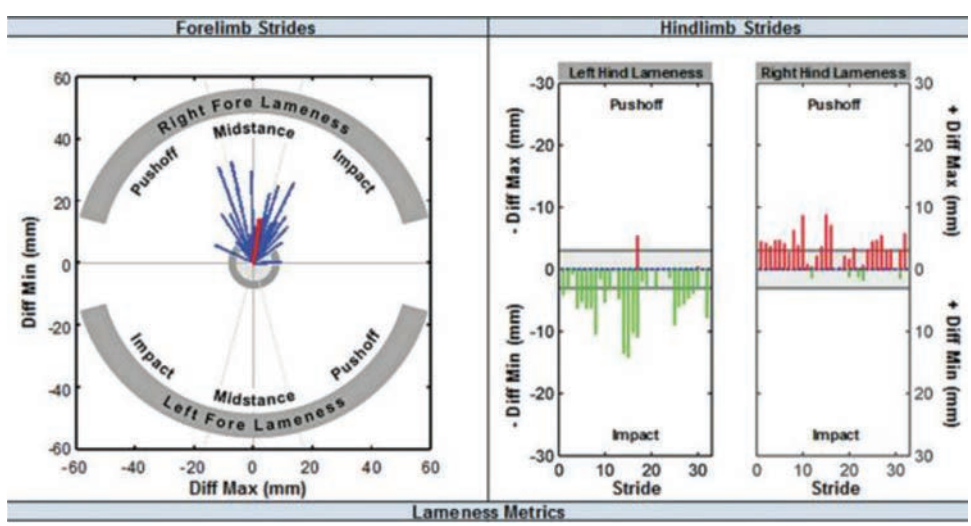

Fig. 4. Right forelimb with right hindlimb pushoff and left hindlimb impact CFHL.

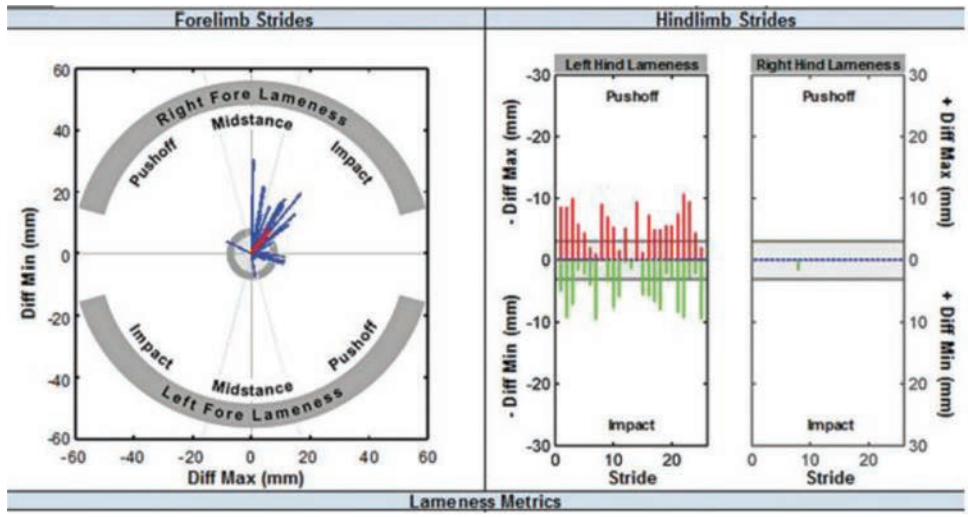

Fig. 5. Right forelimb with left hindlimb impact and pushoff CFHL.

lack of pushoff, and ipsilateral hindlimb lameness that is lack of impact. This pattern was not very common, comprising only about 7% of all cases. About two thirds of these cases had the primary cause of lameness in the forelimb and about one third in the hindlimb. The simplest explanation for the CFHL is primary forelimb lameness with compensatory contralateral hindlimb lack of pushoff and ipsilateral hindlimb lack of impact. An alternative explanation for this pattern is primary hindlimb lameness (lack of pushoff) and secondary contralateral forelimb and hindlimb lameness (Fig 8).

Most CFHL patterns seen during the initial straight-line trotting evaluation are easily explained by compensatory movement principles, and this knowledge is useful for localization of primary limb lameness in many cases. However, CFHL patterns in which hindlimb lameness is only of the impact type suggest that the diagnostic process will be more difficult.

3. Ipsi-Impact vs. Ipsi-Pushoff

In a second "big data" study, cases were either ipsi-pushoff (CFHL with forelimb lameness and ipsilateral hindlimb lameness that is only lack of pushoff) or ipsi-impact (CFHL with forelimb lameness and ipsilateral hindlimb lameness that is only lack of impact). These 2 patterns correspond to patterns 2 and 3 above. As was found earlier (see above), pattern 2 cases were more likely to have a primary hindlimb lameness, and those with pattern 3 were just as likely to have primary forelimb as primary hindlimb cause of lameness. However, interestingly, if the cause of lameness was found in a forelimb, it was more likely to be navicular disease in ipsi-impact cases and more likely to be in the foot for ipsi-pushoff cases compared to ipsi-impact cases. Alternatively, if the cause of lameness was found in a hindlimb, it was more likely

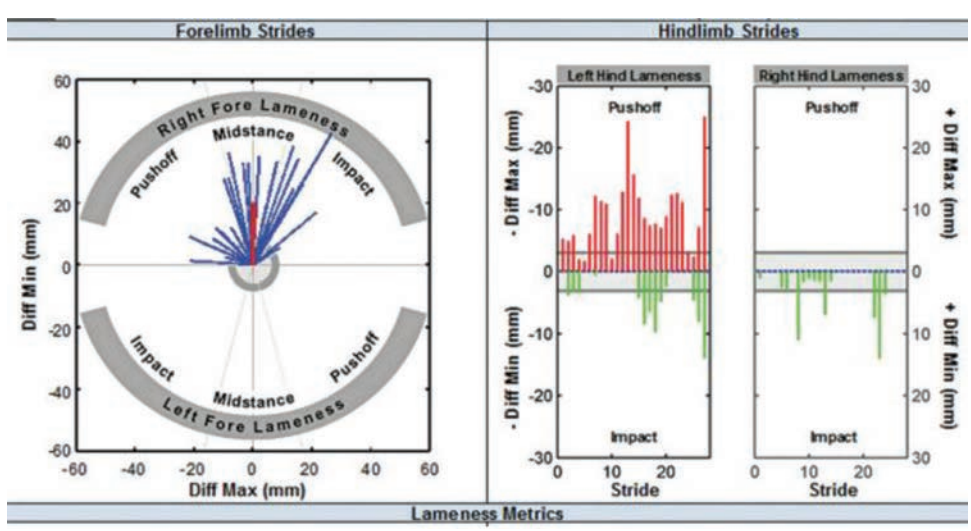

Fig. 6. Right forelimb with only left hindlimb pushoff CFHL.

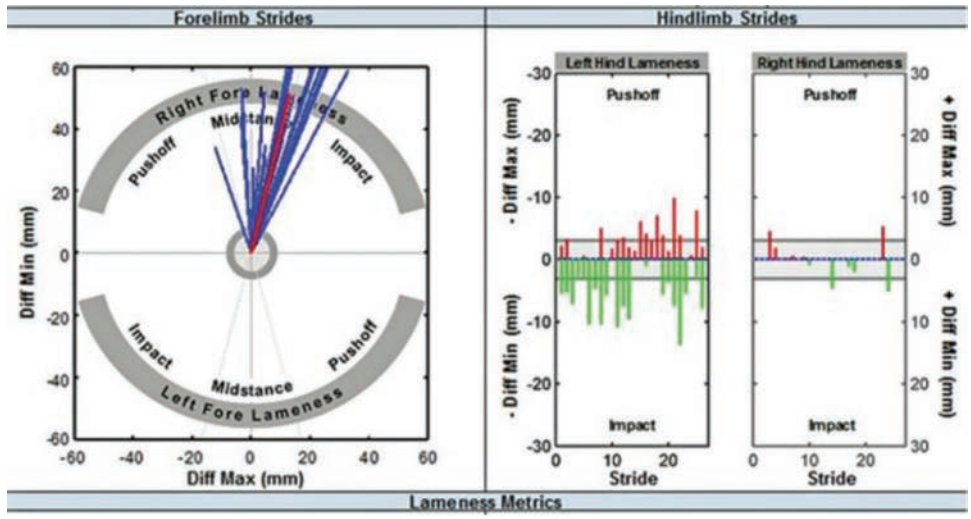

Fig. 7. Right forelimb with only left hindlimb impact CFHL.

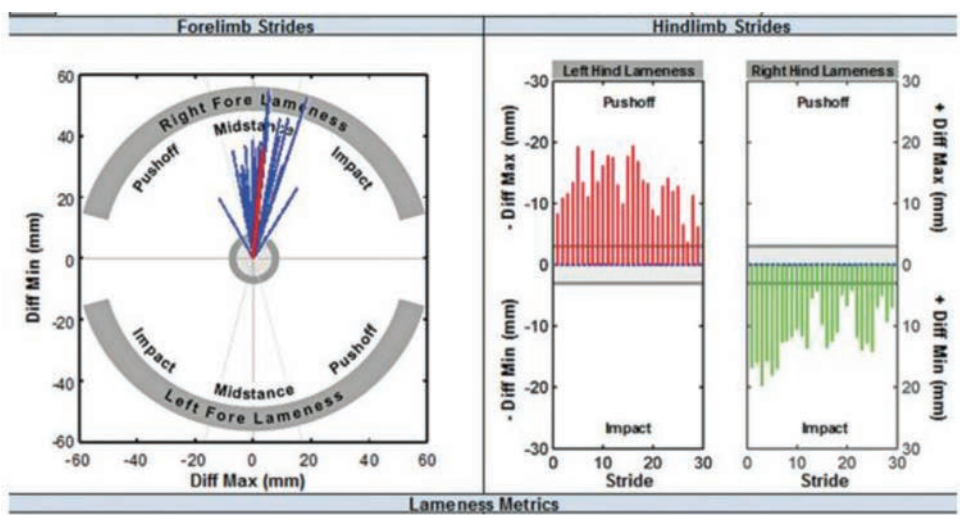

Fig. 8. Right forelimb with left hindlimb pushoff and right hindlimb impact CFHL.

to be foot, pastern, or distal tarsal joint for ipsi-impact vs. ipsi-pushoff cases and more likely to be tendon, ligament, or high-motion joint (fetlock, tibiotarsal, stifle) for ipsi-pushoff cases compared to ipsi-impact cases.

4. Conclusion

Additional studies, for example, comparing contra-impact to contra-pushoff, or more simply, hind-limb-only lameness that is mostly lack of pushoff vs. hind-limb-only lameness that is mostly lack of impact, are currently being investigated. This type of information will be valuable to practitioners for planning specific steps in some lameness evaluations, for example, which limb to block first or even which block to perform first.

Acknowledgments

Declaration of Ethics

The Author has adhered to the Principles of Veterinary Medical Ethics of the AVMA.

Conflict of Interest

Dr. Keegan is a co-developer of the algorithms, code, and hardware used in Equinosis Q with Lameness Locator; is the original founder of Equinosis; and holds a minority share. All intellectual property associated with the development of the Q with Lameness Locator is owned by the University of Missouri and licensed to Equinosis. Dr. Keegan is not a paid employee or consultant of Equinosis and receives no salary or consulting fees from Equinosis.

References

1. Reed SK, Kramer J, Thombs L, et al. Comparison of results for body-mounted inertial sensor assessment with final lameness determination in 1,224 equids. *J Am Vet Med Assoc* 2020;256:590–599.
2. Uhlir C, Licka T, Kübber P, et al. Compensatory movements of horse with a stance phase lameness. *Equine Vet J* 1997; 29:102–105.
3. Kelmer G, Keegan KG, Kramer J, et al. Computer-assisted kinematic evaluation of induced compensatory movements

resembling lameness in horses trotting on a treadmill. *Am J Vet Res* 2005;66:646–655.
4. Weishaupt MA, Wiestner T, Hogg HP, et al. Compensatory load redistribution of horses with induced weight bearing hindlimb lameness trotting on a treadmill. *Equine Vet J* 2004;36:727–733.
5. Weishaupt MA, Wiestner T, Hogg HP, et al. Compensatory load redistribution of horses with induced weight bearing forelimb lameness trotting on a treadmill. *Equine Vet J* 2006;171:135–146.
6. Maliye S, Voute LC, Marshall JF. Naturally occurring forelimb lameness in the horse results in significant compensatory load redistribution during trotting. *Vet J* 2015;204:208–213.
7. Maliye S, Marshall JF. Objective assessment of the compensatory effect on clinical hindlimb lameness in horses: 37 cases (2011-2014). *J Am Vet Med Assoc* 2016;249:940–944.
8. Ross MW. Movement. In: Ross MW, Dyson SJ, eds. *Diagnosis of lameness in the horse*. 2nd ed. St. Louis, MO: Elsevier Saunders, 2011;66–67.
9. Keegan KG. Objective assessment of lameness. In: Baxter GM, ed. *Adams and Stashak's lameness in horses*. 6th ed. West Sussex, UK: Wiley-Blackwell, 2011;159.

Use of Biometric Wearable Sensors to Identify Subtle Gait Abnormalities in Thoroughbred Racehorses

Scott Palmer, VMD, DABVP, Eq Practice*; and Hussni Omar Mohammed, BVSc, PhD

Wearable biometric sensors show great promise as a practical screening tool to detect subtle gait abnormalities in Thoroughbred racehorses before overt clinical signs of lameness are evident. Horses with subtle gait abnormalities should be examined by veterinarians. Early diagnosis of musculoskeletal injury and timely intervention can help to prevent career-ending or catastrophic injury. Authors' address: Cornell University College of Veterinary Medicine, 602 Tower Road, Ithaca, NY 14853; e-mail: sepalmer@att.net. *Corresponding and presenting author. © 2022 AAEP.

1. Introduction

Reduction of catastrophic musculoskeletal injuries in Thoroughbred (TB) racehorses is a top priority of the TB racing industry world-wide. Pre-existing musculoskeletal abnormalities are present in many of the horses that experience catastrophic injuries. Early detection of gait abnormalities associated with these conditions using subjective examinations is problematic. An objective, non-invasive and accurate screening protocol is needed to help identify subclinical musculoskeletal pathology in TB racehorses. This study aimed to determine if wearable biometric sensors can detect subtle and otherwise unrecognizable gait abnormalities in galloping TB racehorses.

2. Materials and Methods

StrideSAFE® GPS-accelerometer devices were placed in the saddlecloths of 131 TB racehorses competing at the Saratoga Race Course between July 25 and September 6, 2021. Acceleration was recorded in 3 dimensions throughout the races. Horse recordings were used to create acceleration curves for individual horses that were compared with mean reference acceleration curves of elite sound TB racehorses. Horses with acceleration curves that were within 2 standard deviations (SD) of the reference mean were classified as green. Horses with acceleration curves that were between 2 and 2.9 SD from the reference mean were classified as yellow. Horses with acceleration curves of 3 SD or greater from the reference mean were classified as red. High-speed exercise records for these 3 groups of horses were obtained for a 4-month period following their analyzed race. Seven high-speed exercise variables were compared, using descriptive statistics and the Independent-samples Kruskal-Wallis test ($p \leq 0.05$).

3. Results

The age distribution of the horses in this study was consistent with the general horse population of New

Research Abstract—for more information, contact the corresponding author

NOTES

York TB racetracks and there was no significant difference in the mean age distribution among the horses with red, yellow, and green alert classifications. In the 4-month follow-up period following the analyzed races, horses with a red alert classification took significantly longer to resume racing than horses with either a yellow or a green alert classification. Horses with a red alert classification raced fewer times after the analyzed race than the horses with a green alert classification. Horses with a red alert classification completed fewer number of high-speed furlong events (official timed workouts and races) after the analyzed race than horses with a green alert classification.

4. Discussion

StrideSAFE® wearable biometric sensors were able to reliably detect subtle gait abnormalities in galloping TB racehorses. There was no association between age and the finding of subtle gait abnormalities in this study population. Horses with subtle gait abnormalities in their analyzed race were unable to resume training and racing to a degree that was directly proportional to their deviation from reference mean acceleration curves of sound elite racehorses. Since lameness is a gait abnormality, and musculoskeletal injury is the most common cause of time lost from training and racing of TB racehorses, it is likely that the subtle gait abnormalities recorded in the red alert horses in this study were an indication of subclinical lameness. StrideSAFE® wearable biometric sensors show great promise as a practical screening tool to detect subtle gait abnormalities before overt clinical signs of lameness are evident. Early diagnosis of subtle musculoskeletal injury and timely intervention are likely to keep horses in training in a safe manner and help to prevent career-ending or catastrophic injury.

Acknowledgments

Declaration of Ethics

The Authors have adhered to the Principles of Veterinary Medical Ethics of the AVMA.

Conflict of Interest

The Authors have no conflicts of interest.

How to Integrate a Novel Objective Gait Analysis System into Daily Practice

Marcus Swail, BVMS, Cert Eq Sports Med, MRCVS

Author's address: EquiVET Ireland, Feighcullen, Rathangan, Kildare R51 W668, Ireland; e-mail: marcusswail@gmail.com. © 2022 AAEP.

1. Introduction

Lameness investigation and diagnosis represents a challenge to the equine practitioner. A reasoned and methodical approach is a key aspect of any lameness investigation. Traditionally, this has involved a careful clinical examination of the horse at rest, then proceeding to examination of the horse moving to visually assess lameness or asymmetry. Additional techniques such as flexion tests or examination of the horse in a circle, on different surfaces, or under saddle can provide further useful information. Much of the above relies upon the skill and experience of the individual practitioner and is therefore subjective. The search for a more objective approach to the subject has resulted in the development of commercially available objective gait analysis (OGA) systems. These systems typically employ either inertial motion sensors that must be attached to the horse (kinematic analysis) or motion capture of reflective markers (also attached to the horse) by multiple cameras.

As a sports medicine clinician, the author has been looking at these systems with keen interest for some time. However, either the extra time and work associated with fitting sensors to a lameness case or the prohibitive cost of a multicamera system for a smaller practice have ultimately made the acquisition of an OGA system unattractive. This presentation describes how a novel, commercially available, sensor-free OGA smartphone application[a] can address these issues. It achieves this by providing objective data to complement the clinical judgment of the busy practitioner using only their smartphone.

The app has been developed by artificial intelligence engineers, veterinary researchers, and clinicians among the veterinary faculty at the Swedish University of Agricultural Sciences, Uppsala, Sweden. It has been validated[1] against a recognized "gold standard" multicamera motion capture system.[b] In contrast to the system against which it was validated and others currently commercially available, it dispenses with having to attach motion sensors or reflective markers to the horse. These are replaced by an algorithm that reads the symmetry of the horse's gait directly from analysis of video of the horse moving, using deep neural networks. The video is collected and processed via this app that is downloaded to the veterinarian's smartphone. The app then produces easily interpreted information in the format set out in the two examples below (Fig. 1). This facilitates easy and direct integration of the app into the daily routine of the busy equine practitioner.

2. Materials and Methods

The OGA app provides data to the clinician using only a camera stand and a smartphone. The smartphone (with the app downloaded) is secured on a stable platform just above eye level and centered on the area where the horse trots up in hand (Fig. 2). Video recording is started within the app, and the horse trots in hand away from and back toward the smartphone. For a typical trot-up length of 100–130 feet, trotting

NOTES

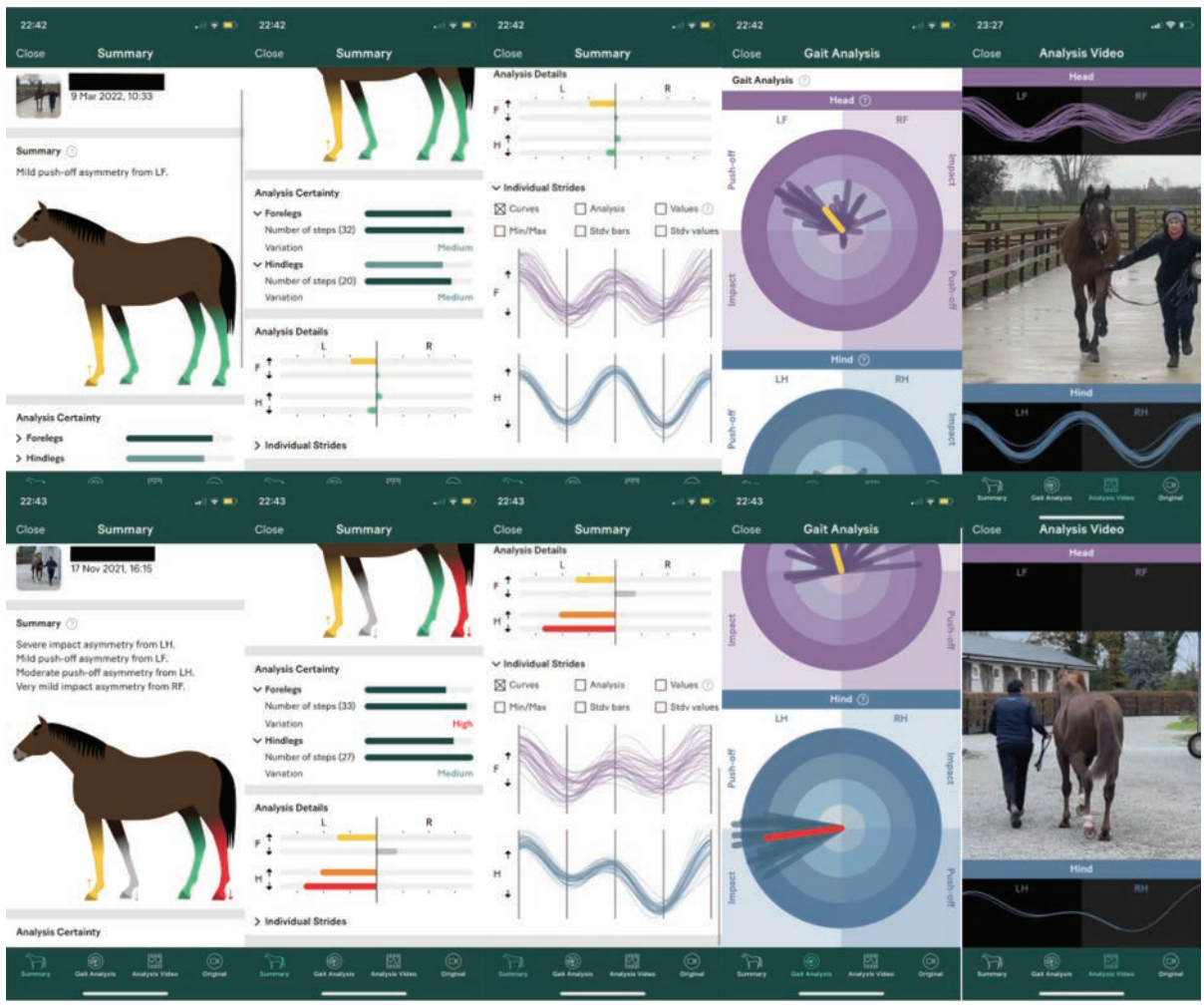

Fig. 1. Two examples of information produced by the OGA app.



Fig. 2. The smartphone (with the app downloaded) is secured on a stable platform just above eye level and centered on the area where the horse trots up in hand.

the horse away and back twice will collect sufficient data to return reliable results. Given that this is a common starting point for many clinicians, it represents no extra work beyond pressing record on the smartphone app. The video is then uploaded and processed by the bespoke algorithm, and a result is returned within approximately 5 minutes. It provides data on the affected limb(s) using a simple color-coded

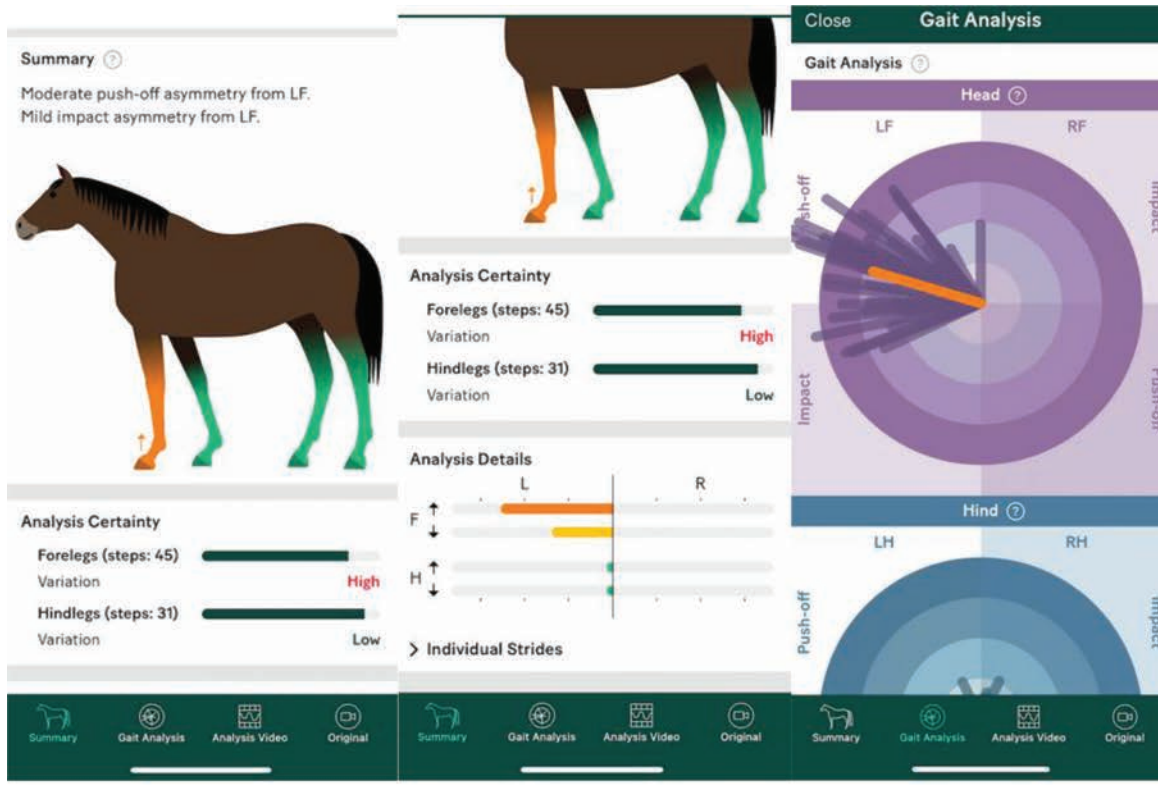

A

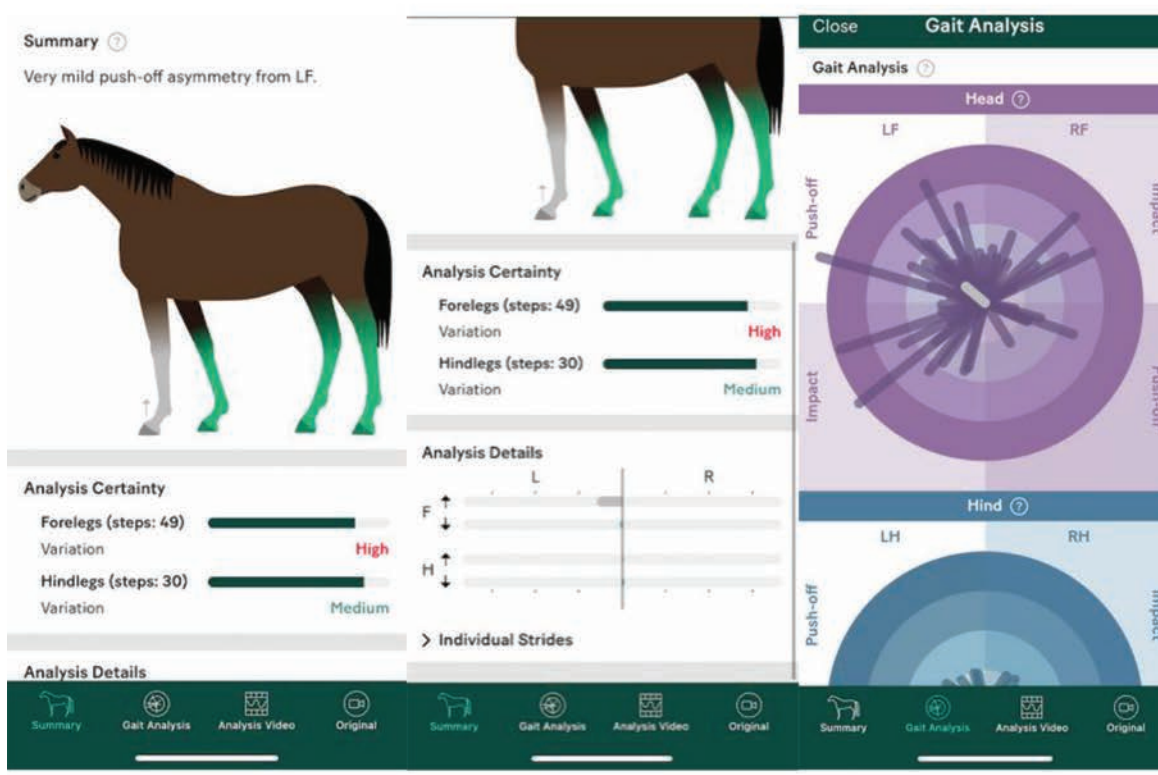

B

Fig. 3. Information provided by the app. A, Baseline data; B, Postblocking.

Fig. 4. MRI image demonstrating the injury to the collateral ligament (arrow).

diagram showing the degree of lameness, character of lameness (impact/push off), etc. (Fig. 1). The turnaround time allows almost real-time objective data to be made available. It also lends itself to the sequential analysis of a horse where diagnostic analgesia is employed to localize the lameness, a common scenario. Typically, one can examine a horse, upload the video for analysis, perform diagnostic analgesia, and have the results back and be ready to use the app again to assess the outcome. This is particularly helpful in the case of a low-grade lameness or where diagnostic analgesia improves but does not completely resolve a lameness.

3. Results

This app has become part of the daily routine of 3 of the 4 clinicians in the author's practice. Case-based examples of the application in practice are presented as follows:

Case 1: 2011 Irish Sport Horse Showjumper

History

This mare had a forelimb lameness of 4 months duration, which started the day after a competition. She had been managed with restricted exercise during that period, and the distal interphalangeal (DIP) joint had been medicated historically by another clinician. The lameness was reportedly unchanged during that period, showing no significant improvement.

Resting Exam

A mild effusion was present in the left fore DIP joint.

Moving Exam

A mild (grade 1/5) left foreleg lameness was present in both a straight line and in a circle on both firm and soft surfaces. A palmar digital nerve block abolished the lameness, with the information provided by the app corroborating that view (Fig. 3). This was helpful in confirming the clinical impression in this case given the relatively subtle visual nature of the lameness. The app provides a color-based interpretation of the lameness in a summary page. The degree of lameness decreases from red, through orange, yellow, gray, and then to green, where no asymmetry is present. This can be helpful in discussion with clients as it is visually simple and generally well received. There is also more in-depth data within the app relating to each limb, each stride analyzed by the app, and whether the lameness is characterized more as an impact or push-off lameness. Note in this case that the lameness is characterized as orange, improving to gray following the block.

Imaging

A small osteophyte was present on the palmaroproximal aspect of the navicular bone. However, this was considered insufficient to account for the lameness. Given the duration of the lameness and the lack of response to rest and medication of the DIP joint, the mare was referred for advanced imaging in the form of magnetic resonance imaging (MRI). This demonstrated the presence of a DIP joint collateral ligament injury (Fig. 4).

Case 2: 2018 National Hunt Thoroughbred Racehorse

History

This filly went lame in front some 3 weeks prior to presentation. She had a short period of rest, came sound, resumed exercise, and went lame again.

Resting Exam

No localizing signs.

Moving Exam

A moderate (grade 2/5) left foreleg lameness was present. A combined low 2-point and abaxial sesamoid nerve block did not alter the lameness. A subcarpal nerve block abolished the lameness. The clinical impression at this time was that a very subtle right foreleg lameness was now present. This was corroborated by the data provided by the app, increasing clinician confidence in the view that the lameness was bilateral in this case (Fig. 5).

Imaging

Ultrasound examination demonstrated findings consistent with proximal suspensory desmitis in both forelimbs. In addition, a small avulsion was present in the left fore proximal cannon (Fig. 6).

This filly was subject to restricted exercise for 6 weeks, at which time she was sound. She resumed an increasing plane of exercise and returned to training uneventfully.

Case 3: 13-Year-Old Irish Sport Horse 3-Day Eventer

This horse was long listed for selection to compete at the European Championships 2022, Herning, Denmark. While ongoing monitoring of these horses is a regular feature of their management

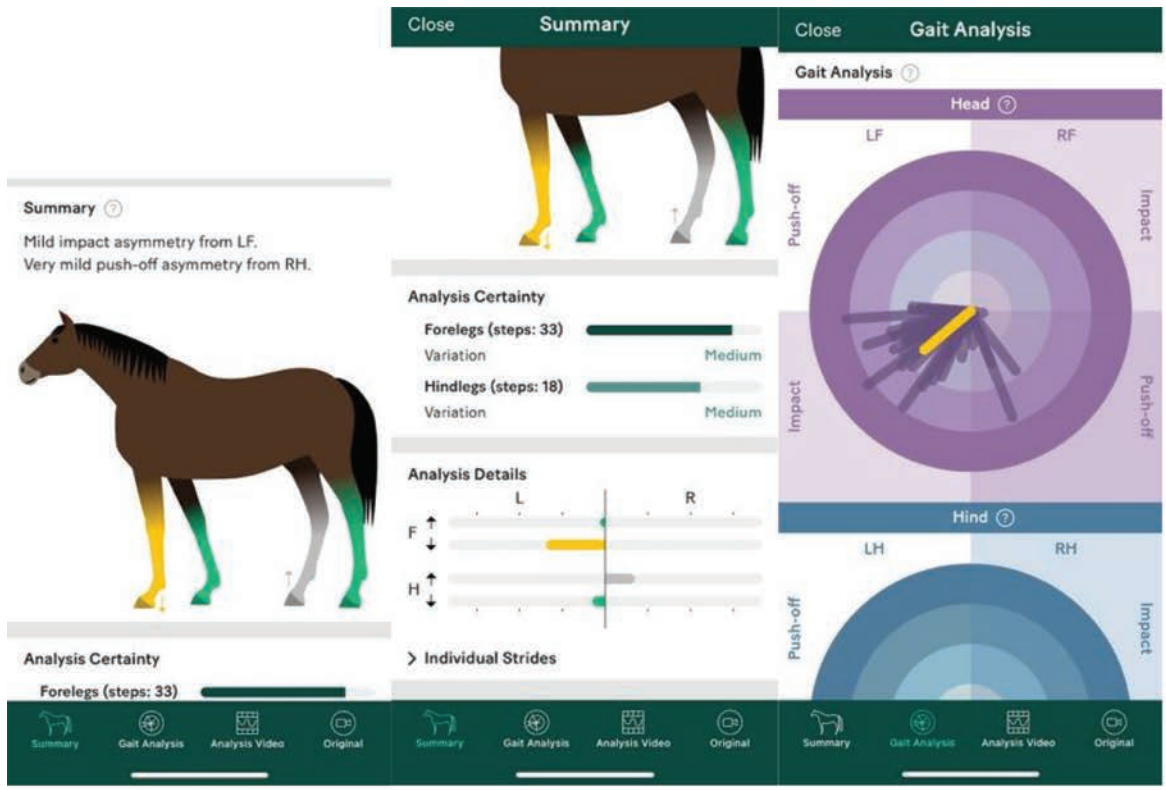

A

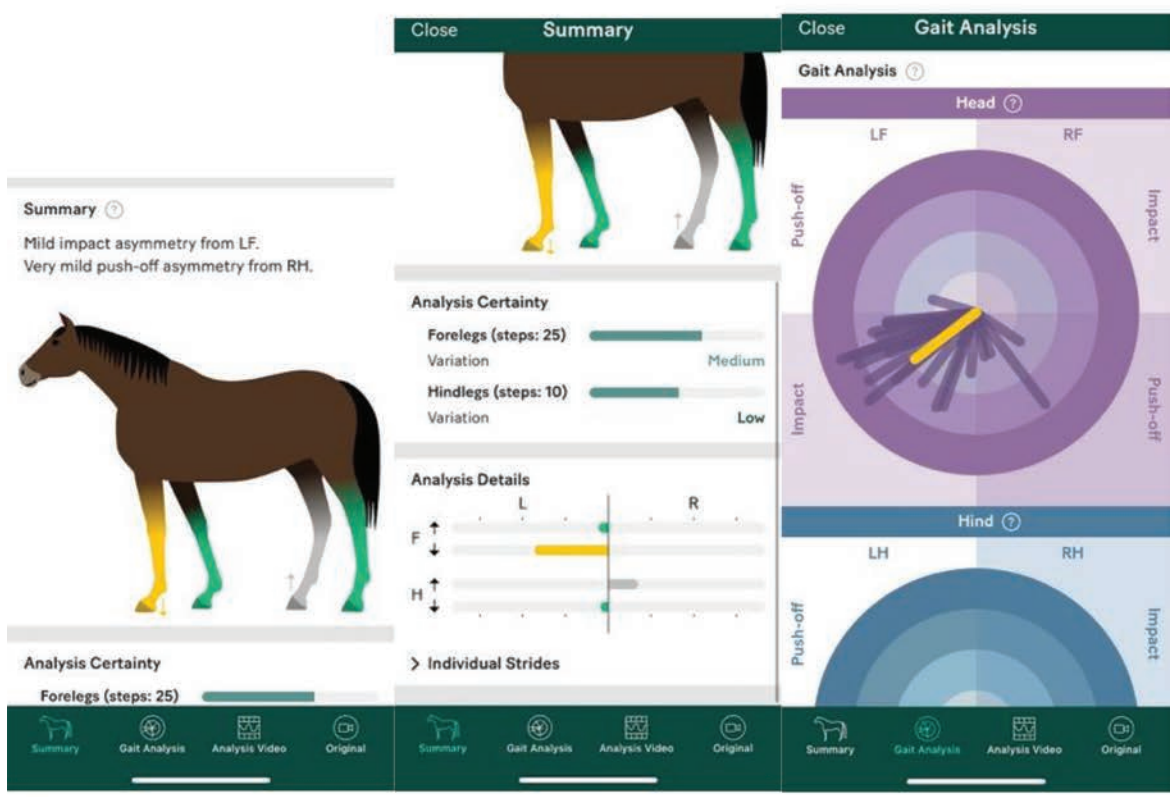

B

Fig. 5. Data provided by the app. A, Baseline; B, Following a combined low 2-point and abaxial sesamoid nerve block; C (see next page), Following a subcarpal block.

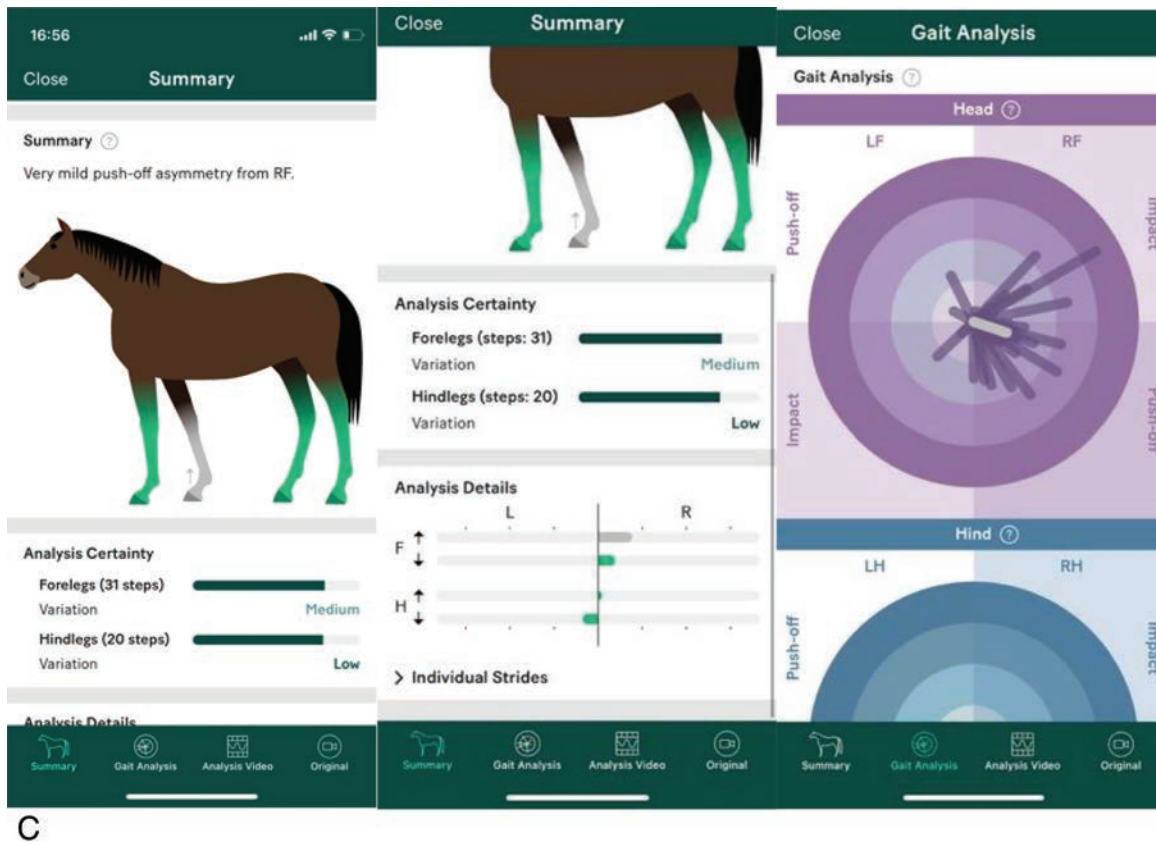

Fig. 5. Continued.

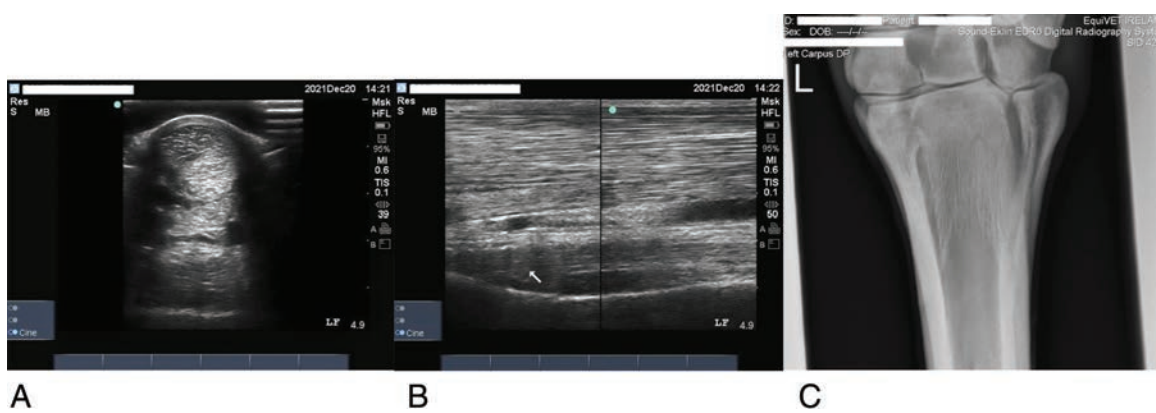

Fig. 6. A and B, Ultrasound images showing proximal suspensory desmitis in the left forelimb. C, Small avulsion present in the left fore proximal cannon.

within the team structure, this has been augmented in this case with the OGA app. Thus far, the picture was as follows:

The initial assessment was satisfactory where the clinical picture was normal, with the app showing a subtle (gray) left hindlimb issue. This was deemed not clinically relevant at this time (Fig. 7).

The second assessment was still clinically satisfactory, although the OGA app now showed the involvement of subtle (gray) findings in two limbs (Fig. 8).

The third assessment was less satisfactory, where the forelimb lameness was now becoming clinically apparent and the OGA app was showing an increase in the frequency of lamer steps in the right foreleg, albeit it still ranked it "gray" overall (Fig. 9).

This combined clinical and OGA app finding prompted further investigation, which resulted in treatment of the right fore (DIP joint) and left hind (tarsometatarsal) joints. This resulted in a satisfactory picture at the most recent assessment day (Fig. 10).

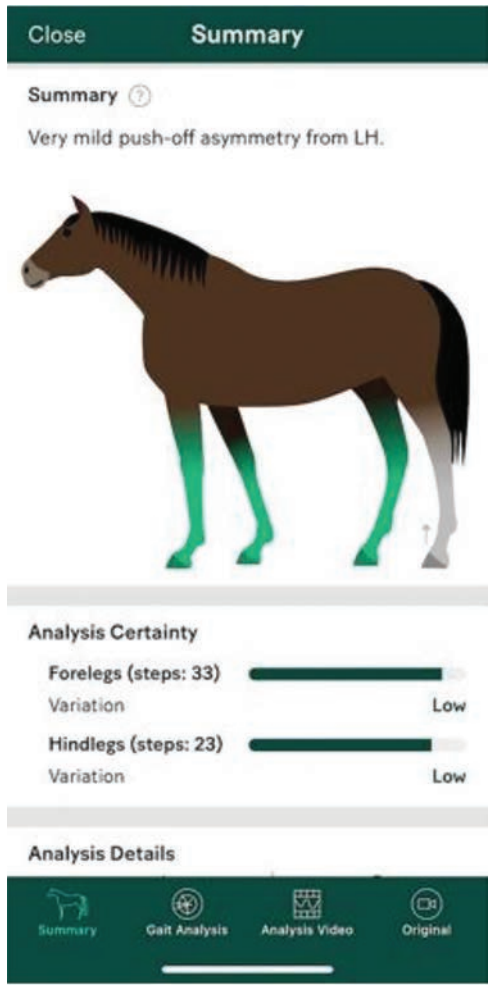

Fig. 7. The OGA app showing a subtle left (gray) hindlimb lameness.



Fig. 8. The OGA app showing subtle findings in two limbs.

This ability to build up an objective ongoing picture within the OGA app is an interesting aspect of it. Additional functionality (Fig. 11) has just been added to the app to allow the owner to video the horse at home as follows:

The video is taken by the owner, after which it automatically uploads to the horse's file on the veterinarian's app. The new data is available only to the veterinarian for interpretation. This, therefore, aids ongoing monitoring of an athlete. In addition, this functionality would seem to lend itself well to follow-up assessment of response to treatment in a patient where the initial examination included analysis with the OGA app.

4. Discussion

OGA has been a strangely divisive issue within the profession. Proponents of it have sought to demonstrate that it is superior to the clinician.[2] This has led to some colleagues viewing it as a threat. Opponents have pushed back against this view, pointing out that it is not without its drawbacks and limitations.[3,4] The author favors the view that the information provided by any OGA system is exactly that—a piece of information to be interpreted by the clinician. As a generalization, the more useful information that is available when progressing a lameness case, the more likely an accurate diagnosis will be achieved. OGA should be viewed through this lens, as a complementary tool similar perhaps to x-ray, ultrasound, or MRI.

It is the author's experience that this application represents a reliable, inexpensive, user-friendly, sensor-free method of collecting objective gait measurements for the busy practitioner. It has become integrated into this practice because it provides additional, rapidly available, easily accessed information. There is no requirement to attach sensors or reflective markers to the horse, nor to pair these to a tablet or laptop to access the data as is the case with other systems. It can therefore be used as easily in ambulatory practice as it can in a clinic setting. It can be particularly useful in the investigation of subtle or multilimb lamenesses, particularly where regional anesthesia is employed to localize the lameness. Additionally, it allows the collection of a database of information over a period of time on an equine athlete. This facilitates ongoing objective monitoring of a horse over a prolonged period, which

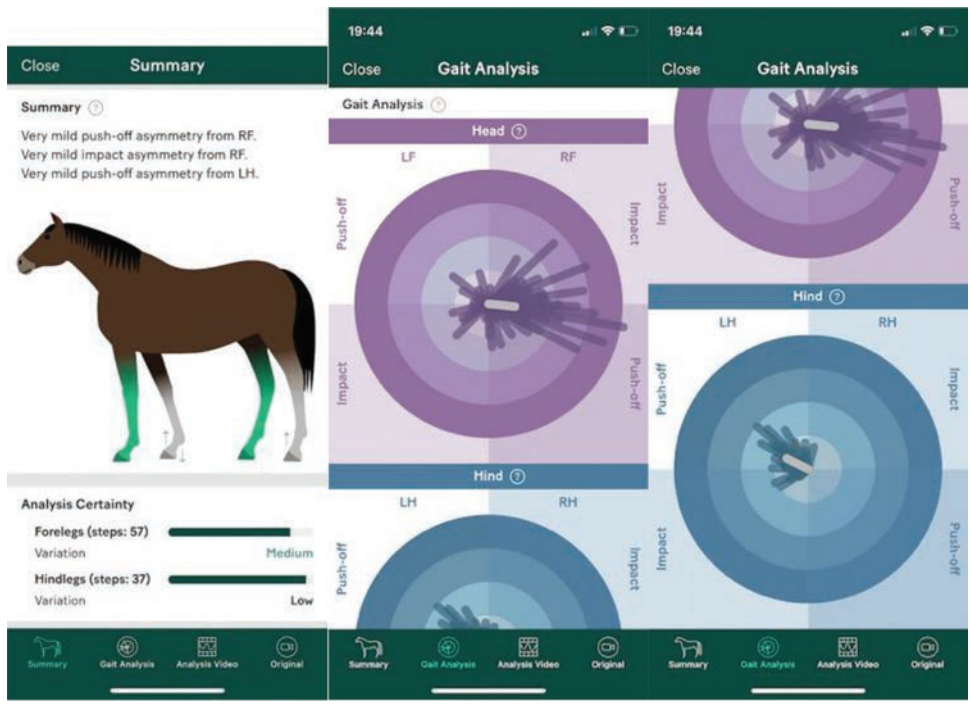

Fig. 9. The forelimb lameness clinically apparent with an increase in the frequency of lamer steps in the right foreleg.

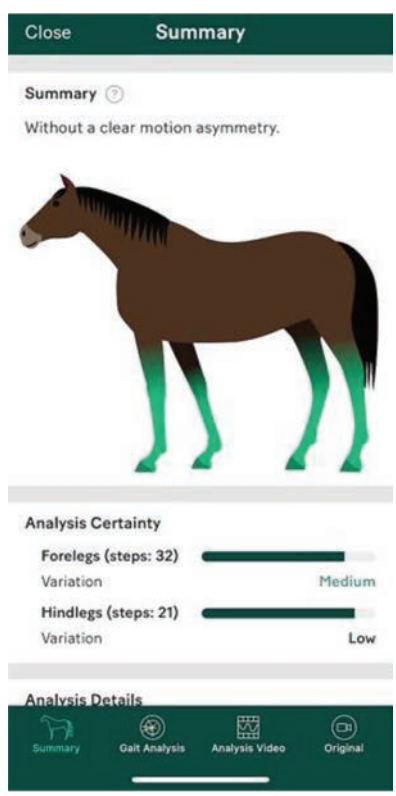

Fig. 10. Picture at the most recent assessment day.

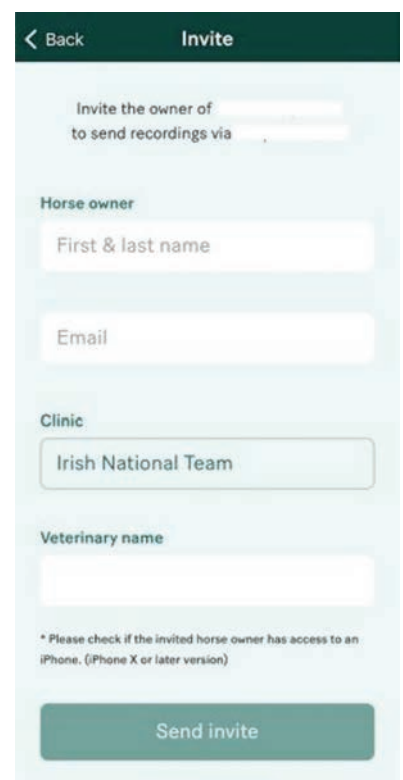

Fig. 11. Additional functionality allows invitation of the owner to allow follow-up analysis of the horse at home.

can be helpful in interrogating a loss of performance, for example. Clients like the concept and the way the results are presented in a simple, color-coded fashion. In summary, this app fits well into practice routine because it is easy to use and provides useful additional information without adding extra work to an already busy schedule.

Acknowledgments

The Author would like to thank Professor Lars Roepstorff, with whom a chance meeting at the Tokyo Olympic Games set in train events that led to the concept of this presentation, and the Sleip AI team, Dr. Elin Hernlund, Selma Claar, and Axel Nyström.

Declaration of Ethics

The Author has adhered to the principles of veterinary medical ethics of the AVMA.

Conflict of Interest

The Author has no conflicts of interest.

References and Footnotes

1. Hernlund, et al. Comparison of a mobile phone computer vision application to optical motion capture for lameness quantification, in *Proceedings*. Int Conf on Equine Exercise Phys 2022.
2. McCracken MJ, Kramer J, Keegan KG, et al. Comparison of an inertial sensor system of lameness quantification with subjective lameness evaluation. *Equine Vet J* 2012;44:652–656.
3. Bathe AP, Judy CE, Dyson S. Letter to the editor: Do we have to redefine lameness in the era of quantitative gait analysis. *Equine Vet J* 2018;50:273–273.
4. Dyson S. Recognition of lameness, man vs machine. *Vet J* 2014;201:245–248.

[a]Sleip AI, Stockholm, Sweden. www.sleip.com.

[b]Qualisys AB, Motion Capture Systems, Goteborg, Sweden. https://www.qualisys.com/applications/equine-animal/qhorse/.

The Physiology of Pain

Kristen Messenger, DVM, PhD, DACVAA, DACVCP*; and
Peter R. Morresey, BVSc, MVM, MACVSc, DACT, DACVIM (LA), CVA

Pain perception depends on the coordination of a complex relay of interconnections at all levels of the nervous system. Peripheral receptors transduce pain stimuli and relay this centrally through synapses in the spinal cord, medulla, hindbrain, thalamus, and cortex. Authors' addresses: North Carolina State University, College of Veterinary Medicine, Raleigh, NC 27607 (Messenger); Rood and Riddle Equine Hospital, PO Box 12070, Lexington, KY 40580 (Morresey); e-mails: kmmessen@ncsu.edu; pmorresey@roodandriddle.com. *Corresponding and presenting author. © 2022 AAEP.

1. Introduction

Pain is defined as "an unpleasant sensory or emotional experience associated with actual or potential tissue damage, or described in terms of such damage."[1] It involves a physiological sensation with an associated behavioral response to that sensation. Pain is somewhat unique in that diverse stimuli can elicit a complex multifaceted response, in contrast to more conventional sensations that are less varied in their generation and response. A thorough understanding of the incitement and generation of a pain response is necessary to formulate a rationale and comprehensive therapeutic plan.

2. Components of Pain Transduction and Signaling

The perception of pain can be divided into three main stages: pain stimulus, signal transmission from the periphery to the dorsal horn via the peripheral nervous system (PNS), and transmission of signals to the thalamus and regions of the cortex via the central nervous system (CNS). Both ascending and descending pathways are present.

Peripheral

Pain can be considered a protective mechanism that allows the animal to both detect and respond to injury or threats to its survival. The skin is the site of the majority of the damage sensing mechanisms, being the boundary between the animal and the external environment.

There are multiple nerve fibers involved in the transmission of pain.[2] Sensory (afferent) neurons are classified into three main groups (A, B, and C) based on function, axon diameter, and the velocity of a conducted impulse.

Group A

Group A nerve fibers are myelinated. They can be further subdivided into Aα, Aβ, Aγ, and Aδ with different sets of characteristics each. These fibers generally terminate in the dorsal horn of the spinal cord.

Type Aα includes both Type Ia and Ib sensory fibers from muscle spindle endings and Golgi tendon organs. They are involved in proprioceptive function.

NOTES

Type Aβ includes low-threshold slow- or fast-adapting cutaneous mechanoreceptors and afferent stretch receptors.

Type Aγ includes fibers from the stretch receptors.

Type Aδ includes thermal and mechanical nociceptor afferent fibers.[3,4] They are responsive to short-duration, sharp-pain stimuli. Aδ fibers are the smallest diameter myelinated nerves and have a relatively fast conduction velocity.

Group B

Group B nerve fibers are preganglionic myelinated nerve fibers with midrange conduction velocities. They include fibers of the autonomous nervous system and general visceral afferent system.

Group C

Group C nerve fibers are unmyelinated small-diameter fibers with relatively slow conduction velocities. This group includes nerve fibers at the dorsal roots and postganglionic fibers of the autonomous nervous system. All these fibers are mainly nociceptive in function, carrying sensory information and assembling the majority of the afferent nociceptive information that then enters the spinal cord. C fibers terminate in the gray matter of the spinal cord.[3]

C fiber nociceptors are activated by thermal, mechanical, and chemical stimuli. Activation can be achieved from poorly localized stimuli, which includes burning sensation of the skin. Pain intensification may occur due to "wind up" whereby constant (same intensity) repeated stimulation of the C fibers can induce a dramatically increased magnitude and duration of response after the stimulus has ceased.

Once activated, the receptor stimulus at nerve terminals is transmitted by both Aδ and C fibers along peripheral nerves to the spinal cord. Modulated synapses subsequently relay the signal, allowing its ascent to the higher levels of the CNS to reach consciousness and produce an appropriate behavioral response. In this manner, peripheral damage can be sensed by the animal. Nociception begins at the terminal end of pain sensitive neurons, which project from the spinal cord to the periphery.[3]

The Aδ and C fibers have a wide range of receptors on their terminals. Transient receptor potential cation channel subtypes each activate in the presence of different stimuli including mechanical, heat, cold, and toxins.[4] A transient, local action potential is generated in response to appropriate receptor binding with the resultant action potential either up- or downregulated by the actions of receptors and ligands at the peripheral nerve endings. The signal is amplified via regenerative sodium channels and inhibited by recruitment of potassium channels.

C-fiber conduction is slower than A-fiber conduction. The C fibers are responsible for sustained burning sensations and pain that may be experienced after removing a noxious stimulus. A subgroup of C fibers is only active under specific conditions and can be categorized into either mechanosensitive or mechanoinsensitive nociceptors. The mechanoinsensitive nociceptors (referred to as silent) are so named due to their lack of response following mechanical or electrical stimuli.[5] Comparatively, the Aδ fibers conduct impulses faster and transmit sharp or intense pain sensations.

Central

The transmission of pain is dependent on the balance of the excitatory and inhibitory inputs to the somatosensory system. Once delivered to the level of the CNS, a number of regions are involved including the spinal cord, the brainstem (midbrain, medulla oblongata, and the pons), and the cortical regions (cerebral cortex).

The dorsal horn of the spinal cord integrates inputs entering the spinal cord. These inputs include the primary afferent neurons and the local interneuron networks. Descending signals are also contained within this region. Within the ascending system, primary afferent nociceptors transmit noxious stimuli to projection neurons in the dorsal horn of the spinal cord. A number of these projection neurons subsequently relay this information proximally to the thalamus and somatosensory cortex along the spinothalamic tract. This transmits the intensity and location of the noxious stimulus.

The spinothalamic tract is within the white matter of the spinal cord. It is composed of two parts. The lateral spinothalamic tract is involved in transmission of pain and temperature sensation. The ventral spinothalamic tract carries information related to touch and firm pressure.

Other projection neurons contribute to the pain experience via contacting the cingulate and insular cortices via connections in the parabrachial nucleus and the amygdala. This ascending information accesses the neurons of the periaqueductal gray (PAG) and rostral ventral medulla (RVM) within the midbrain to contact the descending feedback systems to regulate the output from the spinal cord and modulate pain.[4] The fundamental function of the PAG is to integrate information obtained from higher centers of the brain (hypothalamus, amygdala, and frontal lobe) and ascending nociceptive inputs from the dorsal horn. This nociceptive information from the dorsal horn of the spinal cord is regulated by the PAG via the projection neurons to the RVM and dorsolateral pontine tegmentum.

The RVM is able to both inhibit and facilitate nociceptive input. Inhibition is achieved through low-intensity electrical stimulation or low concentrations of stimulatory neurotransmitters. The endogenous opioid and cannabinoid systems and other neurotransmitters, such as 5-hydroxytryptamine and norepinephrine, are abundant throughout the PAG and RVM pathways. Pain amplification via the RVM has been implicated in the development of central sensitization and secondary hyperalgesia.[6,7] Disordered descending influences from the brainstem on nociceptive afferent information may contribute to abnormal pain perception in both functional pain disorders and neuropathic pain.[8]

3. Neuropathic Pain

Neuropathic pain may be described as "pain arising as a direct consequence of disease affecting the somatosensory nervous system."[9] Following nerve injury, changes in the sensory transmission of pain occur. The expression of neurotransmitters, changed presence of neuromodulators, altered receptors, changes in ion channels, and altered structural proteins have been described.[9]

Following nerve injury, physiological changes can occur. An increase in sodium ion channels at the site of injury and along the axon results in foci of hypersensitivity. Also, the development of α1-noradrenergic receptors in both affected as well as unaffected neurons in the vicinity of damage occurs. This mechanism enables the sympathetic nervous system (via noradrenergic neurons) to have an excitatory and therefore amplifying effect on pain-transmitting neurons.

Following injury, afferent pain neurons may also affect descending analgesic pathways that inhibit pain. The inhibitory neurons themselves become inhibited, accentuating the sensation of pain. The density of both gamma-aminobutyric acid and opioid receptors may be reduced following injury to an afferent pain neuron.[10] Hypertrophy and activation of glial cells may occur following injury to neurons, and the resulting activation leads the dorsal horn microglia to produce proinflammatory cytokines (interleukin-1, interleukin-6, and tumor necrosis factor α).[11]

Demyelination of nerves lead to hyperexcitability. Damaged Schwann cells, similar to dorsal horn glial cells, may release proinflammatory mediators including the interleukins and tumor necrosis factor α. These contribute to regional activation of sensory fibers.[12]

Neuropathic pain may be induced by degenerative lumbosacral lesions, spinal cord injuries, intervertebral disc herniation, discospondylitis, vertebral osteomyelitis, and immune-mediated nervous system inflammation.[9]

4. Visceral Pain

Visceral pain is often poorly localized in contrast to somatic pain (pain related to skin, tissue, or muscles). Visceral pain is associated with mechanical stimuli such as stretching of the mesentery or visceral capsules, ischemia (with resulting hypoxia and regional lactic acid formation), or chemical or thermal stimulus.

In contrast to somatic pain, visceral pain displays no distinction between Aδ and C fibers.[13] Visceral pain is also coupled with tonic increases in somatic muscle tone. Strong autonomic responses are generated including changes in heart rate and blood pressure.[14] Within the spinal cord, the dorsal columns (gracile and cuneate fasciculi) are more important than the spinothalamic tract in transmitting nociceptive signals from viscera.[15]

5. Summary

Pain is complex in generation, transduction, perception, and response. Animals vary in actions when suffering pain, this being a factor of individual tolerance and whether the pain is acute and unexpected or chronic with some degree of accommodation for the repeated stimulus. Multiple levels and components of the neurological system are involved in the physiology of pain, these being subject to the effects of other body systems and events. The reader is referred to excellent reviews by Muir and Woolf[16] and Lemke.[17]

Acknowledgments

Declaration of Ethics

In writing this review, the Authors have adhered to the Principles of Veterinary Medical Ethics of the AVMA.

Conflict of Interest

The Authors have no conflicts of interest.

References

1. Merskey HE. Classification of chronic pain: Descriptions of chronic pain syndromes and definitions of pain terms. *Pain* 1986;3:226.
2. Smith ESJ, Lewin GR. Nociceptors: A phylogenetic view. *J Comp Physiol A Neuroethol Sens Neural Behav Physiol* 2009;195:1089–1106.
3. Dubin AE, Patapoutian A. Nociceptors: The sensors of the pain pathway. *J Clin Invest* 2010;120:3760–3772.
4. Basbaum AI, Bautista DM, Scherrer G, et al. Cellular and molecular mechanisms of pain. *Cell* 2009;139:267–284.
5. Schmidt R, Schmelz M, Forster C, et al. Novel classes of responsive and unresponsive C nociceptors in human skin. *J Neurosci* 1995;15:333–341.
6. Urban MO, Gebhart GF. Supraspinal contributions to hyperalgesia. *Proc Natl Acad Sci U S A* 1999;96:7687–7692.
7. Urban MO, Gebhart GF. Central mechanisms in pain. *Med Clin North Am* 1999;83:585–596.
8. Porreca F, Ossipov MH, Gebhart GF. Chronic pain and medullary descending facilitation. *Trends Neurosci* 2002;25:319–325.
9. Mathews KA. Neuropathic pain in dogs and cats: If only they could tell us if they hurt. *Vet Clin North Am Small Anim Pract* 2008;38:1365–1414.
10. Woolf CJ, Mannion RJ. Neuropathic pain: Aetiology, symptoms,mechanisms, and management. *The Lancet* 1999;353: 1959–1964.
11. Gilron I, Watson CP, Cahill CM, et al. Neuropathic pain: A practical guide for the clinician. *Can Med Assoc J* 2006; 175:265–275.
12. Watkins LR, Milligan ED, Maier SF. Glial activation: A driving force for pathological pain. *Trends Neurosci* 2001;24:450–455.
13. Cervero F, Laird JM. Visceral pain. *The Lancet* 1999;353:2145–2148.
14. Hobson AR, Aziz Q. Central nervous system processing of human visceral pain in health and disease. *News Physiol Sci* 2003;18:109–114.
15. Palecek J. The role of dorsal columns pathway in visceral pain. *Physiological Research* 2004;53:S125–S130.
16. Muir III WW, Woolf CJ. Mechanisms of pain and their therapeutic implications. *J Am Vet Med Assoc* 2001;219:1346–1356.
17. Lemke KA. Understanding the pathophysiology of perioperative pain. *The Can Vet J* 2004; 45:405–413.

Pharmacology of Pain Control

Kristen Messenger, DVM, PhD, DACVAA, DACVCP*; and Lori Bidwell, DVM, DACVAA, CVA

Authors' addresses: North Carolina State University, College of Veterinary Medicine, Raleigh, NC 27607 (Messenger); East-West Equine Sports Medicine, 7220 Russell Cave Road, Georgetown, KY 40324-9602 (Bidwell); e-mails: kmmessen@ncsu.edu; loribidwell@hotmail.com. *Corresponding and presenting author. © 2022 AAEP.

The science of pain management continues to evolve with the development of insight into the physiology of pain. Opioids have been available since the early 1800s, and most of the current medications used in this class are opiates or derivatives of opium. Nonsteroidal anti-inflammatory drugs were introduced to the market in 1897 by Felix Hoffman in the form of aspirin,[a] and phenylbutazone[b] was introduced in the 1950s. Gabapentin[c] was approved for use in 1993, and tramadol[d] (an analog of codeine[e]) was synthesized in 1962.

1. Opioids

An opioid is any compound that works at opioid receptors. Opiates are naturally occurring alkaloids from the poppy seed (morphine[f] and codeine are examples). Morphine is the classic opioid, structured as a benzene ring with a phenolic hydroxyl group at position 3 and an alcohol hydroxyl group at position 6. Changes in this structure can result in ethers and esters (examples are codeine and heroin[g]), and these changes result in differences in analgesic potency or antagonistic properties. There are three varieties of opioid receptors in the body: mu, kappa, and delta. The receptor type determines the physiologic response when an opioid is bound. Analgesia, respiratory depression, euphoria, sedation, decreased gastrointestinal motility, and psychomimetic and dysphoric effects are specific responses to the binding of different receptors. The density of receptors in different locations in the brain and body varies between species.[1]

Opioids produce their effect by binding to opioid receptors in the brain, spinal cord, and body after administration. Binding activates the receptor, releasing a G (guanine nucleotide) protein in the cell membrane. This protein diffuses with the membrane until it reaches its target, an enzyme or ion channel. When activated by an opioid, the receptors on presynaptic terminals of C and A delta sensory nerve fibers indirectly inhibit voltage-dependent calcium channels. This process blocks the release of pain neurotransmitters such as glutamate, substance P, and calcitonin gene-related peptide from sensory fibers, resulting in analgesia.

Opioids and exogenous opioids activate presynaptic receptors on the brain's gamma-aminobutyric acid (GABA) neurons. The inhibition of GABA results in the release of dopamine, which produces intense pleasure in humans.[2]

Pure mu agonists (morphine, methadone,[h] and fentanyl[i]) are used commonly in a referral equine practice setting. Butorphanol[j] is an agonist (kappa)/antagonist (mu) analgesic used commonly in ambulatory and referral practice. Intravenous administration of opioids in horses results in analgesia and excitation. Combining morphine, methadone, or butorphanol with an alpha-2

NOTES

adrenergic agonist is recommended to avoid some negative effects. The duration of analgesia is dependent on the route of administration.

Tramadol is not a standard opioid, although it is an analog of codeine. This medication has partial mu receptor activity, works centrally on GABA receptors, and has activity involving control of catecholamines and serotonin. Intravenous dosing has produced evidence of analgesia in horses undergoing castration.[3]

2. Nonsteroidal Anti-Inflammatory Drugs

Tissue trauma results in the release of cell membrane phospholipids. These phospholipids are converted into arachidonic acid that travels through one of two pathways: the lipoxygenase pathway or the cyclooxygenase pathway. The lipoxygenase pathway produces leukotrienes; the cyclooxygenase (COX) pathway produces inflammatory or protective prostaglandins (COX-1 or COX-2 enzymes catalyze the change). COX-1 is present in most normal tissues and maintains homeostasis: maintenance of gastric mucosa, platelet aggregation, and renal blood flow. COX-2 is inducible and synthesized in the face of inflammation or carcinogenesis. The resulting prostaglandins mediate inflammation, pain, fever, headache, vascular permeability, miosis, and the disruption of the blood-aqueous barrier. Corticosteroids block both arachidonic acid pathways (leukotriene and cyclooxygenase). Nonsteroidal anti-inflammatory drugs interrupt COX-1 and -2 enzymes; medication formulations have variation in selectivity for one over the other.

3. Pregabalin and Gabapentin

Pregabalin[k] and gabapentin (1-[aminomethyl]cyclohexane acetic acid) are anti-epileptic agents that are structurally similar to GABA, but neither has activity in the GABA neuronal system. Both medications have potent anticonvulsive effects and are recognized as having potential for treatment of neuropathic conditions in humans. Although their mechanism of action is not completely understood, activity at voltage-activated calcium channels of the postsynaptic dorsal horn of the spinal cord interrupts the process that leads to the experience of a neuropathic pain sensation. These medications differ in their speed of absorption through the intestinal tract and their bioavailability. Gabapentin has limited research to show efficacy as a stand-alone analgesic in horses.[4] Pregabalin has been shown to produce plasma concentrations in horses within the therapeutic range for humans when dosed intragastrically every 8 hours at 4 mg/kg. There is no research discussing effectiveness as an analgesic in horses.[5]

4. Conclusion

Like people, every animal responds differently to analgesic administration. A common mistake made by practitioners is giving up on a medication because they had a negative or lack of effect in a patient. In addition, there are several options in some classes of medications; if one option is not producing a positive effect, it is worth trying another version within the same drug class.

Acknowledgments

Declaration of Ethics

The Authors have adhered to the Principles of Veterinary Medical Ethics of the AVMA.

Conflict of Interest

The Authors have no conflicts of interest.

References and Footnotes

1. Thomasy SM, Moeller BC, Stanley SD, et al. Comparison of opioid receptor binding in horse, guinea pig, and rat cerebral cortex and cerebellum. *Vet Anaesth Analg* 2007;34:351–358.
2. Trescott AM, Datta S, Lee M, et al. Opioid pharmacology. *Pain Physician* 2008;11:S133–S153.
3. Cagnardi P, Ferraresi C, Zonca A, et al. Clinical pharmacokinetics of tramadol and main metabolites in horses undergoing orchiectomy. *Vet Q* 2014;34:143–141.
4. Young JM, Schoonover MJ, Kembel SL, et al. Efficacy of orally administered gabapentin in horses with chronic thoracic limb lameness. *Vet Anaesth Analg* 2020;47:259–266.
5. Mullen KR, Schwark W, Divers TJ, et al. Pharmacokinetics of single-dose intragastric and intravenous pregabalin administration in clinically normal horses. *Am J Vet Res* 2013;74:1043–1048.

[a]Aspirin, Bayer, Leverkusen, Germany.
[b]Phenylbutazone, VetOne, Boise, ID 83705.
[c]Gabapentin, Amneal Pharmaceuticals, Pvt, Ltd. Ahmedabad, India 382220.
[d]Ultram, Janssen, Beerse, Belgium.
[e]Codeine, Actavis Mid-Atlantic (Teva Pharmaceuticals), Tel Aviv-Yafo, Israel.
[f]Morphine, Pfizer, New York, NY 10017.
[g]Heroine, Bayer (original manufacturer), Leverkusen, Germany.
[h]Methadone, Malinckrodt Pharmaceuticals.
[i]Duragesic, Janssen Pharmaceuticals, Beerse, Belgium.
[j]Torbugesic, Zoetis Animal Health, Parsippany, NJ 07054.
[k]Lyrica, Pfizer, New York, NY 10017.

Performance Horse Pain Management

Lori A. Bidwell, DVM, DACVAA, CVA

Author's address: East-West Equine Sports Medicine, 7220 Russell Cave Road, Georgetown, KY 40324-9602; e-mail: loribidwell@hotmail.com. © 2022 AAEP.

1. Introduction

Options are limited when considering conventional medications available for a practitioner dealing with a painful performance horse. The governing organization or federation of a competitive discipline dictates what medications are allowed or what blood levels are legal if the horse intends to continue competing. The benefit of these medication limitations is protecting horses from injuries masked by analgesic drugs or procedures. The deleterious effects are the prohibition of Food and Drug Administration (FDA)–approved drugs commonly used for sport-related discomfort and injuries. Nonsteroidal anti-inflammatory drugs (NSAIDs) are banned from international competition, but homeopathic medications or herbal formulas that are not FDA approved are allowed. This aspect of veterinary medicine can be controversial regarding ethics and acting in the best interest of the patients.Too often, client demands to continue competing with a horse because of potential money to be won, money to be made in sales, or clients' expectations result in inappropriate use of medications and poor decision-making for the owner's sake. It is important to understand the available medications and doses allowed by two of the largest competition governing organizations (United States Equestrian Federation [USEF] and Federation Equestre Internationale [FEI]).Unfortunately, science has not always been a paramount consideration in the formulation of dictated regulations regarding medications and therapies. The first step in dealing with pain is recognizing it as such. Often, horses present for examination due to poor performance that has been considered a behavioral problem. When the horse suddenly becomes "girthy," starts bucking, or refuses to jump, the first step for many is to give calming medications or methocarbamol. When those options do not alter the behavior, the horse is usually treated for ulcers or is examined with a gastroscope to ascertain the presence of glandular or nonglandular gastric ulceration. If that does not provide the answer, lameness or discomfort (orthopedic, visceral) is considered. Some owners will buy a new saddle before having their horse examined by a veterinarian. Most often, these behavioral changes are due to discomfort.

2. Selecting Medications and Treatments

Pain management should start with a thorough physical exam, palpation of muscles and limbs, and evaluation of movement in hand and under saddle if appropriate. Understanding the patient at that point allows you to make a therapeutic plan. Nonsteroidal anti-inflammatory drugs (NSAIDs) should be considered first when seeking a medication option. Phenylbutazone[a], flunixin meglumine[b], and firocoxib[c] are the most commonly used. Unfortunately, some horses have sensitivities to this class of drug, or the competition governing body has regulations that prevent their use. Butorphanol[d] is the only opioid commonly used in sports medicine practice and should only be considered when dealing with gastric emergencies or as an adjunct to sedation. Alternative medication options include gabapentin[e], detomidine[f],

NOTES

Sarapin[g], Traumeel[h], Zeel[i], and Arnica[j]. Actively competing horses are limited in medication options or dependent on timing due to required withdrawal times and potential for positive blood tests. Therapeutic options like acupuncture, massage, and chiropractic manipulation are useful for maintaining performance and treating pain in horses. Additional options include physiotherapy, magnet therapy, laser therapy, electrical stimulation, and ultrasound.Unfortunately, there is a deficiency in research to back many of these modalities. The existing research is often limited to evaluating a single modality with results that are difficult to interpret. Shockwave is a useful tool for many performance-related injuries and conditions, but the USEF has regulations that limit use at least 12 hours prior to competition (if treating the back and sacroiliac area) and 3 days prior for any treatment involving the limbs. FEI regulations restrict the use of shockwave within 5 days of competition for any part of the body. Gabapentin should be considered in unusual cases with a neuropathic pain component. Although the mechanism of action is not completely understood, activity at voltage-activated calcium channels can minimize hyperexcitability in nerves responsible for burning and shooting pain. Research, however, has not shown significant improvement in lameness scores using this medication.[1] From the author's personal experience, the medication is useful as an adjunct in cases involving a neuropathic component. Recommended dosing can range between 2.5 and 40 mg/kg orally twice a day. Withdrawal time from the competition is a minimum of 14 days after using this medication. If horses are also receiving other medications, the author suggests adding an additional 7 days before returning to competition. Sarapin is an extract from the pitcher plant, Sarraceniaceae, useful for neuropathic pain. It has anti-inflammatory and nerve-quieting properties. This medication is useful for "veggie blocks" for horses that are "footsore" from working and walking on different surfaces at shows. These blocks are performed at the location of an abaxial block. This is performed using 2.5 mL Sarapin (or Traumeel or Zeel) per site, sometimes combined with 0.5 mg dexamethasone[k] (if the horse is not currently receiving dexamethasone during competition). Sterile preparation of the injection site with chlorhexidine and alcohol prior to injection and a light bandage over the area postinjection can aid in minimizing swelling. Homeopathic medications like Traumeel, Zeel, and Arnica have anti-inflammatory properties that are particularly valuable for horses sensitive to NSAIDs or actively competing where NSAIDs cannot be used. Traumeel is not legal for USEF-governed competition because of the inclusion of *Atropa belladonna* (deadly nightshade). Oddly, it is legal for international (FEI) competition. FDA standards do not govern homeopathic medications. It is difficult to know who to trust as a source when purchasing these products. Word of mouth or online reviews are important when searching for options. Injectable Traumeel, Zeel, and Arnica are sourced as 2.2-mL or 5-mL individual dose ampules. Most adult horses can receive 10 mL intravenously once or twice daily as an adjunct or alternative to NSAIDs. There are oral Traumeel tablets (that can be purchased at most human pharmacies), and the dosing is typically 10 tabs orally once or twice a day. Oddly, there is no actual dose label on these medications.

3. Alternative Options

Acupuncture originated in China about 5000 years ago, with the fundamental principles dating 3000 years before that. Needles were originally made of stone and eventually replaced with metal around 110 B.C. The theory involved in acupuncture is that animals have meridians or lines through which qi (pronounced "chee") or energy flow circulates through, enabling normal physiological function. Disease processes or inflammation alter or stop the flow of qi. Therefore, introducing a needle in points along these meridians opens the energy flow and the release of endorphins, serotonin, norepinephrine, or gamma-aminobutyric acid. Acupuncture is not limited to needle placement. There are many techniques used to stimulate points and meridians: massage or acupressure along the meridians; the burning of moxa (an herb that burns at high temperature) over points or the application of the burning herb on the ends of needles to warm the needles; hemoacupuncture, or simply pricking acupuncture points and allowing bleeding; the injection of blood, saline, or B-12 at acupuncture points for longer stimulation; and the placement of implants at points (gold beads or surgical staples). There are multiple peer-reviewed studies published describing acupuncture for equine care. A study in 2005 describes the successful use of electroacupuncture for chronic thoracolumbar pain.[2] There are many uses for acupuncture, but, like any treatment modality, it does not work for every patient. Veterinary chiropractic manipulation started in the early 1900s and was semi-formalized in the late 1980s through accepted training programs. The American Veterinary Chiropractic Association is the primary organization in the United States that oversees training in veterinary chiropractic principles and techniques. This treatment modality must be performed by a licensed veterinarian or by a licensed human chiropractor under the supervision of a licensed veterinarian (regulations vary in every state). The concept behind chiropractic is the manipulation of joints and soft tissues through mobilization, manipulation, and adjustment. Massage is the rubbing or kneading of muscles and soft tissues to aid in circulation and relaxation. There are several veterinary massage courses, including the Chinese version called Tui-na. Massage and physiotherapy are modalities that can be performed by veterinarians and paraprofessionals (technicians, assistants, and therapists) and are not limited to licensed veterinarians (although again, in some states, this modality can only be performed under the supervision of a licensed veterinarian). Physiotherapy is

performed in collaboration with veterinarians to treat injuries or movement dysfunction and combines techniques like mobilization, stretching, massage, and electrotherapy. Often, a treatment plan is developed specifically for each patient, including exercises to be performed at the farm between treatments.

4. Summary

Pain management in the performance horse involves communication with the trainer, rider, groom, and horse owner. Decision-making must be based on what is best for the horse, not the humans, while keeping in mind regulations in place by competition governing bodies. There is not a single treatment modality that is perfect and that will work for every patient. Therefore, combining physical therapies with appropriately dosed medications, supplements, or diet changes produces the best outcome.

Acknowledgments

Declaration of Ethics

The Author has adhered to the Principles of Veterinary Medicals Ethics of the AVMA.

Conflict of Interest

The Author has no conflicts of interest.

References and Footnotes

1. Young JM, Schoonover MJ, Kembel SL, et al. Efficacy of orally administered gabapentin in horses with chronic thoracic limb lameness. *Vet Anaesth Analg* 2020;47:259–266.
2. Xie H, Colahan P, Ott EA. Evaluation of electroacupuncture treatment of horses with signs of chronic thoracolumbar pain. *J Am Vet Med Assoc* 2005;227:281–286.

[a]Phenylbutazone, VetOne, Boise, ID 83705.
[b]Flunixin Meglumine, VetOne, Boise, ID 83705.
[c]Firocoxib, Boehringer Ingelheim Animal Health USA Inc., Duluth, GA 30096.
[d]Torbugesic, Zoetis Animal Health, Parsippany, NJ 07054.
[e]Gabapentin, Amneal Pharmaceuticals, Pvt, Ltd., Ahmedabad, India 382220.
[f]Dormosedan, Zoetis Animal Health, Parsippany, NJ 07054.
[g]Sarapin, High Chemical Company, Levittown, PA 19056-3333.
[h]Traumeel, Biologische Heilmittel Heel GmbH, Baden Baden, Germany 76532.
[i]Zeel, Heel Biologische Heilmittel Heel GmbH, Baden Baden, Germany 76532.
[j]Arnica, Biologische Heilmittel Heel GmbH, Baden Baden, Germany 76532.
[k]Dexamethasone, VetOne, Boise, ID 83705.

How to Manually Analyze a Stallion's Breeding Records

Regina M. Turner, VMD, PhD, DACT

Author's address: University of Pennsylvania, New Bolton Center, 382 West Street Road, Kennett Square, PA 19348; e-mail: rmturner@vet.upenn.edu © 2022 AAEP.

1. Introduction

Analysis of historical breeding records can be an important source of information about a stallion's past fertility and reproductive efficiency. Additionally, information gleaned from breeding records facilitates formulation of targeted recommendations for the stallion's future breeding management. In the absence of commercial software, the only way to pull information out of historical records is to analyze the information by hand. For stallions with larger books, the process is time-consuming, but not difficult, and generally the information gained is well worth the effort. This presentation will explain one method for manual review of stallion breeding records and will describe how to use the resulting information to formulate recommendations for future breeding management targeted at improving future reproductive efficiency.

2. Materials and Methods

The goal was to calculate the following end-of-year values: seasonal pregnancy rate (SPR; number of mares pregnant/number of mares bred); per cycle pregnancy rate (PCPR; number of mares pregnant/number of estrous cycles bred) and, alternatively, cycles per pregnant (CPP), which is the inverse of PCPR (number of estrous cycles bred/number of mares pregnant); first cycle pregnancy rate (FCPR; number of mares pregnant on first cycle bred/number of mares pregnant); pregnancy loss rate (number of mares diagnosed pregnant that failed to produce a live foal/number of mares diagnosed pregnant); and breedings per cycle (number of breedings/number of estrous cycles).

SPR is an important indicator of a stallion's fertility but alone may not reflect reproductive efficiency. For example, assuming that management is similar, and that mares are of similar fertility, a stallion that achieves an SPR of 80% with an average PCPR of 80% would be considered more fertile than a stallion that achieves an SPR of 80% with an average PCPR of 50%. The second stallion is achieving the high SPR by breeding mares over multiple cycles, while the first stallion is achieving the same SPR in a much more efficient manner. In this regard, PCPR (CPP) and FCPR are considered more sensitive indicators of reproductive efficiency and are important to include when performing a detailed retrospective analysis.[1]

With a bit of additional work, it is also possible to calculate (1) breeding success based on number of covers (breedings) per day, (2) breeding success based on number of days of sexual rest prior to breeding, (3) breeding success based on order of breeding (for Thoroughbred [TB] stallions breeding by natural cover), and (4) breeding success by month.[2] These values are important when making recommendations on whether decreasing or increasing book size is likely to be helpful or detrimental to future fertility and for identifying unique events that might have caused a transient decrease in fertility.

NOTES

The most important "material" required to analyze breeding records is a detailed breeding history for at least the previous breeding season and ideally for several past breeding seasons. These data are usually supplied by the stallion's farm and should include the name of each mare bred, the date(s) that each mare was bred, and whether that breeding resulted in pregnancy or not. Ideally, one should also attempt to determine whether each mare produced a live foal from a successful breeding. In the case of TB stallions breeding by natural cover, it is also helpful to obtain information on the order that mares were bred on a given day. Larger commercial farms often have access to computerized software that can easily print out all or most of these data. Table 1 is a fictional, one-page example of how the raw information is typically provided. When these data are obtained for the entire breeding season, one can readily calculate SPR, PCPR (CPP), and FCPR. If live foal numbers are also provided, then pregnancy loss rate is also easy to calculate. Some commercial software programs provide these data automatically. Using the above data as a limited example, it can be readily seen that, over this part of the breeding season, 15 mares were bred with 13 pregnant. SPR (for the limited season shown in this example) = 13/15 = 87%.

By reviewing the dates that each mare was bred, one can determine that 4 mares (SuperFast, Angel, Longwood, and Bridget) were bred multiple times over single estrous cycles (denoted by the red bars), and 5 mares were bred over multiple estrous cycles (Angel, Fancy, InAPinch, Longwood, and Bridget). From this, it can be seen that 13 pregnancies resulted from 20 cycles. PCPR = 13/20 = 65% (alternatively, CPP = 20/13 = 1.54). Average breedings per cycle can also be calculated. While this number is not a reflection of a stallion's fertility, it is a valuable indicator of the efficiency of mare management. In the above example, 26 breedings occurred over 20 estrous cycles = 26/20 = 1.3. Some suggested values for these indices are listed in Table 2.

Certainly, these are important numbers, but with some additional effort, more detailed information can be extracted. The printouts provided by most farms are typically not in a format from which it is easy to extract information on number of mares bred per day and number of days of sexual rest prior to each breeding. However, these data can be manually reformatted to allow for easier evaluation. To do this, print out a blank calendar that covers the months when the stallion was actively breeding, with each month illustrated on an individual page. Then, using the farm-provided records, enter each mare's name on the date(s) that the mare was bred, followed by an "O" if that breeding resulted in an open diagnosis or a "P" if that breeding resulted in a diagnosis of pregnancy. The "O" or "P" should only be entered for the last breeding of a given cycle. For TB stallions breeding by natural cover, enter the order in which each mare

Table 1. Mares Bred Summary

Season: 2021				
Mare	Date Bred	Days Since	Final Status	Projected Foaling Date
Missy	2/15/21	166	In-foal	1/11/2022
Kelly	2/25/21	156	In-foal	1/21/2022
Louise	2/27/21	154	In-foal	1/23/2022
SuperFast	2/27/21	154	In-foal	1/23/2022
	2/25/21			
	2/23/21			
Angel	3/21/21	137	In-foal	2/14/2022
	3/19/21			
	3/1/21			
Cutie	3/6/21	147	In-foal	1/30/2022
Fancy	3/6/21	147	Switched studs	1/30/2022
	2/25/21			
InAPinch	3/8/21	145	In-foal	2/1/2022
	2/16/21			
Esmerelda	3/8/2021	145	In-foal	2/1/2022
Ocean Wave	4/5/2021	117	In-foal	2/29/2022
Fuzzy	4/8/2021	114	In-foal	3/3/2022
Julie	4/8/2021	114	In-foal	3/3/2022
Longwood	4/29/2021		Open	
	4/8/2021			
	4/5/2021			
Joy	5/3/2021	89	In-foal	3/28/2022
Bridget	5/6/2021	86	In-foal	3/31/2022
	4/15/2021			
	4/12/2021			
	4/10/2021			

Table 2. Suggested Values for Seasonal Pregnancy Data

	SPR	PCPR (CPP)	FCPR	PLR	Breedings/Cycle
Excellent	≥ 80%	≥ 75% (≤ 1.3)	≥ 75%	< 10%	≤ 1.2
Moderate	60–80%	40–75% (1.3–2.5)	45–75%		1.2–1.5
Poor	< 60%	< 40% (> 2.5)	< 45%		> 1.5

Abbreviations: SPR, seasonal pregnancy rate; PCPR, per cycle pregnancy rate; CPP, cycles per pregnant; FCPR, first cycle pregnancy rate; PLR, pregnancy loss rate. Adapted from Love and Kenney (1998)[3] and Whitesell et al. (2020).[4]

was bred on a given day (when those data are provided). Fig 1 shows a sample of the March breeding log for the data shown in Table 1.

From these manually entered data, it is possible to calculate breeding success based on number of covers (breedings) per day, breeding success based on number of days of sexual rest prior to breeding, and breeding success by month. In this simple example, the pregnancy rate when one mare is bred per day is 50% (Angel open following March 1 breeding, pregnant following March 21 breeding); the pregnancy rate when 2 mares are bred per day is 100% (Cutie and Fancy on March 6, InAPinch and Esmerelda on March 8). April's breeding on March 19 is not counted in this calculation since it was the first of two breedings that occurred on the same estrous cycle. Breeding success based on number of days of sexual rest prior to breeding can also be calculated, although it is of little value in this example since so few mares were bred in March. This value becomes much more meaningful for stallions with larger books. When a sufficient number of mares are bred, this manual analysis takes quite a bit of time but results in highly relevant information about the stallion's past performance, allowing for more targeted recommendations for future breeding management.

3. Results

The following examples illustrate how the data can be applied to interpret a stallion's past breeding performance and to formulate targeted recommendations for improving future reproductive efficiency.

Example Stallion 1

The first example is a 5-year-old TB stallion that stood first year at stud. The managing farm had the impression that the horse was not as fertile as others on the farm but ended the season well. The syndicate is now asking if book can be further increased next year.

Stallion 1 Summary Statistics

Book Size	SPR	PCPR (CPP)	FCPR	Pregnancy Loss Rate	Breedings/ Cycle
102	83%	49% (2.05)	47%	3.6%	1.3

Stallion 1 PCPR Based on No. of Days of Sexual Rest Prior to Breeding

0 Days	1 Day	2 Days	> 2 Days
48%	58%	0% (1 mare)	100% (2 mares)

Stallion 1 PCPR Based on No. of Covers per Day

1	2	3	4
50%	52%	46%	50%

Stallion 1 PCPR Based on Month of Breeding Season

February	March	April	May	June	July
54.5%	45%	48%	48%	52%	100% (2 mares)

Interpretation

- SPR good, PCPR low (CPP high), FCPR low, pregnancy loss normal, breedings per cycle a little high.
- Number of covers per day (up to 4) does not appear to affect PCPR.
- Number of days of sexual rest prior to breeding (0 or 1) does not appear to affect PCPR. Too few mares in the 2 days and > 2 days categories to interpret.
- PCPR did not change throughout the breeding season (February–June). Too few mares in July to interpret.

Conclusions

Adding more mares would not be expected to further reduce reproductive performance since this stallion's PCPR does not change with days of sexual rest or based on the number of mares bred/day. However, if the decision is made to increase book size, assume an average of 2 cycles per pregnancy per mare. If breedings per cycle does not decrease (i.e., if mare management is not tightened up), assume 2.6 covers for each additional mare.

Recommendations

Use ovulation induction agent and breed 24 hours later to decrease breedings per cycle and to breed close

Fig. 1. Sample March breeding log for the records shown in Table 1. The numbers in front of mare names indicate the order that the mares were bred (for a TB stallion breeding by natural cover when more than 1 mare was bred on a given day). An "O" after a mare's name indicates that the mare was diagnosed as open following that breeding cycle. A "P" after a mare's name indicates that the mare was diagnosed as pregnant following that breeding cycle.

Stallion 2 Summary Statistics

Book Size	SPR	PCPR (CPP)	FCPR	Pregnancy Loss Rate	Breedings/Cycle
120 (data available for 101 mares)	68%	42% (2.4)	46%	2.2%	1.2

to ovulation. Consider reinforcement breeding in an attempt to compensate for what is likely marginal semen quality.

Example Stallion 2

The second example is a 6-year-old Standardbred that stood first season to 120 mares (data available for 101); "was a lot of work" but "can we increase book size anyway?" The stallion is collected on a M-W-F-Sat schedule, and semen is split evenly to artificially inseminate as many mares as are presented on a given day.

Interpretation

- SPR marginal, PCPR low (CPP high), FCPR low, pregnancy loss normal, breedings per cycle good.
- Breeding over 2 mares per day lowers pregnancy rate.
- Number of days of sexual rest prior to breeding (0 or 1) was not evaluated as this was a Standardbred on a regular collection schedule.
- PCPR lower in April and May. Probably associated with increase in number of mares per day.

Stallion 2 PCPR Based on No. of Mares per Day

1 Mare per Day	2 Mares per Day	3 Mares per Day	4+ Mares per Day
56%	51%	35%	26%

Stallion 2 PCPR Based on Month of Breeding Season

February	March	April	May	June
51%	45%	30%	35%	49%

Conclusion

Adding more mares is not recommended since this stallions PCPR decreases when 3 or more mares are bred on a single day. Hypothetically, if the decision is made to add more mares, assume 2.4 cycles per pregnancy. If breedings per cycle doesn't

change, assume 2.9 additional breedings for each additional mare. This will likely further reduce reproductive efficiency as it will increase the number of days the stallion has to breed 3 or more mares.

Recommendations

Consider reducing book with goal of breeding no more than 2 mares per day (no more than 100 mares). Deep horn insemination, centrifugation where possible, to compensate for what is likely marginal sperm numbers and/or marginal semen quality. Reevaluate semen quality prior to next breeding season.

Example Stallion 3

The third example is a 15-year-old TB stallion that has been a breeding stallion for many years. He moved to a new farm last year. The stallion's prior breeding history is not available, but the current farm feels that the horse performed poorly under their management. He has good testicular size.

Interpretation

SPR is good but was achieved despite marginal reproductive efficiency.

Interpretation

Reproductive efficiency (fertility) is better when 2 to 3 mares are bred per day versus 1 mare per day.

Interpretation

Reproductive efficiency (fertility) is better when the stallion has 0 or 1 day of sexual rest. Longer periods of sexual rest are associated with a decrease in fertility.

Interpretation

Reproductive efficiency (fertility) appreciably improved in April, May, and June versus February and March. This improvement occurred immediately following resolution of right hind limb lameness after hospitalization. Improvement is also coincident with increase in covers per day and covers per week and a decrease in number of days off between breedings.

Conclusions

Sperm accumulation could be a factor for this stallion as the horse appears to be more reproductively efficient when more mares are bred and with fewer days of sexual rest. Alternatively, or in addition, reproductive efficiency improved following resolution of hind limb lameness. Was stallion ejaculating consistently while lameness was present?

Recommendations

Semen evaluation during the off season while at sexual rest and after appropriate "clean out" collections to determine if sperm accumulation is a factor. Collect dismount sample after all natural covers to confirm that ejaculation is occurring.

4. Discussion

Analysis of breeding records is an often-overlooked component of fertility evaluation that can add significant data to a case investigation. Numerical data, as shown in the examples above, often go a long way to help stallion owners and managers understand why certain recommendations are made and, in many cases, increase compliance with veterinary recommendations. Although the most meaningful data are calculated when book size (mare sample size) is larger, even the records of stallions with smaller books can yield important information.

Acknowledgments

Declaration of Ethics

The Author has adhered to the Principles of Veterinary Medical Ethics of the AVMA.

Stallion 3 Summary Statistics

Book Size	SPR	PCPR (CPP)	FCPR	Pregnancy Loss Rate	Breedings/Cycle
60	82%	55% (1.84)	54%	2%	1.04

Stallion 3 Breeding Success Based on No. of Covers per Day

	No. of Days	No. of Cycles	PCPR	Cycles per Pregnancy
1 Cover per Day	40	39	49% *Low moderate*	2.1 *Low moderate*
2 Covers per Day	27	51	61% *High moderate*	1.6 *High moderate*
3 Covers per Day	3	6	67% *High moderate*	1.5 *High moderate*

Stallion 3 Breeding Success Based on Days of Sexual Rest Prior to Breeding

	Cycles	PCPR	CPP
0	62	58% *Moderate*	1.7 *Moderate*
1	22	59% *Moderate*	1.7 *Moderate*
2	7	29% *Poor*	3.5 *Poor*
3	0	-	-
≥ 4	8	37% *Poor*	2.7 *Poor*

Stallion 3 Breeding Success Based on Month

		Cycles	PCPR	CPP
Lameness/ Hospitalization→	Feb	11	36% *Poor*	2.75 *Poor*
	March	19	32% *Poor*	3.2 *Poor*
	April	23	61% *Moderate*	1.6 *Moderate*
	May	39	69% *Moderate*	1.5 *Moderate*
	June	7	86% *High*	1.2 *High*

Conflict of Interest

The Author has no conflicts of interest.

References

1. Love CC. Relationship between sperm motility, morphology and the fertility of stallions. *Therio* 2011;76:547–557.
2. Blanchard T, Brinsko S, Varner D, et al. Relationships between stallion age, book size, number of matings (covers), breeding soundness examination findings, and fertility parameters in 15 Thoroughbred stallions (34 stallion years). *Clin Therio* 2010;2:91–98.
3. Love CC, Kenney RM. The relationship of increased susceptibility of sperm DNA to denaturation and fertility in the stallion. *Therio* 1998;50:955–972.
4. Whitesell K, Stefanovski D, McDonnell S, et al. Evaluation of the effect of laboratory methods on semen analysis and breeding soundness examination (BSE) classification in stallions. *Therio* 2020;142:67–767.

Retrograde Flushing Followed by Slicing Float-up Enhanced Epididymal Sperm Recovery Without Affecting Cryopreservation in Stallions

Igor Canisso, DVM, MSc, PhD, DACT, DECAR*; and Giorgia Podico, DVM, MSc

Retrograde flushing (RF) followed by slicing float-up (SF) of the tail of the epididymides enhanced epididymal sperm recovery without affecting cryopreservation in the stallion. Authors' addresses: University of Illinois, 1102 West Hazelwood Drive, Urbana, IL 61802; e-mail: canisso@illinois.edu. *Corresponding and presenting author. © 2022 AAEP.

1. Introduction

Cryopreserving epididymal sperm often represent the last opportunity to preserve the breeding potential upon castration or sudden death. Epididymal sperm recovery is performed via RF or SF of sperm into an extender. However, these techniques are not typically applied in combination unless RF results in poor yield. This study aimed to assess the yield and cryopreservation of epididymal sperm harvested via RF followed by SF.

2. Materials and Methods

Epididymides from fifteen stallions aging from 2- to 15-years-old were harvested. Each epididymis was subjected to RF with 10 mL of freezing extender[a] and then sliced in 1-2 mm pieces, covered with 10 mL of the freezing extender. Then the slices were kept at room temperature for 15 min for completion of the SF technique. The recovered sperm after each technique was evaluated separately for volume, concentration, and total sperm count and then frozen. In addition, pre-freezing and post-freezing total motility (TM) and progressive motility (PM) were evaluated with CASA.[b] Sperm membrane integrity (SMI) and high mitochondrial membrane potential (HMMP) were assessed after freezing with Zombie Green[c] and Mitotracker Deep-Red[d] staining via flow cytometry[e].[1] Data analyses were carried out via mixed model in R.[f] Significance was set at $P < 0.05$.

3. Results and Discussion

The total sperm recovered by RF was $8.3 \pm 2.0 \times 10^9$ and by SF was $3.0 \pm 0.8 \times 10^9$. The sperm concentration after RF was $693 \pm 86.4 \times 10^6$/mL and $417 \pm 90 \times 10^6$/mL after SF. The TM, PM, SMI, and HMMP were similar for both techniques before and after freezing ($P > 0.05$). Whilst the fertility was not tested, the lack of differences for sperm quality and enhanced

Research Abstract—for more information, contact the corresponding author

NOTES

recovery of 36.14% per harvesting suggest that the combination of RF and SF can become a new standard approach in clinical practice.

Acknowledgments

Declaration of Ethics

The Authors have adhered to the Principles of Veterinary Medical Ethics of the AVMA.

Conflict of Interest

The Authors have no conflicts of interest.

References and Footnotes

1. Peña FJ, Ball BA, Squires EL. A new method for evaluating stallion sperm viability and mitochondrial membrane potential in fixed semen samples. *Cytometry B Clin Cytom* 2018;94:302–311.

[a]Botucrio, Botupharma, Phoenix AZ 85027.
[b]CASA Spermvision, Minitube of America, Vernon, WI 53593.
[c]Zombie Green Fixable Viability Kit #423112, Biolegend, San Diego CA 92121.
[d]Mitotracker™ Deep Red #M22426, Invitrogen™-Thermo Fisher Scientific Corporation, Waltham MA 02451.
[e]Cytek Autora, Cytek Bioscience, Freemont CA 94538.
[f]R Version 1.4.1717, R Studio PBC, Boston MA 02210.

The Ability of Donkey Sperm for Cooling: Effect of Extender Base and Removal of Seminal Plasma on Sperm Parameters and Fertility Rates

Lorenzo G.T.M. Segabinazzi, DVM, MS, PhD*; Mariana Gobato, MS; Veronica Scheeren, MS; Rafael Bandeira, MS; José Dell'Aqua, Jr., PhD; Marco A. Alvarenga, DVM, MS, PhD; and Frederico Papa, DVM, PhD

The cooling ability of donkey semen can be enhanced by sodium caseinate or egg yolk-based extender. In addition, centrifugation might be an option for donkey semen extended in milk-based extenders. Authors' address: Ross University School of Veterinary Medicine, PO Box 334, Basseterre, St. Kitts, 00265 West Indies; e-mail: lgseg@hotmail.com. *Corresponding and presenting author. © 2022 AAEP.

1. Introduction

Donkey semen does not have good cooling ability in commercially available equine extenders. Therefore, this study aims to develop approaches to improve the cooling ability of donkey semen.

2. Material and Methods

Semen of 7 donkeys (n = 21) was cooled at 5°C for 48 hours in 3 different extenders (milk based, SKM[a] sodium caseinate based, SC[b] or egg yolk based, EY[c] in the presence or not of seminal plasma (C, centrifugation). Sperm motility, plasma membrane stability (PMS), and mitochondrial membrane potential (HMMP) were assessed before, 24 hours, and 48 hours after cooling. In addition, 15 mares (136 estrous cycles) were randomly inseminated with semen from 2 Jacks (jack 1, n = 90; jack 2, n = 46) previously cooled for 24 hours with either one of the treatments (SKM, SC, EY, SKM-C, SC-C, or EY-C).

3. Results and Discussion

Groups EY, SC-C, and EY-C ($P < .05$) had superior sperm parameters than SKM at 24 and 48 hours. Centrifugation positively affected sperm parameters in donkey cooled semen extended in SKM ($P < .05$). Mares bred with semen extended in SC (74%, 14/19), SC-C (89%, 17/19), EY (90%, 18/20), or EY-C (79%, 15/19) had significantly greater conception rates than mares bred with SKM (30%, 6/20; $P < .05$). Mares bred with SKM-C had intermediate conception rates (62%, 13/21). In conclusion, SC and EY

Research Abstract—for more information, contact the corresponding author

NOTES

improved the cooling ability and fertility of donkey semen in horse mares, and centrifugation positively affected donkey semen extended in SKM.

Acknowledgments

Funding Sources

The Authors would like to thank FAPESP (Fundação de Apoio a Pesquisa no Estado de São Paulo) and CAPES (Coordination for the Improvement of Higher Education Personnel) for supporting the study.

Declaration of Ethics

The Authors have adhered to the Principles of Veterinary Medical Ethics of the AVMA.

Conflict of Interest

The Authors have no conflicts of interest.

Footnotes

[a]BotuSemen Special, Botupharma, Brazil.
[b]BotuSemen Gold, Botupharma, Brazil.
[c]BotuCrio, Botupharma, Brazil.

Sperm Filter and Re-extension of Cooled-Shipped Semen as an Alternative to Circumvent Poor Cooling Ability of Stallions

Lorenzo G.T.M. Segabinazzi, DVM, MS, PhD*; Marcio T. Carmo, DVM, MS, PhD; Camila Dell'Aqua, DVM, MS, PhD; Marco A. Alvarenga, DVM, MS, PhD; Frederico O. Papa, DVM, PhD; and Igor Canisso, DVM, MSc, PhD, DACT, DECAR

Sperm parameters and fertility of poor cooled-transported semen can be enhanced by semen processing and re-extension in an egg yolk–based extender. Authors' addresses: Ross University School of Veterinary Medicine, Basseterre, St. Kitts, West Indies, 00265 (Segabinazzi); Faculty of Veterinary Medicine and Animal Science, São Paulo State University (UNESP), Botucatu, SP, Brazil, 18618-681 (Segabinazzi, Carmo, Dell'Aqua, Alvarenga, Papa); Department of Veterinary Clinical Medicine, College of Veterinary Medicine, University of Illinois Urbana Champaign, Urbana, IL 61802 (Canisso); e-mail: lgseg@hotmail.com. *Corresponding and presenting author. © 2022 AAEP.

1. Introduction

Cooled-shipped semen is the primary method used by the horse industry to breed mares. Unfortunately, some stallions have inadequate cooling ability. Therefore, there is a critical need to develop alternative methods to process semen from such stallions. This study aimed to assess semen parameters and fertility of cooled-stored stallion semen processed and re-extend in 3 extenders.

2. Materials and Methods

Cooled-stored semen of 21 stallions classified as *good coolers* (GCs, n = 8), *bad coolers* (BCs, n = 6), or subfertile (n = 7) had the supernatant removed by SpermFilter[a] (SF) or centrifugation (600 × *g*/10 min). The resulting pellets from either method were resuspended in either skim milk–based (SKM),[b] SKM containing pentoxifylline (SKM-P),[c] or an egg yolk–based (EY)[d] extender. The control consisted of cooled semen with no further processing. Sperm motility parameters, plasma membrane integrity (PMI), and mitochondrial membrane potential (HMMP) were assessed in all samples. In addition, semen from 9 stallions with a bad cooling ability (4–8 ejaculates) was used to breed 66 cycles of 18 mares (control, n = 22; SF-SM-P, n = 16; or SF-EY, n = 28 cycles).

3. Results and Discussion

Sperm motility was increased ($P < .05$) in all samples with resuspended EY compared with the control, SKM,

Research Abstract—for more information, contact the corresponding author

NOTES

and semen centrifuged and resuspended in SKM-P. Semen processed by SF and resuspended in SKM-P was similar to EY groups ($P > 0.05$). HMMP was benefited ($P < .05$) by EY and SKM-P in BC and subfertile stallions. Semen processed by SF had superior PMI than centrifuged semen ($P < .05$). In addition, mares inseminated with SF-SM-P (50%) or SF-EY (68%) had higher pregnancy rates than mares inseminated with the control (14%; $P < .05$). In conclusion, sperm parameters and fertility of poor cooled-transported semen can be enhanced by removing the supernatant by SF and sperm resuspension with EY or SKM-P.

Acknowledgments

Funding Sources

This study was supported by FAPESP (Fundação de Apoio a Pesquisa no Estado de São Paulo), number 2017/13883-9.

Declaration of Ethics

The Authors have adhered to the Principles of Veterinary Medical Ethics of the AVMA.

Conflict of Interest

The Authors have no conflicts of interest.

Footnotes

[a]SpermFilter®, Botupharma, Brazil.
[b]BotuSemen®, Botupharma, Brazil.
[c]BotuTurbo®, Botupharma, Brazil.
[d]BotuCrio®, Botupharma, Brazil.

How to Evaluate and Diagnose a Disorder of Sexual Development in the Horse

Patrick M. McCue, DVM, PhD, DACT*; Brittany T. Middlebrooks, DVM, MS; Emily M. May, DVM; and Christina J. Divine, DVM

Chromosomal abnormalities and disorders of sexual development (DSD) in horses can be diagnosed by a combination of reproductive history, physical and reproductive examinations, hormone assessment, and ultimately a karyotype. Authors' address: Equine Reproduction Laboratory, Colorado State University, 3101 Rampart Road, Fort Collins, CO 80521; e-mail: pmccue@colostate.edu. *Corresponding and presenting author. © 2022 AAEP.

1. Introduction

Development of the reproductive tract of horses and other mammalian species follows a specific order of events, beginning with establishment of chromosomal sex, followed by establishment of gonadal sex, development of the internal genitalia, and finally development of the external genitalia.[1] The phrase disorders of sexual development (DSD) is currently used to describe congenital conditions associated with atypical development of chromosomal, gonadal, or anatomic sex.[2] Horses with a DSD may present as a normal phenotypic female or male, or the external genitalia may be ambiguous, with various degrees of masculinization.[3] In addition, chromosomal abnormalities and disorders of sexual development may be associated with reduced fertility or infertility.[3,4]

The goals of this review are to provide a brief overview of normal development of the reproductive tract and describe a clinical approach on how to investigate and diagnose DSDs in horses utilizing a series of clinical cases.

2. Normal Development of the Reproductive Tract

Chromosomal or genetic sex is determined at the time of fertilization and is dependent on the sex chromosome constitution of the spermatozoon (Fig. 1). Establishment of gonadal sex, or differentiation of the bipotential precursor tissue of the fetal genital ridge into either male gonads (testes) or female gonads (ovaries), is initiated by the presence or absence of the sex-determining region of the Y chromosome.[1] Testes develop in the presence of a Y-chromosome containing a SRY region (*Sry* gene) following upregulation and activation of male-specific genes (*Sox9, Fgf9, Pgds, Amh*). In contrast, ovaries develop in the absence of an SRY region and associated genes.

Male and female embryos both have 2 sets of primordial internal reproductive duct systems.[1] The Wolffian duct is the embryonic precursor to male internal genitalia that eventually develops into the epididymis, vas deferens, and seminal vesicles. The Müllerian duct is the embryonic precursor to female internal genitalia that eventually develops into the

NOTES

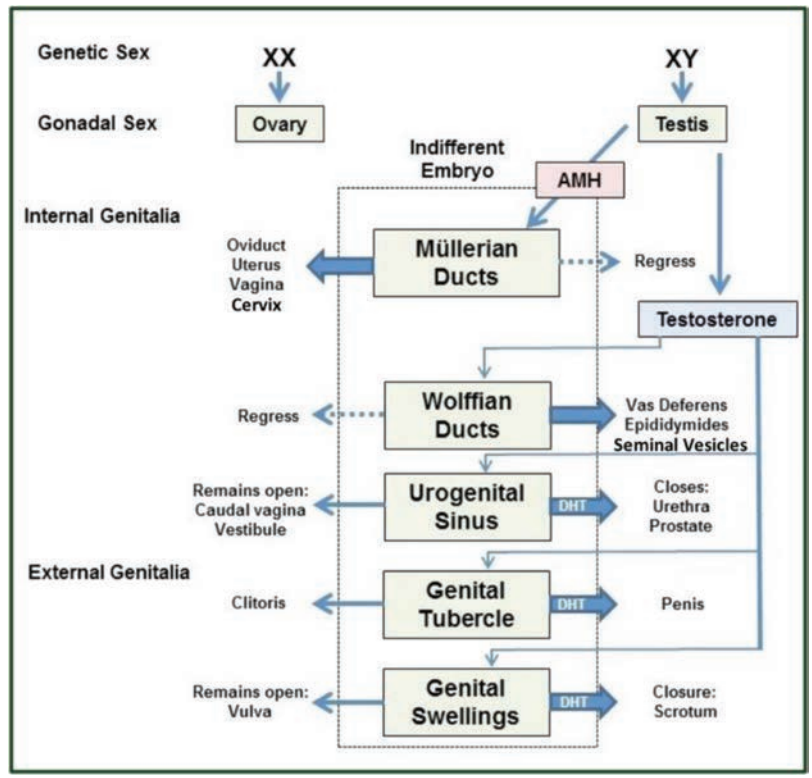

Fig. 1. Development of the reproductive tract (adapted from Meyers-Wallen VN. *J Reprod Fert* 1993;47:441–452).

oviduct, uterus, cervix, and cranial vagina. Normal development of the internal genitalia follows differentiation of the gonads. In the male, testosterone produced by Leydig cells of the testes stimulates development of the Wolffian duct, and anti-Müllerian hormone (AMH) produced by Sertoli cells causes regression of the Müllerian duct system. In the female, in the absence of testosterone and AMH, the Wolffian duct fails to develop, and the Müllerian duct continues to develop into the normal female reproductive tract.

Embryonic tissues in the perineal region are bipotential and can develop into either male or female anatomic structures.[1] The external genitalia will develop into a female form (i.e., clitoris, vulva, vestibule, and caudal vagina) unless there is active intervention initiated by production of gonadal hormones to direct development into male structures (i.e., penis and scrotum). Testosterone produced by Leydig cells of the fetal testis is converted into dihydrotestosterone (DHT) by the enzyme 5α-reductase in peripheral tissues. DHT binds to the androgen receptor (AR) in peripheral tissue and initiates formation of the penis and scrotum in males. In the absence of testosterone, 5α-reductase, DHT, or a functional AR, the external genitalia develop into a clitoris, vulva, vestibule, and caudal vagina.

3. Clinical Presentation and Evaluation

Horses with a chromosomal abnormality or disorder of sexual development may present for a routine prebreeding reproductive evaluation, or evaluation of small size or stature, lack of vigor, masculine behavior, failure to show estrus, failure to cycle, reduced fertility, infertility, embryonic loss, or ambiguous external genitalia.[5–7] Disorders of sexual development may go undetected in a young horse until a reproductive examination is eventually performed. The initial diagnostic evaluation should include acquisition of a complete and accurate medical and reproductive history, behavioral assessment (if possible), general physical examination (including an oral examination), examination of the external genitalia, and transrectal palpation and ultrasound examination (Table 1).[8] Additional diagnostic procedures that may be indicated based on the results of the initial evaluation include vaginal speculum examination, endocrine analysis, exploratory laparoscopy, and other tests. Ultimately, a definitive diagnosis is made by chromosomal analysis (karyotype), polymerase chain reaction (PCR) analysis of the presence or absence of the *Sry* gene, and histopathological evaluation of gonadal tissue.

4. Chromosomal Issues and Disorders of Sexual Development in Horses

The normal karyotype of the mare and stallion is 64,XX and 64,XY, respectively. Estimates of the prevalence of sex chromosome disorders in the general population of horses range from 1.5% to 5.5%.[9–11] Parada and coworkers[12] reported a cytogenetic survey of 244 problem mares in which 4% of all mares and 12.8% of sterile mares had chromosome aberrations. A cytogenetic analysis of 766 horses with congenital abnormalities,

Table 1. Diagnostic Tests for Evaluation of a Potential Disorder of Sexual Development

Diagnostic Test	Indications and Comments
Medical and reproductive history	Review reported behavior (normal vs abnormal), previous medical exams and procedures, reproductive history (breeding, pregnancies, live foals), etc.
Behavioral evaluation	Expression of stallion-like or aggressive behavior; behavioral estrus; prolonged anestrus, etc.
General physical examination	Body condition and overall health; degree of masculinization or muscle mass; oral exam to confirm age and evaluate canine teeth (male vs female), etc.
Genital examination	Perineal area; vulva and clitoris; mammary gland; inguinal and scrotal area; testes; sheath, prepuce, and penis
Speculum examination	Vaginal assessment (complete vs "blind" ended); cervical anatomy
Transrectal palpation/ultrasound	Gonads (ovaries vs cryptorchid testes); internal genitalia (uterus vs male accessory sex glands)
Hormone analysis	Endocrine markers for functional testes or ovaries (anti-Müllerian hormone, testosterone, inhibin, progesterone, estrone sulfate); markers for ovarian tumors (GCT/GTCT)
Exploratory laparoscopy	Evaluate presence of gonads (ovaries vs cryptorchid testes); gonadectomy or biopsy; internal genitalia
Chromosomal analysis (karyotype)	Evaluate chromosome number and structure; detect aneuploidy, mosaicism, chimerism, translocations, and other chromosomal abnormalities; determine presence or absence of the *Sry* gene. Sample submission: whole blood in sodium or lithium heparin tube(s)
Histopathology	Assessment of the gonad for ovarian or testicular tissue

Table 2. Endocrine Parameters in a Mare With 63,X Monosomy

Hormone*	Clinical Case	Normal Range
Anti-Müllerian hormone (ng/mL)	0.02	0.1 to 3.8
Inhibin (ng/mL)	0.18	0.1 to 0.7
Progesterone (ng/mL)	0.01	<1.0 in estrus or anestrus >1 in diestrus
Testosterone (pg/mL)	48.5	20 to 45
Estrone sulfate (ng/mL)	0.01	0.1 to 10.0 for a nonpregnant mare

*Clinical Endocrinology Laboratory, University of California, Davis.

disorders of sexual development and/or reproductive problems noted that 28% of problem horses had karyotype abnormalities.[5] The most common chromosomal abnormality in horses is 63,X monosomy and its mosaic forms.[5,7,10,12,13] The second most frequent karyotype aberration is 64,XY SRY-negative DSD, followed by 64, XY SRY-positive DSD.[5] Numerous other chromosomal abnormalities have also been reported in horses.[5,6]

Laboratories in the United States that perform karyotyping of equine samples are listed below.

- Molecular Cytogenetics Laboratory, 664 Raymond Stotzer Pkwy, VICI 126, Texas A&M University, College Station, TX 77843-4458

https://vetmed.tamu.edu/molecular-cytogenetics

- Veterinary Genetics Laboratory, Old Davis Road, School of Veterinary Medicine, University of California–Davis, Davis, CA 95616

https://vgl.ucdavis.edu

5. Clinical Cases—Disorders of Sexual Development

Assessment of clinical cases of DSD in horses provides an opportunity to highlight a pathway to a clinical diagnosis. The diagnostic strategy should begin by acquisition of a thorough medical and reproductive history, followed by a general physical examination and a reproductive evaluation. A list of differential diagnoses can then be formulated. Subsequently, additional diagnostic tests are performed to rule in or out specific conditions and ultimately lead to a final diagnosis.

Case 1. 63,X Monosomy

A 5-year-old Quarter Horse mare was evaluated in early March as a potential breeding candidate. The mare had been owned by the same person since birth and had never been bred. Physical examination revealed that the mare was small to medium in size and was in good body condition. The perineum was normal for a mare, with no abnormalities noted. Transrectal palpation revealed a small oval structure adjacent to the tip of each uterine horn and the uterus was noted to be small and flaccid. Ultrasound examination confirmed that the ovaries were small (~1.5 cm in diameter) and each contained several small follicles. A vaginal speculum examination revealed a normal vaginal vault and a normal external cervical os. The cervix was closed, pale, dry, and located low on the cranial vaginal wall. A hymen was present at the vestibular-vaginal junction and was disrupted during initial

passage of the speculum. Hormone analysis indicated that serum concentrations of anti-Müllerian hormone (AMH), inhibin, progesterone, and estrone sulfate were all low, whereas testosterone concentration was slightly above the normal range for mares (Table 2).

Differential diagnoses included a young prepubertal mare, an older mare with ovarian senescence, a mare in winter anestrus, exogenous hormone (i.e., anabolic steroid) administration, pituitary pars intermedia dysfunction, and a chromosomal abnormality. In this case, the mare was a young adult and had never been administered any type of exogenous hormones. The relatively young age suggested that pituitary pars intermedia dysfunction was unlikely, as the condition is usually associated with older mares. However, the initial examination was performed in early March, a time when seasonal anestrus could result in small inactive ovaries. Consequently, it was recommended that the mare be re-examined during the physiologic breeding season. A recheck in mid-April revealed that the ovaries were still small and inactive. A blood sample was subsequently collected and submitted for karyotype analysis. Chromosomal analysis confirmed a diagnosis of 63,X monosomy (Fig. 2). The mare was subsequently retired as a potential broodmare.

Clinical Comments

63,X monosomy and its mosaic forms (63,X/64,XX and 63,X/64,XY, etc.) are the most common chromosomal abnormality of mares.[3,5–7,14,15] Approximately 31% to 51% mares with chromosomal abnormalities or gonadal dysgenesis have a 63,X karyotype.[5,7,13] Affected mares may be small in stature, with small hypoplastic ovaries, often with minimal follicular activity, a small flaccid uterus and a normal vagina, vulva, and clitoris. A majority of 63,X mares are infertile, but 63,X mosaic mares have been reported to produce foals.[16]

Case 2. 64,XY SRY-Negative DSD

A 7-year-old Quarter Horse mare was referred in May for a reproductive evaluation. The owner indicated that they had never seen the mare in heat. Physical examination revealed that the mare was in good body condition, the vulva and clitoris were normal, and a small mammary gland, consistent with that of a maiden mare, was noted. Transrectal ultrasound examination revealed very small gonads (1.5 cm in length), devoid of any visible follicles, adjacent to the tip of each uterine horn. A speculum examination revealed a normal vaginal vault and a normal external cervical os. Hysteroscopy showed a normal uterine lumen with uterotubular junctions visible at the tip of each uterine horn. Hormone analysis revealed low concentrations of all ovarian hormones (Table 3).

A chromosomal abnormality was considered the most likely cause of the inactive ovaries and failure to exhibit heat, since the mare was 7 years old, had never received hormone therapy, and the examination

Fig. 2. Ultrasound image of the left ovary (arrow) of a mare with 63,X monosomy.

Table 3. Endocrine Parameters in a Phenotypic Mare With a 64,XY SRY-Negative Karyotype

Hormone*	Clinical Case	Normal Range
Anti-Müllerian hormone	0.01 ng/mL	0.1 to 3.8 ng/mL
Inhibin	0.21 ng/mL	0.1 to 0.7 ng/mL
Progesterone	0.12 ng/mL	<1.0 ng/mL in an estrus or anestrus mare >1 ng/mL in a diestrus mare
Testosterone	27.6 pg/mL	20 to 45 pg/mL

*Clinical Endocrinology Laboratory, University of California, Davis.

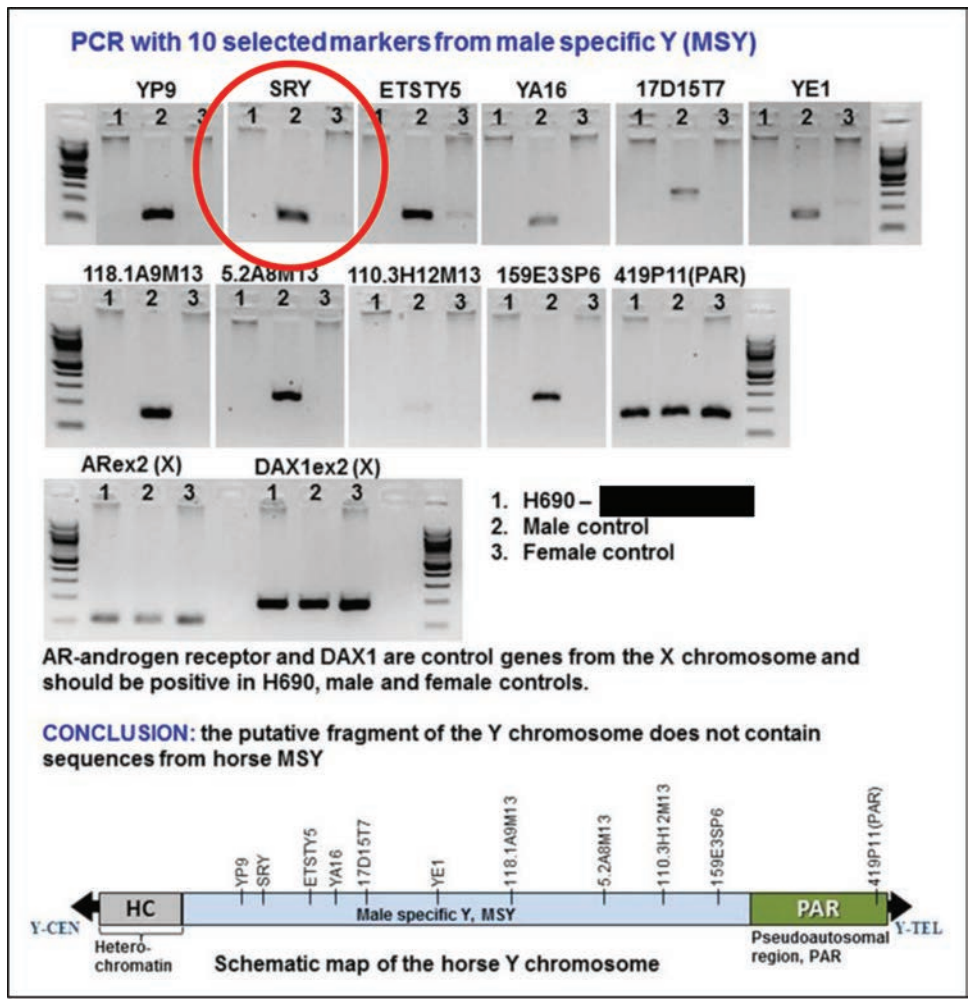

Fig. 3. PCR analysis on a 64,XY SRY-negative DSD phenotypic mare. The circled area indicates the absence of the SRY region (courtesy of the Molecular Cytogenetics Laboratory, Texas A&M University).

was performed in the late spring. A blood sample submitted for chromosomal analysis revealed a 64,XY karyotype and a PCR test confirmed the absence of the sex-determining region of the Y chromosome (SRY) (Fig. 3). The gonads were removed by laparoscopic surgery and histologic analysis indicated that the gonads were devoid of any normal ovarian or testicular structures.

Clinical Comment

Horses with 64,XY SRY-negative DSD have female external genitalia, a vagina, cervix, and flaccid uterus, along with small, dysgenic gonads.[6] The condition is caused by deletion of the SRY region of the Y chromosome. Absence of the SRY region results in failure of the undifferentiated fetal gonad to develop into testes, and in the absence of testicular hormones (testosterone and AMH), the internal genitalia and external genitalia develop into typical female structures. The phenotype resembles that of 63,X monosomy and the conditions are distinguished by karyotype.[3,5]

Case 3. 64,XY SRY-Positive Monorchid DSD

A 4-year-old Quarter Horse mare was referred for stallion-like behavior and an elevated serum testosterone level. Differential diagnoses included a granulosa-theca cell tumor, pregnancy, disorder of sexual development, estrus, and anabolic steroid administration. Oral examination revealed erupting canines, the size of which were consistent with that of a mare. External genitalia consisted of a normal vulva and clitoris. A mammary gland with 2 small bilaterally symmetric teats was noted. Transrectal ultrasound revealed a structure in the right abdomen consistent with the morphologic appearance of a testicle. No gonadal structure was identified on the left side. A vaginal speculum examination revealed a short, "blind-ended" vaginal vault, with no cervix. Hormone analysis revealed that anti-Müllerian hormone, testosterone, and estrone sulfate concentrations were above the upper limit of the laboratory reference ranges for a nonpregnant mare (Table 4). Cytogenetic analysis of a blood sample revealed a 64,XY karyotype, and PCR assay confirmed presence of the sex-determining

Table 4. Endocrine Parameters in a Phenotypic Mare with a 64,XY SRY-Positive Karyotype

Hormone*	Clinical Case	Normal Range			
		Mares	Gelding	Cryptorchid	Stallion
Anti-Müllerian hormone (ng/mL)	96	0.1 to 6.9	n/a	>0.15	n/a
Inhibin-B (pg/mL)	76	2 to 100	n/a	n/a	n/a
Testosterone (pg/mL)	731	20 to 45	<50	100 to 500	800 to 2000
Estrone sulfate (ng/mL)	11	0.1 to 6	<0.1	35 to 60	140 to 200

*Clinical Endocrinology Laboratory, University of California, Davis.

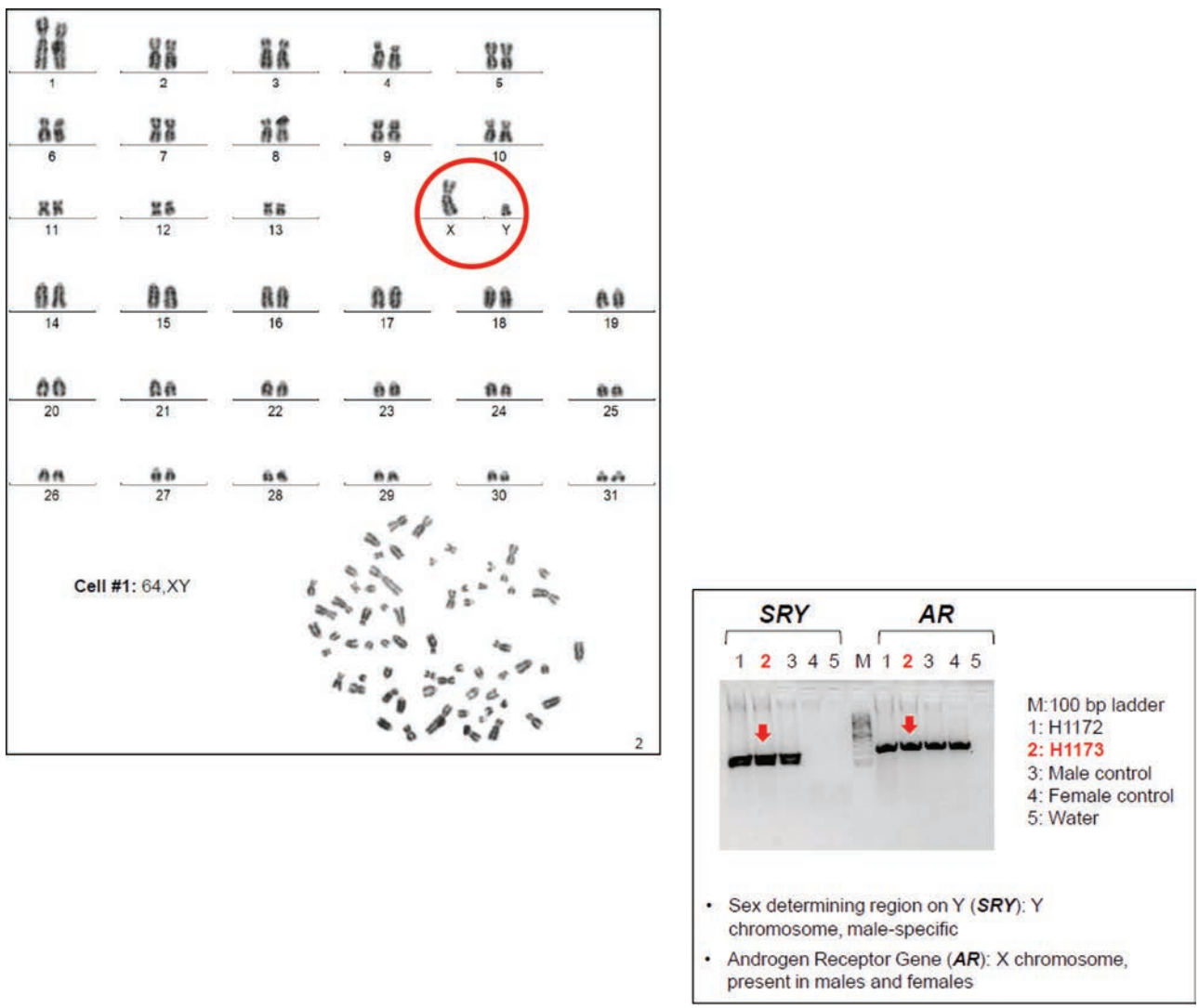

Fig. 4. Karyotype (left image) showing the 31 pairs of autosomes and the 2 sex chromosomes (X and Y, red circle) in a 64,XY SRY-positive monorchid DSD. PCR analysis (right image) shows the presence of the SRY region (lane 2, red arrow) and androgen receptor (AR) (lane 2, red arrow) (courtesy of the Molecular Cytogenetics Laboratory, Texas A&M University).

region of the Y chromosome (SRY) (Fig. 4). A standing laparoscopic procedure was performed and a cryptorchid testis was identified on the right side of the abdomen and subsequently removed. No gonadal structure was noted on the left side during laparoscopy. Histopathology of the excised right gonad revealed degenerate seminiferous tubules with no evidence of spermatogenesis, along with spermatogonia, Sertoli cells, and Leydig cells. In addition, an island of adrenal cortical tissue was identified histologically within the cryptorchid testis, and epididymal tissue was noted adjacent to the testis. Immunohistochemistry confirmed the presence of anti-Müllerian hormone protein in Sertoli cells. Re-evaluation 5 weeks after surgery confirmed that the stallion-like behavior had resolved, and all

Fig. 5. Sheath and teats in a 64,XX SRY-negative DSD phenotypic male.

endocrine parameters were in the normal range of nonpregnant mares or geldings.

Clinical Comments

Approximately 12% to 30% of all chromosomal abnormalities in the mare are XY DSDs.[7,17] 64,XY SRY-positive DSD horses typically have cryptorchid testes, elevated testosterone, male-like behavior, and ambiguous or female-like external genitalia. Affected horses may have an enlarged clitoris with or without a vulva and a blind-ended vagina.[13] A previous term for this condition was male pseudohermaphroditism, indicating a lack of correlation between gonadal sex (testes) and phenotypic sex (female). The pathophysiology is hypothesized to be a mutation of the androgen receptor gene.[6] An alternative cause may be inadequate conversion of testosterone to DHT by the enzyme 5α-reductase.

In the clinical case, only 1 testis was detected in the abdomen and monorchidism was confirmed by the decrease in testosterone and AMH concentrations and the elimination of male behavior following surgical removal of the single gonad. The presence of ectopic adrenal cortical tissue within the testis was unexpected but has been reported previously in testes and ovaries of horses and other species.[18]

Case 4. 64,XX SRY-Negative DSD

A Friesian-cross phenotypic male horse was referred for a reproductive evaluation. The horse was purchased as a gelding, but the medical and surgical history were unknown. Genotyping for parentage testing indicated that the horse had 2 X chromosomes (64,XX). Oral examination revealed a pair of large male-type canines. The sheath appeared slightly edematous, and the opening was oriented somewhat ventrally and appeared to be folded in on itself. Prominent teats were noted on the lateral aspects of the sheath (Fig. 5). There was no evidence of a scrotum, no evidence of testes, and no visual or palpable evidence of a surgical castration scar. The penis was gently extended from the sheath and appeared smaller than expected, but had a glans penis, urethral process, and urethral fossa. The perineum had a prominent fold of tissue running ventrally from the anus along the midline toward the sheath. Transrectal palpation and ultrasound examination failed to detect any evidence of gonads or other reproductive structures. Serum concentration of testosterone (11.1 pg/mL) was within the normal range of a gelding (<50 pg/mL) and AMH concentration was below the limit of detection of the assay (<0.1 ng/mL). Chromosomal analysis of a blood sample confirmed that the horse had a karyotype of 64,XX, and a PCR test for the Y-linked *Sry* gene was negative, consistent with the absence of a Y chromosome.

Clinical Comment

A 64,XX SRY-negative karyotype in horses with an enlarged clitoris, ambiguous genitalia, male-like behavior, or a relatively normal male phenotype has been reported previously,[5,19,20] but is the least common of the 4 DSD conditions described in this report. The molecular cause(s) for the condition are unknown.

6. Summary

An understanding of the anatomic and endocrine events associated with normal development of the male and female reproductive tract is key to understanding the pathogenesis of disorders of sexual development. The external genitalia of horses with a DSD may appear as female, male, or may be ambiguous. Behavior exhibited by affected horses ranges from anestrus to stallion-like and is dependent on the predominant steroid hormone (if any) produced by the gonads. The definitive diagnosis of a DSD is a chromosome analysis and determination of the presence or absence of the *Sry* gene. The number of clinical cases of DSD in horses is likely underestimated and many cases remain undetected unless abnormal behavior, ambiguous genitalia, or other issues are present. Mares with a history of subfertility, infertility, or repeated embryonic loss may have a chromosomal abnormality and warrant further investigation.[21–23] A few chromosomal abnormalities, such as balanced translocations, can be hereditary and passed from a carrier to their offspring, while other abnormalities may result in early embryonic loss and subfertility.[5,24]

Acknowledgments

Declaration of Ethics

The Authors have adhered to the Principles of Veterinary Medical Ethics of the AVMA.

Conflict of Interest

The Authors have no conflicts of interest.

References

1. Johnson MH. Sex. In: Johnson MH, ed. *Essential Reproduction*. West Sussex, UK: Wiley-Blackwell; 2013:35–49.

2. Lee PA, Houk CP, Ahmed SF, et al. Consensus statement on management of intersex disorders. *Pediatrics* 2006;118:e488–500.
3. Raudsepp T. Genetics of equine reproductive diseases. *Vet Clin North Am Equine Pract* 2020;36:395–409.
4. Long SE. Chromosome anomalies and infertility in the mare. *Equine Vet J* 1988;20:89–93.
5. Bugno-Poniewierska M, Raudsepp T. Horse clinical cytogenetics: Recurrent themes and novel findings. *Animals* 2021;11:831.
6. Lear TL, McGee RB. Disorders of sexual development in the domestic horse, Equus caballus. *Sex Dev* 2012;6:61–71.
7. Bowling AT, Millon L, Hughes JP. An update of chromosomal abnormalities in mares. *J Reprod Fert Suppl* 1987; 35:149–155.
8. McCue Pm. Reproductive evaluation of the mare. In: Dascanio JJ, McCue PM, eds. *Equine Reproductive Procedures*. 2nd ed. Hoboken, NJ: Wiley-Blackwell; 2021:1–5.
9. Nie GJ, Momont HW, Buoen L. A survey of sex chromosome abnormalities in 204 mares selected for breeding. *J Equine Vet Sci* 1993;13:456–459.
10. Bugno M, Słota E, Kościelny M. Karyotype evaluation among young horse populations in Poland. *Schweiz Arch Tierheilkd* 2007;149:227–232.
11. Wojtaszek M, Kowalska K, Witarski W. Diagnostics of horse karyotype aberrations: The initial results of screening. *Wiadomosci Zootech R Lv* 2017;5:49–55.
12. Parada R, Jaszczak K, Sysa P, et al. Cytogenetic investigations of mares with fertility disturbances. *Pr Mat Zoot* 1996;48:71–81.
13. Power MM. Chromosomes of the horse. *Adv Vet Sci Comp Med* 1990;34:131–167.
14. Bruère AN, Blue MG, Jaine PM, et al. Preliminary observations on the occurrence of the equine XO syndrome. *NZ Vet J* 1978;26:145–146.
15. Stewart-Scott IA, Pearce PD, Burkin DJ. Further cases of equine sex chromosome abnormalities. *NZ Vet J* 1990;38: 54–56.
16. Neuhauser S, Handler J, Schelling C, et al. Fertility and 63, X mosaicism in a Haflinger Sibship. *J Equine Vet Sci* 2019;78:127–133.
17. Raudsepp T, Durkin K, Lear TL, et al. Molecular heterogeneity of XY sex reversal in horses. *Anim Gen* 2010;41:41–52.
18. Marino G, Quartuccio M, Rizzo S, et al. Ectopic adrenal tissue in equine gonads: Morphofunctional features. *Turkish J Vet Anim Sci* 2012;36:560–565.
19. Bannasch D, Rinaldo C, Millon L, et al. SRY negative 64, XX intersex phenotype in an American Saddlebred horse. *Vet J* 2007;173:437–439.
20. Villagómez DA, Lear TL, Chenier T, et al. Equine disorders of sexual development in 17 mares including XX, SRY-negative, XY, SRY-negative and XY, SRY-positive genotypes. *Sex Dev* 2011;5:16–25.
21. Makinen A, Hasegawa T, Syrja P, et al. Infertile mares with XO and XY sex chromosome deviations. *Equine Vet Educ* 2010;18:60–62.
22. Shilton CA, Kahler A, Davis BW, et al. Whole genome analysis reveals aneuploidies in early pregnancy loss in the horse. *Sci Rep* 2020;10:2.
23. Pieńkowska-Schelling A, Kaul A, Schelling C. X chromosome aneuploidy and micronuclei in fertile mares. *Theriogenology* 2020;147:34–38.
24. Raudsepp T, Chowdhary BP. Chromosome aberrations and fertility disorders in domestic animals. *Annu Rev Anim Biosci* 2016;4:15–43.

Decreased Equine Chorionic Gonadotropin Secretion Following Hysteroscopic-Guided Injection of an Immunomodulator

Maria R. Schnobrich, VMD, DACT*; Robert Douglas, PhD; M.H.T Troedsson, DVM, PhD, DACT, DECAR; and Carleigh Fedorka, PhD

Hysteroscopic-guided injection of endometrial cups with an immunomodulator (mycobacterium cell wall fraction[a]) led to a reduction of equine chorionic gonadotropin following prostaglandin F2α-induced abortion.
Authors' addresses: Rood and Riddle Equine Hospital, PO Box 12070, Lexington, KY 40580-2070 (Schnobrich); Gluck Research Center, 1400 Nicholasville Road, Lexington, KY 40546 (Douglas, Troedsson, Fedorka); e-mail: mschnobrich@roodandriddle.com. *Corresponding and presenting author. © 2022 AAEP.

1. Introduction

The initial invasive aspects of equine placentation at approximately 30 days of gestation include the formation of endometrial cups that secrete equine chorionic gonadotropin (eCG). This hormone luteinizes follicles, resulting in the development of accessory corpora lutea and prolonged suppression of estrus. Hence, pregnancy loss after the development of endometrial cups often leads to the inability to breed mares back for the remainder of the breeding season. To date, no treatment has been found effective in the early reduction/elimination of endometrial cups following pregnancy loss. Endometrial cups are naturally degraded by effector lymphocytes between 100 and 150 days of gestation. Immunomodulators such as mycobacterium cell wall fraction (MCWF) have been shown to increase the expression of specific cytokines essential in stimulating the production of these effector lymphocytes, but it is unknown if this stimulation will hasten the degradation of endometrial cups.

2. Materials and Methods

Pregnancy was established in 9 mares ($n = 9$) before prostaglandin F2α-induced abortion was performed at 45 days of gestation. Ten days after abortion, hysteroscopic-guided injection of either treatment ($n = 5$; 0.3 mg/mL MCWF) or placebo ($n = 4$; lactated Ringer's solution) occurred, with mares randomly assigned into groups. Treatment consisted of total 20-mL volume of intraendometrial injection (1 mL/endometrial cup, with any excess volume being injected peripherally into the endometrial stroma surrounding the cups). Blood was obtained prior to hysteroscopy, in addition to weekly post-treatment to measure eCG as a marker of endometrial cup viability, and this continued for 8 weeks.

3. Results and Discussion

Hysteroscopic-guided injection of the immunomodulator MCWF led to a significant reduction of eCG

Research Abstract—for more information, contact the corresponding author

NOTES

concentration in comparison to placebo-treated mares. This reduction in eCG concentration was most pronounced at 7 days following treatment, with a diminished response noted throughout the remainder of the study. Return to cyclicity could not be assessed under the confines of this study as mares were treated in late fall of Central Kentucky and therefore became acyclic due to winter anestrus. Future research is warranted to determine the clinical ramifications of this decrease in eCG concentrations following treatment with the immunomodulator MCWF.

Acknowledgments

Declaration of Ethics

The Authors have adhered to the Principles of Veterinary Medical Ethics of the AVMA.

Conflict of Interest

This study was funded in part from unrestricted gifts by NovaVive in support of Dr. Troedsson's research program, and Settle® was provided by the company free of charge for this project.

Footnote

[a]Settle®, NovaVive USA Inc., Athens, GA 30601.

Arthritis Prevention in Sport Horses

Caitlin O'Shea, DVM, MS, DACVS-LA, CVA

Author's address: 1002 S Palmetto Avenue, Ontario, CA 91762; e-mail: cmboshea@gmail.com.
© 2022 AAEP.

1. Introduction

Veterinarians counsel clients that arthritis, "degenerative joint disease," is a degenerative condition by definition. One of the main goals in treatment, along with alleviating pain (symptom modification), is to slow progression of the disease process (disease modification). Prevention of arthritis is the ultimate goal, but many strategies in use are still speculative and supported by anecdotal and/or poorly documented evidence. Inflammation is central in both pain and degenerative pathways. Recognizing predisposing factors as well as signs of inflammation in a joint early, when still in synovitis stage, affords many more treatment options and the ability to not only enhance current performance but also extend comfort level into geriatric years. Normal forces on abnormal cartilage and abnormal forces on normal cartilage are both known to lead to degenerative joint disease. Improving biomechanics is therefore one of the most fundamental preventive measures, but in-depth discussion of therapeutic farriery, hoof-ground interface, conformation and posture, and rider interference is beyond the scope of this presentation. This session will focus on describing physical manipulation techniques and monitoring as well as the purported mechanisms of action of available oral supplements to equip veterinarians to have meaningful discussions with clients and other professionals involved in the equine athletic team. Although specific regulating bodies should be consulted, at the time of writing, the modalities discussed are allowed during competition in most performance horses.

2. Physical Manipulation and Physical Therapy Exercises

Patient education, exercise, and weight management are the primary preventive management strategies for osteoarthritis in human medicine.[1] While most of the athletic population of sport horses is not obese, client education on conformation, training practices, realistic objectives, and goal setting, along with individually targeted exercise regimes, are areas where the most impact in prevention of osteoarthritis can be made. Frequent, open communication with clients and trainers as well as with therapists providing bodywork modalities coupled with an understanding of the specific sports the equine patients are competing in allow the practitioner to recognize subtle changes in performance and effect change earlier.

Exercise includes building cardiovascular fitness and musculoskeletal strength as well as flexibility and proprioception.[2] Cross-training of equine athletes including stretching and mobility exercises along with aerobic conditioning in underwater treadmills of different water depths may not only improve muscle strength and supportive structures around joints but also improve proprioception and thereby decrease the risk of injury. It is widely accepted that core strength conditioning in human athletes reduces risk of injury in addition to enhancing performance. It is intuitive that horses can benefit from similar training of the core stabilizing muscles. Cross-training enables an increase in athleticism while decreasing the risk of repetitive use injuries.[3]

NOTES

Specific training strategies for each discipline are beyond the scope of this presentation, but there is evidence that bones, cartilage, and the surrounding soft tissues respond (favorably or unfavorably) to the forces applied to them. Therefore, incorporating dynamic mobility exercises and core strengthening maneuvers to equine athletes' daily routines can help build supporting musculature and stave off injury, fatigue, and misuse of joints. Core strengthening is considered a progression of dynamic mobilization.[4] Studies on the effects of specific dynamic mobilization exercises have focused on axial and core musculature and have demonstrated not only hypertrophy of the multifidus muscle but also improved symmetry in muscle size.[5] Gymnastic exercises including backing up, tight turns around barrels, and walking over raised poles performed 3 days per week were shown to significantly increase stride and tracking lengths.[6] Ground poles and cavaletti gymnastic exercises increase joint flexion.[7] Joint mobility is substantially increased following heating.[8] An adequate warm-up period and/or application of heat in the form of wraps and blankets prior to stretching can improve the elasticity joint capsules and tendons as well as muscles.[8] Although further research is needed, since symmetrical conformation and posture is important in the even application of forces across joint spaces, it is reasonable to assume that a routine of dynamic mobilization and gymnastic exercises could help prevent or mitigate degenerative joint disease in the distal limb by improving posture and motion.

Often the terminology used in integrative treatment modalities to describe disturbances is confusing and leads to misunderstandings between different types of practitioners. Chiropractors speak of "luxations" that seem anatomically impossible, and acupuncturists describe energy blockages that may not be detected in Western examinations. In physiotherapy or physical therapy, a "functional diagnosis" results from a static and dynamic *functional* assessment rather than a *pathoanatomic* diagnosis veterinarians are trained to provide.[9] Acupuncture, myofascial release, spinal manipulation, joint mobilization, and other bodywork have been purported to improve joint and overall health. There are no studies specifically supporting their effectiveness in preventing distal limb osteoarthritis in horses, but some reviews have shown improvement in human chronic knee pain following acupuncture.[10] These modalities are thought to be most effective in early recognition of abnormalities. For example, a traditional Chinese veterinary medicine diagnosis may be made prior to any clinical signs of osteoarthritis being present from a Western veterinary medicine perspective. However, this is difficult to investigate in blinded controlled studies, so objective data is lacking. Acupuncture often takes several sessions to achieve effect, which gives the practitioner the additional benefit of repeated intense observation. This allows practitioners to recognize and address areas of weakness rather than waiting for overt injury.

Incorporating objective assessments of motion and physical condition into examinations and medical records can help monitor individual cases and recognize pathology earlier as well as describe response to treatments more accurately and precisely for discussion with other professionals. Meticulous recording of weight tape and goniometry measurements, videos and stationary photos, performance statistics from competition and training, and objective gait analysis equipment will help analyze response to treatments and manipulations. Goniometry, the measurement of joint angles, has been validated in horses[11–13] and is a simple and inexpensive way to measure and monitor joint range of motion. Bergh et al. demonstrated good inter- and intraobserver reliability of measurements of the range of motion of the carpus and fetlock in sound horses. Both universal and digital goniometers were precise and repeatable, but findings suggested "that the same type of goniometer should be used in subsequent measures of the same horse"[12] with the type of goniometer being recorded in the medical records along with the measurements. Reliable systemic biomarker tests are not yet currently available to screen for early stages of joint inflammation. Some intriguing work has investigated urinary excretion of glycosaminoglycans (GAGs) in athletic versus sedentary horses and those with evidence of osteoarthritis in one or more joints,[14] but assays are not commercially available, and complete understanding of the relation of urinary GAGs to cartilage metabolism requires more research.

3. Oral Supplements

In a 2018 survey of owners and trainers in Ireland, Murray et al. found that joint supplements were the most used type of oral supplement, and more respondents sought advice from feed merchants than from veterinarians.[15] Veterinary advice is too often bypassed in the selection of oral joint health supplements. Veterinarians need to be prepared to discuss relevant available data, proposed mechanisms of action, and possible contraindications with clients.

Most oral joint supplements are intended to act through one or both of two mechanisms: as building block substrates for articular cartilage (proanabolic effect) and as anti-inflammatory modulators (anticatabolic effect). Articular cartilage is composed of a dense extracellular matrix of water, type 2 collagen, and proteoglycans.[16] Glucosamine is an amino monosaccharide that is the main component of GAGs including chondroitin sulfate, keratin sulfate, and heparan sulfate. The negatively charged GAGs in turn bond to protein backbones to form proteoglycans. Aggrecan molecules, produced by chondrocytes, have the charged bottle brush structure of proteoglycan molecules (lending cartilage its resistance to compression) bonded to a hyaluronan backbone. Hyaluronan is produced by both chondrocytes and synoviocytes for incorporation into the cartilage extracellular matrix and synovial fluid, respectively. However, it is believed that its demonstrated beneficial effects on

joint health are due not to incorporation of the administered hyaluronan into cartilage and synovial fluid, but rather to anti-inflammatory effects and possibly induction of synthesis of high molecular weight hyaluronan by synoviocytes.[17]

The most common oral joint health supplements with some supporting research include glucosamine, chondroitin sulfate, hyaluronic acid (hyaluronan), unsaponified avocado soy, extract of green-lipped mussel (*Perna canaliculus*), methylsolfonylmethane, and various combinations of those ingredients. More is known about the oral bioavailability and volume of distribution of glucosamine and chondroitin sulfate than other oral joint supplements.[18,19] Most literature has focused on management of mild arthritis, and extrapolations to equine treatment are made from human and canine research. Many of the most recent publications exploring in vivo clinical efficacy of nutraceuticals use multi-ingredient formulations with varying amounts of substances, so it is difficult to draw conclusions on specific dosages and ratios (which may have synergistic or additive effects) and to compare to other studies.

Because of the possibly slow-acting nature of oral joint health supplements, it has been recommended that human osteoarthritis patients supplement for at least 3 continuous months before assessing individual effect.[1] Extrapolating the same 3-month trial period for equine patients would be reasonable if clients are to try them. However, Clayton et al. demonstrated a measurable improvement in gait symmetry in horses with degenerative joint disease of the distal tarsal joints after only 2 weeks of supplementation with a mixture including manganese, copper, sulphur, vitamin B6, ascorbic acid, glutamine, proline, glutamic acid, glycine, and glucuronic acid.[20] Many of the ingredients included are surmised to act as free-radical scavengers and anti-inflammatories.

In general, adverse effects of nutraceutical supplementation have not been reported in studies in which specific amounts of high-quality ingredients are confirmed, and beneficial effects are noted in numerous reports. However, quality control and adherence to current good manufacturing practices in commercially available formulations can be highly variable and run the risk of contamination with harmful substances.[21,22] The 7-step ACCLAIM system devised and presented by Dr. Stacey Oke at the 2008 AAEP convention[23] remains the most reliable and comprehensive assessment tool for commercially available products. It is important to enquire about testing for quality assurance (potency and purity of ingredients and batch-to-batch consistency) as well as how dosages are determined and measured. Especially with the risks of inadvertent doping violations in competitive horses, contamination of nutraceutical supplements could have jurisdictional consequences at best,[24] in addition to health risks depending on the compound. Questions have been raised in human medicine about the impact of oral glucosamine and chondroitin sulfate in people with type 2 diabetes.[25] However, as of yet, there has been no evidence in horses with insulin dysregulation and equine metabolic syndrome (and hopefully less so in upper-level athletes) to dissuade use of these supplements at levels indicated for joint health.

4. Systemic Parenteral (IV and IM) Products

Parenteral administration of some of the same compounds described as oral joint supplements bypasses the effects of digestion and gastrointestinal absorption, potentially increasing bioavailability and effective blood and tissue levels. Incorporation of these compounds into articular cartilage and effects on inflammation and cartilage metabolism in vivo still require more research. However, there are two systemic parenteral injectable medications that are Food and Drug Administration (FDA) approved for equine arthritis. This approval requires demonstration of efficacy as well as safety and oversight of ongoing good manufacturing processes. Intravenous hyaluronic acid (hyaluronan) and intramuscular polysulfated glycosaminoglycan are approved for treatment of arthritis in horses, but it should be noted that there are some solutions of chondroitin sulfate and pentosan polysulfate that are approved by the FDA as "medical devices" for topical wound care and bladder lavage but not for injection for arthritis.

Intramuscular polysulfated glycosaminoglycan has a long history of demonstrated safety and perceived effectiveness in equine arthritis prevention.[26–28] Although experimentally the plant-derived pentosan polysulfate compound was found to have desirable disease-modifying effects in treating arthritis,[29] it is difficult to justify the risk of extra-label use of a device especially for prophylaxis when a similar FDA-approved drug is available. Eighty-six percent of respondents in a recent AAEP survey of practitioners used intramuscular polysulfated glycosaminoglycan[a] "for preventive/prophylactic measures in a high-performance horse"[28] despite it not being specifically labeled for prevention. Hyaluronate sodium[b] was used more for acute disease in the updated survey[28] but is also used prophylactically by many practitioners.[27] The prophylactic use of intravenous hyaluronan is supported by a study involving 140 racing Quarter Horses. Treatment with intravenous hyaluronic acid every 2 weeks for 9 months resulted in significantly improved racing data compared to intravenous saline placebo controls.[30]

5. Regulations

Most of the modalities discussed above are considered relatively safe but still may have medical or regulatory contraindications, especially if examination and diagnosis have not been completed. For any veterinary recommendations, a current veterinary-client-patient relationship should be in effect. A gait analysis should be performed to ensure that there is no detectable lameness that could be more specifically diagnosed and treated. In a *Journal of the American*

Veterinary Medical Association news update from January 2017, it was reported that the AVMA "currently offers no guidance about supplements."[31] This reflects the frustrating paucity of efficacy data and lack of FDA oversight in the nutraceutical and supplement industries that would at least lend standardization and safety assurances to products.[31] As with any substance administered by any route to horses in competition, the current regulations of governing bodies of overseeing competitions must be referenced and adhered to. As manipulative and complementary therapies become more mainstream, state veterinary medical boards are beginning to pass more specific legislation describing what physical therapy modalities may be performed by professional staff and under the prescription of a veterinarian; licensees should reference their relevant states for guidance.

6. Conclusion

Improved monitoring and record keeping will help veterinarians become more effective at objectively evaluating response to therapies and assessing prophylactic measures. Education and open discussion with other professionals involved in the equine athlete's team are paramount in recognizing changes in motion, preventing arthritis, and extending the competitive career of equine patients. In most cases, the sooner subtle pathology can be recognized, the more successful treatment can be. Safety of adjunctive therapies should be carefully contemplated and evaluated even if more research is still needed to demonstrate efficacy in blinded controlled studies. The ACCLAIM method[23] should be employed to assess quality of oral joint health supplements. Physical manipulation and exercises should be discussed following physical examination and gait analysis by a veterinarian.

Acknowledgments

Declaration of Ethics

The Author has adhered to the Principles of Veterinary Medical Ethics of the AVMA.

Conflict of Interest

The Author has no conflicts of interest.

References and Footnotes

1. Anandacoomarasamy A, March L. Current evidence for osteoarthritis treatments. *Ther Adv Musculoskelet Dis* 2010;2:17–28.
2. Aman JE, Elangovan N, Yeh I-L, et al. The effectiveness of proprioceptive training for improving motor function: A systematic review. *Front Hum Neurosci* 2014;8:1075.
3. Stubbs NC, Clayton HM. *Activate your horse's core: Unmounted exercises for dynamic mobility, strength and balance*. Lansing: Sport Horse Publications, 2008.
4. Clayton HM. Core training and rehabilitation in horses. *Vet Clin North Am Equine Pract* 2016;32:49–71.
5. Stubbs NC, Kaiser LJ, Hauptman J, et al. Dynamic mobilization exercises increase cross sectional area of musculus multifidus. *Equine Vet J* 2011;43:522–529.
6. de Oliveira K, Soutello RVG, da Fonseca R, et al. Gymnastic training and dynamic mobilization exercises improve stride quality and epaxial muscle size in therapy horses. *J Equine Vet Sci* 2015;35:888–893.
7. Brown S, Stubbs NC, Kaiser LJ, et al. Swing phase kinematics of horses trotting over poles. *Equine Vet J* 2015;47:107–112.
8. Michlovitz SL. *Thermal agents in rehabilitation* 3rd ed. Philadelphia: F.A. Davis, 1996.
9. Goff L. Physiotherapy assessment for the equine athlete. *Vet Clin North Am Equine Pract* 2016;32:31–47.
10. White A, Foster NE, Cummings M, et al. Acupuncture treatment for chronic knee pain: A systematic review. *Rheumatology (Oxford)* 2007;46:384–390.
11. Adair HS, Marcellin-Little DJ, Levine D. Validity and repeatability of goniometry in normal horses. *Vet Comp Orthop Traumatol* 2016;29:314–319.
12. Bergh A, Lauridsen NG, Hesbach AL. Concurrent validity of equine joint range of motion measurement: A novel digital goniometer versus universal goniometer. *Animals (Basel)* 2020;10:2436.
13. Liljebrink Y, Bergh A. Goniometry: Is it a reliable tool to monitor passive joint range of motion in horses? *Equine Vet J Suppl* 2010;42:676–682.
14. Baccarin RYA, Machado TSL, Lopes-Moraes AP, et al. Urinary glycosaminoglycans in horse osteoarthritis. Effects of chondroitin sulfate and glucosamine. *Res Vet Sci* 2012;93: 88–96.
15. Murray JMD, Hanna E, Hastie P. Equine dietary supplements: An insight into their use and perception in the Irish equine industry. *Irish Vet J* 2018;71:4.
16. Fox AJS, Bedi A, Rodeo SA. The basic science of articular cartilage structure, composition, and function. *Sports Health* 2009;1:461–468.
17. Frisbie DD, Johnson SA, et al. Medical treatment of joint disease. In: Auer J, Stick J, eds. *Equine surgery* 5th ed. London: W.B. Saunders, 2019;1348–1363.
18. Eddington ND, Du J, White N. Evidence of the oral absorption of chondroitin sulfate as determined by total disaccharide content after oral and intravenous administration to horses, in Proceedings. Am Assoc Equine Pract 2001;47:326–328.
19. Laverty S, Sandy JD, Celeste T, et al. Synovial fluid levels and serum pharmacokinetics in a large animal model following treatment with oral glycosaminoglycan at clinically relevant doses. *Arthritis Rheum* 2005;52:181–191.
20. Clayton HM, Almeida PE, Prades M, et al. Double-blind study of the effects of an oral supplement intended to support joint health in horses with tarsal degenerative joint disease, in Proceedings. Am Assoc Equine Pract 2002;48:314–317.
21. Oke SL, Habashi AA, Weese JS, et al. Evaluation of glucosamine levels in commercial equine oral supplements for joints. *Equine Vet J* 2006;38:93–95.
22. Adebowale AO, Cox DS, Linang I, et al. Analysis of glucosamine and chondroitin sulfate content in marketed products and CACO-2 permeability of chondroitin sulfate raw materials. *J Am Nutraceuticals Assoc* 2000;3:37–44.
23. Oke SL, McIlwraith CW. Review of the potential indications and contraindications for equine oral joint health supplements, in Proceedings. Am Assoc Equine Pract 2008;54:261–267.
24. Edited Press Release. Supplement contamination caused positive test results. The Horse. May 9, 2017. Available at: https://thehorse.com/110267/supplement-contamination-caused-positive-test-results/.
25. Marshall PD, Poddar S, Tweed EM, et al. Clinical inquiries: Do glucosamine and chondroitin worsen blood sugar control in diabetes? *J Fam Pract* 2006;55:1091–1093.
26. Caron JP, Kaneene JB, Miller R. Results of a survey of equine practitioners on the use and perceived efficacy of polysulfated glycosaminoglycan. *J Am Vet Med Assoc* 1996; 209:1564–1568.
27. Ferris DJ, Frisbie DD, McIlwraith CW, et al. Current joint therapy usage in equine practice: A survey of veterinarians 2009. *Equine Vet J* 2011;43:530–535.

28. Zanotto GM, Frisbie DD. Current joint therapy usage in equine practice: Changes in the last 10 years. *Equine Vet J* 2021;00:1–7.
29. McIlwraith CW, Frisbie DD, Kawcak CE. Evaluation of intramuscularly administered sodium pentosan polysulfate for treatment of experimentally induced osteoarthritis in horses. *Am J Vet Res* 2012;73:628–633.
30. McIlwraith CW, Goodman NL, Frisbie DD. Prospective study on the prophylactic value of intravenous hyaluronan in 2-year-old racing Quarter Horses, *in Proceedings*. Am Assoc Equine Pract 1998;44:269–271.
31. Burns K. Assessing pet supplements: Use widespread in dogs and cats, evidence and regulation lacking. *Am J Vet Med Assoc*. January 4, 2017. Available at: https://www.avma.org/javma-news/2017-01-15/assessing-pet-supplements.

[a]Adequan, Luitpold Pharmaceuticals, Inc., Shirley, NY 11967.
[b]Legend, Merial, Ltd., Duluth, GA 30096-4640.

Metabolic Disease in the Older Horse: Focus on Prevention

Katherine E. Wilson, DVM, MS, DACVIM

Author's address: Department of Large Animal Clinical Sciences, Virginia-Maryland College of Veterinary Medicine, 215 Duck Pond Drive, Blacksburg, VA, 24061; e-mail: kewilson@vt.edu. © 2022 AAEP.

1. Introduction

Equine metabolic syndrome (EMS) is a well-recognized collection of risk factors associated with endocrinopathic laminitis in horses. While other morbidities (hyperlipemia, hyperglycemia, hypertriglyceridemia, preputial and mammary edema, lipomas, inappropriate lactation, and fertility abnormalities) can also occur subsequent to EMS, the most serious clinical consequence to most horses is the development of laminitis. The two most common components of EMS are increased adiposity and insulin dysregulation (ID). While increased adiposity may be readily identifiable on physical exam, ID may exist in the absence of obesity or regional adiposity and in older horses may occur concurrent with pituitary pars intermedia dysfunction (PPID). Understanding the pathophysiology of EMS is a dynamic and rapidly evolving field, and consensus recommendations for diagnosis, treatment, and prevention of the syndrome are frequently refined. Development of EMS is likely multifactorial, involving the interaction between a genetic predisposition and environmental and management factors. Without the ability to target one causal factor for disease, prevention of metabolic syndrome in the older horse should focus on early identification of individuals at risk of development of endocrinopathic laminitis through monitoring of body condition and diagnostic testing for ID and PPID.

2. Etiology

Genetic Risk

Increased genetic risk of EMS is implied by overrepresentation of certain breeds with the syndrome. Breeds with a higher prevalence of disease include pony breeds, Arabians, Paso Finos, Andalusians, Tennessee Walking Horses, Morgans, miniature horses, and donkeys.[1,2] Individual animals with EMS are frequently described as "easy keepers," indicating that they maintain a high body condition score or have difficulty losing weight as compared to the average horse. In both human and veterinary medicine, "thrifty" genes have been proposed to describe the enhanced feed efficiency of certain individuals who readily store energy acquired from food. This efficiency might provide a survival advantage in times of feed scarcity but has been associated with metabolic syndrome and type 2 diabetes in people and EMS in horses.[3,4]

Investigation into breed differences in metabolic function has elucidated differences in insulin sensitivity, insulin response, and serum concentrations of lipids and glucose between EMS-predisposed breeds and other horses.[5–8] Early research into the heritability of EMS in a group of related Welsh and Dartmoor ponies determined that a diagnosis of laminitis was consistent with a dominant gene or genes with reduced penetrance due to epigenetic factors such as age, body condition, or feed composition.[9] More recently, candidate genetic loci associated with risk for hyperinsuline-

NOTES

mia and increased frequency of laminitis in Arabian horses[10] and with height and metabolic traits in Welsh ponies and Morgans.[11,12] Future research may lead to genetic tests for a risk of EMS, but it is likely that other developmental, environmental, and management factors play a strong role in expression of disease.

Environmental and Management Risk Factors

Not all horses with a genetic predisposition for EMS develop the syndrome. Additionally, horses with low genetic risk can develop EMS with sufficient environmental or management risk exposure, such as a diet high in nonstructural carbohydrate (NSC) concentrations and prolonged obesity. Extrinsic risk factors are more accessible to control than genetics and thus are a more useful focus for prevention of disease.

Increased adiposity in the form of generalized obesity or regional adiposity is frequently associated with EMS. As horses with lean body condition can also develop ID and laminitis, increased adiposity is not necessary for a diagnosis of EMS but is considered a strong risk factor. As horses age, there is a shift in body mass composition with an increase in fat accumulation in adipose tissue and muscle.[13] A decrease in basal metabolic rate as part of the normal aging process, without a concurrent decrease in appetite, may predispose older horses to excess energy intake and storage as adipose tissue. Adipose tissue plays an active role in regulation of adipokines, and inflammatory mediators and increased adiposity can lead to dysregulation of these systems. Leptin is an adipokine produced by adipocytes, and its serum concentration increases with increasing body condition in horses.[14,15] Under normal conditions, leptin serves to suppress appetite and increase energy expenditure in the presence of excess energy stores. Leptin resistance appears to occur in some horse with EMS, reflected by serum leptin concentrations higher than that expected for their body condition, which might lead to increased feed intake and further weight gain.[16] Adiponectin is another fat-derived hormone that functions to enhance insulin sensitivity. In people and horses, adiponectin concentrations decrease with increased body condition and fat mass.[15,17]

Insulin dysregulation is a central feature of EMS and a consistent risk factor for development of laminitis. ID is defined as any combination of resting hyperinsulinemia, a hyperinsulinemic response to intravenous or oral glucose, and tissue insulin resistance.[4] Many studies have found that feeding diets high in NSCs result in decreased insulin sensitivity and adiponectin concentrations.[18–21] The gastrointestinal microbiota has been implicated in the development of metabolic disease and obesity in people[22] through modulation of energy metabolism, gastrointestinal permeability, regulation of gastrointestinal peptide hormone secretion, and inflammation.[23] Studies in horses have shown differences in the microbiota of horses with and without EMS or obesity.[24–26] Recent research has investigated the microbiome, metabolome, and lipidome of obese horses to set a foundation for developing diagnostic biomarkers and therapeutics for obesity and EMS in horses.[23]

Age has been shown to have an effect on insulin and adiponectin concentrations in horses. Older horses are more likely to have higher insulin concentrations and lower adiponectin concentrations than younger horses and ponies, correlating with a higher incidence of EMS and laminitis in older horses.[27–30]

3. Diagnosis

Early detection of EMS is essential for prevention of uncontrolled disease and laminitis. As understanding of the pathophysiology of EMS is rapidly evolving, recommendations for diagnosis have changed frequently in recent years. Recent consensus recommendations for diagnosis of EMS have been published and well discussed elsewhere.[2,4] Briefly, basal testing of serum insulin can be useful to identify individuals with resting hyperinsulinemia but is of low sensitivity.[2] Dynamic testing, measuring glucose and insulin response to an intravenous or oral glucose challenge, can be useful to help identify individuals with postprandial hyperinsulinemia and to evaluate tissue insulin sensitivity. The oral sugar test is practical for use in the field setting. Quantitative testing for ID of at-risk individuals is highly recommended. Detection of subclinical ID allows for treatment strategies to be initiated prior to an onset of laminitis. Regular follow-up testing using the same diagnostics will allow for early detection of ID in previously normal at-risk individuals and/or monitoring response to treatment. In older horses, diagnostic testing for PPID is also recommended, especially in lean individuals in which ID is diagnosed. Consensus recommendations for diagnosis of PPID have been published.[31]

4. Management

Once a horse has been identified as at risk of development of EMS, or has been diagnosed, management strategies should be implemented with the goal of preventing severe ID and ensuing laminitis. An individual program of dietary management, exercise, and monitoring should be tailored for each horse and owner.

Dietary Management

Nutritional strategies for management of EMS should seek to maintain a lean to average body condition score and control ID. As many at-risk or recently diagnosed horses are obese, weight loss is often a goal of dietary management. Feeds high in NSCs such as cereal grains and treats including fruits and vegetables should be minimized in the diet. A key component in the success of dietary management of EMS is owner compliance, and excellent client communication strategies are often necessary.

Multiple studies have shown that weight loss achieved through energy restriction reduces insulin dysregulation in horses with EMS.[32–35] Consensus recommendations for weight loss include feeding of 1.25%

to 1.5% of body weight in dry matter intake (DMI) or 1.4% to 1.7% as fed, in the form of good-quality grass hay.[4] Some obese horses seem to develop weight loss resistance and can be reduced to 1.0% of body weight in DMI or 1.15% body weight as fed if the previous strategy is not successful in achieving weight loss.[4,36]

Hay quality and nutrient composition can be deceiving without quantitative analysis, and ideally forage analysis should be performed. Forage with NSC content of less than 10% is recommended to reduce hyperinsulinemic response to feeding.[37] Soaking hay has also been shown to reduce the hyperinsulinemic response in horses with EMS[38,39] and doubled weight loss when compared to horses fed the same amount of hay without soaking.[40] As dry forage can be deficient in protein, vitamins, and minerals and significant leaching of minerals can occur with soaking of hay, it is recommended to concurrently feed a low-sugar forage balancer to provide appropriate nutrition.[2,40,41] Pasture access should be limited in the obese patient, especially while achieving weight loss, due to variability in NSC content in grasses and inability to limit DMI. Grazing muzzles have been shown to reduce DMI by 17% to 23% and may encourage exercise while grazing.[42]

Weight loss should be monitored closely over time with target losses of 0.5% to 1.25% of the initial body weight achieved weekly.[43] Monitoring weight loss utilizing a scale or measuring girth circumference is preferrable to assessing body condition score as internal fat stores frequently are mobilized first.[36]

Previously obese geriatric horses may develop difficulty maintaining body mass due to changing metabolism, gastrointestinal malabsorption of nutrients, and dental disease. It should not be assumed that ID resolves with a decrease in body condition in geriatric horses as regional adiposity may remain and PPID may be concurrent. High-NSC feeds should continue to be avoided, and dietary energy should be increased in the form of fat, such as vegetable oil, instead of starches.

Exercise

Routine exercise likely plays a role in prevention of development of EMS and/or severe disease due to ID. At-risk breeds often evolved in areas where forage was scarce and walking large distances to source forage was common. Older horses are often retired from work or competition and may not experience daily exercise in any form.

Exercise alone has been shown to improve insulin sensitivity in people.[44] In horses, data has been conflicting, likely due to variation in the breeds, body condition, and metabolic profile of the horses used and the duration and intensity of the exercise.[32,45–48] Consensus recommendations for nonlaminitic horses include low- to moderate-intensity exercise for at least 30 minutes, 5 or more times per week.[4]

Horses with ongoing or previous laminitis pose a challenge in attempts to increase physical activity as lamellar instability can be a life-threatening concern. Consensus recommendations for exercise for horses recovered from laminitis, with stable lamellae, include low-intensity exercise on a soft surface for at least 30 minutes, 3 or more times per week.[4] Careful monitoring of soundness and hoof stability should be a priority in these cases.

Monitoring

Dietary modification, weight loss strategies, and exercise programs should be adjusted based on quantitative measures of response to treatment, such as improvement in body condition score, weight as measured by scale or weight tape, and diagnostic testing. Documentation of these parameters by the owner and veterinarian can often help to detect changes (or lack thereof) when subjective analysis of improvement does not. ID might not resolve with weight loss in all cases, and serial diagnostic testing as compared to a baseline is often helpful in making changes in prevention recommendations.

Medications

Several pharmacologic aids are used for treatment and prevention of EMS in horses. Medication is not a substitute for weight loss and exercise management and will do little to affect ID if diet is not simultaneously controlled.

Levothyroxine sodium has been shown to reduce body weight and improve insulin sensitivity in normal and EMS horses.[49,50] Current consensus recommendations for treatment with levothyroxine support its use in cases where dietary changes with or without exercise have been unsuccessful in achieving weight loss. Levothyroxine should be administered at a dose of 0.1 mg/kg daily and then gradually tapered off after weight loss has been achieved, or after 4 to 6 months.[2] In humans, long-term administration of levothyroxine is associated with cardiac abnormalities. However, administration of up to 96 mg levothyroxine once a day for 48 weeks has been shown to be well tolerated by horses, with an absence of adverse effects.[49,51]

Sodium-glucose co-transporter 2 (SGLT2) inhibitors inhibit the reuptake of glucose by renal tubules and thus increase loss of glucose in the urine. Initial studies in ponies have shown a reduction in insulin when the SGLT2 inhibitor velagliflozin was administered.[52,53] SGLT2 inhibitors show promise but remain cost prohibitive in most circumstances.

Pioglitazone is a thiazolidinedione drug that is commonly used to improve insulin sensitivity in people with type 2 diabetes. Initial studies in horses resulted in subtherapeutic concentrations and lack of an effect on insulin dynamics when administered orally at 1 mg/kg.[54,55] However, a more recent study showed significant decreases in the insulin response to oral sugar test and increased adiponectin concentrations when administered orally at 2 mg/kg once a day for 28 days.[56]

Metformin hydrochloride is commonly used in the management of EMS in horses. Initial studies showed

variable efficacy and poor bioavailability.[57–59] However, work in other species and more recent work in horses has shown that metformin decreases glucose absorption at the level of the enterocyte, thus reducing the hyperinsulinemic response to feeding seen in EMS horses.[60] Current consensus recommendations for use of metformin in cases of EMS are 30 mg/kg orally up to 3 times per day, 30 minutes prior to feeding.[2] Its use has been recommended for cases with persistent ID despite appropriate dietary and exercise management or for the first few weeks that an at-risk horse is placed on pasture.

5. Summary

Prevention of EMS in older horses requires an understanding of the multifactorial etiologic nature of the syndrome. Prevention should start with identification of at-risk individuals based on breed and body condition score. Diagnostic testing for ID will help detect subclinical animals and is useful to determine response to treatment recommendations. Active preventative strategies should be aimed at prevention of severe disease and development of laminitis and include dietary modification, management of body condition, and exercise.

Acknowledgments

Declaration of Ethics

The Author has adhered to the Principles of Veterinary Medical Ethics of the AVMA.

Conflict of Interest

The Author has no conflicts of interest.

References

1. Norton EM, Avila F, Schultz NE, et al. Evaluation of an HMGA2 variant for pleiotropic effects on height and metabolic traits in ponies. *J Vet Intern Med* 2019;33:942–952.
2. Frank N, Bailey S, Bertin FR, et al. Recommendations for the diagnosis and treatment of equine metabolic syndrome (EMS). Equine Endocrinology Group. 2020. Available from: https://sites.tufts.edu/equineendogroup/files/2020/09/200592_EMS_Recommendations_Bro-FINAL.pdf.
3. Neel JV. Diabetes mellitus: a "thrifty" genotype rendered detrimental by "progress"? *Am J Hum Genet* 1962;14:353–362.
4. Durham AE, Frank N, McGowan CM, et al. ECEIM consensus statement on equine metabolic syndrome. *J Vet Intern Med* 2019;33:335–349.
5. Jeffcott LB, Field JR. Current concepts of hyperlipaemia in horses and ponies. *Vet Rec* 1985;116:461–466.
6. Jeffcott LB, Field JR, McLean JG, et al. Glucose tolerance and insulin sensitivity in ponies and Standardbred horses. *Equine Vet J* 1986;18:97–101.
7. Robie SM, Janson CH, Smith SC, et al. Equine serum lipids: Serum lipids and glucose in Morgan and Thoroughbred horses and Shetland ponies. *Am J Vet Res* 1975;36:1705–1708.
8. Bamford NJ, Potter SJ, Harris PA, et al. Breed differences in insulin sensitivity and insulinemic responses to oral glucose in horses and ponies of moderate body condition score. *Domest Anim Endocrinol* 2014;47:101–107.
9. Treiber KH, Kronfeld DS, Hess TM, et al. Evaluation of genetic and metabolic predispositions and nutritional risk factors for pasture-associated laminitis in ponies. *J Am Vet Med Assoc* 2006;228:1538–1545.
10. Lewis SL, Holl HM, Streeter C, et al. Genomewide association study reveals a risk locus for equine metabolic syndrome in the Arabian horse. *J Anim Sci* 2017;95:1071–1079.
11. Norton E, Schultz N, Geor R, et al. Genome-wide association analyses of equine metabolic syndrome phenotypes in Welsh ponies and Morgan horses. *Genes* 2019;10:893.
12. Norton E, McCue ME. Genetics of equine endocrine and metabolic disease. *Vet Clin North Am Equine Pract* 2020;36:341–352.
13. Lehnhard RA, McKeever KH, Kearns CF, et al. Myosin heavy chain profiles and body composition are different in old versus young Standardbred mares. *Vet J* 2004;167:59–66.
14. Buff PR, Dodds AC, Morrison CD, et al. Leptin in horses: Tissue localization and relationship between peripheral concentrations of leptin and body condition. *J Anim Sci* 2002;80:2942–2948.
15. Kearns CF, McKeever KH, Roegner V, et al. Adiponectin and leptin are related to fat mass in horses. *Vet J* 2006;172:460–465.
16. Van Weyenberg S, Buyse J, Kalmar ID, et al. Voluntary feed intake and leptin sensitivity in ad libitum fed obese ponies following a period of restricted feeding: A pilot study. *J Anim Physiol Anim Nutr (Berl)* 2013;97:624–631.
17. Ukkola O, Santaniemi M. Adiponectin: A link between excess adiposity and associated comorbidities? *J Mol Med (Berl)* 2002;80:696–702.
18. Hoffman RM, Boston RC, Stefanovski D, et al. Obesity and diet affect glucose dynamics and insulin sensitivity in Thoroughbred geldings. *J Anim Sci* 2003;81:2333–2342.
19. Treiber KH, Boston RC, Kronfeld DS, et al. Insulin resistance and compensation in Thoroughbred weanlings adapted to high-glycemic meals. *J Anim Sci* 2005;83:2357–2364.
20. Quinn RW, Burk AO, Hartsock TG, et al. Insulin sensitivity in Thoroughbred geldings: Effect of weight gain, diet, and exercise on insulin sensitivity in Thoroughbred geldings. *J Equine Vet Sci* 2008;28:728–738.
21. Bamford NJ, Potter SJ, Baskerville CL, et al. Effect of increased adiposity on insulin sensitivity and adipokine concentrations in different equine breeds adapted to cereal-rich or fat-rich meals. *Vet* 2016;214:14–20.
22. Kovatcheva-Datchary P, Arora T. Nutrition, the gut microbiome, and the metabolic syndrome. *Best Pract Res Clin Gastroenterol* 2013;27:59–72.
23. Coleman MC, Whitfield-Cargile CM, Madrigal RG, et al. Comparison of the microbiome, metabolome, and lipidome of obese and non-obese horses. *PloS One* 2019;14:e0215918.
24. Elzinga SE, Weese JS, Adams AA. Comparison of the fecal microbiota in horses with equine metabolic syndrome and metabolically normal controls fed a similar all-forage diet. *J Equine Vet Sci* 2016;44:9–16.
25. Morrison PK, Newbold CJ, Jones E, et al. The equine gastrointestinal microbiome: Impacts of age and obesity. *Front Microbiol* 2018;9:3017.
26. Biddle AS, Tomb JF, Fan Z. Microbiome and blood analyte differences point to community and metabolic signatures in lean and obese horses. *Front Vet Sci* 2018;5:225.
27. Morgan RA, McGowan TW, McGowan CM. Prevalence and risk factors for hyperinsulinaemia in ponies in Queensland, Australia. *Aust Vet J* 2014;92:101–106.
28. Hart KA, Wochele DM, Norton NA, et al. Effect of age, season, body condition, and endocrine status on serum free cortisol fraction and insulin concentration in horses. *J Vet Intern Med* 2016;30:653–663.
29. Nielsen BD, O'Connor-Robison CI, Spooner HS, et al. Glycemic and insulinemic responses are affected by age of horse and method of feed processing. *J Equine Vet Sci* 2010;30:249–258.
30. Rapson JL, Schott HC, Nielsen BD, et al. Effects of age and diet on glucose and insulin dynamics in the horse. *Equine Vet J* 2018;50:690–696.
31. Hart K, Durham A, Frank N, et al. Recommendations for the diagnosis and treatment of pituitary pars intermedia dysfunction (PPID). Equine Endocrinology Group. 2021. Available from:

https://sites.tufts.edu/equineendogroup/files/2021/12/2021-PPID-Recommendations-V11-wo-insert.pdf.
32. Freestone JF, Beadle R, Shoemaker K, et al. Improved insulin sensitivity in hyperinsulinaemic ponies through physical conditioning and controlled feed intake. *Equine Vet J* 1992;24:187–190.
33. Van Weyenberg S, Hesta M, Buyse J, et al. The effect of weight loss by energy restriction on metabolic profile and glucose tolerance in ponies. *J Anim Physiol Anim Nutr (Berl)* 2008;92:538–545.
34. Dugdale AHA, Curtis GC, Cripps P, et al. Effect of dietary restriction on body condition, composition and welfare of overweight and obese pony mares. *Equine Vet J* 2010;42:600–610.
35. Ungru J, Coenen M, Vervuert I, et al. Effects of body weight reduction on blood adipokines and subcutaneous adipose tissue adipokine mRNA expression profiles in obese ponies. *Vet Rec* 2012;171:528–528.
36. Argo CM, Curtis GC, Grove-White D, et al. Weight loss resistance: A further consideration for the nutritional management of obese Equidae. *Vet J* 2012;194:179–188.
37. Borgia L, Valberg S, McCue M, et al. Glycaemic and insulinaemic responses to feeding hay with different non-structural carbohydrate content in control and polysaccharide storage myopathy-affected horses. *J Anim Physiol Anim Nutr (Berl)* 2011;95:798–807.
38. Carslake HB, Argo CM, Pinchbeck GL, et al. Insulinaemic and glycaemic responses to three forages in ponies. *Vet J* 2018;235:83–89.
39. Müller CE, Nostell K, Bröjer J. Methods for reduction of water-soluble carbohydrate content in grass forages for horses. *Livest Sci* 2016;186:46–52.
40. Argo CM, Dugdale AH, McGowan CM. Considerations for the use of restricted, soaked grass hay diets to promote weight loss in the management of equine metabolic syndrome and obesity. *Vet J* 2015;206:170–177.
41. Mack SJ, Dugdale AH, Argo CM, et al. Impact of water-soaking on the nutrient composition of UK hays. *Vet Rec* 2014;174:452.
42. Longland AC, Barfoot C, Harris PA. The effect of wearing a grazing muzzle vs. not wearing a grazing muzzle on intakes of spring, summer, and autumn pastures by ponies. In: Saastamoinen M, Fradinho MJ, Santos AS, Miraglia N, eds. *Forages and grazing in horse nutrition*. Wageningen: Wageningen Academic Publishers, 2012;185–186.
43. Argo CM. Nutritional management of the older horse. *Vet Clin North Am Equine Pract* 2016;32:343–354.
44. Bird SR, Hawley JA. Update on the effects of physical activity on insulin sensitivity in humans. *BMJ Open Sport Exerc Med* 2016;2:e000143.
45. Powell DM, Reedy SE, Sessions DR, et al. Effect of short-term exercise training on insulin sensitivity in obese and lean mares. *Equine Vet J* 2010;34:81–84.
46. Stewart-Hunt L, Geor RJ, McCutcheon LJ. Effects of short-term training on insulin sensitivity and skeletal muscle glucose metabolism in Standardbred horses. *Equine Vet J* 2006;38:226–232.
47. Carter RA, McCutcheon LJ, Valle E, et al. Effects of exercise training on adiposity, insulin sensitivity, and plasma hormone and lipid concentrations in overweight or obese, insulin-resistant horses. *Am J Vet Res* 2010;71:314–321.
48. Bonelli F, Sgorbini M, Meucci V, et al. How swimming affects plasma insulin and glucose concentration in Thoroughbreds: A pilot study. *Vet* 2017;226:1–3.
49. Frank N, Sommardahl CS, Eiler H, et al. Effects of oral administration of levothyroxine sodium on concentrations of plasma lipids, concentration and composition of very-low-density lipoproteins, and glucose dynamics in healthy adult mares. *Am J Vet Res* 2005;66:1032–1038.
50. Chameroy K, Frank N, Elliot S. Effects of levothyroxine sodium on body condition, blood measures of metabolic status, and glucose dynamics in horses with equine metabolic syndrome. *J Vet Intern Med* 2010;24:780.
51. Frank N, Buchanan BR, Elliott SB. Effects of long-term oral administration of levothyroxine sodium on serum thyroid hormone concentrations, clinicopathologic variables, and echocardiographic measurements in healthy adult horses. *Am J Vet Res* 2008;69:68–75.
52. Meier A, Reiche D, de Laat M, et al. The sodium-glucose cotransporter 2 inhibitor velagliflozin reduces hyperinsulinemia and prevents laminitis in insulin-dysregulated ponies. *PLoS One* 2018;13:e0203655.
53. Meier A, de Laat M, Reiche D, et al. The efficacy and safety of velagliflozin over 16 weeks as a treatment for insulin dysregulation in ponies. *BMC Vet Res* 2019;15:65.
54. Wearn JM, Crisman MV, Davis JL, et al. Pharmacokinetics of pioglitazone after multiple oral dose administration in horses. *J Vet Pharmacol Ther* 2011;34:252–258.
55. Suagee JK, Corl BA, Wearn JG, et al. Effects of the insulin-sensitizing drug pioglitazone and lipopolysaccharide administration on insulin sensitivity in horses. *J Vet Intern Med* 2011;25:356–364.
56. Legere RM, Taylor DR, Davis JL, et al. Pharmacodynamic effects of pioglitazone on high molecular weight adiponectin concentrations and insulin response after oral sugar in equids. *J Equine Vet Sci* 2019;82:102797.
57. Durham AE, Rendle DI, Newton JR. The effect of metformin on measurements of insulin sensitivity and β cell response in 18 horses and ponies with insulin resistance. *Equine Vet J* 2008;40:493–500.
58. Hustace JL, Firshman AM, Mata JE. Pharmacokinetics and bioavailability of metformin in horses. *Am J Vet Res* 2009;70:665–668.
59. Tinworth KD, Boston RC, Harris PA, et al. The effect of oral metformin on insulin sensitivity in insulin-resistant ponies. *Vet J* 2012;191:79–84.
60. Rendle DI, Rutledge F, Hughes KJ, et al. Effects of metformin hydrochloride on blood glucose and insulin responses to oral dextrose in horses. *Equine Vet J* 2013;45:751–754.

Preventive Medicine Strategies for Equine Asthma: Current Evidence and Future Directions

M. Katie Sheats, DVM, PhD, DACVIM (LA)

Author's address: North Carolina State University College of Veterinary Medicine, Raleigh, NC 27607; e-mail: mkpeed@ncsu.edu. © 2022 AAEP.

1. What is Equine Asthma?

Equine asthma (EA) is a significant health and welfare concern for equids, whether they are top performance athletes or backyard pleasure animals. Asthma is an umbrella term for a syndrome of noninfectious, lower airway inflammation that can occur in horses of all breeds and performance disciplines. Mild/moderate EA (mEA), formerly known as inflammatory airway disease, reportedly affects 60% to 100% of some equine populations, including young racehorses.[1] Severe EA (sEA) or heaves, formerly known as recurrent airway obstruction or chronic obstructive pulmonary disease, reportedly affects 10% to 20% of adult horses in the northern hemisphere.[2–4] Mild/moderate EA has been associated with impaired gas exchange and decreased performance in racehorses,[1,5,6] and sEA is a chronic inflammatory disease that causes progressive decline in lung function, compromising quality of life and sometimes requiring humane euthanasia. Both mEA and sEA are characterized clinically by recurrent, variable cough and impaired performance, with sEA horses showing signs of increased respiratory effort even at rest.[2–4] These clinical signs are due to bronchoconstriction, mucus hypersecretion, and airway inflammation as a result of exposure to various environmental triggers present in stables, hay, and dust, with a subset of cases associated with summer pasture exposure.[2–4,7–12] In horses with hay/barn dust and pasture-associated sEA, neutrophils are the predominant inflammatory cell in the lower airway based on bronchoalveolar lavage (BAL) cytology. By contrast, BAL cytology from horses with mEA can identify several inflammatory phenotypes including neutrophilic, mastocytic, eosinophilic, or mixed.[13]

Increased inflammatory cells in the lower airways of horses with sEA and mEA are associated with impaired lung function. In racehorses with mEA, the presence of increased airway mast cells or neutrophils has been shown to negatively impact racing performance. Specifically, a study by Ivester showed that speed figures of Thoroughbred racehorses were reduced by 2.9 and 1.4 points for each percent increase in BAL fluid mast cell or neutrophil proportions, respectively.[1] More recently, Stucchi showed a "significant relationship between the increase in the differential count of neutrophils in bronchoalveolar lavage and the decrease in the speed at 4 mmol/L of lactate" in Standardbred racehorses.[14] While this evidence suggests that these inflammatory cells play a role in decreasing respiratory performance, the cellular mechanisms and immunopathology are not completely understood. In horses with sEA, increasing neutrophil percentages on BAL cytology are highly correlated with asthma severity and decreased lung function.[15] This decline in lung function is a significant welfare concern as these horses experience decreased quality of life and additional health

NOTES

consequences such as pulmonary hypertension[16,17] and can end up surrendered or euthanized by owners who do not have the ability or finances to manage this chronic disease. Given the significant impacts EA has on issues ranging from optimal equine performance to welfare, it is essential that veterinarians and equine health researchers work to develop a better understanding of the underlying mechanisms of disease, as well as identify improved methods for early recognition, diagnosis, treatment, and prevention.

It is well established that in horses with EA, alveolar macrophages and airway neutrophils are activated by airborne organic dust in the breathing zone.[2,18,19] What is less well known is that healthy horses also experience significant airway neutrophilia in response to organic dust exposure.[10,20] Organic dust consists of a mixture of many potential antigens, including particulate matter, endotoxins or lipopolysaccharide, peptidoglycans, noxious gases, and β-D-glucans.[2,18] Following exposure to organic dust, alveolar macrophages become activated and release proinflammatory mediators including tumor necrosis factor-α, interleukin-6, interleukin-8 (IL-8), chemokine ligand-1, and chemokine ligand-2, as well as reactive oxygen species.[21–25] In response to these signals, large numbers of neutrophils are recruited to the airways. Airway neutrophils then release proinflammatory mediators including interleukin-1β, tumor necrosis factor-α, IL-8, interleukin-17, reactive oxygen species, and neutrophil extracellular traps.[19,26–29] Similar immunopathology has been identified as causing organic-dust-induced asthma in human agricultural workers.[2,26] Ongoing research seeks to understand why this cycle of inflammation, which happens in both healthy and asthmatic horses, becomes dysregulated, chronic, and debilitating in horses with sEA. Until more answers are available, strategies of preventive medicine including routine annual exams with comprehensive evaluation of the respiratory system using previously validated scoring systems (discussed below), increased owner education, and mitigation strategies for organic-dust exposure could help improve the lower airway health of all horses.

2. Diagnosing Equine Asthma

Depending on the clinical case presentation and setting (field vs. research), veterinarians can use a combination of history, physical exam, rebreathing exam, screening survey,[30] clinical respiratory scores,[31,32] BAL,[12] airway endoscopy and mucus score,[12,33,34] ultrasound,[33, 35] and lung function testing[13,36–38] to diagnose EA. These diagnostics have been reviewed recently.[13]

While cough and poor performance are common history findings for horses with both mEA and sEA, their physical exam findings will differ. Horses with mEA have no respiratory abnormalities evident on resting exam, whereas horses with sEA in exacerbation or crisis will have readily identifiable abnormalities at rest ranging from elevated respiratory rate and increased nostril flare to increased abdominal effort, anal pumping, and abnormalities on thoracic auscultation including crackles and/or wheezes and tracheal rattle due to increased tracheal mucus. One exception to these typical physical exam findings for horses with sEA is horses that have achieved subclinical status, often referred to as "remission." With optimal environmental management practices that reduce exposure to organic dust, horses with sEA can achieve near-normal to normal lung function and dramatically reduce or even eliminate neutrophilic lower airway inflammation.[36,39,40] A rebreathing maneuver is a useful diagnostic tool in horses with a history of cough or decreased performance but no respiratory abnormalities on resting exam. A small bag (i.e., 4- to 8-gallon trash bag) placed over the horse's nose and mouth is used to induce hyperventilation. The increased respiratory rate and effort create increased air movement and turbulence in the lower airway, which leads to increased sound and an increased ability to detect abnormalities such as crackles or wheezes. The maneuver is commonly performed for 90 seconds to 3 minutes. A healthy horse should easily tolerate the exam, should not cough, and should return to baseline breathing rate and effort within 5 to 8 breaths once the bag is removed. Some horses with mEA will have wheezes or coughs during the maneuver or prolonged recovery following removal of the bag.[41,42]

The Horse Owner Assessed Respiratory Signs Index is a client survey that has been validated and used as a diagnostic aid in multiple studies.[43–47] It is a standardized questionnaire that has been shown to predict sEA based on the frequency of cough, the presence of nasal discharge after exercise, the presence of abnormal respiration, and an evaluation of the performance of the horse by the owner. A score of 1 means that horses are without clinical signs of respiratory disease, a score of 2 or 3 indicates mild or moderate signs, and a score of 4 indicates severe signs of respiratory disease, compatible with severe asthma.[43]

There are several standardized respiratory score rubrics that have been used for research investigations of equine asthma including a 21-[40] or 23-point scoring system,[32,48] the Improved Clinically Detectable Equine Asthma Scoring System (IDEASS) score,[31,49] the short score,[40] and a visual analog scale score.[40] From a research perspective, standardized respiratory score rubrics provide a readily available and inexpensive method to define clinical groups and compare one study population to another using a method that generates quantitative data. From a clinical perspective, potential advantages of using a standardized scoring system are that it promotes a systematic and thorough exam and, if sensitive enough, provides a tool to monitor changes in chronic disease status over time. This is particularly useful when trying to obtain objective data to gauge a patient's response to season, management changes, or therapeutics. To that end, Calzetta et al. conducted a pairwise and network meta-analysis in order to identify

a "quantitative clinical score suitable to assess the minimal important difference (MID), expressed as the minimally clinically detectable difference (MCDD)." Their results showed that a 1-point change in IDEASS represented the MCDD in equine asthma and corresponded to a 30% improvement in clinical condition.[31] It was recently proposed that the 23-point scoring system, which is currently the most useful for discriminating mild from severe EA, be a part of a minimum database for diagnosis of EA.[13] This scoring system is best described in a study by Lavoie et al., which showed that a score ≥15/23 identified horses with severe obstruction (lung resistance >2.5 cm H2O/L/s) with 70% sensitivity and 62% specificity and a score ≥11/23 identified horses with moderate-to-severe obstruction (lung resistance 1.8–2.5 H2O/L/s) with 82% sensitivity and 70% specificity. Further, the 23-point weighted clinical score was a good predictor of pulmonary function as measured by lung resistance.[32] Finally, although a 23-point scoring system may sound intimidating in terms of time, it is quite straightforward in that it addresses common aspects of a respiratory exam (respiratory rate, nasal discharge, abdominal lift, nasal flaring, tracheal sounds, bronchial tones, crackles, wheezes, cough) and assigns an increasing numerical value with increasing abnormality/evidence of dysfunction. A limitation of this score, however, is that it is unlikely to distinguish normal horses from those with subclinical disease.[13]

BAL has been identified as the most readily available and sensitive method for diagnosing EA.[12] While the procedure has been described in detail elsewhere,[50] it is worth mentioning here that the diagnostic utility of BAL cytology is impacted by the technique used both to obtain and analyze the sample. Although accepted standards for BAL have not yet been established, experts routinely recommend using a minimum of 250 mL of sterile saline, attempting to recover 40% of lavage sample volume, pooling multiple aliquots, and keeping cells on ice for no more than 72 hours or placing them in an ethylenediaminetetraacetic acid vacutainer and counting a minimum of 400 cells when performing differentials.[13,50] The differential cell count reference values for normal BAL cytology from published studies using a 250-mL lavage volume are ≤5% neutrophils, ≤2% metachromatic cells, and ≤1% eosinophils.[12] Elevated metachromatic cells >2%, eosinophils >1%, or neutrophils from 5% to 25% are consistent with mEA. Neutrophil percentage ≥20% to 25% is consistent with sEA.

Mucus hypersecretion is a key feature of EA. The 2016 American College of Veterinary Internal Medicine Consensus Statement on Inflammatory Airway Disease, now referred to as mEA, states that mucus grade 2/5 in racehorses or 3/5 for sport/pleasure horses on tracheobronchial endoscopy is sufficient to diagnose mEA.[12] These proposed criteria are further supported in a study by Rossi et al., which found that tracheal mucus was strongly correlated with lower airway inflammation on BAL cytology.[34] In additional to assigning a mucus score, endoscopy is also useful for assessment of the upper airway in horses presenting for decreased performance.

Imaging studies, including thoracic radiographs and ultrasound, are not currently considered part of a minimum database for EA diagnosis[13] as radiographs and ultrasound of horses with mEA or sEA show very little change compared to healthy horses. However, because ultrasound is a readily available diagnostic for ambulatory practitioners, two recent studies have looked more closely at ultrasound findings in horses with EA.[33,35] A study by Siwinska et al. scored the comet tail artifacts in the right and left lungs and found statistically significant differences between the overall scores in the healthy and sEA groups and between the mEA and sEA groups. No significant differences were detected between heathy and mEA horses. Although there were significant differences, Siwinska et al. concluded that due to its low specificity, ultrasound cannot replace other more sensitive methods (i.e., BAL) for diagnosis of EA.[35] Lo Feudo et al. conducted a retrospective study of 303 horses diagnosed with sEA, mEA, or mEA with exercise-induced pulmonary hemorrhage. This group found that ultrasonographic scores were higher in the sEA and mEA with exercise-induced pulmonary hemorrhage groups and were positively associated with increased BAL neutrophils and hemosiderophages, concluding that thoracic ultrasonography can provide useful information about inflammation in the lower airway.[33]

Lung function testing by spirometry or other methods is the gold standard for diagnosing asthma in human medicine.[51] In a research setting, conventional pulmonary function testing with an esophageal balloon and pneumotachometer can be used to calculate pulmonary resistance, elastance, and dynamic compliance. This method is effective for documenting impaired pulmonary function in horses with sEA and is commonly used to investigate individual horse response to interventions in research studies. However, this method is not sensitive enough to detect altered pulmonary function in most horses with mEA unless it is combined with histamine bronchoprovocation,[52] and even then limitations of this technique to differentiate normal and mEA horses have been demonstrated.[53] Further confusing the issue are conflicting results among studies that show a strong correlation between positive response to histamine bronchoprovocation and BAL cytology[52,54,55] and studies that failed to demonstrate correlation between these diagnostic methods.[56,57] In horses with exacerbation of sEA, bronchodilation (N-butylscopolammonium bromide[a], albuterol, or ipratropium bromide), rather than bronchoprovocation, can be combined with conventional pulmonary function testing to demonstrate bronchoreversibility.[13] Recent evidence has shown a good correlation between the 23-point clinical score and pulmonary resistance.[32] It remains to be determined whether the 23-point scoring system combined with bronchodilation in the field will be sufficient to detect change in pulmonary function. Significant research efforts are currently directed toward development

of sensitive, reliable, and economical methods for pulmonary function testing in the field setting.[13]

3. Treating Equine Asthma

Treatments for EA aim to reduce lower airway inflammation, reverse bronchoconstriction, modulate the immune response, and, most importantly, minimize a horse's exposure to airborne, respirable triggers (more on this below). The cornerstones of pharmacological treatment include corticosteroids (systemic or inhaled) and bronchodilators (systemic or inhaled).[3,12] There have also been investigations into the use of mast cell stabilizing agents, mucolytics, and low-dose interferon alpha. These treatments have been reviewed recently but are not in widespread use.[58,59]

Environmental management for horses diagnosed with mEA or sEA aims to reduce horse exposure to respirable airborne triggers, which are particles less than 4 to 5 μm in diameter that can penetrate deep into the lung and have been linked with induction of lower airway inflammation in both people and horses.[60] Because these respirable particles, such as endotoxin and mold spores, can also cause lower airway inflammation in healthy horses,[10,20] and there is currently no way to predict which horses will go on to develop sEA as they age, it would be prudent to recommend horse owners implement preventive strategies aimed at decreasing organic-dust levels in equine environments in general. Further, there is evidence that even subclinical levels (i.e., no evidence of respiratory dysfunction on resting physical exam) of lower airway inflammation can significantly impact performance in top equine athletes.[1] For these reasons, there is now significant interest in organic-dust management strategies for optimizing equine respiratory health.

4. Preventive Medicine Strategies to Address Organic-Dust-Induced Lower Airway Inflammation in Asthmatic and Healthy Horses

As previously stated, EA is a highly prevalent syndrome that affects horses of all ages, breeds, and uses at a global level. Therefore, one of the most important preventive medicine approaches for dealing with this disease should be increased awareness among veterinarians. Client education and careful consideration of the respiratory system during all wellness exams are critical aspects of management and prevention. As a screening tool, the Horse Owner Assessed Respiratory Signs Index scoring system has been validated as a diagnostic aid in multiple studies (as previously stated) and has even demonstrated value as a prognostic aid, showing increased risk for development of sEA in horses with mucous nasal discharge and/or occasional cough monitored over a 3-year period.[30] Because clients are the ones who complete this survey score, it could be used to promote client education and awareness of the potential significance of respiratory signs such as intermittent nasal discharge and occasional cough. The adapted 23-point scoring system and the adapted IDEASS scoring system are also useful, previously published rubrics that can provide practitioners with a standardized approach to their respiratory examinations (see previous).[31,61]

Another important preventive strategy for optimizing equine respiratory health is decreasing exposure to dust. There are 3 main methods of decreasing the airborne dust concentration in a building: (1) decreasing contaminant release by modifying the source materials (i.e., bedding, feed), (2) decreasing the rate of particle release by decreasing the degree of agitation of the source materials (do not feed hay from racks or hay nets, wetting hay), and (3) increasing the particle clearance rates by increased ventilation.[62] Common sources of respirable dust for horses include forage, bedding, performance substrate, geography, and pollution (i.e., industrial, smoke), with adequacy of ventilation playing a significant role in levels of exposure. Almost all horses, except those with pasture associated sEA, would have improved respiratory health if they could live outside year-round and consume grass or complete feeds, rather than hay.[63] However, the reality of management, geography, climate, finances, land limitations, performance use, etc. makes this an unrealistic preventive strategy for many horses. Therefore, a comprehensive approach to decreasing organic dust exposure in forage, bedding, housing, and management will require an individualized approach for each patient.

Strategies to decrease forage-associated organic-dust exposure include thoroughly and properly soaking hay (remembering to consider impacts on non-structural carbohydrate if soaking >30 minutes);[64] feeding hay from the ground (ideally on a rubber mat) to decrease dust and promote optimal mucociliary clearance, rather than a hay net, which increases respirable dust 4-fold compared to feeding from the ground);[65] feeding alternative forms of forage such as haylage,[66] chopped dry forage, alfalfa, silage, or completely cubed diets; or replacing hay altogether with a complete pelleted feed.[40,67,68] Steaming is another strategy that has been shown by multiple investigators to decrease the respirable dust in hay,[20,64,69] which seems to suggest it would benefit horses with EA. However, one study by Orard et al. suggests that hay steaming may not provide clinical benefit to horses with EA. Orard et al.'s study showed that although hay steaming significantly decreased the mold content in hay, it still induced an increase in BAL neutrophils and inflammatory cytokines in a manner similar to dry hay in horses with sEA.[70] The authors of this study concluded that the relevance of hay steaming "as a non-medicinal therapy for sEA-affected horses" might be controversial.[70]

Because of differences in study design and outcome measures, there are various levels of evidence for the impact of bedding types on dust-induced lower airway inflammation in horses with and without EA.[71] For straw bedding, there is clear evidence of its association with increased levels of airborne respirable dust in stable environments,[69] as well as increased clinical signs of respiratory disease in horses; therefore,

compared to straw, wood shavings are a preferred alternative.[69] However, two different studies from the same research group have shown that wood shavings were associated with significantly higher airway neutrophilia in healthy horses compared to peat shavings,[72] and baled peat was associated with lower airway neutrophil percentages compared to straw pellet or loosely stored peat.[73] Other low-dust bedding options include shredded paper or cardboard or a rubber mat.[74] The potential benefit of choosing low-dust bedding and feed options cannot be overstated as one study by Woods et al. showed that compared to wood shavings and pelleted feed, management systems utilizing straw bedding and hay generate 30 times more respirable dust in the horse breathing zone.[62]

Housing and management play significant roles in organic dust exposure for horses and in clinical signs of EA.[64] General recommendations include housing with good ventilation (at least 2 openings for fresh ventilation), grooming the horse outside, not storing dry hay above horse stalls, decreasing barn clutter that accumulates dust, turning horses out while stalls are cleaned and barn aisles are swept and waiting at least 60 minutes before bringing them back in, using low-dust bedding such as wood shavings, not using straw for bedding, not feeding dry hay, not using leaf blowers to clean barn aisles, and opting for pasture as much as possible (ideally 12 hours or more each day) as breathing zone levels of respirable particulate and endotoxin are significantly less at pasture compared to stabling in a low-dust environment.[63,64] While pasture turnout is optimal for avoiding triggers for horses with barn or hay-dust asthma, horses with severe equine pasture asthma (EPA) experience exacerbation of asthma when grazing during the summer.[75] High heat and humidity are additional environmental factors that contribute to triggering exacerbation of EPA.[13,76] Indeed, asthma exacerbation due to high heat and humidity has also been demonstrated in horses with previously diagnosed sEA, indicating that sEA and EPA are not mutually exclusive. A retrospective study by Bullone et al. showed significant positive correlations between higher daily heat and humidity, increased respiratory clinical score (worse symptoms), and decreased pulmonary function.[76] Clinical signs of asthma improve with hours to days of removing affected horses from pasture into a stall environment,[13] which strongly implicates pasture-associated particles as the inciting allergens. A study by Costa et al. identified increased grass pollens and fungal spores as being temporally associated with EPA exacerbations.[11] High humidity is known to shatter pollen that is otherwise too large to reach the lower airway (>10 μm) into respirable particles ($\leq$5 μm).[77] Increased dew point temperature is also known to increase release of *Nigrospora* conidia and basidiospores.[78] Fungal particles have also been identified as triggers for mEA and sEA.[13]

5. Future Directions for Decreasing Organic-Dust-Induced Lower Airway Inflammation in Horses

While the current data are limited, immunomodulatory therapy is one possible strategy for preventing or minimizing deleterious environmental impacts on equine respiratory health. A study by Nogradi et al. demonstrated that mEA and sEA horses fed a polyunsaturated fatty acid supplement containing 1.5 to 3 g docosahexaenoic acid for 2 months showed significantly greater improvement in clinical score and airway neutrophilia compared to horses receiving a low-dust diet alone and placebo.[40] Future research could determine whether docosahexaenoic acid supplementation also mitigates lower airway inflammation and/or respiratory cell "responsiveness" in horses without clinical signs of EA. There have also been several studies on the effects of inhaled nanoparticle-bound cytosine-phosphate-guanosine immunotherapy in horses with asthma.[79–81] The current hypothesis is that these particles interact with lower airway immune cells through toll-like receptors to activate regulatory T cells and restore balance to the Th1/Th2 response. There is also evidence of an anti-inflammatory effect of this treatment, with a decrease in BAL supernatant interleukin-4, IL-8, and interferon-γ in treated horses.[80] Future research could evaluate whether this therapy might also work as a prophylactic for horses entering intensive training, such as young racehorses, as training has been associated with changes in respiratory immune function and increased airway neutrophilia.[82]

While the evidence for "allergy testing" and allergen-specific immunotherapy (AIT) for treating extrinsic atopic asthma in people is compelling, the evidence for AIT for treating EA is conflicting. In the majority of humans with asthma, the airways become sensitized to one or more environmental allergens such as pollen from trees, grass, or weeds (seasonal allergens), animal dander, excretions of house dust mites, molds (perennial allergens), insect stings, drugs, or food. Sensitization occurs through increased activation of allergen-specific T lymphocytes that switch to Th2 cells and secrete mediators that cause B lymphocytes to switch immunoglobulin isotype production toward immunoglobulin E (IgE).[51] Upon subsequent exposure to offended allergens, IgE gets cross-linked and induces immediate release of inflammatory mediators including histamine, leukotriene, and cytokines that cause bronchial constriction and mucus secretion. This immediate Type I hypersensitivity reaction happens within minutes of allergen exposure. Due to recruitment of granulocytes such as eosinophils, basophils, and T lymphocytes, this immediate reaction can be followed by a delayed Type IV hypersensitivity reaction about 8 hours after the initial reaction.[51]

Allergen-specific immunotherapy aims to induce clinical and immunologic tolerance to the offending allergen through administration of select antigen preparations subcutaneously or sublingually over

3 to 5 years. Allergen-specific IgE screening is commercially available for both humans and horses (Allercept® screening test). In people with atopic asthma, the role of Type I hypersensitivity, IgE, and histamine in the immunopathology of disease is clear, which is why antihistamines and AIT therapy for these patients is effective. In horses with EA, the role of IgE and histamine is less clear. For one, horses with EA exhibit only a delayed (possibly Type III or IV) hypersensitivity response, rather than both immediate and delayed responses as in atopic asthma in humans.[83] Additionally, while some studies have found increased levels of IgE in serum or BAL fluid from horses with EA,[84–86] other studies have not been able to demonstrate a difference in IgE levels between control horses and horses with EA.[47,87] Similar inconclusive results have been reported for the use of allergy tests to correctly identify horses with EA.[83] In a recent study by Hansen et al., investigators measured antigen-specific IgE in serum and BAL fluid from 64 horses with a history of lower airway problems diagnosed with mastocytic mEA, neutrophilic mEA, mixed-cell mEA, and sEA. Their results show that allergen-specific IgE in horses with EA is not found in systemic circulation, and only the mastocytic and mixed subgroups of horses with EA had allergen-specific IgE in BAL fluid.[86] This difference in presence/absence of IgE based on EA subtype may help to explain the conflicting evidence of previous studies that did not investigate multiple EA subtypes. Additional differences may be explained by the limited number of allergens investigated in previous studies as more recent research suggests that protein microarrays can be used for large-scale IgE mapping of allergens associated with the environment of horses and may be more useful for informing patient-specific AIT in horses with EA.[85] Further research is needed to determine what role, if any, IgE/histamine plays in the immunopathology of various subtypes of EA as this may help to inform which equine patients would benefit most from AIT.

Finally, improved availability of non- to minimally invasive biomarkers of lower airway inflammation in horses would benefit efforts to develop approaches that are more preventive for EA, especially biomarkers sensitive enough to pick up low levels of lower airway inflammation as in mEA.[13,44] Because equine respiratory health is integrally linked with environmental exposure, the right biomarker could provide a convenient and relevant way to monitor impact of changes in nutrition, stable environment, training practices, and more on lower respiratory health and performance.

6. Conclusion

Respirable particles in a horse's environment can have detrimental effects on equine respiratory health and function, resulting in a range of consequences from the mild-to-moderate lower airway inflammation of mEA that impairs performance in top equine athletes to the severe, debilitating, and recurrent inflammation of sEA that curtails a horse's performance career and threatens their health and welfare. Equine asthma is a highly prevalent disease that has a significant impact on the equine industry; therefore, veterinarians will need to deploy a multipronged approach of treatment, management, and even prevention in order to minimize the impacts of this syndrome on horses and their owners.

Acknowledgments

Declaration of Ethics

The Author has adhered to the Principles of Veterinary Medical Ethics of the AVMA.

Conflict of Interest

The Author has no conflicts of interest.

References and Footnote

1. Ivester KM, Couëtil LL, Moore GE. An observational study of environmental exposures, airway cytology, and performance in racing Thoroughbreds. *J Vet Intern Med* 2018;32:1754–1762.
2. Sheats MK, Davis KU, Poole JA. Comparative review of asthma in farmers and horses. *Curr Allergy Asthma Rep* 2019;19:50.
3. Pirie RS. Recurrent airway obstruction: A review. *Equine Vet J* 2014;46:276–288.
4. Leclere M, Lavoie-Lamoureux A, Lavoie JP. Heaves, an asthma-like disease of horses. *Respirology* 2011;16:1027–1046.
5. Couëtil LL, Denicola DB. Blood gas, plasma lactate and bronchoalveolar lavage cytology analyses in racehorses with respiratory disease. *Equine Vet J Suppl* 1999;31:77–82.
6. Sánchez A, Couëtil LL, Ward MP, et al. Effect of airway disease on blood gas exchange in racehorses. *J Vet Intern Med* 2005;19:87–92.
7. Pirie RS, Dixon PM, Collie DD, et al. Pulmonary and systemic effects of inhaled endotoxin in control and heaves horses. *Equine Vet J* 2010;33:311–318.
8. Davis KU, Sheats MK. Bronchoalveolar lavage cytology characteristics and seasonal changes in a herd of pastured teaching horses. *Front Vet Sci* 2019;6:74.
9. Hotchkiss JW, Reid SW, Christley RM. A survey of horse owners in Great Britain regarding horses in their care. Part 2: Risk factors for recurrent airway obstruction. *Equine Vet J* 2007;39:301–308.
10. Robinson NE, Berney C, Eberhart S, et al. Coughing, mucus accumulation, airway obstruction, and airway inflammation in control horses and horses affected with recurrent airway obstruction. *Am J Vet Res* 2003;64:550–557.
11. Costa LR, Johnson JR, Baur ME, et al. Temporal clinical exacerbation of summer pasture-associated recurrent airway obstruction and relationship with climate and aeroallergens in horses. *Am J Vet Res* 2006;67:1635–1642.
12. Couëtil LL, Cardwell JM, Gerber V, et al. Inflammatory airway disease of horses–Revised consensus statement. *J Vet Intern Med* 2016;30:503–515.
13. Couetil L, Cardwell JM, Leguillette R, et al. Equine asthma: Current understanding and future directions. *Front Vet Sci* 2020;7:450.
14. Stucchi L, Alberti E, Stancari G, et al. The relationship between lung inflammation and aerobic threshold in Standardbred racehorses with mild-moderate equine asthma. *Animals (Basel)* 2020;10:1278.
15. Simões J, Sales Luís J, Tilley P. Contribution of lung function tests to the staging of severe equine asthma syndrome in the field. *Res Vet Sci* 2019;123:112–117.

16. Johansson AM, Gardner SY, Atkins CE, et al. Cardiovascular effects of acute pulmonary obstruction in horses with recurrent airway obstruction. *J Vet Intern Med* 2007;21:302–307.
17. Decloedt A, Borowicz H, Slowikowska M, et al. Right ventricular function during acute exacerbation of severe equine asthma. *Equine Vet J* 2017;49:603–608.
18. Pirie RS, Collie DD, Dixon PM, et al. Inhaled endotoxin and organic dust particulates have synergistic proinflammatory effects in equine heaves (organic dust-induced asthma). *Clin Exp Allergy* 2003;33:676–683.
19. Uberti B, Morán G. Role of neutrophils in equine asthma. *Anim Health Res Rev* 2018;19:65–73.
20. Gerber V, Lindberg A, Berney C, et al. Airway mucus in recurrent airway obstruction–Short-term response to environmental challenge. *J Vet Intern Med* 2004;18:92–97.
21. Joubert P, Cordeau ME, Lavoie JP. Cytokine mRNA expression of pulmonary macrophages varies with challenge but not with disease state in horses with heaves or in controls. *Vet Immunol Immunopathol* 2011;142:236–242.
22. Aharonson-Raz K, Lohmann KL, Townsend HG, et al. Pulmonary intravascular macrophages as proinflammatory cells in heaves, an asthma-like equine disease. *Am J Physiol Lung Cell Mol Physiol* 2012;303:189–198.
23. Barton AK, Gehlen H. Pulmonary remodeling in equine asthma: What do we know about mediators of inflammation in the horse? *Mediators Inflamm* 2016;2016:5693205.
24. Poole JA, Gleason AM, Bauer C, et al. CD11c(+)/CD11b(+) cells are critical for organic dust-elicited murine lung inflammation. *Am J Respir Cell Mol Biol* 2012;47:652–659.
25. Bullone M, Lavoie JP. The contribution of oxidative stress and inflamm-aging in human and equine asthma. *Int J Mol Sci* 2017;18:2612.
26. Poole JA, Romberger DJ. Immunological and inflammatory responses to organic dust in agriculture. *Curr Opin Allergy Clin Immunol* 2012;12:126–132.
27. Giguere S, Viel L, Lee E, et al. Cytokine induction in pulmonary airways of horses with heaves and effect of therapy with inhaled fluticasone propionate. *Vet Immunol Immunopathol* 2002;85:147–158.
28. Ainsworth DM, Grunig G, Matychak MB, et al. Recurrent airway obstruction (RAO) in horses is characterized by IFN-gamma and IL-8 production in bronchoalveolar lavage cells. *Vet Immunol Immunopathol* 2003;96:83–91.
29. Bullone M, Joubert P, Gagné A, et al. Bronchoalveolar lavage fluid neutrophilia is associated with the severity of pulmonary lesions during equine asthma exacerbations. *Equine Vet J* 2018;50:609–615.
30. Bosshard S, Gerber V. Evaluation of coughing and nasal discharge as early indicators for an increased risk to develop equine recurrent airway obstruction (RAO). *J Vet Intern Med* 2014;28:618–623.
31. Calzetta L, Rogliani P, Page C, et al. Clinical effect of corticosteroids in asthma-affected horses: A quantitative synthesis. *Equine Vet J* 2018;50:594–601.
32. Lavoie JP, Bullone M, Rodrigues N, et al. Effect of different doses of inhaled ciclesonide on lung function, clinical signs related to airflow limitation and serum cortisol levels in horses with experimentally induced mild to severe airway obstruction. *Equine Vet J* 2019;51:779–786.
33. Lo Feudo CM, Stucchi L, Alberti E, et al. The role of thoracic ultrasonography and airway endoscopy in the diagnosis of equine asthma and exercise-induced pulmonary hemorrhage. *Vet Sci* 2021;8:276.
34. Rossi H, Virtala AM, Raekallio M, et al. Comparison of tracheal wash and bronchoalveolar lavage cytology in 154 horses with and without respiratory signs in a referral hospital over 2009-2015. *Front Vet Sci* 2018;5:61.
35. Siwinska N, Zak A, Slowikowska M, et al. Prevalence and severity of ultrasonographic pulmonary findings in horses with asthma - A preliminary study. *Pol J Vet Sci* 2019;22:653–659.
36. Miskovic M, Couetil LL, Thompson CA. Lung function and airway cytologic profiles in horses with recurrent airway obstruction maintained in low-dust environments. *J Vet Intern Med* 2007;21:1060–1066.
37. Hoffman A, Kuehn H, Riedelberger K, et al. Flowmetric comparison of respiratory inductance plethysmography and pneumotachography in horses. *J Appl Physiol* 2001;91:2767–2775.
38. Mazan MR, Deveney EF, DeWitt S, et al. Energetic cost of breathing, body composition, and pulmonary function in horses with recurrent airway obstruction. *J Appl Physiol* 2004;97:91–97.
39. Bullone M, Vargas A, Elce Y, et al. Fluticasone/salmeterol reduces remodelling and neutrophilic inflammation in severe equine asthma. *Sci Rep* 2017;7:8843.
40. Nogradi N, Couetil LL, Messick J, et al. Omega-3 fatty acid supplementation provides an additional benefit to a low-dust diet in the management of horses with chronic lower airway inflammatory disease. *J Vet Intern Med* 2015;29:299–306.
41. Lavoie JP, Cesarini C, Lavoie-Lamoureux A, et al. Bronchoalveolar lavage fluid cytology and cytokine messenger ribonucleic acid expression of racehorses with exercise intolerance and lower airway inflammation. *J Vet Intern Med* 2011;25:322–329.
42. Pirrone F, Albertini M, Clement MG, et al. Respiratory mechanics in Standardbred horses with sub-clinical inflammatory airway disease and poor athletic performance. *Vet J* 2007;173:144–150.
43. Ramseyer A, Gaillard C, Burger D, et al. Effects of genetic and environmental factors on chronic lower airway disease in horses. *J Vet Intern Med* 2007;21:149–156.
44. Gy C, Leclere M, Vargas A, et al. Investigation of blood biomarkers for the diagnosis of mild to moderate asthma in horses. *J Vet Intern Med* 2019;33:1789–1795.
45. Herteman N, Mosing M, Waldmann AD, et al. Exercise-induced airflow changes in horses with asthma measured by electrical impedance tomography. *J Vet Intern Med* 2021;35:2500–2510.
46. Pacholewska A, Kraft MF, Gerber V, et al. Differential expression of serum microRNAs supports $CD4^+$ T cell differentiation into Th2/Th17 cells in severe equine asthma. *Genes (Basel)* 2017;8:383.
47. Verdon M, Lanz S, Rhyner C, et al. Allergen-specific immunoglobulin E in sera of horses affected with insect bite hypersensitivity, severe equine asthma or both conditions. *J Vet Intern Med* 2019;33:266–274.
48. Mahalingam-Dhingra A, Mazan MR, Bedenice D, et al. A CONSORT-guided, randomized, double-blind, controlled pilot clinical trial of inhaled lidocaine for the treatment of equine asthma. *Can J Vet Res* 2022;86:116–124.
49. Calzetta L, Crupi R, Roncada P, et al. Clinical efficacy of bronchodilators in equine asthma: Looking for minimal important difference. *Equine Vet J* 2020;52:305–313.
50. Hoffman AM. Bronchoalveolar lavage: Sampling technique and guidelines for cytologic preparation and interpretation. *Vet Clin North Am Equine Pract* 2008;24:423–435.
51. Hufnagl K, Hirt R, Robibaro B. Out of breath: Asthma in humans and their animals. In: Jensen-Jarolim E, ed. *Comparative medicine*. Cham: Springer, 2017;71–85.
52. Bedenice D, Mazan MR, Hoffman AM. Association between cough and cytology of bronchoalveolar lavage fluid and pulmonary function in horses diagnosed with inflammatory airway disease. *J Vet Intern Med* 2008;22:1022–1028.
53. Tilley P, Sales Luis JP, Branco Ferreira M. Correlation and discriminant analysis between clinical, endoscopic, thoracic X-ray and bronchoalveolar lavage fluid cytology scores, for staging horses with recurrent airway obstruction (RAO). *Res Vet Sci* 2012;93:1006–1014.
54. Couëtil LL, Rosenthal FS, DeNicola DB, et al. Clinical signs, evaluation of bronchoalveolar lavage fluid, and assessment of pulmonary function in horses with inflammatory respiratory disease. *Am J Vet Res* 2001;62:538–546.
55. Richard EA, Fortier GD, Denoix JM, et al. Influence of subclinical inflammatory airway disease on equine respiratory function evaluated by impulse oscillometry. *Equine Vet J* 2009;41:384–389.
56. Wichtel M, Gomez D, Burton S, et al. Relationships between equine airway reactivity measured by flowmetric plethysmography and specific indicators of airway inflammation in horses with suspected inflammatory airway disease. *Equine Vet J* 2016;48:466–471.

57. Cullimore AM, Secombe CJ, Lester GD, et al. Bronchoalveolar lavage fluid cytology and airway hyper-reactivity in clinically normal horses. *Aust Vet J* 2018;96:291–296.
58. Pirie RS. Mild to moderate equine asthma—An overview. *Livestock* 2017;22:158–163.
59. Pirie RS. Severe equine asthma—An overview. *Equine Health* 2018;39:21–28.
60. Clements JM, Pirie RS. Respirable dust concentrations in equine stables. Part 1: Validation of equipment and effect of various management systems. *Res Vet Sci* 2007;83:256–262.
61. Pirie RS, Mueller HW, Engel O, et al. Inhaled ciclesonide is efficacious and well tolerated in the treatment of severe equine asthma in a large prospective European clinical trial. *Equine Vet J* 2021;53:1094–1104.
62. Woods PS, Robinson NE, Swanson MC, et al. Airborne dust and aeroallergen concentration in a horse stable under two different management systems. *Equine Vet J* 1993;25:208–213.
63. Berndt A, Derksen FJ, Edward Robinson N. Endotoxin concentrations within the breathing zone of horses are higher in stables than on pasture. *Vet J* 2010;183:54–57.
64. Simões J, Sales Luís JP, Tilley P. Owner compliance to an environmental management protocol for severe equine asthma syndrome. *J Equine Vet Sci* 2020;87:102937.
65. Ivester KM, Couëtil LL, Moore GE, et al. Environmental exposures and airway inflammation in young Thoroughbred horses. *J Vet Intern Med* 2014;28:918–924.
66. Olave CJ, Ivester KM, Couetil LL, et al. Dust exposure and pulmonary inflammation in Standardbred racehorses fed dry hay or haylage: A pilot study. *Vet J* 2021;271:105654.
67. Seguin V, Lemauviel-Lavenant S, Garon D, et al. Effect of agricultural and environmental factors on the hay characteristics involved in equine respiratory disease. *Agric Ecosyst Environ* 2010;135:206–215.
68. Hotchkiss JW. Equine asthma: Managing the environment. *UK-Vet Equine* 2019;3:78–84.
69. Auger E-J, Moore-Colyer MJS. The effect of management regime on airborne respirable dust concentrations in two different types of horse stable design. *J Equine Vet Sci* 2017;51:105–109.
70. Orard M, Hue E, Couroucé A, et al. The influence of hay steaming on clinical signs and airway immune response in severe asthmatic horses. *BMC Vet Res* 2018;14:345.
71. Saastamoinen M. Bedding choices for horses – An overview. *Hous Manag Horses Nord Balt Clim* 2011;7:33–36.
72. Mönki J, Saastamoinen M, Karikoski N, et al. Effects of bedding material on equine lower airway inflammation: A crossover study comparing peat and wood shavings. *Front Vet Sci* 2021;8:656814.
73. Mönki J, Saastamoinen M, Karikoski N, et al. Effects of bedding material on equine lower airway inflammation: A comparison of two peat beddings, wood pellet, and straw pellet. *Front Vet Sci* 2021;8:799645.
74. Conrad SE. Breathing easy: Managing horses with asthma, *The Horse*, April 26, 2021. https://thehorse.com/19375/breathing-easy-managing-horses-with-asthma/. Accessed June 28, 2022.
75. Mair TS. Obstructive pulmonary disease in 18 horses at summer pasture. *Vet Rec* 1996;138:89–91.
76. Bullone M, Murcia RY, Lavoie JP. Environmental heat and airborne pollen concentration are associated with increased asthma severity in horses. *Equine Vet J* 2016;48:479–484.
77. Taylor PE, Flagan RC, Valenta R, et al. Release of allergens as respirable aerosols: A link between grass pollen and asthma. *J Allergy Clin Immunol* 2002;109:51–56.
78. Burch M, Levetin E. Effects of meteorological conditions on spore plumes. *Int J Biometeorol* 2002;46:107–117.
79. Klier J, Lehmann B, Fuchs S, et al. Nanoparticulate CpG immunotherapy in RAO-affected horses: Phase I and IIa study. *J Vet Intern Med* 2015;29:286–293.
80. Klier J, Bartl C, Geuder S, et al. Immunomodulatory asthma therapy in the equine animal model: A dose-response study and evaluation of a long-term effect. *Immun Inflamm Dis* 2019;7:130–149.
81. Barton AK, Shety T, Klier J, et al. Metalloproteinases and their inhibitors under the course of immunostimulation by CPG-ODN and specific antigen inhalation in equine asthma. *Mediators Inflamm* 2019;2019:7845623.
82. Karagianni AE, Kurian D, Cillán-Garcia E, et al. Training associated alterations in equine respiratory immunity using a multiomics comparative approach. *Sci Rep* 2022;12:427.
83. Klier J, Lindner D, Reese S, et al. Comparison of four different allergy tests in equine asthma affected horses and allergen inhalation provocation test. *J Equine Vet Sci* 2021; 102:103433.
84. Niedzwiedz A, Jaworski Z, Kubiak K. Serum concentrations of allergen-specific IgE in horses with equine recurrent airway obstruction and healthy controls assessed by ELISA. *Vet Clin Pathol* 2015;44:391–396.
85. White S, Moore-Colyer M, Marti E, et al. Development of a comprehensive protein microarray for immunoglobulin E profiling in horses with severe asthma. *J Vet Intern Med* 2019;33:2327–2335.
86. Hansen S, Otten ND, Birch K, et al. Bronchoalveolar lavage fluid cytokine, cytology and IgE allergen in horses with equine asthma. *Vet Immunol Immunopathol* 2020; 220:109976.
87. Scharrenberg A, Gerber V, Swinburne JE, et al. IgE, IgGa, IgGb and IgG(T) serum antibody levels in offspring of two sires affected with equine recurrent airway obstruction. *Anim Genet* 2010;41:131–137.

[a]Buscopan™, Boehringer Ingelheim, St. Joseph, MO 64506.

Preventative Dentistry

Apryle Horbal, VMD, MPhil, MRCVS, DAVDC-EQ

Author's address: 1301 Grandview Avenue, Suite 220, Pittsburgh, PA, 15211; e-mail: apryle@wynterscircle.com. © 2022 AAEP.

1. Introduction

The physiology of the modern horse is designed to graze for up to 18 hours[1] of their day on very coarse materials, meaning that appropriate preventative dentistry practices can have a profound effect on the digestive efficiency and overall health of the horse. This significant forage intake is coupled with the need to grind it into small enough particles to maximize the surface area on which the cellulase digesting microbes in the hindgut can act upon. This in turn means that the effective mastication by the cheek teeth in the oral cavity produces the most effective digestion in the hindgut. A complete basic understanding of the form and function of the equine dentition is necessary to ensure the cause and effect of any abnormality and subsequent treatment is completely understood by the practitioner to enable the most effective mastication possible.

As the advent of more appropriate feed materials for senior horses coupled with more treatment options for common geriatric ailments are prolonging the overall life span of the horse, it is also important for the practitioner to be able to prolong the effective life of the horse's dentition. On average, the normal horse's teeth erupt and wear at a rate of 2 to 3 mm per year. In this case, preventative dentistry often means identifying a more minor abnormality early in this cycle and addressing it appropriately before it worsens on its own or causes major pathology. Some common cases of this early intervention include treating malocclusions and overgrowths before they lead to further problems (such as diastema formation that leads to periodontal disease, or an overgrowth that causes painful gingival ulceration), and also identifying pathology early to prevent secondary complications and further pain and suffering in the horse (such as a complicated crown fracture in a cheek tooth or early signs of equine odontoclastic tooth resorption and hypercementosis [EOTRH]).

As equine dentistry involves this complex interplay and understanding of anatomy, physiology, and mechanics, dentistry is most appropriately performed by the veterinarian. The ability to assess the overall health of the horse and address multifaceted medical problems, of which dentistry may only be a part, can only be done by the veterinary practitioner. Additionally, a complete dental evaluation involves a physical examination and sedation of the horse, and veterinarians are also the only qualified professionals able to offer follow-up diagnostics and imaging if more significant pathology, dental or otherwise, is suspected. The concept of "floating" teeth is slowly shifting, with veterinarians identifying areas for potential added value to dentistry, but the importance of veterinary dentistry cannot be overstated. There are many occasions that fall outside the concept of "routine" dentistry despite how it is referred to by many horse owners and veterinarians. As such, the first step is to understand normal vs pathological dentition, followed by an understanding of how to address pathological findings appropriately—even if that requires staged treatment and/or referral to a specialist if possible, and lastly, being able to effectively communicate the importance of the exam findings and appropriate treatment to horse owners.

NOTES

2. Anatomy and Physiology Overview

The development of hypsodont (high-crowned and continuously erupting) teeth coincided with increased grazing behavior in the horse.[2] As the hypsodont dentition developed, enamel and dentine infoldings began to form to increase the length of protruding enamel folds on the occlusal surface of the cheek teeth. The teeth of modern horses also contain an increased amount of cementum in comparison to their predecessors. Because of the prolonged eruption of equine teeth, cementum appeared as a component of the equine clinical crown, where it greatly contributes to the crown size[3] as opposed to brachydont teeth, in which it only appears subgingivally to anchor the periodontal ligaments. Additionally, the softer cementum and dentine serve to buffer the more brittle adjacent enamel against cracking or fracturing.[1] Peripheral cementum is present over the entire nonocclusal external surface of the equine cheek tooth, serving subgingivally as part of the periodontal apparatus,[4] while infundibular cementum fills the enamel "cup" of the infundibulum in the incisors and maxillary cheek teeth.

Adult horses have between 36 and 44 permanent teeth. The typical dental formula includes 12 incisors, up to 4 canines, up to 4 first premolars (wolf teeth), and 24 cheek teeth (premolars and molars). Canines only erupt in 27.2% of female horses.[5] The vestigial first premolars are present in nearly 20% of adult horses and are found more frequently in the maxillary than the mandibular arcade.[5] The fully formed equine cheek tooth usually contains 5 vascular pulp horns (with 6 in all Triadan 06 cheek teeth, 6 in mandibular Triadan 11 cheek teeth, and 7 in maxillary Triadan 11 cheek teeth), all of which communicate via a common apical pulp chamber for the first few years after eruption but later develop variable patterns of pulp horn connections as roots form at the apex over several years.[6,7]

The prolonged eruption of equine cheek teeth is due to the constant proliferation and remodeling of the periodontal ligament, which creates traction on the tooth, essentially drawing it into the oral cavity.[8] The rate of attrition, or wear of the teeth, is determined by tooth morphology, abrasive nature of the diet, and the amount of time horses spend masticating. Reserve crowns can be up to 9 cm long at initial eruption of the tooth, and cheek teeth often reach a state of complete senile wear, or "smooth mouth," at between 25 and 30 years of age. Hypsodont teeth constantly lay down secondary dentine at the occlusal and peripheral aspects of the pulp horns for the life of the tooth. Therefore, equine pulp is required to remain metabolically active and maintain an excellent blood supply through large apical vascular foramina. At eruption, the entire equine tooth is covered by a thin layer of cementum and the pulp horns are also covered by a layer of primary dentine. The pulp chambers are surrounded by primary dentine, which is surrounded by folded layers of peripheral enamel. Incisors and maxillary cheek teeth also contain 1 single and 2 infundibula, respectively, lined by enamel and filled to varying degrees with cementum (Fig. 1). At or shortly after eruption, no further deposition or repair of all enamel or infundibular cementum can occur, but peripheral cementum will continue to be deposited around the apex of the tooth, anchoring the tooth via the periodontal ligament to the alveolus.[9] Occlusally, when the tooth comes into attrition, the primary dentine wears off and secondary dentine begins to be laid down over the pulp horns to protect them from exposure to the oral cavity environment and its microorganisms.[6]

The equine cheek teeth arcade is also characterized as anisognathic, meaning that the teeth are in unequal or uneven rows. The maxillary and mandibular rows of cheek teeth typically meet at an approximately 15-degree angle, with the maxillary teeth being wider than the mandibular and the caudal cheek teeth meeting at a steeper angle than the more rostral cheek teeth. This angulation is not a strict mandate for correction, though, and should only be used as a loose reference with any other pathology involved prior to modifying the occlusal table angle during treatment.[10] The cheek teeth are further divided into quadrants and identified using the Triadan nomenclature system. The Triadan 100 tooth arcade lies dorsal to the Triadan 400 arcade on the right side of the mouth, while the Triadan 200 and 300 arcades oppose each other on the left side. Horses can functionally only chew on one side at a time, and this combination of unilateral mastication coupled with the anisognathic morphology is one of the core factors that leads to the formation of sharp enamel points—the most common dental pathology found in the modern horse. Another core component of sharp point formation is due to the difference in microhardness and wear rates between enamel, dentine, and cementum. The enamel wears slower than the other dental tissues, and so it becomes more prominent when compared to areas of dentine and/or cementum.[11,12]

As prey animals, horses are often good at masking signs of dental disease. Even on thorough oral examination, the first signs of disease are often subtle, which is why a comprehensive understanding of "normal" along with a good process and the correct equipment for examination are the first and most important steps in quality preventative dentistry.

3. The Preventative Dental Examination

Many specialists and experienced practitioners in equine dentistry would agree that at least 80% of their time performing more routine dentistry is actually spent on the history, physical examination, and oral examination of the horse prior to any occlusal adjustment or "floating" being performed. This is a significant area in which the veterinarian can educate the client and demonstrate the importance of the veterinary perspective. In order to perform the highest quality and most complete examination possible, the veterinarian should have the following equipment available in addition to their good understanding of dental anatomy and physiology:

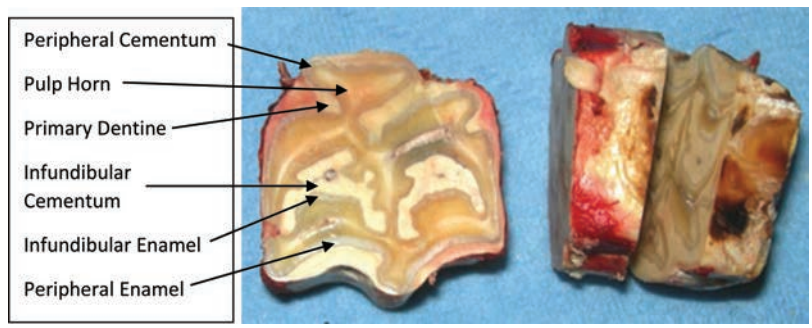

Fig. 1. The dental tissues are visible on this cross section of an equine maxillary cheek tooth.

- Full-Mouth Speculum (eg, McPherson/Hausmann, Millennium, or Alumi-Spec[a])
  - This is designed to give a view of the entire oral cavity, but also to protect the practitioner's hand/arm and other equipment. A high-quality, durable speculum is most essential.
- Rigid Long-Handled Mirror and/or Oroscope
  - An oroscope can be purpose-bought or can be built using several commercially available pieces of equipment.[13,14]
- Long-Handled Periodontal and/or Endodontic Probes (commercially available from many equine veterinary equipment suppliers)
- Headlamp
  - Can be purchased at outdoor/recreational stores, but if performing a significant amount of dentistry, the headlamps available from surgical suppliers offer noticeable improvements in ergonomics and adjustability.
- Large dosing syringe to rinse feed material from the oral cavity
- Appropriate sedation
  - Typically involves a combination of an alpha-2-agonist (xylazine, detomidine, or romifidine) and an opioid (most commonly butorphanol)
- Dental chart for recording findings during the exam
  - This can be a printable PDF found online, may be part of a practice's electronic medical records system, or a subscription may be purchased for several specific dental charting mobile applications.
- For subsequent treatment: Wide variety of dental rasps and/or purpose-built motorized equipment

4. Steps of a Thorough Dental Evaluation

- Obtain a thorough medical and management history.

In addition to routine questions regarding the horse's diet and vaccine status, the practitioner should cover the horse's weight, particularly weight loss, and any changes in appetite or energy level. Changes in diet and management, such as turnout, should also be noted as horses with dental disease generally do better when turned out on fresh grass as opposed to being fed dry hay. The owners/caretakers should also be asked specifically about the horse's eating habits and if they are dropping feed or quidding. They should also be asked about any previous dental examination findings and treatments.

If the horse is ridden, any issues with bitting or the bridle should be noted. As horses age, other comorbid conditions become pertinent, and identifying those may prevent future complications. This can include suspect cases of pituitary pars intermedia dysfunction (PPID), as these horses may have difficulty recovering from dental problems, and horses with advanced degenerative joint disease, as they may be less stable or uncomfortable when sedated. Additionally, if EOTRH is suspected, owners should be asked about the horse's eating and grazing behavior. Horses with EOTRH will often pick up their feed and hay with their lips and slowly maneuver it into the oral cavity. They may be reluctant to grasp hard treats such as carrots and apples, and also may be less enthusiastic about turnout and grazing.

- Observation from a distance

This step can affect the veterinarian's interpretation of the dental examination, but it is often forgotten or passed up in a rush to perform a procedure. The horse's demeanor and facial expressions can be observed from a distance, along with any nasal discharge. The horse should also be observed eating hay, if possible, as quidding will most often be observed when hay is being ingested. Listening for strong and vigorous crunching sounds during mastication may also provide an indicator of the horse's intraoral comfort and their ability to appropriately grind their forage. Soft squelching sounds or quidding may indicate inadequate dentition to fully masticate fibrous feed materials or pain within the oral cavity. The horse's fecal material should also be observed for consistency and fecal fiber length, particularly in horses with poor dentition. Lastly, the position of the lips, tongue, and jaw should be observed. The horse does not typically

rest with their jaws closed tightly together, but if the incisors are purposely held apart or the tongue is held between the incisors, further investigation for EOTRH may be warranted.

- Physical exam

The clinician's steps for a routine physical examination should be followed, with particular attention paid to the horse's fitness for sedation for a full dental examination. This mainly involves examining the cardiovascular system along with the musculoskeletal and nervous systems. The body condition score should be noted, along with any signs of concurrent disease (such as PPID, sinus disease, or other respiratory ailments).

- Sedation

Most dental practitioners choose to use a combination of an alpha-2-agonist and an opioid when performing routine dental examination and treatment, most commonly detomidine + butorphanol in practice. A combination of xylazine + butorphanol should be reserved for patients with regular dental records and no previous knowledge of pathology, or patients with concerns surrounding duration of sedation. The amount of sedative administered should be titrated for the patient's size and temperament, keeping in mind the main goals of sedation when performing dentistry:

- Patient compliance
- Stationary head
- Tongue relaxation
- Cessation of chewing

The sedation should be administered intravenously, and the practitioner should only begin their dental examination when the horse is minimally responsive to external stimulation.

- External examination of the head

This examination should be performed both visually and via palpation. The structures and confirmation of the head should be symmetrical, with note of any focal swellings, condition of the masseter muscles, and any deviation of the nose (wry nose). Even very mild wry nose can be implicated in some cheek teeth malocclusions. The submandibular and parotid lymph nodes should be palpated, along with the ramii of the mandible and temporomandibular joints (TMJs). The TMJs are overimplicated in many occurrences of oral cavity discomfort in the horse, so any suspect pathology should be thoroughly investigated before determining this area to be the cause of any problem, and other more common dental abnormalities should be ruled out. The mandible can also be manipulated at this time to ensure sufficient lateral excursion is present. This will vary by individual, but the mandible should move freely and relatively symmetrically from side to side, and a slight rostral-caudal movement should also be possible.

- Incisor and canine exam

An examination of the incisors should always occur before placing the full-mouth speculum to ensure they are stable enough to allow for a safe examination of the caudal oral cavity. The number of incisors should be counted, along with noting any malocclusions and the presence of permanent or deciduous teeth. Findings that may affect the ability to safely place the full-mouth speculum may include missing or fractured incisors, signs of EOTRH, and signs of stereotypic behavior such as cribbing leading to excessive wear. In many of these cases, using dental impression material or soft fabric/cotton to pad the bite plates of the full-mouth speculum will allow for examination of the cheek teeth. Commonly, calculus deposition may be present on the canines, which can typically be addressed by physical removal of the calculus using forceps to prevent associated gingivitis. In general, reduction of the incisors is performed on a limited basis, specifically when a malocclusion (such as "parrot mouth") or fractured teeth/uneven wear prevents smooth lateral excursion of the jaw.

- Placement of the full-mouth speculum

Care should be taken when both placing and utilizing a speculum as these are large and heavy pieces of equipment and can cause accidental injury to those restraining the horse. The poll strap should be positioned, and the bite plates slid gently between the incisors, and the poll strap should then be tightened. The poll strap may need to be retightened during the exam and treatment. The speculum should then be opened gradually to the extent the practitioner is able to reach the last cheek teeth (Triadan 11). If the exam is prolonged, the speculum should be occasionally closed to allow the mouth to relax during the procedure. The mouth should then be lavaged with dilute chlorhexidine in warm water to remove any feed material.

- Examination of the cheek teeth

The cheek teeth should be examined both manually and visually (Fig. 2). Manual exam can help to determine where there may be sharp areas on the cheek teeth that can lead to soft tissue trauma, including sharp enamel points and overgrowths. The practitioner may also be able to feel any large diastemata, fractures, or feed impaction. A headlamp and mirror should then be used to visually follow the manual examination, looking for any soft tissue trauma, including any bit trauma, and counting the teeth, as supernumerary cheek teeth often are accidentally overlooked when they lay just caudal to the Triadan 11 tooth. The mirror or oroscope should be used to examine the occlusal surface for any pulpar exposure, infudibular caries, or small fractures. The mirror should also be used to examine the entirety

Fig. 2. Utilizing a speculum, headlamp, and a long-handled mirror to examine the cheek teeth.

of the gingival margin of each cheek tooth row lingually, palatally, and buccally for diastemata, food impaction, and periodontal disease along with any peripheral caries.

5. Common Abnormalities Often Able to Be Treated by Routine Occlusal Adjustment

- Enamel points

Eating concentrates encourages horses to have a much greater vertical crushing stroke along with less range in their medially directed horizontal power stroke than when masticating forage.[15] The presence of slow-wearing enamel infoldings along with this vertical chewing motion can lead to development of sharp enamel points or overgrowths as the remaining components of the tooth wear more quickly.[16] However, this is a generalization, and sharp enamel points and overgrowths are also found in horses that consume an exclusively forage diet. The level and direction of occlusal forces on the teeth, and therefore patterns of attrition, vary significantly depending on the individual horse.

The sharp enamel points typically form on the lingual edges of the mandibular cheek teeth and the buccal edges of the maxillary cheek teeth. The maxillary sharp points tend to be more significant as they occur in association with the cingulae that can lead to soft tissue trauma and ulceration of the cheeks. Cingulae are ridges on the lateral aspect of maxillary cheek teeth that arise from enamel folds and give rise to the sharp points (Fig. 3). Their exact purpose is unclear, but it is suggested that they give the tooth structural rigidity. The cingulae are normal anatomical features of the cheek teeth and should not be reduced themselves—only the sharp enamel points that form at the occlusal-buccal junction should be removed.[17]

- Transverse ridges

The normal protruding enamel cusps that form as adjacent dentine and cementum wear more quickly are known as transverse ridges. They function to increase the occlusal surface area but may become exaggerated due to abnormal patterns of wear.[18] Transverse ridges are, again, normal anatomical features of the cheek teeth. If they are relatively symmetrical across all cheek teeth, seem to provide good occlusal contact, and do not prevent excursion of the jaw, they are likely not pathological and should only be reduced minimally if at all. Exaggerated transverse ridges (or overgrowths) would be focal and noticeably larger than those on the other cheek teeth. They may be associated with an opposing pathology (such as a diastema or missing tooth) and may lead to further abnormal wear patterns if left untreated. These should be reduced within safe limits to prevent further wear abnormalities and diastema formation, with an understanding that they may still provide valuable occlusal surface contact if they can be managed appropriately.

- Focal overgrowths

Excessive wear in the occlusal surface is attributed to reduced enamel content or delayed eruption of that tooth, which then leads to the development of overgrowth in the opposing tooth.[19] It is a common misconception that the overgrown/overlong tooth is pathological, when in actuality it is often dysplastic calcified tissue in the overworn tooth. Despite this, the overgrown tooth must still be reasonably reduced (4–5 mm at a time) to allow for proper masticatory motion and prevent sequelae from a significant overgrowth, such as severe malocclusion or soft tissue injury.[20]

- Senile excavation and expiration (Fig. 4)

As the cheek teeth reach the end of their dental life, they wear much more quickly as their enamel folds expire. The maxillary cheek teeth often have an excavated appearance, with the central portion of the tooth completely worn due to lack of infundibular enamel at the apical aspect of the tooth. Any opposing teeth with a greater enamel content may overerupt as teeth with less enamel will wear quite quickly. These teeth are then of limited use in mastication, and may either then be naturally shed or wear down to the smooth cemental components of the roots. Dental treatment in senior horses is mostly palliative, and it is most important to preserve as much of the occlusal enamel as possible during any dental treatment to prolong the life of the tooth, while also addressing any potential sources of pain and/or periodontal disease appropriately. Frequent reexamination is warranted, but limited adjustments should be performed each time.[17]

6. Special Considerations

- Wolf teeth

The first premolars are often extracted in young horses, although evidence suggests that their extraction is unnecessary unless displaced or abnormally large. In

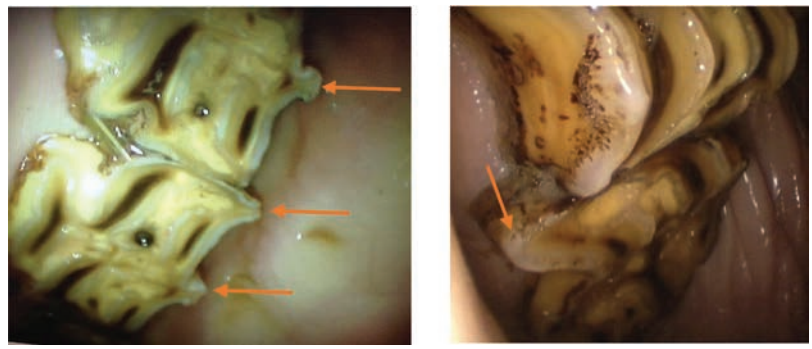

Fig. 3. Maxillary cheek teeth with sharp enamel points forming on the cingulae leading to buccal ulceration (left) vs normal cingulae (right).

Fig. 4. Senile excavation (circle), remaining expired root remnants (star), and senile diastemata (arrows) in aged horse maxillary cheek teeth.

fact, these vestigial teeth often shed with the deciduous second premolars at approximately 2.5 years of age, completely without intervention. While their extraction is not necessarily harmful, it is best to wait if possible and observe for any biting difficulties when training begins, and then make the decision to extract if necessary.

- Parrot mouth and sow mouth (Abbreviation: MAL/2 and MAL/3)

Malocclusions caused by mismatch of the length of the mandible and maxilla lead to the pathology normally termed either parrot mouth (maxilla longer than mandible) or sow mouth (mandible longer than maxilla). If severe, intervention with interdental wiring and splints is present when identified very early and with extremely dedicated and conscientious owners, but it is not possible to intervene once the horse is over 12 months in age. In this case, the incisor overbite must be managed, along with the cheek teeth malocclusion that occurs due to the mandible/maxilla mismatch. This may be significant, or it may be extremely subtle. Depending on the degree of displacement, the Triadan 06 and 11 teeth can become severely overgrown.[21]

- Cheek tooth malocclusions (Abbreviation: MAL/1)

The malocclusion of 1 single or bilaterally paired cheek teeth is usually also classified as a displacement in the lingual, buccal, or palatal direction (Fig. 5). Some of these occur congenitally while some are acquired due to abnormal mastication, but in either case, these displacements often worsen if left untreated, causing the teeth to become more severely angled or rotated over time.[22] These displacements frequently cause obliquely angled diastemata to form in the interproximal spaces between the normal and displaced teeth, which can be complicated to manage and lead to severe periodontal disease. When the displacements and periodontal disease become severe, extraction is sometimes warranted. However, if diagnosed early, the displaced teeth can be managed by reducing the overgrown portions of the displaced teeth that are not in good occlusal contact, therefore reducing the masticatory forces, which could lead to further displacement, along with management of the diastemata. These cases must be managed closely, with examination and occlusal adjustment every 4 to 6 months. When the teeth are severely displaced and periodontal disease is expected, radiographs should be used to evaluate the viability and angulation of the tooth, and to determine if extraction is appropriate.

- Skull distortions and wry nose (Abbreviation: MAL/4)

Severe cases of wry nose are noticeable even to a casual observer, and often cause greater respiratory problems than dental issues; however, more subtle distortions are less noticeable but may cause wear abnormalities in the teeth. These cases often are noted

Fig. 5. Severe lingual displacement of the Triadan 309 tooth in the mandibular arcade creating large oblique diastemata.

as a "slant" or "shear" occlusion and must be examined carefully to determine the source of the angulation. The incisors are most obviously affected, but more shear confirmation in the cheek teeth may also be found. The focus of any adjustment should be enabling free lateral excursion in these cases. Reduction of overgrowths at the extremes of the incisor arcades may be indicated, but reducing the slant and straightening the occlusion is unnecessary, highly likely to recur, and may compromise pulp.[23]

7. Overview of Occlusal Adjustment

Both manual and motorized instrumentation are acceptable when performing most routine occlusal adjustment, although motorized equipment has undergone great development in the past decade, and a great variety of motorized implements are now available. In general, motorized equipment offers more precision than manual instruments along with a greater ease in reducing overgrowths and less potential for soft tissue trauma when used appropriately. However, motorized instrumentation can be dangerous when used by unskilled operators or without sedation, and the work must be visually observed at all times. Whether manual or motorized instrumentation is being used, the practitioner should have a variety of implements available—either hand rasps of varying lengths, widths, and angles, and/or motorized equipment with a variety of head attachments (e.g., flat disc, apple core, chamfer) to reach all parts of the mouth.

Water cooling of motorized instrumentation has been debated by many practitioners, and while it may not be strictly necessary, it is beneficial. Water cooling prevents thermal damage to the teeth and also reduces dust production. If water cooling is not available, no tooth should be reduced for more than 30 seconds at a time as this will prevent significant internal temperature increases within each tooth.[24] In addition, no tooth should be reduced more than 4 to 5 mm in total in 1 treatment session due to the risk of pulpar exposure. It has been suggested one could also carefully reduce until the beginning loss of the stained secondary dentine is seen on any of the tooth's pulp horns, but by the time a change in color is visible to the operator, the pulp may already be exposed. If further reduction is warranted, the practitioner should return in 4 to 6 months' time and reduce the tooth again.[25,26] If the horse is found to have relatively normal wear and occlusion, annual re-examination and treatment is usually advised. In general, though, more frequent evaluation and less reduction of dental surface in each individual session leads to better outcomes.

8. Abnormalities That Require Further Investigation or Referral

The specific abnormalities discussed below are far from an exhaustive list of all possible equine dental pathologies. In general, a good principle when addressing a more complex dental problem is to perform radiography of the head. Some of these problems may only require monitoring or routine maintenance, while others may necessitate referral or more specialized intervention. References to assist in obtaining quality dental radiographs are available from many sources.[27,28]

- Equine odontoclastic tooth resorption and hypercementosis

Radiographs are used to both definitively diagnose and determine when extraction is necessary in cases of EOTRH. Full-mouth incisor and canine extraction is the recommended treatment in advanced cases of EOTRH. The inflammation and resorption that is visible on clinical examination in advanced cases is often preceded in radiographic changes by several years. Screening incisor radiographs may be performed in horses over 15 years in age so that earlier intervention or closer monitoring may take place if EOTRH is found. Radiographs are definitely recommended in horses with aforementioned signs noticed by owners, or if even subtle pathology is noted on clinical examination.[29]

- Pulp exposure

Pulpar exposure on the occlusal surface is often a consequence of apical infection and death of the tooth as the periodontal tissues are an independent system and continue to function in dental eruption even if the tooth's endodontic system has died (Fig. 6). Secondary dentine is no longer produced to protect and cover the pulp, and as the secondary dentine becomes worn, the pulp horns become exposed to the surrounding environment.[30] The metabolically active hypsodont tooth can allow areas of pulpar exposure or areas of noxious stimuli to the pulp, such as adjacent caries, to be sealed with tertiary dentine in order to limit further pathological changes.[31] Radiographs are recommended in cases with pulpar exposure to determine if the affected tooth can be monitored or should be extracted.

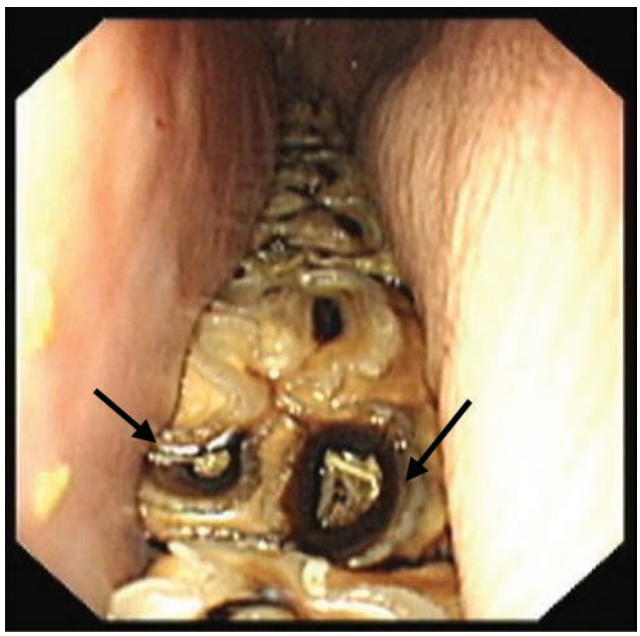

Fig. 6. Oroscopic view of exposure of pulp horns 1 and 3 of the 309 mandibular cheek tooth.

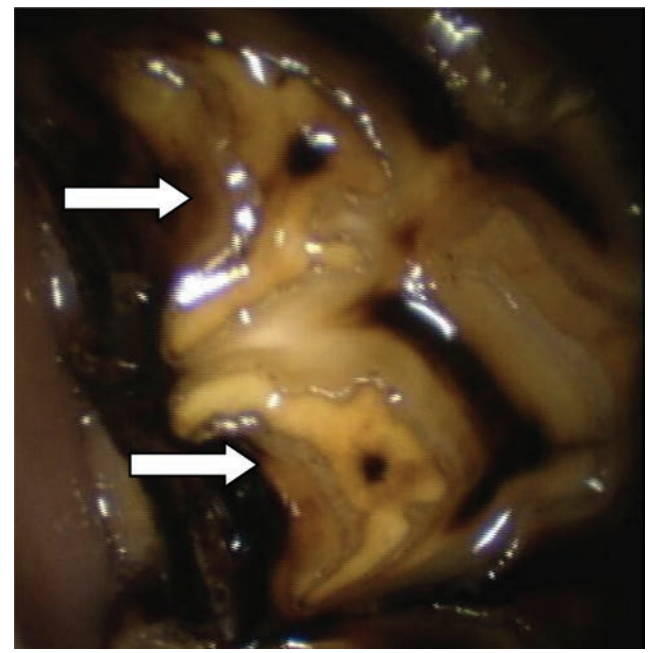

Fig. 7. Oroscopic view of a "slab" or complicated crown fracture through pulp horns 1 and 2 of the 109 maxillary cheek tooth.

- Fractured teeth

Teeth with visible fractures leading to missing portions of the clinical crown should be radiographed any time they are identified, although not all fractured teeth will require extraction. Many cheek teeth with complicated crown fractures (commonly termed "slab" fractures) will form a tertiary dentine bridge and remain stable (Fig. 7). However, radiographs should be obtained, and if the tooth is affected by apical infection or is no longer viable, extraction is recommended. If a tooth is affected by a crown/root fracture, extraction is almost always indicated. Most commonly, the sharp edges created by the tooth fracture cause soft tissue pain, which can be addressed simply by removing the fragments and reducing any sharp edges.[32–34]

- Infundibular caries

Maxillary cheek tooth infundibular caries is one of the most common dental disorders reported in horses with caries and/or hypocementosis found in 65% to 97% of teeth depending on the study.[35,36] Most of these lesions are mild (classified as grade 1), which are unlikely to lead to further sequelae, but grade 2 and grade 3 lesions can lead to severe complications such as midline tooth fracture, apical infection, and secondary sinusitis. If infundibular caries are found on oral examination, they should be probed if possible and radiographed to determine their depth along with the stability and viability of the surrounding tooth structure (Fig. 8). Few affected teeth require outright extraction (prior to fracture), but restoration of the infundibula with flowable composite materials designed for human dentistry may be considered if the horse is of a relatively young age and the caries are of grade 2 or 3 with a depth of >10 mm.[37] Recent long-term follow-up published by Pearce and Brooks[38] has shown infundibular restoration to be safe, durable, and seeming to prevent the development of further pathological changes, including apical infection and dental fracture. Infundibular restoration is a relatively new procedure best performed by specialists and veterinarians with specific training as the morphology of the infundibula is complex and proper preparation of the cavities requires special instrumentation. If restoration is not performed, severely affected teeth should be taken out of occlusion and closely monitored for signs of fracture or apical infection.

- Periodontal disease and diastemata

Periodontal disease in the horse is most often secondary to another pathology, most commonly diastemata in the cheek teeth. These can be either primary (developmental), secondary to cheek tooth displacement, or form as cheek teeth lose their angulation and wear to the apex in senile horses. The soft tissue pain caused by food impaction, gingival ulceration, and ultimately loss of periodontal attachments is significant (Fig. 9)—this is one of the most painful dental diseases in horses.[39] The focus of treatment is mainly to prevent further food impaction while also attempting to address the underlying cause. The periodontal pockets should be mechanically debrided and lavaged to clear any food material fully. They may also be filled with dental impression material or wax when fully cleared of debris. In severe valve-form cases, the spaces can be mechanically widened to allow more free clearance of feed material, but this should only be

Fig. 8. Grade 1 (left), grade 2 (middle, arrow), and grade 3 (right) infundibular caries in maxillary cheek teeth.

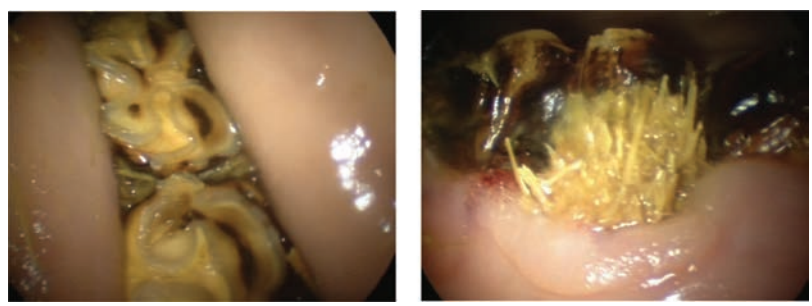

Fig. 9. Oroscopic view of a valve-shaped diastema with impacted feed material occlusally (left) and at the gingival margin (right).

done by experienced practitioners as the risk of pulp exposure is high.[40] It is also very important to reduce any opposing focal overgrowths that could be contributing to poor interproximal contact and food impaction.

9. Conclusion

The breadth and variety of equine dental disorders is large, but the clinical skills of the equine veterinary practitioner enable them to treat the whole horse appropriately. With good understanding of dental anatomy and physiology, good communication skills, and appropriate diagnostics, many common yet significant dental pathologies can be treated by the veterinarian in the field. Appropriate preventative dental practices will preserve the life of the dentition and greatly improve the life of the horse.

Acknowledgments

Declaration of Ethics

The Author has adhered to the Principles of Veterinary Medical Ethics of the AVMA.

Conflict of Interest

The Author has no conflicts of interest.

References and Footnote

1. Bennett D. The evolution of the horse. In: J. W. Evans, ed. *World Animal Science: Horse Breeding and Management*. Amsterdam, The Netherlands: Elsevier Science; 1992: 1–37.
2. Budiansky S. *The Nature of Horses: Their Evolution, Intelligence and Behaviour*. UK: Butler and Tanner, Ltd, Phoenix Illustrated; 1997:21–35.
3. Mitchell SR, Kempson SA, Dixon PM. Structure of peripheral cementum of normal equine cheek teeth. *J Vet Dent* 2003;20:199–208.
4. Butler P. Dentition in function. In: Osborn JW, ed. *Dental Anatomy and Embryology*. Oxford, UK: Blackwell Scientific; 1991:345.
5. Colyer F, Grigson C, Miles AW. *Colyer's Variations and Diseases of the Teeth of Animals*. Cambridge, UK: Cambridge University Press; 1990
6. Dacre IT, Kempson S, Dixon PM. Pathological studies of cheek teeth apical infections in the horse. 1: Normal endodontic anatomy and dentinal structure of equine cheek teeth. *Vet J* 2008;178:311–320.
7. Kopke S, Angrisani N, Staszyk C. The dental cavities of equine cheek teeth: Three-dimensional reconstructions based on high resolution micro-computed tomography. *BMC Vet Res* 2012;8:173–188.
8. Ten Cate AR, Sharpe PT, Roy S. Development of the tooth and its supporting tissues. In: Nanci A, ed. *Ten Cate's Oral Histology: Development, Structure, and Function*. St. Louis, MO: Mosby; 2003:79–110.
9. Du Toit N, Kempson SA, Dixon PM. Donkey dental anatomy. Part 1: Gross and computed axial tomography examinations. *Vet J* 2008;176:338–344.
10. Brown SL, Arkins S, Shaw DJ, et al. Occlusal angles of cheek teeth in normal horses and horses with dental disease. *Vet Rec* 2008;162:807–810.
11. Muylle S, Simoens P, Verbeeck R, et al. Dental wear in horses in relation to the microhardness of enamel and dentine. *Vet Rec* 1999;144:558–561.
12. Kilic S, Dixon PM, Kempson SA. A light microscopic and ultrastructural examination of calcified dental tissues of horses: 2 Ultrastructural enamel findings. *Equine Vet J* 1997;29:198–205.

13. Henry TJ. How to make dental endoscopy part of your routine oral examination, in *Proceedings*. Am Assoc Equine Pract 2017;63:39–45.
14. Dotzel A. How to use an oral mirror and endoscope, in *Proceedings*. Am Assoc Equine Pract 2018;64:25–29.
15. Bonin SJ, Clayton HM, Lanovaz JL, et al. Comparison of mandibular motion in horses chewing hay and pellets. *Equine Vet J* 2007;39:258–262.
16. Dobberstein J, Pallaske G, Stunzi H, Band V, eds. *Handbuch der speziellen pathologischen anatomie der haustiere*. 3rd ed. Berlin, Germany: Verlag Paul Parey; 1962.
17. Dixon PM. The evolution of horses and the evolution of equine dentistry, in *Proceedings*. Am Assoc Equine Pract 2017;63:79–116.
18. Dixon PM, Dacre I. A review of equine dental disorders. *Vet J* 2005;169:165–187.
19. Dixon PM, Tremaine WH, Pickles K, et al. Equine dental disease part 3: A long-term study of 400 cases: Disorders of wear, traumatic damage and idiopathic fractures, tumours and miscellaneous disorders of the cheek teeth. *Equine Vet J* 2000;32:9–18.
20. Marshall R, Shaw DJ, Dixon PM. A study of sub-occlusal secondary dentine thickness in overgrown equine cheek teeth. *Vet J* 2012;193:53–57.
21. Easley J, Dixon PM, Reardon RJ. Orthodontic correction of overjet/overbite ('parrot mouth') in 73 foals (1999–2013). *Equine Vet J* 2016;48:565–572.
22. Dixon PM. Abnormalities of development and eruption. In: Easley KJ, Dixon PM, Schumacher JS, eds. *Equine Dentistry*. 3rd ed. Edinburgh, UK: Elsevier Saunders; 2011:99–114.
23. DeLorey MS. A retrospective evaluation of 204 diagonal incisor malocclusion corrections in the horse. *J Vet Dent* 2007;24:145–149.
24. O'Leary JM, Barnett TP, Parkin TDH, et al. Pulpar temperature changes during mechanical reduction of equine cheek teeth: Comparison of different motorised dental instruments, duration of treatments and use of water cooling. *Equine Vet J* 2013;45:355–360.
25. Kempson SA, Davidson ME, Dacre IT. The effect of three types of rasps on the occlusal surface of equine cheek teeth: A scanning electron microscopic study. *J Vet Dent* 2003;20:19–27.
26. White C, Dixon PM. A study of the thickness of cheek teeth subocclusal secondary dentine in horses of different ages. *Equine Vet J* 2010;42:119–123.
27. Limone LE, Baratt RM. Dental radiography of the horse. *J Vet Dent* 2018;35:37–41.
28. Baratt RM. How to improve the diagnostic quality of your dental radiographs, in *Proceedings*. Am Assoc Equine Pract 2016;62:63–68.
29. Henry TJ, Puchalski SM, Arzi B, et al. Radiographic evaluation in clinical practice of the types and stage of incisor tooth resorption and hypercementosis in horses. *Equine Vet J* 2017;49:486–492.
30. Dixon PM, Du Toit N, Dacre I. Dental pathology. In: Easley J, Dixon PM, Schumacher J, eds. *Equine Dentistry*. Edinburgh, UK: Saunders; 2010:77–84.
31. Dacre IT, Shaw DJ, Dixon PM. Pathological studies of cheek teeth apical infections in the horse: 3. Quantitative measurements of dentine in apically infected cheek teeth. *Vet J* 2008;178:333–340.
32. Van Enden M, Dixon P. Prevalence of occlusal pulpar exposure in 110 equine cheek teeth with apical infections and idiopathic fractures. *Vet J* 2008;178:364–371.
33. Taylor L, Dixon PM. Equine idiopathic cheek teeth fractures: Part 2: A practice-based survey of 147 affected horses in Britain and Ireland. *Equine Vet J* 2007;39:322–326.
34. Dixon PM, Barakzai SZ, Collins NM, et al. Equine idiopathic cheek teeth fractures: Part 3: A hospital-based survey of 68 referred horses (1999-2005). *Equine Vet J* 2007;39:327–332.
35. Windley Z, Weller R, Tremaine WH, et al. Two- and three-dimensional computed tomographic anatomy of the enamel, infundibulae and pulp of 126 equine cheek teeth. Part 2: Findings in teeth with macroscopic occlusal or computed tomographic lesions. *Equine Vet J* 2009;41:441–447.
36. Honma K, Yamakawa M, Yamauchi S, et al. Statistical study on the occurrence of dental caries of domestic animals: 1. Horse. *Jpn J Vet Res* 1962;10:31–36.
37. Pearce CJ, Horbal AA. Infundibular Restorations. In: Easley J, Dixon PM, DuToit N, eds. *Equine Dentistry and Maxillofacial Surgery*. Cambridge, UK: Cambridge Scholars Press; 2022.
38. Pearce CJ, Brooks N. Long-term follow-up of restorations of equine cheek teeth infundibula (2006–2017). *Front Vet Sci* 2022;8: 793631. Available from: https://www.frontiersin.org/article/10.3389/fvets.2021.
39. Dixon PM, Ceen S, Barnett T, et al. A long-term study on the clinical effects of mechanical widening of cheek teeth diastemata for treatment of periodontitis in 202 horses (2008–2011). *Equine Vet J* 2014;46:76–80.
40. Bettiol N, Dixon PM. An anatomical study to evaluate the risk of pulpar exposure during mechanical widening of equine cheek teeth diastemata and 'bit seating'. *Equine Vet J* 2011;43:163–169.

[a]Alumispec MAI Animal Health 605 Pro-Ject Drive, Elmwood, WI 54740.

Subchondral Lucencies of the Medial Femoral Condyle in Yearling and 2-Year-Old Thoroughbred Sales Horses

Frances Peat, BVSc, PhD, DACVSMR*; Chris Kawcak, DVM, PhD, DACVS, DACVSMR; Wayne McIlwraith, BVSc, DSc, FRCVS, DACVSMR; Jeff Berk, VMD, MRCVS; Dave Keenan, BVSc, MANZCVS; and Dan Mork, PhD

The size and location of subchondral lucencies (SCLs) in the medial femoral condyle (MFC) influence their importance in terms of progression and associations with racing performance. Authors' addresses: Matamata Veterinary Services, 362 Hinuera Road, Matamata, 3472 New Zealand (Peat, Keenan); Colorado State University, 300 West Drake Road, Fort Collins, CO 80523 (Kawcak, McIlwraith); Equine Medical Associates, PO Box 11067, Lexington, KY 40512-1067 (Berk); Department of Biostatistics, Harvard T.H. Chan School of Public Health, Boston, MA 02115 (Mork); e-mail: frances@matamatavet.co.nz. *Corresponding and presenting author. © 2022 AAEP.

1. Introduction

Subchondral lucencies (SCLs) in the medial femoral condyle (MFC) of unraced Thoroughbreds have contentious significance on pre-sale radiographs due to concern over progression to larger lesions and potential clinical importance.

2. Materials and Methods

Horses were enrolled at the 2016 Keeneland September Yearling Sale and five 2017 Fasig-Tipton and Ocala Breeders' 2-year-old Sales. A radiological grading system for MFC SCLs was defined, tested for interobserver agreement, and applied to all stifle radiographs. Descriptive statistics were used to evaluate the prevalence and progression of MFC grades in yearling and 2-year-old sales horses. Associations between MFC grade and racing performance from 2 to 4 years of age were analyzed via regression using eight racing performance outcomes.

3. Results

2,508 yearlings and 436 2-year-olds were included. The majority of yearling Grade 1 MFC SCLs resolved or remained static by 2-year-old sales. Fewer sales yearlings with a Grade 3 MFC SCL made it to the races, but those that did raced as well as their unaffected peers. Axial MFC lucencies did not affect racing performance.

Research Abstract—for more information, contact the corresponding author

NOTES

4. Discussion

The results are relevant to yearling and 2-year-old Thoroughbreds presented for sale at public auction and for use by veterinarians when evaluating repository radiographs.

Acknowledgments

Funding Sources

Funding was supplied by the Grayson-Jockey Club Research Foundation, Keeneland Association, Ltd., Fasig-Tipton, Ltd., and significant donations from private individuals.

Declaration of Ethics

The Authors have adhered to the Principles of Veterinary Medical Ethics of the AVMA.

Conflict of Interest

The Authors have no conflicts of interest.

Radiological Findings in the Proximal Sesamoid Bones of Yearling and 2-Year-Old Thoroughbred Sales Horses

Frances Peat, BVSc, PhD, DACVSMR*; Chris Kawcak, DVM, PhD, DACVS, DACVSMR; Wayne McIlwraith, BVSc, DSc, FRCVS, DACVSMR; Jeff Berk, VMD, MRCVS; Dave Keenan, BVSc, MANZCVS; and Dan Mork, PhD

Many radiological findings in the proximal sesamoid bones (sesamoids) have contentious significance. Grade 3 vascular channels, abaxial bone formation, and sesamoid fragments are important.
Authors' addresses: Matamata Veterinary Services, 362 Hinuera Road, Matamata, 3472 New Zealand (Peat, Keenan); Colorado State University, 300 West Drake Road, Fort Collins, CO 80523 (Kawcak, McIlwraith); Equine Medical Associates, PO Box 11067, Lexington, KY 40512–1067 (Berk); Department of Biostatistics, Harvard T.H. Chan School of Public Health, Boston, MA 02115 (Mork); e-mail: frances@matamatavet.co.nz. *Corresponding and presenting author. © 2022 AAEP.

1. Introduction

Radiological findings in the sesamoids are a persistent source of controversy at Thoroughbred sales due to inconsistent classification and conflicting assignment of potential clinical importance.

2. Materials and Methods

Horses were enrolled at the 2016 Keeneland September Yearling Sale and five 2017 Fasig-Tipton and Ocala Breeders' 2-year-old sales. Radiological sesamoid findings and their change in appearance between sales were examined. Associations with racing performance from 2 to 4 years of age were analyzed.

3. Results

Horses included 2508 yearlings and 436 2-year-olds. Interobserver agreement using the new grading system was substantial. Yearling findings associated with a significantly reduced likelihood of starting a race were Grade 3 vascular channels in forelimb sesamoids, abaxial new bone in forelimb sesamoids, and apical or abaxial fragments in forelimb sesamoids. For affected horses that did race, Grade 3 vascular channels in forelimb sesamoids were associated with fewer race starts, Grade 3 vascular channels in hindlimb sesamoids were associated with a delayed start to racing careers, and abaxial new bone in forelimb sesamoids was associated with lower total earnings and earnings per start.

4. Discussion

The findings are applicable for use by veterinarians when evaluating repository radiographs, and the results refine the appropriate use of the term sesamoiditis.

Research Abstract—for more information, contact the corresponding author

NOTES

Acknowledgments

Funding Sources

Funding was supplied by the Grayson-Jockey Club Research Foundation, Keeneland Association, Ltd., Fasig-Tipton, Ltd., and significant donations from private individuals.

Declaration of Ethics

The Authors have adhered to the Principles of Veterinary Medical Ethics of the AVMA.

Conflict of Interest

The Authors have no conflicts of interest.

How to Evaluate and Balance the Distal Limb Using Specific Anatomical and Radiographic Parameters

Mariah D. Kerr, DVM*; and Pete Healey, AFP-1

A comprehensive evaluation/trimming/shoeing system can produce successful results in improving the balance and function of the distal limb. Using specific measuring parameters could increase communication between veterinarians, farriers, and horse owners in the management of the equine foot.
Authors' address: Alamo Pintado Equine Medical Center, 2501 Santa Barbara Avenue, Los Olivos, CA 93441; e-mail: mariah@alamopintado.com. *Corresponding and presenting author. © 2022 AAEP.

1. Introduction

Currently, there is not a specialty for podiatry in equine medicine. This could be in part because there is not a universal method to assess foot conformation and balance or a uniform method for trimming or shoeing the equine foot.[1,2] Although guidelines have been published,[1] there are no biomechanical studies defining precise measurements that should be adhered to when addressing foot balance.[3] Equine distal limb lameness is commonly associated with a faulty and imbalanced foot conformation,[4] and hoof-related lameness is a key cause of poor performance, lameness, and early retirement in the sport and pleasure horse.[5] Foot balance encompasses assessment in the dorsopalmar, lateromedial, and craniocaudal planes as well as the ventral depth of the hoof.[6,7] Not one aspect of balance is an entity of its own as they are all integrated by limb conformation, ground reaction forces, and the muscle-tendon unit of the deep digital flexor tendon and how they act around the center of rotation in the condyle of the second phalanx. This paper presents a method using specific anatomical dimensions and measurements that can be used to evaluate and define lack of hoof mass or excess hoof mass or distortions. This information can be visualized on the foot from a radiograph or from the foot to the radiograph. This information can then be applied in a measurable trimming/shoeing procedure to achieve improved balance in the distal limb.

2. Materials and Methods

The front feet from 10 horses were randomly selected for farrier service. These horses were of mixed breeds, ages, and riding disciplines. These feet represent a range of conditions normally seen by a veterinarian or farrier in routine practice scenarios. The abnormal hoof conditions include low ventral depth, long toe-low heel, long toe-high heel, club foot, and mild chronic laminitis. Two horses presented 1 foot with chronic laminitis that were omitted from this study because of soft tissue distortions that were beyond the scope of this paper. This created a database of 18 feet. Some of these horses presented with

NOTES

foot-related lameness issues. Shoeing was performed by one author (PH). To test the validity of the physical evaluation/shoeing procedure, this author was blinded to the preshoeing radiographs.

Radiographic Method

Dorsopalmar and mediolateral radiographs were obtained on each foot, pre- and postshoeing, at 1 clinic. These radiographs were acquired by the attending veterinarian using standard techniques (68–70 kVp, 0.05 mAs) with a portable x-ray generator and a digital radiography system. The feet were radiographed on flat wooden blocks incorporating a metal ground line. The x-ray generator was placed on the ground, whereas the horizonal beam was directed ±25 mm over the block. For the mediolateral view, a barium paste marker[a] was placed on the dorsal wall from the junction of the coronet band and hair line to the distal aspect of the toe. Radiographs were transferred in DICOM format to a PACS system.[b] Radiographs were retrieved using a DICOM viewer[c] to measure soft tissue and break-over distances. To increase efficiency, the radiographs were printed out and the angle measurements were done with a protractor. All measuring was done by one author.

Physical Evaluation of the Foot

After the shoes are removed or on the bare foot, the solar surface of the hoof is evaluated about the center of rotation–third phalanx line of action (COR-P3 LOA). This is a point just distal to the central frog sulcus at the first bend of the bars (Fig. 1). The physiology of the COR-P3 LOA is beyond the scope of this paper, but its relevance is important as it appears that hoof growth and compression occur about this point. This is clearly visible when evaluating the solar surface of the hoof, and unpublished data of venograms show lack of perfusion along this line (Fig. 2). The COR-P3 LOA bisects the dorsal and palmar planes of the hoof. When reversed, the distance from the COR-P3 LOA to the palmar extent of the central frog sulcus at the heel bulb will estimate the solar margin of P3.[8] Hoof capsule extending 20 mm beyond this point may be considered distorted as normal hoof–lamella width has been recorded as 15 to 20 mm.[9]

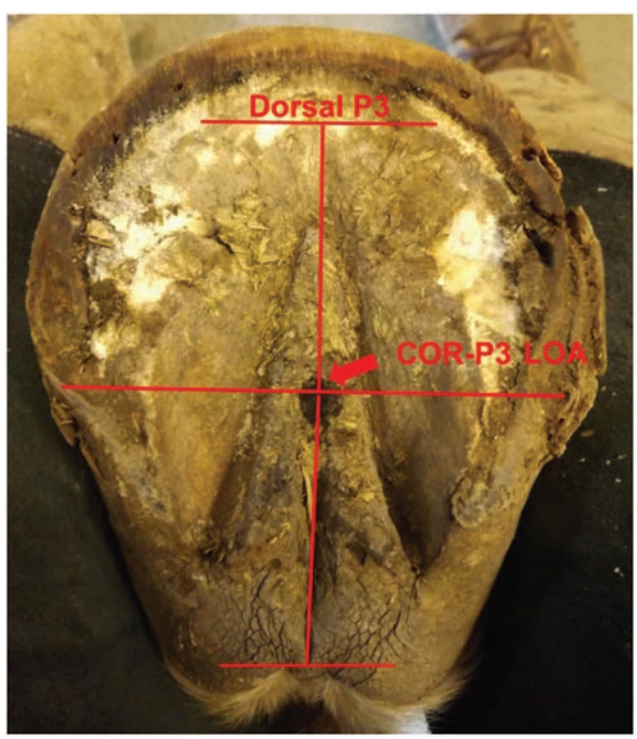

Fig. 1. The COR-P3 LOA exits the hoof just distal to the central frog sulcus. The palmar extent of the central frog sulcus is an equal distance to the dorsal extent of P3 from the COR-P3 LOA.

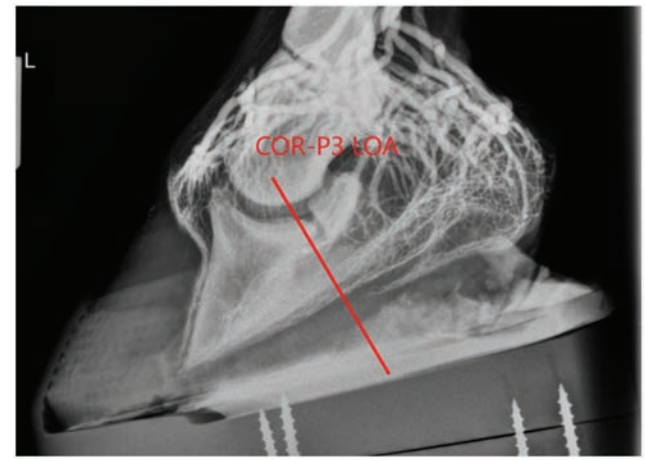

Fig. 2. A venogram of a laminitis case demonstrates lack of perfusion dorsal to COR-P3 LOA.

The Frog

The ventral plane of the frog can give an estimate as to the ventral plane of P3. The angle of the central frog sulcus can give an estimate of the palmar angle of P3 when evaluated to the hoof plane and its relationship to the ventral plane of the frog.[10] Hoof wall and sole dorsal to the COR-P3 LOA that is growing in a lower angle plane than the ventral plane of the frog can create a mechanical wedge to the foot, which shifts weight to the low side of the hoof.[11] Probing the depth of the apex of the frog and sole can be used to estimate sole depth at the apex of P3 (Fig. 3).[12] Healthy feet on a light breed horse should have a minimum sole depth of 15 to 18 mm.[13] The length of the frog from its apex to its widest part can be used as a guide for dorsal wall length during trimming or as a guideline for adequate hoof.[14] The digital cushion/frog (DCF) can be palpated or measured with a set of calipers for depth. Normal variations in DCF depths have been estimated to be between 50 and 70 mm.[15] Healthy heels should extend to the ground surface depth of the frog as described above.

Evaluating the Mediolateral and Palmarodorsal Planes of the Hoof

The mediolateral (ML) and palmarodorsal (PD) planes on the solar surface of the hoof can be

Fig. 3. Estimating sole depth ventral to the solar margin of P3 by probing the frog sulcus at the apex of the frog.

visualized using a "T" square fitted with a tendon stay. To use the T square, hold the leg in the normal shoeing position, allowing the pastern to hang free. The long arm of the "T" with the tendon stay is positioned mid-cannon over the tendon bundle as the short arm of the "T" is slid up to the solar surface of the hoof to the heels (Fig. 4). Evaluation of the mediolateral balance of the foot is made here, noting the length or lack of hoof to the ventral plane of the frog. The palmarodorsal balance is evaluated in two planes from the COR-P3 LOA. With the foot flexed toward the "T," the short arm of the T square is slid dorsally to the point of the COR-P3 LOA. From this view, the direction of break-over at the toe and excess hoof above the horizonal plane of the "T" can be visualized. In the mediolateral plane, the foot is balanced to the "T" when the solar surface of the hoof stays level to the "T" as the foot is flexed toward it from heel to toe. In the palmarodorsal plane, the hoof is balanced when both the palmar and dorsal planes are level to the "T" with the dorsal plane slightly lower creating a cranial radius.

Evaluating the Craniocaudal Balance of the Foot

The craniocaudal balance of the foot can be evaluated by measuring the hoof-pastern axis (HPA) of that leg with a goniometer.[d] To measure: Posture the leg with

Fig. 4. T square to view the ventral plane of the hoof to the ventral plane of the frog.

the cannon bone at 90° to the ground with the pastern extended in the weight-bearing position by lifting the opposite leg. Place the goniometer on the dorsal crest of the hoof with 1 arm extending distally from the coronet band and the other arm extending proximally from the coronet in a parallel line to the dorsal aspect of P1. The goniometer is expressed in degrees and the optimum reading would be a 0° axis. Although the HPA is beyond the scope of this paper, the reason for the procedure described is that it simulates the early weight-bearing phase of the stride, whereas a balanced distal limb is set up for a cranial rotation of P3 before full weight-bearing of the leg. The HPA has a direct relationship to the palmar angle (PA) of P3; a 2° PA increase will extend the HPA 5°.[16]

Trimming and Shoeing Method

1. After evaluation of the foot as described above, any excess hoof wall in the dorsal or palmar planes about the COR-P3 LOA of the hoof is removed. If any areas in the palmar or dorsal planes of the hoof lack sufficient depth, this area of the hoof is built up with an acrylic polymer[e] (Fig. 5); in some cases, this may be the entire perimeter of the hoof.
2. The hoof is assessed with a "T" square as described and evaluated for ML and PD balance to the COR-P3 LOA. The hoof is trimmed in 2 planes to the COR-P3 LOA. First the toe is rockered back to the COR-P3 LOA and then the heels are leveled palmar to the COR-P3 LOA parallel to the angle of the central frog sulcus. The hoof is viscoelastic[17] and can decompress and become unlevel through the solar plane during the trimming process; this may require several evaluations with the "T" square for ML and PD adjustments. Consideration to the ventral depth of the foot is maintained through the trimming process. The radius of the 2-plane trim may allow some PA adjustment as the

Fig. 5. Using an acrylic polymer as a prosthesis to build an artificial heel.

Fig. 6. Acrylic, rockered wedged aluminum shoe and a wedge pad is used to balance the PA of a foot by using a 0° HPA axis in the weighted position as a guide.

deep flexor tendon-muscle unit can cranially rotate the foot about the COR-P3 LOA.

3. After the foot is trimmed or reconstructed as needed, the HPA is evaluated with the goniometer. The goniometer allows an easy and efficient way to monitor the HPA on the "shoeing floor." If the weighted HPA is a negative (broken-back) angle, each 5° increment will require a 2° adjustment to the shoe or shoe package. If the foot measures positive (broken-forward), the foot is not corrected to a 0° HPA as this could add tension to the flexor tendon-muscle unit.
4. Rocker mechanics are employed in each shoe. The ground surface of the shoe on the leading edge is beveled with a hammer and the foot surface is rockered into a cranial radius as dictated by the 2-plane trim. The goal is to place the mechanics of break-over halfway between COR and the line of action of the apex of P3. This is about the widest part of the foot and often referred to as the center of pressure (COP).[5] On a foot that needs a degree increase, an aluminum degree shoe can be used by itself or with degree pads. Degree pads up to 3° can usually be added to a steel shoe without adding too much weight to the foot. The decision to use an aluminum or steel shoe depends on the quality of the hoof and the weight of the shoe-pad package. The specific degree increase is determined by calculating the amount of correction needed as indicated by measuring the HPA with the goniometer (Fig. 6).

Radiographic Measurements and Calculations (Fig. 7)

1. Coronary Band–Extensor Process Distance (CE): The vertical distance between the proximal limit of the dorsal wall marker and the proximal limit of the extensor process.
2. Extensor Process–Condyle (EC): The proximal limit of the extensor process to the proximal limit of the condyle of the second phalanx. The distance between the CE and the EC (CE-EC) is noted as a palmar displacement of P3.
3. Palmar Cortex (PC): The distance from the apex of P3 to the articulation of P3 with the navicular bone. Twenty-five percent of this distance is used as a gauge for equilibrium in the HL, SD, and the HDW measurements.
4. Hoof–Lamella Zones (HL): The perpendicular distance between the dorsal surface of P3 and the dorsal crest of the hoof as measured to the inside of the dorsal wall marker. The HL is measured in 2 places: proximally just below the extensor process and distally near the tip of P3.

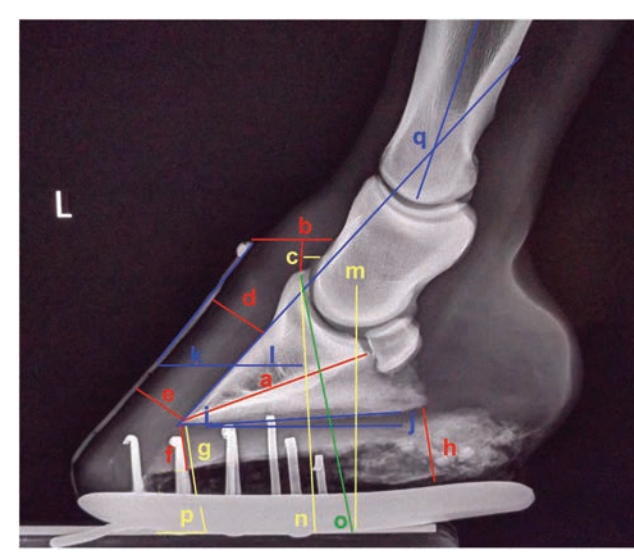

Fig. 7. Radiograph measurements: CE (b); EC (c); PC (a); HL (d, e); SD (f); SDG (g); HDW (h); BA (i); DBA (l); HA (k); PA (j); BO (p); LOAT (n); LOAT-COR (o).

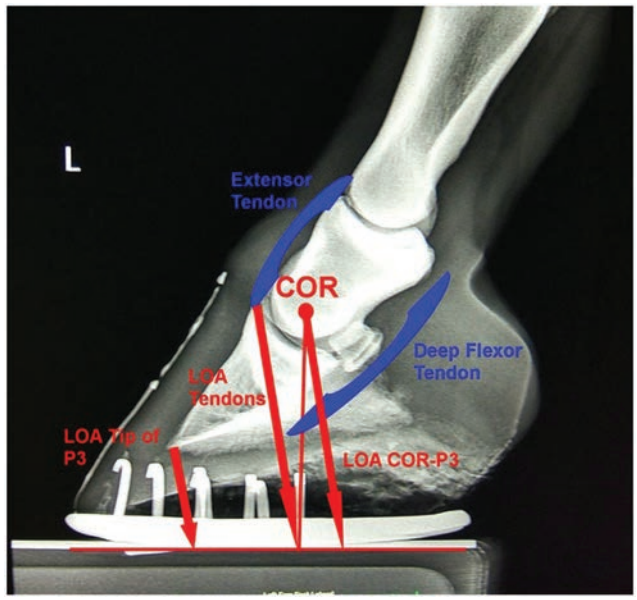

Fig. 8. Lines of action within the foot. The line of action of the tendons sets up parallel lines of action at the apex of P3 and from COR through the palmar plane of P3.

5. Sole Depth (SD): The perpendicular distance from the solar margin of the apex of P3 to the radiolucent border of the sole.
6. Sole Depth Ground (SDG): The perpendicular distance from the solar margin of the apex of P3 to the solar surface of the radiograph block or the shoe.
7. Heel Depth Wing (HDW): The distance from the ventral surface of the palmar aspect of the wing of P3 to the ground surface of the hoof.
8. Bone Angle (BA): The angle made by the dorsal and ventral surfaces of P3.
9. Dorsal Bone Angle (DBA): The angle made by the dorsal surface of P3 and the ground surface.
10. Hoof Angle (HA): The angle made by the proximal dorsal hoof wall and the ground surface.
11. Hoof Angle–Dorsal Bone Angle (HA-DBA): The angle difference between the HA and the DBA.
12. Palmar Angle (PA): The angle made by the palmar surface of P3 to the ground surface.
13. Break-Over (BO): The distance from a vertical line drawn at the tip of P3 and 90° to the ventral plane of P3 to the most dorsal aspect of the hoof or shoe that contacts the ground.
14. Line of Action of the Tendons–Center of Rotation (LOAT-COR): The angle between a line 90° from the extensor process through the palmar plane of P3 to the ground surface and a line 90° from the center of the condyle of P2 to the ground surface.
15. Coffin Joint Tilt (CJT): The angle of the distal condyle of P2 to the ground surface as viewed on the dorsopalmar radiograph.

Parameters of a Radiographically Balanced Foot

A well-balanced foot as viewed on a lateral and dorsopalmar radiograph may include these findings:

1. The proximal extent of the dorsal hoof wall as defined by the marker is level with the proximal extent of the condyle of P2.
2. The HL zones are 25% of the PC measurement.[18,19]
3. SD on a light breed horse should have a minimum of 15 to 18 mm.[13] Sole depth is deemed adequate when it approximates a healthy HL distance.[15]
4. An appropriate HD measurement should be equal to a healthy SD measurement plus what additional hoof mass is necessary to provide adequate PA for that foot.
5. The BA plus the PA equals the DBA, which is the same angle as the HA. The PA can be from 2° to 10° in a sound horse.[20]
6. BO of the hoof or shoe is in the line of action of the apex of P3.
7. The angle difference between the LOAT and COR is at 0° (Fig. 8). When the LOAT is divergent from COR, a moment arm is created about that joint.[21]

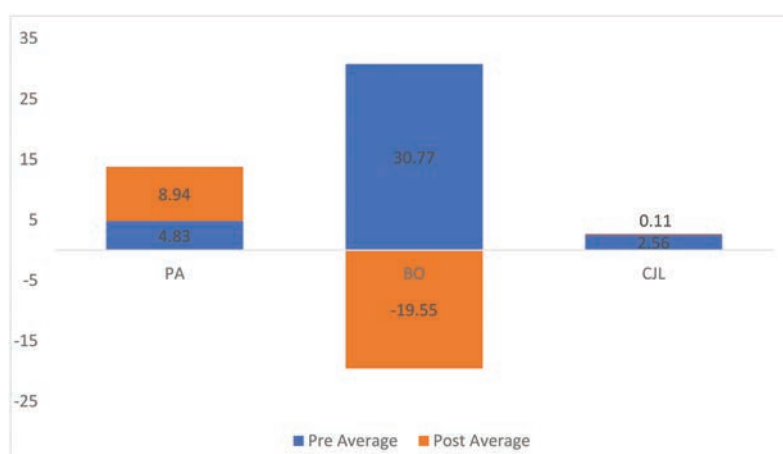

Fig. 9. Overview of pre- and postaverages of the palmar angle, breakover, and coffin joint tilt.

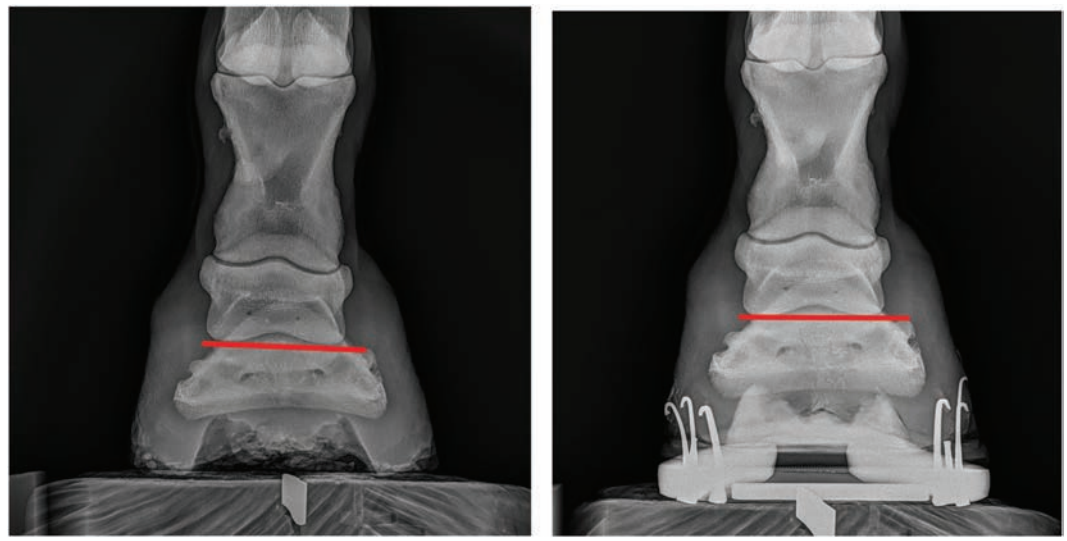

Fig. 10. Pre- and post-DP radiographs of the CJT.

3. Results

The preshoeing radiograph data show that the CE-EC distance ranged from 0 mm to 15 mm, with a mean (SD) of 3.33 (4.34) mm, and 7 of the 18 feet (39%) had a 0-mm distance. Postshoeing, the CE-EC reduced to mean (SD) of 1.38 (3.35) mm, and 15 of the 18 feet (83%) had a 0-mm distance. Preshoeing, the mean (SD) proximal HL distance was 17.94 (1.84) mm, with a mean 1.08 mm greater than 25% PC (16.86 mm, SD 1.23). Postshoeing, the mean (SD) proximal HL was 17.22 (1.43) mm, with a mean .53 mm greater than 25% PC (16.69 mm, SD 1.11); this is a mean reduction of .55 mm. The preshoeing BO distance ranged from 6 mm to 51 mm, with a mean (SD) of 30.77 (13.27) mm. Postshoeing, the BO distance ranged from –11 mm to –25 mm, with a mean (SD) of –19.55 (3.96). These data suggest that the reduction of the BO leverage has a significant effect on the dorsal proximal placement of P3 and laminar leverage.

Fig. 11. How to use a goniometer to evaluate the HPA.

Preshoeing, SD at the apex of P3 was a mean (SD) of 18.38 (7.22). Post-trimming and shoeing, SD was a mean (SD) of 15.77 (5.96) (25% PC 16.69), with .92 mm within target. Preshoeing, SDW was a mean (SD) of 25.83 (5.96) mm. Postshoeing, SDW was a mean (SD) of 24.72 (6.87) mm. Preshoeing, PA was a mean (SD) of 4.83° (5.91°). Postshoeing, the PA was a mean (SD) of 8.94° (4.30°). PA increase was a mean (SD) of 4.16° (3.5°). The PA increase changed the LOAT-COR angle from a mean (SD) of 9.44° (4.83°) preshoeing to 1.83° (2.41°) postshoeing. Postshoeing, 12 of the 18 feet (63%) had a 0° LOAT-COR angle. Eight of the 18 feet had a DBA that was negative to the HA, with a mean (SD) of 4.5° (1.93°). Being able to have known this angle difference, this angle would have been subtracted from the goniometer reading during shoeing and then added to the adjustment of the foot or shoeing package. This may have increased the accuracy of the PA adjustment in 3 of the 8 feet that were DBA-HA negative. This could have increased the 0° LOAT-COR feet from 12 to 15 (83%). The pre- and postaverages of the 18 horses are highlighted in Figure 9. Preshoeing, 16 of the 18 feet measured a CJT between 1° and 5°, with a mean (SD) of 2.55° (1.42°). Postshoeing, 17 of the 18 feet measured a CJT of 0°, and 1 foot measured a CJT of 2°, with a mean (SD) of .11° (.46°).

4. Discussion

Current balance methods promote equal weight-bearing about COR.[22] The COR-P3 LOA is a new concept that incorporates the biomechanics of the foot rather than just a static view of the foot through COR. The COR-P3 LOA divides the foot into 2 planes about the coffin joint. From the COR-P3 LOA, the solar surface of the hoof can be evaluated for ventral depth and mediolateral and

palmarodorsal balance. Using a T square proved beneficial in both the mediolateral and palmarodorsal planes of the hoof as the "T" provides a sight line of the heels to the ventral plane of the frog and from the palmar aspect of the heels to the COR-P3 LOA and then from the COR-P3 LOA through the dorsal aspect of the hoof. This appears to be more accurate than simply sighting the solar plane of the hoof without a visual reference;[23] evidence of this was reflected in the CJT data (Fig. 10). Because of the viscoelastic nature of the hoof, it often deforms through the COR-P3 LOA, which requires several evaluations with the T square and adjustments with a rasp during trimming. The length of the frog as a guide for dorsal wall length is effective for retaining adequate sole depth under the apex of P3. Postshoeing radiographs had an average SD within 1 mm of optimum depth. Postshoeing radiographs also show that the parameters described above for the ventral depth of the DCF were adequate for the hoof palmar to the COR-P3 LOA.

The HPA has a direct connection to the PA, which positions the LOAT-COR. Rather than just a visual assessment, measuring the HPA with a goniometer can increase the accuracy for management decisions and shoeing prescriptions (Fig. 11). The DBA-HA angle from the LM radiograph can be added to the HPA measurement for further accuracy. The rocker trim and shoe add "mechanics" to the foot. This allows the DDFT to rotate the foot about the DIP joint without excessive ground reaction forces (GRF). The mechanics of the rocker shoe moves the break-over radius palmar to the apex of P3, reducing GRF on the dorsal foot while still supporting the dorsal hoof wall. Previous literature has placed optimal break-over at 6 mm dorsal to the apex of P3.[24] Break-over leverage dorsal to the apex of P3 can cause proximal dorsal distortion of the dorsal hoof,[15] with maximum values close to the coronary band.[25] Evidence of this was recorded as a reduction in the CE-EC distance and proximal HL zone postshoeing using "rocker" mechanics. Although further investigation is needed, this is believed to be significant as it may relate to the perfusion and integrity of the dorsal coronary, laminar, and solar plexuses. The use of wedges with a flat shoe can further weaken the heels in a foot with a low palmar angle.[26] A properly placed rocker shoe may mitigate heel compression as it relieves the GRF palmar to the COR-P3 LOA.[27]

A comprehensive evaluation/trimming/shoeing system can produce successful results in improving the balance and function of the distal limb. The goals of the system can be verified radiographically. Using specific anatomical lengths and measures for the palmarodorsal, mediolateral, and craniocaudal planes and the ventral depth of the foot can increase communication between veterinarians, farriers, and horse owners for management of the equine foot.

Acknowledgments

Funding Source

Radiographic studies were funded by Mrs. Susan Cheney through the Equine Podiatry Education Foundation.

Declaration of Ethics

The Authors have adhered to the Principles of Veterinary Medical Ethics of the AVMA.

Conflict of Interest

Mr. Pete Healey is owner of Healing Enterprises LLC and is president of Equine Podiatry Education Foundation. Dr. Mariah Kerr has no conflicts of interest.

References and Footnotes

1. O'Grady SE. Guidelines for trimming the equine foot: A review, in *Proceedings*. Am Assoc Equine Pract 2009;55: 218–225.
2. Parks A. Form and function of the equine digit. *Vet Clin Equine* 2003;19:285–307.
3. Hunt RJ. Farriery for the hoof with low or underrun heels. *Vet Clin North Am Equine Pract* 2012;28:351–364.
4. Dyson SJ, Tranquille CA, Collins SN, et al. An investigation of the relationships between angles and shapes of the hoof capsule and the distal phalanx. *Equine Vet J* 2011;43:295–301.
5. Moleman M, Van Heel MCV, van Weeren PR, et al. Hoof growth between two shoeing sessions leads to a substantial increase of the moment about the distal, but not the proximal, interphalangeal joint. *Equine Vet J* 2006;38:170–174.
6. Butler D. Geometric or structural foot balance. In: Butler DS, Butler J, eds. *The Principles of Horseshoeing (P3)*. La Porte, CO: Doug Butler Enterprises; 2004:71–101.
7. Parks AH. Foot balance, conformation and lameness. In: Ross MW, Dyson SJ, eds. *Diagnosis and Management of Lameness in the Horse*. St Louis, MO: Saunders Elsevier; 2003:250–261.
8. Healey P. Pinpointing P3 during the shoeing cycle. *Am Farriers J*. April 2006;29–33.
9. Redden RF. Radiograph views of most value to farriers. *Equine Podiatry* 2007;11:1999–1202.
10. Redden RF. Shoeing the laminitic horse. In: Redden RF, ed. *Understanding Laminitis, The Blood Horse*. Lexington, KY: 1998:60–79.
11. Colles C, Ware R. Foot balance, and gait. In: Diggle M, ed. *The Principles of Farriery*. London, UK: J. A. Allen; 2010:146–172.
12. Ramey P. Evaluating and trimming the sole. In: Ramey D, ed. *Care and Rehabilitation of the Equine Foot*. Lakemont, GA: Hoof Rehabilitation Publishing; 2011:284–300.
13. Redden RF. The use of venograms as a diagnostic tool. In: *Proceedings 7th Bluegrass Laminitis Symposium*. 1993;7: 1–6.
14. Kane AJ, Stover SM, Gardner IA, et al. Hoof size, shape, and balance as possible risk factors for catastrophic musculoskeletal injury of Thoroughbred racehorses. *Am J Vet Res* 1998;59:1545–1552.
15. Redden RF. Hoof capsule distortion: Understanding the mechanisms as a basis for rational management. *Vet Clin North Am Pract* 2003;19:443–462.
16. Healey P. Measurement of the hoof-pastern axis. *Am Farriers J* December 2016:50–55.
17. Curtis S. Anatomy, physiology and function of the hoof. In: Curtis S, ed. *The Hoof of the Horse*. Suffolk, UK: Newmarket Farrier Consultancy; 2018:8–28.

18. Pollitt C. The horse's foot. In: Pollitt C, ed. *Equine Laminitis*. Canberra, Australia: RIRCC Publication; 2001:4–14.
19. Mullard J, Ireland J, Dyson S. Radiographic assessment of the ratio of the hoof wall distal phalanx distance to palmar length of the distal phalanx in 415 front feet of 279 horses. *Equine Vet Educ* 2020;32:2–10.
20. van Heel MC, Barneveld A, van Weeren PR, et al. Dynamic pressure measurements for the detailed study of hoof balance: The effect of trimming. *Equine Vet J* 2004;36: 778–782.
21. Wilson A, Weller R. The biomechanics of the equine limb and its effect on lameness. In: Ross MW, Dyson SJ, eds. *Diagnosis and Management of Lameness*. St Louis, MO: Saunders Elsevier; 2011:270–281.
22. Colles C. Interpreting radiographs 1. The foot. *Equine Vet J* 1983;15:297–303.
23. Curtis S. The principles of foot balance. In: Curtis S, ed. *Corrective Farriery, a Textbook of Remedial Horseshoeing*. Vol. 1. Suffolk, UK: Newmarket Farrier Consultancy; 2002:105–130.
24. Ovnicek G, Page B, Trotter G. Natural balance trimming and shoeing: Its theory and application. *Vet Clin Equine* 2003;19: 353–377.
25. Hinterhofer C, Stanek C, Haider H. The effect of flat horseshoes, raised heels and lowered heels on the biomechanics of the equine hoof assessed by finite element analysis (FEA). *J Vet Med Series A* 2000;47:73–82.
26. Floyd AE. Use of a grading system to facilitate treatment and prognosis in horses with negative palmar angle syndrome (heel collapse): 107 cases. *J Equine Vet Sci* 2010;30:666–675.
27. Morrison S. Foot management. *Clin Techn Equine Pract* 2004;3:71–82.

[a]E-Z Paste, E-Z-EM Canada Inc. Monroe Township, NJ 08831.
[b]Impax 6.4.0, Agfa Healthcare, Mississauga, ON, Canada.
[c]OsiriX imaging software, Geneva, Switzerland.
[d]Balanced Break-over Management, Healey Enterprises, LLC, Los Olivos, CA 93441.
[e]Farriers Choice Fast Set, Castle Plastics, Leominster, MA 01453.

Evaluation of the Suspensory Ligament in Quarter Horses Used for Cutting

Hayley M. Sullivan, DVM, MS*; Myra F. Barrett, DVM, MS, DACVR, DACVR-EDI; Tianjian Zhou, PhD; and Chris Kawcak, DVM, PhD, DACVS, DACVSMR

After commencing training, cutting horses have induced ultrasonographic suspensory ligament (SL) morphology change that does not impact lifetime earnings ($LTE). Forelimb and osseous attachment abnormalities are more prevalent than hindlimb and ligament abnormalities. Authors' address: Colorado State University, 300 West Drake Road, Fort Collins, CO 890523; e-mail: thegallopingvet@gmail.com. *Corresponding and presenting author. © 2022 AAEP.

1. Introduction

Needs exist for characterization of normal ultrasonographic proximal SL (PSL) cross-sectional area (CSA) in specific breeds/disciplines, characterization of subtle PSL changes, and understanding SL morphology change from work-related stress. The objectives of this study were to establish normal-angle contrast ultrasonographic PSL CSA in cutting horses, monitor SL morphology change with training, and assess PSL diseases' impact on $LTE. It was hypothesized that in cutting horses, SL morphology change occurs, and this impacts $LTE.

2. Materials and Methods

Prospectively, ultrasonographic examination of all limbs in 110 two-year-old cutting horses was performed and repeated two years later. An equine radiologist graded entire examinations and CSA measurements at select locations were compared over time. Individual's National Cutting Horse Association $LTE were analyzed by PSL abnormality number, location, and development over time.

3. Results

In total, 267 examinations were evaluated. Forelimb and hindlimb normal CSA by zone were established. The prevalence of abnormal limbs increased between time points, forelimb abnormalities were more prevalent than hindlimb abnormalities, and osseous attachment abnormalities were more prevalent than ligament abnormalities. No differences were seen in CSA changes over time and impact on $LTE.

4. Discussion

This study establishes normal PSL CSA in cutting horses using angle contrast ultrasonography, provides information on the response of the SL to training, and allows better ultrasonographic characterization of PSL lesions.

Research Abstract—for more information, contact the corresponding author

NOTES

Acknowledgments

The Authors would like to thank Drs. Gustavo Zanotto, Sherry Johnson, Erin Contino, Jodie Daglish, and Phil Manchon, as well as the staff of Equine Sports Medicine and Surgery and Weatherford Equine for their contributions to the collection of data.

Funding Sources

The Authors thank the American Quarter Horse Association, as well as funding by Jon and Abby Winkelried to the Colorado State University Equine Orthopaedic Research Center for funding this project.

Declaration of Ethics

The Authors have adhered to the Principles of Veterinary Medical Ethics of the AVMA.

Conflict of Interest

The Authors have no conflicts of interest.

Ultrasonographic Comparison of the Intermediate Patellar Ligament in Warmbloods Versus Quarter Horses

Joanna Cannon, DVM*; and Katherine L. Ellis, DVM, MS, DACVSMR

There are no significant differences between striation characteristics in Warmbloods versus Quarter Horses. Regardless of breed, striation pattern was bilaterally symmetric in two-thirds of horses but was asymmetric in one-third of horses. Authors' address: University of Georgia, 2200 College Station Road, Athens, GA 30602; e-mail: joanna.cannon@uga.edu. *Corresponding and presenting author. © 2022 AAEP.

1. Introduction

Striations are present on ultrasonography of the intermediate patellar ligament, which can be confused with tears. Comparison to the contralateral limb is often performed to help differentiate anatomic variation from pathologic change. The purposes of this study were to describe the striation patterns in Warmbloods and Quarter Horses, determine if these patterns are bilaterally symmetric, and compare striation characteristics between Warmbloods and Quarter Horses.

2. Materials and Methods

The intermediate patellar ligaments of six Warmblood horses and six Quarter Horses, free from substantial hindlimb lameness and in full work, were examined ultrasonographically. Striation pattern, striation number, and the cross-section areas were compared between Warmbloods and Quarter Horses. Striation pattern was also recorded and compared to the left and right limb of each horse.

3. Results

There were no significant breed differences, and a parallel pattern was the most common pattern type. Two thirds of the horses in this study had bilaterally symmetric patterns within the distal aspect of their intermediate patellar ligaments, while one-third of the population were asymmetric.

4. Discussion

These results show that comparison to the contralateral limb during ultrasonography to determine if changes within the intermediate patellar ligament are normal striations versus tears may lead to misdiagnosis in one-third of horses, regardless of breed. Other signs of pathology on ultrasonography should be used instead.

Research Abstract—for more information, contact the corresponding author

NOTES

Acknowledgments

Declaration of Ethics

The Authors have adhered to the Principles of Veterinary Medical Ethics of the AVMA.

Conflict of Interest

The Authors have no conflicts of interest.

The Accuracy of Ultrasound to Detect Changes in Cervical Facet Joint Effusion—A Cadaveric Study

Lauren A. Scott; Kurt T. Selberg, DVM, MS, DACVR; and Kathryn A. Seabaugh, DVM, DACVS, DACVSMR*

Ultrasound can detect increases in cervical facet joint effusion but will underestimate the amount of effusion. Computed tomography provides a better assessment of cervical facet joint effusion. Some extravasation of injectate should be expected when performing ultrasound-guided injections of cervical facet joints even with an experienced operator. Authors' addresses: College of Veterinary Medicine and Biomedical Sciences (Scott), Orthopaedic Research Center, C. Wayne McIlwraith Translational Medicine Institute (Selberg, Seabaugh), Colorado State University, Fort Collins, CO 80523; e-mail: kaseabaugh@yahoo.com. *Corresponding and presenting author. © 2022 AAEP.

1. Introduction

Osteoarthritis (OA) in the cervical region is a common source of pain in horses. It has been linked to multiple performance-limiting conditions. Diagnosis of OA can be made with radiography but ultrasonography is often used to identify more clinically relevant changes such as increased effusion, joint capsule thickening, and/or osteophytosis. The ability to accurately grade effusion with ultrasound has not been well evaluated. The goal of this project was to determine the accuracy of grading of effusion with ultrasound.

2. Materials and Methods

Five cadaver necks were graded for cervical facet effusion of C2–C3, C3–C4, C4–C5, C5–C6, and C6–C7 on the left and right side by operator 1. A second operator then injected the cervical facets with 0, 2, or 4 mL of a 50/50 mixture of positive contrast solution and water in a randomized manner. The first operator returned and scanned the cervical facets and assigned a new effusion grade to the facet joints. The cervical specimens underwent a baseline computed tomography (CT) scan as well as a postinjection CT scan. Effusion scores were compared between ultrasound and CT as well as between preinjection and postinjection.

3. Results and Discussion

Ultrasound resulted in significantly lower scores ($P < .0001$) than CT for both pre- and postinjection assessments. For both CT and ultrasound, postinjection scores were significantly greater than preinjection scores ($P < .01$). Extravastion of the injectate was identified in 11% of the ultrasound-guided injections.

Research Abstract—for more information, contact the corresponding author

NOTES

Subjective ultrasound scores underestimate cervical facet effusion, but they can accurately identify an increase in effusion.

Acknowledgments

Declaration of Ethics

The Authors have adhered to the Principles of Veterinary Medical Ethics of the AVMA.

Conflict of Interest

The Authors have no conflicts of interest.

Blinded Versus Ultrasound-Guided Low-Volume Injection of Tibial and Fibular Nerves in Equine Cadaver Limbs

Sandro Colla, DVM, MS*; Kurt T. Selberg, DVM, MS, DACVR; Kathryn A. Seabaugh, DVM, DACVS, DACVSMR; and Gustavo M. Zanotto, DVM, MS, PhD, DACVSMR

Accuracy of ultrasound-guided injection of the tibial and fibular nerves was not significantly different than blinded injection in equine cadaver limbs. Less diffusion of injectate was seen in the low-volume injection compared to the traditional volume. Authors' addresses: Colorado State University, 300 West Drake Road, Fort Collins, CO 80523 (Colla, Selberg, Seabaugh); Texas A&M University, College of Veterinary Medicine, College Station, TX 77843 (Zanotto); e-mail: sandrocolla18@gmail.com. *Corresponding and presenting author. © 2022 AAEP.

1. Introduction

Techniques for local anesthesia of the tibial (TN) and superficial and deep fibular nerves (FNs) in horses are well established. Ultrasound-guided nerve blocks can identify the nerve location, reduce the anesthetic volume needed, and avoid needle misplacement. The aim of this research was to compare the accuracy of blind injection technique (BLIND) to ultrasound-guided technique (U/S). The hypothesis was that U/S would be more accurate even with reduced injectate volume.

2. Materials and Methods

Fifteen equine cadaver hindlimbs were divided into two groups, and the TN and FNs were injected using a mixed solution of radiopaque contrast, saline, and food dye. BLIND ($n = 8$) used 15 mL for the TN and 10 mL for each fibular nerve. U/S ($n = 7$) used 3 mL for the TN and 1.5 mL for each fibular nerve. The limbs were radiographed immediately after injections and sectioned transversally to evaluate the diffusion and presence of the injectate adjacent to the TN and FNs. Contrast and dye distributions were compared using unpaired t test, and successful rate between groups was compared using Fisher's exact test.

3. Results

No statistically significant difference was observed between groups when evaluating the presence of dye near the nerves. Distal contrast diffusion associated with the TN injection was less for U/S compared to BLIND. Proximal, distal, and medial diffusion associated with the FNs were less for U/S compared to BLIND.

Research Abstract—for more information, contact the corresponding author

NOTES

4. Discussion

Both blind and ultrasound-guided techniques showed similar successful injection rates. Ultrasound may not be necessary for this perineural block as diffusion of anesthetic is less concerning for this block.

Acknowledgments

Declaration of Ethics

The Authors have adhered to the Principles of Veterinary Medical Ethics of the AVMA.

Conflict of Interest

The Authors have no conflicts of interest.

How to Use Power Doppler in Musculoskeletal Ultrasonography in the Horse

Rob van Wessum, DVM, MS, DACVSMR (EQ)*; and Kimberly Johnston, VMD, DACVS-LA

Authors' address: Equine All-Sports Medicine Center PLLC, 1820 Darling Road, Mason, MI 48854; e-mail: wessumdvm@gmail.com. *Corresponding and presenting author. © 2022 AAEP.

1. Introduction

Ultrasonography is a common diagnostic imaging tool for equine musculoskeletal disease in the field as well as in clinical settings.[1] Many ultrasound machines have the option to use power Doppler (PD), but for many veterinarians, the use of Doppler seems to be limited to use in echocardiography,[2] and less so for musculoskeletal imaging.

PD is a form of Doppler that analyzes the total strength of the returning echoes and ignores the direction of flow. A color map of the Doppler shift is created where the hue and brightness of the displayed color represent the velocity of flow within the vessel. PD can detect very low-velocity blood flow[3] and is 3 times more sensitive than color Doppler in doing so.[1]

PD can consistently demonstrate blood flow in smaller vessels (hyperperfusion) associated with musculoskeletal inflammatory disease and can provide a useful adjunct to grayscale sonographic examination. The use of PD can increase the specificity of an ultrasound examination by helping to differentiate vascular tissue from other types of tissue debris (blood clot, fibrin) and effusion. Increased perfusion is usually evident in the vicinity of tendon injury and within the area of tendonitis.[1] However, as with ultrasonography in general, applicability is highly operator dependant.[4]

In human medicine, the use of PD in musculoskeletal imaging is more common than in veterinary medicine. PD is widely used to evaluate synovial inflammation and shows to be positively and significantly correlated to disease severity.[5] It was initially used in rheumatology as a tool for detecting increased blood flow in a joint as an indicator of active arthritis, where active arthritis is defined as a higher state of metabolism in the joint associated with release of cytokines and other inflammatory mediators. In human medicine, data show active inflammation is related to pain and other symptoms in a patient, while chronic, inactive inflammation may have a similar appearance on radiographs and grayscale ultrasound but less association with pain. PD has also shown utility for use in imaging of tendons and ligaments to assess the amount of blood flow in and around these structures.

Interestingly, PD imaging of equine tendinopathy and sclerosing therapy is seen as a possible model for human tendinopathy,[6] and PD imaging for musculoskeletal pathology in human orthopedic medicine has been shown to be a very reliable tool to evaluate soft-tissue hyperemia in tendons and ligaments.[7]

In equine medicine, PD is an emerging field in ultrasonographic imaging of the equine superficial digital flexor tendon.[8–10] PD ultrasonography of equine suspensory ligament branches was able to identify increased vascular activity in 22 of 35 horses with pathology of the suspensory ligament, while no increased vascular signal was observed in normal horses.[10] PD scores were

NOTES

subjectively higher in suspensory ligament branches of lame limbs and in branches with more severe grayscale changes. Findings supported the use of PD as an adjunctive diagnostic test for lame horses with known suspensory desmopathy.[11] When neovascularization is present, as with tendon degeneration, PD can identify and characterize the extent of new vessel formation in the tendon tissue. Intratendinous vascular activity is not detectable within normal tendons.[12,13]

In the last 16 years, the authors' practice has incorporated PD imaging in their ultrasonographic exams of tendons and ligaments after a human radiologist made the author aware of this possibility. Since 2010, PD imaging has also been used to assess the synovium of several joints and assess capsular or pericapsular blood flow.[4,5]

With more literary evidence emerging about the value of PD imaging in equine ultrasonography, the authors feel confident that there is utility for PD findings to aid in a more accurate diagnosis when performing ultrasonography of equine tendons, ligaments, and joints. It does not take much longer to complete an ultrasonographic exam with a short addendum for imaging the same structures of interest with PD. The PD observations may improve accuracy of the diagnosis and assist with evaluation of the momentary status of inflammation of the observed structure.[13]

2. Materials and Methods

In the authors' practice, PD imaging is performed on nearly all musculoskeletal cases with ligament and tendon injury (since 2005) and often for joint evaluation (since 2010). With a caseload approaching 500 cases a year, 80% of which is musculoskeletal (specialty sports medicine and rehabilitation), the total number of PD examinations for musculoskeletal imaging that have been performed in the authors' practice is estimated at approximately 6000 cases. Preparation for PD ultrasonography does not differ from the usual ultrasound preparation. For imaging superficial structures, a linear transducer capable of 8 to 12 MHz is used, while for deeper structures, a convex transducer at 3 to 8 MHz is preferred. Imaging of structures within the hoof capsule from in between the hoof bulbs is best performed using a microconvex transducer at 8 to 11 MHz.[14a]

For imaging with the linear transducer and the microconvex transducer, the haircoat should be clipped with a #40 blade and skin washed with soap and water to remove any grease that may interfere with sound transmission and returning signals. When using the convex transducer, spraying the haircoat with alcohol is generally sufficient for adequate imaging, though the presence of hair may impede Doppler interrogation.[14] A contact ultrasound gel is used in all examinations. Echolucent standoff pads may also impede Doppler interrogation slightly and should be used only when necessary.

Any ultrasonographic examination starts with the complete imaging of the subjected structure in multiple orientations and, when needed, with specific angles before imaging the same structure with PD. This makes evaluation of structures easier as part of the computing power of the ultrasound machine is used to produce the Doppler image, which may lead to loss of grayscale resolution during Doppler evaluation. Therefore, routine imaging is performed first with optimal settings to evaluate the structure(s) in detail, and then imaging is repeated with optimal settings for PD imaging of the same sites.[1] Gain settings for imaging while using PD should be around 50% as higher settings will saturate the image with too much color to be of diagnostic value. Increasing pulse repetition frequency and using a small field of view will improve detection of vessels. Decreasing B-mode gain may improve detection of blood flow as well. Motion of the horse, ultrasound transducer, or the operator will result in aliasing artifacts (Fig. 1). Sedation of the horse and a sitting position of the operator while imaging lower extremities will facilitate "motionless" imaging, while supporting the imaging hand with a pillow or the other arm may make imaging of the thoracolumbar facet joints easier. Too much pressure on the transducer will collapse smaller vessels in the observed area (less flow is detected due to operator error). Similarly, increased vascularity of distal limb structures can be appreciated in a non-weight-bearing position when compared with weight-bearing stance as vessels are somewhat compressed with weight bearing. The effects of vasoconstrictive and vasodilatory sedatives on the vascularity of these structures have not been assessed.

As with any ultrasound exam, split-screen imaging of the similar structures in the affected and contralateral limb with grayscale imaging as well as PD is preferred in the authors' practice to assess the condition observed. The ultrasonographer must realize that after exercise, the vascular activity of any given structure may increase. Conversely, vascularity may decrease with decreased ambient temperature or recent cold therapy. The effect of other commonly administered therapies such as laser, pulsed electromagnetic field, theraplate, etc. on vascularity of injuries detectable with PD has not been assessed. Performing the PD imaging procedure might best be done before exercise or after a set time following exercise to get an accurate sense of basal blood flow. In the authors' experience, differences in blood flow between the contralateral structures may be more apparent after exercise, when an increase in flow on the affected side might be augmented by work.

A general rule is to not change conditions during sequential imaging. When evaluating the effect of a treatment or medication, the circumstances of each examination should be the same, like before or after work, similar ambient temperature (the hospital has a climatized examination room), and, obviously, with the same ultrasound machine settings.

When evaluating PD activity, good understanding of the regional anatomy is imperative. Knowledge of the normal location of blood vessels in the observed area is required to perform an adequate evaluation.

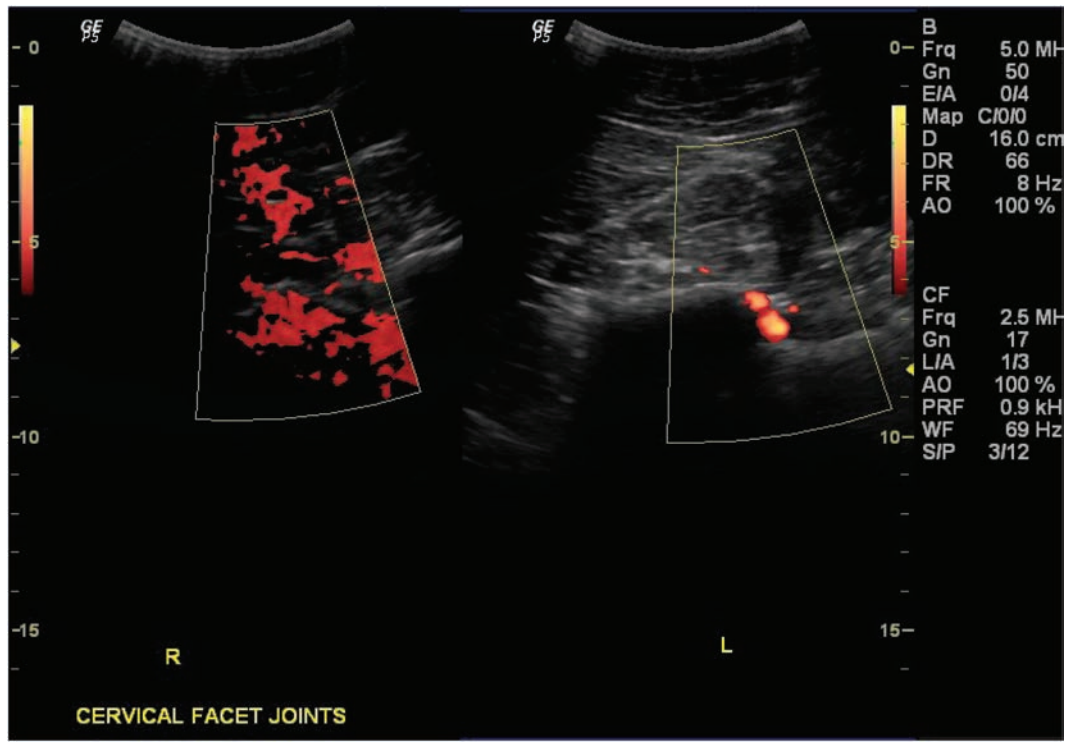

Fig. 1. Artifact due to motion at the left of the image, unform color pattern in weird shapes. Compare to the right image, which is a clearly located pattern of several hues of colors, which is an adequate power Doppler image.

Tendon and joint anatomy are of greatest importance. Recognizing increased blood flow in a vessel adjacent to a tendon or joint has a different impact than a diffuse microflow in the tendon structure itself or a diverging vascular pattern in the synovial tissue of a joint itself.

In the authors' practice, PD has shown to be a great tool for making it possible to differentiate between several similar conditions, whereas without PD, this differentiation cannot be made easily.

Differentiation Between Active and Inactive Tendon or Ligament Lesion

An active lesion is a lesion in which a higher metabolism is present due to release of inflammatory mediators within the tissue and increased metabolism in the tenocytes. This process is often called tendinitis. When the initial inflammatory processes have diminished, a metabolically inactive stage with less inflammation but with persistent alterations in the tendon matrix is referred to as tendinosis.[9]

Upon initial examination of a tendon or ligament injury, PD can provide information about the vascular activity in and around the injured structure (Fig. 2). In general, the more blood flow that is observed in close proximity to that structure, the more inflammation is likely present.[1]

Often an enlarged tendon is suspected of being a cause of lameness and grayscale ultrasound shows some altered fiber pattern. However, it is not evident if the lesion has vascularization/active inflammation. PD imaging can be used to demonstrate increased vascular activity in close proximity of the lesion when there is more active metabolism in the tendon. With active tendinitis there might be increased blood flow detectable while chronic adaptation to strain might have led to tendon enlargement with no increase in blood flow, the latter often is not related to clinical lameness.[10–12] Evaluations and diagnoses should be performed with care to ensure that lack of Doppler signal is not due to user error, environmental factors, or incorrect machine settings. Routine monitoring of inactive lesions is recommended in competing horses to assess for possible reinjury and to confirm stasis.

Differentiation Between Tendinitis and Tendinosis or Tendon Degeneration

Acute inflammatory stages of tendon and ligament injuries (2–3 weeks after injury) may exhibit increased blood flow in the adjacent structures as well as the tendon or ligament. More chronic processes may have less blood flow in the vicinity, while degenerative processes and regions of fiber disruption often demonstrate microvascularization within the tendon or ligament.[1,6,13] Granulation tissue will also produce increased signal during PD evaluation. Recognizing these patterns during a complete ultrasonographic examination of a tendon or ligament will assist greatly in staging the process and developing an adequate therapy and rehabilitation plan.

Differentiation Between Active and Nonactive Synovitis

When examination and radiographs indicate a small fragment in a joint, like the distal interphalangeal or

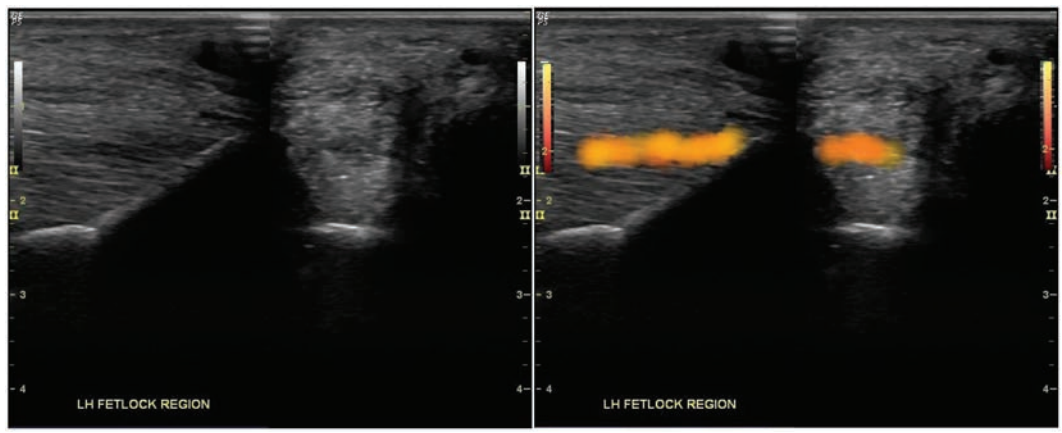

Fig. 2. Left image shows a grayscale ultrasonogram of a lesion in the suspensory ligament attachment to the proximal sesamoid bone. The right image shows the same image with use of power Doppler, which shows increased vascular activity within the lesion.

metacarpophalangeal joints, it may not be apparent if the fragment is causing reaction in the joint or if it is encapsulated and inert to the joint. Ultrasonography of the synovial structures to evaluate volume and thickness of the synovial membrane assists in making this determination. PD imaging of the synovial structures and the adjacent joint capsule may provide an impression of the amount of inflammation in the joint and potentially aid treatment decisions (i.e., medical versus surgical; Fig. 3). As with tendon and ligament injuries, serial evaluation after exercise may be necessary to evaluate exercise-induced inflammation. Increasingly recognized, osteoarthritis of cervical articular process joints has been identified as a cause for behavioral issues and lameness.[14] Radiography, however, may be limited to differentiate which cervical articular joint(s) are causing the symptoms as many clinically sound horses exhibit radiographic abnormalities.[15–17] Doppler imaging of the articular process joints may allow for visualization of increased capsular blood flow as an indication for active synovitis/capsulitis/arthritis.[17] Longitudinal studies are needed to further characterize the utility of PD in differentiating between inflamed and noninflamed joints. Anecdotally, PD imaging after an initial grayscale ultrasonographic evaluation of the cervical articular process joints correlates with other signs of synovitis/capsulitis/arthritis such as effusion, synovial thickening, and proliferation. On the other hand, increased vascular activity has not been appreciated in the authors' practice without accompanying signs of effusion, synovial reactivity, and/or proliferation. Performing both imaging modalities in sequence may provide a better understanding of which joint(s) are experiencing active inflammation,[17] though more work is needed to assess the significance and reproducibility of detectable vascularity of these sites.

3. Power Doppler and Rehabilitation of Tendon and Ligament Injuries

An advantage of the use of PD can be found when directing rehabilitation after an injury of a tendon or ligament. Often, a good rehabilitation program depends on serial exams to follow the progress of the healing process.[18] When PD is used at the outset and for each follow-up exam, changes in the pattern of blood flow can be observed over time. In general, especially with tendon and ligament lesions, during the healing of the

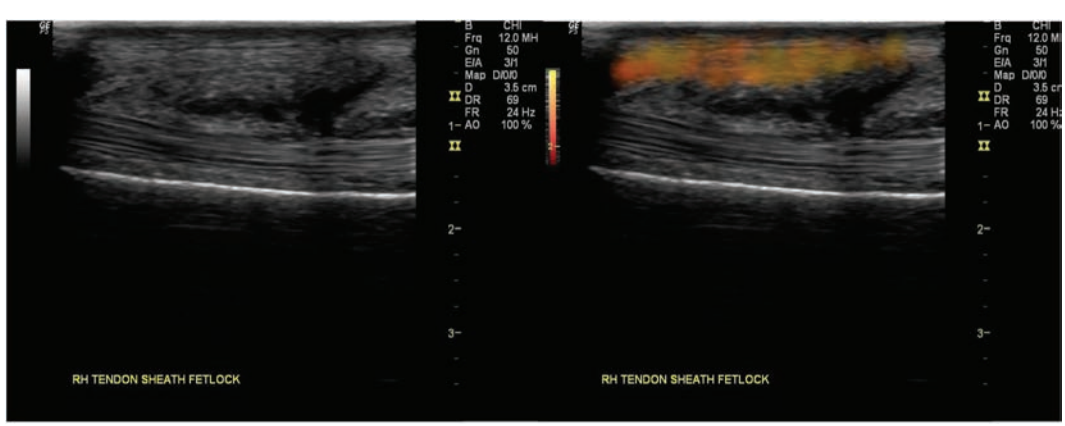

Fig. 3. The left image shows a grayscale image of the tendon sheath of the fetlock with some synovial proliferation. The right image of the same area imaged with power Doppler shows an area of increased signal in the synovial membrane and the connective tissue.

injury, a decrease in PD activity can be observed over time. A sudden increase in vascular activity during rehabilitation might indicate a potential reinjury/inflammation or too high-intensity work. These findings facilitate objective decision-making regarding progress of the rehabilitation program and can be used to adjust treatment strategies, adapt the level of exercise, and add other treatment modalities.

As with any diagnostic, data from PD imaging should never be taken as the sole tool for diagnosis. A full physical exam, careful palpation, and other imaging modalities, as well as grayscale ultrasonography, should be performed adjacent to the PD session, and all results should be evaluated as a whole. Serial evaluation is imperative to assess progression and determine stasis. Experience with the technique is required to perform representative examinations.

4. Summary

Upon completion of a standard grayscale ultrasonography evaluation, it takes only a few additional minutes to obtain PD images of regions of interest and add them to the stored sequence, with no extra costs for the provider.

By performing a PD sequence at each musculoskeletal ultrasound exam, the added information about the degree of inflammation present, relative age of the injury process, and reactivity of the observed tissue can be incorporated to facilitate treatment and rehabilitation strategies.

Acknowledgments

Declaration of Ethics

The Authors have adhered to the Principles of Veterinary Medical Ethics of the AVMA.

Conflict of Interest

The Authors have no conflicts of interest.

References and Footnote

1. Redding WR. Ultrasound. In: Baxter GM, ed. *Adams and Stashak's lameness in horses 7th ed*. Hoboken: Wiley Blackwell, 2020;301–335.
2. Morresey PR. Ultrasonography of the heart. In: Kidd JA, Lu, KG, eds. *Atlas of equine ultrasonography*. Oxford: John Wiley and Sons, 2014;379–408.
3. Palgrave K, Kidd JA. Introduction. In: Kidd JA, Lu, KG, eds. *Atlas of equine ultrasonography*. Oxford: John Wiley and Sons, 2014;1–23.
4. Smith E, Azzopardi C, Thaker S, et al. Power Doppler in musculoskeletal ultrasound: Uses, pitfalls and principles to overcome its shortcomings. *J Ultrasound* 2021;24:151–156.
5. Rabab HI, Nihal AF, Esam NA, et al. Assessment of joint inflammatory activity in rheumatoid arthritis: A comparative study between clinical evaluation and musculoskeletal ultrasound. *Sohag Medical J* 2017;21:207–215.
6. Boesen MI, Nanni S, Langberg H, et al. Colour Doppler ultrasonography and sclerosing therapy in diagnosis and treatment of tendinopathy in horses—A research model for human medicine. *Knee Surg Sports Traumatol Arthrosc* 2007;15:935–939.
7. Newman JS, Adler RS, Bude RO, et al. Detection of soft tissue hyperemia: Value of power Doppler sonography. *Am J Res* 1994;163:385–389.
8. Lacitignola L, Rossella S, Pasquale DL, et al. Power Doppler to investigate superficial digital flexor tendinopathy in the horse. *Open Vet J* 2020;9:317–321.
9. Banes AJ, Tsuzaki M, Wall M, et al. The molecular biology of tendinopathy: Signaling and response pathways in tenocytes. In: Woo SLY, Renstrom FH, Arnoczky SP, eds. *Tendinopathy in athletes*. Malden: Blackwell Publishing, 2007:29–45.
10. Murata D, Misumi K, Fujiki M, et al. A preliminary study of diagnostic color Doppler ultrasonography in equine superficial digital flexor tendonitis. *J Vet Med Sci* 2012;74:1639–1642.
11. Hatazoe T, Endo Y, Iwamoto Y, et al. A study of the distribution of color Doppler flows in the superficial digital flexor tendon of young Thoroughbreds during their training periods. *J Equine Sci* 2015;26:99–104.
12. Rabba S, Grulke S, Verwilghen D, et al. B-mode and power Doppler ultrasonography of the equine suspensory ligament branches: A descriptive study on 13 horses. *Vet Radiol Ultrasound* 2018;59:453–460.
13. Kristofferson M, Ohberg L, Johnston C, et al. Neovascularisation in chronic tendon injuries detected with colour Doppler ultrasound in horse and man: implications for research and treatment. *Knee Surg Sports Traumatol Arthrosc* 2005;13:505–508.
14. Docking SI, Ooi CC, Connell D, et al. Tendinopathy: Is imaging telling us the entire story? *J Orthop Sports Phys Ther* 2015;45:842–852.
15. Koenig JB, Westlund A, Nykamp S, et al. Case-control comparison of cervical spine radiographs from horses with a clinical diagnosis of cervical facet disease with normal horses. *J Equine Vet Sci* 2020;92:103176.
16. Down SS, Henson FMD. Radiographic retrospective study of the caudal cervical articular process joints in the horse. *Equine Vet J* 2010;41:518–524.
17. van Wessum RL. Lameness associated with the axial skeleton. The neck and poll. In: Baxter GM, ed. *Adams and Stashak's lameness in horses 7th ed*. Hoboken: Wiley Blackwell, 2020; 796–800.
18. Thaler R, McKnight A. Imaging. In: Jann H, ed. *The equine tendon in health and disease*. New York: Nova Science Publishers Inc., 2013, online version, pp 103176.

[a]GE Logiq P5: linear transducer L9, convex transducer 4C-SC, microconvex 8C.

Comparison of 16-MHz and 9-MHz Ultrasonography to Low-Field Magnetic Resonance Imaging of the Distal Suspensory Apparatus

Mathias Ankjær Dinesen, DVM*; Alexia McKnight, DVM, DACVR; Henrik Sten Andersen, DVM; and Casper Lindegaard, DVM, PhD, DECVS

Higher ultrasound frequency improves diagnostic accuracy of injuries in the distal suspensory apparatus. Authors' address: Hørsholm Hestepraksis, Kongevejen 124D, Fredensborg, Denmark 3480; e-mail: md@hestepraksis.com.*Corresponding and presenting author. © 2022 AAEP.

1. Introduction

Diagnostic accuracy of ultrasonography of distal sesamoidean ligaments (DSLs) is reported as poor compared to magnetic resonance imaging (MRI). Higher ultrasound frequency with higher spatial resolution may therefore result in improved diagnostic accuracy. The study objective was to assess and compare diagnostic accuracy for two different ultrasound frequencies compared to 0.31T MRI for injuries of the DSLs and suspensory ligament branches (SLBs).

2. Materials and Methods

Horses with metacarpo-/metatarsopahalangeal region lameness were included. The metacarpo-/metatarsophalangeal region was examined ultrasonographically using a 9-MHz (US9) and a 16-MHz (US16) transducer and subsequently by 0.31T MRI. Cross-sectional area measurements (CSAs) at 9 specific zones were compared using paired t tests and Wilcoxon signed rank tests. Sensitivity (Se), specificity (Sp), and negative (NPV) and positive predictive values (PPV) were determined with 0.31T MRI as the gold standard.

3. Results

Thirteen horses were included. A total of 17 SLB and 16 DSL injuries were identified with MRI. US9 identified 8/17 SLB injuries (Se = 0.47, Sp = 0.88, NPV = 0.44, PPV = 0.89) and 4/16 DSL injuries (Se = 0.25, Sp = 0.93, NPV = 0.85, PPV = 0.44). US16 identified 10/17 SLB injuries (Se = 0.59, Sp = 1, NPV = 0.56, PPV = 1) and 8/16 DSL injuries (Se = 0.50, Sp = 0.96, NPV = 0.9, PPV = 0.72). CSA measurements did not differ between ultrasonography transducers. CSA measurements differed significantly between ultrasonography (9 + 16 MHz pooled) and MRI ($p < 0.05$, median difference = 0.298 cm^2).

Research Abstract—for more information, contact the corresponding author

NOTES

4. Discussion

US16 had higher diagnostic accuracy than US9, and a high-frequency transducer should be preferred for examinations of the SLBs and DSLs. CSA differs significantly between US and MRI; hence, comparisons between modalities should be made with caution.

Acknowledgments

Declaration of Ethics

The Authors have adhered to the Principles of Veterinary Medical Ethics of the AVMA.

Conflict of Interest

The Authors have no conflicts of interest.

How to Diagnose Equine Odontoclastic Tooth Resorption and Hypercementosis in the Equine

Olivia James, BVSc (Hons), MANZCVS (Equine Dentistry), CMAVA, DICEVO, DAVDC (Equine)

Author's address: Australian Veterinary Equine Dentistry Pty Ltd., The Veterinary Dental Company, PO Box 266, Clayfield QLD 4011, Australia; e-mail: dr.olivia.james@gmail.com. © 2022 AAEP.

1. Introduction

Equine odontoclastic tooth resorption and hypercementosis (EOTRH) is a painful and progressive condition of middle-aged and geriatric equines with unknown etiology. EOTRH predominately affects the permanent incisor and canine teeth and, less commonly, the premolar and molar dentition. It is characterized by external odontoclastic tooth resorption of the reserve crown, crown and apex of the tooth, and osteoclastic resorption of surrounding areas of the alveolar bone, as well as occasional progressive proliferation of irregular cementum.

The severity of EOTRH increases with advancing age, with most clinically affected horses being 15 years or older; however, moderate to severe radiographic changes have been identified in horses as young as 11 years of age.[1–3] The condition appears to progress mesially from the canine teeth or corner incisors, with cases typically presenting with varying stages of concurrent periodontal disease. The clinical appearance usually leads to an underestimation of the condition's severity relative to the radiologic findings.

Since tooth resorption is initially identified in the reserve crown or apices, early cases may be asymptomatic or may exhibit only subtle changes, such as tooth discoloration (Fig. 1), small pits at the gingival margins, or mild to moderate gingival hyperemia and gingival recession (Fig. 2).[4,5] In contrast, horses with advanced disease often present with dysphagia, painful and edematous gingivitis, suppurative gingival draining tracts (Fig. 2), resorptive lesions at the gingival margins (Fig. 3), and/or pathological tooth fracture (Fig. 4).[4,5] There may be concurrent bulbous enlargement of the reserve crown and roots of the incisors and, to a lesser extent, of the canine teeth.

EOTRH-affected horses may show masticatory problems or dysphagia, hypersalivation, quidding, halitosis, biting problems, head shaking, and weight loss. Although painful, EOTRH is often asymptomatic until periodontal disease has become advanced.[5]

Other clinical findings include enlarged mandibular lymph nodes, calculus deposition, resorptive lesions deep to excessive calculi on canine teeth, tooth fracture, prominent juga (eminences on the outer surface of the alveolar process of the incisive bone or mandible, formed by the roots of the incisor teeth that are an abnormally enlarged reserve crown and/or roots from hypercementosis), severe inflammation, gingival fistulas, tooth mobility, and exfoliation, or even tooth ankylosis to the alveolar bone.

2. Materials and Methods

Most commonly, owners are not aware of the presence of EOTRH and no symptoms will be reported by

NOTES

Fig. 1. EOTRH-affected horses showing 25-gauge needles inserted into the occlusal aspect of the pulp chambers, indicating pulp exposure (white arrows) and discolored teeth 101 and 201 (red arrows).

Fig. 2. EOTRH-affected horse with gingival edema and hyperemia with multiple suppurative gingival draining tracts (white arrows).

owners. Some EOTRH-affected horses will be reluctant to have their mouth examined as part of a physical examination and are better examined after sedation is administered. Tapping on the incisor teeth with a metal instrument or similar can produce a marked response (compared to an unaffected horse); this can be done before or after sedation is administered. A "carrot test" can also be utilized, but this must be performed before the horse is sedated. The carrot test as termed by Dr. Chris Pearce, Equine Dental Clinic, UK, shows affected horses reluctant to bite a crisp carrot with their incisors and instead prefer to grasp the carrot with their lips to draw the carrot into the oral cavity to masticate using cheek teeth.

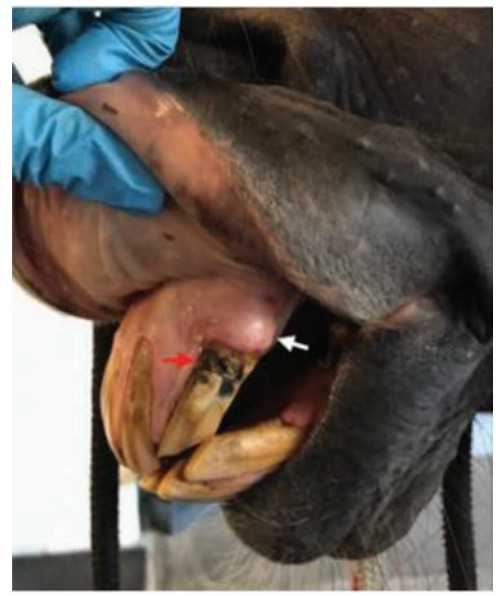

Fig. 3. EOTRH-affected horse with gingival edema and recession (white arrow) and resorptive lesion at the gingival margin (red arrow).

Fig. 4. EOTRH-affected horse showing pathological tooth fracture (red arrows), pulp exposure (white arrows), and gingival recession (yellow arrows) with bulbous enlargement of the reserve crown and roots.



Fig. 5. Positioning of the plate and generator for intraoral radiographs of the maxillary incisors. The dissecting angle technique is being used, and the generator beam is perpendicular to a line that bisects the tooth and the plate.

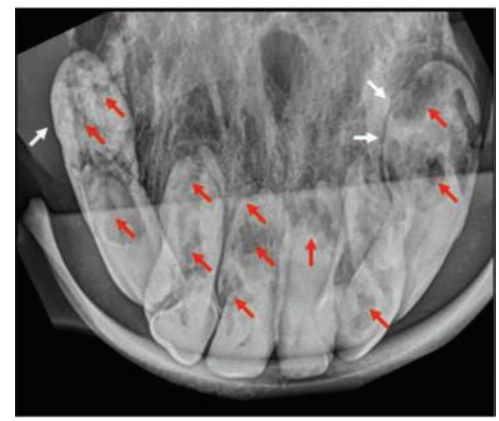

Fig. 6. EOTRH-affected horse showing bulbous enlargement of the tooth roots (hypercementosis) (white arrows) and advanced resorptive lesions (red arrows).

Patients should then be examined while under intravenous sedation to reduce patient movement and pain and to facilitate safety for both the practitioner and patient. The gingiva, incisor, and canine teeth should be examined for the presence of edematous gingiva, suppurative periodontal draining tracts, fractured or missing teeth, resorptive lesions on the crown, and pulp exposures and bulbous enlargement of the incisors and canine teeth.

3. Radiography

It is vital that good-quality radiographs are taken as EOTRH requires a radiological diagnosis, and both staging and progressive monitoring of EOTRH also require the use of radiographs.

The plate should be placed between the incisors. If necessary, the plate can be turned so the corner is furthest in the mouth in order to get as much plate available for imaging as possible. A computed radiography (CR) plate can be safely placed in the mouth without any other form of restraint apart from sedation, but it is imperative that a direct radiology (DR) plate NEVER be placed in the mouth without sedation and a cheek tooth gag or radiolucent speculum in place. Commercially available radiolucent speculums are available.[a]

Orientation for intraoral views are dorsoventral (DV) for maxillary incisors and ventrodorsal (VD) for mandibular incisors. An intraoral bisecting angle technique (Fig. 5) is utilized to image the incisors and a 15- to 30-degree oblique view from each side of the midline is used to image the intermediate and corner teeth without superimposition.[1,6] In the bisecting angle technique, the x-ray beam is directed at 90 degrees to an imaginary line that bisects the angle formed by the long axis of the tooth and the long axis of the film.

Canine teeth are imaged most easily using the extraoral technique. The plate is held on the side of the horse's face and the central beam is perpendicular to the long axis of the head. The generator is lowered 15 to 30 degrees from horizontal to obtain a DV oblique view and raised 15 to 45 degrees from horizontal to obtain a VD oblique view.

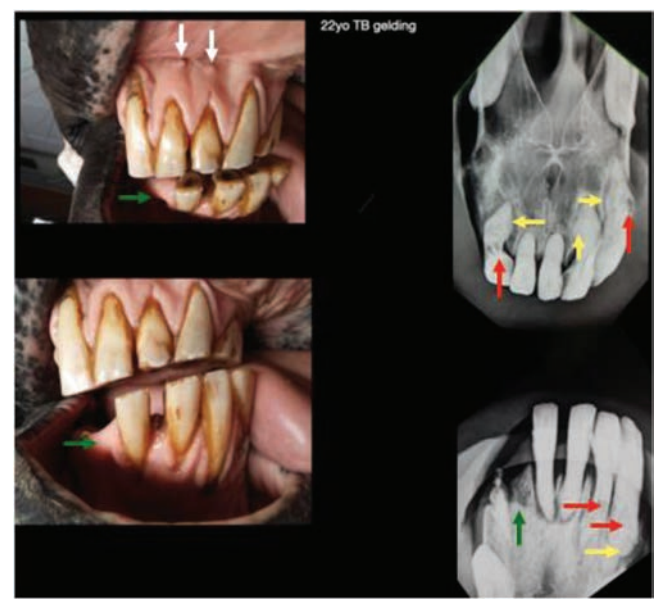

Fig. 7. A 22-year-old gelding with tooth loss (green arrows), gingival draining tracts (white arrows), resorptive lesions (red arrows), and hypercementosis (yellow arrows).

4. Radiology

EOTRH requires radiography of incisors, canines, ± cheek teeth in order to diagnose, stage, and compose treatment options. EOTRH was thought to only affect incisor and canine teeth, but because of the increase in portability and more frequent use of digital radiographs, it is more commonly being identified in cheek teeth. It can be difficult to differentiate the resorptive lesions of EOTRH from the normal aging process of the tooth.

Radiological signs typically include different grades of dental resorption and hypercementosis, alveolar

bone loss, osteomyelitis, and tooth fractures (Fig. 6).[1,6,7] There may be loss or disruption of the pulp canal or loss of the periodontal ligament (PDL) space with resultant ankylosis of the reserve crown and root to the alveolus and crown or root fractures. Resorption may be identifiable without hypercementosis, and if hypercementosis is present, there will be root and reserve crown enlargement. Hypercementosis can potentially make resorptive lesions more difficult to see due to superimposition (Fig. 7).

The most common type of resorption found in EOTRH-affected teeth is external replacement resorption (76%) and internal inflammatory resorption (49%). In one study, tooth resorption occurred in over 88% of cases and hypercementosis occurred in 34% of cases.[2] External replacement resorption is evident radiographically as a gradual disappearance of the periodontal ligament space with progressive replacement of root tissues by the surrounding alveolar bone. In horses, the tooth most frequently affected by external replacement resorption (in both the maxilla and mandible) is the canine and corner incisor tooth, followed by the intermediate and central incisor tooth.[2]

External inflammatory resorption is seen radiologically as alveolar bone loss and a widened periodontal ligament secondary to inflammatory conditions. The tooth most frequently affected (in both the maxilla and mandible) by external inflammatory resorption is the central incisor tooth, followed by the intermediate and corner incisor tooth.[2]

5. Discussion

Equine odontoclastic tooth resorption and hypercementosis is more commonly being recognized by veterinary practitioners as a disease affecting the dentition of the older horse. Horses suffering from various stages and types of EOTRH need a careful assessment of their history, physical examination, neurological and pain score assessment, oral and dental examination under sedation, and radiographs to form a proper diagnosis. EOTRH requires a radiologic diagnosis, and radiographs can easily be taken in the field to diagnose this condition. This allows the veterinarian to properly inform the owner of the horse's prognosis and devise a treatment plan.

Acknowledgments

Declaration of Ethics

The Author has adhered to the Principles of Veterinary Medical Ethics of the AVMA.

Conflict of Interest

The Author has no conflicts of interest.

References and Footnote

1. Smedley RC, Earley ET, Galloway SS, et al. Equine odontoclastic tooth resorption and hypercementosis: Histopathologic features. *Vet Pathol* 2015;52:903–909.
2. Earley E, Rawlinson JT. A new understanding of oral and dental disorders of the equine incisor and canine teeth. *Vet Clin North Am Equine Pract* 2013;29:273–300.
3. Rehrl S, Schröder W, Müller C, et al. Radiological prevalence of equine odontoclastic tooth resorption and hypercementosis. *Equine Vet J* 2018;50:481–487.
4. Lorello O, Foster DL, Levine DG, et al. Clinical treatment and prognosis of equine odontoclastic tooth resorption and hypercementosis. *Equine Vet J* 2016;48:188–194.
5. Limone LE. Update on equine odontoclastic tooth resorption and hypercementosis. *Vet Clin North Am Equine Pract* 2020;36: 671–689.
6. Rahmani V, Häyrinen L, Kareinen I, et al. History, clinical findings and outcome of horses with radiographical signs of equine odontoclastic tooth resorption and hypercementosis. *Vet Rec* 2019;185:730.
7. Henry TJ, Puchalski SM, Arzi B, et al. Radiographic evaluation in clinical practice of the types and stage of incisor tooth resorption and hypercementosis in horses. *Equine Vet J* 2017;49:486–492.

[a]Aluminispec; https://equinedentalinstruments.com/products/alumispec) or radiolucent bite plates can also be used (e.g., https://evds.vet/speculums-c-2/aluminium-incisorplates-pair-p-309.html).

Evaluation of Frontal and Infra-Trochlear Nerve Blocks for Frontonasal Sinusotomy in Standing Horses

Shyla Giancola, DVM*; Singen M. Elliott, DVM; and Valerie J. Moorman, DVM, PhD, DACVS-LA

Targeted nerve blocks of the frontal and infra-trochlear nerves achieved skin desensitization comparable to traditional line blocks and allowed creation and closure of a standing frontonasal sinusotomy. Authors' address: University of Georgia College of Veterinary Medicine, Athens, GA 30602; e-mail: scg20106@uga.edu. *Corresponding and presenting author. © 2022 AAEP.

1. Introduction

Local anesthesia for standing sinusotomy in the horse has commonly been performed using a line block; however, targeted nerve blocks could also desensitize this area. The goal of this study was to determine if local anesthesia of the frontal and infra-trochlear nerves would allow creation of a frontonasal sinusotomy.

2. Materials and Methods

For phase 1, a randomized cross-over study was performed using 6 horses to compare frontal and infra-trochlear nerve blocks to traditional line block. Mechanical nociceptive thresholds (MNT) were obtained along a proposed frontonasal sinusotomy at baseline, 10 minutes, 1 hour, and 2 hours postblocking. For phase 2, frontal and infra-trochlear nerve blocks were performed in 6 horses followed by creation of skin/periosteal incisions. Data from phase 1 was analyzed using mixed-model ANOVA with $P < 0.05$. For phase 2, ability to create and close the incision were recorded, as well as size of the incision.

3. Results

Compared to baseline MNTs, there were significant increases in MNTs following line and targeted blocks ($P < 0.05$). Skin/periosteum incisions could be performed in 5 of 6 horses and median sinusotomy size was 6.5×5 cm.

4. Discussion

Frontal and infra-trochlear nerve blocks could be used to create a small frontonasal sinusotomy; however, anesthesia of the maxillary or infra-orbital nerve may be needed to desensitize the rostral aspect.

Research Abstract—for more information, contact the corresponding author

NOTES

Acknowledgments

Declaration of Ethics

The Authors have adhered to the Principles of Veterinary Medical Ethics of the AVMA.

Conflict of Interest

The Authors have no conflicts of interest.

Medial Femoral Condyle Subchondral Cysts Treated with Transcondylar Lag Screw: Outcome in 58 Quarter Horses

María Isabel Calero, DVM*; Troy Herthel, DVM; Mark Rick, DVM; Jeff Foland, DVM; and Elizabeth Santschi, DVM

Subchondral cystic lesions (SCLs) are known to cause lameness in horses and have been identified in multiple locations in the forelimbs and hindlimbs. A common location is the medial femoral condyle and has been reported in horses of almost all ages and breeds. Various treatment options have been explored. Conservative treatments include stall rest and various intra-articular injections such as corticosteroids, hyaluronic acid, platelet-rich plasma (PRP), or stem cells. Surgical options are multiple and include transcondylar lag screws. Previous reports in Thoroughbreds treated with transcondylar screws did not have a long-term follow-up. The purpose of this descriptive retrospective study is to report long-term follow-up in 58 Quarter Horses presented for transcondylar screw placement in medial femoral condyle subchondral cystic lesions at 3 equine hospitals in the United States. Different variables were considered as some horses received oral supplements and intra-articular injections. Eighty percent of stifles had a successful outcome, which is similar to previous studies. Of 10 horses that had radiographic follow-up, there was a 22% reduction in cyst size. Most stifle changes were observed in the first 2 years after surgery. Authors' addresses: Alamo Pintado Equine Medical Center, 2501 Santa Barbara Avenue, Los Olivos, CA 93463 (Calero, Herthel, Rick); Weatherford Equine, 1877 Mineral Wells Hwy, Weatherford, TX 76088 (Foland); Kansas State University, 1800 Denison Avenue, Mosier Hall, Manhattan KS 66506 (Santschi); e-mail: m_isabelcalero@hotmail.com. *Corresponding and presenting author © 2022 AAEP.

1. Introduction

Osseous cyst-like lesions (OCLLs) are described as focal radiolucent areas that have a sclerotic rim, are conical or spherical shaped, and are usually found in the trabecular bone at focal highly load articular surfaces.[1,2] These lesions communicate with the joint through tracts (cloaca) of different sizes[1,3–8]

The cysts are filled with fibrous tissue, fibrocartilage that can be mineralized and may contain necrotic bone. Immunoassay of cyst contents identifies various proinflammatory cytokine secretions associated with bone resorption.[2] This amorphous cystic tissue can secrete interleukin-1β, interleukin-6, nitric oxide, prostaglandin E2, and neutral metalloproteinases, which may contribute to the maintenance, poor endogenous healing, and expansion of the lesions.[8] The lack of resolution or healing of subchondral cystic lesions (SCLs) after intralesional corticosteroid injections suggests factors other than just inflammatory cytokines could

NOTES

contribute to their formation.[4] SCLs are the most common type of OCLLs in horses. Theories regarding subchondral cyst formation include dietary, biomechanical, genetic, and physiological factors. The SCLs are divided into 2 categories: developmental (juvenile) or acquired lesions.[6,7,9–11] SCLs are most commonly detected at <2 years of age but have been reported in older horses.[5] Developmental SCLs diagnosed in young horses are often detected on survey radiographs prior to the onset of clinical findings. Acquired SCLs occur as a consequence of trauma or overload of the cartilage and subchondral bone.[3,6,10] Several hypotheses about pathogenesis have been raised. One hypothesis states that the focal microdamage to the trabecule exceeds reparative ability, the subchondral bone collapses, and the cartilage barrier cracks, allowing joint fluid to contact the bone, which activates monocytes, leading to cytokine release and osteoclast activation, osteocyte death, and inhibition of osteoblasts.[5,12] The pressurized synovial fluid may alter loading conditions of the surrounding bone and induce a mechanoregulated bone adaptation response.[13]

Another suggests subchondral lesions are mediated by damage to the microvasculature with ensuing chondronecrosis. The osteochondral unit is composed of articular cartilage, calcified cartilage, and subchondral and trabecular bone, working synergistically to support functional loading of the joint.[14] A third hypothesis proposes that altered collagen metabolism may be an underlying predisposing factor. The biomechanical insults may eventually result in osteochondral fragmentation of the articular surface or at periarticular locations or in the formation of juvenile subchondral bone cysts.[1] A more recent theory states that bone strain is reduced within the SCL and that environment could contribute to the poor bone healing response.[2]

Lamenesses caused by distal medial femoral condyle SCLs are variable in severity and often intermittent. Many treatments have been described varying from exercise restriction, synovial and intralesional steroid injections, to surgical treatments including arthrotomy with cyst debridement, arthroscopic cyst enucleation, cancellous bone grafting, cartilage implants with fibrin glue overlays, intraoperative synovial and intralesional injections with steroids, and transcondylar screws placed in lag fashion.[2,15–17] Some of these treatments have been used sequentially; exercise restriction tends to be the first choice, followed by steroid injection before undergoing surgery.[5]

Previous reports utilizing transcondylar lag screws are predominantly in Thoroughbreds (TBs) with very few Quarter Horses included. In those studies, 75% of TB patients demonstrated an increase in SCL density and elimination of lameness, indicating that the screw's compression helps to promote SCL resolution.[18] Thoroughbreds often retire from their racing careers at a young age, making long-term follow-up problematic due to horse movement, confidentiality, and complexities in finding new owners. The prevalence of medial femoral condyle SCLs is 1.7% to 3.6% in Thoroughbreds and 10% to 13.6% in Quarter Horses.[2] The purpose of this study is to present follow-up data in Quarter Horses that were treated with a transcondylar lag screw based on initiation of training, return to their activities or training, soundness, and in some cases radiographic assessment. Return to initial activities or training is not an ideal measurement but is the most accessible information in long-term follow-up.

2. Materials and Methods

Horses

Medical records from 2014 to 2021 were compiled for 58 Quarter Horses. The horses were between 1 and 7 years of age. Each horse had a medial femoral condyle subchondral bone cyst that was treated with a transcondylar lag screw. Of the 58 horses, 38 were confirmed by the attending clinician to be lame in a rear limb. The remainder were diagnosed on survey radiographs. Follow-up data included phone calls (47 horses), recheck radiographs (10 horses), and lameness exams (5 horses).

Surgical Technique

For the surgical technique, as described by Santschi et al.,[2] the horses were anesthetized and positioned in dorsal recumbency with the affected limb in extension. Potassium penicillin (22,000 IU/kg, intravenous [IV]), gentamicin (6.6 mg/kg, IV), and phenylbutazone (4.4 mg/kg, IV) were administered preoperatively. A 10-MHz linear ultrasound probe was used to examine and identify the medial collateral ligament, medial meniscus, and proximal margin of the articular process. It is important that the stifle was not locked or in tension. Skin staples were placed cranial to the medial collateral ligament 30 mm proximal to the proximal margin of the articular process. A fourth staple was placed 10 mm cranial to the medial collateral ligament (MCL) and 15 mm proximal to cartilage. In some cases, a lateromedial radiograph was used to reassure the position of the staple in relation to the craniocaudal position of the SCL.[2] A 15-mm vertical stab incision was made perpendicular to the skin surface and soft tissues 5 mm cranial to the MCL and centered 10 mm proximal to the palpable proximal margin of the articular cartilage of the medial condyle.[2] A tissue guide and a 4.5-mm drill bit were placed proximal to the medial femoral condyle (MFC) cartilage, angled proximodistal to intersect the center of the medial intercondylar eminence and drilled until the cyst was entered. The drill insert was then placed into the 4.5-mm glide hole and a 3.2-mm bit was used to continue the tract axially. For assessing the position of the drill bits and screw, intraoperative multiple caudal to cranial 20° stifle radiographs were taken. The 3.2-mm bit was then cleaned of bone before minimally penetrating the axial aspect of the condyle. In some cases, biologic therapy was injected into the SCL before the screw was placed. The hole was measured and tapped, and a properly measured 4.5-mm cortical screw was placed and tightened. Most screws were placed across the condyle perpendicular to the

Table 1. Outcomes for Horses and for Number of Stifles Operated

Number of Horses	Successful Outcome	Negative Outcome	Unknown Outcome
58	46 for 79.3%	8 for 13.8%	4 for 6.9%
Number of Stifles	Successful Outcome	Negative Outcome	Unknown Outcome
69	57 for 82.6%	8 for 11.6%	4 for 6.9%

Table 2. Outcomes on Operated Stifles Ranked by Age of Horses

Age of Horse	Number of Horses	Number of Stifles	Successful Stifle Outcome	Unsuccessful Stifle Outcome	Unknown Outcome
1 year	16	20	17 for 85%	3 for 15%	—
2 years	27	31	25 for 80%	4 for 13%	2 for 7%
3 years	5	6	3 for 50%	1 for 17%	2 for 33%
4 years	4	5	5 for 100%		
5 years or >	6	7	7 for 100%		

Table 3. Gender

Gender	Number of Horses	Number of Stifles Affected	Success Horse	Success Stifle
Male	35	42	31 for 88.6%	38 for 90.5%
Female	23	27	18 for 80%	20 for 74%

sagittal plane.[16] Routine skin closure was performed, and a layer of skin glue was placed over the sutures.

Grading Lesions

Lesions were graded according to a previous assessment system.[19] Lesion grades were as follows: grade 1 demonstrates flattening or a small defect on the subchondral bone, grade 2 is <10 mm in depth and usually has a dome-shaped lucency, grade 3 has a condylar lucency with no evidence of cloaca, grade 4 demonstrates a > 10-mm defect with a large dome extending to the articular surface, grade 5 is defined as a > 10-mm lucency with a narrow cloaca at the articular surface and a mushroom shape, and grade 6 is similar to grade 4 or 5 SCL with other lucencies in the caudal MFC or proximal medial tibial plateau.[18,19]

Postoperative Protocol

The standard postoperative protocol consisted of oral phenylbutazone (2.2 mg/kg) the day of and 3 days after surgery. Initially restricted exercise included 2 to 4 weeks of stall rest, followed by hand walking for 30 minutes twice a day for 2 weeks and then access to a small paddock for 30 days. After 60 days, patients were allowed pasture exercise and returned to normal work or training at 90 days.

3. Results

This retrospective study includes 58 Quarter Horses presented for transcondylar screw placement in their medial femoral condyle subchondral cystic lesions. Different parameters subdivided the group. Some cases presented bilateral lesions, and the outcome per limb was different. Some of the criteria classified the information by stifle (counting a total of 69) and other items were classified by horse (58) (Table 1).

Age and Gender Distribution

Patients were divided by age groups (Table 2): 16 horses were 1 year of age (28% horses, 29% stifles), 27 were 2 years (46% horses, 45% stifles), 5 were 3 years (9% horses, 9% stifles), 4 were 4 years (7% horses, 7% stifles), and 6 were 5 years or older (10% horses, 10% stifles). The success rate on stifles operated was 85% for 1-year-old horses, 80% for 2-year-old horses, 50% on 3-year-old horses, 100% on 4-year-old horses, and 100% on 5-year-old or older horses. These data show that the biggest population presenting for MFC SCLs is under 3 years. Of the 58 patients, 23 (39.7%) were mares and 35 (60.3%) were geldings or stallions (Table 3).

Presentation and Grading

Patients were classified by the grade of the cyst on presentation and, if bilateral, right hind or left hind (Table 6). The distribution based on laterality demonstrated that bilateral presentation is less common, given that 11 horses were presented with bilateral cysts representing 19%. Distribution on horses with a unilateral SCL was very similar; 25 horses (43%) had an SCL on the left hind and 22 (38%) on the right hind (Table 4). The cystic lesions were divided by grade in each of the previously mentioned categories. A total of 69 stifles with SCL were treated. From the 11 patients with bilateral cystic lesions (22 stifles), 1 (4.5%) was classified as a grade 5 cyst, 12 lesions (54%) were grade 4 cysts, 6 (27.3%) were grade 3 cystic lesions, 2 (9%) were grade 2 cysts, and 1 lesion was grade 1 (4.5%). Of the 25 patients with left hind MFC cystic lesions, 8% (2) had a grade 5 lesion, 52% (13) had a grade 4 lesion,

Table 4. Limb Affected

Limb Affected	Number Horses	%
Bilateral	11	19%
Left hind	25	43%
Right hind	22	38%

32% (8) had a grade 3 lesion, and 8% (2) had a grade 2 lesion; no patients had a grade 1 lesion on the left hind. From the 22 patients with MFC cystic lesions on the right hind, 4.5% (1) had a grade 5 lesion, 77.27% (17) had a grade 4 lesion, 13.36% (3) patients presented a grade 3 lesion, 4.5% (1) patients had a grade 2 lesion, and no patients were presented with a grade 1 lesion.

Follow-Up Time

Of the 58 horses involved, 18 had a follow-up of a year or less and 14 (77.7%) had successful outcomes (Table 5). Horses that had successful outcomes were those that at time of follow-up were back to their previous activity level, performing at intended use or horses that were not performing but were sound on a recheck lameness exam or follow-up radiographs. Of 16 horses that had a follow-up of 1 year, the success rate was 75% (12 horses). Eight horses had a 2-year follow-up, and the result for one of them is unknown, because the horse never performed again and is used for breeding. The success rate was 87.5% for horses with a 2-year follow-up. Of the 3 horses with a 3-year follow-up, the success rate was 100% with all still performing. Six horses had a 4-year follow-up, and one of them is not performing, showing an 83.3% success on the 4-year follow-up. Of the 6 horses that had a 5-year follow-up, 100% of them were successful, with all performing well. The 1 horse that had a 7-year follow-up is sound.

Radiographic follow-up was recorded in 10 of the horses involved, one of them with a bilateral defect (Table 6). The mean age of this subgroup at time of surgery was 30 months, and the mean follow-up time was 12 months. All of these horses demonstrated reduction in the cysts size. The mean cyst size reduction was 47%. Eighty percent of these horses returned to performance and 20% of horses had an unknown outcome. For the horse with bilateral pathology, on the 3-month follow-up radiographs, the cyst on the left stifle was found enlarged and the screw had to be replaced, and the right stifle did not present complications. Follow-up radiographs on that horse 5 months after the screw replacement demonstrated a decrease in size on the left stifle of 10 × 3 mm (67.9%), and in the right the cyst was completely resolved.

General Distribution

Of 69 stifles that were submitted to the study, 5.8% were presented with a grade 5 cystic lesion and all had a successful outcome, 60.9% presented a grade 4 MFC subchondral cystic lesion with an 85.7% success rate, 24.6% of stifles had a grade 3 lesion and 76.5% had a successful outcome, 7.2% had a grade 3 lesion with a 100% success rate, and 1.5% had a grade 1 lesion and a successful outcome.

Table 5. Follow-Up Time and Outcome Tracking

Time	Number of Horses	Positive	Negative	Unknown
<1 year	18	14	3	1
1 year	16	12	3	1
2 years	8	7		1
3 years	3	3		
4 years	6	5	1	
5 years	6	6		
7 years	1	1		

Table 6. Grade of Cyst Per Stifle

	Grade 1	Grade 2	Grade 3	Grade 4	Grade 5
Bilateral (22)	1	2	6	12	1
Left hind (25)	0	2	8	13	2
Right hind (22)	0	1	3	17	1
Success	100%	100%	76.5%	85.7%	100%

Supplements and Other Treatments

Another category considered was use of supplements during or after surgery and how this affected the outcome. The population that received supplements had either Platinum Performance Osteon a (natural zeolite) and or Platinum Performance CJ (glucosamine, hyaluronic acids, MSM [methylsulfonylmethane]). Some patients had arthroscopy and platelet-rich plasma (PRP), as well as polyglycans injected, stem cells injected, and Adequan. Patients that did not receive any kind of supplements represented 62.1% (36 horses) of the total population. Of these 36 unsupplemented horses, 88.8% had a successful outcome, 8.3% did not have a successful outcome, and for the remaining 2.7%, the outcome is unknown. Of the 14 (24.1%) patients that received Platinum Performance CJ and Osteon, 92.5% had successful outcomes, and for 1 horse, the result was unknown. The horse that had an arthroscopy and received PRP had a successful outcome. The final result on the horse that received proteoglycan is unknown. One horse received stem cell injections and the result was successful. The horse that had Adequan injected was sound.

Complications

Four horses (6.9%) had complications listed as failure to engage enough opposite cortex, enlargement of the cyst after screw placement, development of a tibial cyst (2 horses), and cartilage damage on the affected joint and osteoarthritis on the affected joint. Twenty-five percent of this population still became sound.

4. Discussion

SCLs are known to cause lameness in horses and have been identified in multiple locations in the forelimbs

and hindlimbs. Equine subchondral bone cysts develop most often in the MFC. The etiology of cystic bone lesions in horses is not well defined. Some studies support an inflammatory response, due to trauma and to impaired weightloading over the joint. This retrospective study involved 58 Quarter Horses with a total of 69 stifles presented for a transcondylar screw placement in medial femoral condyle subchondral cystic lesions. Data show that most Quarter Horses presenting with MFC SCL are under 3 years of age and the age range is more varied than reported in other breeds. Previous studies report that the development of SCL is more common in horses ≤2 years of age,[18] and when occurring in older horses, the prognosis is reduced.[2,18] This report shows 100% success rate on 4-year-old patients and older than 5 years compared to 85% success on horses that are 1 year old and 80% on horses that are 2 years old at the time of surgery, although the case number is very small. The number of patients that are 4 years old and 5 years old or older cannot be considered representative because there were only 4 horses. Further research should be done in older horses for a more reliable statistic.

Eleven horses (18% of the population) presented with SCL in both stifles, demonstrating that it is quite common to present the lesion in more than 1 limb. No significant difference was shown in the distribution per limb affected. Of the 11 horses with bilateral MFC SCL, 17 of the 22 stifles (77.3%) showed a successful outcome. The result in 1 horse with bilateral MFC SCL (9%) is unknown. Three stifles (13.6%) had an unsuccessful outcome. Two of these horses demonstrated radiographic improvement in just 1 limb; however, both patients were sound and are back in full work. One of the horses with bilateral SCLs had an unsuccessful outcome due to the development of a tibial cyst and has been unable to return to intended activity. From a total of 69 stifles that were submitted to the study, 59.4% presented a grade 4 MFC subchondral cystic lesion, with this grade the most frequently presented with an 85.7% success rate, and 24.6% of the stifles had a grade 3 lesion with a 76.5% rate of successful outcome. Both are considered representative samples given the number of horses per group. This outcome supports what has been shown in previous studies, in which 75% of the horses had shown resolution, in that study resolution was considered a resolution of the lameness and increase in radiographic density.[20] Of horses with unsuccessful outcomes, 2 developed a tibial SCL within the first year of follow-up (4 and 10 months) after the transcondylar screw placement. None of these showed obvious signs of osteoarthritis on radiographs. The horse that developed a tibial cyst at 10 months was a mare with bilateral MFC SCLs. There are reports of cases that developed a tibial subchondral cystic lesion together with an MFC SCL.[4,13] This was a finding on postmortem examination on horses that were previously treated medically for an MFC SCL in which the medial tibial condyle SCL was described as round and lined with fibrous tissue that contained yellow gelatinous material.[4] A recent study suggests that damage to the articular surface of the medial femoral condyle could cause an adjacent lesion in the opposing tibial condyle by abrasion or repetitive trauma, subsequently promoting formation of a tibial SCL.[4] Four types of tibial SCLs have been described. SCLs that affect the lateral condyle of the tibia have been described in young horses as well as a manifestation of osteochondrosis, whereas SCLs affecting the medial tibial condyle are observed in older horses with evidence of osteoarthritis and have been related with poor prognosis. Other described but less common cystic lesions are in the intercondylar eminence and in the distal tibial epiphysis. One horse with an unsuccessful outcome had an enlargement on the cyst. Further investigation would be required to determine the cause of the enlargement. Gender was a subdivision in the attempt to see its impact on the outcome. In total, 73.9% of mares and 88.57% of geldings or stallions had a successful outcome. This does not make a statistical difference, and it can be supported by previous research where no relation between gender and outcome is suggested.[20] The percentage of success on horses without supplements was 88.9%; CJ and osteon, 92.9%; arthroscopy and PRP, 100%; polyglycan, 0%; stern cells, 100%; and Adequan, 100%. This supports a previous study that shows no evidence on supplements influencing the outcome of patients that received this treatment.[20] Follow-up time was another factor considered. Of the 58 horses involved, 18 had a follow-up of a year or less and 14 (77.7%) of them had successful outcomes. One of the 3 unsuccessful cases of this group showed improvement on the 60-day recheck and later developed a suspensory desmopathy, so the horse is not currently performing. Two horses in the unsuccessful group developed a tibial cyst in the first months; the remaining horse of the group is coursing his first month postoperatively, so the postoperative recheck is pending. Of the 16 horses that had a 1-year follow-up, the success rate was 75% (12 horses). Eight horses had a 2-year follow-up and the result of one of them is unknown, because the horse is currently just used for breeding. The success rate was 87.5% for horses with a 2-year follow-up; in this case, basing follow-up on having the horse back to work is not reliable, and new sets of radiographs to confirm success would be ideal. Of the 3 horses with a 3-year follow-up, the success rate was 100%; 6 horses had a 4-year follow-up, and one of them is not performing. The radiographs on the first recheck showed no reaction and the owner did not feel a complete improvement on the stifle. This result shows an 83.3% success rate on the 4-year follow-up and supports that the radiographic follow-up is important to determine the resolution of the SCL; in this case, the first radiographic study postoperatively shows no improvement and the telephone follow-up supports that 6 horses that had a 5-year follow-up showed a 100% success rate, with all of them still performing. The 1 horse that has had a 7-year follow-up is also performing well. This suggests that 4 years after the surgery, the likelihood of having changes in the outcome is lower. On the other hand, the shorter timed follow-up

Table 7. Cyst Reduction on Horses With Radiographic Follow-Up

	Age in Months	Stifle	Size Before Surgery (mm)	Size After Surgery (mm)	% Size Reduction	Follow-up time in Months	Outcome
	12	L	28 × 29	12 × 14	79.31	24	Back to work
	24	L	18 × 5	15 × 4	33.33	36	Back to work
	15	L	10 × 15	9 × 13	22	24	Back to work
	36	L	15 × 20	11 × 20	26.66	2	Unknown
	48	L	15 × 16	9 × 16	40	4	Back to work
	24*	R	10 × 21	0	100	8	Unknown
	24*	L	16 × 21	6 × 18	67.85	8	Unknown
	24	R	17 × 18	17 × 13	27.77	5	Back to work
	60	R	17 × 20	10 × 18	47.05	11	Back to work
	48	L	11 × 18	9 × 15	31.81	7	Back to work
	24	L	9 × 16	7 × 12	41.66	4	Back to work
Mean	30.81				47.04	12.09	

*Same horse with both stifles treated.

changes occurred, as the 2 horses that developed tibial cysts did so on the first year of follow-up. These results suggest that a yearly radiographic follow-up in the first 2 years after surgery should be suggested. The radiographic follow-up recorded in 10 of the horses involved, one of them with a bilateral defect (Table 7), demonstrated a mean 47% reduction in cyst size, and the horse that had less improvement had a 22% decrease on cyst size. This result can be supported by previous reports where 100% of cases with radiographic follow-up have at least a 50% decrease in cyst size.[2,16] The mean follow-up time on these horses was 12 months, and the mean age at the time of surgery was 30 months. In just one of the cases with a bilateral defect, the cyst was resolved after an 8-month follow-up; in this case, a screw replacement was necessary on the left stifle as the cyst was getting enlarged, and the right side kept recovering favorably.

5. Conclusion

The present study demonstrates that MFC SCLs are more frequent in Quarter Horses aged 1 to 3 years old. All 58 horses that were part of the study underwent transcondylar screw placement, making a total of 69 stifles. In total, 79.7% of stifles had a successful outcome, which is similar to previous studies; 11.6% of stifles had an unsuccessful outcome; and 2 horses from this group had an unsuccessful outcome due to the development of a tibial subchondral cyst. The results support there is no correlation between gender and likelihood of developing MFC SCLs. An interesting point that has been shown in this study is that most changes in the outcome of patients treated with a transcondylar screw are seen the first 2 years after surgery. It also supports previous studies that have shown that no relation is observed between supplements administration and the outcome. The 10 horses that had a radiographic follow-up had at least a 22% reduction in cyst size, with a mean of 47%. These results are encouraging because they demonstrate that cyst size reduction is achievable. The limitations of this study are the retrospective descriptive nature and the lack of standardized follow-up data. It would have been valuable to acquire radiographic follow-up on all the patients involved and assessment of healing in all patients in the study.

Acknowledgments

Declaration of Ethics

The Authors have adhered to the Principles of Veterinary Medical Ethics of the AVMA.

Conflict of Interest

One Author, Troy Herthel, was related to the former owner of Platinum Performance Co.

References

1. Denoix JM, Jeffcott LB, McIlwraith CW, et al. A review of terminology for equine juvenile osteochondral conditions (JOCC) based on anatomical and functional considerations. *Vet J* 2013;197:29–35.
2. Santschi EM, Williams JM, Morgan JW, et al. Preliminary investigation of the treatment of equine medial femoral condylar subchondral cystic lesions with a transcondylar screw. *Vet Surg* 2015;44:281–288.
3. Balducci JJ, Barrett MF, Moorman VJ. Surgical treatment of an osseous cyst-like lesion in the middle phalanx communicating with the distal interphalangeal joint of a horse. *J Equine Vet Sci* 2019;78:138–143.
4. Bonilla AG, Williams JM, Litsky AS, et al. Ex vivo equine medial tibial plateau contact pressure with an intact medial femoral condyle, with a medial femoral condylar defect, and after placement of a transcondylar screw through the condylar defect. *Vet Surg* 2015;44:289–296.
5. Jenner F. Treatment of osseous cyst-like lesions. *Equine Vet Educ* 2021;33:345–348.
6. Jeffcott LB, Kold SE, Melsen F. Aspects of the pathology of stifle bone cysts in the horse. *Equine Vet J* 1983;15:304–311.
7. Sherlock C, Mair T. Osseous cyst-like lesions/subchondral bone cysts of the phalanges. *Equine Vet Educ* 2011;23:191–204.
8. von Rechenberg B, McIlwraith CW, Auer JA. Cystic bone lesions in horses and humans: a comparative review. *Vet Comp Orthop Traumatol* 1998;11:8–18.

9. Lemirre T, Santschi EM, Girard CA, et al. Microstructural features of subchondral radiolucent lesions in the medial femoral condyle of juvenile Thoroughbreds: A microcomputed tomography and histological analysis. *Equine Vet J* 2021;54(3):601–603.
10. Naccache F, Metzger J, Distl O. Genetic risk factors for osteochondrosis in various horse breeds. *Equine Vet J* 2018;50:556–563.
11. Ray CS, Baxter GM, McIlwraith CW, et al. Development of subchondral cystic lesions after articular cartilage and subchondral bone damage in young horses. *Equine Vet J* 1996;28:225–232.
12. Williams JM, Santschi EM. Pathological fracture through a subchondral bone cyst in the proximal phalanx of a horse. *Equine Vet Educ* 2017;29:299–303.
13. Bonilla AG, Bertone AL, Brokken MT, et al. Concurrent or sequential tibial subchondral cystic lesions in 4 horses with medial femoral condyle subchondral cystic lesions. *J Am Vet Med Assoc* 2016;249:1313–1318.
14. Stewart HL, Kawcak CE. The importance of subchondral bone in the pathophysiology of osteoarthritis. *Front Vet Sci* 2018; 5:178.
15. Ortved KF, Nixon AJ, Mohammed HO, et al. Treatment of subchondral cystic lesions of the medial femoral condyle of mature horses with growth factor enhanced chondrocyte grafts: A retrospective study of 49 cases. *Equine Vet J* 2012;44:606–613.
16. Santschi EM. Treatment options and long-term outcomes of horses with subchondral lucencies of the medial femoral condyle. *Equine Vet Educ* 2021;33:386–388.
17. Smith MA, Walmsley JP, Phillips TJ, et al. Effect of age at presentation on outcome following arthroscopic debridement of subchondral cystic lesions of the medial femoral condyle: 85 horses (1993-2003). *Equine Vet J* 2010;37:175–180.
18. Frazer LL, Santschi EM, Fischer KJ. The impact of subchondral bone cysts on local bone stresses in the medial femoral condyle of the equine stifle joint. *Med Eng Phys* 2017;48:158–167.
19. Wallis TW, Goodrich LR, McIlwraith CW, et al. Arthroscopic injection of corticosteroids into the fibrous tissue of subchondral cystic lesions of the medial femoral condyle in horses: A retrospective study of 52 cases (2001–2006). *Equine Vet J* 2008;40:461–467.
20. Frazer LL, Santschi EM, Ring SJ, et al. Impact of size and shape of equine femoral subchondral bone cysts with a transcondylar screw on predicted bone formation area in a finite element model. *J Biomech Eng* 2020;142(6): 061010.

Recurrent Colic: An Important yet Poorly Understood Problem

Louise L. Southwood, BVSc, PhD, DACVS, DACVECC

Author's address: New Bolton Center, University of Pennsylvania, 382 West Street Road, Kennett Square, PA 19348; e-mail: southwoo@vet.upenn.edu. © 2022 AAEP.

1. Definition

Recurrent colic has been defined as "a colic episode diagnosed by a veterinary surgeon or displaying behavioral signs of colic in the case of owner reported colic, on the proviso that the horse had been free from colic signs, eating a normal diet and passing normal feces for a full 48 h since the end of the previous colic episode."[1,2] The frequency of colic episodes leading to a horse being diagnosed with recurrent colic has been defined as three or more transient (less than 24 hours duration) or prolonged (longer than 24 hours duration) colic episodes diagnosed within 1 month or 1 year,[3] or "two or more episodes of colic within a 6-month period of time, with at least 48 hours between colic episodes."[4] Most of these definitions have only included horses with medically managed colic and excluded horses with recurrent colic episodes undergoing surgery. Recurrent colic has also been called chronic intermittent colic.[5] The most recent report of recurrence was 50 colic events per 100 horse years at risk.[1]

2. Causes of Recurrent Colic and Diagnostic Tests

There are limitless causes of recurrent colic. In an earlier study of recurrent colic,[3] some of the more common causes included lymphoma, recurrent tympanic/spasmodic colic, recurrent impaction, intussusception, partial ileal obstruction, adhesions, and thromboembolic disease/verminous arteritis. While in some instances, causes of recurrent colic may be apparent when a thorough history is obtained and with various diagnostic tests (Table 1),[6–20] in the majority of horses, the cause is not identified. Even in horses with recurrent displacements,[21] or impaction, the reasons for the recurrence are often undetermined. Most of the studies completed to date have been epidemiological studies focusing on management practices that tend to predispose horses to recurrent colic (Table 2).[1,2,5] While addressing management factors associated with recurrent colic, including diet, dental problems, and parasite control programs, may help some horses, there remains a population of horses with unexplained recurrent colic. These horses can become a challenge to diagnose and manage.

There are several case reports and small case series published identifying histological changes in horses with recurrent colic.[7,8,16,22–29] Neuropathies (associated with damage to the myenteric plexus), myopathies, secondary neuromuscular disorders, and inadequate interstitial cells of Cajal can cause gastrointestinal motility disorders and recurrent colic.[22] More recently, recurrent colic has been associated with myenteric ganglionitis (some of these horses had lymphocytic-plasmacytic infiltration into the lamina propria, submucosa, and through to the myenteric plexus),[22,24,25] lower myenteric plexus density and increased enteroglial cell numbers,[26] fibrosis of the intestinal muscle layers,[8,27] inflammatory bowel disease,[28] and decreased density of the interstitial cells of Cajal (pacemaker cells that create the bioelectrical

NOTES

Table 1. Examples of Reasons for or Causes of Recurrent Colic

Location	Lesion	Diagnosis	Management or Treatment
Stomach	Gastric ulceration	Gastroscopy	Diet modification Omeprazole Sucralfate Misoprostol Ranitidine
	Pyloric lesions[6]	Gastroscopy (caudal esophagitis, delayed emptying, ulceration) Transabdominal ultrasonography Contrast radiography (delayed gastric emptying)	Diet modification Antiulcer medication Gastrojejunostomy
	Gastric impaction (gross muscular thickening; histological focal myositis and fibrosis)[7]	Gastroscopy Transabdominal ultrasonography	Gastric lavage Gastrojejunostomy
Small intestine	Adhesions	Transabdominal ultrasonography Exploratory laparoscopy or laparotomy	Diet modification Laparoscopic adhesiolysis Laparotomy with adhesiolysis or intestinal resection and anastomosis
	Stenotic anastomosis (prior surgery especially jejunocecostomy)	Exploratory laparotomy	Revision of previous anastomosis
	Ileocecal intussusception	Transabdominal or transrectal ultrasonography Exploratory laparotomy	Abdominal surgery Reduction/jejunocecostomy Cestodicide (praziquantel)
	Muscular hypertrophy with or without diverticula formation	Palpation per rectum Transabdominal ultrasonography Exploratory laparotomy or laparoscopy with biopsy	Intestinal resection and anastomosis if localized Bypass with jejunocecostomy if localized to ileum Euthanasia if generalized or inaccessible
	Neoplasia	Transabdominal ultrasonography Duodenal biopsy (endoscopically obtained) Exploratory laparotomy Necropsy	Intestinal resection and anastomosis if localized Euthanasia if generalized or inaccessible
	Proliferative enteropathy (*Lawsonia intracellularis*)	Foals and weanlings (typically) Weight loss or failure to thrive and diarrhea Hypoproteinemia/hypoalbuminemia Transabdominal ultrasonography Fecal polymerase chain reaction Serum antibody titers Biopsy	Supportive care Tetracycline Chloramphenicol Macrolides
Cecum	Cecal impaction (secondary to muscular hypertrophy)[8]	Palpation per rectum	Cecal bypass with jejunocolostomy Euthanasia
	Cecocecal or cecocolic intussusception	Palpation per rectum Transabdominal ultrasonography Exploratory laparotomy	Surgical reduction/partial typhlectomy Praziquantel
	Neoplasia	See small intestine	Partial typhlectomy if localized Euthanasia if generalized

(continued on next page)

Table 1. (Continued)

Location	Lesion	Diagnosis	Management or Treatment
Large colon	Enterolithiasis	Abdominal radiography Exploratory laparotomy	Enterotomy
	Sand enteropathy	Transabdominal ultrasonography Abdominal radiography Exploratory laparotomy	Medically psyllium, $MgSO_4$, oil[9–11] Surgically via an enterotomy
	Lymphocytic/plasmacytic or eosinophilic enterocolitis	Transabdominal ultrasonography Rectal biopsy Exploratory laparoscopy or laparotomy (biopsy)	Corticosteroid treatment (possibly)
	Nephrosplenic entrapment	Palpation per rectum Transabdominal ultrasonographic examination	Nephrosplenic space ablation[12–15] Colopexy Colon resection
	Right dorsal displacement and large colon volvulus	Palpation per rectum Transabdominal ultrasonographic examination Exploratory laparotomy	Diet modification [Transfaunation] [Motility modification] Colopexy Colon resection
	Neoplasia	See small intestine	Colon resection if localized Euthanasia if generalized
	Right dorsal colitis with or without stenosis*	History of NSAID administration Hypoproteinemia/hypoalbuminemia Transabdominal ultrasonography Exploratory laparotomy	Avoid NSAIDs Misoprostol Omega-3 fatty acids Diet modification Bypass right dorsal colon with colocolostomy Resection of right dorsal colon and colocolostomy
Small colon	Small colon impaction (secondary to myenteric ganglionopathy)[16]*	Palpation per rectum Biopsy	Medical or surgical treatment Diet modification Euthanasia
Non-GI	Choledocholilithiasis[17]*	Liver profile Transabdominal ultrasonography Liver biopsy Bacterial culture and sensitivity	Supportive care Antimicrobials[18] Fragmentation without choledocholilithotomy Choledocholithotripsy[19] Choledocholithotomy[20]
	Abdominal abscessation*	Palpation per rectum Transabdominal or transrectal ultrasonography Fibrinogen and serum amyloid A Peritoneal fluid analysis Bacterial culture and sensitivity	Antimicrobial drugs (systemic and local) En bloc resection Bypass of affected intestine Drainage

*Uncommon. NSAID, nonsteroidal anti-inflammatory drugs; GI, gastrointestinal.

slow

Table 2. Epidemiological Findings Associated with Recurrent Colic[1,2,5]

Previous colic episode
History of colic surgery
> 8 years old
Geldings
Recent change in diet
[Feeding coastal grass hay]
Recent change in stabling
Farm density < 0.5 horses/acre
Dental problems
Crib biting/windsucking
Weaving behavior
Less time at pasture

wave potentials that lead to smooth muscle contraction).[29] As already mentioned, these are primarily case reports, and in the majority of horses with recurrent colic, it is unknown if these histological changes exist.

Intestinal biopsy is indicated to identify the aforementioned histological changes. In horses with generalized intestinal mucosal inflammation or neoplasia, duodenal biopsy obtained via an endoscopic approach or rectal biopsy may be useful.[30] In a recent retrospective study, however, rectal biopsy was found to be significantly less useful for obtaining a diagnosis in horses with recurrent colic compared to a biopsy obtained via an exploratory laparoscopy or laparotomy.[4] Similarly, another group of authors concluded that while duodenal and rectal biopsies may be useful for diagnosing inflammatory bowel disease, care must be taken with interpretation until there is more standardization of biopsy technique and histological scoring.[31] It is important to recognize that only a mucosal sample is obtained from the duodenum and rectum, and therefore any changes in the submucosa and muscle layers cannot be evaluated. Intestinal biopsy is recommended in any horse undergoing exploratory laparotomy with a history of recurrent colic unless the reason for recurrent colic is readily apparent during surgery. Single or multiple small full thickness biopsies can be obtained using an 8-mm biopsy punch during laparotomy. The biopsy site can be closed using 3-0 or 2-0 synthetic absorbable suture in a cruciate pattern then oversewn with a Cushing or Lembert pattern. Samples can also be obtained from an enterotomy or enterectomy site; however, additional samples from distant sites would likely be more representative of global infiltrative disease. Biopsies should be obtained early during abdominal exploration, and care does need to be taken with interpretation of intestinal biopsies taken during exploratory celiotomy. Hopster-Iversen et al. reported that intestinal manipulation resulted in an increase in neutrophilic inflammation as well as the migration of eosinophils toward the intestinal lumen.[32] Furthermore, there may be variation between pathologists in biopsy interpretation principally because the normal histological appearance of the equine intestine has not been well defined.[4] Care must also be taken with biopsy sample handling because forceps can cause sufficient damage to prevent evaluation.[4] One other challenge with the interpretation of histological findings is whether the observed changes are a cause or an effect of recurrent colic.[4]

In a recent study retrospectively evaluating gastrointestinal biopsies, inflammatory cellular infiltrates (54%) and neoplasia (22%) were the most common histological diagnosis categories associated with recurrent colic.[4] Lymphocytic-plasmacytic was the most common inflammatory infiltrate in cases of recurrent colic.[4] The relationship between recurrent colic (including colonic displacements), inflammatory bowel disease, management factors (including parasite control and diet), and the microbiome is an active area of research. A possible link between dysbiosis, intestinal inflammation, gastric ulcers, and stereotypic behavior (crib biting/windsucking, weaving) warrants further investigation.

3. What Can Be Done to Help These Horses and Horse Owners?

Recurrent colic is a frustrating and stressful problem for owners and caregivers. Horses with recurrent colic require a complete examination including obtaining a thorough history to identify management factors that may predispose the horse to colic, complete physical examination including abdominal palpation per rectum, transabdominal ultrasonographic examination (and radiographic examination depending on the geographical region), gastroduodenoscopy with biopsy, and rectal biopsy. Other diagnostic tests such as plasma biochemistry profile, peritoneal fluid analysis, and polymerase chain reaction, enzyme-linked immunosorbent assay, or antibody titers for specific diseases may be indicated depending on the signalment and results of other diagnostic tests (Table 1). Exploratory laparoscopy or laparotomy with intestinal biopsy is indicated if a diagnosis is not obtained with the results of the less invasive tests.

Treatment can be challenging. Some diseases have fairly straightforward treatment (Table 1). However, others are more problematic. Surgical procedures such as nephrosplenic space ablation, colopexy, and colon resection should be considered in horses with definitive diagnosis of specific colonic displacements or volvulus. It is important that owners recognize that these surgical procedures can be extremely beneficial; however, can be associated with complications and that they do not prevent tympanic/spasmodic colic. For example, nephrosplenic space ablation was more effective for preventing nephrosplenic ligament entrapment of the large colon in horses with a definitive surgical diagnosis compared to horses with a presumed diagnosis on palpation per rectum of nephrosplenic ligament entrapment.[15] Management factors should always be explored (diet, housing, exercise regimen, water source, dental care, parasite control). Corticosteroid therapy may be beneficial in some horses diagnosed with inflammatory bowel disease;[4,33]

however, long-term treatment with low-dose corticosteroids may be necessary in horses diagnosed with lymphocytic-plasmacytic inflammation. Owners should be warned about the risks of infection and laminitis in horses receiving corticosteroids. Cetirazine has been used to treat eosinophilic inflammation and may be used seasonally when the horse has more problems with recurrent colic; however, the efficacy of cetirazine has not been objectively evaluated in horses with eosinophilic intestinal inflammation. Bethanechol has been evaluated as a motility stimulant in horses[34–36] and may prove beneficial in management of recurrent colic. The role of dysbiosis in recurrent colic and benefit of fecal transfaunation[37] is another critical area of research.

Unfortunately, if colic recurrence is frequent, severe, or persistent, humane euthanasia is often elected by owners. It is an important role of the primary care and specialist veterinarian to discuss the option of euthanasia with owners. The decision for euthanasia is an individual owner decision and often made based on poor response to treatment, use of the horse, perceptions of suffering, comorbidities, and finances.

Recurrent colic is an important yet poorly understood problem in horses. Understanding the role of breed, diet, dysbiosis, and inflammation as well as the relationship between stereotypic behaviors (e.g., crib biting), gastric ulceration, and colonic disease is an important area of research.[1,2,4,5,15,38,39] Elucidation of underlying causes and disease processes through a team approach with owners, caregivers, primary and tertiary care veterinarians, and clinical researchers will hopefully lead to better management options in affected horses.

Acknowledgments

Declaration of Ethics

The Author has adhered to the Principles of Veterinary Medical Ethics of the AVMA.

Conflict of Interest

The Author has no conflicts of interest.

References

1. Scantlebury CE, Archer DC, Proudman CJ, et al. Recurrent colic in the horse: Incidence and risk factors for recurrence in the general practice population. *Equine Vet J* 2011;43:81–88.
2. Scantlebury CE, Archer DC, Proudman CJ, et al. Management and horse-level risk factors for recurrent colic in the UK general equine practice population. *Equine Vet J* 2015;47:202–206.
3. Hillyer MH, Mair TS. Recurrent colic in the mature horse: a retrospective review of 58 cases. *Equine Vet J* 1997;29:421–424.
4. Stewart HL, Engiles J, Stefanovski D, et al. Clinical and intestinal histologic features of horses treated for recurrent colic: 66 cases (2006-2015). *J Am Vet Med Assoc* 2018;252:1279–1288.
5. Cohen ND, Peloso JG. Risk factors for history of previous colic and for chronic, intermittent colic in a population of horses. *J Am Vet Med Assoc* 1996;208:697–703.
6. Bezdekova B, Wohlsein P, Venner M. Chronic severe pyloric lesions in horses: 47 cases. *Equine Vet J* 2020;52:200–204.
7. Bird AR, Knowles EJ, Sherlock CE, et al. The clinical and pathological features of gastric impaction in twelve horses. *Equine Vet J* 2012;44:105–110.
8. Huskamp B, Scheidemann W. Diagnosis and treatment of chronic recurrent caecal impaction. *Equine Vet J Suppl* 2010;32:65–68.
9. Niinistö KE, Ruohoniemi MO, Freccero F, et al. Investigation of the treatment of sand accumulations in the equine large colon with psyllium and magnesium sulphate. *Vet J* 2018;238:22–26.
10. Kaikkonen R, Niinistö K, Lindholm T, et al. Comparison of psyllium feeding at home and nasogastric intubation of psyllium and magnesium sulfate in the hospital as a treatment for naturally occurring colonic sand (geosediment) accumulations in horses: A retrospective study. *Acta Vet Scand* 2016;58:73.
11. Niinistö K, Hewetson M, Kaikkonen R, et al. Comparison of the effects of enteral psyllium, magnesium sulphate and their combination for removal of sand from the large colon of horses. *Vet J* 2014;202:608–611.
12. Gandini M. How effective is surgical closure of the nephrosplenic space in preventing recurrent colic in horses? *Vet Rec* 2019;185:655–656.
13. Arévalo Rodríguez JM, Grulke S, Salciccia A, et al. Nephrosplenic space closure significantly decreases recurrent colic in horses: A retrospective analysis. *Vet Rec* 2019; 185:657–657.
14. Nelson BB, Ruple-Czerniak AA, Hendrickson DA, et al. Laparoscopic closure of the nephrosplenic space in horses with nephrosplenic colonic entrapment: Factors associated with survival and colic recurrence. *Vet Surg* 2016;45:O60–O69.
15. Burke MJ, Parente EJ. Prosthetic mesh for obliteration of the nephrosplenic space in horses: 26 clinical cases. *Vet Surg* 2016;45:201–207.
16. Ortolani F, Nannarone S, Sforna M, et al. Diagnostic and clinical course of small colon recurrent impaction associated with severe myenteric ganglionopathy in a mare. *J Equine Vet Sci* 2021;101:103453.
17. Ryu S, Bak U, Lee C, et al. Cholelithiasis associated with recurrent colic in a Thoroughbred mare. *J Vet Sci* 2004;5:79–82.
18. Peek SF, Divers TJ. Medical treatment of cholangiohepatitis and cholelithiasis in mature horses: 9 cases (1991-1998). *Equine Vet J* 2000;32:301–306.
19. Tulleners EP, Becht JL, Richardson DW, et al. Choledocholithotripsy in a mare. *J Am Vet Med Assoc* 1985;186: 1317–1319.
20. Green DS, Davies JV. Successful choledocholithotomy in a horse. *Equine Vet J* 1989;21:464–467.
21. Smith LJ, Mair TS. Are horses that undergo an exploratory laparotomy for correction of a right dorsal displacement of the large colon predisposed to postoperative colic, compared to other forms of large colon displacement?. *Equine Vet J* 2010;42:44–46.
22. Chénier S, Macieira SM, Sylvestre D, et al. Chronic intestinal pseudo-obstruction in a horse: A case of myenteric ganglionitis. *Can Vet J* 2011;52:419–422.
23. Harvey-Micay J. Intestinal adenocarcinoma causing recurrent colic in the horse. *Can Vet J* 1999;40:729–730.
24. Blake KR, Affolter VK, Lowenstine LJ, et al. Myenteric ganglionitis as a cause of recurrent colic in an adult horse. *J Am Vet Med Assoc* 2012;240:1494–1500.
25. Pavone S, Sforna M, Gialletti R, et al. Extensive myenteric ganglionitis in a case of equine chronic intestinal pseudo-obstruction associated with EHV-1 infection. *J Comp Pathol* 2013;148:289–293.
26. Schusser GE, White NA. Morphologic and quantitative evaluation of the myenteric plexuses and neurons in the large colon of horses. *J Am Vet Med Assoc* 1997;210:928–934.
27. Mair TS, Sherlock CE, Fews D, et al. Idiopathic fibrosis of the tunica muscularis of the large intestine in five horses with colic. *J Comp Pathol* 2016;154:231–234.
28. Scott EA, Heidel JR, Snyder SP, et al. Inflammatory bowel disease in horses: 11 cases (1988-1998). *J Am Vet Med Assoc* 1999;214:1527–1530.

29. Fintl C, Hudson NP, Mayhew IG, et al. Interstitial cells of Cajal (ICC) in equine colic: An immunohistochemical study of horses with obstructive disorders of the small and large intestines. *Equine Vet J* 2010;36:474–479.
30. Lindberg R, Nygren A, Persson SG. Rectal biopsy diagnosis in horses with clinical signs of intestinal disorders: A retrospective study of 116 cases. *Equine Vet J* 1996;28:275–284.
31. Boshuizen B, Ploeg M, Dewulf J, et al. Inflammatory bowel disease (IBD) in horses: A retrospective study exploring the value of different diagnostic approaches. *BMC Vet Res* 2018;14:21.
32. Hopster-Iversen C, Hopster K, Staszyk C, et al. Influence of mechanical manipulations on the local inflammatory reaction in the equine colon. *Equine Vet J Suppl* 2011;43:1–7.
33. Kaikkonen R, Niinisto K, Sykes B, et al. Diagnostic evaluation and short-term outcome as indicators of long-term prognosis in horses with findings suggestive of inflammatory bowel disease treated with corticosteroids and anthelmintics. *Acta Vet Scand* 2014;56:35.
34. Marti M, Mevissen M, Althaus H, et al. In vitro effects of bethanechol on equine gastrointestinal contractility and functional characterization of involved muscarinic receptor subtypes. *J Vet Pharmacol Ther* 2005;28:565–574.
35. Lester GD, Merritt AM, Neuwirth L, et al. Effect of alpha 2-adrenergic, cholinergic, and nonsteroidal anti-inflammatory drugs on myoelectric activity of ileum, cecum, and right ventral colon and on cecal emptying of radiolabeled markers in clinically normal ponies. *Am J Vet Res* 1998;59: 320–327.
36. Ringger NC, Lester GD, Neuwirth L, et al. Effect of bethanechol or erythromycin on gastric emptying in horses. *Am J Vet Res* 1996;57:1771–1775.
37. Mullen KR, Yasuda K, Divers TJ, et al. Equine faecal microbiota transplant: Current knowledge, proposed guidelines and future directions. *Equine Vet Educ* 2018;30: 151–160.
38. Tannahill VJ, Cardwell JM, Witte TH. Colic in the British military working horse population: A retrospective analysis. *Vet Rec* 2019;184:24–24.
39. Nicol CJ, Davidson HPD, Harris PA, et al. Study of crib-biting and gastric inflammation and ulceration in young horses. *Vet Rec* 2002;151:658–662.

Referral of Horses with Colic: A Time to Review

David E. Freeman, MVB, PhD, DACVS*;
Louise L. Southwood, BVSc, PhD, DACVS, DACVECC;
Kira Epstein, DVM, DACVS-LA, DACVECC; Anje G. Bauck, DVM, PhD, DACVS;
Joanne Hardy, DVM, PhD, DACVS; Callie Fogle, DVM, DACVS; and
Debra C. Archer, BVMS, CERTES (SOFT TISSUE), DIPECVS, FRCVS, FHEA

Authors' addresses: College of Veterinary Medicine, University of Florida, 2015 SW 16th Avenue, Gainesville, FL 32608 (Freeman, Bauck); New Bolton Center, University of Pennsylvania, 382 West Street Road, Kennett Square, PA 19348-1691 (Southwood); Department of Large Animal Medicine, University of Georgia College of Veterinary Medicine, Athens, GA 30602-0001 (Epstein); Texas A&M University College of Veterinary Medicine, 4475-TAMU College Station, TX 77843-0001 (Hardy); North Carolina State College of Veterinary Medicine, 1060 William Moore Drive, Raleigh, NC 27606 (Fogle); University of Liverpool, Leahurst Campus, Chester High Road, Wirral, Ch64 7TE, UK (Archer); e-mail: freemand@ufl.edu. *Corresponding and presenting author. © 2022 AAEP.

1. Introduction

One of the most positive trends in colic surgery over the past 50 years and probably the single most critical factor in improved outcomes is shortening the interval from on-farm assessment to surgical treatment. Today, trained surgeons and a well-equipped surgical hospital are within easy reach of most horses with colic, and referring veterinarians have shortened the interval to referral. However, over the last 10 years or so, the authors have independently recognized a growing increase in the interval between onset of colic and surgical treatment. Many factors probably contribute to this change, including owner misconceptions, failure of diagnostic procedures to provide sufficient accuracy, and financial impact. The shared goal must be to maximize survival and minimize complications and cost associated with surgical treatment. Therefore, the authors are bringing this issue forward to equine practitioners to start a dialog about resolving our shared concerns.

2. Role of Early Referral in Survival

The main benefits of early referral can be attributed to reduced severity of tissue injury and resulting endotoxemia/systemic inflammatory response syndrome (SIRS) on admission.[1] A much overlooked benefit is reduced complication rates (Fig. 1), which not only improve survival but lower costs, increase owner satisfaction, and improve overall confidence in colic surgery. The benefits of early referral are listed below:

- In a recent study on surgery for small intestinal strangulation in horses, horses that did not require resection (Fig. 2) had superior long-term survival rates than those that required resection (Fig. 3).[2] In the same horses, those that did not require resection had a significantly shorter duration of colic before surgery than those that did, suggesting they were the beneficiaries of early referral.[3] This is a clear demonstration of the

NOTES

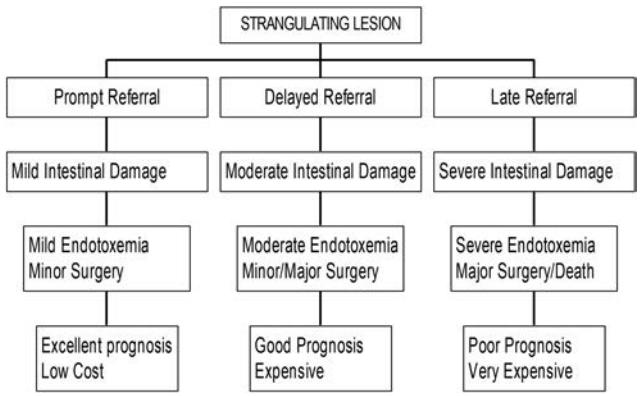

Fig. 1. Flowchart relating delay in decision-making to prognosis and cost.

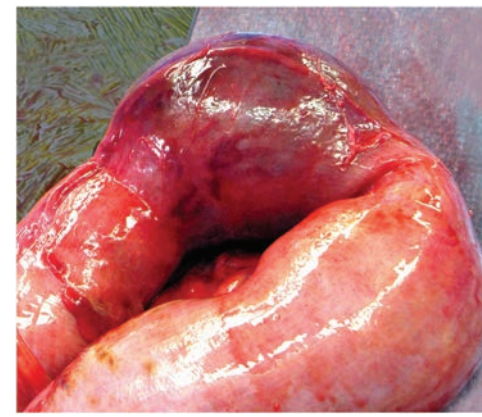

Fig. 2. Segment of small intestine strangulated in an inguinal hernia that was correctly judged as not needing a resection. Reproduced from *Equine Vet J* with permission.

benefits of surgery before irreversible intestinal damage has developed. The proportion of horses that do not require resection appears on the decline compared with the proportion treated in 1994–2008,[2] suggesting that duration of colic before referral is longer than ideal.

- In a study on horses with a high survival rate (86%) after surgery for large colon volvulus (LCV), a decrease in intraoperative colonic biopsy score by ~0.5 per year was evidence of early referral and its benefits.[4]
- In a study on Thoroughbred mares with LCV and an overall survival to discharge of 88%, colic duration before admission was significantly related to survival.[5]
- Horses with ileal impaction can also benefit from early referral,[6] demonstrating an example of this benefit in a nonstrangulating small intestinal disease.
- A 92% survival has been reported in horses treated by closed manual reduction of an inguinal hernia,[7] compared with a short-term survival rate of 56% to 85.1% for surgical treatment.[8] Presumably closed manual reduction is effective shortly after disease onset, whereas surgery is required after a longer duration.
- In a multicenter study of horses with inguinal hernia, 69% of affected horses survived if admitted before 10 hours from onset of pain compared with 29% in those admitted later.[8]
- In 143 horses with entrapment in the epiploic foramen, 76% survived surgery performed ≤ 8 hours from onset of colic compared with 45% survival after surgery performed ≥ 12 hours after onset of colic.[9]
- A prolonged duration of colic before referral can increase the risk of postoperative ileus and diarrhea after surgery.[10]
- A strong argument for early referral is provided by the observation that the length of small intestine strangulated can actually increase over time as more is drawn into the strangulating ring, eventually leading to ileal involvement and a more complicated surgery.[11]
- Delays in referral can lead to distention in the intestine oral to the lesion,[12] which leads to poor perfusion of that segment and adhesions.

The preceding information identifies literature support for the perception that a delay to surgery is harmful for a variety of different diseases, but especially for those associated with strangulating lesions. These observations provide a scientific basis to taking a closer look at how the interval from initial treatment to surgery can be shortened.

3. Owner Role—Need for Careful Discussion

Decision-making about colic surgery by owners is a critical but complex part of the referral process.[13] It can be fraught with confusion largely brought on by the nature of the disease, its abrupt onset that allows little preparation, demands for resources that are not always available (trailer, money), and limited access to emotional support from friends and family. Once a veterinarian on the farm has a concern about the possible need for referral, the discussion that follows with the owner is critical. If the owner states that "surgery is not an option," the groundwork for failure has been laid in many cases. This statement can presage a change of heart at a time when the prospects of a successful surgery have passed, considerable expense has been incurred, and the need for euthanasia is imminent. Then surgery becomes an option but involving a resection that could have been avoided earlier. Therefore, the referring veterinarian must have a frank and informed discussion with the owner about their aversion to colic surgery. The following are commonly used explanations from owners for rejecting the surgery option:

- Colic surgery is rarely successful.
- I would prefer to try medical treatment first.

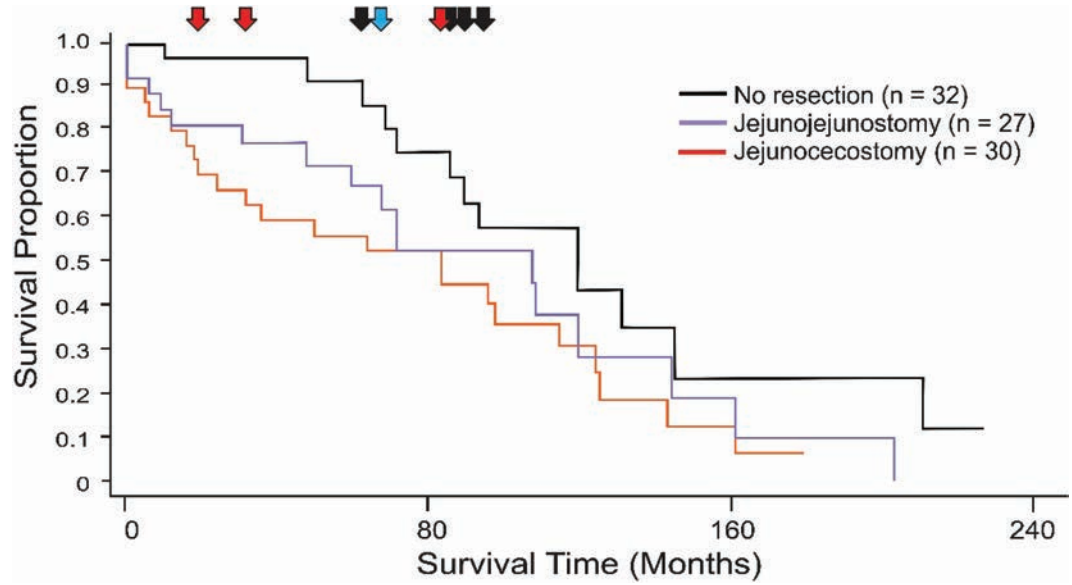

Fig. 3. Long-term survival in horses that had surgery for small intestinal strangulation. Arrows indicate times of death from colic matched by color to the treatment lines. Note superior outcomes after no resection. Reproduced from *Equine Vet J*[2] with permission.

- A friend's horse died from colic surgery, and he or she was devastated by the poor outcome.
- The horse will never be the same after colic surgery.
- This is a pregnant mare, and it will be impossible to save the mare and foal with surgery.
- This is an old horse and old horses do not handle anesthesia and colic surgery well.
- This horse is much loved/valued but we cannot justify spending money on colic surgery in our present financial circumstances.

These concerns need to be respected as valid in the owner's view, even if they do not apply to most cases. However, veterinarians need to create or avail of opportunities to correct these misconceptions as they apply to colic surgery in general and prognosis specifically. There is growing evidence that the last explanation, cost of surgery, can play a large role in an owner's decisions about colic surgery[14] and could explain the growing rates of euthanasia, especially before and during surgery.[15] The cost should not be viewed solely as the cost of surgery, but also include expenses incurred before referral, and both combined can be substantial if referral is delayed.

The role of the referring veterinarian in handling the early decision process is critical. In a study from the United Kingdom on old horses, a group commonly affected with colic, owners stated that they relied heavily on guidance from their own veterinarian.[16] This is where a team approach applies (see below). Horses have performed well after colic surgery, even achieving their intended goals, such as winning major stakes races and the Kentucky Derby ("Lil E. Tee"). The financial issue should be guided by accurate information as to the true range of costs for the suspected disease and based on consultation with a surgeon at the hospital (see below). Owner education to address unfounded reasons for reluctance becomes the critical issue at this point.

If the owner declines referral, the veterinarian must also establish very clear guidelines for how to proceed. At this point, the owner must be informed that if the horse has a true surgical lesion (especially small intestinal strangulation), only surgery will save its life. Because a surgical diagnosis cannot be made definitively in every case and if the horse "appears comfortable," the owner might request continued medical treatment, "just in case. . . ." Medical treatments do not resolve surgical lesions. Euthanasia can become a reality at this point. Once the surgery option is rejected, the owner must consider the following if on-the-farm treatment is selected:

- What is my true financial limit on this horse?
- Can I afford repeated visits to the farm for treatments?
- How much time can I commit to around-the-clock monitoring and care?
- Can I handle watching my horse suffer?
- Is my family supportive of this decision?
- Will I change my mind or stick the course?

The last question is critical because if surgery becomes an option at any point, it should be selected promptly, not after all other medical treatment options and resources have been exhausted and euthanasia is the only reasonable choice. At that point, the cost of surgery will be considerable and the outcome poor. Referral to a hospital for a second opinion and for supportive care is a reasonable option and could confirm that humane euthanasia is needed, and at reasonable cost.

4. Challenges

The major challenge with referral for surgery is diagnosing a surgical lesion with a comfortable degree of certainty. Horses that require surgery or euthanasia because of a surgical lesion can have one or more of the following: persistent pain despite analgesic drugs, a persistently elevated or increasing heart rate (≥48 beats/min), reflux from a nasogastric tube, worsening abdominal distention, abnormal rectal examination findings, obvious abnormality on ultrasound examination, and belonging to a high-risk group (see above). However, many of these changes might not develop, even in horses with strangulating lesions, and some horses might only have subtle pain indicators (nostril tension and flare, facial grimace, and abrasions on bony prominences).

The approach to diagnosis should be predicated on acceptance that an approach with a high degree of diagnostic sensitivity might be preferable in the farm setting to seeking a high degree of diagnostic specificity.[17] High sensitivity means that many horses that could be treated at home will be referred. However, overzealous pursuit of diagnostic accuracy might leave more horses with surgical lesions on the farm and delay referral. This is the error that leads to the worst outcomes.

5. Role of Risk Factors in Diagnosis

Often overlooked in the diagnostic approach are simple features in the signalment that provide strong diagnostic clues as to what type of surgical lesion is involved (Table 1). If other findings fit with the possible "at-risk" diagnosis, as with lipoma (see below), the odds of that disease being responsible for colic increase accordingly. However, it is important not to fixate on any particular diagnosis, which may be wrong.

6. Strangulating Lipoma

Old horses have similar types of colic as young horses, but they also have their own more lethal and common disease, strangulating lipoma (horses ≥10 years).[18] This age/disease link is so well established,[18] with increasing risk due to increasing age, that an old horse with colic should be considered as having a strangulating lipoma until proven otherwise. Unfortunately, these horses are the most likely victims of delayed decisions about surgery. They are already at the end of their life span, and many of them have comorbidities (lameness, pituitary pars intermedia dysfunction, and laminitis) that might tilt the decision against surgery. Many have earned a strong degree of emotional worth but have passed their prime for athletic activity. If distended loops of small intestine are found on rectal examination or on ultrasound examination, with or without reflux through a nasogastric tube, or with abrasions on bony prominences, this horse most likely has a strangulating lipoma.

Sadly, this is the horse likely to be denied surgery because of the myth that old horses cannot handle anesthesia and surgery well. They can and should not be denied surgery for this reason only.[19] Old horses tend to be stoic,[19] which can create a false impression of responding well to medical treatment. Some of this could be a breed effect (e.g., Tennessee Walking Horses), but all horses with a strangulating lesion can also become obtunded by endotoxemia. These can mislead lay handlers to an impression of a mild or resolving disease. As with all horses with small intestinal strangulation, these horses also develop a vacuum-packed large colon, which creates the erroneous impression on palpation per rectum that they have a large colon impaction, a nonsurgical disease. This finding is actually a tip that small intestinal strangulation is the primary lesion.

7. Abdominocentesis

Peritoneal fluid changes, such as serosanguinous discoloration and elevated lactate, develop early in the course of intestinal ischemia.[20] Although easy to perform, abdominocentesis at home for horses that could be candidates for surgery delays referral and increases cost. Abdominocentesis might have a place if the only option is euthanasia. The following limitations should be considered before using this procedure:

Abdominocentesis in the field is easy to perform and point-of-care testing for lactate might enhance its diagnostic value. However, any data from abdominocentesis can be difficult to interpret and equivocal findings are common and can delay referral. The

Table 1. Risk Factors for Surgical Diseases That Could Help with Diagnosis

Horse factor(s)	At risk for:
Horse > 10 years old	Strangulating lipoma[18]
Intact male (especially Standardbreds)	Inguinal hernia[26]
Miniature horse, small pony	Fecalith in small colon[26]
Mare in late pregnancy	Uterine torsion[26]
Previous small intestinal surgery	Recurrent disease or adhesions[26]
Postpartum mare with severe abdominal pain	Large colon volvulus, other strangulation[5]
Postpartum mare with mild colic, peritonitis	Small colon avulsion/necrosis, ruptured uterus
Feeding coastal Bermuda grass hay	Ileal impaction[26]
Cribber (especially a Thoroughbred gelding)	Epiploic foramen entrapment[27]

following limitations must be fully understood when interpreting abdominal fluid:

- Gross appearance, packed cell volume (PCV), and total protein (TP) in peritoneal fluid can be misleading or equivocal and time for laboratory analyses can delay decision-making.
- The following surgical lesions might not develop diagnostic peritoneal fluid changes:
  - Large colon volvulus.
  - Diaphragmatic hernia (strangulated segment in the thorax).
  - Ruptured viscus. This can produce fluid with a normal gross appearance, white blood cells (WBC), and TP (need a cytological examination).[21]
  - Early pressure necrosis in the site of an enterolith, fecalith, or foreign body impaction.
  - Lipoma strangulation by wrapping of the lipoma around a segment of intestine rather than strangulating a loop and its vasculature.

8. Reassessment of Intravenous Fluid Therapy

Although intravenous (IV) fluid therapy is a necessary and life-saving treatment for horses in cardiovascular shock, many horses with signs of severe colic are not in cardiovascular shock. In horses with ischemic lesions, delays, complications, and costs associated with fluid therapy on the farm are harmful when balanced against the benefits of early referral. Similar concerns apply to continuous rate infusions on the farm (e.g., lidocaine).

In the authors' opinion, instituting IV fluids for horses with surgical colic at a hospital is sufficient and minimizes some of the risks of aggressive fluid therapy before referral, such as:

- High-volume fluid therapy can actually produce a misleading degree of improvement that only confuses owners and delays referral.
- High-volume fluid therapy can create electrolyte imbalances through sodium diuresis that creates other electrolyte abnormalities (calcium, magnesium).[22] Some of these changes can delay postoperative recovery and reduce survival.
- Time required for administration of fluids and to monitor responses is time that allows progression of the disease and tissue injury. Consequently, the ischemic changes can become irreversible, and the more proximal distended segments will probably fill with much of the fluid-infused IV. This only adds to proximal intestinal distention and mural edema, critical factors that increase pain and delay recovery.[23]
- There is a growing awareness that aggressive fluid therapy can actually cause adverse consequences for recovery of intestinal function. This can be mediated through damage to the vascular endothelium that exacerbates transcapillary fluid leakage and tissue edema.[24]
- In a clinical study in horses with small intestinal strangulation, a more restricted goal-directed approach to fluid therapy had similar survival and complication rates as the traditional liberal fluid therapy.[25]
- Fluids given IV at the surgical facility are sufficient to prepare the horse for surgery.

9. Treatments and Diagnostic Procedures Repeated at the Hospital

This can become a contentious issue with many owners. Although applying diagnostics and treatments on the farm is well intentioned, many of the same procedures have to be repeated at the surgical facility to justify the decision for the next option–surgery or euthanasia. Owners regard this as an unnecessary additional cost, arguing that their veterinarian already did the same. Unfortunately, some information might be missing or some indicators could have changed during the interim. Possibly, warning owners of this beforehand might prepare them to accept this necessity.

10. Teamwork

Decision-making about colic referral is complicated for owners,[13] and therefore a team approach is recommended, which starts with the owner, trainer (or manager), and referring/primary veterinarian. If clinical signs in any way suggest a surgical treatment is indicated, but owner reluctance persists, a surgeon at the hospital that would receive the referral should be consulted to provide a reasonable overview of cost and prognosis. The decision that surgery is or is not an option should be based on solid facts that could be produced by frank discussion with all involved. The goal is not to change the owner's mind but to prevent a fatal change of course when the window for a successful surgery has passed.

11. Recommendations

The referral process could be regarded on the most basic clinical level as needing a second opinion for a horse that does not fit within the typical colic that will respond on the farm. The decision for or against surgery when indicated is the owner's prerogative and, in most cases, the decision they make is the correct one for them. The problem situations are those in which the surgery option is rejected, only to be selected later when the nonsurgical approach is clearly failing. Again, this decision is the owner's prerogative, but should be based on a realistic understanding of cost and prognosis and with guidance from all involved in case management. The cost of surgical treatment is substantial, and hospitals should review their surgical pricing system to

determine if treatment components can be "packaged or structured" in a way that produces a favorable cost for all. For example, "stop" points could be identified at different stages of the surgery and postoperative care, related to complexity and associated expenses (e.g., need for resection and anastomosis, development of postoperative reflux or colic). Regardless of approach, owner education is critical to a successful outcome, and everyone plays a role in that duty.

Acknowledgments

Declaration of Ethics

The Authors have adhered to the Principles of Veterinary Medical Ethics of the AVMA.

Conflict of Interest

The Authors have no conflicts of interest.

References

1. Proudman CJ, Dugdale AHA, Senior JM, et al. Pre-operative and anaesthesia-related risk factors for mortality in equine colic cases. *Vet J* 2006;171:89–97.
2. Rudnick MJ, Denagamage TN, Freeman DE. Effects of age, disease and anastomosis on short- and long-term survival after surgical correction of small intestinal strangulating diseases in 89 horses. *Equine Vet J* [Epub ahead of print].
3. Freeman DE, Hammock P, Baker GJ, et al. Short- and long-term survival and prevalence of postoperative ileus after small intestinal surgery in the horse. *Equine Vet J Suppl* 2010;32:42–51.
4. Levi O, Affolter VK, Benak J, et al. Use of pelvic flexure biopsy scores to predict short-term survival after large colon volvulus. *Vet Surg* 2012;41:582–588.
5. Hackett ES, Embertson RM, Hopper SA, et al. Duration of disease influences survival to discharge of Thoroughbred mares with surgically treated large colon volvulus. *Equine Vet J* 2015;47:650–654.
6. Parks AH, Doran RE, White NA, et al. Ileal impaction in the horse: 75 cases. *Cornell Vet* 1989;79:83–91.
7. Baranková KM, de Bont MP, Simon O, et al. Non-surgical manual reduction of indirect inguinal hernias in 89 adult stallions. *Equine Vet Educ* 2022. https://doi.org/10.1111/eve.13494.
8. François I, Lepage O, Boswell J, et al. Acquired inguinal herniation in horses: A retrospective multicenter study of 48 cases. *Vet Surg* 2014;43:E167.
9. Scheidemann W. *Beitrag zur Diagnostik und Therapie der Kolik des Pferdes: Die Hernia Foraminis omentalis*. 1989; DMV thesis, Muenchen.
10. Fogle CA, Gerard MP, Correa M, et al. An analysis of factors associated with a prolonged duration of colic (344 horses). *Proc 10th Equine Colic Res Symp* 2011;10:202.
11. Gandini M, Giusto G. Why is the ileum involved in the majority of cases of internal hernias? A biomechanical hypothesis. *Equine Vet Educ* 2021;33:48.
12. Dabareiner RM, Sullins KE, Snyder JR, et al. Evaluation of the microcirculation of the equine small intestine after intraluminal distention and subsequent decompression. *Am J Vet Res* 1993;54:1673–1682.
13. Scantlebury CE, Perkins E, Pinchbeck GL, et al. Could it be colic? Horse-owner decision making and practices in response to equine colic. *BMC Vet Res* 2014;10:S1–S1. https://doi.org/10.1186/1746-6148-10-S1-S1.
14. Archer DC. Colic surgery: Keeping it affordable for horse owners. *Vet Rec* 2019;185:505–507.
15. Blikslager AT, Mair TS. Trends in the management of horses referred for evaluation of colic: 2004–2017. *Equine Vet Educ* 2021;33:192–197.
16. Ireland JL, Clegg PD, McGowan CM, et al. Factors associated with mortality of geriatric horses in the United Kingdom. *Prev Vet Med* 2011;101:204–218.
17. Peloso JG, Cohen ND, Taylor TS, et al. When to send a horse with signs of colic: Is it surgical, or is it referable? A survey of the opinions of 117 equine veterinary specialists, in *Proceedings*. Am Assoc Equine Pract 1996;42:250–253.
18. Freeman DE, Schaeffer DJ. Age distribution of horses with strangulation of the small intestine by a lipoma or in the epiploic foramen: 46 cases (1994–2000). *J Am Vet Med Assoc* 2001;219:87–89.
19. Southwood LL, Gassert T, Lindborg S. Colic in geriatric compared to mature nongeriatric horses. Part 2: Treatment, diagnosis and short-term survival. *Equine Vet J* 2010;42:628–635.
20. Ruggles AJ, Freeman DE, Acland HM, et al. Changes in fluid composition on the serosal surface of jejunum and small colon subjected to venous strangulation obstruction in ponies. *Am J Vet Res* 1993;54:333–340.
21. Pratt SM, Hassel DM, Drake C, et al. Clinical characteristics of horses with gastrointestinal ruptures revealed during initial diagnostic evaluation: 149 cases (1990–2002), in *Proceedings*. Am Assoc Equine Pract 2003;42:254–255.
22. Garcia-Lopez JM, Provost PJ, Rush JE, et al. Prevalence and prognostic importance of hypomagnesemia and hypocalcemia in horses that have colic surgery. *Am J Vet Res* 2001;62:7–12.
23. Shah SK, Uray KS, Stewart RH, et al. Resuscitation-induced intestinal edema and related dysfunction: State of the science. *J Surg Res* 2011;166:120–130.
24. Woodcock TE, Woodcock TM. Revised Starling equation and the glycocalyx model of transvascular fluid exchange: An improved paradigm for prescribing intravenous fluid therapy. *Br J Anaesth* 2012;108:384–394.
25. Giusto G, Vercelli C, Gandini M. Comparison of liberal and goal-directed fluid therapy after small intestinal surgery for strangulating lesions in horses. *Vet Rec* 2021;188:e5.
26. Cohen ND. Epidemiology of colic. *Vet Clin N Am* 1997;13:191–201.
27. Archer DC, Freeman DE, Doyle AJ, et al. Association between cribbing and entrapment of the small intestine in the epiploic foramen in horses: 68 cases (1991–2002). *J Am Vet Med Assoc* 2004;224:562–564.

Retrospective Study Evaluating Clinical Outcomes of Foals with Surgical Strangulating Lesions of the Small Intestine

Sara J. Erwin, BS*; Marley E. Clark, BS; Julie E. Dechant, DVM, MS, DACVS, DACVECC; Maia R. Aitken, DVM, DACVS-LA, DACVECC; Diana M. Hassel, DVM, PhD, DACVECC; Amanda L. Ziegler, DVM, PhD; and Anthony T. Blikslager, DVM, PhD, DACVS

No significant difference was seen in outcome of surgically treated foals with small intestinal strangulating obstruction (SISO) compared with adults. These findings support more optimism toward surgical treatment of foals with SISO, and first opinion veterinarians should be encouraged to discuss favorably a surgical referral option for owners of foals with suspected SISO given these updated survival rates. Authors' address: North Carolina State University, College of Veterinary Medicine, 1060 William Moore Drive, Raleigh, NC 27607; e-mail: sjerwin@ncsu.edu. *Corresponding and presenting author. © 2022 AAEP.

1. Introduction

Short-term survival rates of 50% to 80% have been reported in adult horses with small intestinal strangulating obstruction (SISO), while rates of 27% to 50% have been reported in foals, but age-dependent outcomes have not been compared directly. This retrospective case-control study examined differences in clinical outcomes between adult and foal SISO patients.

2. Materials and Methods

Hospital records for surgical SISO cases were collected from North Carolina State, Colorado State, University of Pennsylvania, The Ohio State University, and University of California, Davis equine referral centers. Foals were ≤6 months of age and case-matched to adult controls between 2 to 20 years of age. GraphPad Prism software was utilized for statistical analyses using Shapiro-Wilk normality tests, simple logistic regression, or Fisher's exact tests when appropriate and $P < .05$ was considered significant.

3. Results

Common adult lesions included strangulating lipomas (n = 36), volvulus (n = 25), and inguinal hernias (n = 10). Common foal lesions included volvulus (n = 22), intussusception (n = 5), and mesenteric rents (n = 3). Data revealed 25 of 41 (60.98%) foals and 75 of 105 (71.43%) adults were recovered from surgery. Of those recovered

Research Abstract—for more information, contact the corresponding author

NOTES

from surgery, 24 (96.0%) foals and 66 (88.0%) adults survived short-term. Of 16 nonsurviving foals, 15 (93.75%) were euthanized intraoperatively and 1 (6.25%) was euthanized postoperatively. Of 38 nonsurviving adults, 28 (73.7%) were euthanized intraoperatively, and 10 were euthanized postoperatively. Resection had no significant effect on survival in either group ($P = .6$; 95% CI, 0.8–2.7). Survival analysis indicates foal short-term survival is not significantly different from adults ($P = .44$; 95% CI, 0.5–37.3). Long-term survival was collected when possible and was available for 13 adults and 5 foals. Of 13 adults and 5 foals, 2 adults and 2 foals were euthanized 1 month postoperatively for adhesions. Follow-up shows 84.62% survival in available adults and 60% survival in available foals, though the cases available were too few for statistical analysis.

4. Discussion

The results of this study demonstrate no significant difference in outcome of surgically treated SISO foals compared with adults. The clinical application of such findings supports more optimism toward surgical treatment of foals with SISO.

Acknowledgments

The Authors thank Emily Hellstrom for her assistance collecting long-term follow-up data. The authors also thank Megan Burke for coordinating case collection with the Ohio State University, and Alison Gardner at the Ohio State University for providing relevant cases.

Funding Sources

This research was funded by National Institutes of Health K01 OD 028207, National Institutes of Health P30 DK 034987, National Institutes of Health R01 HD095876, United States Department of Agriculture-AFRI-NIFA 2019-67017-29372, NCSU CVM Veterinary Faculty Practice Plan.

Declaration of Ethics

The Authors have adhered to the Principles of Veterinary Medical Ethics of the AVMA.

Conflict of Interest

The Authors have no conflicts of interest.

A

Acutt, EV, 288
Adam, E, 85, 308
Adams, A, 232
Aitken, MR, 476
Aleman, M, 62, 66, 243
Alexander, K, 83
Allen, AK, 9
Alonso, F, 224
Alonso, MA, 274
Alvarenga, MA, 46, 382, 384
Andersen, HS, 449
Archer, DC, 470
Arthur, RM, 60
Atkins, A, 9
Austin, S, 271

B

Baccarin, RYA, 306
Bain, F, 56
Bandeira, R, 382
Barbosa Fernandes, C, 274
Barnett, C, 56
Barnum, SM, 56, 60
Barrett, MF, 288, 436
Bartels, T, 245
Bass, L, 83
Batalla, R, 310
Bauck, AG, 241, 470
Bell, SC, 180
Bellone, RR, 220
Berk, J, 424, 426
Berryhill, E, 224
Bidwell, L, 369, 371
Bittar, JHJ, 284
Blikslager, AT, 476
Boakari, YL, 274

C

Caldwell, J, 9
Caldwell, T, 130
Calero, MI, 457
Canisso, I, 284, 380, 384
Cannon, J, 438
Carmalt, JL, 326
Carmo, MT, 384
Carnevale, EM, 286
Catandi, GD, 286
Chalk, JA, 260, 328
Chappell, DE, 56
Chen, T, 286
Cheng, M-H, 286
Chicco, AJ, 286
Chigerwe, M, 226
Claes, AN, 280
Clark, AR, 268
Colbath, AC, 222
Colla, S, 442
Conklin, B, 206
Conley, A, 276
Conrad, P, 62
Contino, E, 297
Cordivano, S, 113
Craig, B, 56

D

Da Rosa Curcio, B, 243
Daly, C, 249
Deane, E, 64
Dechant, JE, 476
Dell'Aqua, C, 384
Dell'Aqua, Jr, J, 382
DeNotta, S, 198
Dinesen, MA, 449
Dini, P, 66, 276, 280, 282
Divine, CJ, 386
Dobbie, T, 31
Donnelly, CG, 226
Douglas, R, 394
Draheim, P, 282
Dutton, DM, 211
Dyson, S, 316

E

Edwards, LA, 226
Edwards, RB, 151

Elliott, SM, 455
Ellis, KL, 288, 438
Epstein, K, 470
Erwin, SJ, 476

F

Fedorka, C, 394
Ferris, RA, 27, 37
Fielding, L, 64
Finno, CJ, 62, 226
Fogle, C, 470
Foland, J, 457
Freeman, DE, 241, 470
Freitas, N, 243
Fresa, K, 286
Frisbie, DD, 304

G

Gaughan, E, 56
Giancola, S, 455
Gobato, M, 382
Good, KL, 220
Gosselin, M, 87
Grice, AL, 124, 252, 257, 263
Griffenhagen, G, 304
Guardia, C, 257

H

Hagerman, L, 111
Hall, TL, 172
Hand, DR, 1
Hardy, J, 470
Harris, PA, 235
Hartmann, P, 85
Hassel, DM, 476
Healey, P, 428
Herthel, T, 457
Horbal, A, 414
Horohov, DW, 308
Howard, B, 85
Huggins, L, 276
Husted, R, 68

J

James, K, 56
James, O, 451
Jarvis, H, 9
Johns Price, S, 9
Johnson, AL, 226
Johnson, M, 308
Johnson, SA, 304
Johnston, K, 444
Jones, K, 284

K

Kawcak, C, 424, 426, 436
Keegan, KG, 335, 349
Keenan, D, 424, 426
Kelty, E, 239
Kent Dostal, D, 331
Kerr, MD, 428
King, MR, 288, 304
Knickelbein, KE, 220
Knych, H, 85
Krebs, W, 108
Kurucz, E, 130

L

Lanovaz, JL, 326
Lawton, KOY, 60
Leemans, B, 280
Lindegaard, C, 449
Loynachan, A, 282
Lyman, C, 282

M

MacKay, R, 198
MacKenzie, CG, 121
Magdesian, G, 64
Magnus, RP, 105, 328
Major, D, 64
Mama, K, 83
Marteniuk, JV, 230
Martin-Pelaez, S, 280, 282
May, EM, 278, 386
Mayer, J, 64
McClure, S, 3, 6, 290
McCue, PM, 278, 386
McIlwraith, W, 424, 426
McKnight, A, 449
Megahed, AA, 284
Messenger, K, 366, 369
Meyers, S, 282
Middlebrooks, BT, 278, 386
Moeller, BC, 60
Mohammed, HO, 355

Moorman, VJ, 345, 455
Mork, D, 424, 426
Morresey, PR, 366

N

Nogueira, CEW, 243
Nunes da Silva, P, 274

O

O'Shea, C, 396
Ortved, K, 166

P

Packham, A, 62
Page, AE, 308
Palmer, S, 355
Pandit, P, 62
Papa, F, 382, 384
Parker, J, 308
Partridge, E, 308
Peat, F, 424, 426
Peck, KN, 290
Pfiko, JW, 326
Podico, G, 232, 284, 380
Price, D, 58
Pusterla, N, 56, 58, 60, 62, 175

Q

Quattrini, C, 66

R

Rabow, Z, 282
Rao, S, 83
Reed, SM, 226
Refsal, KR, 230
Reisbig, NA, 326
Rendle, D, 239
Revenaugh, M, 13
Rick, M, 457
Russillo, C, 9

S

Salman, MD, 288
Santischi, E, 457
Scalco, R, 66, 243
Scheeren, V, 382
Schneider, C, 56
Schnobrich, MR, 17, 394
Schott, HC, 222, 230
Schramme, M, 141
Schumaker, M, 278
Scollay, M, 85
Scott, LA, 440
Seabaugh, KA, 440, 442
Segabinazzi, LGTM, 46, 382, 384
Selberg, KT, 440, 442
Sheats, MK, 406
Simon, E, 83
Smith, W, 62
Southwood, LL, 464, 470
Spencer, KM, 284
Spriet, M, 158
Stout, TAE, 22, 41, 280
Stover, S, 95
Strachota, JR, 230
Sullivan, HM, 288, 436
Sundman, E, 186
Sundra, T, 239
Swail, M, 357

T

Taormina, J, 85
Tipton, TE, 216
Tokawa, PKA, 306
Troedsson, MHT, 394
Turner, RM, 374

U

Urbina, N, 224

V

Vaala, W, 56
Valberg, SJ, 226
van Wessum, R, 444
Vernau, B, 66

W

Whitcomb, MB, 137
White, JM, 222
Willis, AT, 190
Wilson, KE, 401
Wood, C, 308
Woolard, K, 62
Wright, C, 117

Z

Zanotto, GM, 306, 442
Zeytoonian, KA, 90
Zhou, T 436
Ziegler, AL, 476
Zimmerman, M, 141

A

Ability of donkey sperm for cooling: effect of extender base and removal of seminal plasma on sperm parameters and fertility rates, 382
Abnormal mare behavior is not often associated with changes in hormonal markers of granulosa cell tumors: a retrospective study, 276
Accounts receivable
  By moving to payment at the time of service, how practices can reduce, 108
  Culture, process and impact, 105
  In an ambulatory practice, how to decrease, 111
Accuracy of ultrasound to detect changes in cervical facet joint effusion—a cadaveric study, 440
Ambulatory Practice
  How to decrease accounts receivable, 111
  Intra-articular alpha-2 macroglobulin, use of, 9
Arthritis
  Injectable pentosan polysulfate, 290
  Prevention in sport horses, 396

B

Behavior and perinatal parameters of mule foals, 274
Betamethasone in an equine acute synovitis model, residual anti-inflammatory effects of intra-articular triamcinolone acetonide, 308
Big data and body-mounted inertial sensors, 349
Biofilm in the uterus, a tutorial on, 27
Biometric wearable sensors to identify subtle gait abnormalities in Thoroughbred racehorses, use of, 355
Blinded versus ultrasound-guided low-volume injection of tibial and fibular nerves in equine cadaver limbs, 442
Boundaries: telephone time and wellness in equine practice, 137
Building a team-based culture, 87
Building wealth—outside of your practice, 260

C

Cerebrospinal fluid in horses, effect of time and autologous serum addition, 66
Chronic lameness on thoracolumbar musculus multifidus structure in the horse, influence of, 288
Clinical and subclinical infection, molecular detection of EHV-1 horses, investigation of the use of non-invasive samples for, 58
Clinical outcomes of foals with surgical strangulating lesions of the small intestine, retrospective study evaluating, 476
Club foot with a rocker shoe, upright/low-grade, 310
Colic
  An important yet poorly understood problem, recurrent, 464
  Gastrointestinal examination in the horse, emergency, 190
  Referral of horses with, 470
Colostrum in the postpartum period, IgG content, 278
Comparison of 16-MHz and 9-MHz ultrasonography to low-field magnetic resonance imaging of the distal suspensory apparatus, 449
Computed tomography, 166
Congenital and juvenile cataracts in horses, 220
COVID-19 pandemic through serological and molecular testing, investigation of the role of healthy and sick equids, 60
Cystic fibrosis in people, right dorsal colitis, is this similar to, 241

D

Dave Ramsey method, paying off student debt, 249
Decreased equine chorionic gonadotropin secretion following hysteroscopic-guided injection of an immunomodulator, 394
Dentistry examination in the adult horse, 175
Deslorelin acetate is effective to induce ovulation during early and late fall despite lower endometrial edema in the latter, 284

Dipyrone on the diuretic effect of furosemide in horses, phenylbutazone, firocoxib, and, 222
Disorder of sexual development in the horse, how to evaluate and diagnose, 386
Distal limb using specific anatomical and radiographic parameters, how to evaluate and balance, 428

E

Early career veterinarian, how to use a mentorship framework to support, 117
Effect of time and autologous serum addition on the analysis of cerebrospinal fluid in horses, 66
Endometritis
  Breeding the young mare versus the teenager, impact on the incidence of, 22
  Causes and methods of diagnosis, clinical overview, 17
  In mares, responsible use of antimicrobial agents to treat bacterial, 31
  When antimicrobials are not the only answer, a menu for treating postmating-induced, 37
  Detection and resolution, the enigma of fungal, 41
  Is there evidence to support this, use of biologic agents to treat, 46
Emergency colic and gastrointestinal examination in the horse, 190
Enhanced epididymal sperm recovery without affecting cryopreservation in stallions, retrograde flushing followed by slicing float-up, 380
Equine acute synovitis model, residual anti-inflammatory effects of intra-articular triamcinolone acetonide and betamethasone in, 308
Equine asthma: current evidence and future directions, preventive medicine strategies for, 406
Equine blood flow restriction training, safety validation of, 304
Equine influenza virus in the United States during 2008-2001, voluntary surveillance program for, 56
Equine neonate, emergency triage of, 172
Equine neurologic exam, 198
Equine odontoclastic tooth resorption and hypercementosis in the equine, how to diagnose, 451
Equine podiatry, simplifying the approach, mechanical objectives, 206
Equine protozoal myeloencephalitis, *Sarcocystic neurona*, a fresh look at the SarcoFluor antibody test for the detection of specific antibodies to, agent of, 62
Equine temporomandibular joint, rein-lameness associated with inflammation, 326
Equinosis Q with lameness locator to evaluate lameness in horses, use of, 335
Ertugliflozin in the management of hyperinsulinemia and laminitis, 239
Evaluation of the suspensory ligament in Quarter Horses used for cutting, 436

F

Feeding the equid with insulin dysregulation, review of consideration when, 235
Firocoxib, and dipyrone on the diuretic effect of furosemide in horses, phenylbutazone, 222
Foals
  Behavior and perinatal parameters, mule, 274
  Red cell distribution width values and red cell distribution width to platelet ratio, 243
  With surgical strangulating lesions of the small intestine, 476
Follicular and systemic metabolic alterations in obese mares can be mitigated by dietary supplementation, 286
Frontal and infra-trochlear nerve blocks for frontonasal sinusotomy in standing horses, evaluation of, 455
Frontonasal sinusotomy in standing horses, frontal and infra-trochlear nerve blocks, 455

G

Gait abnormalities in Thoroughbred racehorses, biometric wearable sensors, 355
Gait analysis system into daily practice, how to integrate novel objective, 357
Gastrointestinal examination in the horse, emergency colic, 190
Granulosa cell tumors, abnormal mare behavior, changes in hormonal markers, 276

H

Harvesting the value of smaller practices: mergers, partnerships, or sale to individuals, 263
Having a difficult conversation — speaking your truth effectively, 124
Hypercementosis in the equine, equine odontoclastic tooth resorption, 451
Hyperinsulinemia and laminitis, ertugliflozin in the management of, 239
Hysteroscopic-guided injection of an immunomodulator, decreased equine chorionic gonadotropin secretion, 394

I

IgG content of mare colostrum in the postpartum period, evaluation of, 278
Immunomodulator, decreased equine chorionic gonadotropin secretion, hysteroscopic-guided injection, 394
Inertial measurement units: what are they and how can they be used, 345
Injectable pentosan polysulfate for the control of clinical signs associated with osteoarthritis in horses, clinical field study to evaluate, 290
Injection
  Blinded versus ultrasound-guided, tibial and fibular nerves in equine cadaver limbs, 442
  Decreased equine chorionic gonadotropin secretion following hysteroscopic-guided, 394
  Traditional options, intra-articular therapies in the field, 1
Injury
  Nuclear scintigraphy use, 151
  pathogenesis and training concepts for prevention, 95
Insulin Disregulation
  Feeding the equid, 235
  Oral sugar test to diagnose, 232
Intra-articular alpha-2 macroglobulin in ambulatory practice, use of, 9
Intra-Articular Therapy
  In the field: Traditional options for injections, 1
  Polyacrylamide hydrogel, how to use, 3
  Stanozolol, how to use, 6
Intra-sinovial corticosteroid use and laminitis: what is the evidence, systematic review of the association between, 306
Intrathecal mepivacaine and intravenous pentobarbital for humane equine euthanasia, comparison of technique, 83
Intravenous calcium administration as part of a fluid resuscitation protocol: a randomized, blinded clinical trial, 64
Intravenous pentobarbital for humane equine euthanasia, comparison of technique, intrathecal mepivacaine and, 83

J

Joint effusion, accuracy of ultrasound to detect changes, 440

L

Lameness
  Associated with inflammation of the equine temporomandibular joint, 326
  Chronic, on thoracolumbar musculus multifidus structure in the horse, 288
  Equinosis Q, to evaluate in horses, 335
  Nuclear scintigraphy use, 151
Laminitis
  Ertugliflozin in the management of hyperinsulinemia and laminitis, 239
  Intra-sinovial corticosteroid use, systematic review, 306
Levamisole and its metabolites in horses after an oral levamisole administration over seven days, detection of, 85
Long-term response of equids with pituitary pars intermedia dysfunction to treatment with pergolide, 230

M

Magnetic Resonance Imaging
  Distal suspensory apparatus, comparison of 16-MHz and 9-MHz ultrasonography, 449
  Role of, 141
Manually analyze a stallion's breeding records, how to, 374
Mares
  Abnormal behavior not associated with changes in hormonal markers, 276
  Breeding the young versus the teenager, impact on the incidence of endometritis, 22
  Follicular and systemic metabolic alterations mitigated by dietary supplementation, 286
  IgG content of colostrum in the postpartum period, evaluation of, 278
  Milk and maintain milk production, how to, 271
  Ovum pick up in a clinical program can induce mild transient discomfort, 280
  Responsible use of antimicrobial agents to treat bacterial endometritis, 31
Mechanical objectives, simplifying the approach to equine podiatry, 206
Medial femoral condyle subchondral cysts treated with transcondylar lag screw: outcome in 58 Quarter Horses, 457
Mentorship framework to support an early career veterinarian, how to use a, 117
Metabolic disease in the older horse: focus on prevention, 401
Milk mares and maintain milk production, how to, 271
Mindfulness: a powerful tool for sustainable equine practice, 130
Molecular detection of EHV-1 horses with clinical and subclinical infection, investigation of the use of non-invasive samples for, 58
Mud scenarios, how to respond and extricate equines trapped in, 68
Musculoskeletal injury and lameness, nuclear scintigraphy use in, 151

N

Navigating student loans and repayment strategies, climbing Mt. Debt, 245
Neurologic exam, equine, 198
Novel objective gait analysis system into daily practice, how to integrate, 357
Nuclear scintigraphy use in musculoskeletal injury and lameness, 151

O

Older horse: focus on prevention, metabolic disease, 401
Ophthalmic examination in the horse, 180
Oral sugar test to diagnose insulin dysregulation, review of factors to consider when using, 232
Ovarian removal before or after euthanasia for postmortem gamete retrieval: an assessment of pentobarbital concentration in the follicular fluid, 282
Ovulation during early and late fall, induce, deslorelin acetate, 284
Ovum pick up in a clinical program can induce mild transient discomfort in mares, 280

P

Pain control, pharmacology of, 369
Pain management, performance horse, 371
Paying off student debt utilizing the Dave Ramsey method, 249
Pentobarbital
  Assessment of concentration in the follicular fluid, ovarian removal, 282
  Humane equine euthanasia, intrathecal mepivacaine and, 83
Performance horse pain management, 371
Pergolide, long-term response of equids with pituitary pars intermedia dysfunction, 230
Pharmacology of pain control, 369
Phenylbutazone, firocoxib, and dipyrone on the diuretic effect of furosemide in horses, effects of, 222
Phosphorylated neurofilament heavy biomarker test, how to interpret, 226
Physiology of pain, 366
Pituitary pars intermedia dysfunction to treatment with pergolide, long-term response, 230
Plasma
  Platelet rich, important considerations for using, 13
  Seminal, effect of extender base and removal on sperm parameters and fertility rates, 382
  Whole blood, equine insulin concentrations, 224
Polyacrylamide hydrogel as an intra-articular therapy, how to use, 3
Positron emission tomography, 158
Postmortem gamete retrieval: an assessment of pentobarbital concentration in the follicular fluid, ovarian removal before or after euthanasia, 282
Power doppler in the musculoskeletal ultrasonography in the horse, how to use, 444
Practice
  Boundaries: telephone time and wellness, 137
  Harvesting value: mergers, partnerships, or sale to individuals, 263
  How to decrease accounts receivable, ambulatory, 111
  Mindfulness: a powerful tool, 130
  Ownership—the key to financial health, 252
  Reduce accounts receivable by moving to payment at the time of service, 108
  Technicians, maximizing utilization, 90
Preventative dentistry, 414
Preventive medicine strategies for equine asthma, 406
Profitability implications of revenue and expenses, 328
Proximal sesamoid bones of yearling and 2-year-old Thoroughbred sales horses, radiological findings in, 426
Proximal suspensory desmopathy in horses: a review, managing, 297
Psychological safety is key for reducing turnover and improving the bottom line, why employees quit, 113

Q

Quarter Horses
  Evaluation of the suspensory ligament for cutting, 436
  Medial femoral condyle subchondral cysts treated with transcondylar lag screw, 457
  Ultrasonographic comparison of the intermediate patellar ligament in warmbloods versus, 438

R

Radiographing the lame horse: how to acquire and interpret diagnostic radiographs, 211
Radiological findings in the proximal sesamoid bones of yearling and 2-year-old Thoroughbred sales horses, 426
Recurrent colic: an important yet poorly understood problem, 464
Red cell distribution width values and red cell distribution width to platelet ratio in Thoroughbred foals in the first 24 hours of life, 243
Referral of horses with colic: a time to review, 470

Rein-lameness associated with inflammation of the equine temporomandibular joint, 326
Repayment strategies, navigating student loans and, 245
Residual anti-inflammatory effects of intra-articular triamcinolone acetonide and betamethasone in an equine acute synovitis model, 308
Respiratory exams in the adult horse, upper and lower, 186
Respond and extricate equines trapped in mud scenarios, how to, 68
Retrograde flushing followed by slicing float-up enhanced epididymal sperm recovery without affecting cryopreservation in stallions, 380
Review of good record keeping: will your documentation defend you, 121
Ridden horse pain ethogram and the performance of sports horse, a review, 316
Right dorsal colitis: is this similar to cystic fibrosis in people, 241

S

Safety validation of equine blood flow restriction training: a pilot investigation, 304
Sarcocystic neurona, a fresh look at the SarcoFluor antibody test for the detection of specific antibodies to, agent of equine protozoal myeloencephalitis, 62
Seeding the field to grow future owners, 257
Selling to a corporate entity, 268
Sensors
  Big data and body-mounted, 349
  Biometric wearable, use of, 355
Serological and molecular testing, COVID-19 pandemic, 60
Sexual development in the horse, disorder, 386
Skeletal injuries in equine athletes—pathogenesis and training concepts for injury prevention, 95
Smaller practices, harvesting value, 263
Sperm
  Epididymal recovery without affecting cryopreservation in stallions, 380
  Effect of extender base and removal of seminal plasma, donkey, 382
  Filter and re-extension to circumvent poor cooling ability of stallions, 384
Sports horse, ridden horse pain ethogram and the performance of, 316
Stallions
  Sperm epididymal recovery without affecting cryopreservation, 380
  Sperm filter and re-extension to circumvent poor cooling ability, 384
  Manually analyze breeding records, how to, 374
Stanozolol as an intra-articular therapy, how to use, 6
Student debt utilizing the Dave Ramsey method, paying off, 249
Student loans and repayment strategies, navigating, 245
Subchondral lucencies of the medial femoral condyle in yearling and 2-year-old Thoroughbred sales horses, 424
Surgical strangulating lesions of the small intestine, foals, 476
Suspensory ligament in Quarter Horses used for cutting, 436

T

Taking control of cost of goods sold with focused inventory management, 331
Technicians in equine practice, maximizing utilization, 90
Thoracolumbar musculus multifidus structure in the horse, chronic lameness, 288
Thoroughbred Horses
  Biometric wearable sensors to identify subtle gait abnormalities, 355
  Radiological findings in the proximal sesamoid bones of yearling and 2-year-old, 426
  Red cell distribution width values and red cell distribution width to platelet ratio, 243
  Subchondral lucencies of the medial femoral condyle in yearling and 2-year-old, 424
Tomography
  Computed, 166
  Positron emission, 158
Transcondylar lag screw: outcome in 58 Quarter Horses, medial femoral condyle subchondral cysts treated, 457
Triamcinolone acetonide and betamethasone in an equine acute synovitis model, residual anti-inflammatory effects of, intra-articular, 308
Turnover and improving the bottom line, psychological safety is key for reducing, 113

U

Ultrasonographic comparison of the intermediate patellar ligament in warmbloods versus Quarter Horses, 438
Ultrasonography
  Comparison to low-field magnetic resonance imaging of the distal suspensory apparatus, 449
  Power doppler in the horse, how to use, 444
Ultrasound
  Accuracy to detect changes in cervical facet joint effusion, 440

Blinded versus guided low-volume injection, 442
For diagnosis of common soft tissue injuries, use of, 216
Upper and lower respiratory exams in the adult horse, 186
Upright/low-grade club foot with a rocker shoe, 310
Uterus, biofilm in, 27

W

Wellness in equine practice, boundaries, telephone time, 137
Whole blood and plasma equine insulin concentrations using a novel stall-side insulin assay and reference radioimmunoassay, comparison of, 224

Notes

Notes

Notes